


Illustrated Veterinary Anatomical Nomenclature

Edited by
Oskar Schaller

2nd edition



Enke material

This One



FOL7-28C-4163



Enke

Copyrighted material

Illustrated Veterinary Anatomical Nomenclature

Edited by
Oskar Schaller

With the cooperation of
Georghe M. Constantinescu, Robert E. Habel,
Wolfgang O. Sack, Oskar Schaller,
Paul Simoens, Nestor R. de Vos

2nd edition

280 Plates including 1316 Illustrations

Enke Verlag • Stuttgart

*Bibliografische Information
der Deutschen Nationalbibliothek*

Die Deutsche Nationalbibliothek verzeichnet
diese Publikation in der Deutschen
Nationalbibliografie; detaillierte bibliografische
Daten sind im Internet
über <http://dnb.d-nb.de> abrufbar.

First edition 1992

© 2007 Enke Verlag in
MVS Medizinverlage Stuttgart GmbH & Co. KG
Oswald-Hesse-Str. 50, 70469 Stuttgart, Germany

Our Homepage: www.enke.de

Printed in Germany

Cover design: Thieme Verlagsgruppe
Illustrations by Dr. Georghe M. Constantinescu,
Adrian Cornford, William P. Hamilton, Lewis
Sadler, Dr. Paul Simoens
Typesetting by Druckhaus Götz GmbH,
Ludwigsburg
Linotype System 5 (202), 8.5/9 pt Times
Printed by Druckhaus Götz GmbH, Ludwigsburg

ISBN 978-3-8304-1069-0

2 3 4 5 6

This book, including all parts thereof, is legally
protected by copyright. Any use, exploitation, or
commercialization outside the narrow limits set
by copyright legislation, without the publisher's
consent, is illegal and liable to prosecution. This
applies in particular to photostat reproduction,
copying, mimeographing, preparation of micro-
films, and electronic data processing and storage.

Preface

The *Nomina Anatomica Veterinaria* (N.A.V.) constitute the first internationally recognized list of terms serving the gross anatomy of the domestic animals, specifically the cat, dog, pig, ox, sheep, goat, and horse. The N.A.V. were first published in 1968 by the International Committee on Veterinary Anatomical Nomenclature (I.C.V.A.N.) which was appointed by the World Association of Veterinary Anatomists. The third edition appeared in 1983. The present work already includes the changes that have been approved for the fourth edition of the N.A.V. This was possible because the authors are either members or chairmen of subcommittees of the International Committee on Veterinary Gross Anatomical Nomenclature (I.C.V.G.A.N.).

The *Nomina Anatomica Veterinaria* are 6,545 Latin terms (synonyms and terms of structures present only in primates not counted) of which fewer than ten percent are explained in footnotes. Besides, the nine figures illustrating the list are all in the section on the central nervous system. Some terms appear repeatedly; *ramus caudalis* and *tunica muscularis*, for instance, 13 times each.

Similar circumstances with the *Nomina Anatomica* (N.A.) of human anatomy prompted HEINZ FENEIS in 1967 to publish an illustrated anatomical nomenclature with the original title of "Anatomisches Bildwörterbuch der Internationalen Nomenklatur". The book was well received and subsequently translated into several languages. It proved useful not only to students, teachers, and researchers of anatomy, but also in many other branches of medicine and biology.

The editor of the present *Illustrated Veterinary Anatomical Nomenclature* was Chairman of the International Committee on Veterinary Anatomical Nomenclature (I.C.V.A.N.) from 1965 to 1980 and soon recognized the need for an illustrated version similar to that of FENEIS. He was fortunate in securing as authors outstanding veterinary anatomists who were active in matters of veterinary anatomical nomenclature and were members of the respective subcommittees of the International Committee on Veterinary Gross Anatomical Nomenclature (I.C.V.G.A.N.):

PARTS AND REGIONS OF THE BODY: W. O. SACK, U.S.A., Chairman of the subcommittee;

OSTEOLOGY AND ARTHROLOGY: O. SCHALLER, Austria, former Chairman of the subcommittee;

MYOLOGY: Begun by the late L. E. ST. CLAIR, U.S.A., former Chairman of the subcommittee; continued by O. SCHALLER;

SPLANCHNOLOGY: R. E. HABEL, U.S.A., Chairman of the subcommittee;

ANGIOLOGY: Begun by N. R. DE VOS, Belgium, former Chairman of the subcommittee; continued by P. J. SIMOENS, Belgium, present Chairman of the subcommittee;

NERVOUS SYSTEM: Begun by R. C. McCLURE, U.S.A., Chairman of the subcommittee on *Systema nervosum periphericum*; continued by G. CONSTANTINESCU, U.S.A., member of the subcommittee;

SENSE ORGANS AND INTEGUMENT: W. O. SACK, U.S.A., member of the subcommittee on *Integumentum commune*.

MOREOVER, O. SCHALLER was the Chairman and R. E. HABEL a member of the Editorial Committee for the first edition of the N.A.V., and R. E. HABEL was the Chairman and W. O. SACK was a member of the Editorial Committee for the third edition. The composition of the team of authors thus guarantees that the aims of the International Committee on Veterinary Gross Anatomical Nomenclature (I.C.V.G.A.N.) find expression in the present illustrated version of the list.

The arrangement of text and illustrations—similar to that of the "Feneis"—makes the book easy to use. The left (verso) pages contain numbered terms arranged as in the N.A.V., and each term is followed by a brief definition. The respective illustrations, labeled by numbers that correspond to those of the terms, are on the opposite page. The names of structures, their definition and depiction are therefore easy to find. An index lists all terms alphabetically.

The illustrations were produced by several artists of whom LEWIS SADLER, ADRIAN CORNFORD, and WILLIAM P. HAMILTON are prominent medical illustrators. Dr. P. J. SIMOENS, who contributed the

chapter on Angiologia, and Dr. G. M. CONSTANTINESCU, who contributed the chapter on Systema nervosum, drew most of the figures of those chapters themselves. A few drawings were adopted from other publications for which permission from the respective authors and publishers was obtained and indicated in the legends. The sources are listed under References. Obviously, in many cases the subject matter will be represented by illustrations similar to those in other books, although they were not copied.

I thank the Enke Verlag for publishing this book, but especially Mr. J. NIENDORF, Dr. P. KLEINER, and Mr. D. KOSMIDIS who were directly involved in its production.

Vienna, October 1991

OSKAR SCHALLER

List of Contributors

Professor GEORGHE M. CONSTANTINESCU, D.V.M., Ph.D.

University of Missouri-Columbia, College of Veterinary Medicine, Department of
Veterinary Biomedical Sciences
Columbia, Missouri 65211 USA

Professor ROBERT E. HABEL, D.V.M., M.Sc., M.V.D.

New York State Veterinary College
Cornell University, Department of Anatomy
Ithaca, New York 14853 USA

Professor WOLFGANG O. SACK, D.V.M., Ph.D., Dr. med. vet.

New York State Veterinary College
Cornell University, Department of Anatomy
Ithaca, New York 14853 USA

Professor Dr. Dr. OSKAR SCHALLER

Veterinärmedizinische Universität Wien, Institut für Anatomie
Linke Bahngasse 11, A-1030 Wien

Professor Dr. PAUL SIMEONS

Rijksuniversiteit Gent, Faculteit Diergeneeskunde, Anatomie van de Huisdieren
Casinoplein 24, B-9000 Gent

Professor Dr. NESTOR R. DE VOS

Rijksuniversiteit Gent, Faculteit Diergeneeskunde, Anatomie van de Huisdieren
Casinoplein 24, B-9000 Gent

Contents

Regiones corporis, Regions of the body	2
Osteologia, Osteology	10
Arthrologia, Arthrology	76
Myologia, Myology	98
Bursae et Vaginae synoviales, Synovial bursae and sheaths	132
Splanchnologia, Splanchnology	140
Apparatus digestorius, Digestive apparatus	140
Apparatus respiratorius, Respiratory apparatus	174
Cavum thoracis, Thoracic cavity	192
Apparatus urogenitalis, Urogenital apparatus	194
Organa urinaria, Urinary organs	194
Organa genitalia masculina, Male genital organs	200
Organa genitalia feminina, Female genital organs	212
Perineum	222
Peritoneum [Peritoneum]	226
Glandulae endocrinae, Endocrine glands	230
Angiologia, Angiology	234
Cor, Heart	234
Arteriae, Arteries	242
Venae, Veins	338
Systema lymphaticum, Lymphatic system	402
Lien, Spleen	412
Systema nervosum, Nervous system	414
Systema nervosum centrale, Central nervous system	414
Systema nervosum periphericum, Peripheral nervous system	464
Systema nervosum autonomicum, Autonomic nervous system	502
Organa sensum, Sense organs	510
Integumentum commune, Common integument	544
Partes corporis, Parts of the body	562
Termini generales, General terms	565
References	574
Index	576

Directions for the Use of the Book

The three ways for looking up a specific term are to find it by reference to the body systems which are indicated at the top of each page, by reference to the index, or by consulting the relevant illustrations.

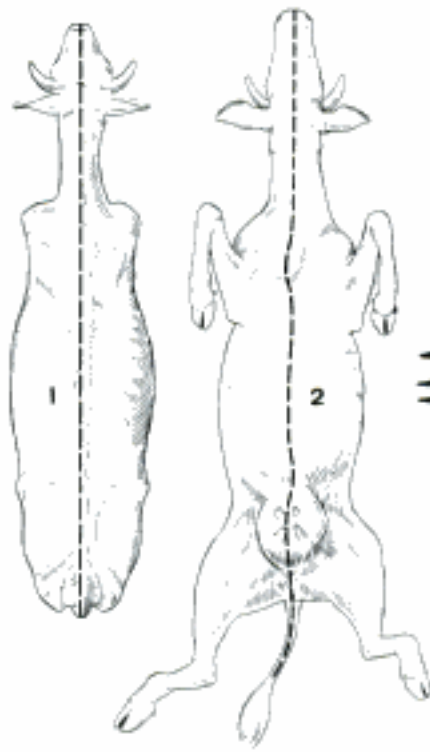
Terms of the index set in italics are embryologic terms. On the text pages different type faces indicate the hierarchy of terms. Official alternatives and explanatory additions are set in square brackets []. Common anatomical variations are enclosed in parentheses (), except in *Systema lymphaticum*, where many of the lymph nodes cited are variable in occurrence. Terms for ontogenetic structures are designated by (ont).

The species of domestic animals considered in the N.A.V. are:

Carnivora	(Car)	Ruminantia	(Ru)
Felis catus	(fe)	Bos taurus	(bo)
Canis familiaris	(ca)	Ovis aries	(ov)
Ungulata	(Un)	Capra hircus	(cap)
Sus scrofa domestica	(su)	Equus caballus	(eq)

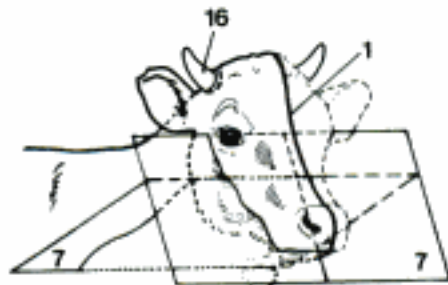
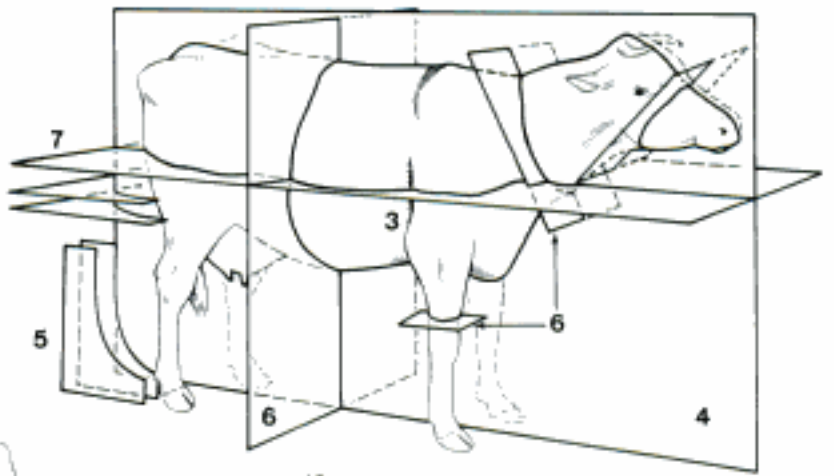
The larger group designations are, of course, restricted in their meaning to the species of domestic mammals designated; for example, "Ungulata" includes only *Sus scrofa domestica*, *Ovis aries*, *Capra hircus*, *Bos taurus* and *Equus caballus*. The term *Artiodactyla*, used in the definitions, means *Sus scrofa domestica* and *Ruminantia* (*Bos taurus*, *Ovis aries*, *Capra hircus*), the term *Carnivora* means *Felis catus* and *Canis familiaris*. When a species designation is listed after a term, it indicates that the structure occurs only in that species among domestic mammals. However, the absence of a species designation does not necessarily mean that the structure is present in all domestic mammals. In the nomenclature of the blood vessels and peripheral nerves it was often necessary to make separate lists for different species. Such lists begin with a heading that gives the species or order in capitals. At the end of the separate list, the nomenclature common to all species is resumed under the heading *TERMINI COMMUNES*.

- 1 *Linea mediana dorsalis*. Dorsal midline. Longitudinal line in the middle of the dorsal surface of head, neck, trunk, and tail. A C
- 2 *Linea mediana ventralis*. Ventral midline. Longitudinal line in the middle of the ventral surface of head, neck, trunk, and tail. A C
- 3 *Margo tricipitalis*. Formed by the caudal border of *M. triceps brachii*. B
- 4 *Planum medianum*. Median plane, dividing the body in two symmetrical halves. B
- 5 *Plana sagittalia [paramediana]*. Sagittal planes, parallel to the median plane. B
- 6 *Plana transversalia*. Transverse planes, at right angles to the longitudinal axis of the body, limbs, or any other organ or part. B
- 7 *Plana dorsalia*. Dorsal planes, parallel to the Dorsum (back) and corresponding surfaces of head, neck, tail, Dorsum manus, and Dorsum pedis. B C
- 8 **Regiones capitis**. Regions on the surface of the head.
- 9 **Regiones cranii**. Cranial regions, regions on the dorsocaudal part of the head.
- 10 *Regio frontalis*. Frontal region, over the frontal bone. In bo it extends caudally to the *Regio occipitalis*. D
- 11 *Regio parietalis*. Parietal region, over the parietal bone. In bo the parietal bone is on the caudal surface of the head. D
- 12 *Regio occipitalis*. Occipital region, over the occipital bone. D
- 13 *Regio temporalis*. Temporal region, over the temporal bone and muscle. D
- 14 *Fossa supraorbitalis*. Supraorbital fossa, the depression caudal to the *Orbita* and dorsal to the *Arcus zygomaticus*. D
- 15 *Regio auricularis*. Auricular region. D
- 16 *Regio cornualis*. Cornual region. C
- 17 **Regiones faciei**. Regions on the rostroventral or facial part of the head.
- 18 *Regio nasalis*. Nasal region. D
- 19 *Regio dorsalis nasi*. Dorsal nasal region. D
- 20 *Regio lateralis nasi*. Lateral nasal region. D
- 21 *Regio naris*. Region surrounding the nostril. D
- 22 *Regio oralis*. Oral region, surrounding the *Rima oris*. D
- 23 *Regio labialis superior*. Region of the upper lip. D
- 24 *Regio labialis inferior*. Region of the lower lip. D E
- 25 *Regio mentalis*. Region of the chin. D E
- 26 *Regio orbitalis*. Orbital region, outlined by the margin of the bony orbit. D
- 27 *Regio palpebralis superior*. Region of the upper eyelid. D
- 28 *Regio palpebralis inferior*. Region of the lower eyelid. D
- 29 *Regio zygomatica*. Zygomatic region, over the *Arcus zygomaticus*, ventral and caudal to the *Orbita*. D
- 30 *Regio infraorbitalis*. Infraorbital region, rostroventral to the *Orbita*. D
- 31 *Regio articulationis temporomandibularis*. Region of the temporomandibular joint, caudal to the *Regio zygomatica*. D
- 32 *Regio masseterica*. Masseteric region, over *M. masseter*. D E
- 33 *Regio buccalis*. Buccal region, between *Regio masseterica* and *Regio oralis*. D E
- 34 *Regio maxillaris*. Maxillary region, over the maxilla, between *Regio buccalis* and *Regio nasalis*. D
- 35 *Regio mandibularis*. Mandibular region, over the *Corpus mandibulae*, ventral to the *Regio buccalis*. D E
- 36 *Regio intermandibularis*. Intermandibular region, between the two mandibles, extending from the *Regio mentalis* to the *Regio subhyoidea*. E
- 37 *Regio subhyoidea*. Subhyoid region, over the *Basihyoideum*, caudal to the *Regio intermandibularis*. E

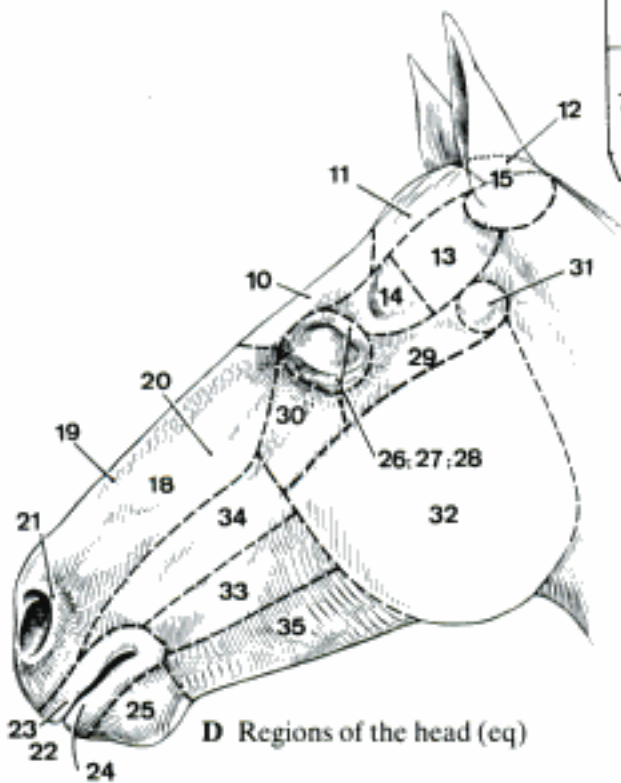


A Dorsal and ventral midlines (bo)

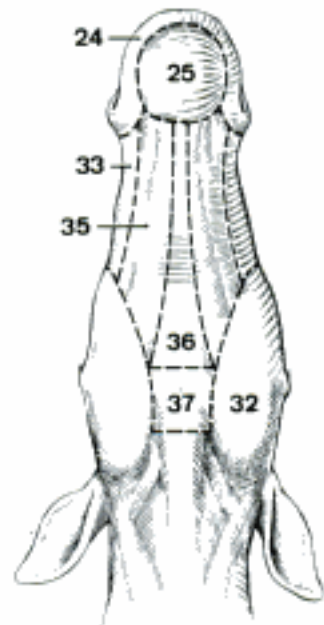
B Planes of the body (bo) (Dyce, Sack, Wensing)



C Dorsal planes on head, neck and thoracic limb (bo)

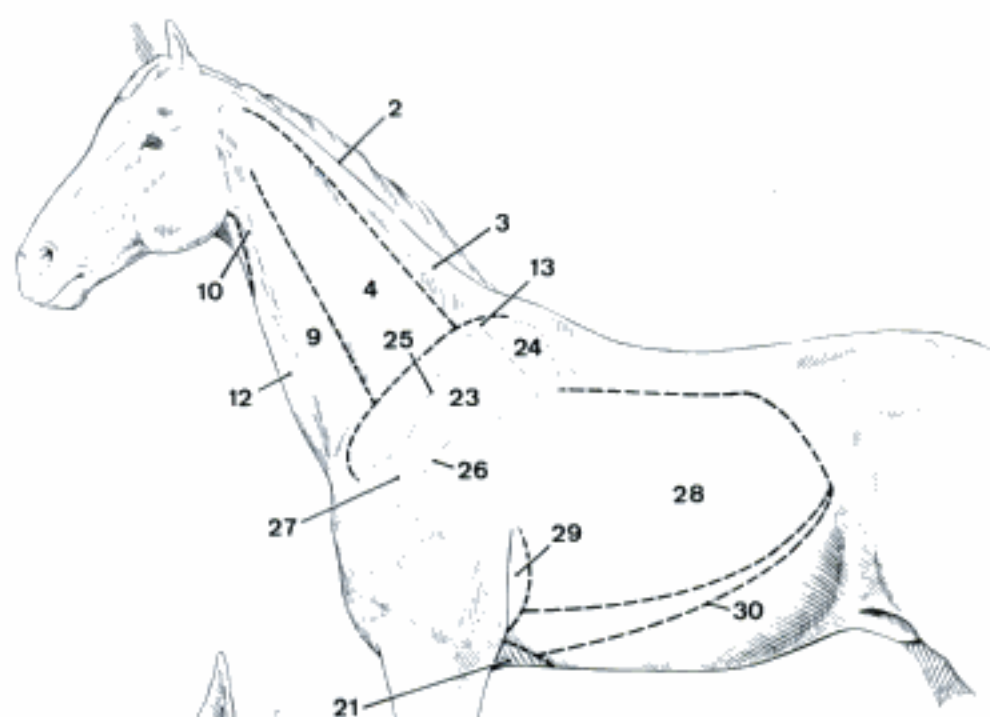


D Regions of the head (eq)

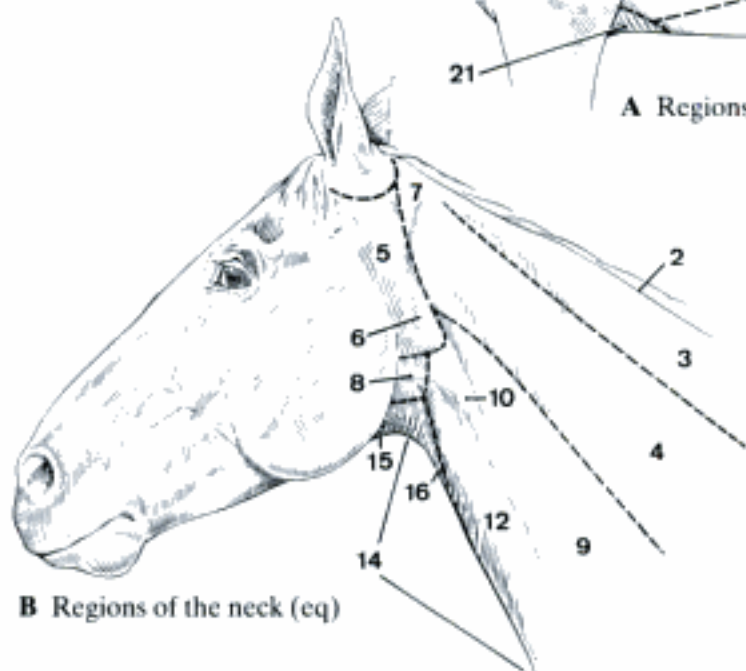


E Regions of the head (eq)

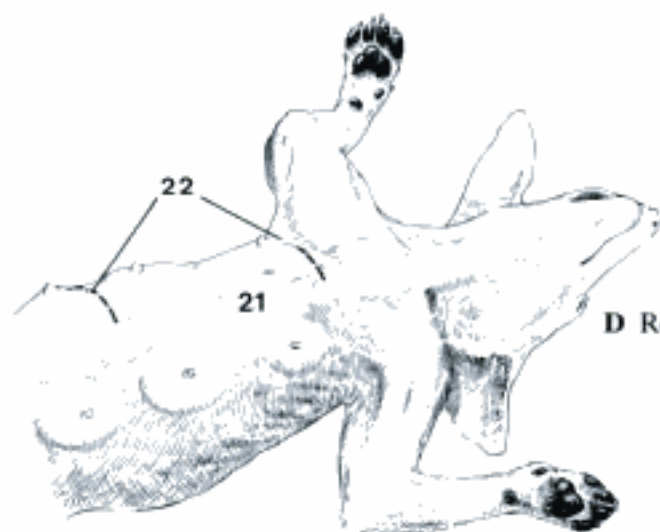
- 1 **Regiones colli.** Neck regions.
- 2 *Margo colli dorsalis.* Dorsal border of the neck, the crest in the horse. A B
- 3 *Regio colli dorsalis.* Dorsal neck region. A B
- 4 *Regio colli lateralis.* Lateral neck region. A B
- 5 *Regio parotidea.* Parotid region, over the parotid gland at the cranial end of the neck. B
- 6 *Fossa retromandibularis.* Retromandibular fossa, the depression in the Regio parotidea, caudal to the mandible and ventral to the Ala atlantis. B
- 7 *Regio retroauricularis.* Retroauricular region. B
- 8 *Regio pharyngea.* Pharyngeal region, over the pharynx between Regio parotidea and Regio laryngea. B
- 9 *Regio brachiocephalica.* Brachiocephalic region, over M. brachiocephalicus, ventral to Regio colli lateralis. A
- 10 *Sulcus jugularis.* Jugular groove, the depression over V. jugularis externa, bounded dorsally by M. brachiocephalicus and ventrally by M. sternocephalicus. A B C
- 11 *Fossa jugularis.* Jugular fossa, the depression at the caudal end of the Sulcus jugularis. C
- 12 *Regio sternocephalica.* Sternocephalic region, over M. sternocephalicus ventral to the Sulcus jugularis. A B C
- 13 *Regio prescapularis [prae-].* Prescapular region, cranial to the scapula at the caudal end of the neck. A
- 14 *Regio colli ventralis.* Ventral neck region, ventral to Regio sternocephalica, and consisting of Regio laryngea and Regio trachealis. B
- 15 *Regio laryngea.* Laryngeal region, on the ventral surface of the neck between Regio subhyoidea and Regio trachealis. B
- 16 *Regio trachealis.* Tracheal region, the wedge-shaped region over the trachea ventral to the Regio sternocephalica and caudal to Regio laryngea. B C
- 17 **Regiones pectoris.** Regions on the surface of the chest.
- 18 *Regio presternalis [prae-].* Presternal region, over M. pectoralis descendens, between Sulcus pectoralis lateralis and Sulcus pectoralis medianus. C
- 19 *Sulcus pectoralis medianus.* Median pectoral groove. The groove between the right and the left M. pectoralis descendens. D
- 20 *Sulcus pectoralis lateralis.* Lateral pectoral groove, between M. pectoralis descendens and M. brachiocephalicus; in the depth of the groove is the V. cephalica. C
- 21 *Regio sternalis.* Sternal region, over the sternum. A D
- 22 *Regio mammaria thoracica.* Region of the thoracic mammary glands in Car and su. D
- 23 *Regio scapularis.* Scapular region, over the scapula. A
- 24 *Regio cartilaginis scapulae.* Region of the scapular cartilage. A
- 25 *Regio supraspinata.* Supraspinatus region, over M. supraspinatus. A
- 26 *Regio infraspinata.* Infraspinatus region, over M. infraspinatus. A
- 27 *Regio acromialis.* Acromial region, over the acromion or over the ventral end of the Spina scapulae. A
- 28 *Regio costalis.* Costal region, over the ribs excluding the costal cartilages. A
- 29 *Regio cardiaca.* Cardiac region, over the heart caudal to the Margo tricipitalis. It can be enlarged by advancing the thoracic limb. A
- 30 *Arcus costalis.* Costal arch, formed by the Cartilagine costales of the asternal ribs and connecting the ventral end of the last rib with the sternum. A



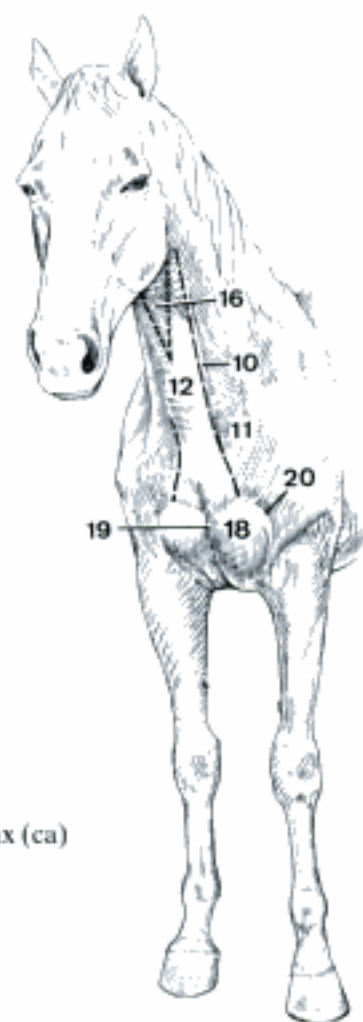
A Regions of the neck and thorax (cq)



B Regions of the neck (cq)

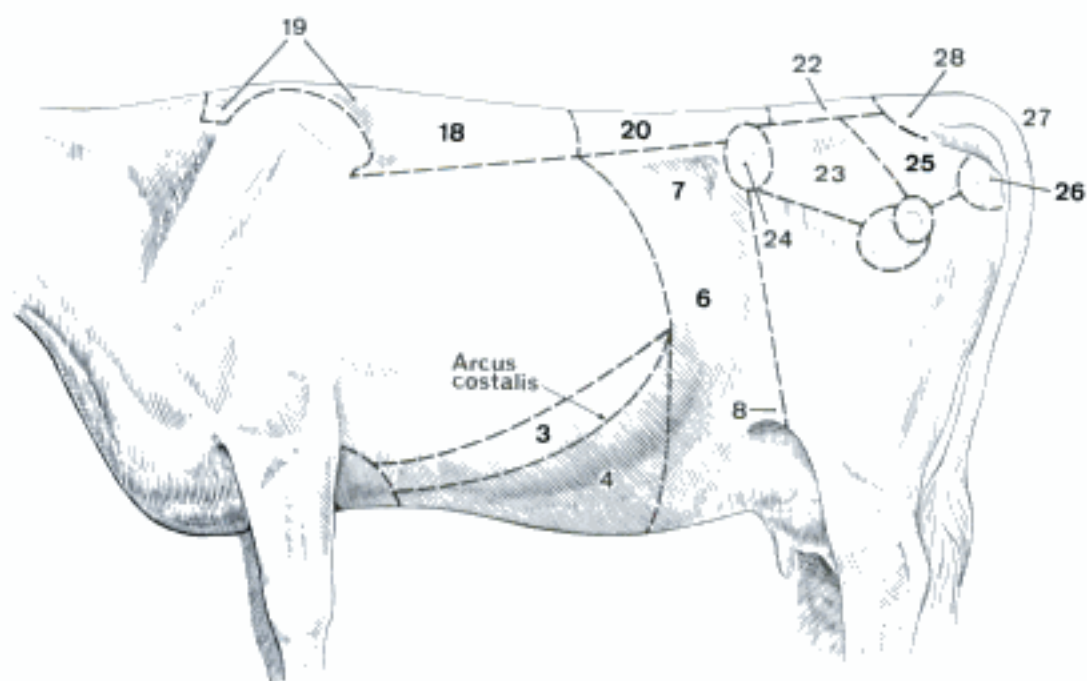


D Regions of the thorax (ca)

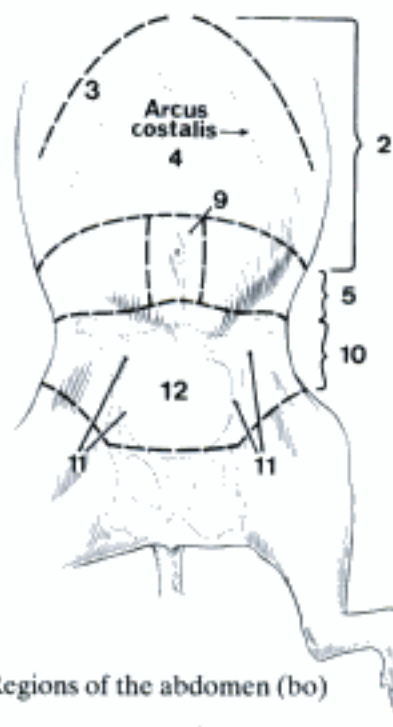


C Regions of the neck and cranial thorax (cq)

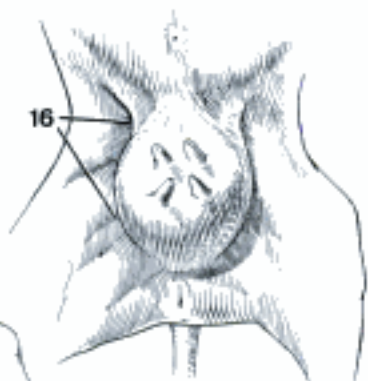
- 1 **Regiones abdominis.** Regions on the surface of the abdomen.
- 2 *Regio abdominis cranialis.* Cranial abdominal region, consisting of *Regio hypochondriaca* (dextra et sinistra) and *Regio xiphoidea*. B
- 3 *Regio hypochondriaca.* Hypochondriac region, the band of abdominal wall over the costal cartilages. A B
- 4 *Regio xiphoidea.* Xiphoid region, the ventral surface of the abdomen between the *Arcus costales*, extending to the level of the ventral end of the last rib. A B
- 5 *Regio abdominis media.* Middle abdominal region, consisting of *Regio abdominis lateralis* (dextra et sinistra) and *Regio umbilicalis*. B
- 6 *Regio abdominis lateralis.* Lateral abdominal region, flank, extending to the level of the *Tuber coxae*. A
- 7 *Fossa paralumbalis.* Paralumbal fossa, bounded dorsally by the lumbar transverse processes, ventrally by the part of *M. obliquus abdominis internus* passing from the *Tuber coxae* to the last rib, and cranially by the last rib. A
- 8 *Regio plicae lateris.* Region of the fold of the flank. A
- 9 *Regio umbilicalis.* Umbilical region. B
- 10 *Regio abdominis caudalis.* Caudal abdominal region, the ventral surface of the abdomen between the folds of the flank, and extending from the *Regio abdominis media* to the *Pecten ossis pubis*. B
- 11 *Regio inguinalis.* Inguinal region, lateral to the *Regio pubica*. B C
- 12 *Regio pubica.* Pubic region, cranial to *Os pubis*, between right and left *Regiones inguinales*. B C
- 13 *Regio preputialis* [prae-]. Preputial region. C
- 14 *Regio mammaria abdominalis.* Region of the abdominal mammary glands in *Car* and *su*. E
- 15 *Regio mammaria inguinalis.* Region of the inguinal mammary glands. E
- 16 *Regio uberis.* Region of the udder. D
- 17 **Regiones dorsii.** Regions on the surface of the back.
- 18 *Regio vertebralis thoracis* [*Reg. dorsocostalis*]. Region of the thoracic vertebrae, extending from the *Regio colli dorsalis* to the *Regio lumbalis*. A
- 19 *Regio interscapularis.* Interscapular region, between the dorsal borders of the scapulae or of the *Cartilagine scapulae*. Owing to the length of the *Processus spinales* in large domestic mammals, it forms a high ridge, the withers. A
- 20 *Regio lumbalis.* Lumbar region, over the lumbar vertebrae. A
- 21 **Regiones pelvis.** Regions on the surface of the pelvis.
- 22 *Regio sacralis.* Sacral region, over the *Os sacrum*. A
- 23 *Regio glutea* [*glutaea*]. Gluteal region, over the *M. gluteus medius*, caudal to the *Regio tuberis coxae*. A
- 24 *Regio tuberis coxae.* Region of the *Tuber coxae*. A
- 25 *Regio clunis.* The caudal end of the rump, lateral to the *Radix caudae*. A
- 26 *Regio tuberis ischiadici.* Region of the *Tuber ischiadicum*. A F
- 27 *Regio caudalis.* Tail region. A F
- 28 *Regio radice caudae.* Region of the root of the tail. A
- 29 *Regio perinealis.* Perineal region. F
- 30 *Regio analis.* Anal region, surrounding the anus. F
- 31 *Regio urogenitalis.* Urogenital region, ventral to the *Regio analis* and between the thighs. In the male of most species it extends to the caudal attachment of the scrotum, but, owing to the short distance between the scrotum and the anus in *fe* and *su*, includes the scrotum in these species. C F
- 32 *Regio scrotalis.* Scrotal region. C
- 33 *Regio supramammaria.* Supramammary region, in *Ru* and *eq* the region dorsal to the caudal attachment of the udder. F



A Dorsal, abdominal, and pelvic regions (bo)

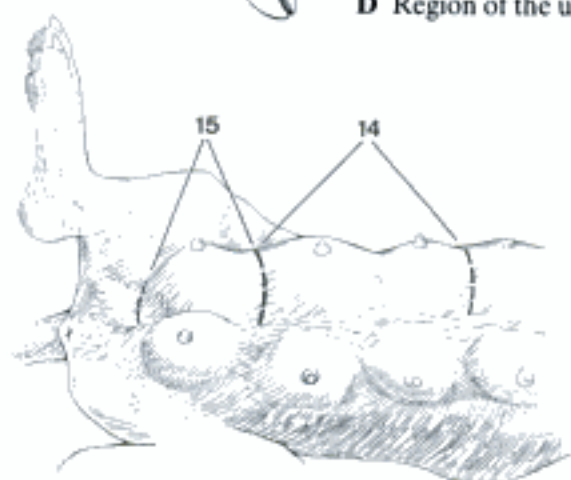
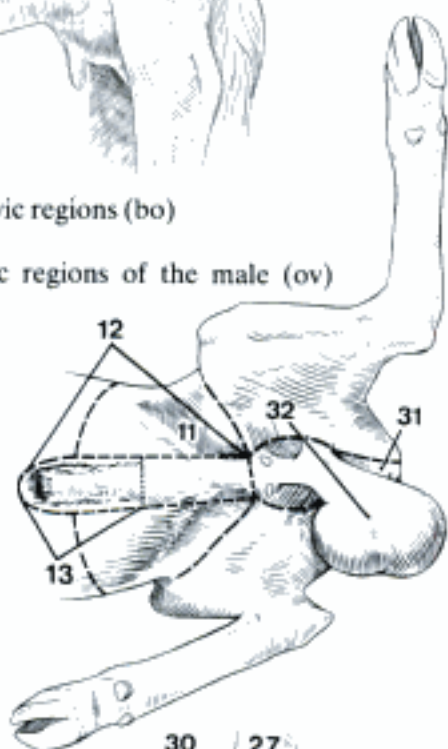


B Regions of the abdomen (bo)

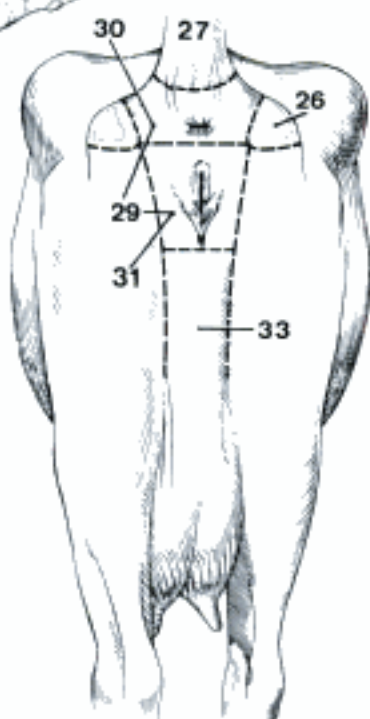


D Region of the udder (bo)

C Abdominal and pelvic regions of the male (ov)
(Dyce, Sack, Wensing)

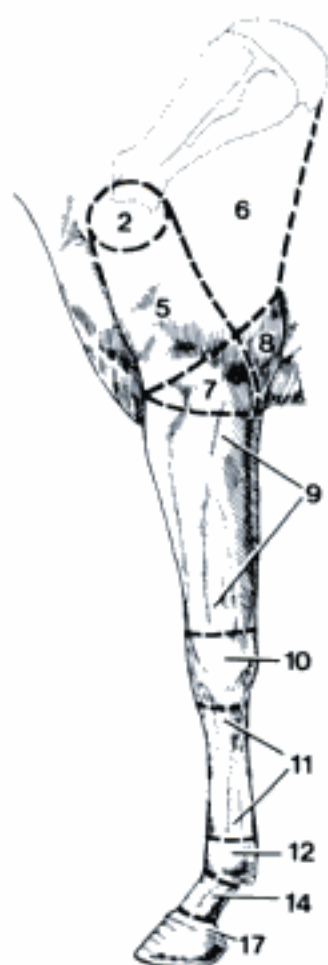


E Abdominal regions of the female (ca)

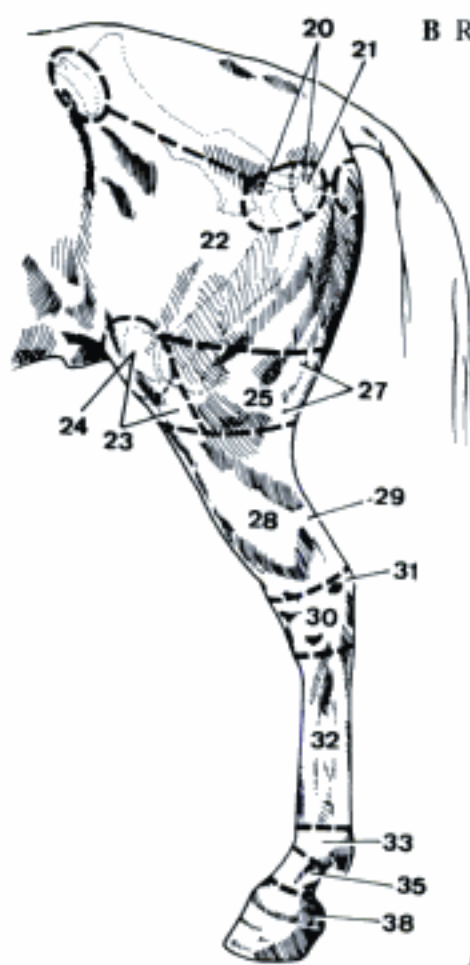


F Regions of the pelvis (bo)

- 1 **Regiones membri thoracici.** Regions on the surface of the thoracic limb.
- 2 *Regio articulationis humeri.* Shoulder joint region. A
- 3 *Regio axillaris.* Axillary region. F
- 4 *Fossa axillaris.* Axillary fossa, the depression between arm and thorax. F
- 5 *Regio brachii.* Brachial region, on the arm distal to the *Regio articulationis humeri.* A F
- 6 *Regio tricipitalis.* Triceps region, over *Caput longum m. tricipitis brachii.* A F
- 7 *Regio cubiti.* Region of the elbow joint, distal to the *Regio brachii.* A F
- 8 *Regio olecrani.* Olecranon region, distal to the *Regio tricipitalis.* A F
- 9 *Regio antebrachii.* Antebrachial region. A F
- 10 *Regio carpi.* Carpal region. A D F
- 11 *Regio metacarpi.* Metacarpal region. A D
- 12 *Regio metacarpophalangea.* Metacarpophalangeal region, the surface over the *Articulatio metacarpophalangea.* A C D
- 13 *Regio phalangis proximalis.* Proximal phalangeal region. D
- 14 *Regio compedis.* Pastern region, part of the digit of Un between metacarpophalangeal joint and *Regio coronalis.* A C
- 15 *Regio interphalangea proximalis.* Proximal interphalangeal region, surrounding the *Articulatio interphalangea proximalis.* D
- 16 *Regio phalangis mediae.* Middle phalangeal region. D
- 17 *Regio coronalis.* Coronal region, slightly raided band of skin that joins the narrower *Regio compedis* to the coronet of the hoof. A C
- 18 *Spatium interdigitale.* Interdigital space. C
- 19 **Regiones membri pelvini.** Regions on the surface of the pelvic limb.
- 20 *Regio articulationis coxae.* Hip joint region. B
- 21 *Regio trochanterica.* Region over the *Trochanter major.* B
- 22 *Regio femoris.* Region of the thigh. B
- 23 *Regio genus cranialis.* Cranial stifle region. B
- 24 *Regio patellaris.* Region of the patella. B
- 25 *Regio genus lateralis.* Lateral stifle region. B
- 26 *Regio genus medialis.* Medial stifle region.
- 27 *Regio poplitea.* Popliteal region, caudal to the stifle. B
- 28 *Regio cruris.* Crural region. B
- 29 *Regio tendinis calcanei communis.* Region of the common calcanean tendon. B
- 30 *Regio tarsi.* Tarsal region. B E
- 31 *Regio calcanea.* Region over the calcaneus. B E
- 32 *Regio metatarsi.* Metatarsal region. B E
- 33 *Regio metatarsophalangea.* Metatarsophalangeal region, the surface over the *Articulatio metatarsophalangea.* B C E
- 34 *Regio phalangis proximalis.* Proximal phalangeal region. E
- 35 *Regio compedis.* Pastern region, part of the digit of Un between metatarsophalangeal joint and *Regio coronalis.* B C
- 36 *Regio interphalangea proximalis.* Proximal interphalangeal region, surrounding the *Articulatio interphalangea proximalis.* E
- 37 *Regio phalangis mediae.* Middle phalangeal region. E
- 38 *Regio coronalis.* Coronal region, slightly raided band of skin that joins the narrower *Regio compedis* to the coronet of the hoof. B C
- 39 *Spatium interdigitale.* Interdigital space. C

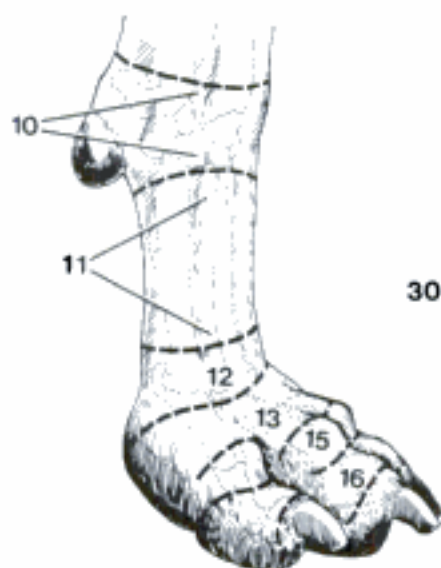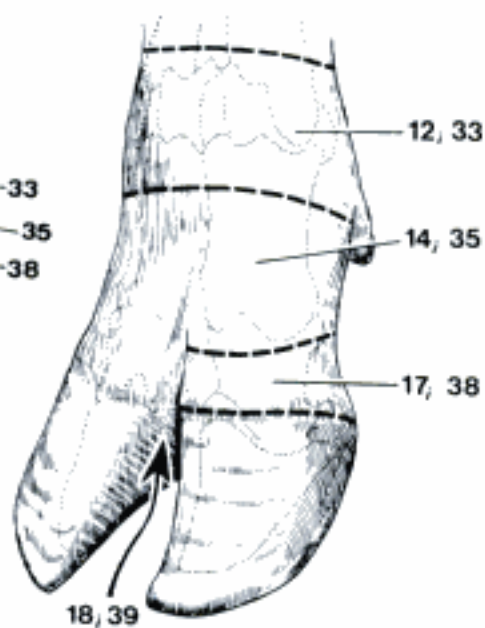


A Regions of the left thoracic limb (cq)

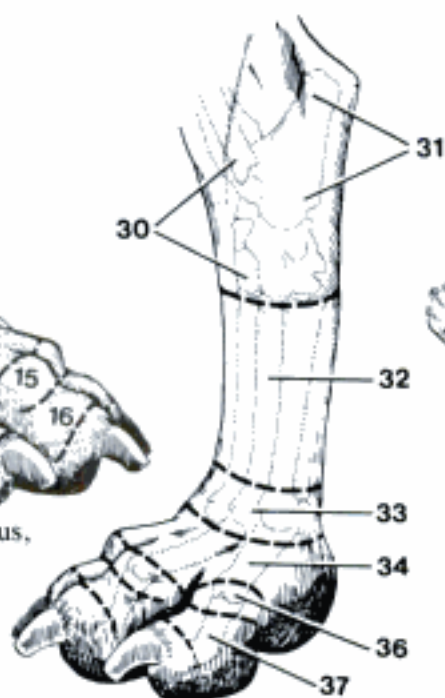

B Regions of the left pelvic limb (eq)

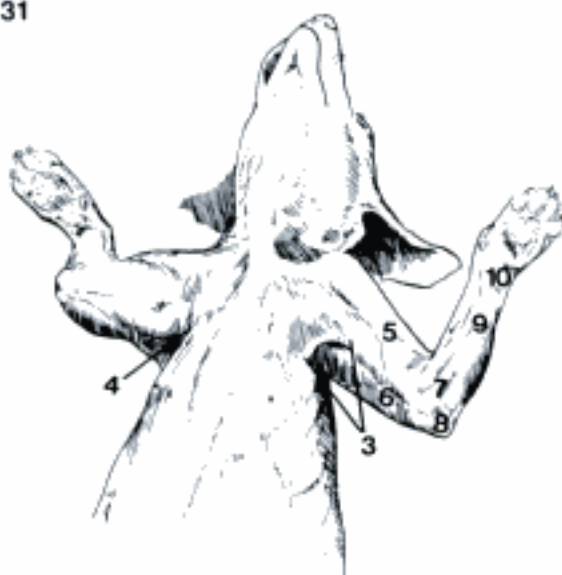C Regions of the digit, dorsolateral aspect (bo)



D Regions of the right manus, dorsolateral aspect (ca)

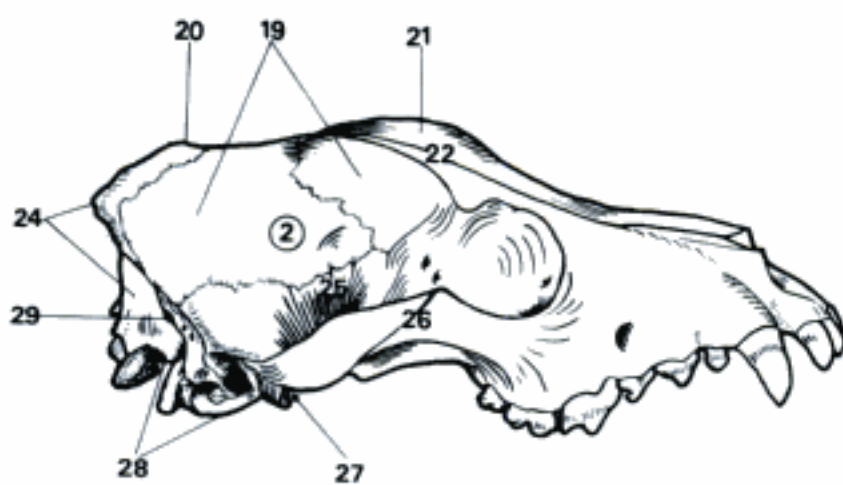


E Regions of the left pes, dorsolateral aspect (ca)

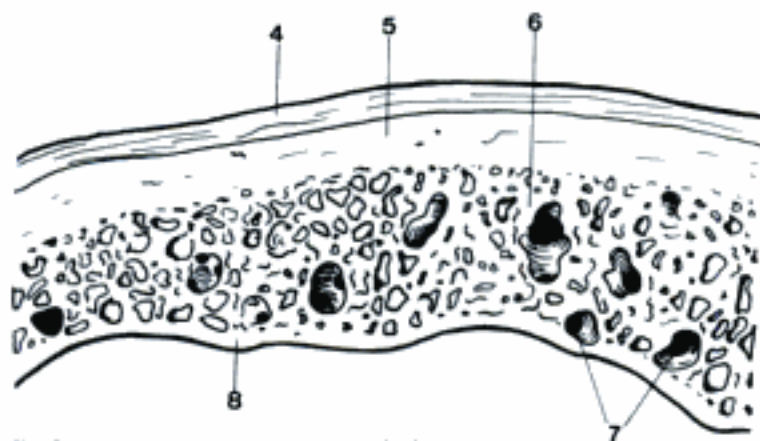


F Regions of the thoracic limb (ca)

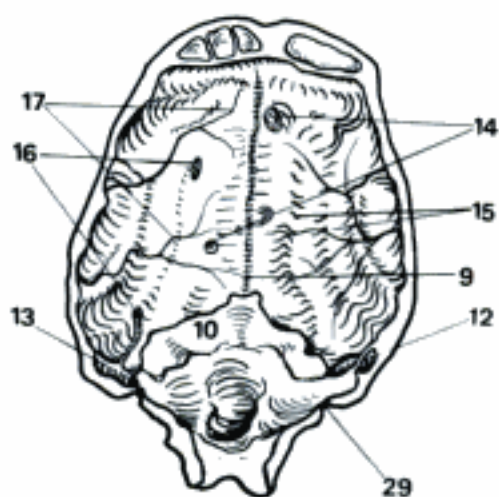
- 1 **SKELETON AXIALE.** Axial skeleton, formed by Ossa cranii, Ossa faciei, Columna vertebralis, and Skeleton thoracis.
- 2 **CRANIUM.** Part of the skull, that encloses the brain (formerly Neurocranium). A
- 3 *Cavum cranii.* Cranial cavity, encloses the brain with its membranes and vessels.
- 4 *Pericranium.* Periosteum on the external surface of the skull. B
- 5 *Lamina externa.* External lamina of cranial bones. B
- 6 *Diploë.* Spongiosa between Lamina externa and Lamina interna of the cranial bones. B
- 7 *Canales diploici.* Venous canals in the diploë. B
- 8 *Lamina interna.* Internal lamina of the cranial bones. B
- 9 *Sulcus sinus sagittalis dorsalis.* Groove for the dorsal sagittal sinus. C
- 10 *Tentorium cerebelli osseum.* Osseous shelf over the dorsal surface of the cerebellum in Car and eq, formed by Processus tentoricus of Os occipitale, Os interparietale and Ossa parietalia. C
- 11 *Eminentia cruciformis.* Cruciform elevation on the inner surface of the Calvaria in su and Ru with the Protuberantia occipitalis interna in the center. D
- 12 *Meatus temporalis.* Temporal meatus, formed by Os temporale and Os parietale (except bo) for the Sinus temporalis, rudimentary in fe and su. C
- 13 *Canalis sinus transversi.* Canal for the transverse sinus in ca and eq in the Tentorium cerebelli osseum. C
- 14 *Foveolae granulares.* Pits for arachnoid granulations on the inner surface of the Calvaria. C
- 15 *Impressiones digitatae.* Shallow grooves accommodating the gyri of the brain. C
- 16 *Sulci venosi.* Grooves for veins on the inner surface of the cranial bones. C
- 17 *Sulci arteriosi.* Grooves for arteries on the inner surface of the cranial bones. C
- 18 (*Ossa suturarum*). Sutural bones, occasionally in the sutures of the skull. F
- 19 *Calvaria.* Roof of the cranium. A B C F
- 20 *Vertex.* Highest part of Calvaria in the normal position of the head. A
- 21 *Frons.* Forehead. A
- 22 *Fossa frontalis.* Shallow depression on the external surface of the Ossa frontalia. A
- 23 *Protuberantia intercornualis.* Thick border, separating nuchal and frontal surfaces of the skull in bo. E
- 24 *Occiput.* A
- 25 *Fossa temporalis.* Temporal fossa, area surrounded by the Linea temporalis. A
- 26 *Arcus zygomaticus.* Zygomatic arch, consisting of the Processus zygomaticus of the temporal bone and the Processus temporalis of the zygomatic bone. A
- 27 *Fossa infratemporalis.* Ventral extension of the Fossa temporalis. A
- 28 *Basis cranii externa.* External surface of the base of the skull. A
- 29 *Foramen mastoideum.* Mastoid foramen, dorsolateral to the Foramen magnum, for blood vessels, absent in su. A



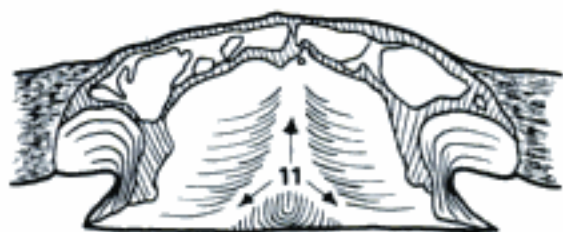A Skull (ca)



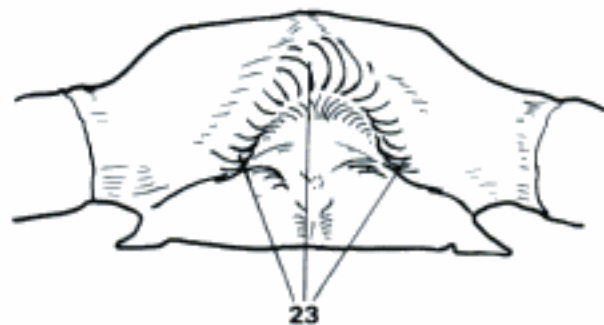
B Calvaria, transverse section (ca)



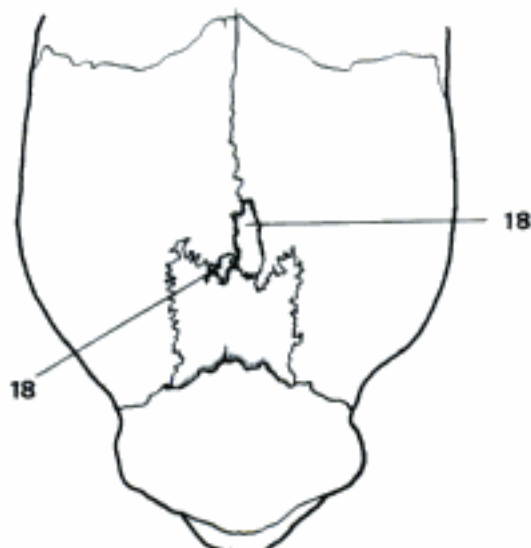
C Calvaria, interior aspect (ca)



D Occiput, interior aspect (bo)



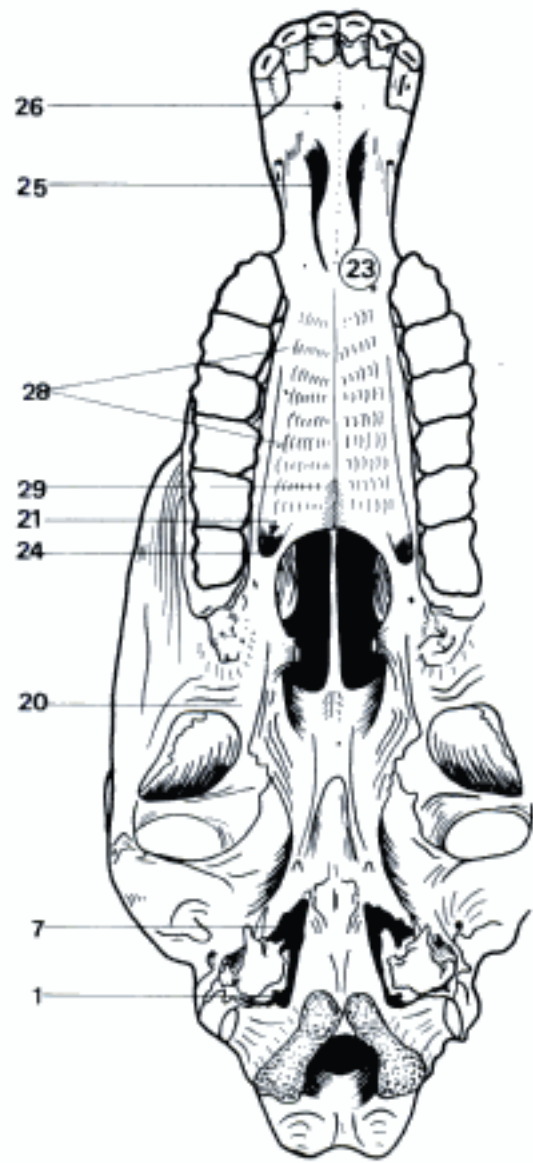
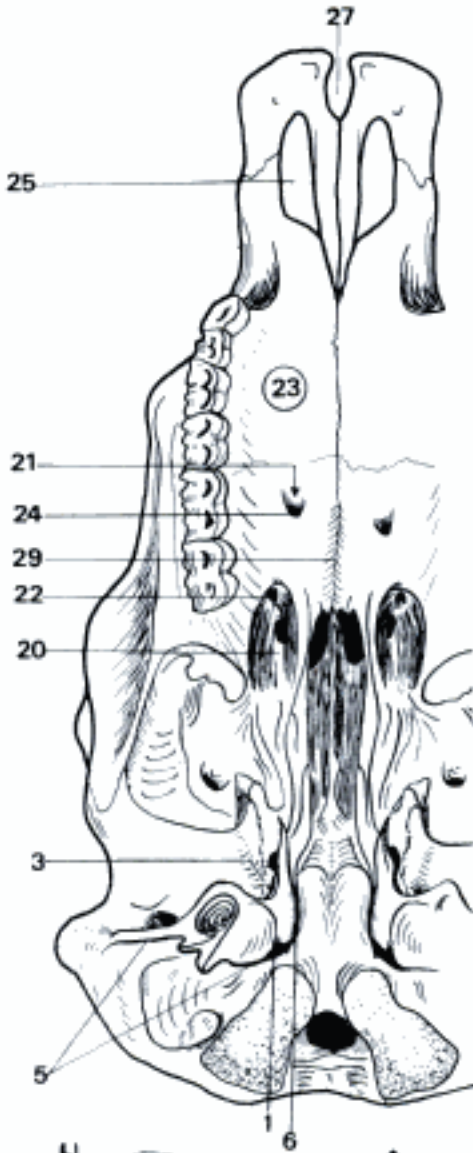
E Calvaria, caudal aspect (bo)



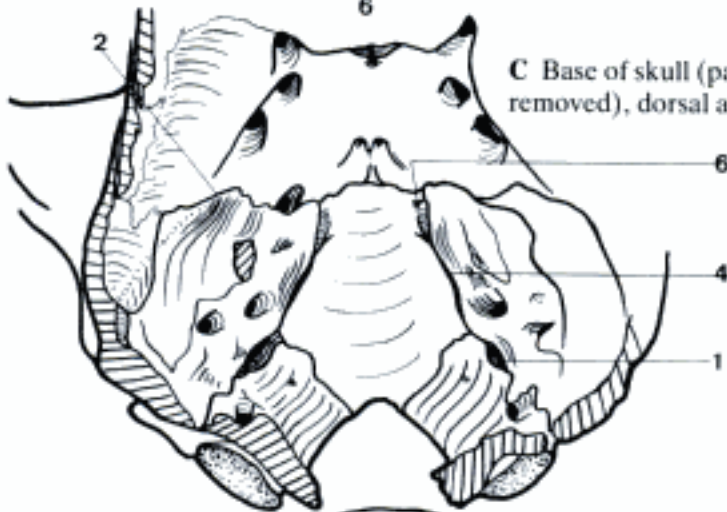
F Calvaria, dorsal aspect (eq, young)

- 1 *Foramen jugulare*. Jugular foramen, between occipital and petrosal bones for passage of cranial nerves IX, X, and XI. A B C
- 2 *Fissura sphenopetrosa (Car)*. Sphenopetrosal fissure, between petrosal and basisphenoid bones. C
- 3 *Fissura sphenotympanica (Car, Ru)*. Sphenotympanic fissure, between Pars tympanica and Os basisphenoidale. A
- 4 *Fissura petrooccipitalis (Car, Ru)*. Petrooccipital fissure, between Pars petrosa and Os occipitale. C
- 5 *Fissura tympanooccipitalis (Car, Ru)*. Tympanooccipital fissure, between Pars tympanica and Os occipitale. A
- 6 *Canalis petrooccipitalis*. Petrooccipital canal, within the Fissura petrooccipitalis for passage of the Sinus petrosus ventralis in ca and Ru. A C
- 7 *Foramen lacerum*. Large opening with irregular border between Os temporale, basisphenoidale, and occipitale in su and eq (formerly Foramen lacerum orale). B
- 8 *Basis cranii interna*. Internal surface of the base of the skull. D
- 9 *Fossa cranii rostralis*. Rostral cranial fossa, between the Laminae cribrosae and the Alae ossis presphenoidalis. D
- 10 *Fossae ethmoidales*. Ethmoidal fossae, for the Bulbi olfactorii. D
- 11 *Fossa cranii media*. Middle cranial fossa, from the caudal borders of the Alae ossis presphenoidalis to the Crista sphenoooccipitalis and the Cristae partis petrosae. D
- 12 *Crista sphenoooccipitalis*. Sphenoooccipital crest. D
- 13 *Fossa cranii caudalis*. Caudal cranial fossa, from the Crista sphenoooccipitalis and Cristae partis petrosae to the Foramen magnum. D
- 14 *Clivus*. Part of the Basis cranii interna between Dorsum sellae and Foramen magnum. D
- 15 *Fonticuli cranii*. Membranous intervals between cranial bones. E
- 16 *Fonticulus frontoparietalis*. Median space between Os frontale and parietale, existing for some time only in small breeds of dogs. E
- 17 *Fonticulus sphenoidalis*. Space between Os frontale, parietale, temporale, and presphenoidale. E
- 18 *Fonticulus mastoideus*. Space between Os parietale, occipitale, and temporale. E
- 19 **FACIES**. Part of the skull that encloses parts of Apparatus digestorius and respiratorius (formerly Splanchnocranium).
- 20 *Fossa pterygopalatina*. Pterygopalatine fossa. Space between Processus pterygoideus of Os basisphenoidale and Maxilla. A B
- 21 *Canalis palatinus major*. Greater palatine canal, formed by Os palatinum and Maxilla – in bo only by Os palatinum – for A. palatina major and N. palatinus major. A B
- 22 *Foramen palatinum caudale*. Caudal opening of the Canalis palatinus major. A
- 23 *Palatum osseum*. Osseous palate. A B
- 24 *Foramen palatinum majus*. Rostral opening of the Canalis palatinus major. A B
- 25 *Fissura palatina*. Paramedian fissure in the rostral part of the osseous palate. A B
- 26 *Canalis interincisivus*. Median canal between the Ossa incisiva in ca and eq. B
- 27 *Fissura interincisiva*. Median fissure between the Ossa incisiva in su and Ru. A
- 28 *Impressiones rugales*. Impressions on the ventral surface of the osseous palate, caused by Rugae palatinae. B
- 29 *Torus palatinus*. Median longitudinal protuberance, caudally on the ventral surface of the osseous palate. A B

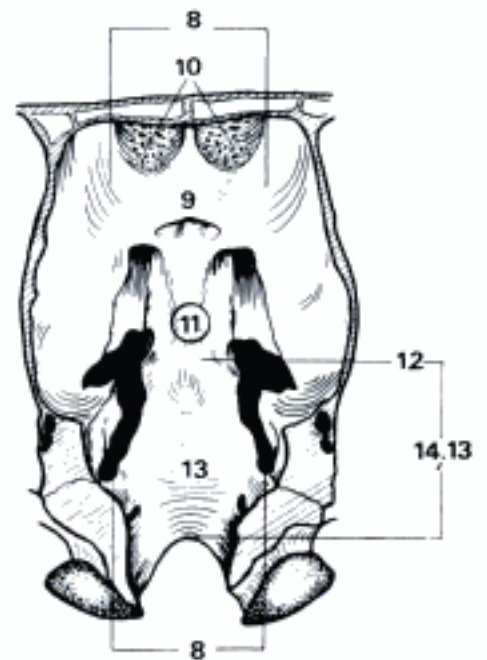
A Base of skull and hard palate (bo)



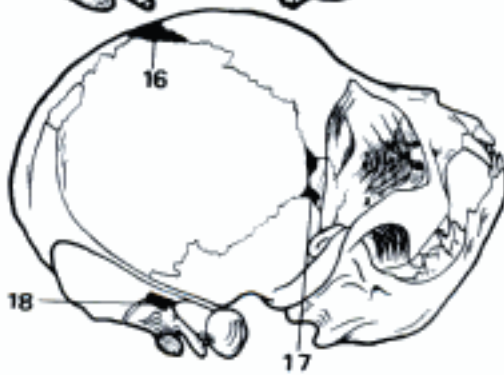B Base of skull and hard palate (eq)



C Base of skull (part of the left petrosal bone removed), dorsal aspect (ca)



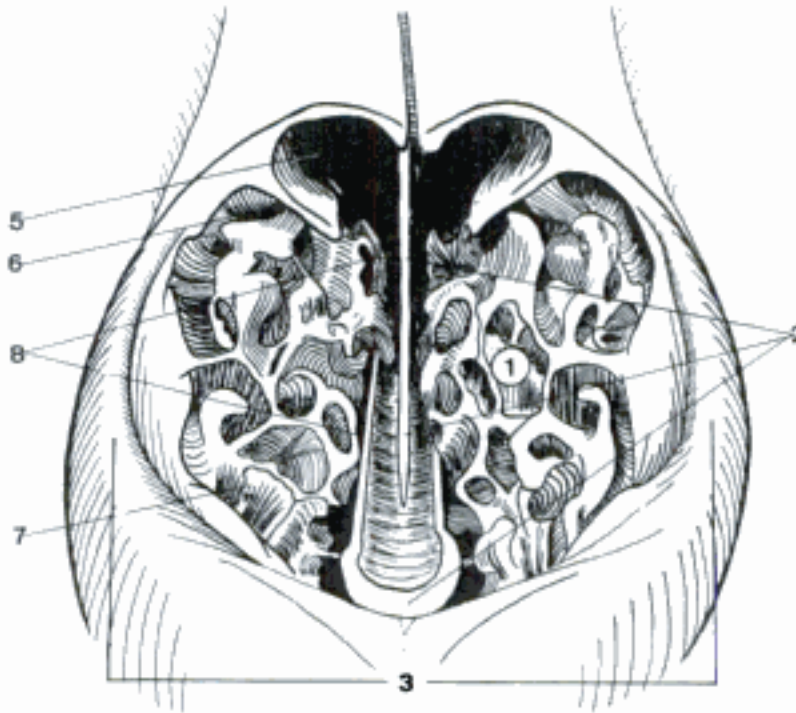
D Base of skull, dorsal aspect (eq)



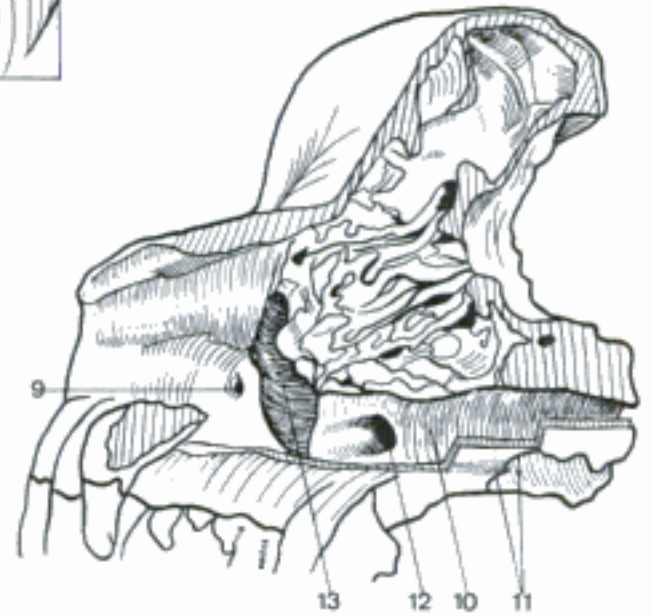
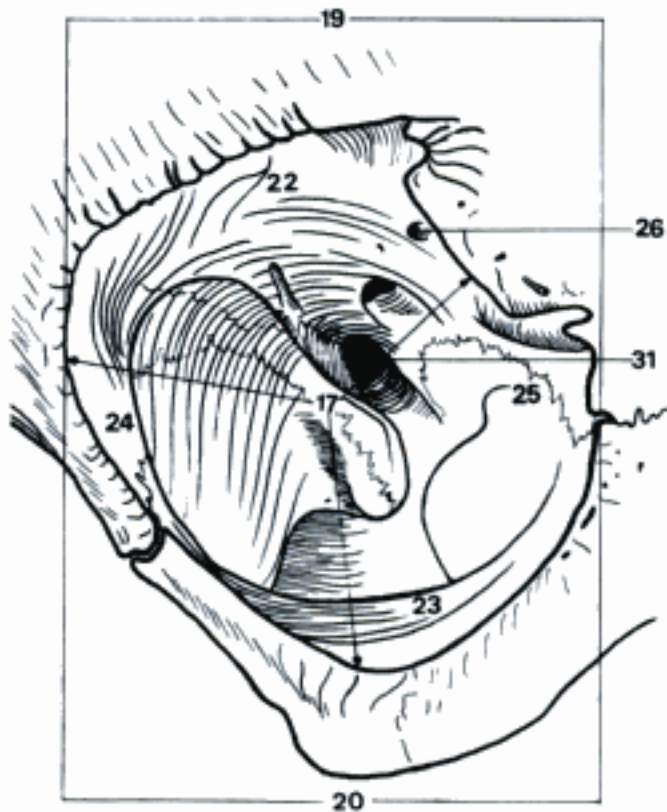
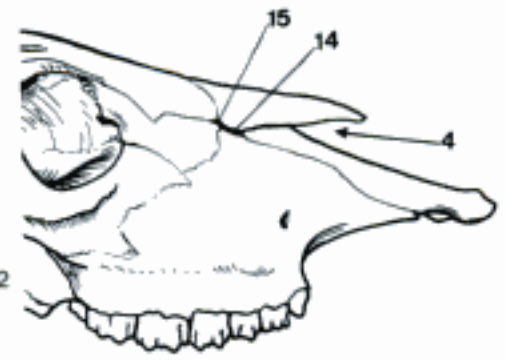
E Skull, right caudodorsal aspect (ca, newborn)

- 1 *Cavum nasi*. Nasal cavity. A
- 2 *Septum nasi osseum*. Osseous nasal septum, composed of Vomer and Lamina perpendicularis ossis ethmoidalis. A
- 3 *Apertura nasi ossea*. Rostral opening of the nasal cavities in the skull. A
- 4 *Incisura nasoincisiva*. Nasoincisive notch, between nasal and incisive bones. B
- 5 *Meatus nasi dorsalis*. Dorsal nasal meatus, situated dorsal to the dorsal concha. A
- 6 *Meatus nasi medius*. Middle nasal meatus, between the dorsal and ventral conchae. A
- 7 *Meatus nasi ventralis*. Ventral nasal meatus, ventral to the ventral concha. A
- 8 *Meatus nasi communis*. Common nasal meatus, space between the nasal septum and the conchae. A
- 9 *Canalis nasolacrimalis*. Nasolacrimal canal, in the lateral wall of the nasal cavity for the nasolacrimal duct. C
- 10 *Meatus nasopharyngeus*. Caudal continuation of Meatus nasi ventralis. C
- 11 *Choanae*. The caudal openings of the nasal cavities. C
- 12 *Foramen sphenopalatinum*. Sphenopalatine foramen, opening of the nasal cavity into the Fossa pterygopalatina. C
- 13 *Recessus maxillaris*. In Car there is no Sinus maxillaris within the Maxilla; the Recessus is bounded medially by the Lamina orbitalis of the Os ethmoidale and laterally by the Maxilla and Os palatinum, in ca also by the Os lacrimale. It is very reduced in fe. C
- 14 *Fissura nasomaxillaris*. Fissure between Os nasale and Maxilla in ov, cap, and sometimes bo. B
- 15 *Fissura nasolacrimalis*. Fissure between Os nasale and Os lacrimale in Ru. B
- 16 *Orbita*. Orbit. D E
- 17 *Aditus orbitae*. Orbital entrance. D E
- 18 *Margo orbitalis*. Orbital margin. E
- 19 *Margo supraorbitalis*. Supraorbital margin, dorsal part of the Margo orbitalis. D E
- 20 *Margo infraorbitalis*. Infraorbital margin, ventral part of the Margo orbitalis. D E
- 21 *Lig. orbitale*. Between Processus temporalis of the Os frontale and Os zygomaticum, forming the lateral part of the Margo orbitalis in Car and su, it is very short in fe. E
- 22 *Paries dorsalis*. Dorsal wall of the orbit. D E
- 23 *Paries ventralis*. Ventral wall of the orbit. D E
- 24 *Paries lateralis*. Lateral wall of the orbit. D
- 25 *Paries medialis*. Medial wall of the orbit. D E
- 26 *Foramen ethmoidale*. Ethmoidal foramen, in medial wall of orbit for like-named nerve and vessels. D
- 27 *Foramina ethmoidalia*. There are usually two Forr. ethmoidalia in ca. E
- 28 *Sulcus lacrimalis*. Groove in Os lacrimale, whose border is formed by the Processus frontalis of the maxilla in fe. F
- 29 *Fossa sacci lacrimalis*. Listed also under Orbita, because in fe it is formed not only by the Os lacrimale, but also by the Processus frontalis of the Maxilla. F
- 30 *Fissura orbitalis*. Orbital fissure, between the wings of the pre- and basisphenoids for nerves and vessels in Car and eq. E
- 31 *Foramen orbitorotundum*. Wide opening by fusion of Fissura orbitalis and Foramen rotundum in su and Ru. D

A Nasal cavities, rostral aspect (ca)

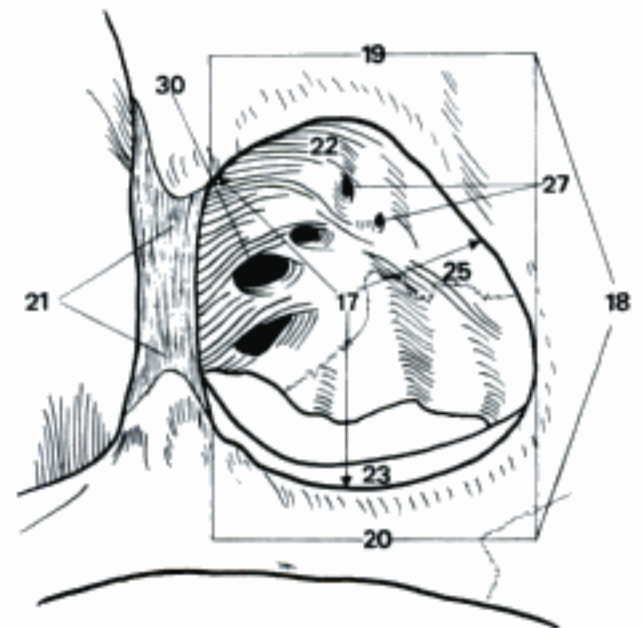
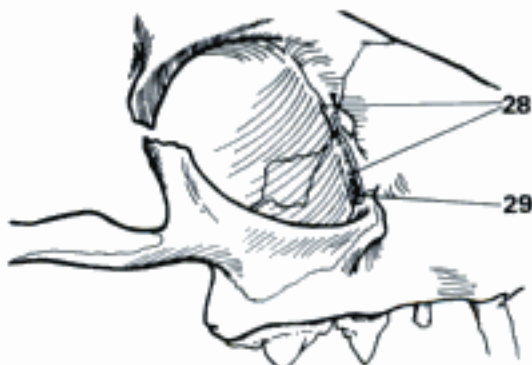

B Right facial bones (bo)



C Lateral wall of right nasal cavity (nasal conchae partly removed), rostromedial aspect (ca)

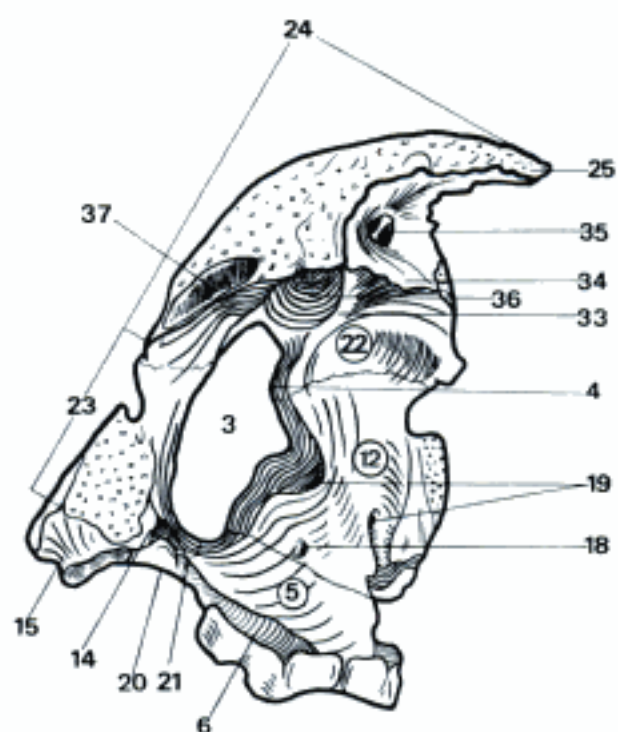
D Right orbit, rostralateral aspect (bo)



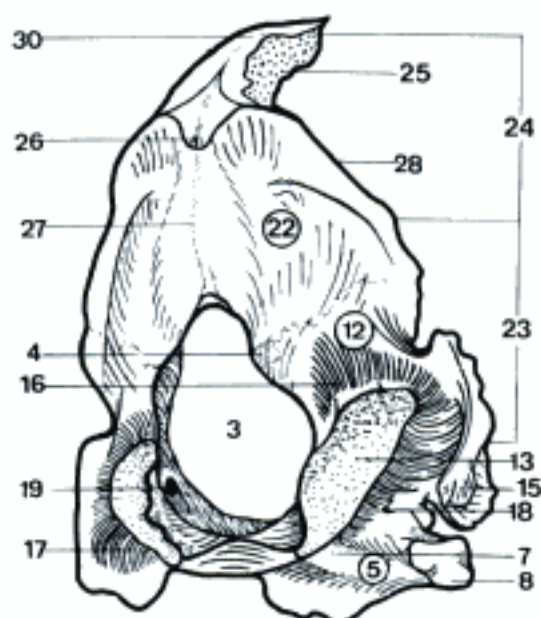
F Right orbit, lateral aspect (fe)

E Right orbit, rostralateral (and dorsal) aspect (ca)

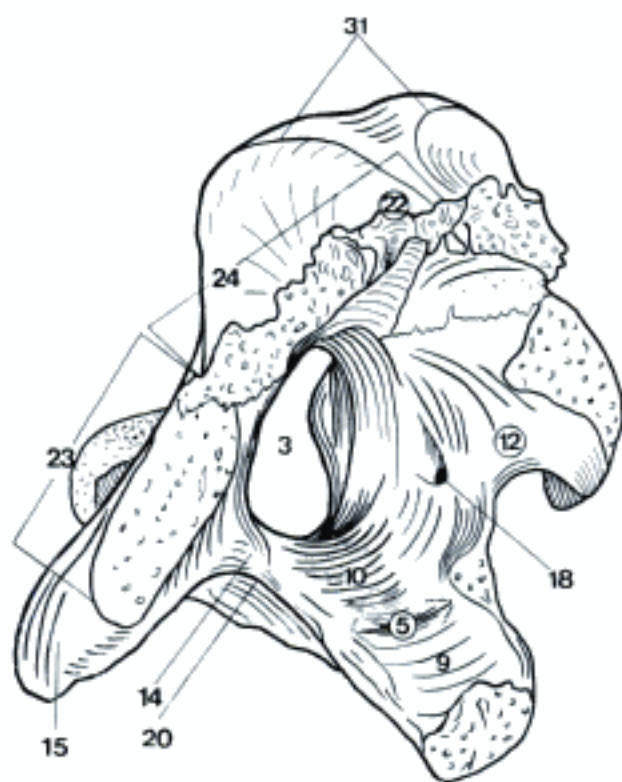- 1 **OSSA CRANII.** Cranial bones.
- 2 **Os occipitale.** Occipital bone. A B C
- 3 *Foramen magnum.* Large foramen for the Medulla oblongata. A B C
- 4 *Tuberculum nuchale.* Tubercle on the dorsolateral border of the Foramen magnum in Car and su. A B
- 5 **Pars basilaris.** Basilar part of Os occipitale. A B C
- 6 *Sulcus sinus petrosi ventralis.* Groove for sinus in Car and Ru. A
- 7 *Tuberculum pharyngeum.* Small median tubercle on the ventral surface of the Pars basilaris in Car. B
- 8 *Tuberculum musculare.* Paramedian tubercle on the ventral surface of the Pars basilaris. B
- 9 *Impressio pontina.* Impression for the pons. C
- 10 *Impressio medullaris.* Impression for the medulla oblongata. C
- 11 *Sinus sphenoidalis.* May excavate also Os occipitale in elder su. D
- 12 **Pars lateralis.** Lateral part of Os occipitale. A B C
- 13 *Condylus occipitalis.* Occipital condyle, for articulation with the atlas. B E
- 14 *Processus jugularis.* Process lateral to the Foramen jugulare, corresponding to a transverse process of a vertebra. A C E
- 15 *Processus paracondylaris.* The Processus jugularis projects laterally from the base of the Condylus occipitalis in man and domestic mammals. From this projects, in domestic mammals, an apophysis for muscular attachment (not homologous with Processus paramastoideus of man). A B C D E
- 16 *Fossa condylaris dorsalis.* Depression dorsal to the Condylus occipitalis. B E
- 17 *Fossa condylaris ventralis.* Depression ventral to the Condylus occipitalis. B
- 18 *Canalis n. hypoglossi.* Canal for the twelfth cranial nerve. A B C D
- 19 *Canalis condylaris.* Canal for the Sinus condylaris, absent in su and eq. A B
- 20 *Incisura jugularis.* Jugular notch for the Foramen jugulare. A C
- 21 *Processus intrajugularis.* A
- 22 **Squama occipitalis.** Dorsal part of Os occipitale. A B C
- 23 *Margo mastoideus.* Mastoid margin, connected with Os temporale. A B C
- 24 *Margo parietalis.* Parietal margin, connected with Ossa parietalia and Os interparietale. A B C
- 25 *Processus interparietalis.* Extends between Ossa parietalia, formed by fusion of Os interparietale with Squama occipitalis in ca. A B
- 26 *Protuberantia occipitalis externa.* Median protuberance on the external surface of the squama. Absent in su. B E
- 27 *Crista occipitalis externa.* Crest from Protuberantia occipitalis externa to Foramen magnum. B E
- 28 *Crista nuchae.* The sharp transverse crest on the external surface of the squama in Car, su and eq. B D
- 29 *Linea nuchae.* Transverse line on the external surface of the squama in Ru. E
- 30 *Crista sagittalis externa.* Median sagittal crest on the dorsal surface of the squama in Car and eq. B
- 31 *Linea temporalis.* The border of the Fossa temporalis, to which the Fascia temporalis is attached. C E
- 32 *Protuberantia occipitalis interna.* In su and Ru. F
- 33 *Crista occipitalis interna.* A
- 34 *Processus tentoricus.* Part of Tentorium cerebelli osseum in ca and eq. A
- 35 *Foramen sinus sagittalis dorsalis.* On the rostral surface of the Processus tentoricus. A
- 36 *Impressio vermialis.* Impression by Vermis cerebelli. A
- 37 *Sulcus sinus transversi.* Groove for the Sinus transversus. A
- 38 *Sinus frontalis caudalis.* Excavates also the squama in su and Ru. D
- 39 *Septum sinuum frontium.* D



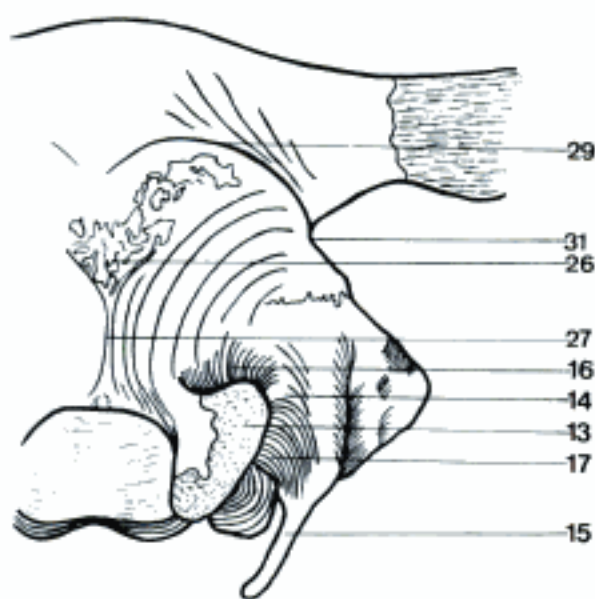
A Os occipitale, right rostral aspect (ca)



B Os occipitale, right caudal aspect (ca)



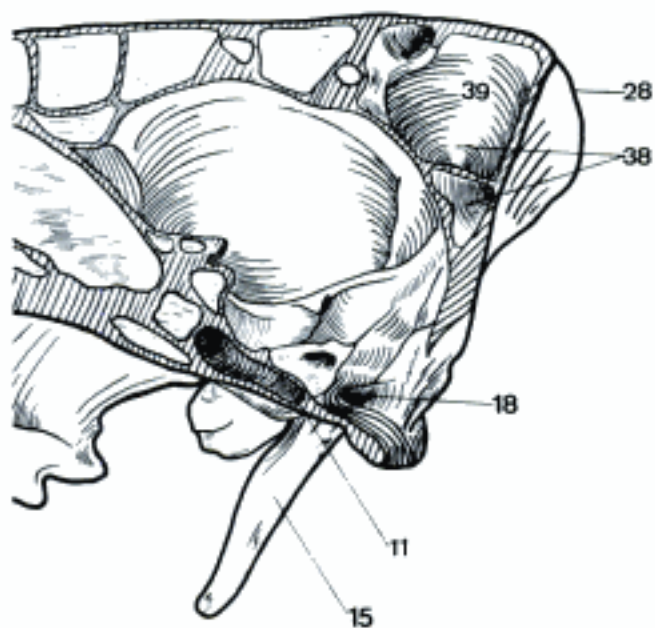
C Os occipitale, right rostradorsal aspect (eq)



E Back of skull, right half, caudal aspect (bo)

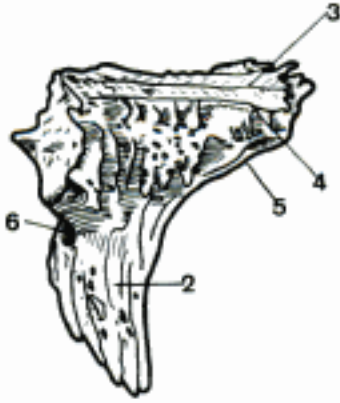


F Calvaria, interior aspect (bo)

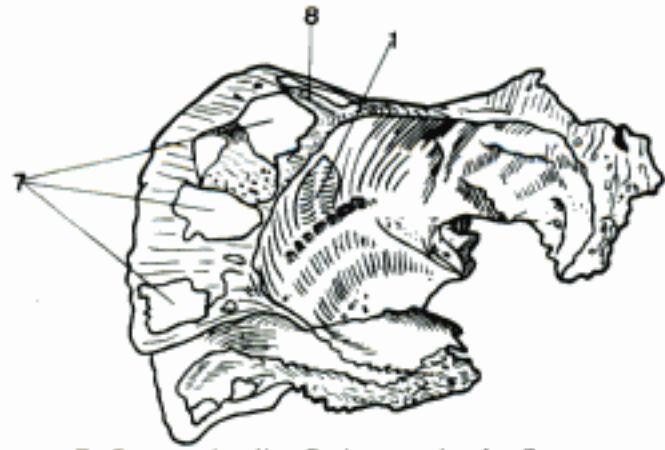


D Cranium, median section (Pars petrosa removed), right half (su)

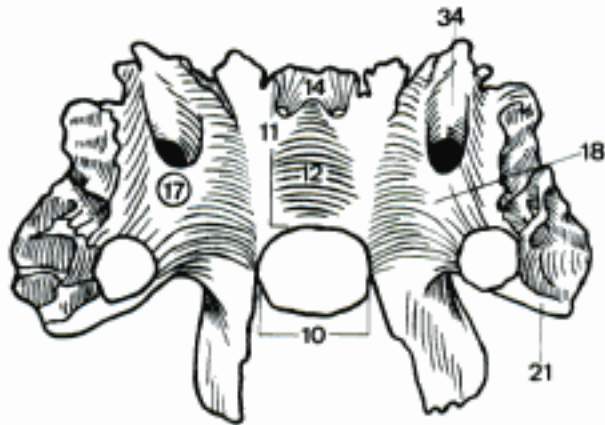
- 1 **Os interparietale.** Interparietal bone, absent on the external surface in su, forms Processus interparietalis of Os occipitale in ca. A B
- 2 *Processus tentoricus.* Part of the Tentorium cerebelli osseum in ca and eq. A
- 3 *Crista sagittalis externa.* Median crest on the external surface in Car and eq. A
- 4 *Linea temporalis.* Temporal line, attachment of the Fascia temporalis in Car and eq. A
- 5 *Crista sagittalis interna.* Median crest on the rostral surface of the Processus tentoricus in ca and eq. A
- 6 *Sulcus sinus transversi.* Groove for the transverse sinus in Car and eq. A
- 7 *Sinus frontalis caudalis.* The frontal sinus may excavate also the Os interparietale in bo. B
- 8 *Septum sinuum frontaliu.* B
- 9 **Os basisphenoidale.** Basisphenoid bone. C D E F
- 10 **Corpus.** Body, median part of Os basisphenoidale. C D E F G
- 11 *Sella turcica.* Dorsal part of the body of the basisphenoid bone. C
- 12 *Fossa hypophysialis.* Central depression in the sella for the hypophysis. C D
- 13 (*Canalis craniopharyngeus*). More or less rudimentary canal between pre- and basisphenoid bones in connection with the development of the Adenohypophysis. Remains in fe, sometimes in ca, cap, and eq, seldom in ov and bo. D
- 14 *Dorsum sellae.* Caudal wall of the Fossa hypophysialis, absent in eq. C G
- 15 *Processus clinoides caudalis.* Process on each side of Dorsum sellae. G
- 16 *Sulcus caroticus.* Groove for A. carotis interna in ca and eq. D
- 17 **Ala.** Wing, lateral part of Os basisphenoidale. C D E F G
- 18 *Facies cerebralis.* Cerebral surface of the Ala, facing the brain. C D
- 19 *Fossa piriformis.* Depression for the caudal part of the Lobus piriformis. D
- 20 *Facies temporalis.* Temporal surface, lateral surface of the Ala. E F
- 21 *Facies maxillaris.* Maxillary surface, facing the Maxilla. C
- 22 *Facies orbitalis.* Orbital surface, facing the Orbita. E F
- 23 *Crista infratemporalis.* Ridge between the laterally and ventrally oriented surfaces of the Ala. E
- 24 *Foramen rotundum.* Round foramen, connecting Cavum cranii and Fossa pterygopalatina, for N. maxillaris, in Car and eq. D G
- 25 *Incisura carotica.* Notch on the caudal border of the Ala which transmits the A. carotis interna in ca and eq. D F
- 26 *Fossa carotica.* Depression on the ventral surface of the Ala for the S-shaped segment of the A. carotis interna in eq. F
- 27 *Foramen ovale.* For passage of the N. mandibularis in Car and Ru. E G H
- 28 *Incisura ovalis.* Notch on the caudal border of the Ala for passage of N. mandibularis in su and eq. D F
- 29 *Foramen spinosum.* For the passage of A. meningea media in Car. H
- 30 *Incisura spinosa.* Notch on the caudal border of the Ala which transmits A. meningea media in su and eq. D F
- 31 *Spina ossis sphenoidalis.* Latero-caudal tip of the Ala. D F
- 32 *Sulcus n. ophthalmici* (Car, eq). Groove for N. ophthalmicus. D
- 33 *Sulcus n. maxillaris* (Car, eq). Groove for N. maxillaris. D
- 34 *Sulcus nn. ophthalmici et maxillaris* (su, Ru). Groove for N. ophthalmicus and N. maxillaris. C
- 35 *Sulcus tubae auditivae.* Groove for the Tuba auditiva on the ventral surface of the Ala, lateral to the root of Processus pterygoideus. E H



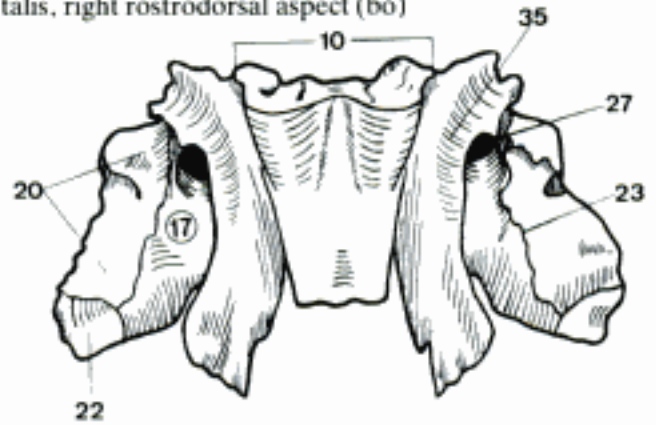
A Os interparietale, right dorsal aspect (eq)



B Ossa parietalia, Os interparietale, Squama occipitalis, right rostradorsal aspect (bo)

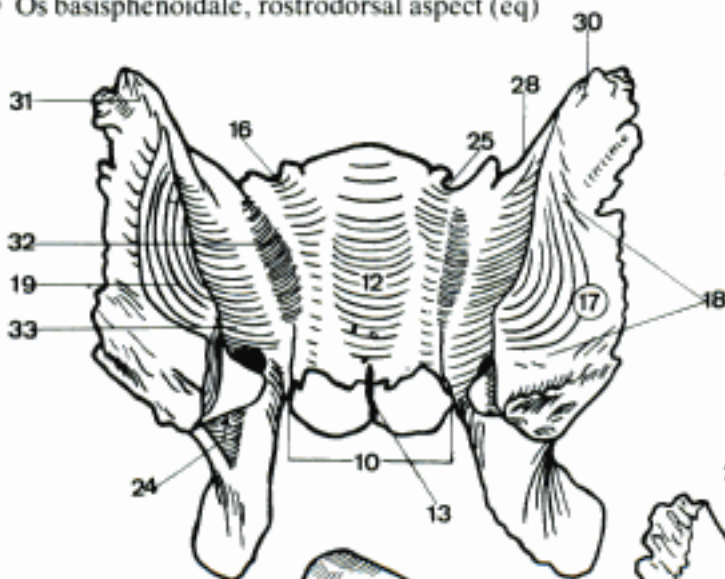


C Os basisphenoidale, rostradorsal aspect (bo)

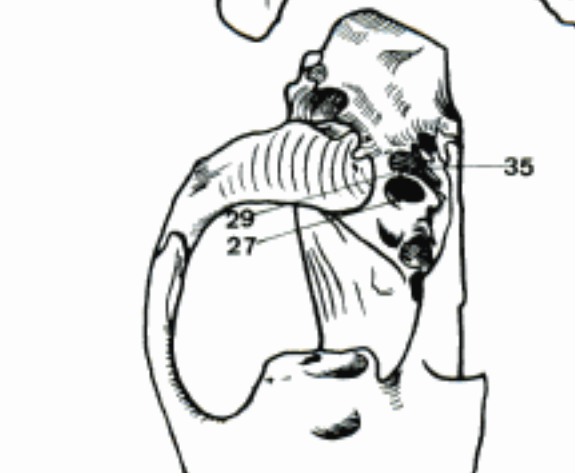


E Os basisphenoidale, ventral aspect (bo)

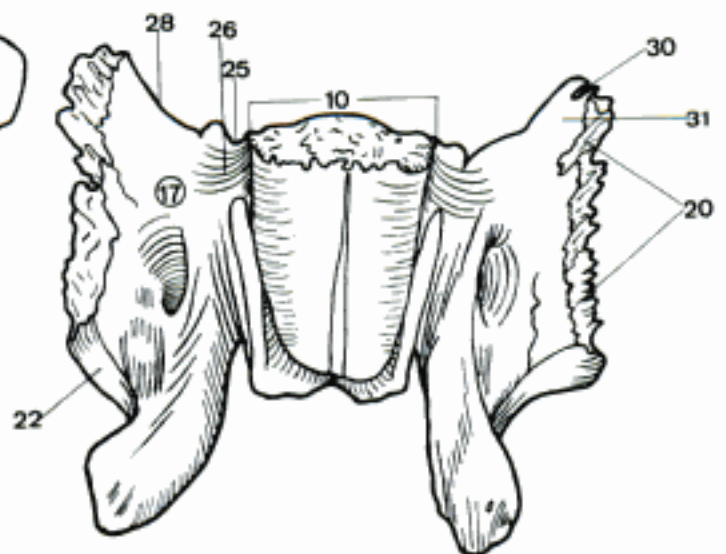
D Os basisphenoidale, rostradorsal aspect (eq)



G Part of base of skull, dorsocaudal aspect (ca)

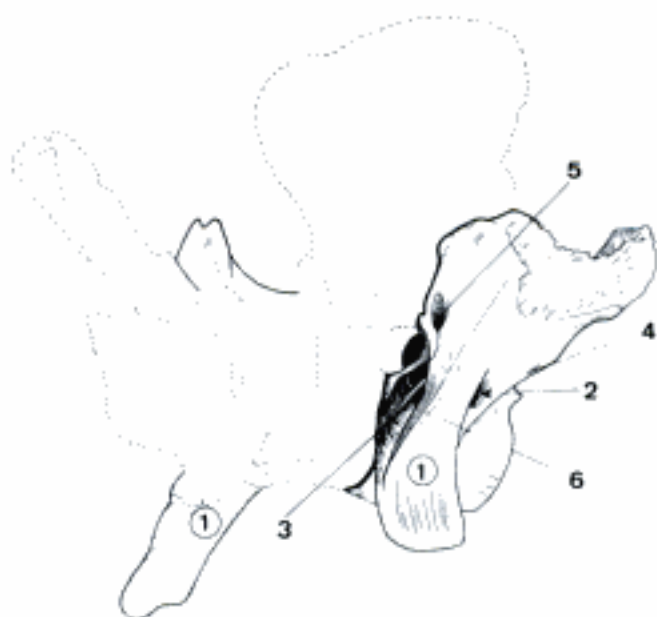

H Part of base of skull, rostroventral aspect (ca)

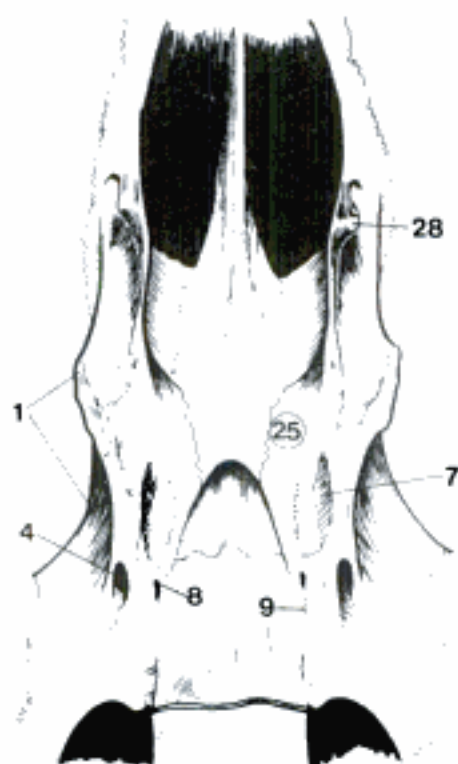


F Os basisphenoidale, ventral aspect (eq)

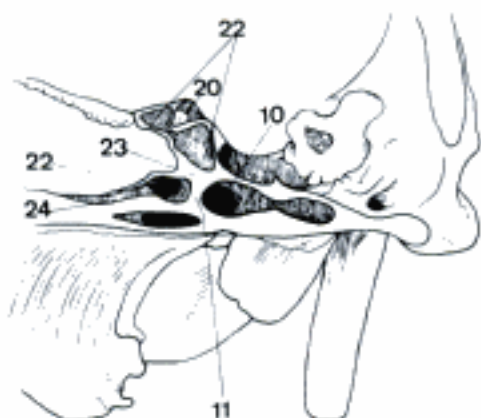
- 1 **Processus pterygoideus.** Pterygoid process of the basisphenoid. A B F
- 2 *Canalis alaris.* Perforates the Processus pterygoideus for passage of the A. maxillaris in ca and eq. A
- 3 *Foramen alare rostrale.* Rostral opening of the Canalis alaris. A
- 4 *Foramen alare caudale.* Caudal opening of the Canalis alaris. A B
- 5 *Foramen alare parvum.* Small alar foramen, for A. temporalis profunda rostralis in eq. A
- 6 *Crista pterygoidea.* Crest continuing the Processus pterygoideus dorsally as border of the Fossa pterygopalatina, absent in Car. A F
- 7 *Fossa scaphoidea.* Depression on the caudal surface of the pterygoid process, dorsal to the Fossa pterygoidea, in su, hardly distinguishable in eq. B F
- 8 *Canalis pterygoideus.* Longitudinal canal through the base of Processus pterygoideus for N. canalis pterygoidei. B
- 9 *Sulcus n. canalis pterygoidei.* Caudal continuation of Canalis pterygoideus between body and pterygoid process of the basisphenoid. B
- 10 **Sinus sphenoidalis.** Excavates in su also the basisphenoid. C
- 11 *Septum sinuum sphenoidalium.* Does not completely separate right and left sinuses. C
- 12 **Os presphenoidale [prae-].** Presphenoid bone. D E
- 13 **Corpus.** Body, median part of Os presphenoidale. D
- 14 *Jugum sphenoidale.* Raised flattened part of the presphenoid, overlying the entrance to the optic canals. D
- 15 *Sulcus chiasmatis.* Chiasmatic groove, between the entrances to the right and left optic canals. D
- 16 *Crista sphenoidalis.* Sphenoid crest. Median ridge on the rostral surface of the presphenoid for attachment of the Lamina perpendicularis of the ethmoid bone. E
- 17 *Rostrum sphenoidale.* Extension of the body of the presphenoid. E
- 18 **Ala.** Wing, lateral part of Os presphenoidale. D E
- 19 *Crista orbitosphenoidalis.* Caudal border of Jugum sphenoidale. D
- 20 *Canalis opticus.* Canal for the optic nerve. C E
- 21 *Processus clinoides rostralis.* Process on the caudal border of the wing of the presphenoid. 19 G
- 22 **Sinus sphenoidalis.** Paired sphenoid sinus, may be absent in Ru. C E
- 23 *Septum sinuum sphenoidalium.* Partition between right and left Sinus sphenoidalis, may be incomplete. C E
- 24 *Apertura sinus sphenoidalis.* Opening of the Sinus sphenoidalis. C
- 25 **Os pterygoideum.** Pterygoid bone. B F
- 26 *Incisura pterygoidea.* Ventrocaudal notch between Os pterygoideum and Processus pterygoideus in su, cap and ov. F
- 27 *Fossa pterygoidea.* Caudal depression between Os pterygoideum and Processus pterygoideus in su. F
- 28 *Hamulus pterygoideus.* Hook-like process at the rostro-ventral end of the Os pterygoideum. B F
- 29 *Sulcus hamuli pterygoidei.* Groove on the lateral surface or rostral border of the Hamulus pterygoideus. F



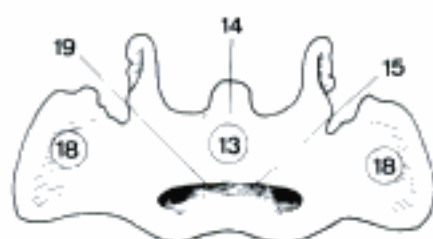
A Os basisphenoidale, left rostral aspect (eq)



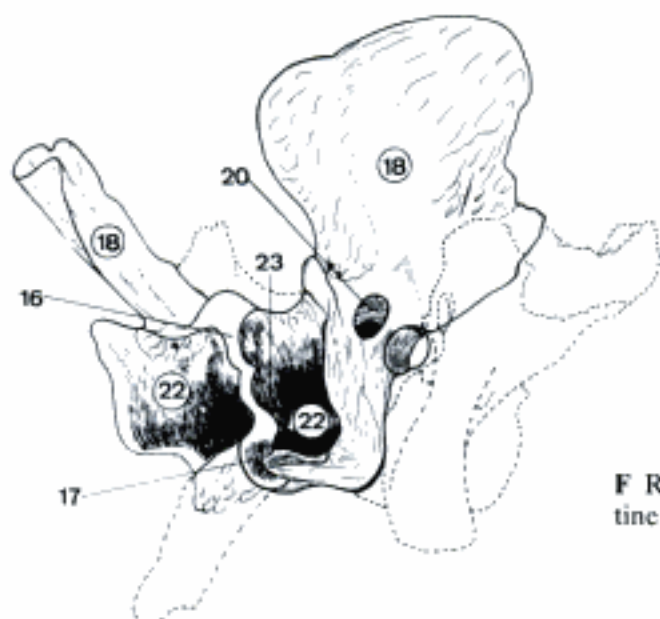
B Part of base of skull, ventral aspect (eq, young)



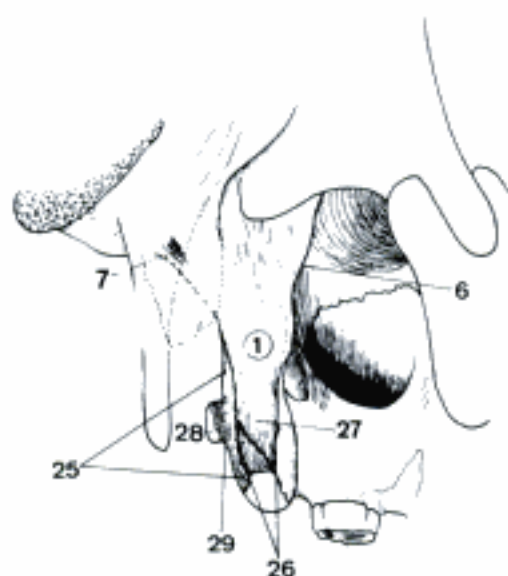
C Part of base of skull, paramedian section, left aspect (su)



D Os praesphenoidale, dorsal aspect (eq)

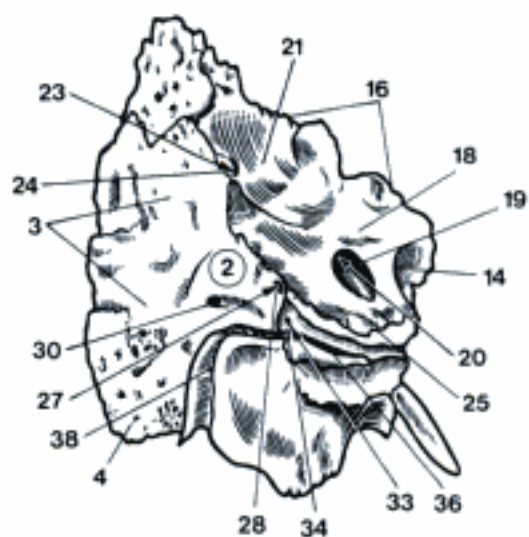


E Os presphenoidale, left rostral aspect (eq)

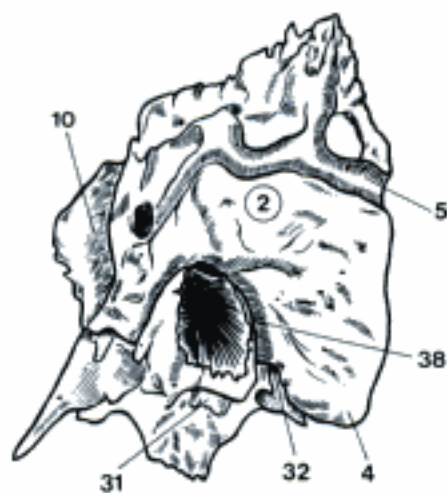


F Right Processus pterygoideus, pterygoid and palatine bones, laterocaudal (and ventral) aspect (su)

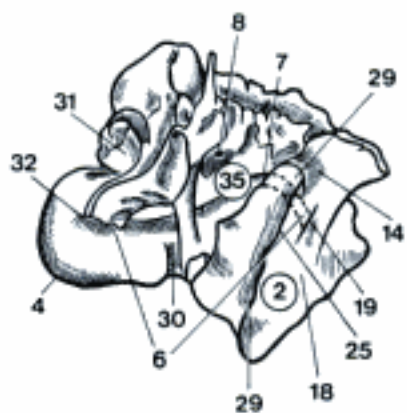
- 1 **Os temporale.** Temporal bone. E
- 2 **Pars petrosa.** Petrous part of the Os temporale, petrosal bone. A B C D E
- 3 *Facies occipitalis.* Surface of the petrosal bone facing the Os occipitale. A
- 4 *Processus mastoideus.* Ventral process, caudal to the external auditory meatus. A B C
- 5 *Sulcus a. meningeae caudalis.* Groove on the lateral surface of the petrosal bone in eq. B
- 6 *Canalis facialis.* Canal for N. facialis, originates in the internal acoustic meatus and terminates at the Foramen stylomastoideum. C
- 7 *Geniculum canalis facialis.* Sharp bend of the facial canal from a lateral to a caudal direction. C
- 8 *Canaliculus chordae tympani.* Narrow passage for the Chorda tympani between facial canal and tympanic cavity. C
- 9 *Apex partis petrosae.* Tip of the petrosal bone directed rostroventrally. D E
- 10 *Facies rostralis partis petrosae.* Rostral surface of the petrosal bone. B D E
- 11 *Tegmen tympani.* Roof of the tympanic cavity. D E
- 12 *Canalis n. petrosi majoris.* Canal in the rostral wall of the petrosal bone for the N. petrosus major. E
- 13 *Canalis n. petrosi minoris.* Canal in the rostral wall of the petrosal bone for the N. petrosus minor. E
- 14 *Impressio n. trigemini.* Depression near the Apex partis petrosae for the Ganglion trigeminale in fe and Un. A C E
- 15 *Canalis n. trigemini.* Canal for Ganglion trigeminale in ca. D
- 16 *Crista partis petrosae.* Sharp crest in ca and eq (low in bo) between rostral and medial surfaces of the petrosal bone. A D E
- 17 *Sulcus sinus petrosi dorsalis.* Groove for the dorsal petrosal sinus in the Crista partis petrosae in Car and eq. D
- 18 *Facies medialis partis petrosae.* Medial surface of the petrosal bone. A C D
- 19 *Porus acusticus internus.* Opening of internal acoustic meatus. A C D
- 20 *Meatus acusticus internus.* Internal auditory canal. A D
- 21 *Fossa cerebellaris.* Large depression dorsal to the Porus acusticus internus for the cerebellum. A
- 22 *Fossa subarcuata.* Deep depression dorsal to the Porus acusticus internus in Car. D
- 23 *Aqueductus [Aquae-] vestibuli.* Canal for the Ductus endolymphaticus. A
- 24 *Apertura externa aq. vest.* External opening of Aqueductus vestibuli. A
- 25 *Margo ventralis partis petrosae.* Ventral border of petrosal bone. A C D
- 26 *Incisura jugularis.* Jugular notch, rostral border of the Foramen jugulare. D
- 27 *Canaliculus cochleae.* Canal for the Ductus perilymphaticus. A
- 28 *Apertura externa canal. coch.* External opening of the Canaliculus cochleae. A
- 29 *Facies ventralis partis petrosae.* Ventral surface of the petrosal bone. C
- 30 *Canaliculus mastoideus.* Canal for Ramus auric. n. vagi. A C
- 31 *Processus styloideus.* Cylindric process in Ru and eq, rough area in Car and su. B C
- 32 *Foramen stylomastoideum.* Opening of the Canalis facialis. B C
- 33 *Canaliculus tympanicus.* Small canal for N. tympanicus. A
- 34 *Fossula petrosa.* Small fossa for the Ganglion distale of N. glossopharyngeus. A
- 35 *Cavum tympani.* Vide Organum vestibulocochleare
- 36 *Fissura petrotympanica.* A E
- 37 *Fissura petrosquamosa.* Cap, ov, su, eq, ossifies in other species. E
- 38 *Fissura tympanomastoidea.* A B
- 39 *Fissura tympanosquamosa.* Cap, ov, eq, ossifies in other species. E



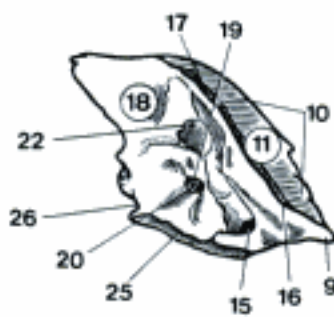
A Petrous and tympanic parts of left temporal bone, caudomedial aspect (eq)



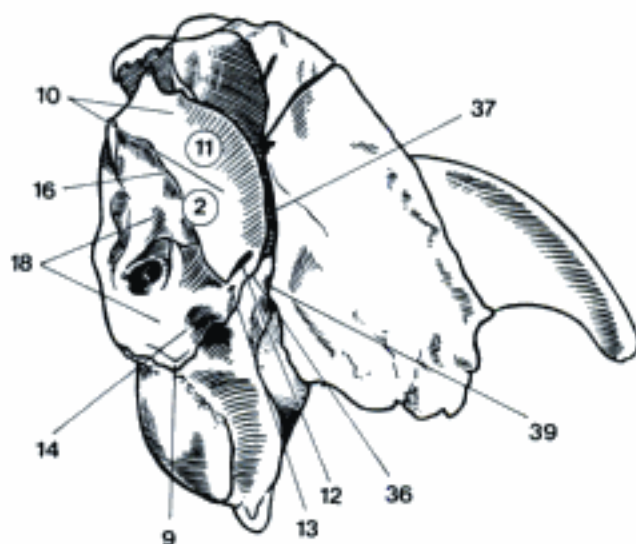
B Petrous and tympanic parts of left temporal bone, lateral aspect (eq)



C Petrous and (part of) tympanic parts of right temporal bone (tympanic cavity open), ventral aspect (eq)



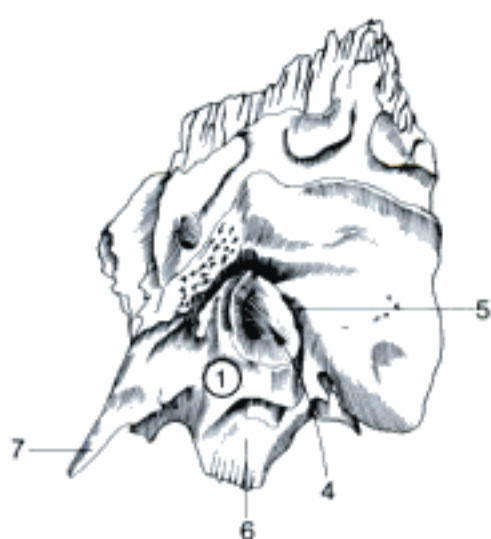
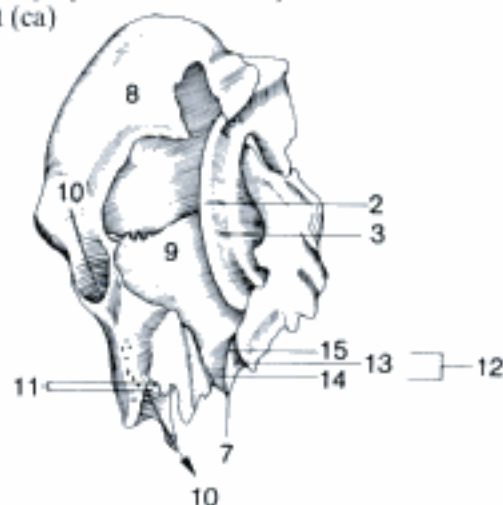
D Petrous part of left temporal bone, mediodorsal (and caudal) aspect (ca)



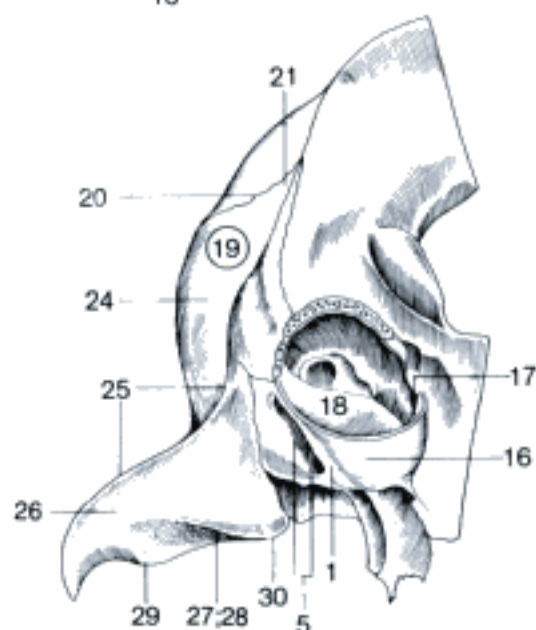
E Left Os temporale, rostradorsal (and medial) aspect (bo)

- 1 **Pars tympanica.** Tympanic part of Os temporale. A B C
- 2 *Anulus tympanicus.* Thin ring which almost completely surrounds the tympanic membrane. A
- 3 *Sulcus tympanicus.* Groove in the Anulus tympanicus for attachment of the tympanic membrane. A
- 4 *Meatus acusticus externus.* Osseous external acoustic meatus. B
- 5 *Porus acusticus externus.* Opening of the osseous external acoustic meatus. B C
- 6 *Vagina processus styloidei.* Sheath of the styloid process in Ru and eq. B
- 7 *Processus muscularis.* Rostroventral process, long in Ru and eq, short in su and ca. A B
- 8 *Bulla tympanica.* Ventral thin-walled extension enclosing part of the tympanic cavity. A
- 9 *Septum bullae.* Septum in the tympanic bulla in ca. A
- 10 *Canalis caroticus.* Canal through the medial wall of the tympanic bulla for the A. carotis interna in ca. A
- 11 *Canaliculi caroticotympanici.* Small canals connecting Canalis caroticus and Cavum tympani in ca. A
- 12 *Canalis musculotubarius.* Double canal leading into the tympanic cavity for the Tuba auditiva and the M. tensor veli palatini, formed by Pars tympanica in su and eq and additionally by Os basisphenoidale in Car and Ru. A
- 13 *Semicanalis m. tensoris veli palatini.* A
- 14 *Semicanalis tubae auditivae.* A
- 15 *Septum canalis musculotubarii.* Separates incompletely the lateral Semicanalis m. tensoris veli palatini and the medial Semicanalis tubae auditivae. A
- 16 **Pars endotympanica.** Forms in fe the large medial part of the Bulla tympanica. Does not ossify directly from connective tissue as the Pars tympanica, but is preformed in cartilage. C
- 17 *Bulla tympanica.* In fe the larger medial part of the bulla is formed by the Pars endotympanica. C
- 18 *Septum bullae.* Is formed in fe by the Pars tympanica and the Pars endotympanica. C
- 19 **Pars squamosa.** Squamous part of the Os temporale. C D
- 20 *Margo parietalis.* Dorsal border adjoining the parietal bone. C D
- 21 *Processus occipitalis.* Caudal process of the squamous part. C D
- 22 *Margo frontalis.* Rostrodorsal border adjoining the frontal bone in su, bo, eq. D
- 23 *Margo sphenoidalis.* Rostroventral border adjoining the sphenoid bones. D
- 24 *Facies temporalis.* Temporal (external) surface. C D
- 25 *Crista supramastoidea.* Ridge crossing the external surface transversely for attachment of Fascia temporalis. C D
- 26 *Processus zygomaticus.* Forms part of the zygomatic arch. C D E
- 27 *Fossa mandibularis.* Fossa for the condyle of the mandible. C D
- 28 *Facies articularis.* C D
- 29 *Tuberculum articulare.* Rounded eminence rostral to the Fossa mandibularis. C D
- 30 *Processus retroarticularis.* Process caudal to Fossa mandibularis. C D
- 31 *Foramen retroarticulare.* External opening of the Meatus temporalis, rudimentary in fe and su. D
- 32 *Incisura tympanica.* Notch facing the Pars tympanica. D
- 33 *Processus retrotympanicus.* Process caudal to Pars tympanica, absent in fe. D
- 34 *Facies cerebralis.* Cerebral (internal) surface. E
- 35 *Crista tentorica.* The Tentorium cerebelli is attached to a crest of the Pars squamosa in su, ov and cap. E
- 36 *Sinus frontalis caudalis.* Excavates also the Pars squamosa of the temporal bone in old su and bo. E
- 37 *Sinus sphenoidalis.* Excavates also the Pars squamosa in old su. E

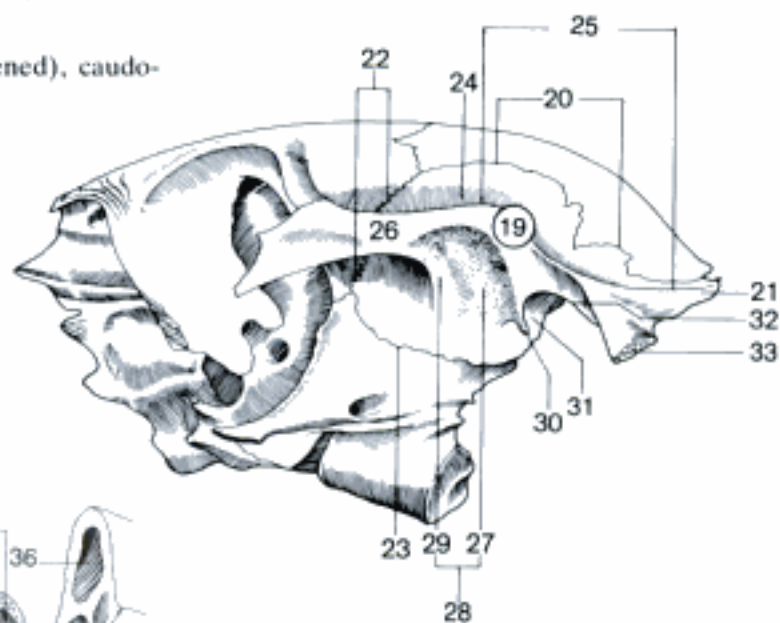
A Pars tympanica of left temporal bone, rostradorsal aspect (ca)



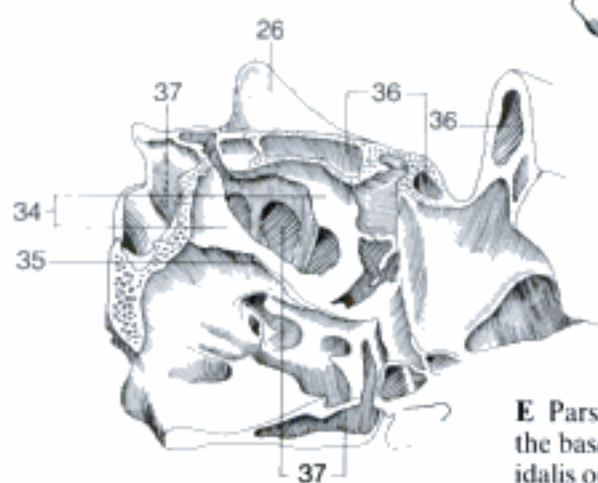
B Petrous and tympanic parts of left temporal bone, lateral aspect (eq)



C Cranial bones (Bulla tympanica opened), caudoventral aspect (fe)



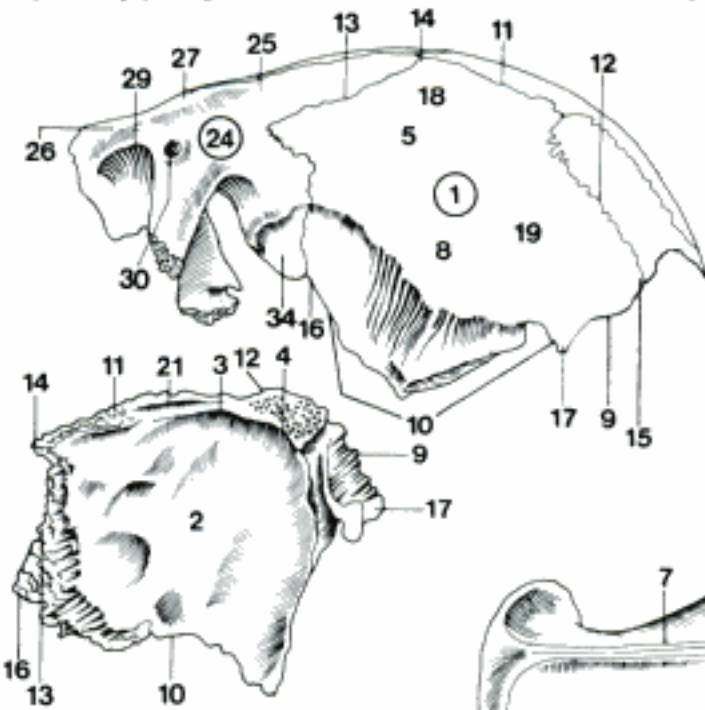
D Left cranial bones (eq)



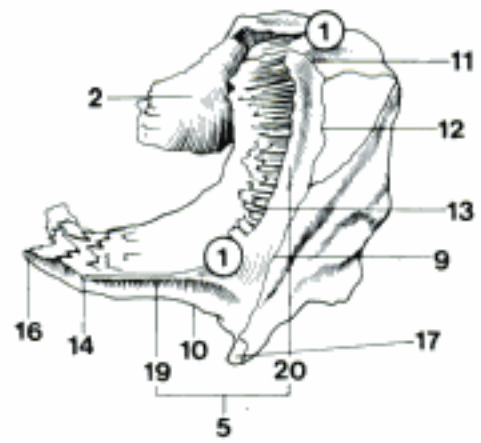
E Pars squamosa of left temporal bone and part of the base of skull (Sinus frontalis caudalis and sphenoidalis opened), dorsomedial aspect (su)

- 1 **Os parietale**. Parietal bone. A B C D E
- 2 *Facies interna*. Internal surface. B D E
- 3 (*Crista sagittalis interna*). Inconstant median ridge on the internal surface of *Os parietale* of eq. D
- 4 *Processus tentoricus*. Part of Tentorium cerebelli osseum in Car and eq. D
- 5 *Facies externa*. External surface. A B C E
- 6 *Crista sagittalis externa*. External median crest in Car and eq. C
- 7 *Linea temporalis*. Border of the Fossa temporalis to which the Fascia temporalis is attached. C
- 8 *Tuber parietale*. More or less pronounced eminence on the external surface in Car and eq. A C
- 9 *Margo occipitalis*. Border adjoining the *Os occipitale*. A B D
- 10 *Margo squamosus*. Border adjoining the *Os temporale*. A B D
- 11 *Margo sagittalis*. Median border. A B D E
- 12 *Margo interparietalis*. Border adjoining *Os interparietale*, in ca *Processus interparietalis*. A B D
- 13 *Margo frontalis*. Border adjoining the *Os frontale*. A B D
- 14 *Angulus frontalis*. Rostrodorsal angle. A B D
- 15 *Angulus occipitalis*. Dorsocaudal angle. A
- 16 *Angulus sphenoidalis*. Rostroventral angle. A B D
- 17 *Angulus mastoideus*. Ventrocaudal angle. A B D
- 18 *Planum parietale*. Dorsal part of the external surface, medial to *Linea temporalis*, in dolichocephalic ca and bo not existent. A E
- 19 *Planum temporale*. Lateral part of the external surface, covered by the *M. temporalis*. A B
- 20 *Planum nuchale*. Caudal part of the external surface in bo. B
- 21 *Sulcus sinus sagittalis dorsalis*. Median groove for the *Sinus sagittalis dorsalis*. D
- 22 *Sinus frontalis caudalis*. Excavates also the *Os parietale* in su and bo. E
- 23 *Septum sinuum frontaliuum*. E
- 24 **Os frontale**. Frontal bone. A C E F
- 25 *Squama frontalis*. Squama of the frontal bone. A F
- 26 *Facies externa*. External surface. A E F
- 27 *Tuber frontale*. Flat eminence on the external surface of *Os frontale*, visible especially in ca and bo. A C F
- 28 *Arcus superciliaris*. Elevation dorsal to the *Margo supraorbitalis*, especially in Ru. F
- 29 *Margo supraorbitalis*. Supraorbital margin. A C F
- 30 *Foramen supraorbitale*. Opening near to the base of the *Processus zygomaticus* for passage of blood vessels and nerve in eq. A C
- 31 *Incisura supraorbitalis*. Notch in the *Margo supraorbitalis* in man, sometimes present in ca.
- 32 *Canalis supraorbitalis*. Canal medial to the *Margo supraorbitalis* for passage of blood vessels and nerve in su and Ru. E F
- 33 *Sulcus supraorbitalis*. Groove from the opening of the *Canalis supraorbitalis* in rostral (su, Ru) and caudal (bo) directions. E F
- 34 *Facies temporalis*. Temporal (lateral) surface. A
- 35 *Linea temporalis*. Border of the Fossa temporalis, to which the Fascia temporalis is attached. C F

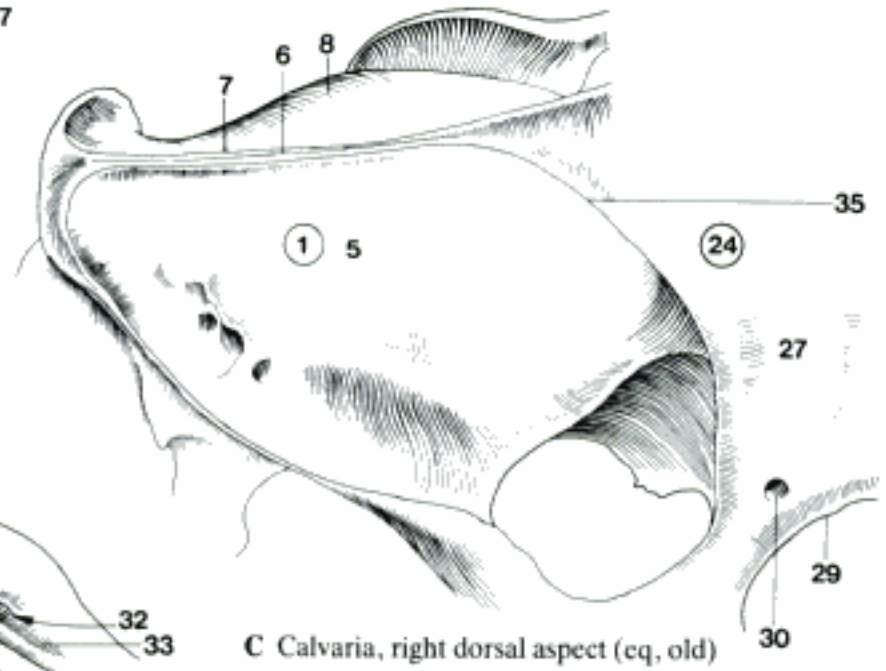
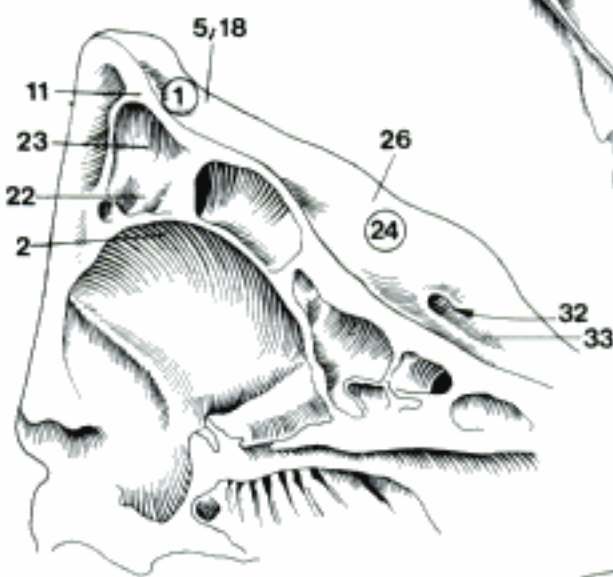
A Os parietale and Os frontale, caudolaterodorsal aspect (eq, young)



B Squama occipitalis, Os interparietale and Ossa parietalia, left and caudodorsal aspect (bo)

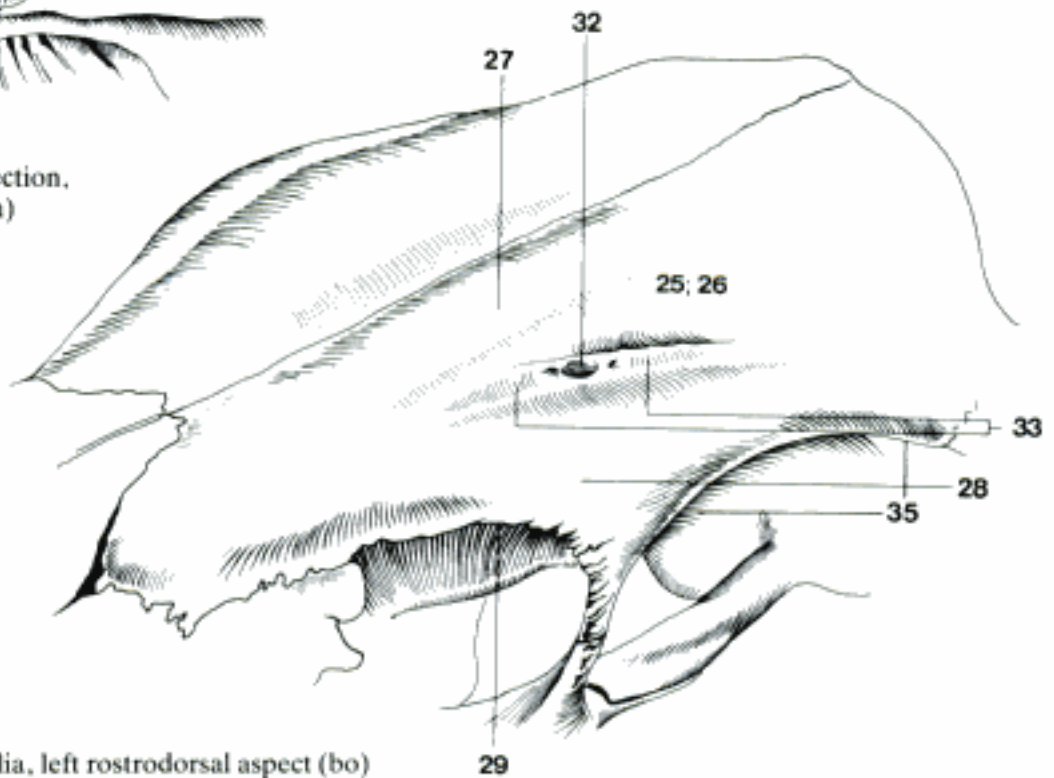


D Right Os parietale, ventromedial aspect (eq)



C Calvaria, right dorsal aspect (eq, old)

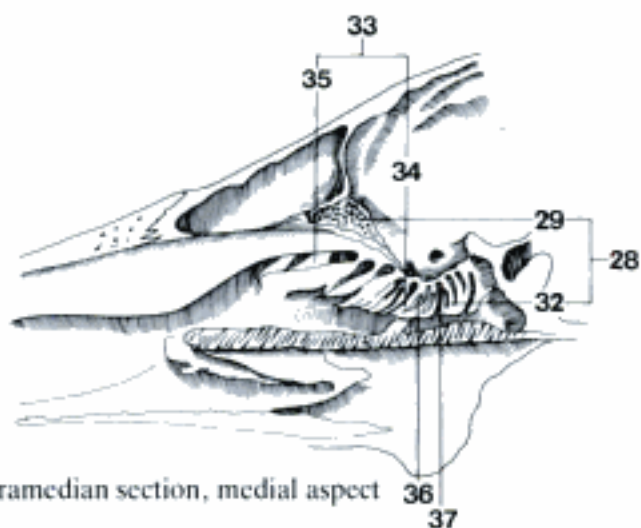
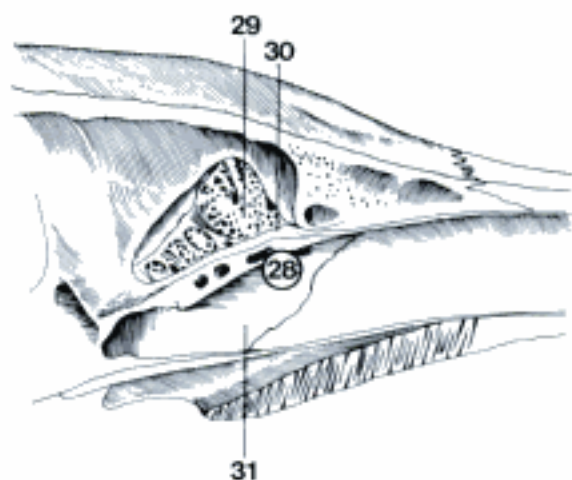
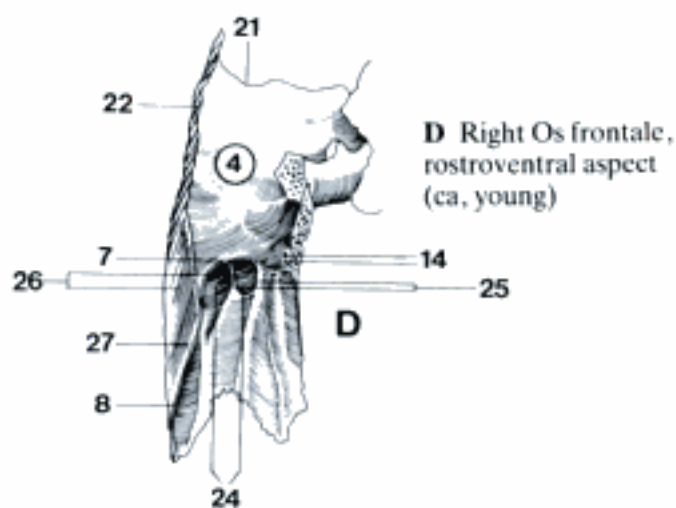
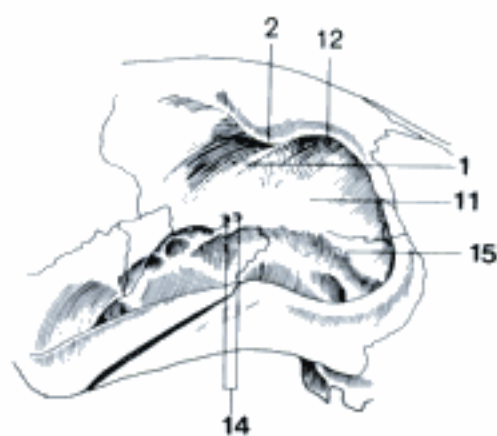
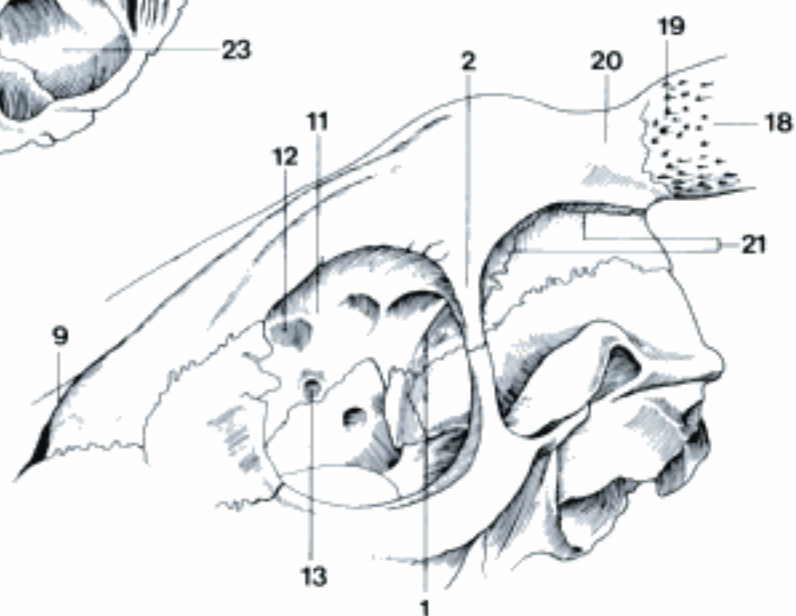
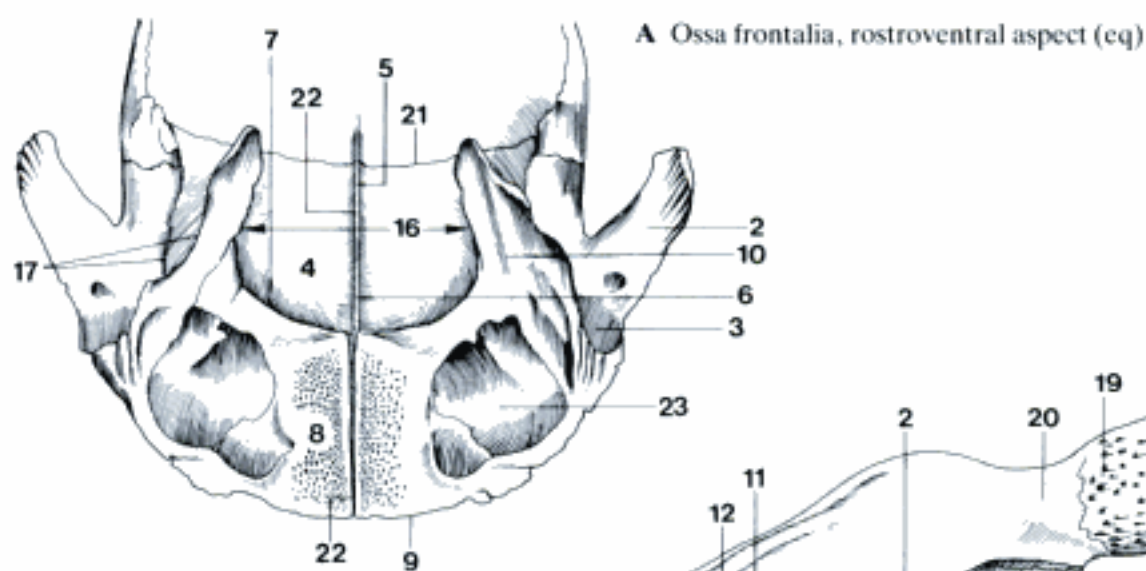
E Cranium, median section, rostromedial aspect (su)



F Ossa frontalia, left rostradorsal aspect (bo)

29

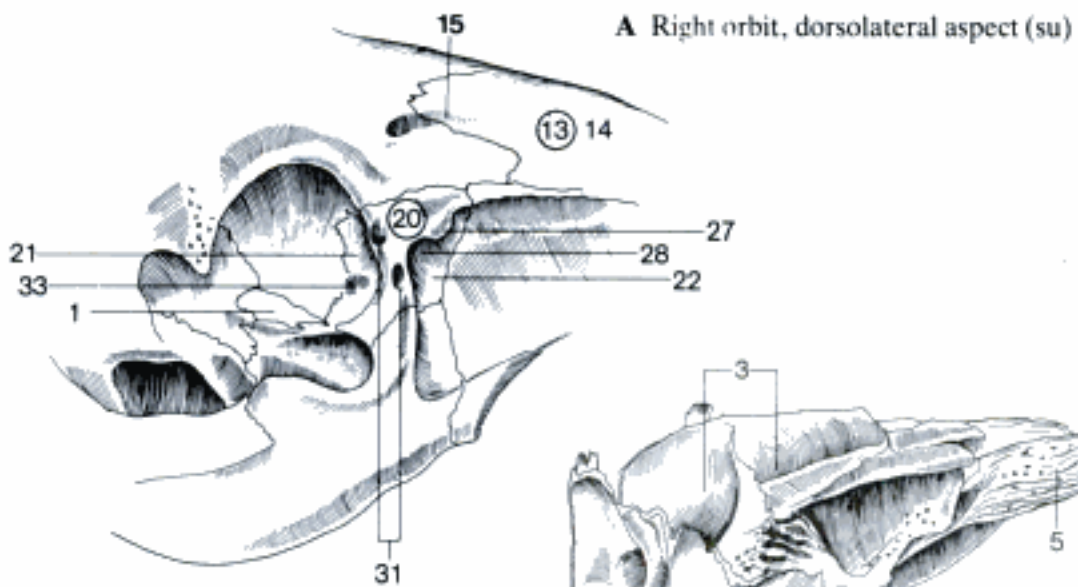
- 1 *Crista orbitotemporalis*. Crest between Pars orbitalis and Pars temporalis. B C
- 2 *Processus zygomaticus*. Lateral to the Orbita, connection with Os zygomaticum in Ru, Os temporale in eq, Lig. orbitale in Car and su. A B C
- 3 *Fossa glandulae lacrimalis*. Depression for the lacrimal gland in Ru and eq. A
- 4 *Facies interna*. Internal surface, facing the brain. A D
- 5 *Crista frontalis*. Median crest on the internal surface for the attachment of Falx cerebri. A
- 6 *Sulcus sinus sagittalis dorsalis*. Groove in caudal continuation of the Crista frontalis for the Sinus sagittalis dorsalis. A
- 7 *Margo ethmoidalis*. Ethmoidal margin between internal surface and Pars nasalis, junction with the ethmoid. A D
- 8 *Pars nasalis*. Rostral part of the frontal bone facing the nasal cavity. A D
- 9 *Margo nasalis*. Rostral border of the Pars nasalis. A B
- 10 *Pars orbitalis*. Forms a part of the medial wall of the orbit. A
- 11 *Facies orbitalis*. Orbital surface, facing the Orbita. B C
- 12 *Fovea trochlearis*. Small depression for the attachment of trochlea serving the M. obliquus dorsalis. B C
- 13 *Foramen ethmoidale*. Opening in the Pars orbitalis, but on the border adjoining the ethmoid in eq. B
- 14 *Foramina ethmoidalia*. There are usually two foramina in the Pars orbitalis in ca. C D
- 15 *Crista orbitalis ventralis*. Crest which marks the junction between Orbita and Fossa pterygopalatina. C
- 16 *Incisura ethmoidalis*. Notch between right and left orbital parts into which the ethmoid is inserted. A
- 17 *Incisura sphenoidalis*. Notch between orbital and temporal parts into which the wing of the presphenoid is inserted in Ru and eq. A
- 18 *Processus cornualis*. Supports the horn in horned Ru. B
- 19 *Corona processus cornualis*. Crown of the cornual process, an enlargement distal to its neck. B
- 20 *Collum processus cornualis*. Neck of the cornual process, a constriction of its base. B
- 21 *Margo parietalis*. Border adjoining the Os parietale. A B D
- 22 *Margo sagittalis*. Median border. A D
- 23 *Sinus frontalis*. Frontal sinus in fe and eq. A
- 24 *Sinus frontales*. Frontal sinuses in ca, su, and Ru. The plural indicates that there are more than one Sinus frontalis on each side. D
- 25 *Aperturae sinuum frontaliuum*. Openings of the frontal sinuses into the nasal cavity or the caudal maxillary sinus (eq). D
- 26 *Septa sinuum frontaliuum*. All septa between frontal sinuses. D
- 27 *Processus septalis*. In Car, forms with the septal processes of the nasal bones a dorsal part of the Septum nasi. D
- 28 **Os ethmoidale**. Ethmoid bone. E F
- 29 *Lamina cribrosa*. Cribriform plate, between the nasal cavities and the cranial cavity, perforated for the passage of Nn. olfactorii. E F
- 30 *Crista galli*. Median ridge into the cranial cavity for attachment of Falx cerebri. E
- 31 *Lamina perpendicularis*. Median plate forming the caudal part of the Septum nasi. E
- 32 *Labyrinthus ethmoidalis*. Collective term for the Ethmoturbinalia. F
- 33 *Ethmoturbinalia*. Delicate scroll-like bones in the nasal cavity. F
- 34 *Ectoturbinalia*. Small ethmoturbinates. F
- 35 *Endoturbinalia*. Large ethmoturbinates. F
- 36 *Cellulae ethmoidales*. Exist in su and Ru. F
- 37 *Meatus ethmoidales*. Spaces between ethmoturbinates. F



E Os ethmoidale, paramedian section, right (and dorsal) aspect (su)

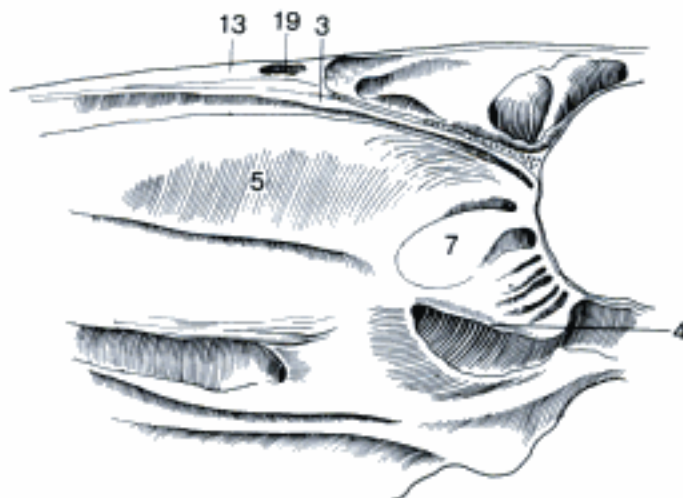
F Os ethmoidale, paramedian section, medial aspect (su)

- 1 *Lamina orbitalis*. Thin lateral plate, only in su and bo forming a part of the medial wall of the Fossa pterygopalatina, in Car the medial wall of the Recessus maxillaris. A D
- 2 *Foramen ethmoidale*. Only in eq does the ethmoid take part in forming this foramen. B
- 3 *Lamina tectoria*. Upper plate, forming the roof of the Labyrinthus ethm. B C
- 4 *Lamina basalis*. Lower plate, forming the floor of the Labyrinthus ethm. C D
- 5 *Concha nasalis dorsalis*. Dorsal nasal concha. B C
- 6 *Processus uncinatus*. Rostrodorsal end of Lamina orbitalis, detached from the nasal wall, partially closes the entrance to the Recessus maxillaris in Car. D
- 7 *Concha nasalis media*. Middle nasal concha. C
- 8 **Vomer**. E
- 9 *Sulcus vomeris [septalis]*. Dorsal groove containing the Cartilago septi nasi. E
- 10 *Crista vomeris*. Ventral crest on the caudal part of the Vomer. E
- 11 *Ala vomeris*. Wing-like lateral process on the caudal end of the Vomer. E
- 12 **OSSA FACIEI**. Facial bones.
- 13 **Os nasale**. Nasal bone. A C F G
- 14 *Facies externa*. External surface. A F
- 15 *Sulcus supraorbitalis*. In su the Sulcus supraorbitalis extends onto the Os nasale. A F
- 16 *Facies interna*. Internal surface. G
- 17 *Processus septalis*. Sagittal crest for attachment of Cartilago septi nasi. G
- 18 *Crista ethmoidalis*. Sagittal crest for attachment of Concha nasalis dorsalis. G
- 19 (*Sinus frontalis*). May excavate also the Os nasale in su, bo and eq. C
- 20 **Os lacrimale**. Lacrimal bone. A H I
- 21 *Facies orbitalis*. Orbital surface, facing the Orbita. A H
- 22 *Facies facialis*. Facial surface, rostral to the Orbita, small in ca, absent in fe. A
- 23 *Facies nasalis*. Nasal (internal) surface. I
- 24 *Incisura infratrochlearis*. Notch for passage of N. infratrochlearis. H
- 25 *Processus frontalis*. Dorsal process into a notch of the Os frontale in ca. D
- 26 *Processus lacrimalis caudalis*. Process on Margo supraorbitalis in Ru and eq. H
- 27 *Processus lacrimalis rostralis*. Small process on Facies facialis in su and eq. A
- 28 *Fossa lacrimalis externa*. On Facies orbitalis in su and ov. A
- 29 *Fossa sacci lacrimalis*. Depression on Facies orbitalis for Saccus lacrimalis, absent in su. H
- 30 *Foramen lacrimale*. Opening for the Ductus nasolacrimalis, absent in su. H
- 31 *Foramina lacrimalia* (su). Two openings on Facies facialis in su. A
- 32 *Canalis lacrimalis*. Canal for the Ductus nasolacrimalis. I
- 33 *Fossa m. obliqui ventralis*. Depression for muscle attachment. A H
- 34 *Bulla lacrimalis*. Large thin-walled protuberance into the ventral part of the Orbita in Ru. H I
- 35 *Sinus maxillaris*. Extends also into the Bulla lacrimalis in Ru. I
- 36 *Sinus lacrimalis* (bo). Excavates the Os lacrimale except the Bulla lacrimalis, entrance from the Sinus maxillaris. I

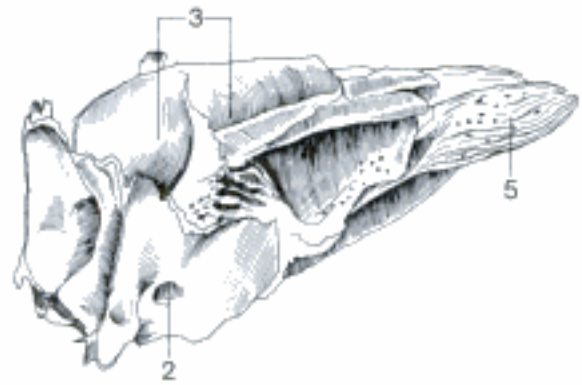


A Right orbit, dorsolateral aspect (su)

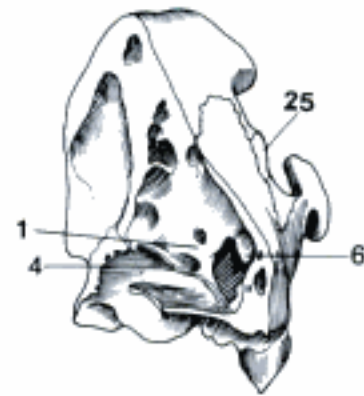
B Os ethmoidale, right dorsocaudal aspect (eq)




C Part of right nasal cavity, paramedian section, medial aspect (eq)



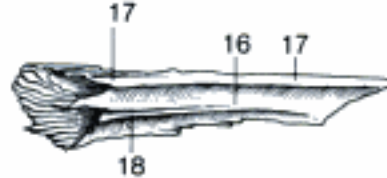D Left facial bones, rostromedial aspect (ca)



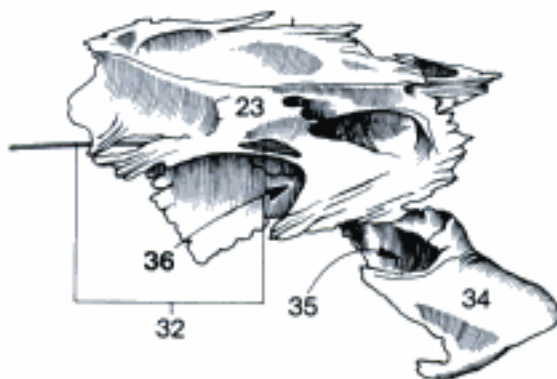
E Vomer, right dorsal aspect (eq)



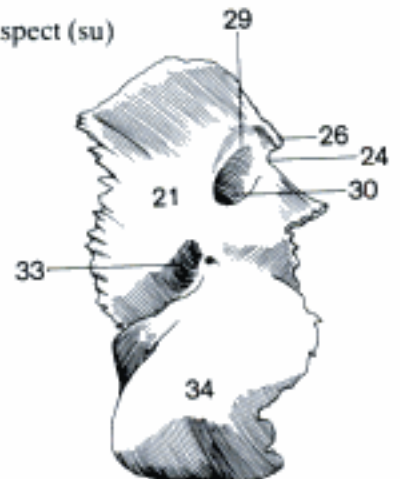
F Left Os nasale, dorsolateral aspect (su)



G Left Os nasale, ventromedial aspect (su)

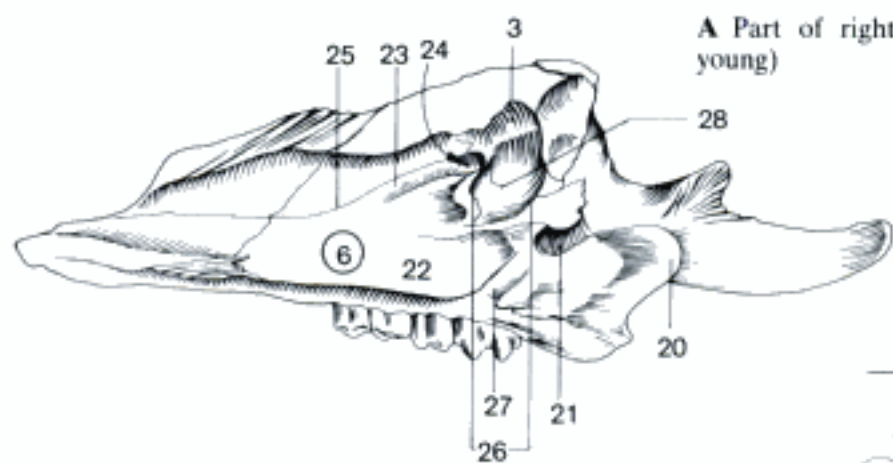


I Right Os lacrimale, medial aspect (bo)

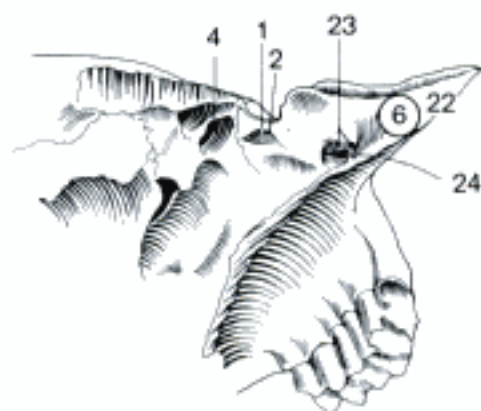


H Right Os lacrimale, caudal aspect (bo)

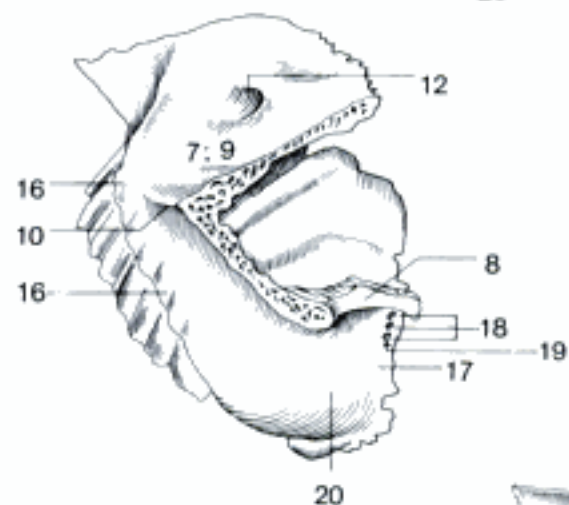
- 1 (*Sinus lacrimalis*) (su, ov, cap). In these species only occasionally as individual diverticulum of the nasal cavity, in other cases the Os lacrimale – except the Bulla – is excavated by a frontal sinus (see 3 and 4). B
- 2 *Apertura sinus lacrimalis*. B
- 3 (*Sinus frontalis rostralis lateralis*) (su). See 1. A
- 4 (*Sinus frontalis lateralis*) (ov, cap). See 1. B
- 5 *Sinus maxillaris caudalis* (eq). Excavates also the Os lacrimale. C
- 6 **Maxilla**. Principal bone of the upper jaw. A B C D E F
- 7 **Corpus maxillae**. Body of the maxilla. C D E F
- 8 *Facies orbitalis*. Orbital surface, which in ca and to a lesser extent also in eq forms part of the wall of the orbit. D
- 9 *Facies facialis*. Facial surface. C D E F
- 10 *Crista facialis*. Facial crest, for attachment of M. masseter. C D E F
- 11 *Tuber faciale*. At the rostral end of *Crista facialis* in Ru. E
- 12 *Foramen infraorbitale*. Rostral opening of the *Canalis infraorbitalis*. C D E F
- 13 *Canalis infraorbitalis*. Contains the N. infraorbitalis and accompanying blood vessels. C
- 14 *Canalis alveolaris*. Contains the nerves and blood vessels for *Dentes incisivi*, *caninus*, and *premolares*, absent in Ru. F
- 15 *Fossa canina*. Concavity dorsal to *Crista facialis* and *For. infraorbitale* in su. F
- 16 *Juga alveolaria*. Ridges caused by the underlying teeth. C D F
- 17 *Facies pterygopalatina*. Caudal surface facing the *Fossa pterygopalatina*. D
- 18 *Foramina alveolaria*. Small openings for nerves and blood vessels for the molar teeth. D
- 19 *Canales alveolares*. Canals for alveolar and dental branches of nerves and vessels to the molar teeth. D
- 20 *Tuber maxillae*. Prominence on the caudal surface of maxilla. A C D E
- 21 *Foramen maxillare*. Caudal opening of the *Canalis infraorbitalis*. A
- 22 *Facies nasalis*. Nasal (medial) surface. A B
- 23 *Sulcus lacrimalis*. Groove for the *Ductus nasolacrimalis*, rostral continuation of 24. A B
- 24 *Canalis lacrimalis*. Canal for the *Ductus nasolacrimalis*. A B
- 25 *Crista conchalis*. Ridge for the attachment of the *Concha nasalis ventralis*. A
- 26 *Hiatus maxillaris*. Wide opening into *Sinus maxillaris* after removal of *Os ethmoidale* and *Concha nas. ventr.* A
- 27 *Sulcus palatinus major*. Semicanal for greater palatine nerve and vessels, forms with *Sulcus pal. maj.* of *Os palatinum* the *Canalis palatinus maj.* (except bo). A
- 28 *Sinus maxillaris*. Maxillary sinus in su and Ru. A
- 29 *Sinus maxillaris rostralis*. Smaller rostral maxillary sinus in eq. C
- 30 *Sinus maxillaris caudalis*. Larger caudal maxillary sinus in eq. C
- 31 *Septum sinuum maxillarium*. Septum between rostral and caudal maxillary sinuses in eq. C



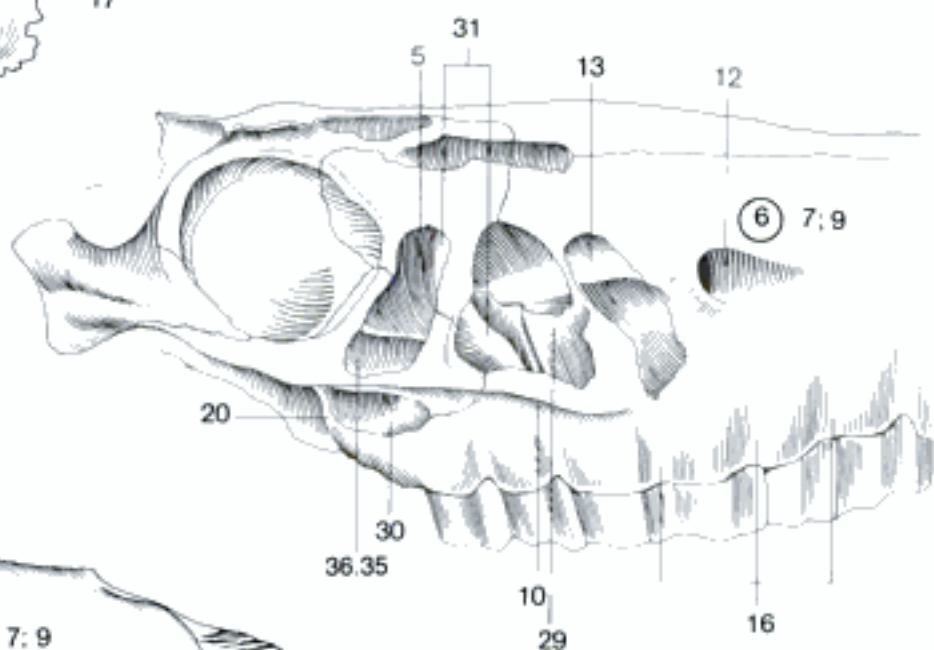
A Part of right facial bones, medial aspect (su, young)



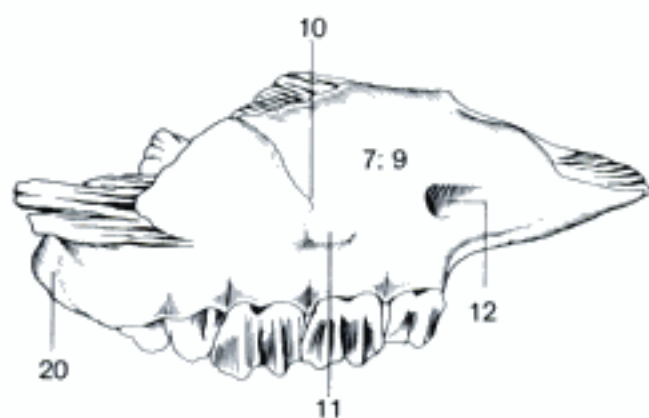
B Part of left facial bones, mediorostroventral aspect (cap)



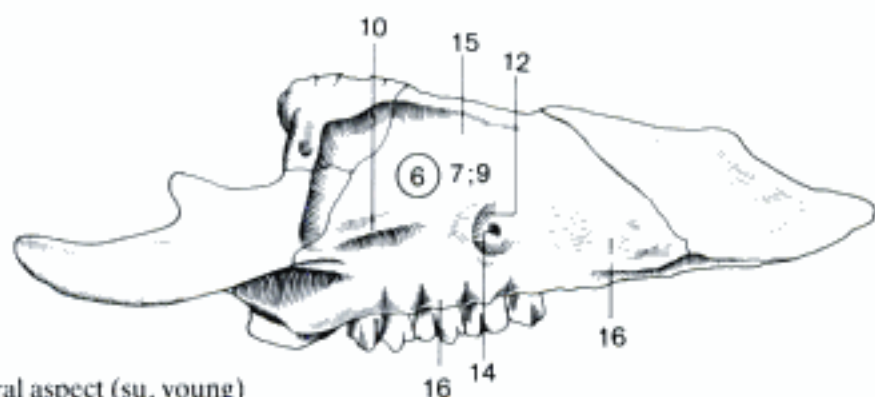
D Left maxilla, laterocaudal aspect (eq)



C Right facial bones (sinus opened), lateral aspect (eq)

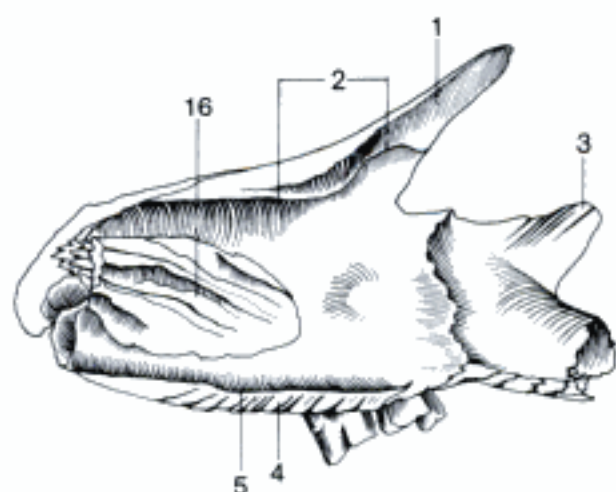


E Right maxilla, lateral aspect (bo)

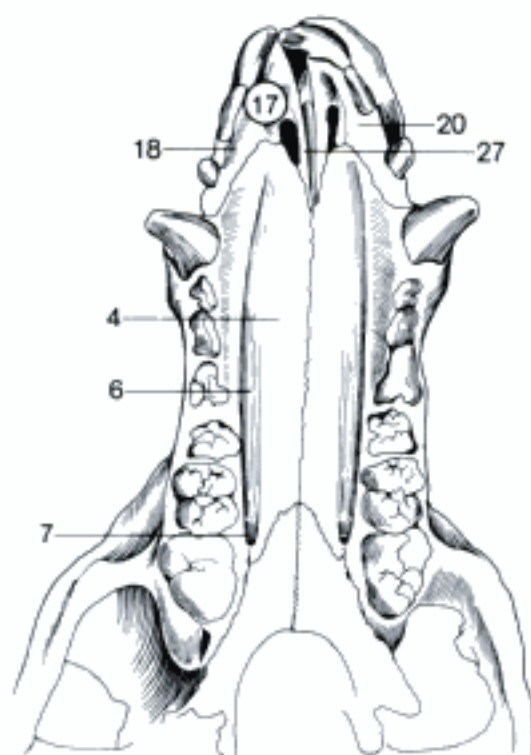


F Part of right facial bones, lateral aspect (su, young)

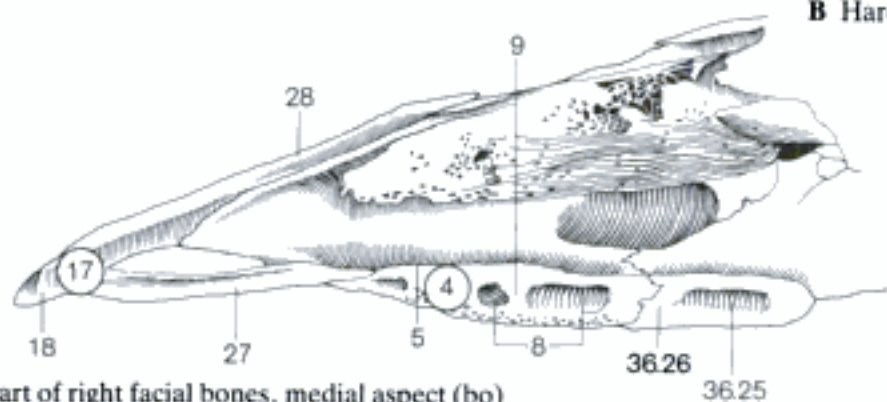
- 1 **Processus frontalis.** Frontal process in Car. A
- 2 *Crista ethmoidalis.* The line of attachment of the Concha nasalis dorsalis also runs across the maxilla in Car and su. A
- 3 **Processus zygomaticus.** Caudal process dorsolateral to the Tuber maxillae, adjoining the Os zygomaticum. A
- 4 **Processus palatinus.** Plate forming the largest portion of the hard palate. A B C D
- 5 *Crista nasalis.* Median crest for attachment of Septum nasi (Vomer). A C
- 6 *Sulcus palatinus.* Sagittal groove on the oral surface for the greater palatine nerve and vessels. B D
- 7 *Foramen palatinum majus.* Rostral opening of Canalis palatinus, formed only by the maxilla in su and sometimes in ca. B
- 8 *Sinus palatinus.* Excavates the Proc. palatinus of the maxilla in Ru. C
- 9 *Septum sinuum palatinorum.* Septum between right and left palatine sinuses in Ru. C
- 10 **Processus alveolaris.** Ventral process presenting the alveoli for the teeth. D
- 11 *Margo alveolaris.* Border of the Processus alveolaris presenting alveoli. D
- 12 *Margo interalveolaris.* The rostral part of Processus alveolaris of maxilla does not present alveoli. D
- 13 *Alveoli dentales.* Cavities in the Processus alveolaris for the roots of the teeth. D
- 14 *Septa interalveolaria.* Septa between the alveoli of neighboring teeth. D
- 15 *Septa interradicularia.* Septa between the chambers for the roots of one tooth. D
- 16 **Os conchae nasalis ventralis.** Ventral nasal conchal bone. A
- 17 **Os incisivum.** Incisive bone, rostral part of the upper jaw. B C D E
- 18 **Corpus ossis incisivi.** Body of the incisive bone. B C D E
- 19 *Facies labialis.* Labial (external) surface, facing the upper lip. E
- 20 *Facies palatina.* Palatine (internal) surface. B D E
- 21 **Processus alveolaris.** Process presenting the alveoli for the incisor teeth (except Ru). D E
- 22 *Arcus alveolaris.* Arcuate border of the Processus alveolaris. D E
- 23 *Alveoli dentalis.* Cavities in the Processus alveolaris for the roots of the incisor teeth. D E
- 24 *Septa interalveolaria.* Septa between alveoli. D E
- 25 *Margo interalveolaris.* The caudal part of Processus alveolaris of Os incisivum does not present alveoli. D E
- 26 *Juga alveolaria.* Prominences on the external surface caused by the teeth. E
- 27 **Processus palatinus.** Thin plate forming the rostral portion of the hard palate. B C D E
- 28 **Processus nasalis.** Projects caudodorsally, forms part of the lateral wall of the nasal cavity. C E
- 29 **Os rostrale.** Forms the rostral end of the Septum nasi in su, sometimes in bo. F



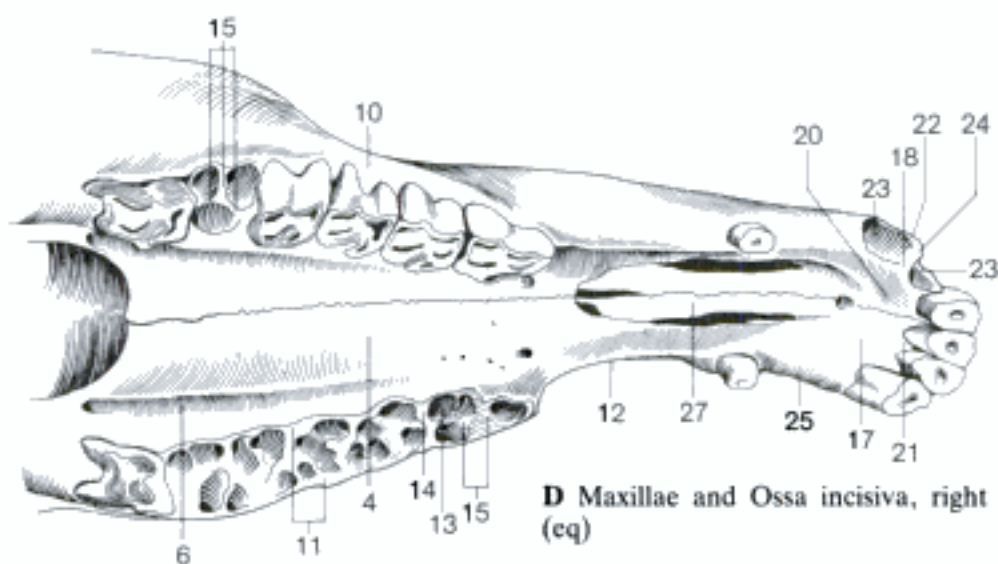
A Right maxilla, medial aspect (ca, young)



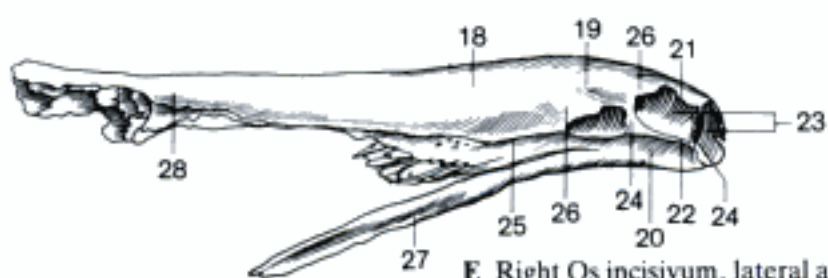
B Hard palate (su, young)



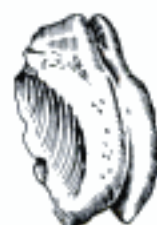C Part of right facial bones, medial aspect (bo)



D Maxillae and Ossa incisiva, right ventral aspect (eq)



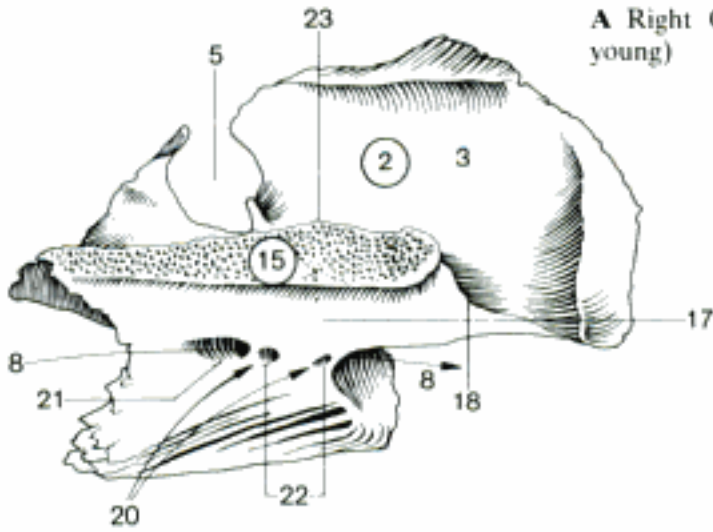
E Right Os incisivum, lateral aspect (eq)



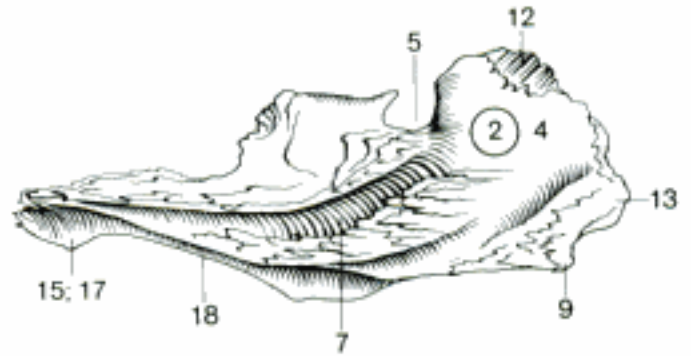
F Os rostrale, right rostral aspect (su)

- 1 **Os palatinum.** Palatine bone. A B C D
- 2 **Lamina perpendicularis.** Perpendicular plate. A B C D
- 3 *Facies nasalis.* Nasal (medial) surface. A C D
- 4 *Facies maxillaris.* Maxillary (lateral) surface. B
- 5 *Incisura sphenopalatina.* Notch present in bo and sometimes in eq, part of the Foramen sphenopalatinum. A B
- 6 *Foramen sphenopalatinum.* Opening between Fossa pterygopalatina and Cavum nasi, in bo and sometimes in eq only partially formed by the Os palatinum. C
- 7 *Sulcus palatinus major.* Semicanal for the greater palatine nerve and vessels, forms with Sulcus pal. maj. of the maxilla the Canalis palatinus maj. (except in bo). B
- 8 *Canalis palatinus major.* In bo this canal is formed only by the Os palatinum. A
- 9 *Processus pyramidalis.* Caudoventral process, inserted between Processus pterygoideus of the basisphenoid and Os pterygoideum, well developed in su, absent in Car. B
- 10 *Crista ethmoidalis.* Rostral continuation of Lamina sphenothmoidalis in ca for attachment of an ectoturbinate. C
- 11 *Lamina sphenothmoidalis.* Plate detached from Facies nasalis, parallel to Pars horizontalis. The laminae of both sides separate the Meatus nasopharyngeus from the ethmoidal labyrinths, caudally adjoining the presphenoid, rostradorsally united with Lamina basalis of the ethmoid. Absent in Ru, long in ca and su. C
- 12 *Processus orbitalis.* Dorsal process to the medial wall of the orbit. B C
- 13 *Processus sphenoidalis.* Caudomedial process to the body of the presphenoid. B C
- 14 (*Sinus sphenoidalis*). May excavate the Processus sphenoidalis in su and eq. D
- 15 **Lamina horizontalis.** Horizontal plate, forms the caudal portion of the hard palate. A B C D
- 16 *Facies nasalis.* Nasal (dorsal) surface. C
- 17 *Facies palatina.* Palatine (ventral) surface. A B D
- 18 *Margo liber.* Free (caudal) border. A B C D
- 19 *Spina nasalis caudalis.* Median caudal spine on the caudal border in Car, su and occasionally eq. C
- 20 *Canales palatini minores.* Canals for the minor palatine nerves and vessels in ca, su and bo. A
- 21 *Foramen palatinum majus.* Rostral opening of Canalis palatinus major, in bo entirely formed by the Os palatinum. A
- 22 *Foramina palatina minora.* Rostral openings of the Canales palatini minores in ca, su, and bo. A
- 23 *Crista nasalis.* Median dorsal crest, sometimes absent in bo. A C D
- 24 (*Crista palatina*). Ridge on Facies palatina, occasionally present in su. D
- 25 **Sinus palatinus.** In the Pars perpendicularis in eq, in the Pars horizontalis in Ru. 35 C
- 26 *Septum sinuum palatinorum.* Median septum between the palatine sinuses in bo. 35 C
- 27 **Os zygomaticum.** Zygomatic bone. D E F
- 28 *Facies lateralis.* Lateral surface. E
- 29 *Facies orbitalis.* Surface facing the orbit. E F
- 30 *Processus temporalis.* Caudally directed process which forms the zygomatic arch with the Processus zygomaticus ossis temporalis. D E F
- 31 *Processus frontalis.* Adjoining the Processus zygomaticus ossis frontalis in Ru, the Lig. orbitale in Car and su. D E F
- 32 *Margo infraorbitalis.* Infraorbital margin, separates lateral and orbital surfaces. E F
- 33 *Crista facialis.* Facial crest, continuation from maxilla. E
- 34 *Sinus maxillaris.* Excavates also the Os zygomaticum in su and Ru. D F
- 35 *Sinus maxillaris caudalis.* Excavates also the Os zygomaticum in eq. 33 C

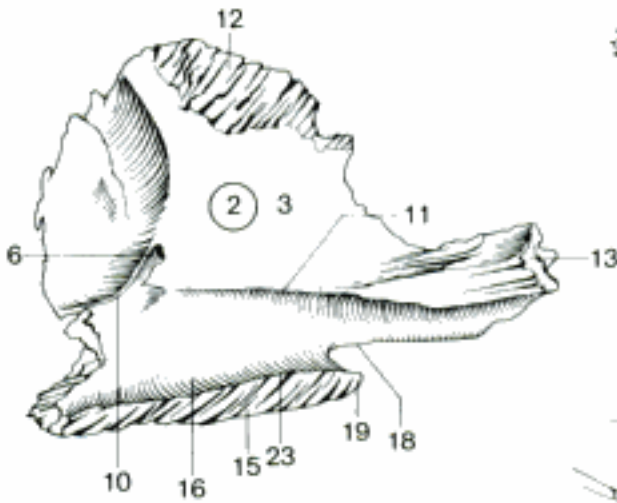
A Right Os palatinum, medioventral aspect (bo, young)



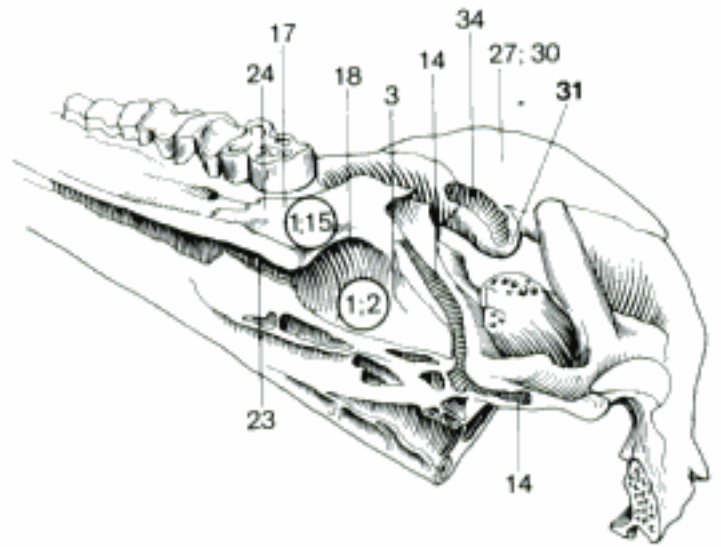
B Left Os palatinum, lateral aspect (eq)



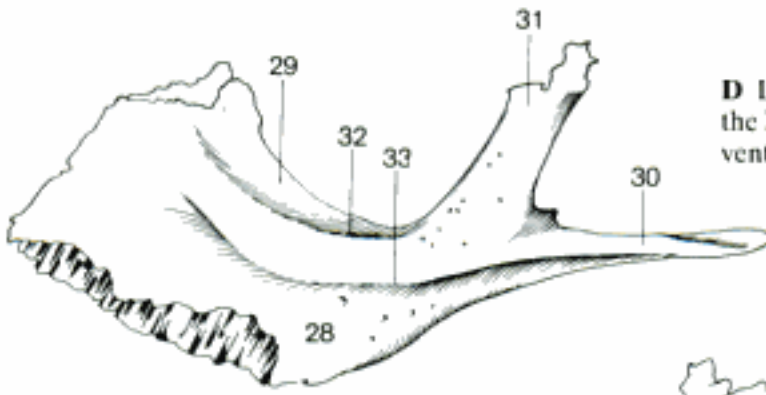
C Right Os palatinum, mediodorsal aspect (ca)



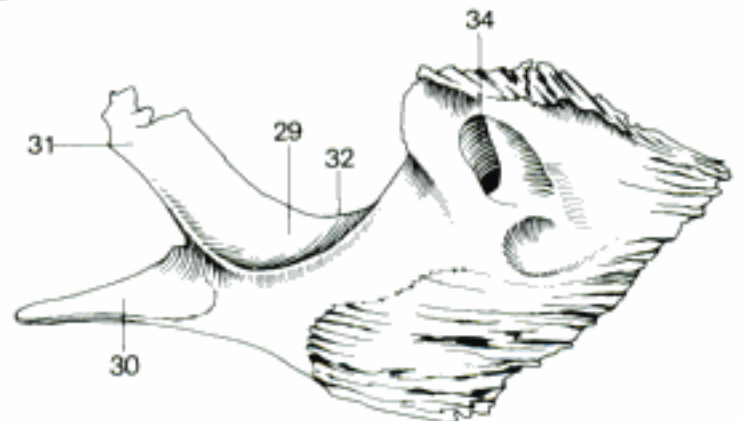
D Left Fossa pterygopalatina and part of the hard palate, Sinus sphenoidalis opened, caudo-ventromedial aspect (su)



E Left Os zygomaticum, lateral aspect (bo)

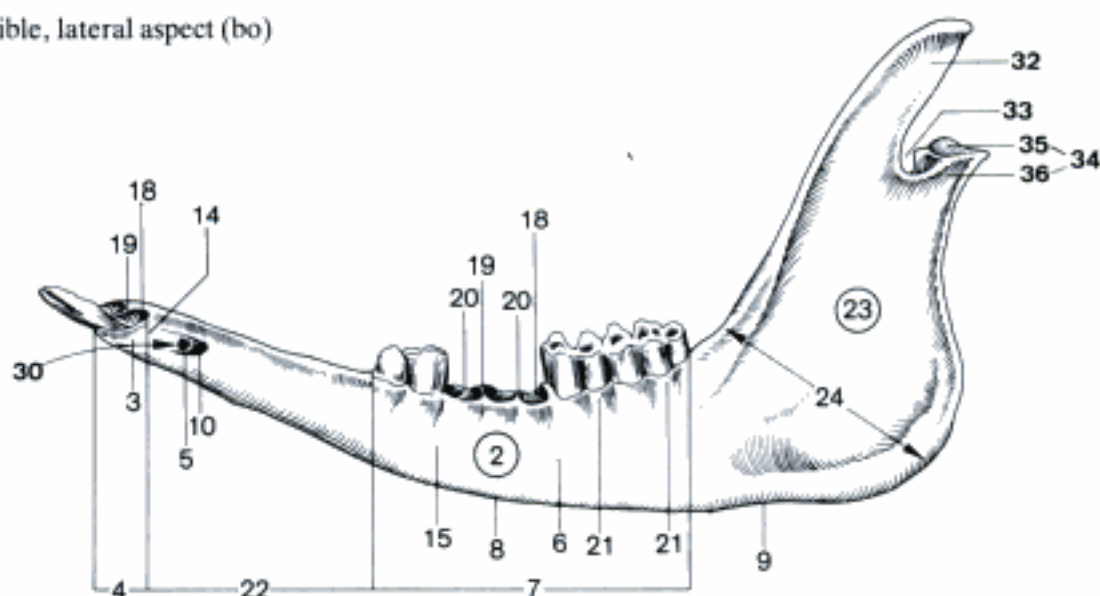


F Left Os zygomaticum, medial aspect (bo)

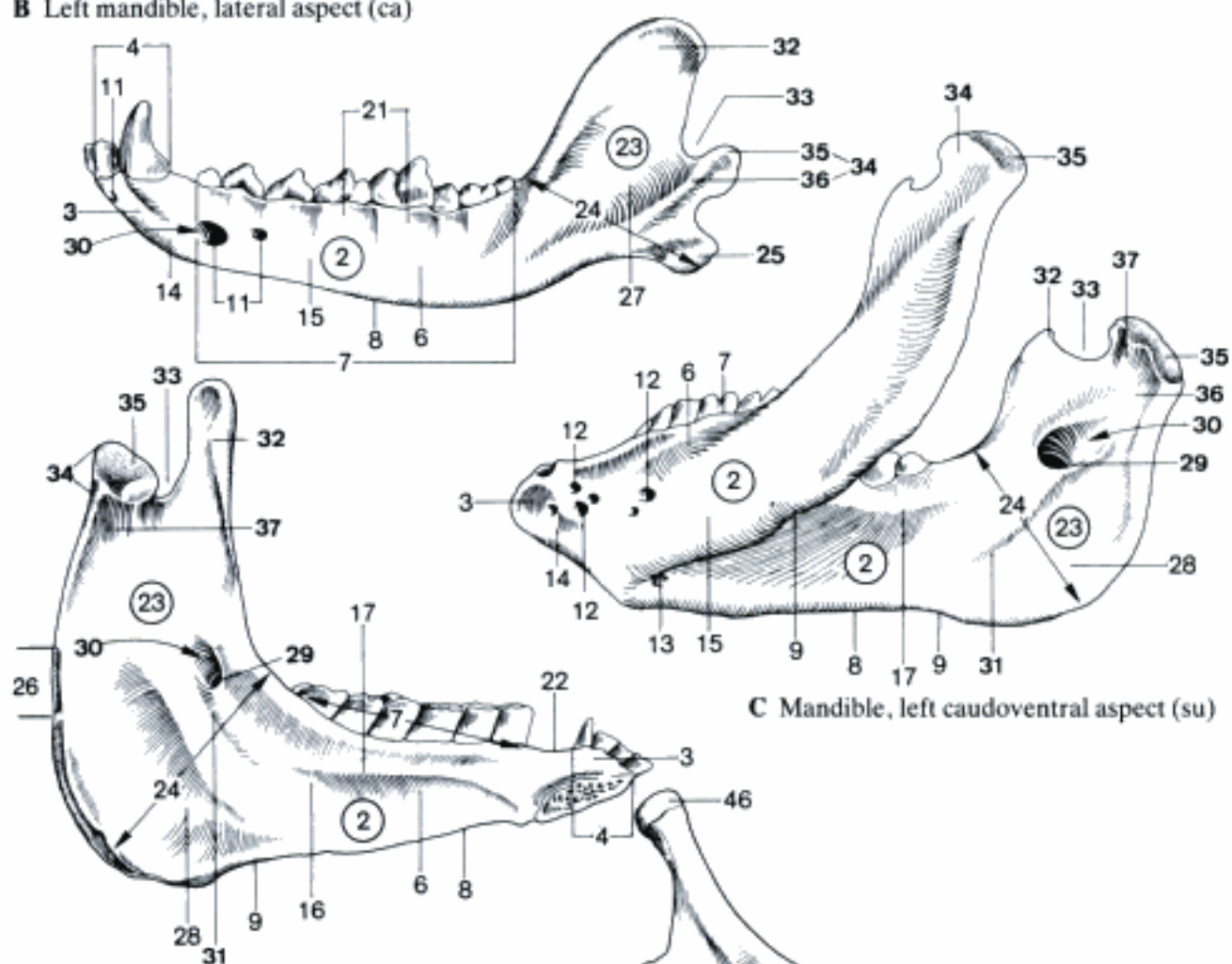


- 1 **Mandibula.** Mandible. Lower jaw bone. A B C D
- 2 **Corpus mandibulae.** Body of mandible, presenting teeth. A B C D
- 3 *Pars incisiva.* Rostral part with alveoli for incisor teeth. A B C D
- 4 *Arcus alveolaris.* Curved border of the Pars incisiva. A B D
- 5 *Canalis alveolaris.* Contains nerves and vessels for incisor and canine teeth. A
- 6 *Pars molaris.* Caudal part with alveoli for premolar and molar teeth. A B C D
- 7 *Margo alveolaris.* Dorsal border presenting alveoli. A B C D
- 8 *Margo ventralis.* Free ventral border. A B C D
- 9 *Incisura vasorum facialium.* Notch for facial vessels, absent in Car. A C D
- 10 *Foramen mentale.* Opening of Canalis mandibulae in Ru and eq. A
- 11 *Foramina mentalia.* Openings of Canalis mandibulae in Car. B
- 12 *Foramina mentalia lateralia.* Openings on the lateral surface of the mandible in su. C
- 13 *Foramen mentale mediale.* Present in su. C
- 14 *Facies labialis.* Labial surface of Pars incisiva related to the lip. A B C
- 15 *Facies buccalis.* Lateral surface of Pars molaris related to the cheek. A B C
- 16 *Facies lingualis.* Lingual (internal) surface of the body of the mandible. D
- 17 *Linea mylohyoidea.* Line from which the M. mylohyoideus originates. C D
- 18 *Alveoli dentales.* See 34, 13. A
- 19 *Septa interalveolaria.* See 34, 14. A
- 20 *Septa interradicularia.* See 34, 15. A
- 21 *Juga alveolaria.* See 34, 26. A B
- 22 *Margo interalveolaris.* Portion of dorsal border without alveoli. A D
- 23 **Ramus mandibulae.** Dorsal directed caudal part of the mandible. A B C D
- 24 *Angulus mandibulae.* Angle between body and ramus of the mandible. A B C D
- 25 *Processus angularis.* Caudoventral process in Car. B
- 26 *Tuberositas m. sternomandibularis.* Insertion of M. sternocephalicus in eq. D
- 27 *Fossa masseterica.* Depression on the lateral surface for M. masseter. B
- 28 *Fossa pterygoidea.* Depression on medial surface for M. pterygoideus med. C D
- 29 *Foramen mandibulae.* Dorsocaudal opening of the Canalis mandibulae. C D
- 30 *Canalis mandibulae.* Canal for N. alveolaris inf. A B C D
- 31 *Sulcus mylohyoideus.* Groove rostroventral to Foramen mandibulae. C D
- 32 *Processus coronoideus.* Process for the attachment of M. temporalis. A B C D
- 33 *Incisura mandibulae.* Notch between coronoid and condylar processes. A B C D
- 34 *Processus condylaris.* Condylar (articular) process. A B C D
- 35 *Caput mandibulae.* Articular head of Proc. condylaris. A B C D
- 36 *Collum mandibulae.* Neck of Processus condylaris. A B C
- 37 *Fovea pterygoidea.* Insertion of M. pterygoideus lat. C D
- 38 **Apparatus hyoideus [Os hyoideum].** Hyoid apparatus [hyoid bone] E
- 39 *Basihyoideum [Corpus].* Body, rostroventral part. E
- 40 *Processus lingualis.* Rostral process in Ru and eq. E
- 41 *Ceratohyoideum [Cornu minus].* Lesser horn. E
- 42 *Thyrohyoideum [Thyreo-, Cornu majus].* Greater horn. E
- 43 *Epihyoideum.* Between Ceratohyoideum and Stylohyoideum, in su ligamentous. E
- 44 *Stylohyoideum.* Between Epihyoideum and Tympanohyoideum. E
- 45 *Angulus stylohyoideus.* Angle of Stylohyoideum. E
- 46 *Tympanohyoideum.* Between Stylohyoideum and Os temporale. E

A Left mandible, lateral aspect (bo)

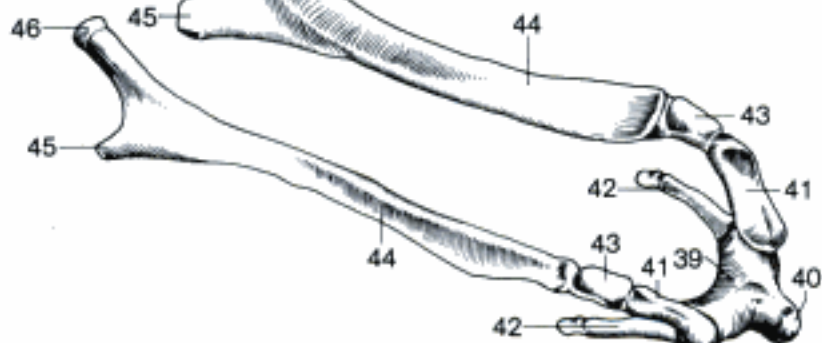


B Left mandible, lateral aspect (ca)



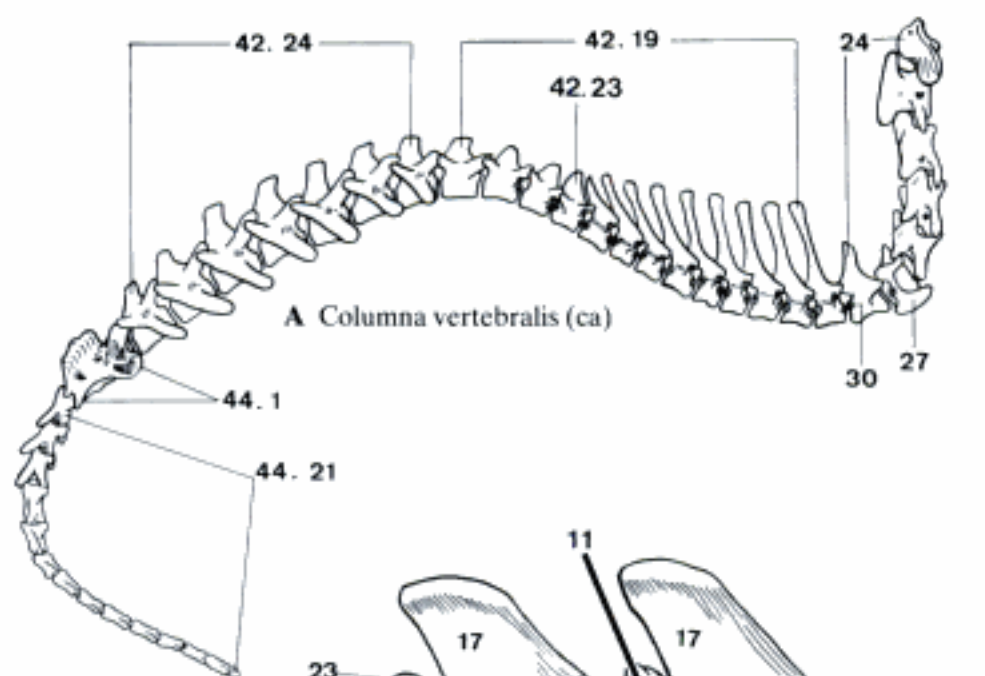
C Mandible, left caudoventral aspect (su)

D Left mandible, caudomedial aspect (eq)

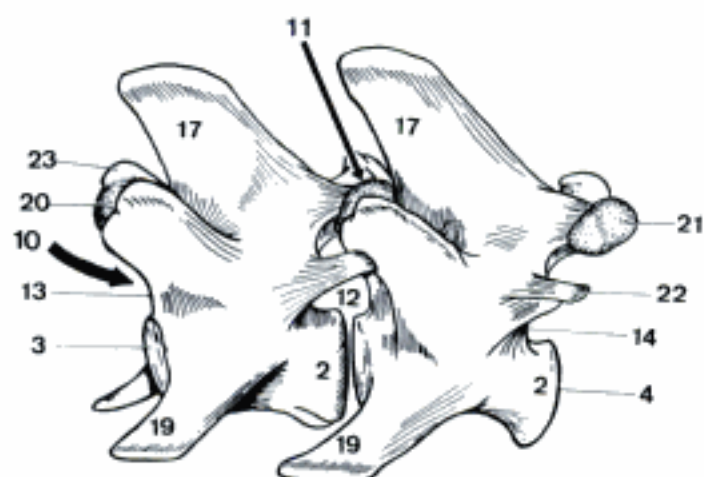


E Apparatus hyoideus, right dorsorostral aspect (bo)

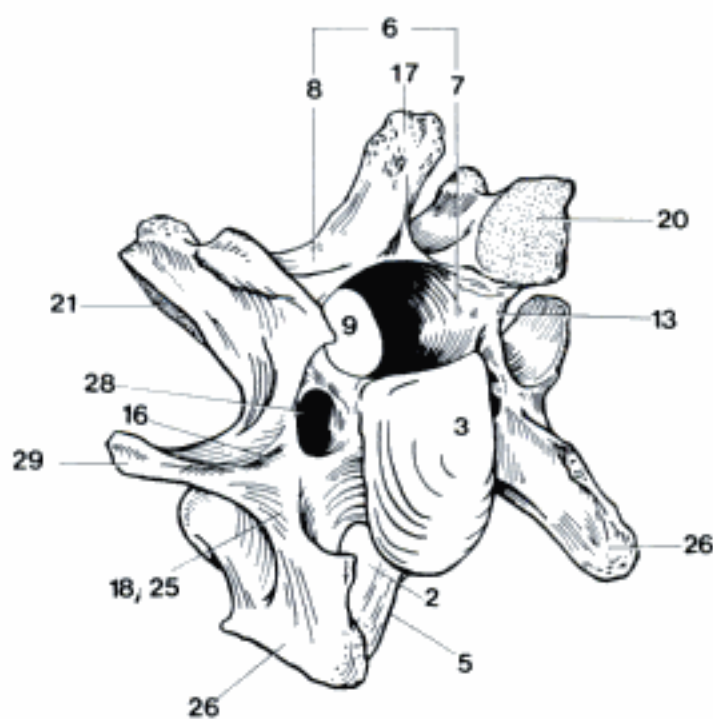
- 1 **COLUMNA VERTEBRALIS.** Vertebral column. A
- 2 *Corpus vertebrae.* Body of vertebra. B C
- 3 *Extremitas cranialis [Caput vertebrae].* Cranial extremity (head). B C
- 4 *Extremitas caudalis [Fossa vertebrae].* Caudal extremity. B
- 5 *Crista ventralis.* Ventral crest on the body of cervical, cranial and caudal thoracic, and lumbar vertebrae. C
- 6 *Arcus vertebrae.* Vertebral arch, forms the Foramen vertebrale dorsally and laterally. C
- 7 *Pediculus arcus vertebrae.* Pedicle (root) of the arch, attached to the body. C
- 8 *Lamina arcus vertebrae.* Dorsal portion of vertebral arch. C
- 9 *Foramen vertebrale.* Formed by the vertebral arch and body. C
- 10 *Canalis vertebralis.* Vertebral canal, formed by the Foramina vertebralia, contains the spinal cord. B
- 11 *Spatium interarcuale.* Interval separating adjacent arches dorsally. B
- 12 *Foramen intervertebrale.* Opening between adjacent vertebrae for passage of a spinal nerve. B
- 13 *Incisura vertebralis cranialis.* Cranial notch on the Pediculus. B C
- 14 *Incisura vertebralis caudalis.* Caudal notch on the Pediculus. B
- 15 *Foramen vertebrale laterale.* Conversion of a large caudal notch into a foramen, esp. in thoracic vertebrae of bo, occasionally eq, often doubled in su. 43 D
- 16 *Sulcus n. spinalis.* Groove for spinal nerve on transverse process of fourth to sixth cervical vertebra in fe, su, and bo. C
- 17 *Processus spinosus.* Spinous process. B C
- 18 *Processus transversus.* Transverse process. C
- 19 *Processus costalis.* The transverse process of a lumbar vertebra is homologous to a rib. B
- 20 *Processus articularis cranialis.* Cranial articular process on the vertebral arch. B C
- 21 *Processus articularis caudalis.* Caudal articular process on the vertebral arch. B C
- 22 *Processus accessorius.* Between transverse and caudal articular process on caudal thoracic (Car and su), and lumbar (Car) vertebrae. B
- 23 *Processus mamillaris.* Between transverse and cranial articular process on thoracic and lumbar vertebrae. B
- 24 **Vertebrae cervicales.** Cervical vertebrae. A
- 25 *Processus transversus.* Transverse process. C
- 26 *Tuberculum ventrale.* Cranioventral branch of transverse process of third to fifth cervical vertebra. C
- 27 *Lamina ventralis [vertebrae cervicalis VII].* Sagittal plate instead of a Tuberculum ventrale. A
- 28 *Foramen transversarium.* Opening in transverse process for passage of vertebral vessels and nerve. C
- 29 *Tuberculum dorsale.* Caudodorsal branch of transverse process of third to sixth cervical vertebra. C
- 30 *Fovea costalis caudalis [vertebrae cervicalis VII].* A



A Columna vertebralis (ca)

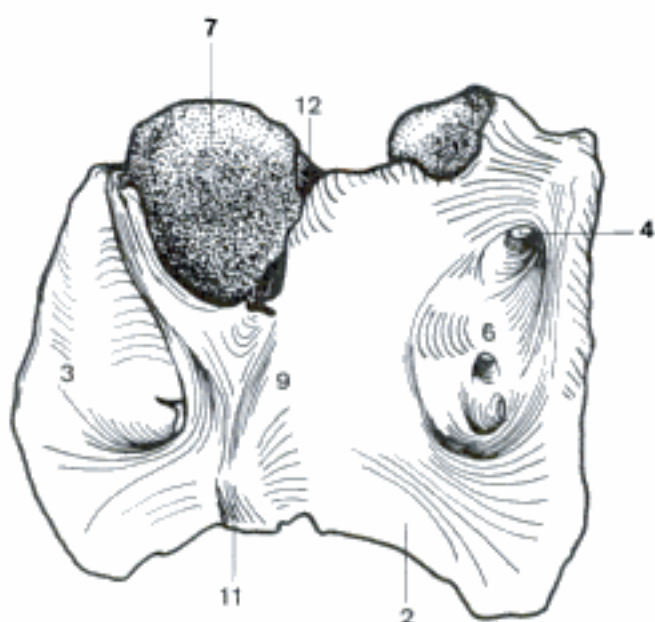


B Vertebrae lumbales II et III, left (and dorsal) aspect (ca)

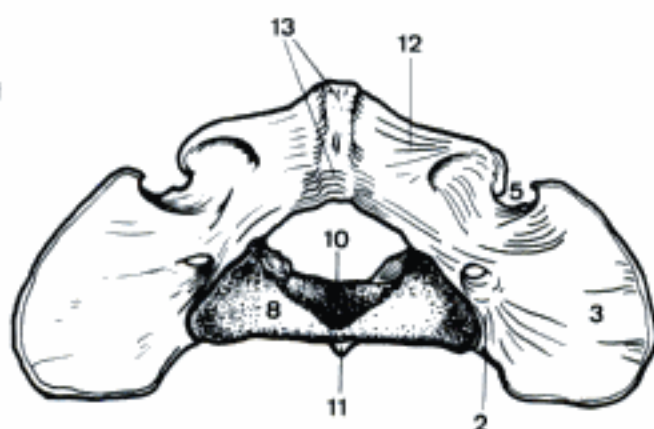


C Vertebra cervicalis IV, right cranial aspect (bo)

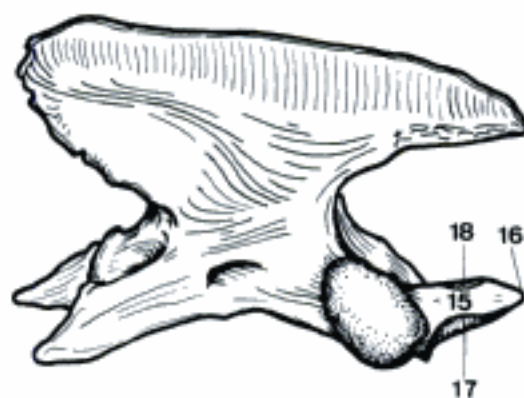
- 1 **Atlas.** First cervical vertebra, lacking a body. A B
- 2 *Massa lateralis.* Lateral portion of the Atlas. A B
- 3 *Processus transversus [Ala atlantis].* Transverse process (wing). A B
- 4 Foramen alare. Perforates the wing cranially for A, vertebralis, absent in Car. A
- 5 Incisura alaris (Car). Notch in the cranial border of the wing for A, vertebralis. B
- 6 *Fossa atlantis.* Concavity on ventral surface of the wing, esp. deep in eq, flat in Car. A
- 7 *Fovea articularis cranialis.* A
- 8 *Fovea articularis caudalis.* B
- 9 *Arcus ventralis.* Ventral arch. A
- 10 *Fovea dentis.* Articular fovea for dens of axis on the dorsal surface of the ventral arch. B
- 11 *Tuberculum ventrale.* Ventral tubercle. A B
- 12 *Arcus dorsalis.* Dorsal arch. A B
- 13 *Tuberculum dorsale.* Dorsal tubercle, vestige of a spinous process. B
- 14 **Axis.** Second cervical vertebra. C
- 15 *Dens.* Tooth-like cranial process of axis. C
- 16 *Apex.* Cranial extremity of the dens. C
- 17 *Facies articularis ventralis.* Ventral articular surface of the dens. C
- 18 *Facies articularis dorsalis.* Dorsal articular surface of the dens in Car and su. C
- 19 **Vertebrae thoracicae.** Thoracic vertebrae. 41 A
- 20 *Fovea costalis cranialis.* Facet on the cranial extremity for part of the head of a rib. D
- 21 *Fovea costalis caudalis.* Facet on the caudal extremity for part of the head of a rib. D
- 22 *Fovea costalis processus transversi.* Articular facet on transverse process for the Tuberculum costae. A
- 23 *Vertebra anticlinalis.* First vertebra in the caudal thoracic or lumbar region whose spinous process is perpendicular to the body. The spinous processes of the preceding vertebrae incline caudally. 41 A
- 24 **Vertebrae lumbales.** Lumbar vertebrae. 41 A



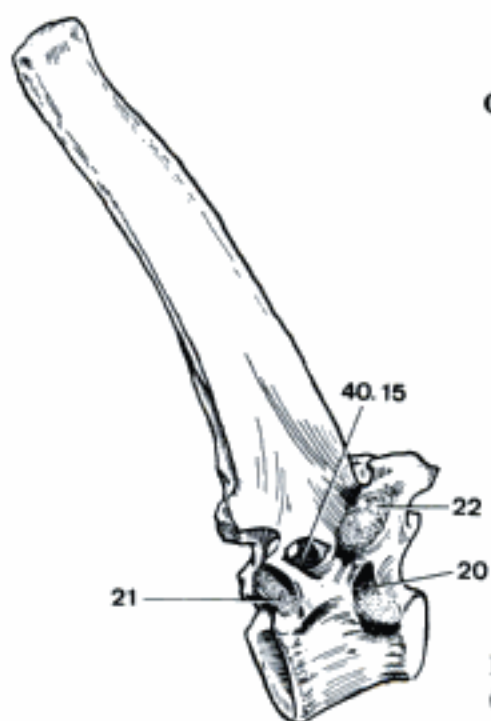
A Atlas, left ventral aspect (eq)



B Atlas, caudodorsal aspect (ca)

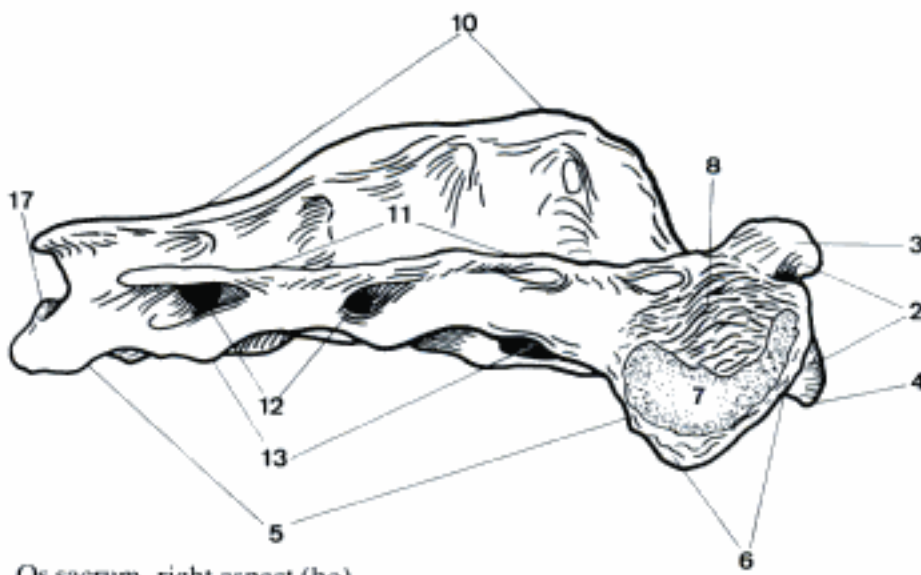


C Axis, right aspect (ca)



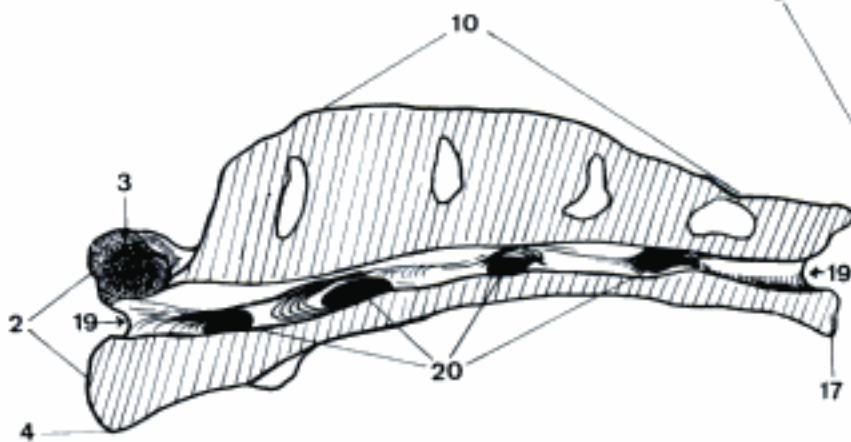
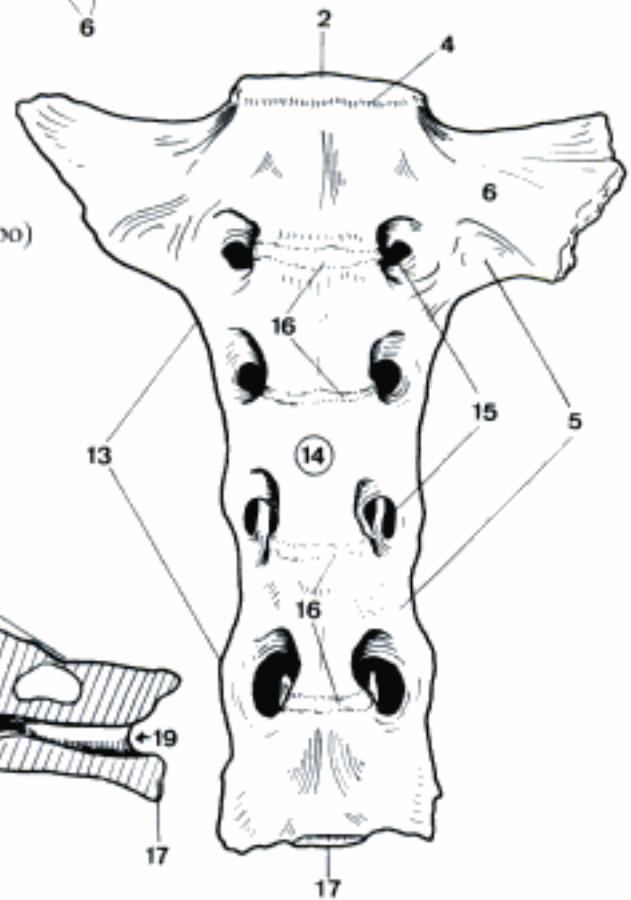
D Vertebra thoracica VIII, right (and caudal) aspect (eq)

- 1 **Os sacrum [Vertebrae sacrales]**. Fused sacral vertebrae. A B C D
- 2 *Basis ossis sacri*. Base (cranial extremity) of sacrum. A B C D
- 3 *Processus articularis cranialis*. A C D
- 4 *Promontorium*. Ventral border of Basis ossis sacri projecting together with the intervertebral disc into the pelvic inlet. A B C
- 5 *Pars lateralis*. Lateral part, composed of fused transverse processes. A B D
- 6 *Ala ossis sacri*. Wing of sacrum, the elongated first (eq, bo) or first and second transverse processes. A B D
- 7 *Facies auricularis*. Auricular surface for articulation with the ilium. A
- 8 *Tuberositas sacralis*. Rough surface dorsal to the Facies auricularis for attachment of ligaments. A
- 9 *Facies dorsalis*. Dorsal surface. D
- 10 *Crista sacralis mediana*. Dorsal crest in bo, sometimes also ov and cap, formed by the totally fused spinous processes. A C
- 11 *Crista sacralis intermedia*. Dorsolateral crest in bo formed by fusion of the articular processes. A
- 12 *Foramina sacralia dorsalia*. Openings for the exit of the dorsal branches of the sacral nerves. A D
- 13 *Crista sacralis lateralis*. Lateral crest formed by the fused transverse processes. A B
- 14 *Facies pelvina*. Pelvic (ventral) surface. B
- 15 *Foramina sacralia ventralia*. Openings for the exit of the ventral branches of the sacral nerves. B
- 16 *Lineae transversae*. Lines of fusion of the sacral vertebral bodies. B
- 17 *Apex ossis sacri*. Small caudal extremity of the sacrum. A B C
- 18 *Processus articularis caudalis*. Present only in Car and su. D
- 19 *Canalis sacralis*. Vertebral canal in the sacrum. C
- 20 *Foramina intervertebralia*. Openings between the arches of the sacral vertebrae for passage of the spinal nerves. C
- 21 **Vertebrae caudales [coccygeae]**. Caudal [coccygeal] vertebrae. 41 A
- 22 *Processus hemalis [haemalis]*. Paramedian ventral process in Car and Ru. E
- 23 *Arcus hemalis [haemalis]*. Hemal arch, formed by fusion of right and left Processus hemales usually of the second and third caudal vertebrae, in Car by the Processus hemales and attached Ossa arcus hemalis of one or more of the third to the eighth caudal vertebrae. E
- 24 *Os arcus hemalis [haemalis]*. Separate paired bone attached to Processus hemalis in Car. Right and left bones may fuse to form a single V-shaped bone. E

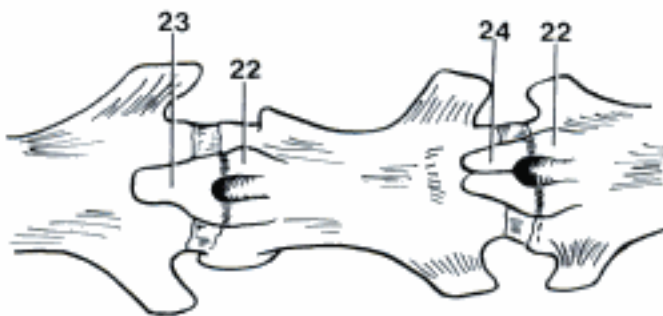


A Os sacrum, right aspect (bo)

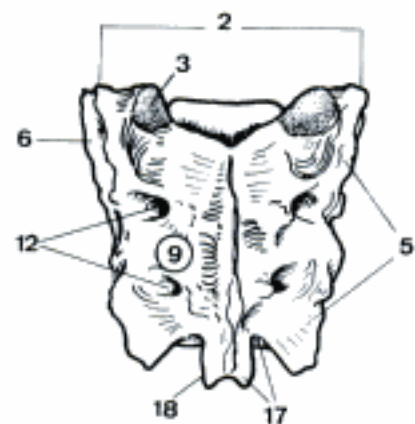
B Os sacrum, ventral aspect (bo)



C Os sacrum, median section, right half (bo)

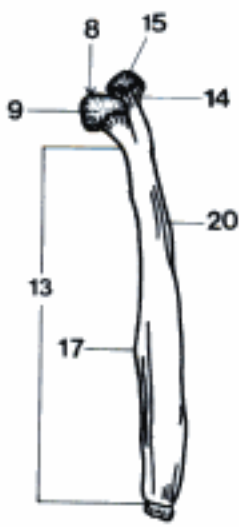


D Os sacrum, dorsal (and left) aspect (ca)

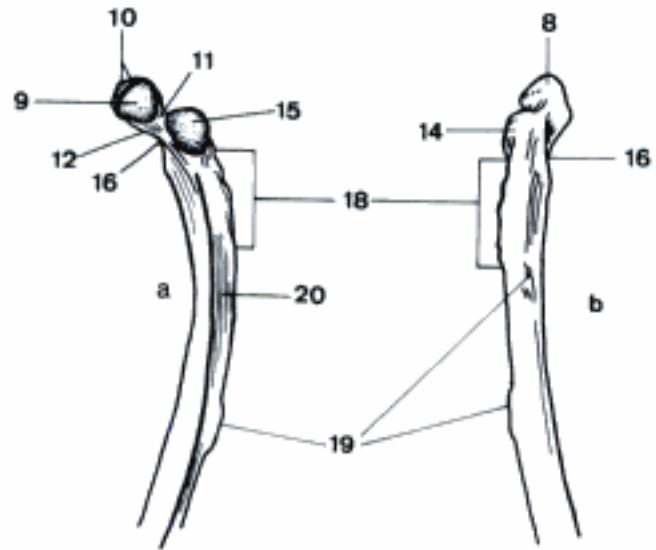


E Vertebrae caudales V, VI, VII, ventral aspect (fe)

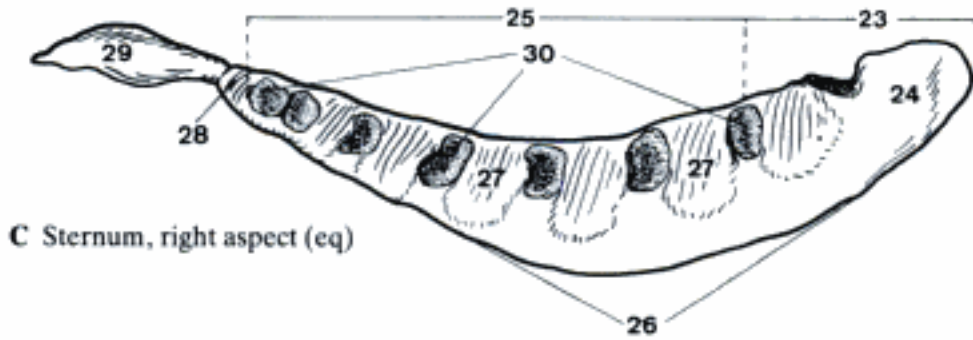
- 1 **SKELETON THORACIS.** Bony thorax comprizing the thoracic vertebrae, ribs, and sternum. D
- 2 **Costae.** Ribs. D
- 3 *Costae verae [sternales].* Sternal ribs, connected directly with the sternum. D
- 4 *Costae spuriae [asternales].* Asternal ribs, not directly connected to the sternum. D
- 5 *Costae fluctuantes.* Floating ribs, their ventral ends are free. D
- 6 *Cartilago costalis.* Costal cartilage, the ventral part of the rib. D
- 7 *Os costale.* Bony dorsal part of the rib. D
- 8 *Caput costae.* Head of rib, articulates with two vertebral bodies. A B
- 9 *Facies articularis capitis costae.* Articular surface of the head of a rib. A B
- 10 *Crista capitis costae.* Crest of head of a rib, separates the two parts of the *Facies articularis*. B
- 11 *Collum costae.* Neck of rib. Narrow portion extending lateral from the head. B
- 12 *Crista colli costae.* Crest on cranial border of the neck of the rib. B
- 13 *Corpus costae.* Body (main part) of the rib. A
- 14 *Tuberculum costae.* Tubercle of the rib. Dorsal eminence between *Collum* and *Corpus costae*. A B
- 15 *Facies articularis tuberculi costae.* Articular surface of tubercle, articulates with the transverse process of a vertebra. A B
- 16 *Angulus costae.* Angle of the rib, accentuated point of the curvature near the *Tuberculum*. B
- 17 *Tuberculum m. scaleni ventralis.* Raised area on the cranial border of the first rib for the termination of *M. scalenus ventralis*, easily seen in su and eq. A
- 18 *Tuberositas m. longissimi.* Tuberosity for attachment of *M. longissimus*, always present in eq, often occurring in other species. B
- 19 *Tuberositas m. iliocostalis.* Tuberosity for attachment of *M. iliocostalis*, always present in eq, often occurring in other species. B
- 20 *Sulcus costae.* Costal groove, on medial surface near caudal border. A B
- 21 *Genu costae.* Knee of rib, curvature near costochondral junction in Un, within the cartilage in Car. D
- 22 **Sternum.** C D
- 23 *Manubrium sterni.* Cranial extremity of the sternum. C D
- 24 *Cartilago manubrii.* Cartilage of manubrium, absent or small in Ru. C D
- 25 *Corpus sterni.* Body of the sternum, between *Manubrium* and *Processus xiphoides*. C D
- 26 *Crista sterni.* Cartilaginous ventral crest in eq. C
- 27 *Sternebrae.* Bony segments, united by intervening cartilages or fused by synostoses. C
- 28 *Processus xiphoides.* Xiphoid process at caudal extremity of the sternum. C
- 29 *Cartilago xiphoides.* Xiphoid cartilage, caudal continuation of xiphoid process. C
- 30 *Incisurae costales.* Costal notches, depressions for costal cartilages. C
- 31 **Cavum thoracis.** Thoracic cavity. D
- 32 *Apertura thoracis cranialis.* Cranial thoracic aperture, thoracic inlet. D
- 33 *Apertura thoracis caudalis.* Caudal thoracic aperture, thoracic outlet. D
- 34 *Sulcus pulmonalis.* Dorsal part of thoracic cavity, lateral to the vertebral bodies. D
- 35 *Arcus costalis.* Costal arch, formed by cartilages of the last sternal and the asternal ribs. D
- 36 *Spatium intercostale.* Intercostal space. D
- 37 *Angulus arcuum costalium.* Angle between right and left costal arches. D



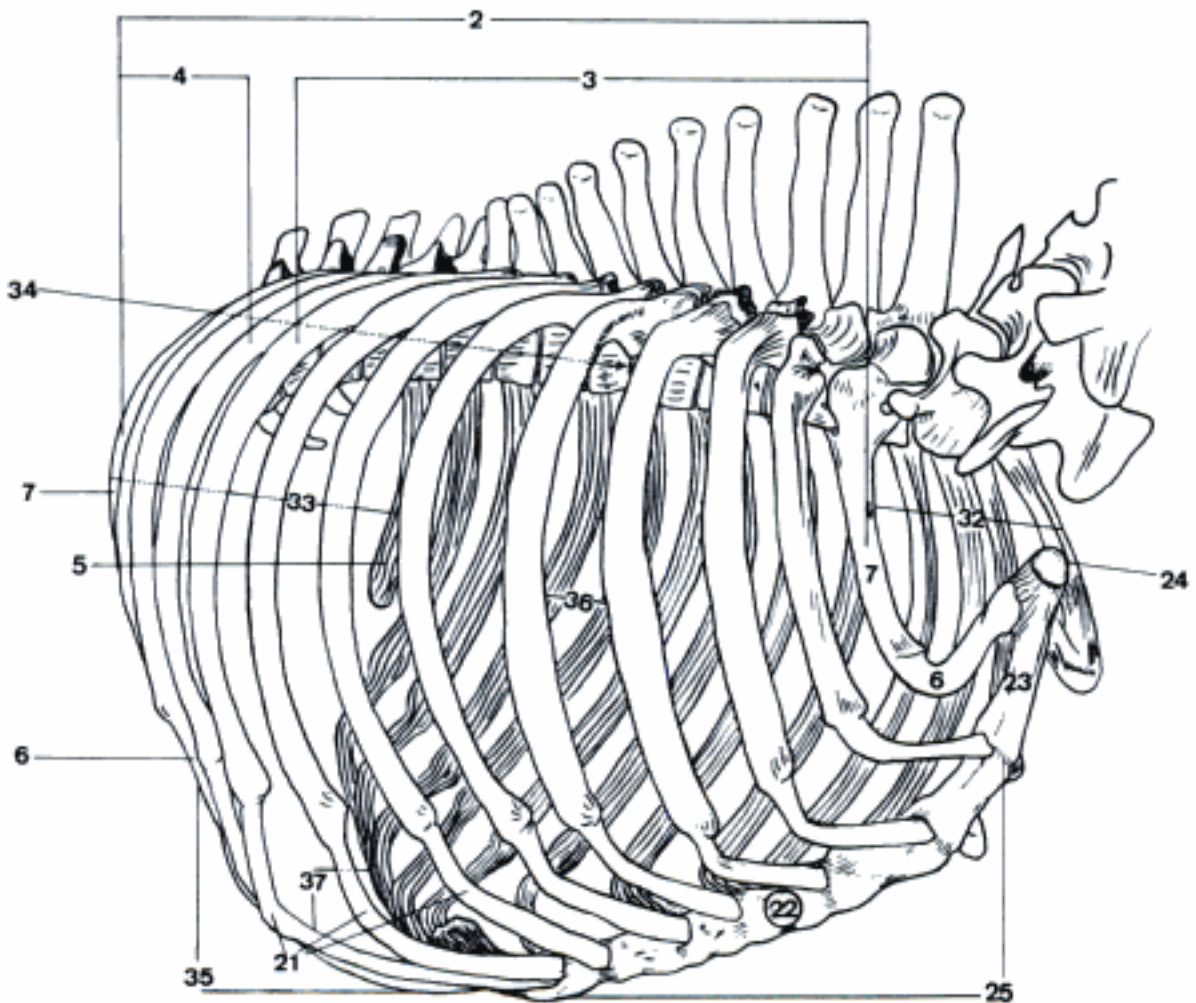
A Right 1st rib, medial aspect (eq)



B Dorsal part of right 12th rib (eq)
a medial aspect
b lateral aspect

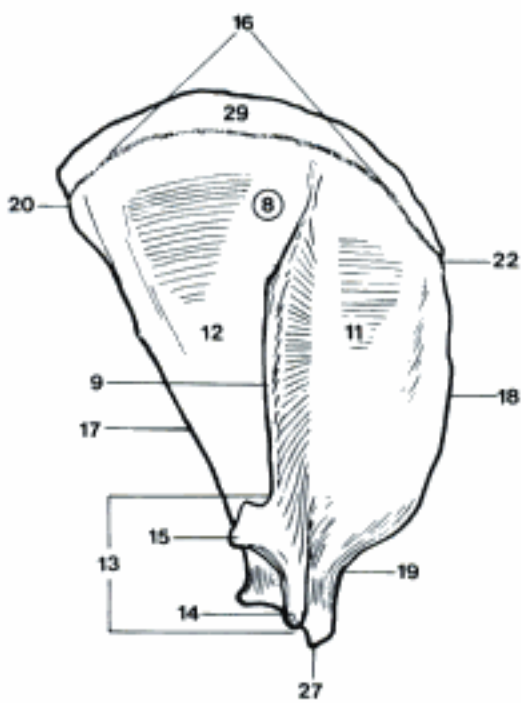


C Sternum, right aspect (eq)

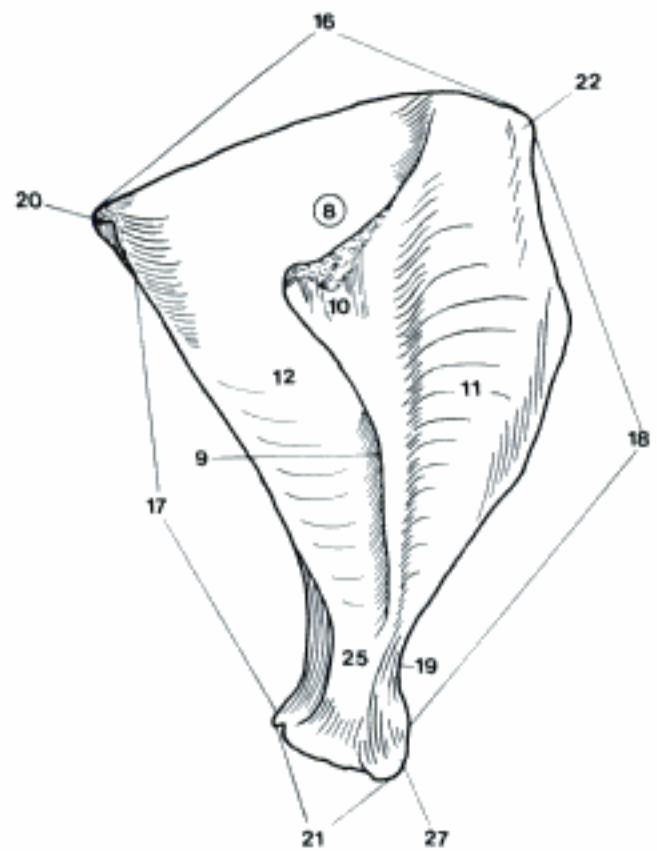


D Thorax, right cranioventral aspect (ca)

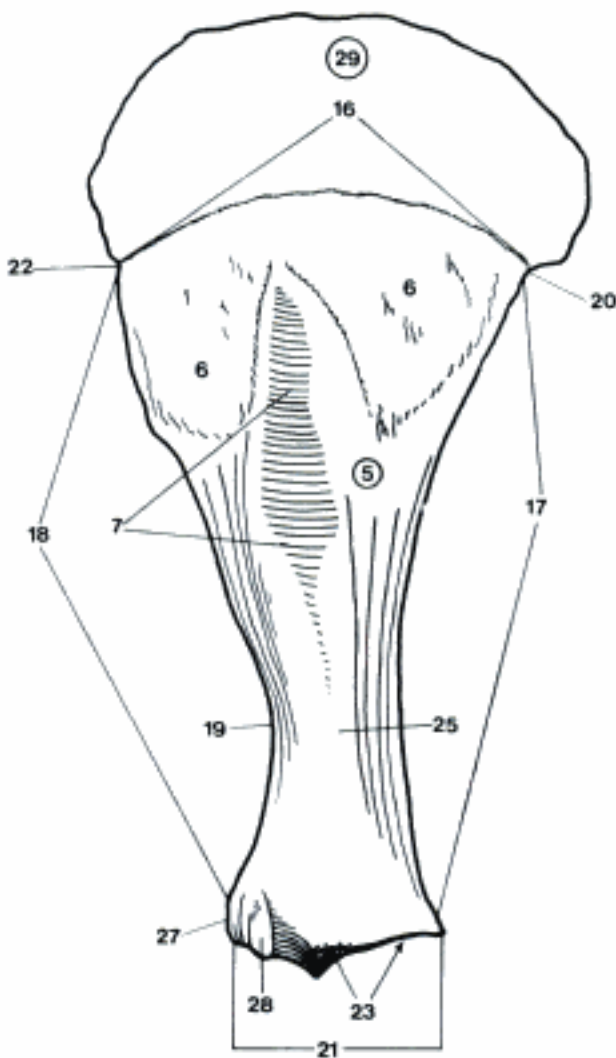
- 1 **SKELETON APPENDICULARE.** Appendicular skeleton.
- 2 **OSSA MEMBRI THORACICI.** Bones of thoracic limb.
- 3 **Cingulum membri thoracici.** Shoulder girdle.
- 4 **Scapula.** Shoulder blade. A B C
- 5 *Facies costalis [medialis].* Costal (medial) surface, facing the ribs. C
- 6 *Facies serrata.* Surface for termination of *M. serratus ventralis*. C
- 7 *Fossa subscapularis.* Concavity for origin of *M. subscapularis*. C
- 8 *Facies lateralis.* Lateral surface. A B
- 9 *Spina scapulae.* Spine on lateral surface of the scapula. A B D
- 10 *Tuber spinae scapulae (su, eq).* Tuber in the middle of *Spina scapulae*. B
- 11 *Fossa supraspinata.* Fossa cranial to *Spina scapulae*. A B
- 12 *Fossa infraspinata.* Fossa caudal to *Spina scapulae*. A B
- 13 *Acromion.* Ventral end of *Spina scapulae* in Car and Ru. A D
- 14 *Processus hamatus.* Ventral process of *Acromion* in Car. A D
- 15 *Processus suprahamatus (fe).* Caudal process of *Acromion*. A
- 16 *Margo dorsalis.* Dorsal border facing the vertebral column. A B C
- 17 *Margo caudalis.* Caudal border facing the *Regio tricipitalis*. A B C
- 18 *Margo cranialis.* Cranial border facing the neck. A B C
- 19 *Incisura scapulae.* Scapular notch in cranial border dorsal to *Tuberculum supraglenoidale*. A B C
- 20 *Angulus caudalis.* Caudal angle. A B C
- 21 *Angulus ventralis.* Ventral angle, bears the glenoid cavity. B C E
- 22 *Angulus cranialis.* Cranial angle. A B C
- 23 *Cavitas glenoidalis.* Glenoid cavity, for articulation with the humerus. C D E
- 24 *Incisura glenoidalis.* Craniomedial notch in the border of glenoid cavity in eq. E
- 25 *Collum scapulae.* Neck of scapula, dorsal to the *Angulus ventralis*. B C
- 26 *Tuberculum infraglenoidale.* Tubercle on the caudal border dorsal to the *Angulus ventralis* for origin of *M. triceps brachii* in ca. D
- 27 *Tuberculum supraglenoidale.* Tubercle on ventral end of the cranial border for origin of *M. biceps brachii*. B C
- 28 *Processus coracoideus.* Medial process on *Tuberculum supraglenoidale* for origin of *M. coracobrachialis*. Small in domestic mammals. C E
- 29 *Cartilago scapulae.* Scapular cartilage on dorsal border, small in Car. A C
- 30 **Clavicula.** Clavicle in fe, rudimentary in ca. F



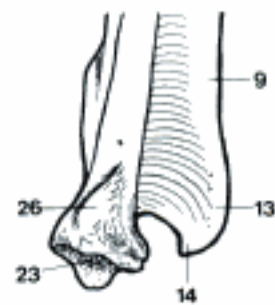
A Right scapula, lateral aspect (fe)



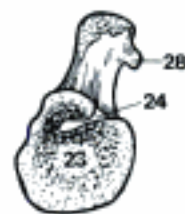B Right scapula, lateral aspect (su)



C Right scapula, medial aspect (eq)



D Part of right scapula, caudal aspect (ca)

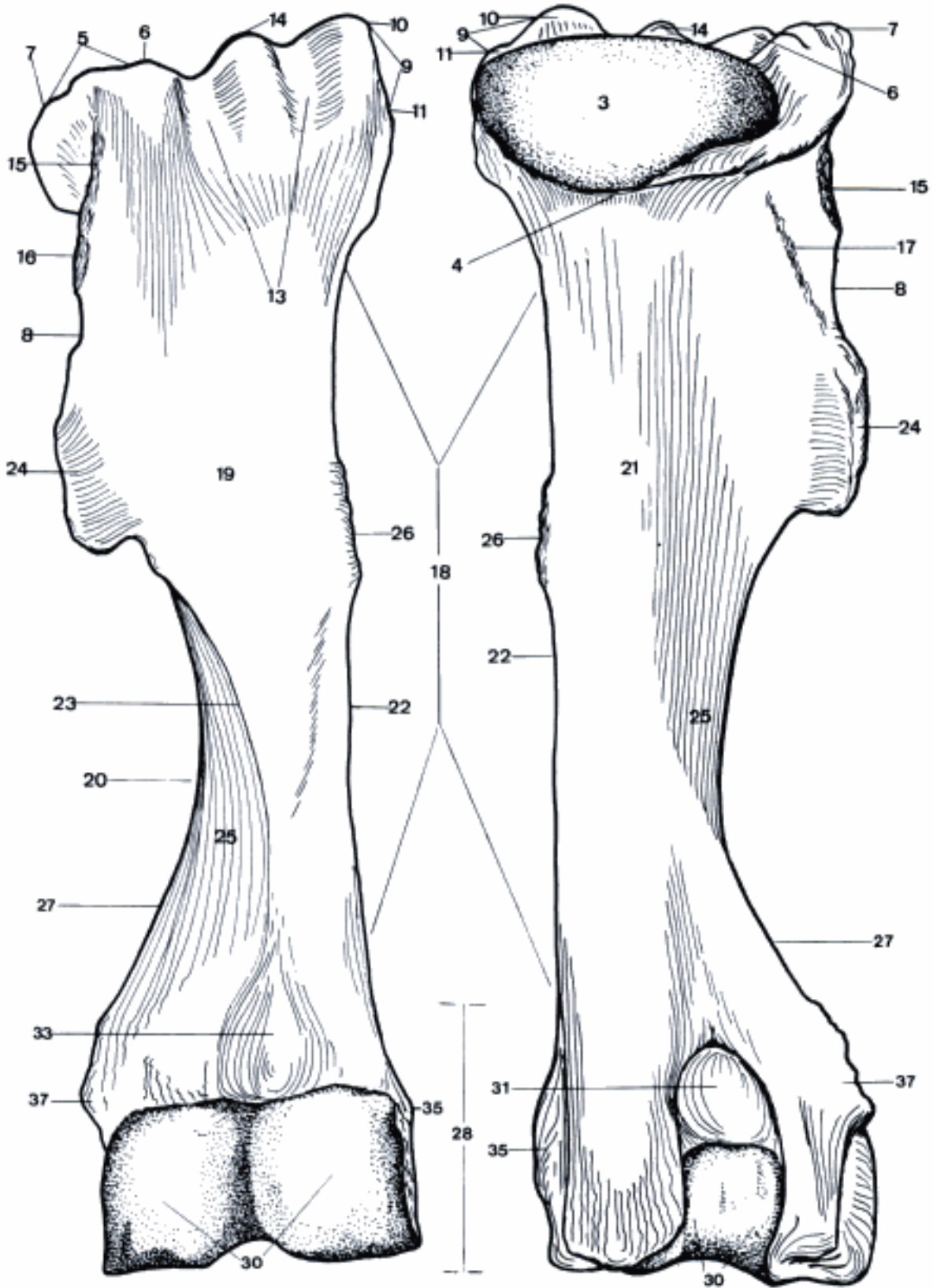


E Angulus ventralis of right scapula, cranioventral aspect (eq)



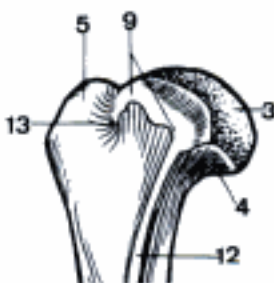
F Right clavicle, dorsal aspect (fe)

- 1 **Skeleton brachii.** Arm skeleton.
- 2 **Humerus.** A B
- 3 *Caput humeri.* Head of humerus. B C
- 4 *Collum humeri.* Neck of humerus. Between the head and the tubercles and body. B C
- 5 *Tuberculum majus.* Greater tubercle, cranio-lateral on the proximal extremity of the humerus. A C
- 6 *Pars cranialis.* Cranial part of Tuberculum majus in Un. A B
- 7 *Pars caudalis.* Caudal part of Tuberculum majus in Un. A B
- 8 *Crista tuberculi majoris.* Crest of the greater tubercle running distally. A B
- 9 *Tuberculum minus.* Lesser tubercle, craniomedial on the proximal extremity of the humerus. A B C
- 10 *Pars cranialis.* Cranial part of Tuberculum minus in Ru and eq. A B
- 11 *Pars caudalis.* Caudal part of Tuberculum minus in Ru and eq. A B
- 12 *Crista tuberculi minoris.* Crest of lesser tubercle running distally. C
- 13 *Sulcus intertubercularis.* Intertubercular groove between the two tubercles. A C
- 14 *Tuberculum intermedium.* Intermediate tubercle in the Sulcus intertubercularis in eq. A B
- 15 *Facies m. infraspinati.* Area of termination of a part of M. infraspinatus. A B
- 16 *Tuberositas teres minor.* Area of termination of M. teres minor. A
- 17 *Linea m. tricipitis.* Line of origin of Caput laterale m. tricipitis brachii. B
- 18 *Corpus humeri.* Body of humerus. A B
- 19 *Facies cranialis.* Cranial surface. A
- 20 *Facies lateralis.* Lateral surface. A
- 21 *Facies caudalis.* Caudal surface. B
- 22 *Facies medialis.* Medial surface. A B
- 23 *Crista humeri.* Crest of humerus, running distally from Tuberositas deltoidea. A
- 24 *Tuberositas deltoidea.* Deltoid tuberosity, on the lateral surface for insertion of M. deltoideus. A B
- 25 *Sulcus m. brachialis.* Oblique groove in laterodistal direction for M. brachialis. A B
- 26 *Tuberositas teres major.* Teres tuberosity, area of termination of M. teres major and M. latissimus on the medial surface in Un. A B
- 27 *Crista supracondylaris lateralis.* Crest running proximally from Epicondylus lateralis. A B D
- 28 *Condylus humeri.* The whole distal end of the humerus. A B D
- 29 *Capitulum humeri.* Present in Car, more distinctly in fe. D
- 30 *Trochlea humeri.* Semicylindrical portion of distal end. A B D
- 31 *Fossa olecrani.* Deep depression on the caudal surface proximal to the trochlea. B
- 32 *Fossa coronoidea.* Depression on the cranial surface in fe, medial to Fossa radialis accommodating the Processus coronoideus medialis ulnae when the elbow is flexed. D

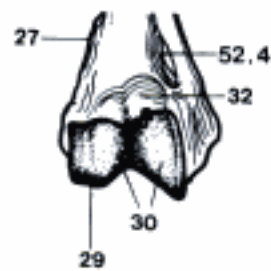


A Right humerus, cranial aspect (cq)

B Right humerus, caudal aspect (eq)

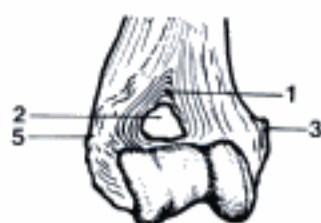

C Part of right humerus, medial aspect (ca)

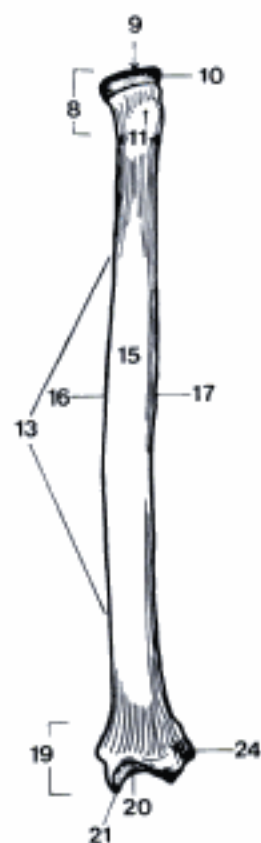


D Condylus of right humerus, cranial aspect (fe)

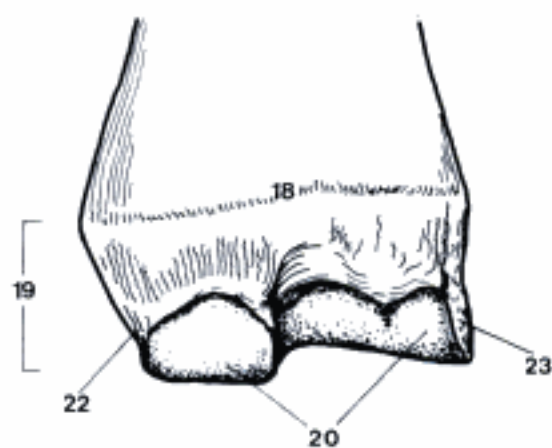
- 1 *Fossa radialis*. Depression on the cranial surface proximal to the trochlea accommodating the Caput radii when the elbow is flexed. A
- 2 *Foramen supratrochleare*. Opening between Fossa olecrani and Fossa radialis in ca and occasionally in su. A
- 3 *Epicondylus medialis*. Medial prominence of Condylus humeri. A
- 4 *Foramen supracondylare (fe)*. Opening in Epicondylus medialis. 51 D
- 5 *Epicondylus lateralis*. Lateral prominence of Condylus humeri. A
- 6 **Skeleton antebrachii**. Forearm skeleton.
- 7 **Radius**. B D
- 8 *Caput radii*. Head of radius. B D
- 9 *Fovea capitis radii*. Fovea of head of radius. B D
- 10 *Circumferentia articularis*. Circumference for articulation with Incisura radialis ulnae in Car, reduced to two small caudal facets in Un. B
- 11 *Collum radii*. Neck of radius. Between the head and the body. B D
- 12 *Tuberositas radii*. Radial tuberosity. Medially located, roughened area of the neck of the radius for insertion of the biceps. D
- 13 *Corpus radii*. Body of the radius. B D
- 14 *Facies cranialis*. Cranial surface. D
- 15 *Facies caudalis*. Caudal surface. B
- 16 *Margo medialis*. Medial border. B D
- 17 *Margo lateralis*. Lateral border. B D
- 18 *Crista transversa*. Transverse crest on the caudal surface, proximal to the trochlea. C
- 19 *Trochlea radii*. Trochlea of radius, distal end. B C D
- 20 *Facies articularis carpea*. Surface for articulation with the carpal bones. B C D
- 21 *Processus styloideus*. Styloid process, distal extension of radius, located medially, except eq. B
- 22 *Processus styloideus medialis*. For sake of clarity in eq the process homologous to Processus styloideus of other species is designated "medialis". C D
- 23 *Processus styloideus lateralis*. The lateral styloid process in eq appears to originate from the radius, although developmentally it belongs to the ulna. C D
- 24 *Incisura ulnaris*. Ulnar notch. Concave surface for articulation with the ulna in Car and su. B



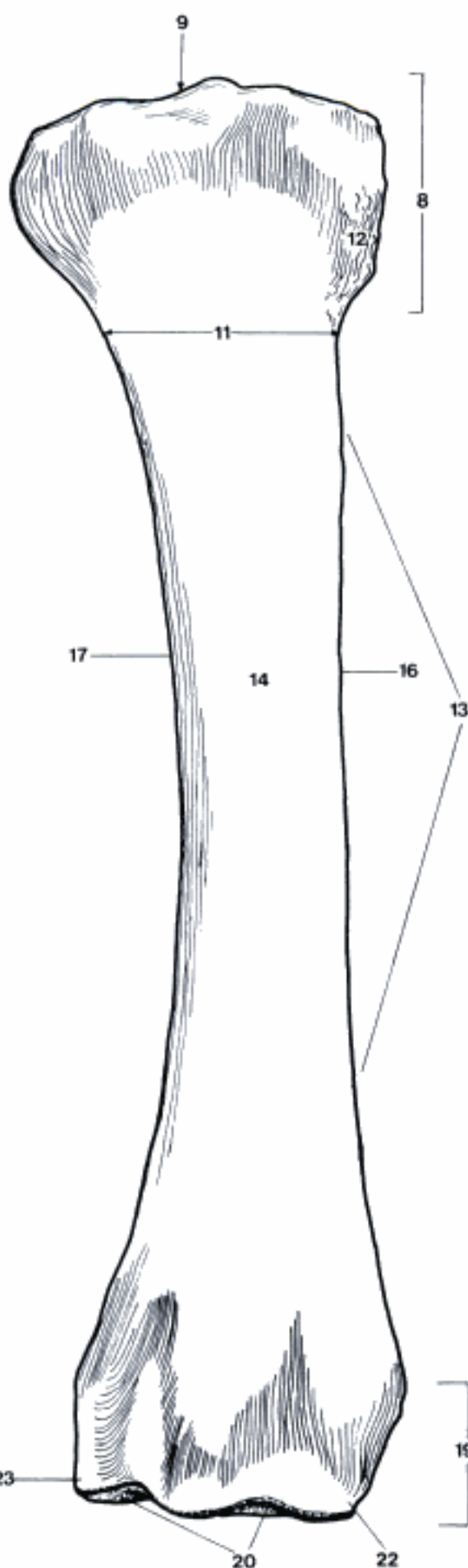
A Condylus of right humerus, cranial aspect (ca)



B Right radius, caudal aspect (ca)



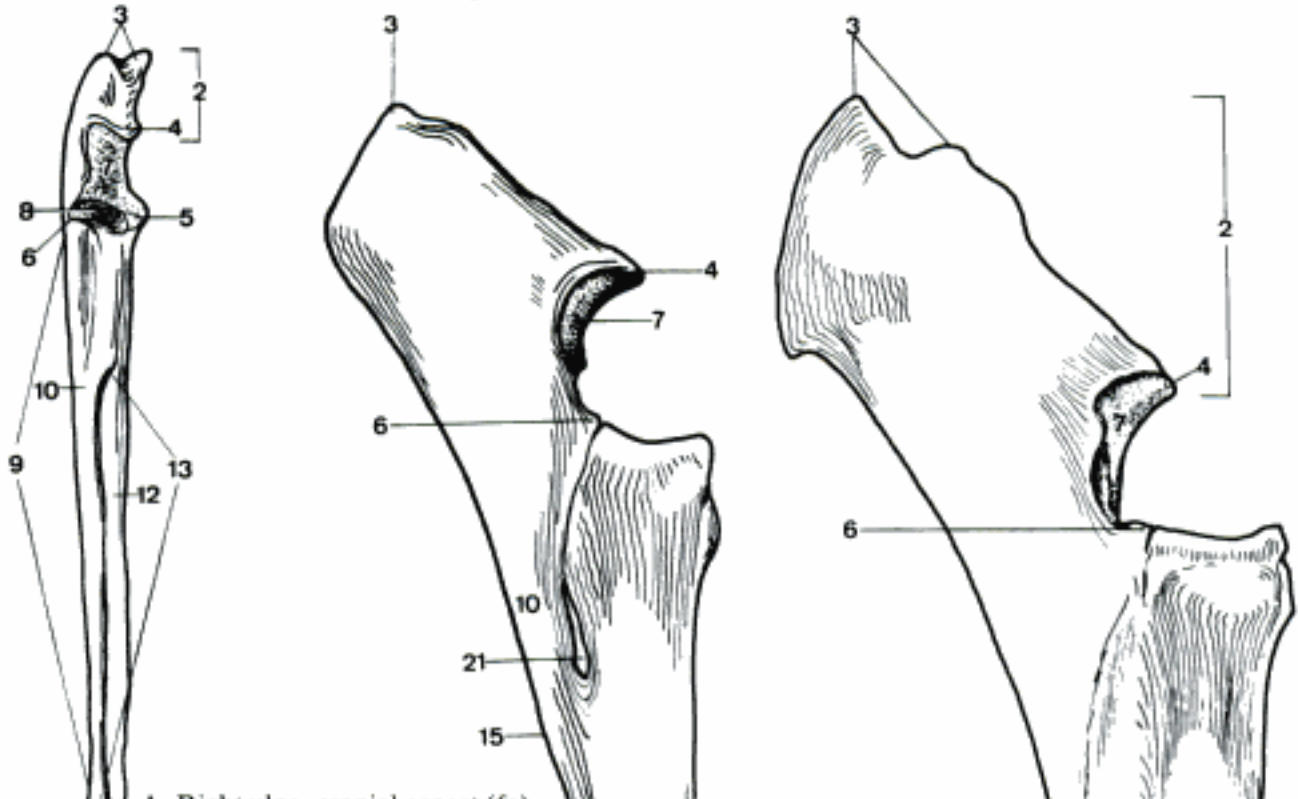
C Part of right radius, caudal aspect (cq)



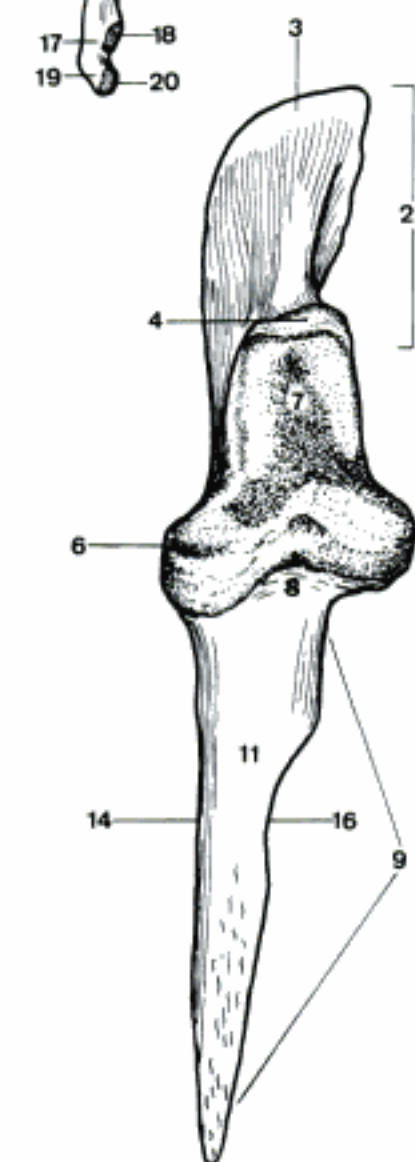
D Right radius, cranial aspect (cq)

- 1 **Ulna.** A C D E
- 2 *Olecranon.* Proximal extremity of the ulna. A C D E
- 3 *Tuber olecrani.* Proximal tuberosity for attachment of the triceps. A B C D E
- 4 *Processus anconeus [anconaeus].* Cranial process at the proximal end of *Incisura trochlearis*. A B C D E
- 5 *Processus coronoideus medialis.* Craniomedial process at the distal end of *Incisura trochlearis*. It corresponds to the *Processus coronoideus* of man. A D E
- 6 *Processus coronoideus lateralis.* Craniolateral process at the distal end of *Incisura trochlearis*, reduced in Car. A B C D E
- 7 *Incisura trochlearis.* Trochlear notch, articulating with *Trochlea humeri*. A B C D
- 8 *Incisura radialis.* Radial notch, between the coronoid processes, facing the *Caput radii*. A D
- 9 *Corpus ulnae.* Body of the ulna, reduced in eq. A C D E
- 10 *Facies lateralis.* Lateral surface. A B C E
- 11 *Facies cranialis.* Cranial surface. D
- 12 *Facies medialis.* Medial surface. A E
- 13 *Margo interosseus.* Border for attachment of *Membrana interossea* in Car. A
- 14 *Margo lateralis.* Lateral border in Un. D E
- 15 *Margo caudalis.* Caudal border. B C E
- 16 *Margo medialis.* Medial border. D E
- 17 *Caput ulnae.* Head of the ulna, distal extremity, except in eq. A C
- 18 *Circumferentia articularis.* Circumference for articulation with *Incisura ulnaris* of radius in Car and su. A
- 19 *Processus styloideus.* Styloid process, distal extension of the ulna. A C
- 20 *Facies articularis carpea.* Surface for articulation with *Os carpi ulnare*. A
- 21 *Spatium interosseum antebrachii.* Interosseous space between radius and ulna in eq. B
- 22 *Spatium interosseum antebrachii proximale.* Proximal interosseous space between radius and ulna in Ru. C
- 23 *Spatium interosseum antebrachii distale.* Distal interosseous space between radius and ulna in Ru. C

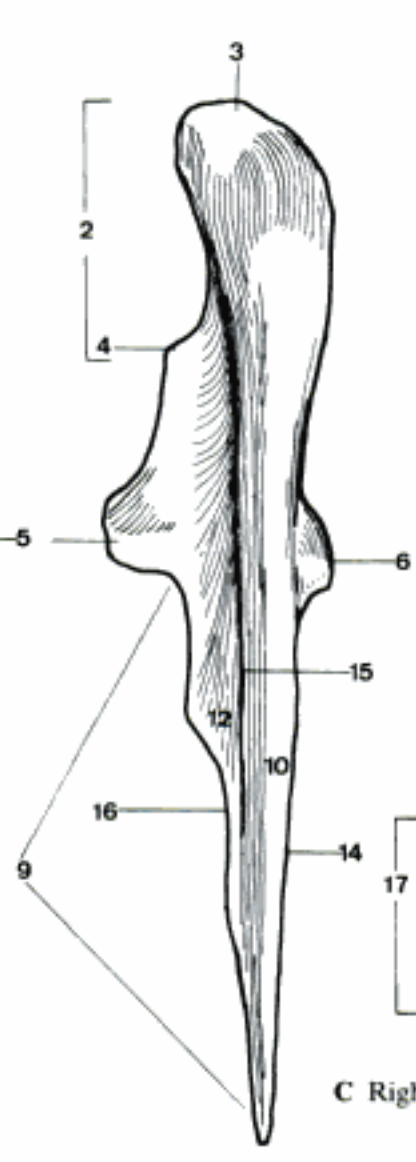
B Part of right radius and ulna, lateral aspect (eq)



A Right ulna, cranial aspect (fe)

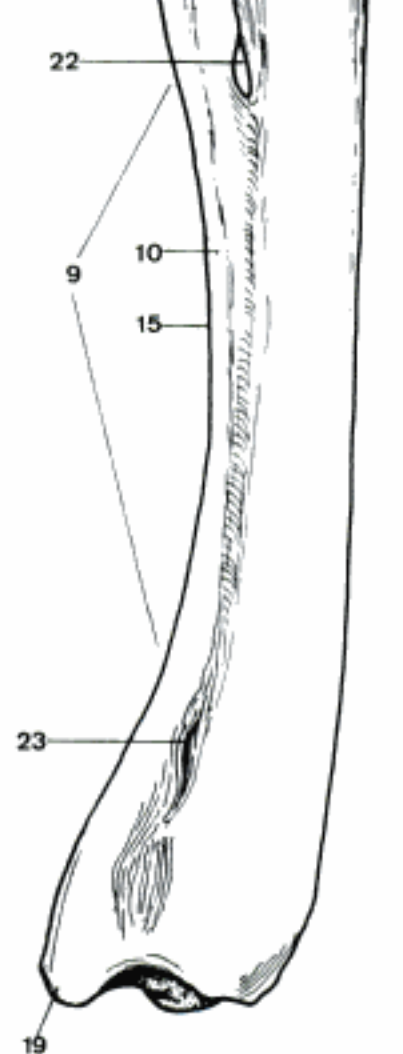


D Right ulna, cranial aspect (eq)

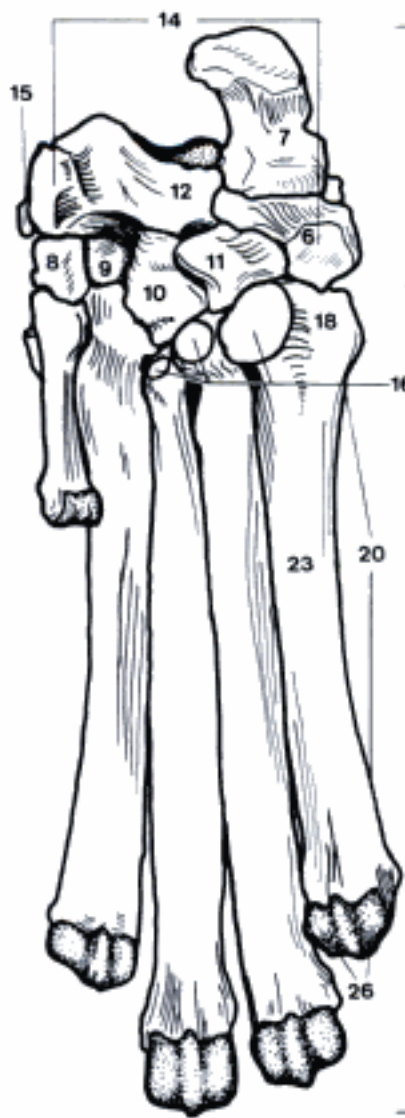


E Right ulna, caudal aspect (eq)

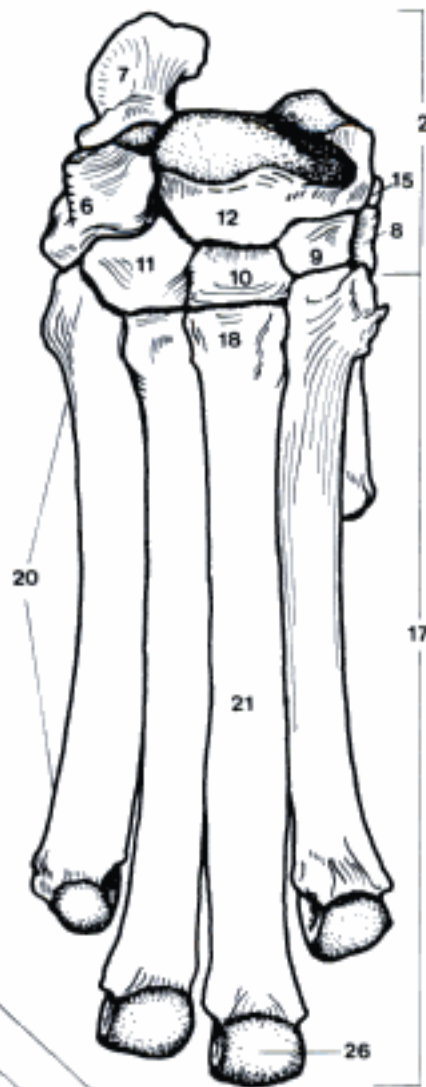
C Right radius and ulna, lateral aspect (bo)



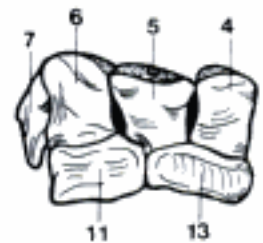
- 1 **Skeleton manus.**
- 2 **Ossa carpi.** Carpal bones. A B C
- 3 (*Os carpi centrale*). The central carpal bone of Car is situated distal to the *Os carpi intermedioradiale*, proximal to the *Os carpale II* and *Os carpale III*, and fuses with the *Os carpi intermedioradiale* some weeks after birth.
- 4 *Os carpi radiale [Os scaphoideum]*. Radial carpal [scaphoid] bone. C
- 5 *Os carpi intermedium [Os lunatum]*. Intermediate carpal [lunate] bone. C
- 6 *Os carpi ulnare [Os triquetrum]*. Ulnar carpal [triangular] bone. A B C
- 7 *Os carpi accessorium [Os pisiforme]*. Accessory carpal [pisiform] bone. A B C
- 8 *Os carpale I [Os trapezium]*. First carpal [trapezium] bone, absent in Ru and often in eq. A B
- 9 *Os carpale II [Os trapezoideum]*. Second carpal [trapezoid] bone. A B
- 10 *Os carpale III [Os capitatum]*. Third carpal [capitate] bone. A B
- 11 *Os carpale IV [Os hamatum]*. Fourth carpal [hamate] bone. A B C
- 12 *Os carpi intermedioradiale [Os scapholunatum]*. Fused radial and intermediate carpal bones in Car. A B
- 13 *Os carpale II et III [Os trapezoideo-capitatum]*. Fused second and third carpal bones in Ru. C
- 14 *Sulcus carpi*. Carpal groove, formed by the palmar surface of radial and intermediate carpal bones and the medial surface of the accessory carpal bone, converted into the *Canalis carpi* for flexor tendons by the *Retinaculum flexorum*. A
- 15 *Os sesamoideum m. abductoris digiti I [pollicis] longi*. Sesamoid bone on the medial side of the carpus in Car. A B
- 16 (*Ossa sesamoidea palmaria*). Variable sesamoid bones on the palmar surface of the carpus in Car. A
- 17 **Ossa metacarpalia I–V.** Metacarpal bones I–V. A B D E
- 18 *Basis*. Base, the proximal end. A B D E
- 19 *Facies articularis*. Articular surface. D E
- 20 *Corpus*. Body. A B D E
- 21 *Facies dorsalis*. Dorsal surface. B E
- 22 *Tuberositas ossis metacarpalis III*. Tuberosity at the base of the third metacarpal bone for insertion of *M. extensor carpi radialis (brevis in Car)*. E
- 23 *Facies palmaris*. Palmar surface. A D
- 24 *Margo medialis*. Medial border. D E
- 25 *Margo lateralis*. Lateral border. D E
- 26 *Caput*. Head, the distal end. A B D E
- 27 *Os metacarpale III et IV (Ru)*. Fused third and fourth metacarpal bones. E
- 28 *Sulcus longitudinalis dorsalis*. Dorsal longitudinal groove. E
- 29 *Sulcus longitudinalis palmaris*. Palmar longitudinal groove. D
- 30 *Canalis metacarpi proximalis*. Proximal metacarpal canal. D E
- 31 *Canalis metacarpi distalis*. Distal metacarpal canal. D E
- 32 *Incisura intertrochlearis*. Intertrochlear notch, dividing the distal ends. D E



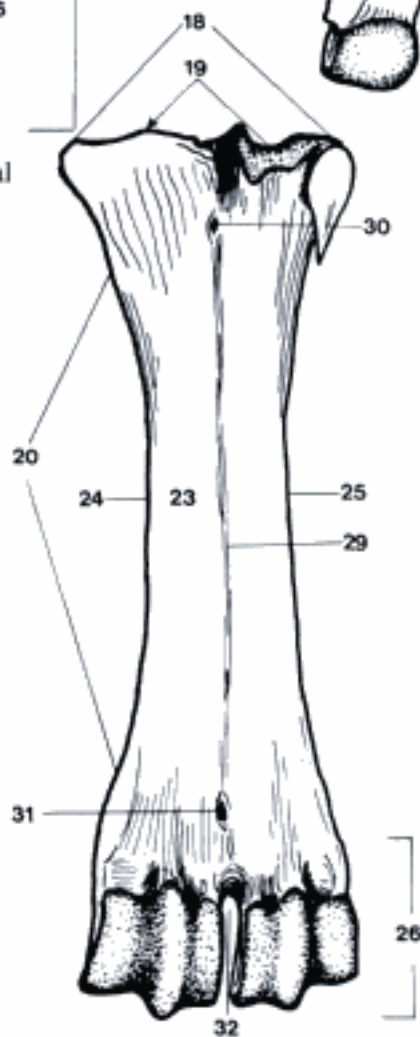
A Right carpal and metacarpal bones, palmar aspect (ca)



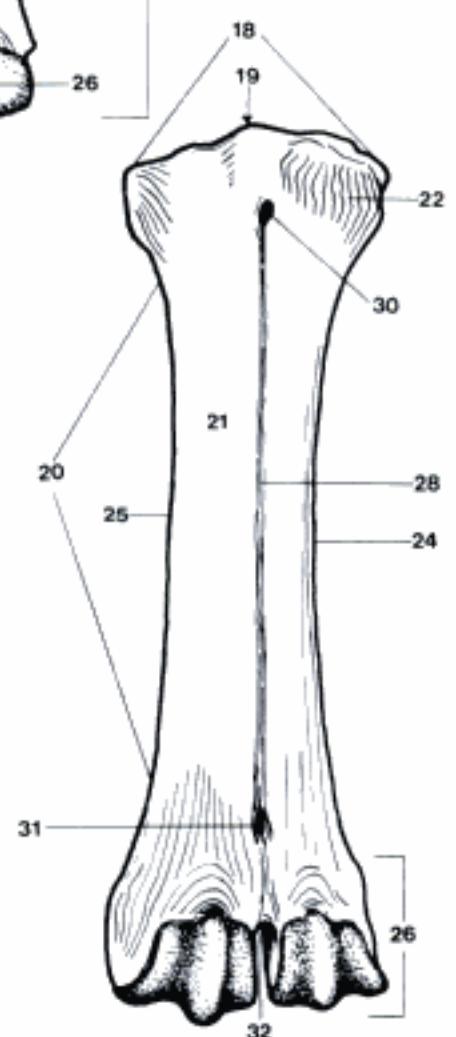
B Right carpal and metacarpal bones, dorsal aspect (ca)



C Right carpal bones, dorsal aspect (bo)

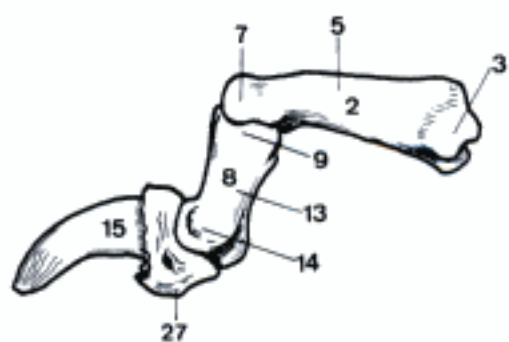


D Right metacarpal bones, palmar aspect (bo)

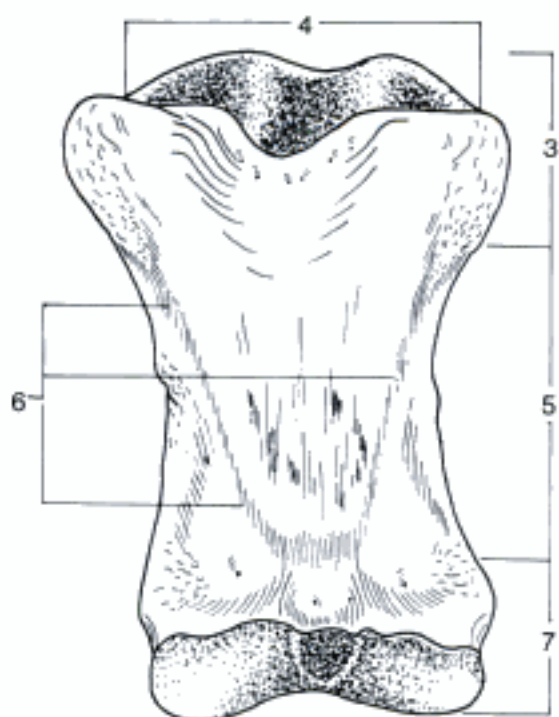


E Right metacarpal bones, dorsal aspect (bo)

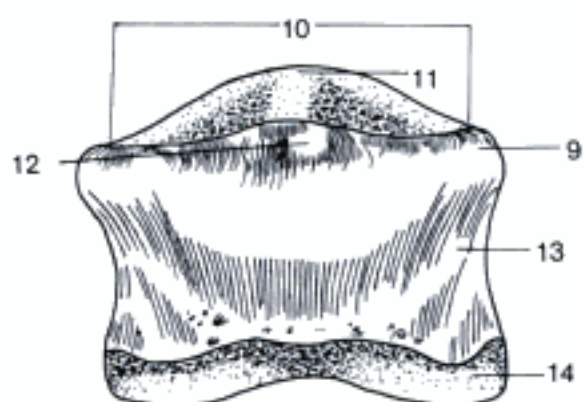
- 1 **Ossa digitorum manus.** Digital bones of the manus. A
- 2 *Phalanx proximalis [Os compedale].* Proximal phalanx. A B
- 3 *Basis phalangis proximalis.* Base of proximal phalanx, proximal end. A B
- 4 *Fovea articularis.* Articular fovea. B
- 5 *Corpus phalangis proximalis.* Body of proximal phalanx. A B
- 6 *Trigonum phalangis proximalis.* Triangular rough area on the palmar surface in eq. B
- 7 *Caput phalangis proximalis.* Head of proximal phalanx, distal end. A B
- 8 *Phalanx media [Os coronale].* Middle phalanx. A C
- 9 *Basis phalangis mediae.* Base of middle phalanx, proximal end. A C
- 10 *Fovea articularis.* Articular fovea. C
- 11 *Processus extensorius.* Extensor process in Ru and eq, dorsally. C
- 12 *Tuberositas flexoria.* Thickened palmar border for passage of flexor tendon in Ru and eq. C
- 13 *Corpus phalangis mediae.* Body of middle phalanx. A C
- 14 *Caput phalangis mediae.* Head of middle phalanx, distal end. A C
- 15 *Phalanx distalis [Os ungulare, Os unguiculare].* Distal phalanx. A D E
- 16 *Facies parietalis.* Parietal surface. D
- 17 *Sulcus parietalis medialis.* Medial parietal groove in eq. D
- 18 *Sulcus parietalis lateralis.* Lateral parietal groove in eq. D
- 19 *Processus palmaris medialis.* Medial palmar process in eq. D E
- 20 *Processus palmaris lateralis.* Lateral palmar process in eq. D E
- 21 *Foramen processus palmaris.* Variable foramen of palmar process. D
- 22 *Incisura processus palmaris.* Variable notch of palmar process. D
- 23 *Facies articularis.* Articular surface. D
- 24 *Facies articularis sesamoidea.* Part of articular surface articulating with *Os sesamoideum distale.* D
- 25 *Facies solearis.* Sole surface. E
- 26 *Facies flexoria.* Flexor surface for attachment of deep flexor tendon in su and eq. E
- 27 *Tuberculum flexorium.* Eminence, present in Ru and Car and faintly in su on which the deep flexor tendon ends. A 61 A
- 28 *Linea semilunaris.* Semilunar line in eq, separating *Facies flexoria* and *Planum cutaneum.* E
- 29 *Planum cutaneum.* Corresponds to the sole of the hoof in Un. E
- 30 *Sulcus solearis medialis.* Medial solar groove in eq. E
- 31 *Sulcus solearis lateralis.* Lateral solar groove in eq. E
- 32 *Foramen soleare mediale.* Medial solar foramen in eq. E
- 33 *Foramen soleare laterale.* Lateral solar foramen in eq. E
- 34 *Canalis solearis.* Solar canal within the *Phalanx distalis* in eq. E



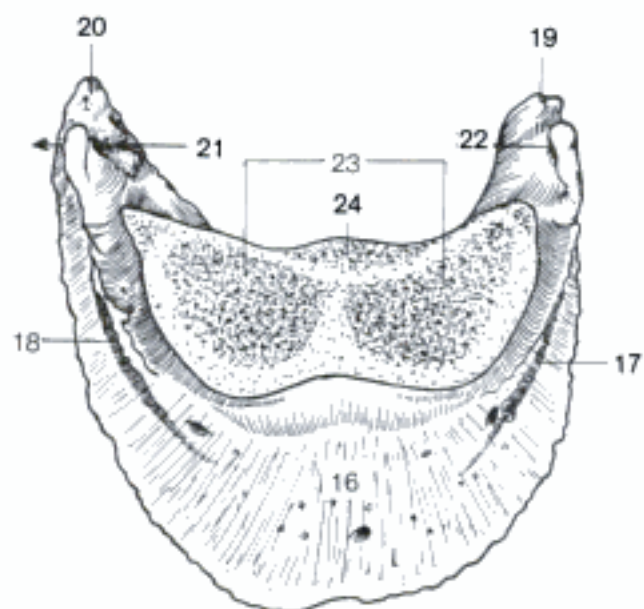
A Bones of the right fourth digit, axial aspect (ca)



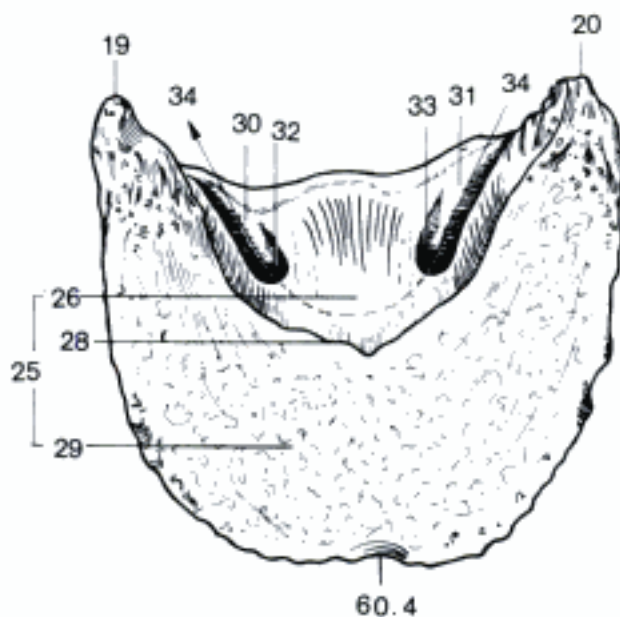
B Phalanx proximalis of right digit, palmar aspect (eq)



C Phalanx media of right digit, palmar aspect (eq)

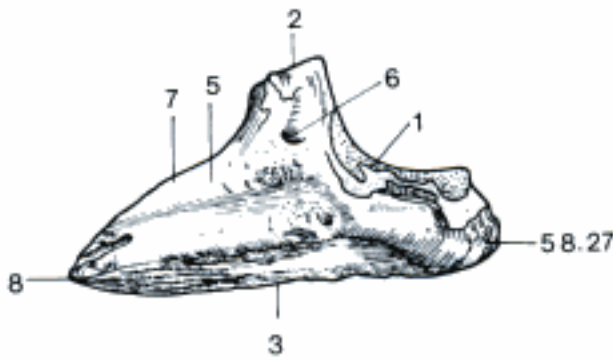


D Phalanx distalis of right digit, proximal aspect (eq)

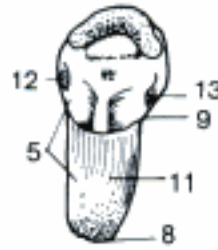


E Phalanx distalis of right digit, distal aspect (eq)

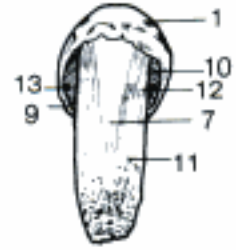- 1 *Margo coronalis*. Coronary (proximal) border. A C D
- 2 *Processus extensorius*. Extensor process, attachment of extensor tendon. A D
- 3 *Margo solearis*. Solar (distal) border. A D
- 4 (*Crena marginis solearis*). Shallow middorsal notch of *Margo solearis* in eq. 59 E
- 5 *Facies axialis*. Axial surface in Car, su and Ru. A B
- 6 *Foramen axiale*. Axial foramen in su and Ru. A
- 7 *Margo dorsalis*. Dorsal border, except in eq. A C
- 8 *Apex*. Distal end of *Margo dorsalis* in Car, su, and Ru. A B
- 9 *Crista unguicularis*. Ungual crest in Car, shelf at base covering the root of the claw. B C
- 10 *Sulcus unguicularis*. Ungual groove in Car, contains the root of the claw. C
- 11 *Processus unguicularis*. Ungual (distal) process in Car. B C
- 12 *Foramen soleare axiale*. Axial solar foramen in Car. B C
- 13 *Foramen soleare abaxiale*. Abaxial solar foramen in Car. B C
- 14 *Cartilago unguularis medialis*. Medial cartilage of hoof in eq. D
- 15 *Cartilago unguularis lateralis*. Lateral cartilage of hoof in eq. D
- 16 *Ossa sesamoidea proximalia*. Two proximal sesamoid bones, palmar to distal end of Os metacarpale. E
- 17 *Facies articularis*. Articular (dorsal) surface. E
- 18 *Facies flexoria*. Flexor (palmar) surface for the deep digital flexor tendon. E
- 19 *Facies m. interossei*. Axial, or abaxial (in eq medial, or lateral) surface for attachment of M. interosseus. E
- 20 *Os sesamoideum distale*. Distal sesamoid bone, palmar to the distal end of Phalanx media, in Car replaced by cartilage. F G
- 21 *Facies flexoria*. Flexor (palmar) surface for the deep digital flexor tendon. F
- 22 *Facies articularis*. Articular (dorsal and small distal) surface. G
- 23 *Margo proximalis*. Proximal border. F
- 24 *Margo distalis*. Distal border, attachment of ligament. G
- 25 *Ossa sesamoidea dorsalia*. Dorsal sesamoid bones in ca, sometimes replaced by cartilage. H



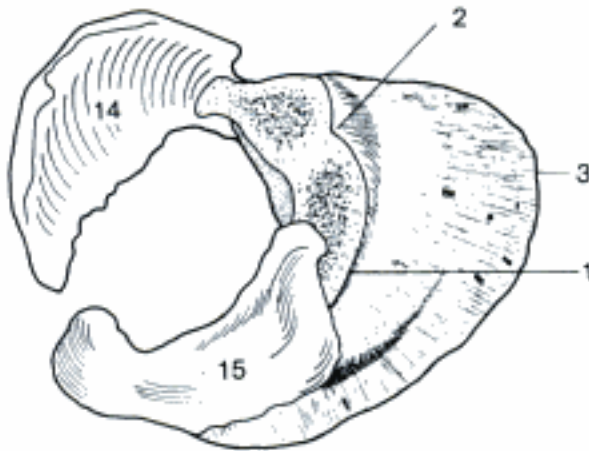
A Phalanx distalis of right fourth digit, axial aspect (bo)



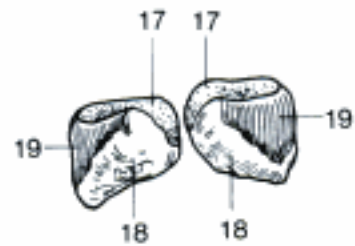
B Phalanx distalis of left third digit, proximal aspect (ca)



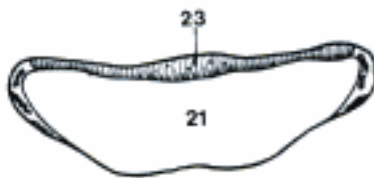C Phalanx distalis of left third digit, dorsodistal aspect (ca)



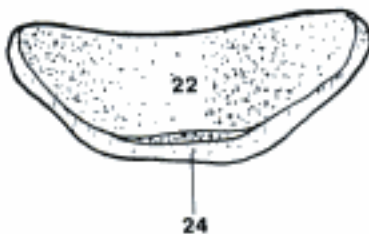D Phalanx distalis and hoof cartilages of right digit, proximolateral aspect (eq)



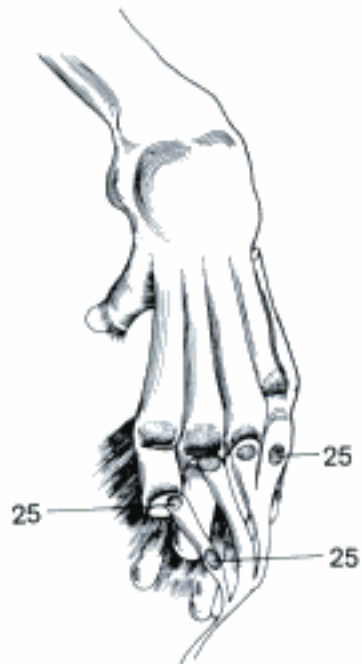
E Proximal sesamoid bones of right digit, proximal aspect (eq)



F Distal sesamoid bone of right digit, proximopalmar aspect (eq)



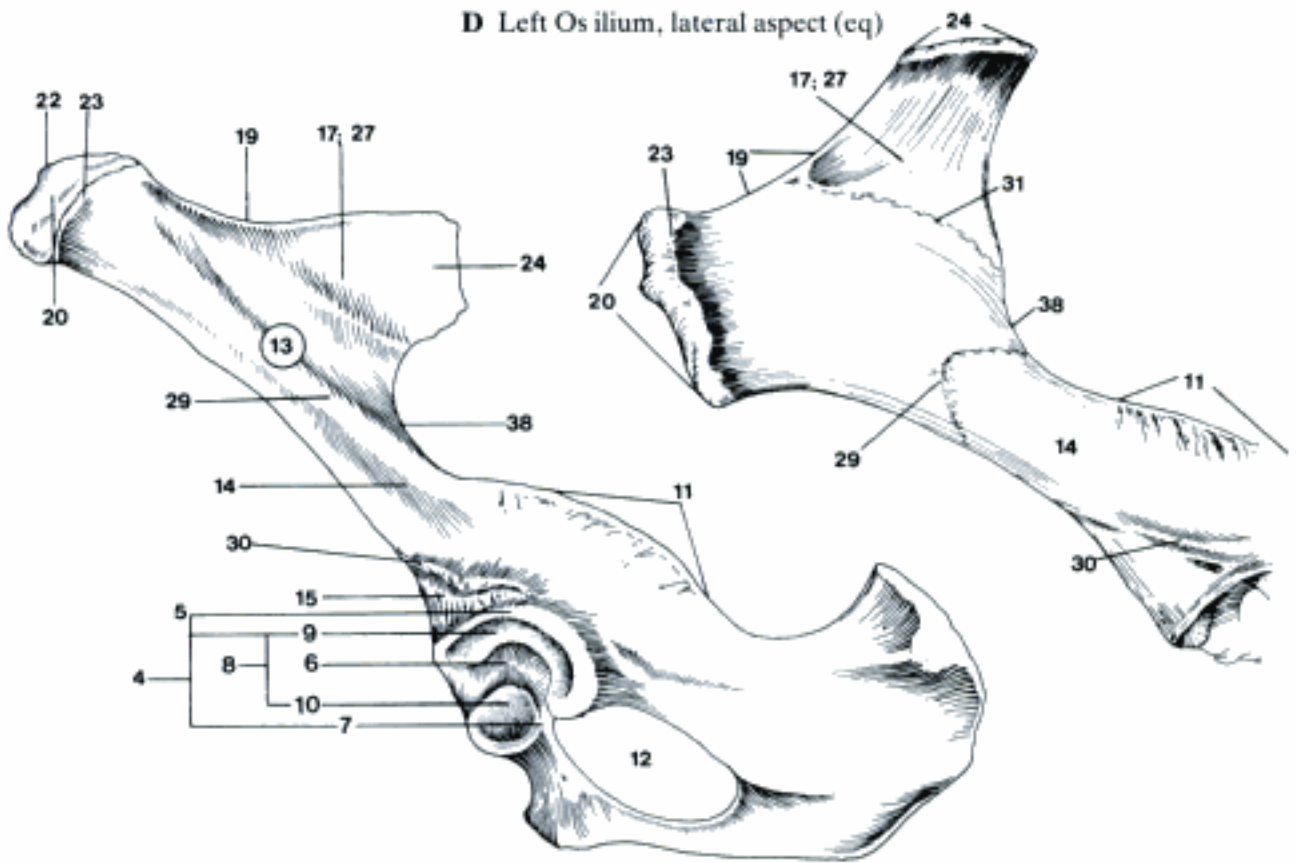
G Distal sesamoid bone of right digit, distodorsal aspect (eq)



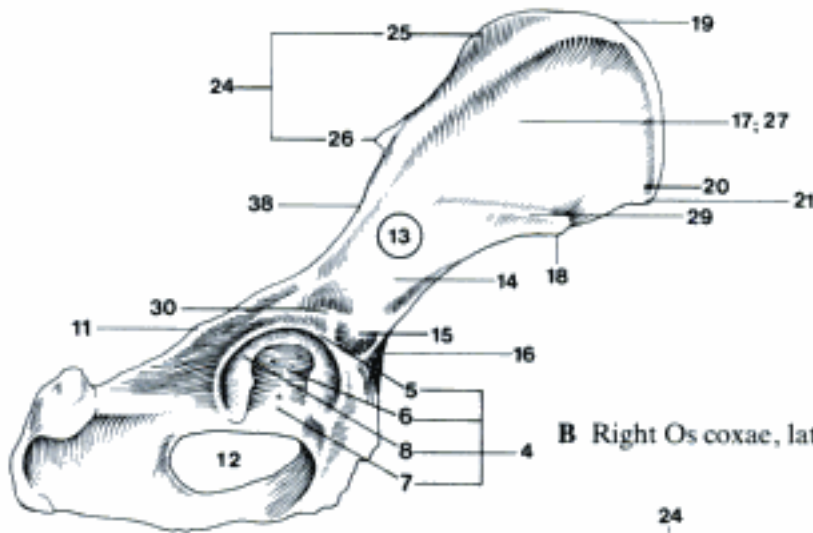
H Bones of the right manus, dorsal aspect (ca)

- 1 **OSSA MEMBRI PELVINI.** Bones of pelvic limb.
- 2 **Cingulum membri pelvini.** Pelvic girdle.
- 3 **Os coxae.** Hip bone, composed of ilium, ischium and pubis. A B C
- 4 **Acetabulum.** Socket of the hip joint. A B
- 5 **Margo acetabuli.** Acetabular rim. A
- 6 **Fossa acetabuli.** Deep part of the acetabulum for attachment of ligament. A B
- 7 **Incisura acetabuli.** Acetabular notch, interruption of *Facies lunata*, facing the *Foramen obturatum*. A B
- 8 **Facies lunata.** Moon-shaped articular surface. A B
- 9 **Pars major.** In Ru the *Facies lunata* consists of a major and minor part, separated by rough area. A
- 10 **Pars minor.** See 9 A
- 11 **Spina ischiadica.** Elevation between *Incisura ischiadica major* and *minor*, formed by ilium and ischium. A B C D
- 12 **Foramen obturatum.** Large opening bounded by pubis and ischium. A B C
- 13 **Os ilium.** A B C
- 14 **Corpus ossis ilii.** Body of ilium, constricted caudoventral part. A B C D
- 15 **Area lateralis m. recti femoris.** A B
- 16 **Area medialis m. recti femoris [Spina iliaca ventralis caudalis].** B C
- 17 **Ala ossis ilii.** Wing of ilium, wide craniodorsal part. A B C D
- 18 **Spina alaris.** Prominence at the ventral border of the wing in Car, ov, and cap. B C
- 19 **Crista iliaca.** Iliac crest, dorsocranial border of ilium. A B C D
- 20 **Tuber coxae.** Coxal tuber, lateroventral projection of the wing. A B C D
- 21 **Spina iliaca ventralis cranialis.** Cranioventral angle of *Tuber coxae* in Car, ov, and cap. B C
- 22 **Labium internum.** Internal lip in Ru and eq, border of the area of origin of *M. iliacus*. A
- 23 **Labium externum.** External lip in Ru and eq, border of the area of origin of *M. gluteus medius*. A D
- 24 **Tuber sacrale.** Sacral tuber, dorso-medial projection of the wing. A B C D
- 25 **Spina iliaca dorsalis cranialis.** Prominence at the cranial end of *Tuber sacrale* in Car, ov, and cap. B C
- 26 **Spina iliaca dorsalis caudalis.** Prominence at the caudal end of *Tuber sacrale* in Car, ov, and cap. B C
- 27 **Facies glutea [glutaea].** External surface of the wing. A B D
- 28 **Linea gluteae [glutaeae].** Lines at the borders of fields of origin of *Mm. glutei*.
- 29 **Linea glutea [glutaea] ventralis.** Line between the fields of *M. gluteus medius* and *profundus* in Car, bo and eq. A B D
- 30 **Linea glutea [glutaea] caudalis.** Border of the field of *M. gluteus profundus*. A B
- 31 **Linea glutea [glutaea] accessoria (eq).** Line between the fields of *M. gluteus medius* and *accessorius*. D
- 32 **Facies sacropelvina.** Internal surface of the wing. C
- 33 **Facies iliaca.** Iliac surface, craniolateral part of *Facies sacropelvina*. C
- 34 **Facies auricularis.** Ear-shaped surface for articulation with the sacrum. C
- 35 **Tuberositas iliaca.** Roughened area craniodorsal to the *Facies auricularis* for attachment of ligament. C
- 36 **Linea arcuata.** Ventromedial border of *Corpus ossis ilii*, part of *Linea terminalis*. C
- 37 **Tuberculum m. psoas minoris.** Absent in ca. 65 E
- 38 **Incisura ischiadica major.** Greater sciatic notch between *Tuber sacrale* and *Spina ischiadica*. A B D

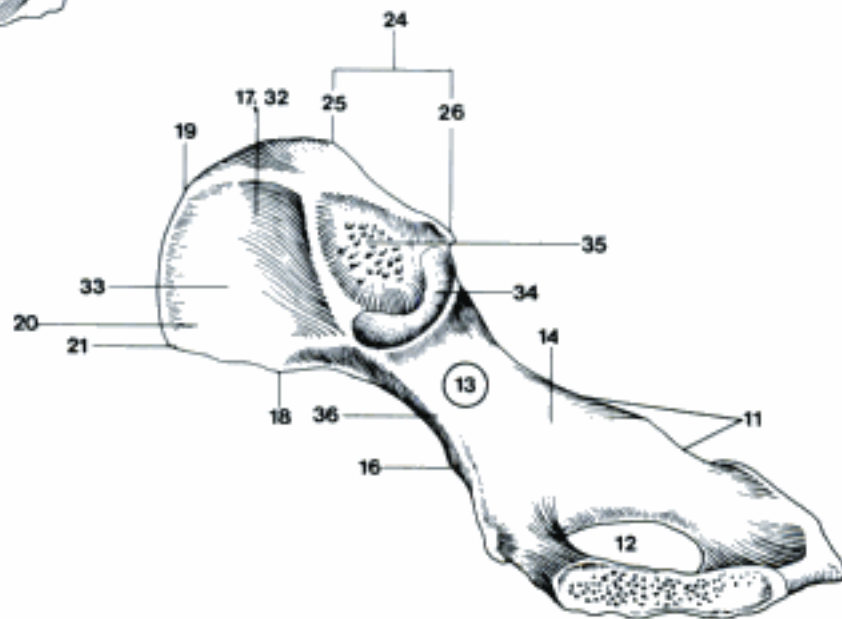
D Left Os ilium, lateral aspect (eq)



A Left Os coxae, lateral (and ventral) aspect (bo)

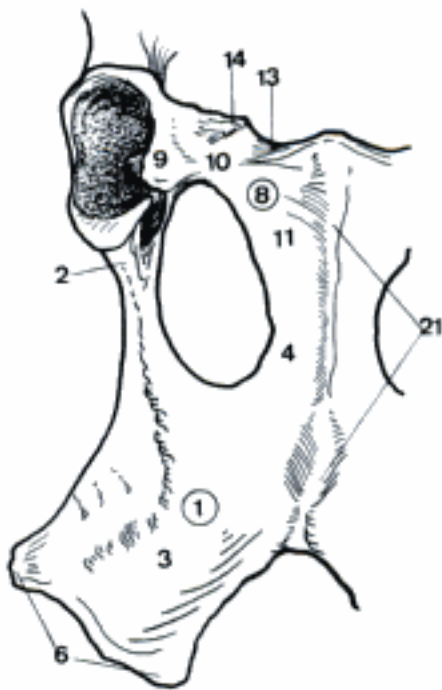


B Right Os coxae, lateral (and ventral) aspect (ca)

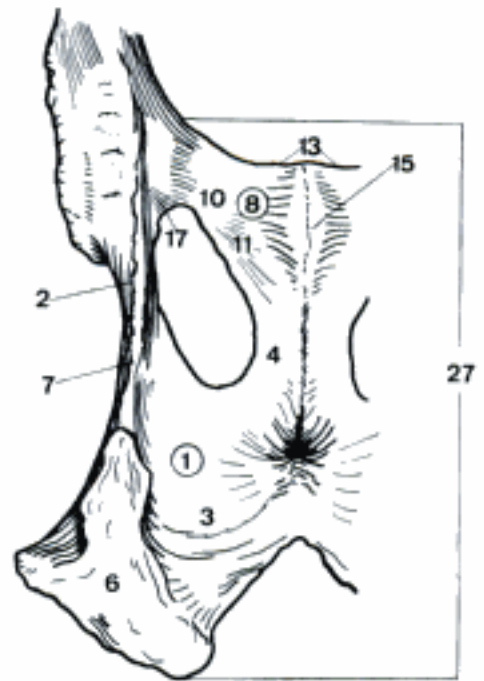


C Right Os coxae, medial (and dorsal) aspect (ca)

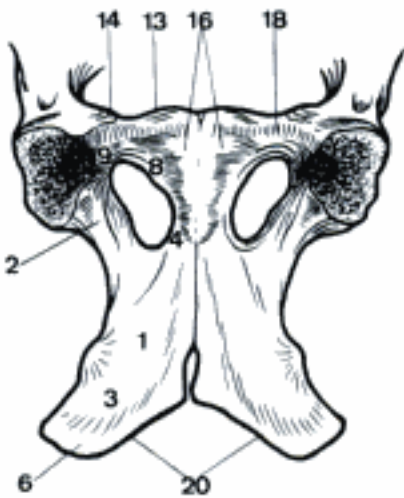
- 1 **Os ischii.** Ischial bone. A B C E
- 2 *Corpus ossis ischii.* Body of ischium, lateral to Foramen obturatum. A B C E
- 3 *Tabula ossis ischii.* Tabula of ischium, caudal to Foramen obturatum. A B C E
- 4 *Ramus ossis ischii.* Brach of ischium, medial to Foramen obturatum, fused cranially with Ramus caudalis ossis pubis. A B C E
- 5 *Facies symphysialis.* Surface facing the Symphysis pelvina. E
- 6 *Tuber ischiadicum.* Ischial tuber, caudolateral extremity of the ischium. A B C E
- 7 *Incisura ischiadica minor.* Lesser ischiadic notch, between Spina ischiadica and Tuber ischiadicum. B E
- 8 **Os pubis.** Pubic bone. A B C E
- 9 *Corpus ossis pubis.* Body of pubis. A C
- 10 *Ramus cranialis ossis pubis.* Cranial branch of pubis, cranial to Foramen obturatum. A B
- 11 *Ramus caudalis ossis pubis.* Caudal branch of pubis, medial to Foramen obturatum, fuses caudally with Ramus ossis ischii. A B
- 12 *Facies symphysialis.* Surface facing the Symphysis pelvina. E
- 13 *Pecten ossis pubis.* Sharp cranial border of Ramus cranialis ossis pubis. A B C
- 14 *Eminentia iliopubica.* Eminence at the lateral end of Pecten ossis pubis. A C E
- 15 *Tuberculum pubicum dorsale.* Dorsal median tubercle in the male, esp. eq. B
- 16 *Tuberculum pubicum ventrale.* Ventral paramedian tubercle. C
- 17 *Sulcus obturatorius.* Groove on the pelvic floor craniolateral to the Foramen obturatum. B
- 18 *Sulcus ligamenti accessorii ossis femoris* (eq). Groove for the accessory ligament on the ventral surface of Ramus cranialis ossis pubis. C
- 19 **Pelvis.** Composed of Os sacrum and right and left Os coxae. D E
- 20 *Arcus ischiadicus.* Ischial arch, formed by the caudal borders of right and left Tabula ossis ischii between right and left Tuber ischiadicum. C
- 21 *Crista symphysialis.* Median crest on the ventral surface of Symphysis pelvina in bo. A
- 22 *Cavum pelvis.* Pelvic cavity, between Apertura pelvis cranialis and caudalis. D
- 23 *Linea terminalis.* Circular line from the Promontorium, across Ala ossis sacri, along Linea arcuata and Pecten ossis pubis. D
- 24 *Apertura pelvis cranialis.* Cranial pelvic aperture, bordered by the Linea terminalis. D
- 25 *Apertura pelvis caudalis.* Caudal pelvic aperture, bordered by Os sacrum, Lig. sacrotuberale, and Arcus ischiadicus. E
- 26 *Axis pelvis.* Center of all median diameters between pelvic surface of the sacrum and the symphysis. E
- 27 *Solum pelvis osseum.* Floor of the pelvic cavity, formed by the Ossa pubis and Ossa ischii. B C
- 28 *Diameter conjugata.* Line from the Promontorium to the cranial end of the symphysis. E
- 29 *Diameter transversa.* Greatest transverse diameter of Apertura pelvis cranialis. D
- 30 *Diameter verticalis.* Line from the cranial end of the symphysis to the pelvic surface of sacrum or a caudal vertebra, perpendicular to the Solum pelvis osseum. E
- 31 *Inclinatio pelvis.* Angle between Diameter conjugata and Diameter verticalis. E



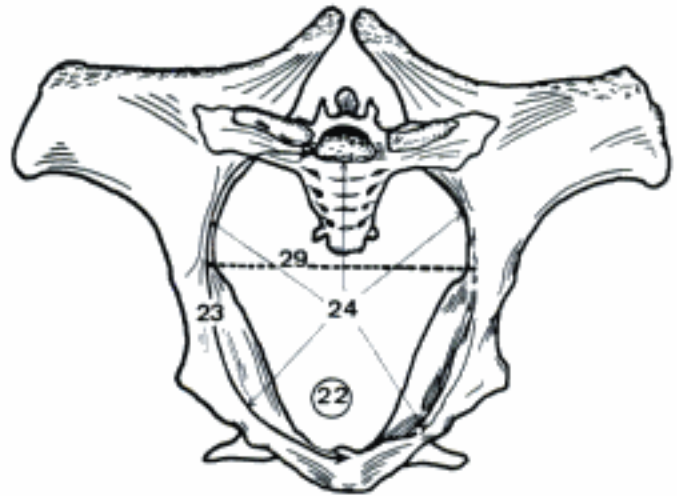
A Right Os ischii and Os pubis, ventral aspect (bo masc)



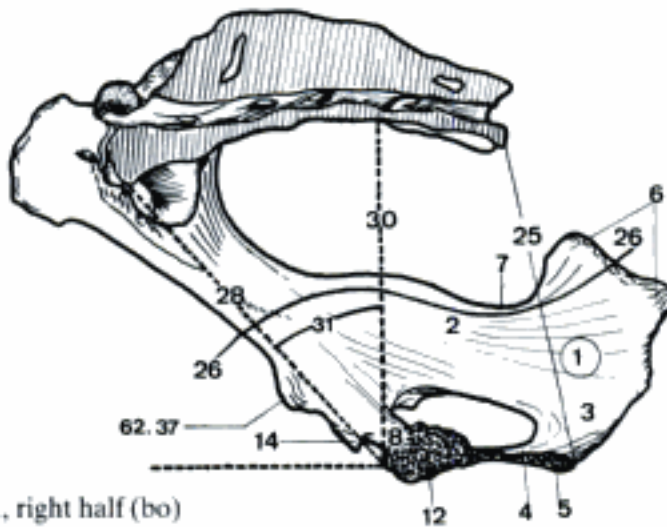
B Left Os ischii and Os pubis, dorsal aspect (eq)



C Solum pelvis osseum, ventral aspect (eq)



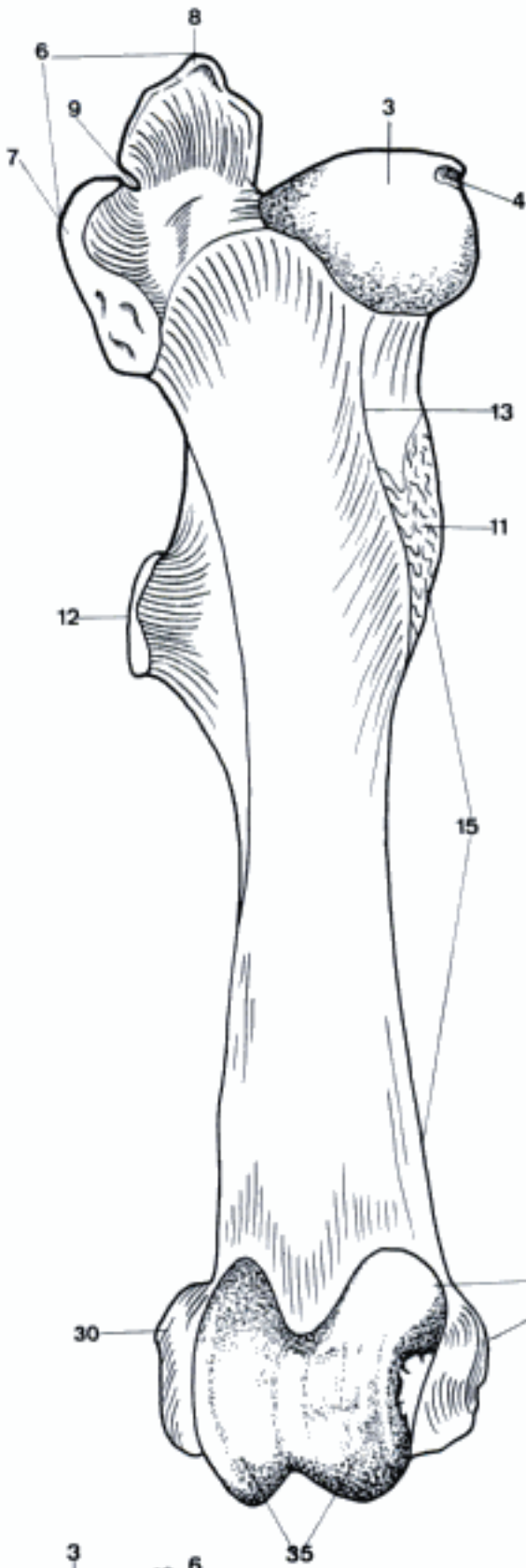
D Pelvis, cranial aspect (eq)



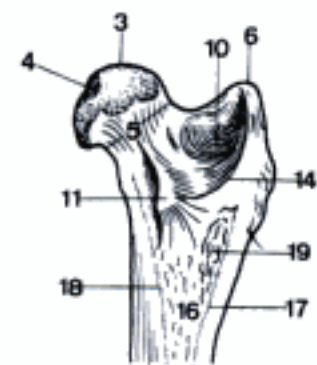
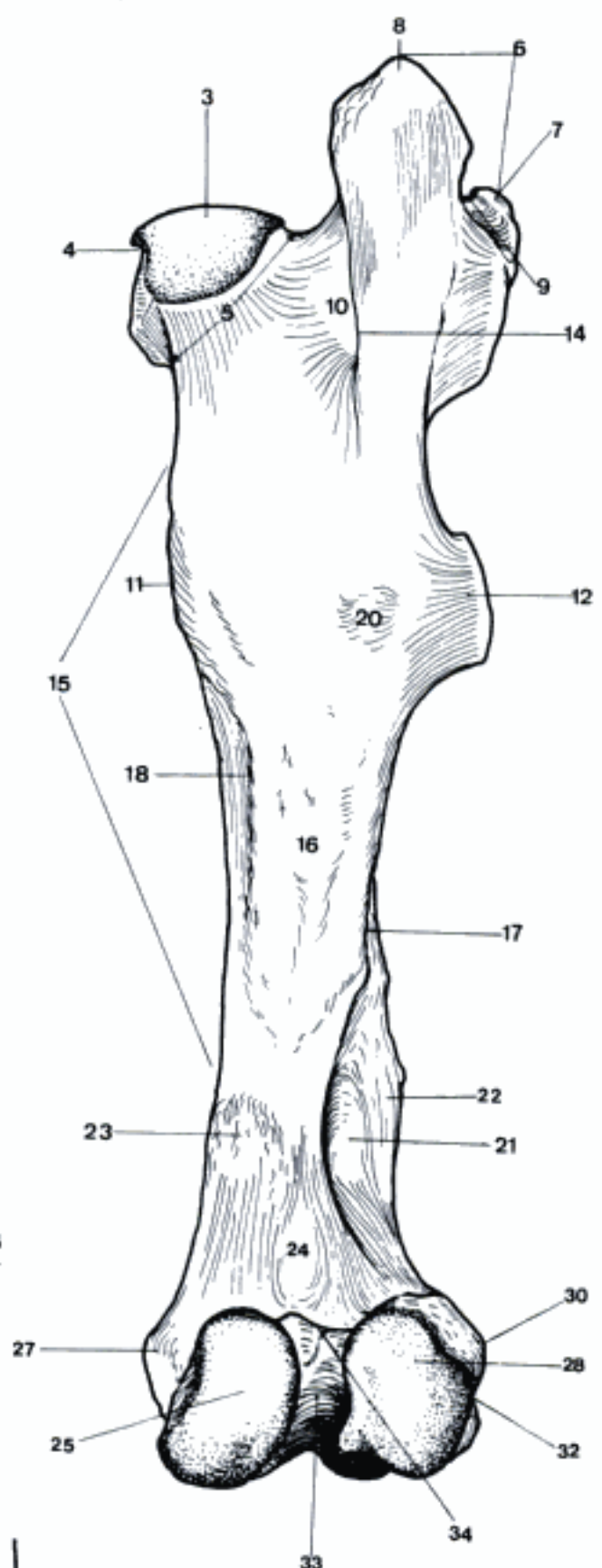
E Pelvis, median section, right half (bo)

- 1 **Skeleton femoris.** Skeleton of the thigh.
- 2 **Os femoris [Femur].** A B
- 3 *Caput ossis femoris.* Head of femur. A B C
- 4 *Fovea capitis.* Fovea of head, attachment of ligament. A B C
- 5 *Collum ossis femoris.* Neck of femur, between Caput and Corpus. B C
- 6 *Trochanter major.* Greater trochanter, proximolateral extremity, attachment of Mm. glutei medius and profundus. A B C
- 7 *Pars cranialis.* Cranial part, eq. A B
- 8 *Pars caudalis.* Caudal part, eq. A B
- 9 *Incisura trochanterica.* Notch between cranial and caudal parts in eq. A B
- 10 *Fossa trochanterica.* Deep notch at the caudal surface, medial to the root of Trochanter major. B C
- 11 *Trochanter minor.* Lesser trochanter, medial eminence for attachment of M. iliopsoas. A B C
- 12 *Trochanter tertius.* Third trochanter in eq, lateral protuberance for attachment of M. gluteus superficialis. A B
- 13 *Linea intertrochanterica.* Line on the cranial surface, running from Trochanter minor to Caput, absent in su. A
- 14 *Crista intertrochanterica.* Crest on the caudal surface, continuation of the medial border of Trochanter major. B C
- 15 *Corpus ossis femoris.* Body of femur. A B
- 16 *Facies aspera.* Rough caudal surface for attachment of adductor muscles. B C
- 17 *Labium laterale.* Lateral lip, lateral border of Facies aspera. B C
- 18 *Labium mediale.* Medial lip, medial border of Facies aspera. B C
- 19 *Tuberositas glutea [glutaea].* Rough area at the proximal end of Labium laterale in Car, attachment of M. gluteus superficialis. C
- 20 *Tuberositas m. bicipitis.* Origin of biceps in eq. B
- 21 *Fossa supracondylaris.* Depression proximal to Condylus lateralis, deep in eq. shallow in Ru and su, attachment of M. flexor digit. supf. B
- 22 *Tuberositas supracondylaris lateralis.* Rough area proximal to Condylus lateralis, in Un lateral to Fossa supracondylaris, attachment of Caput lat. m. gastrocnemii. E
- 23 *Tuberositas supracondylaris medialis.* Rough area proximal to Condylus medialis, attachment of Caput lat. m. gastrocnemii. B E
- 24 *Facies poplitea.* Popliteal surface, smooth part of the caudal surface, proximal to the condyles. B E
- 25 *Condylus medialis.* Medial condyle for articulation with the tibia. B E
- 26 *Facies articularis sesamoidea medialis.* Facet for the medial sesamoid bone in Car. E
- 27 *Epicondylus medialis.* Medial elevation on Condylus medialis. A B D E
- 28 *Condylus lateralis.* Lateral condyle for articulation with the tibia. B E
- 29 *Facies articularis sesamoidea lateralis.* Facet for lateral sesamoid bone in Car. E
- 30 *Epicondylus lateralis.* Lateral elevation on Condylus lateralis. A B D
- 31 *Fossa extensoria.* Small depression between Condylus lat. and Trochlea, attachment of M. extensor digit. longus. D
- 32 *Fossa m. poplitei.* Depression lateral on Condylus lat. B D
- 33 *Fossa intercondylaris.* Notch between the condyles. B E
- 34 *Linea intercondylaris.* Ridge at the proximal end of Fossa intercondylaris. B E
- 35 *Trochlea ossis femoris.* For articulation of patella. A D
- 36 *Tuberculum trochleae ossis femoris.* Medial eminence on the proximal end of the medial ridge of the trochlea in eq. A

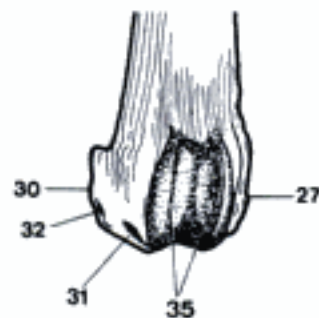
A Right femur, cranial aspect (eq)



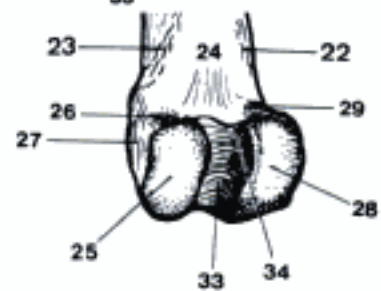
B Right femur, caudal aspect (eq)



C Proximal part of right femur, mediocaudal aspect (ca)

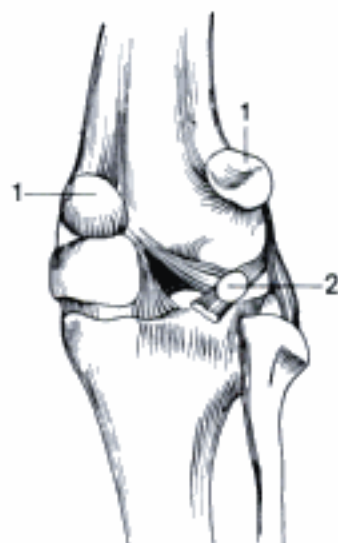
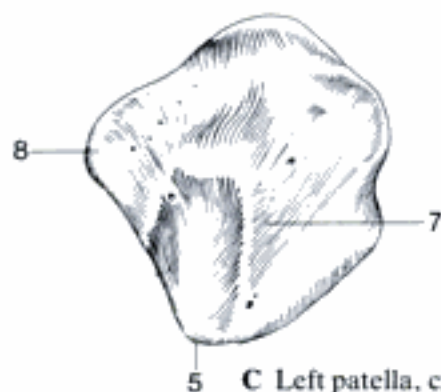
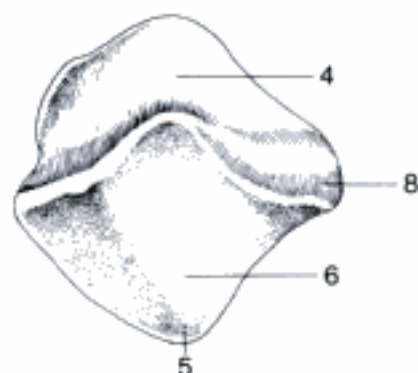
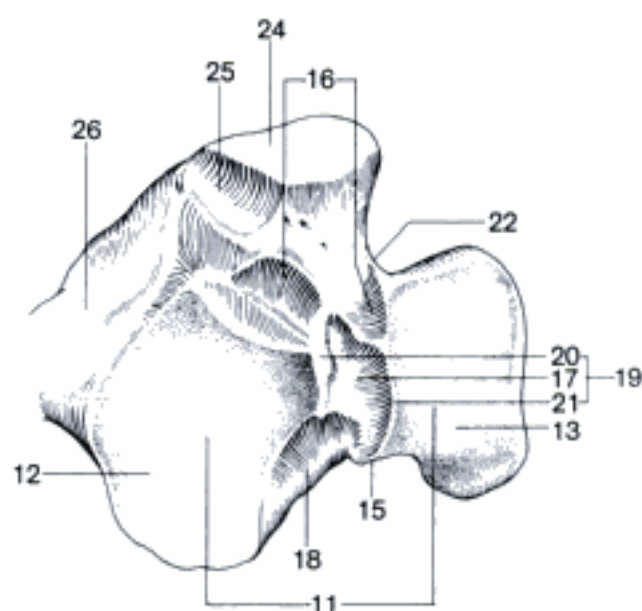
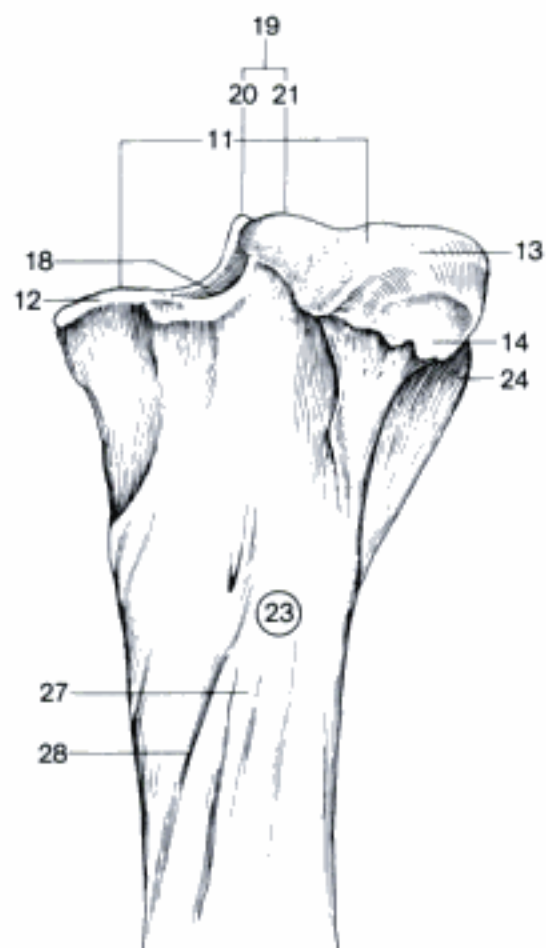


D Distal part of right femur, cranial (and lateral) aspect (ca)

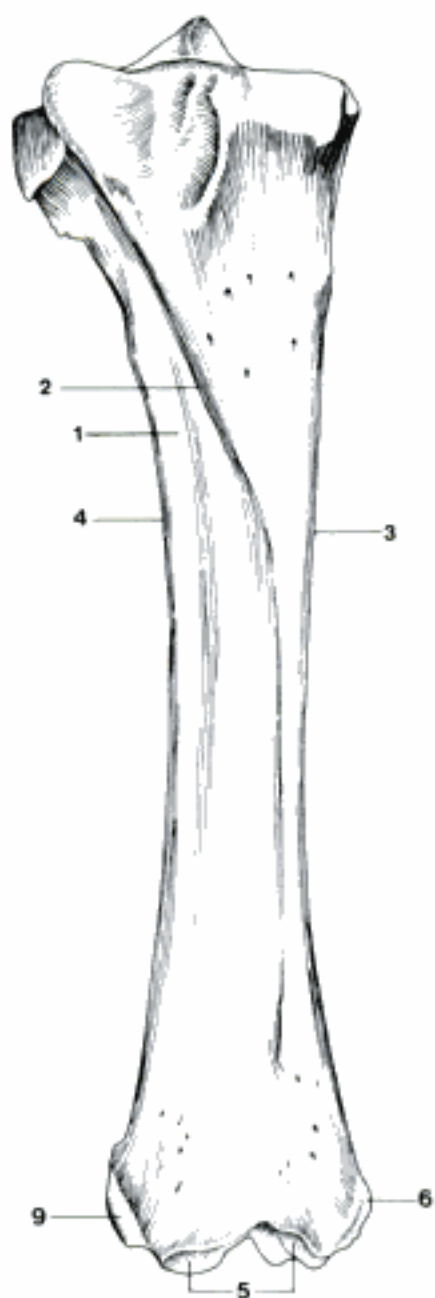


E Distal part of right femur, caudal (and medial) aspect (ca)

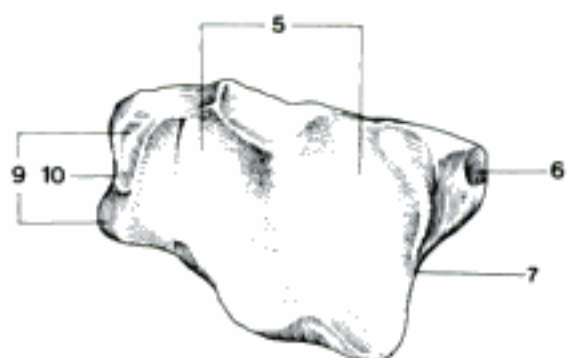
- 1 *Ossa sesamoidea m. gastrocnemii*. Two sesamoid bones in the heads of *M. gastrocnemius* in Car. A
- 2 *Ossa sesamoidea m. poplitei*. Sesamoid bone in the tendon of *M. popliteus* in Car. A
- 3 **Patella**. Knee cap. B C
- 4 *Basis patellae*. Base of the patella, somewhat wider proximal part. B
- 5 *Apex patellae*. Distal tip of the patella. B C
- 6 *Facies articularis*. Articular surface, facing the femur. B
- 7 *Facies cranialis*. Cranial surface. C
- 8 *Processus cartilagineus*. Medial process in bo and eq, partly cartilaginous. B C
- 9 **Skeleton cruris**. Skeleton of the crus.
- 10 **Tibia**. D E
- 11 *Facies articularis proximalis*. Proximal articular surface. D E
- 12 *Condylus medialis*. Medial condyle for articulation with the femur. D E
- 13 *Condylus lateralis*. Lateral condyle for articulation with the femur. D E
- 14 *Facies articularis fibularis*. Surface for articulation with *Caput fibulae*, except Ru. E
- 15 *Incisura poplitea*. Popliteal (caudal) notch on the proximal extremity of the tibia. D
- 16 *Area intercondylaris cranialis*. Two rough areas cranial to *Eminentia intercondylaris* for attachment of menisci. D
- 17 *Area intercondylaris centralis*. Rough depression in the center of the *Eminentia intercondylaris* for attachment of *Lig. cruciatum craniale*. D
- 18 *Area intercondylaris caudalis*. Rough area caudal to *Eminentia intercondylaris* for attachment of *Lig. cruciatum caudale*. D E
- 19 *Eminentia intercondylaris*. Proximal eminence between the two condyles. D E
- 20 *Tuberculum intercondylare mediale*. Medial tubercle of the *Eminentia intercondylaris*. D E
- 21 *Tuberculum intercondylare laterale*. Lateral tubercle of the *Eminentia intercondylaris*. D E
- 22 *Sulcus extensorius*. Craniolateral notch on the proximal extremity of tibia for *M. extensor digit. longus*. D
- 23 *Corpus tibiae*. Body of tibia. E
- 24 *Tuberositas tibiae*. Cranial elevation on the proximal extremity for attachment of *Lig. patellae*. D E
- 25 *Sulcus tuberositatis tibiae*. Groove on the *Tuberositas tibiae* in su and eq. D
- 26 *Facies medialis*. Craniomedial surface. D
- 27 *Facies caudalis*. Caudal surface. E
- 28 *Linea m. poplitei*. Border of the field of attachment of *M. popliteus*, running mediolaterally. E

A Right stifle joint, caudal aspect (ca)**B** Left patella, caudal aspect (eq)**C** Left patella, cranial aspect (eq)**D** Right tibia, proximal (and medial) aspect (eq)**E** Part of right tibia, caudolateral aspect (eq)

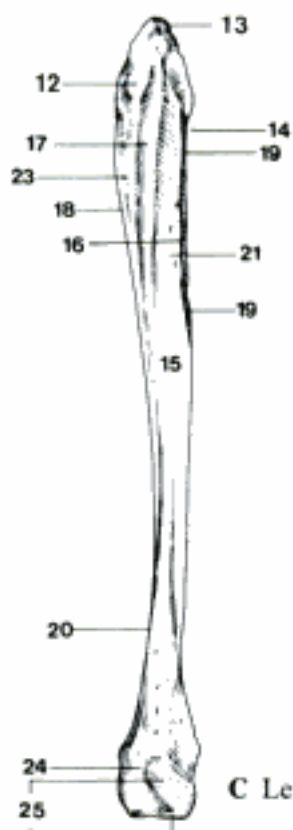
- 1 *Facies lateralis*. Craniolateral surface. A
- 2 *Margo cranialis*. Cranial border, formerly *Crista tibiae*. A
- 3 *Margo medialis*. Medial border. A
- 4 *Margo lateralis* [*Margo interosseus*]). Lateral border facing fibula in Car, su and partly eq, attachment of *Membrana interossea*. A
- 5 *Cochlea tibiae*. Distal articular surface, facing the talus. A B D
- 6 *Malleolus medialis*. A B D
- 7 *Sulcus malleolaris*. Flat groove in the caudal part of *Malleolus medialis* for the tendon of *M. flexor digit. med.* (and *M. tibialis caud.* in Car). B D
- 8 *Incisura fibularis*. Fibular notch on lateral surface of distal extremity in Car, su, and Ru, facet for fibula. D
- 9 *Malleolus lateralis*. Only in eq part of tibia. A B
- 10 *Sulcus malleolaris*. Flat groove in eq, for the tendon of *M. extensor digit. lat.* B
- 11 **Fibula**. C D
- 12 *Caput fibulae*. Head of fibula, proximal extremity, rudimentary and fused with tibia in Ru. C
- 13 *Facies articularis capitis fibulae*. Articular surface of fibular head in Car, su, and eq. C
- 14 *Collum fibulae*. Neck of fibula. C
- 15 *Corpus fibulae*. Body of fibula, usually absent in Ru, rudimentary in eq. C D
- 16 *Margo interosseus*. Interosseous border on the medial surface in su, fused with *Margo cranialis* in Car, attachment of *Membrana interossea*. C
- 17 *Margo medialis*. Present in su and in the proximal half of the fibula in Car. C
- 18 *Margo lateralis*. Present in su and on the proximal half of the fibula in Car. C
- 19 *Margo cranialis*. Present in Car, su, and eq. C D
- 20 *Margo caudalis*. Present on the distal part of the fibula in su and Car. D
- 21 *Facies medialis*. Medial surface, faces the tibia. C
- 22 *Facies lateralis*. Lateral surface. D
- 23 *Facies caudalis*. Caudal surface in the proximal half of the fibula of Car, narrow in su, between *Margo medialis* and *lateralis*. C
- 24 *Malleolus lateralis*. Distal extremity of the fibula in Car and su, separate bone in Ru, part of tibia in eq. C D E
- 25 *Facies articulares malleoli*. Articular surfaces for tibia, talus, and calcaneus. C D E
- 26 *Sulcus malleolaris*. Groove on the lateral surface in su and Ru for the tendon of *M. extensor digit. lat.* and *M. peron. longus*.
- 27 *Sulcus tendinis m. peron. [fibularis] longi*. Groove on the lateral surface in Car for the tendon of *M. peron. longus*. D
- 28 *Sulcus tendinum mm. extensoris dig. lat. et peron. [fibularis] brevis*. Groove on the caudal side for tendons of *M. extensor dig. lat.* and *M. peron. brevis* in Car. D



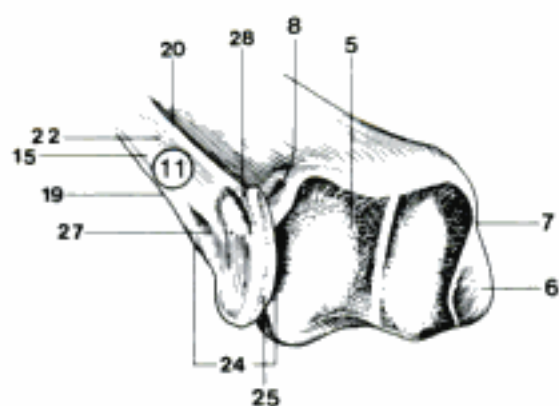
A Right tibia, cranial aspect (eq)



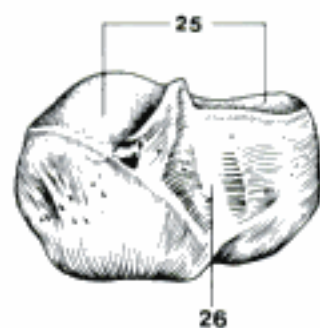
B Right tibia, distal aspect (eq)



C Left fibula, caudomedial aspect (su)

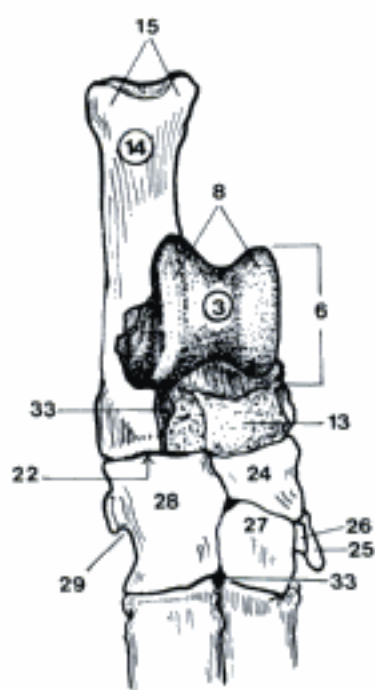


D Left tibia and fibula, distocaudolateral aspect (ca)

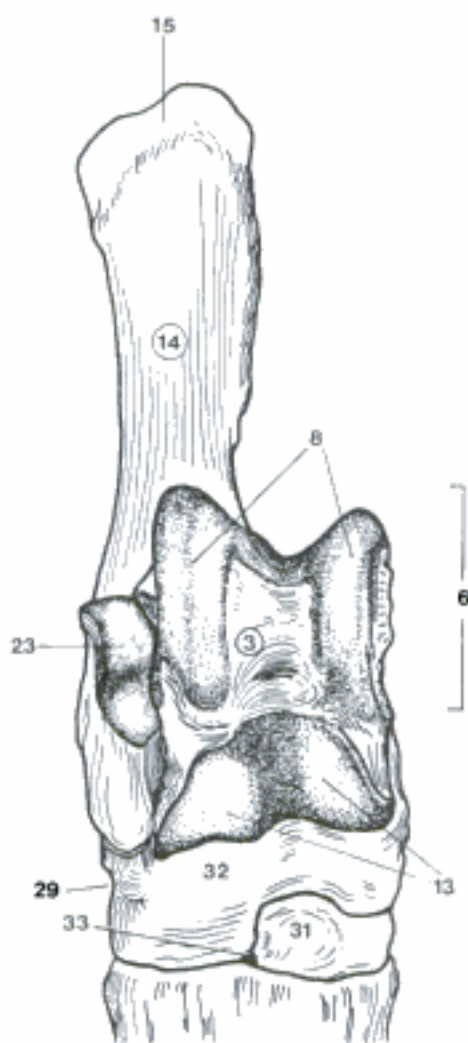


E Right Malleolus lateralis, lateral aspect (bo)

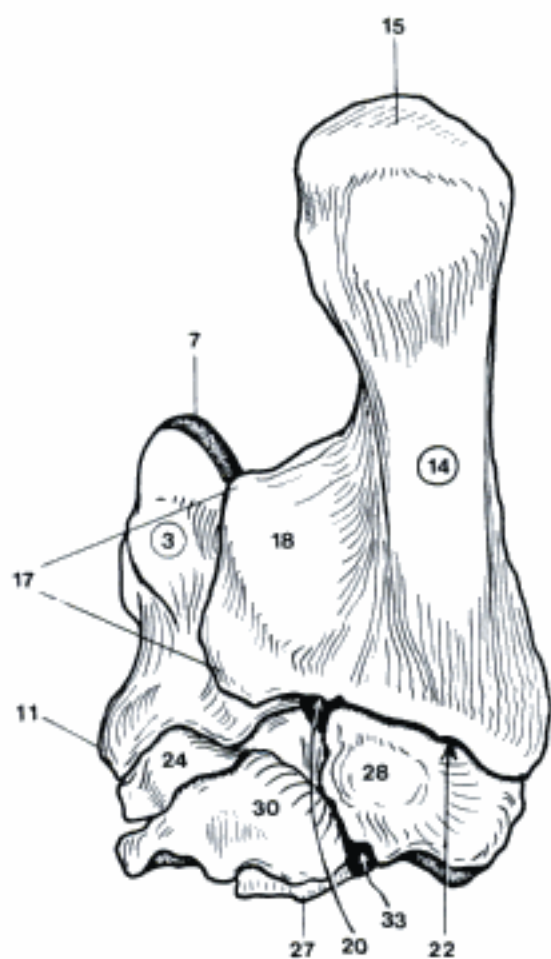
- 1 **Skeleton pedis.** Skeleton of the pes.
- 2 **Ossa tarsi.** Tarsal bones. A B C
- 3 *Talus.* A B C D
- 4 *Caput tali.* Head of talus in Car, articulates with Os tarsi centrale. D
- 5 *Collum tali.* Neck of talus, distinct in Car, absent in eq. D
- 6 *Corpus tali.* Body of talus. A B D
- 7 *Trochlea tali.* Proximal part for articulation with the tibia in eq, tibia and fibula in Car. C D
- 8 *Trochlea tali proximalis.* Proximal part for articulation with tibia and fibula in su and Ru. A B
- 9 *Facies articulares calcaneae.* Articular surfaces for calcaneus, located plantarly. D
- 10 *Sulcus tali.* Proximodistally running groove between plantar articular surfaces in Car and eq. D
- 11 *Tuberculum tali.* Medial tubercle in eq for ligament attachment. C
- 12 *Facies articularis navicularis.* Distal articular surface for Os tarsi centrale in Car and eq. D
- 13 *Trochlea tali distalis.* Distal part for articulation with Os tarsi centrale and tarsale IV in su and Ru. A B
- 14 *Calcaneus.* A B C E
- 15 *Tuber calcanei.* Point of the hock. A B C E
- 16 *Processus coracoideus.* Dorsal process at the root of Tuber calcanei. E
- 17 *Sustentaculum tali.* Medial projection with an articular surface for the talus. C E
- 18 *Sulcus tendinis m. flex. digit. lateralis.* Groove for tendon on the plantar surface of the Sustentaculum tali. C
- 19 *Sulcus calcanei.* Proximodistally running groove between the dorsal articular surfaces in Car and eq. E
- 20 *Sinus tarsi.* Space between talus and calcaneus. C D E
- 21 *Facies articulares talaris.* Articular surfaces for talus, located dorsally. E
- 22 *Facies articularis cuboidea.* Distal articular surface for Os tarsale IV. A C E
- 23 *Facies articularis malleolaris.* Articular surface for Malleolus lateralis. B
- 24 *Os tarsi centrale [Os naviculare].* Central tarsal [navicular] bone. A C
- 25 *Os tarsale I [Os cuneiforme mediale].* First tarsal [medial cuneiform] bone. A C
- 26 *Os tarsale II [Os cuneiforme intermedium].* Second tarsal [intermediate cuneiform] bone. A
- 27 *Os tarsale III [Os cuneiforme laterale].* Third tarsal [lateral cuneiform] bone. A
- 28 *Os tarsale IV [Os cuboideum].* Fourth tarsal [cuboid] bone. A C
- 29 *Sulcus tendinis m. peron. [fibularis] longi.* Lateropalmar groove for tendon. A B
- 30 *Os tarsale I et II [Os cuneiforme mediointermedium].* Fused first and second tarsal bones in eq. C
- 31 *Os tarsale II et III [Os cuneiforme intermediolaterale].* Fused second and third tarsal bones in Ru. B
- 32 *Os centroquartale [Os naviculocuboideum].* Fused central and fourth tarsal bones in Ru. B
- 33 *Canalis tarsi.* Vascular canal for the perforating tarsal vessels in Un between third and fourth tarsal bones, in su additional canal between talus and calcaneus. A C



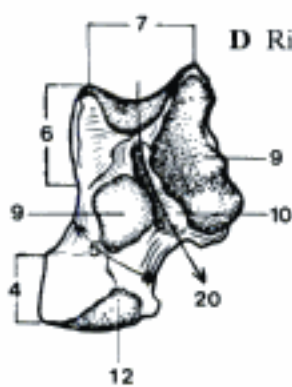
A Right tarsal bones, dorsal aspect (su)



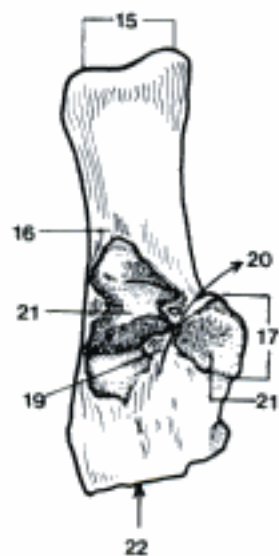
B Right tarsal bones, dorsal aspect (bo)



C Right tarsal bones, plantar aspect (eq)




D Right talus, plantar aspect (ca)



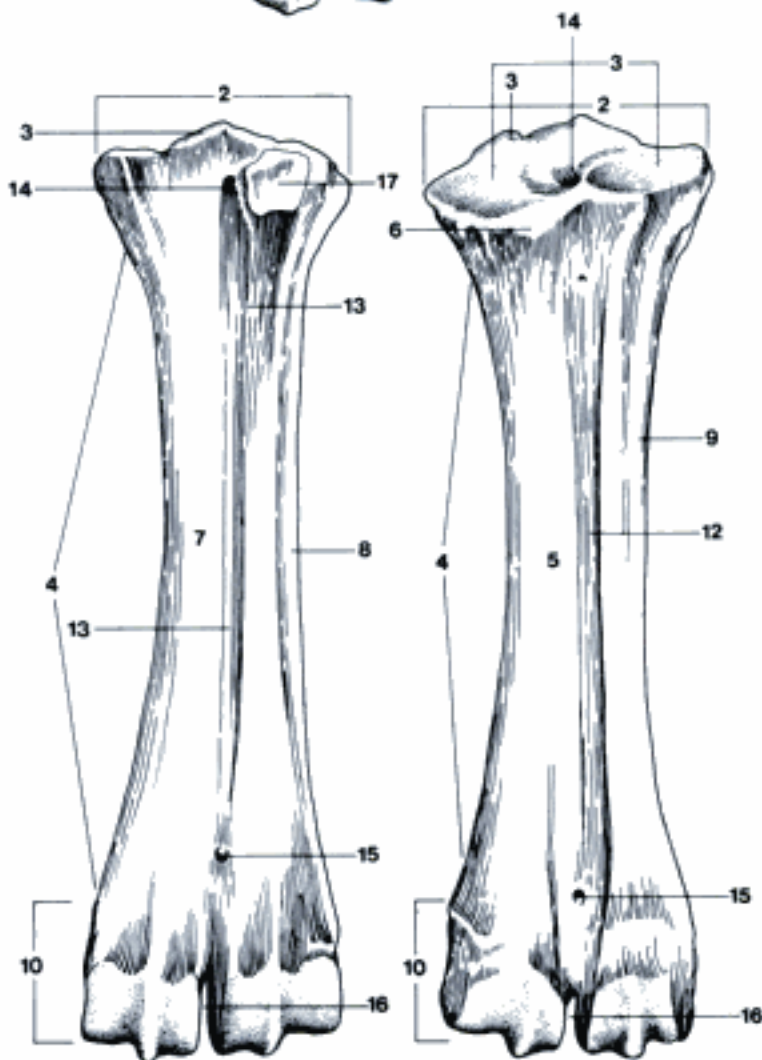
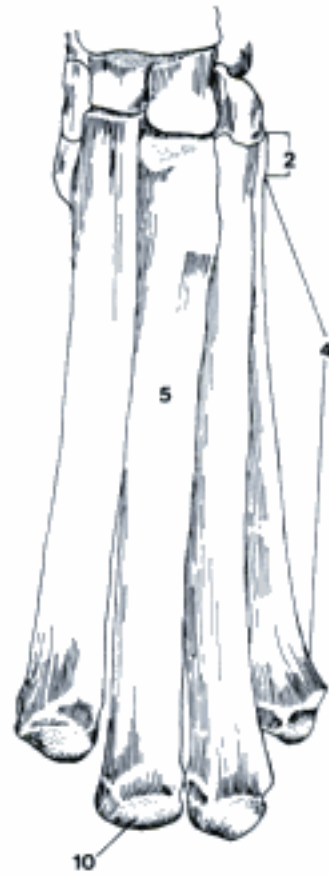E Right calcaneus, dorsal aspect (ca)

- 1 **Ossa metatarsalia I–V.** A B
- 2 *Basis.* Base, the proximal end. A B C D
- 3 *Facies articularis tarsea.* Articular surface. C D
- 4 *Corpus.* Body. A B C D
- 5 *Facies dorsalis.* Dorsal surface. B D
- 6 *Tuberositas ossis metatarsalis III.* Dorsal tuberosity at the base of the third metatarsal bone. D
- 7 *Facies plantaris.* Plantar surface. A C
- 8 *Facies medialis.* Medial surface. C
- 9 *Facies lateralis.* Lateral surface. D
- 10 *Caput.* Head, the distal end. A B C D
- 11 *Os metatarsale III et IV (Ru).* Fused third and fourth metatarsal bones. C D
- 12 *Sulcus longitudinalis dorsalis.* Dorsal longitudinal groove. D
- 13 *Sulcus longitudinalis plantaris.* Plantar longitudinal groove. C
- 14 *Canalis metatarsi proximalis.* Proximal metatarsal canal. C D
- 15 *Canalis metatarsi distalis.* Distal metatarsal canal. C D
- 16 *Incisura intertrochlearis.* Intertrochlear notch, dividing the distal ends. C D
- 17 *Os sesamoideum metatarsale.* Plantar sesamoid bone in su and Ru, articulating with the base of Os metatarsale III. C
- 18 **Ossa digitorum pedis.** Digital bones of pes. (Vide Ossa digitorum manus, sed. See Ossa digitorum manus, but)
- 19 *Processus plantaris medialis.* Medial plantar process in eq. E
- 20 *Processus plantaris lateralis.* Lateral plantar process in eq. E
- 21 *Foramen processus plantaris.* Variable foramen of plantar process. E
- 22 *Incisura processus plantaris.* Variable notch of plantar process. E

A Left metatarsal bones, plantar aspect (ca)

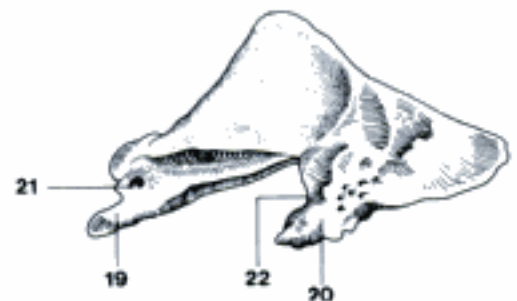


B Left metatarsal bones, dorsal aspect (ca)



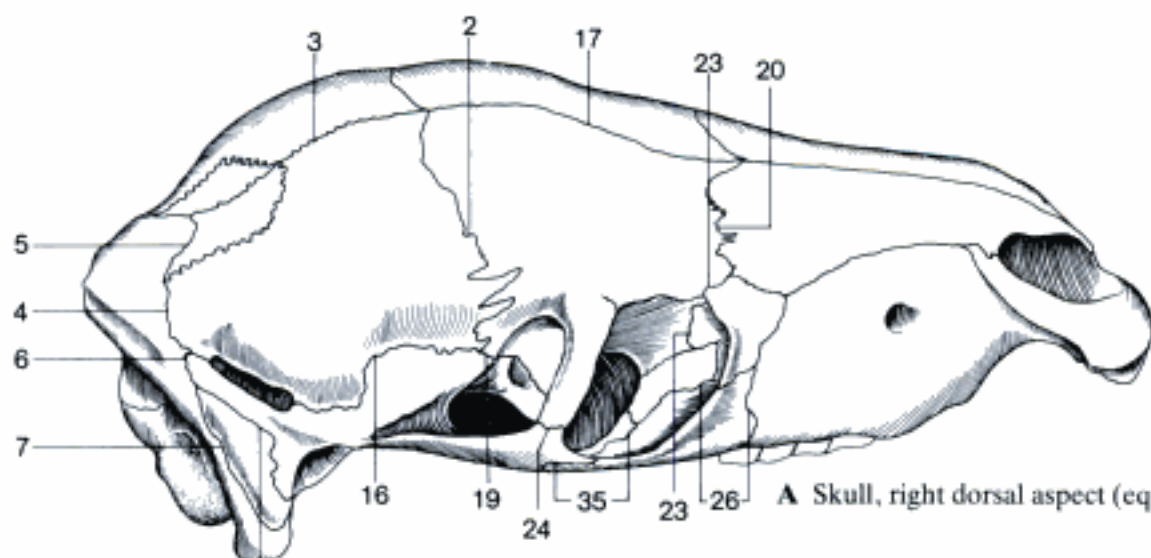
C Left metatarsal bones, plantar aspect (bo)

D Left metatarsal bones, dorsal aspect (bo)

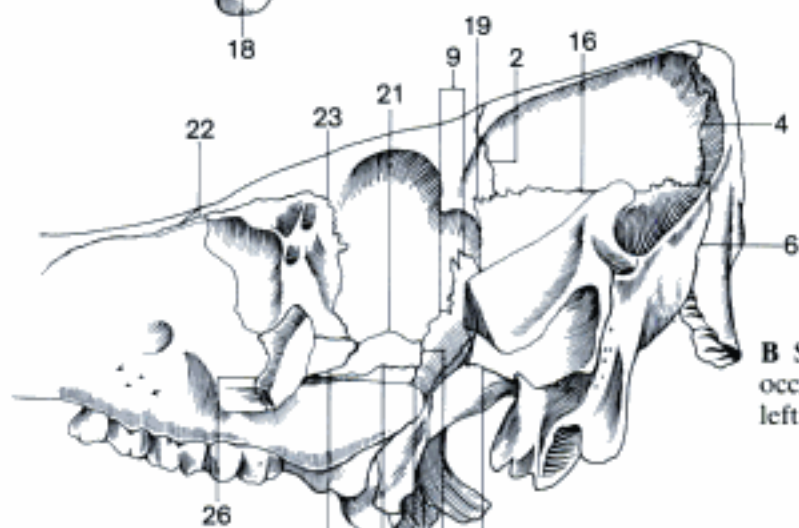


E Phalanx distalis of right hind digit, latero-plantar aspect (eq)

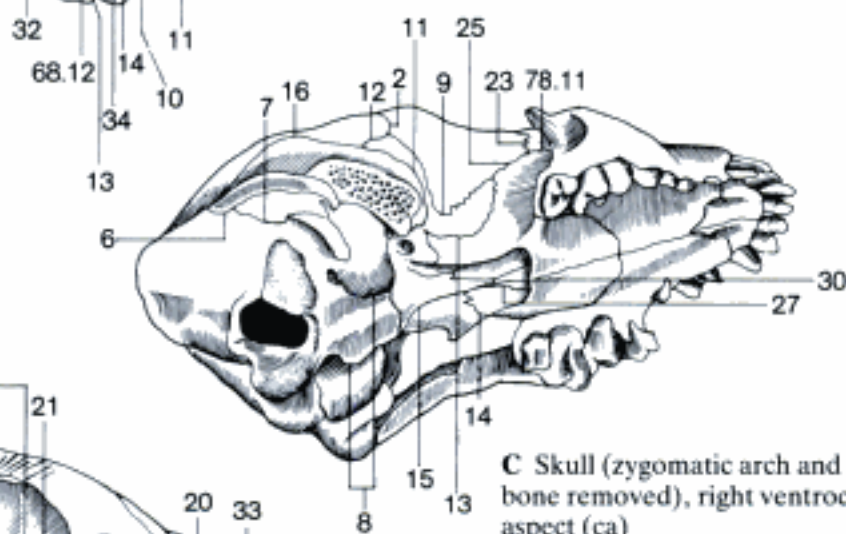
- 1 **SUTURAE CAPITIS.** Skull sutures.
- 2 *Sutura coronalis.* Coronal suture, between frontal and parietal bones. A B C
- 3 *Sutura sagittalis.* Sagittal suture, between right and left parietal bones. A
- 4 *Sutura lambdoidea.* Lambdoid suture, between parietal bones and occipital (and interparietal) bone. A B
- 5 *Sutura occipitointerparietalis.* Between occipital and interparietal bones in fe, Ru, and eq, persistent only in fe and ov. A
- 6 *Sutura occipitosquamosa.* Between occipital bone and squama temporalis. A B C D
- 7 *Sutura occipitomastoidea.* Ventral continuation of the *Sutura occipitosquamosa.* A C D
- 8 *Sutura occipitotympanica.* Between occipital bone and tympanic (endotympanic in fe) part of temporal bone, absent in eq. C D
- 9 *Sutura sphenofrontalis.* Between frontal and sphenoid bones. B D
- 10 *Sutura sphenoeethmoidalis.* Between presphenoid and ethmoid bones, in Car and eq only inside the skull. B D
- 11 *Sutura sphenosquamosa.* Between basisphenoid (and presphenoid in eq) and squama temporalis. B C D
- 12 *Sutura sphenoparietalis.* Between basisphenoid and parietal bone in Car, ov, and cap. C
- 13 *Sutura sphenopalatina.* Between sphenoid and palatine bones. B C D
- 14 *Sutura pterygopalatina.* Between pterygoid and palatine bones. B C
- 15 *Sutura pterygosphenoidalis.* Between pterygoid and sphenoid bones. C
- 16 *Sutura squamosa.* Squamosal suture, between parietal and temporal bones. A B C D
- 17 *Sutura interfrontalis.* Between right and left frontal bones. A
- 18 *Sutura squamosomastoidea.* Between squamous and petrous parts of the temporal bone. A D
- 19 *Sutura squamosofrontalis.* Between squama temporalis and frontal bones in su, older bo, and eq. A B
- 20 *Sutura frontonasalis.* Between frontal and nasal bones. A D
- 21 *Sutura frontoethmoidalis.* Between frontal and ethmoid bones, in Car and eq only inside the skull. B D
- 22 *Sutura frontomaxillaris.* Between frontal bone and maxilla in Car and su. B
- 23 *Sutura frontolacrimalis.* Between frontal and lacrimal bones. A B C
- 24 *Sutura frontozygomatica.* Between frontal bone and zygomatic bone in Ru, Processus zygomaticus of temporal bone in eq, at the lateral wall of the Orbita. A
- 25 *Sutura frontopalatina.* Between frontal et palatine bones in Car and eq. C
- 26 *Sutura zygomaticomaxillaris.* Between zygomatic bone and maxilla. A B
- 27 *Sutura vomeropalatina.* Between Ala vomeris and Pars perpendicularis of palatine bone, in ca and su also the ventral border of vomer and Pars horizontalis. C D
- 28 *Sutura vomeromaxillaris.* Between ventral border of vomer and Processus palatinus of right and left maxilla. D
- 29 *Sutura vomeroincisiva.* Between vomer and Processus palatinus of right and left incisive bones. D
- 30 *Sutura vomerosphenoidalis.* Between Ala vomeris and presphenoid. C
- 31 *Sutura vomeroethmoidalis.* Between Sulcus vomeris and Pars perpendicularis of ethmoid, also between Ala vomeris and Lamina basalis of the ethmoid in Car and su. D
- 32 *Sutura ethmoidomaxillaris.* Between maxilla and Laminae basalis and orbitalis of ethmoid. B
- 33 *Sutura ethmoidonasalis.* Between nasal bone and Lamina tectoria of ethmoid. D
- 34 *Sutura sphenomaxillaris.* Between Processus pterygoideus of basisphenoid and maxilla in su. B
- 35 *Sutura temporozygomatica.* Between temporal and zygomatic bones on the Arcus zygomaticus. A



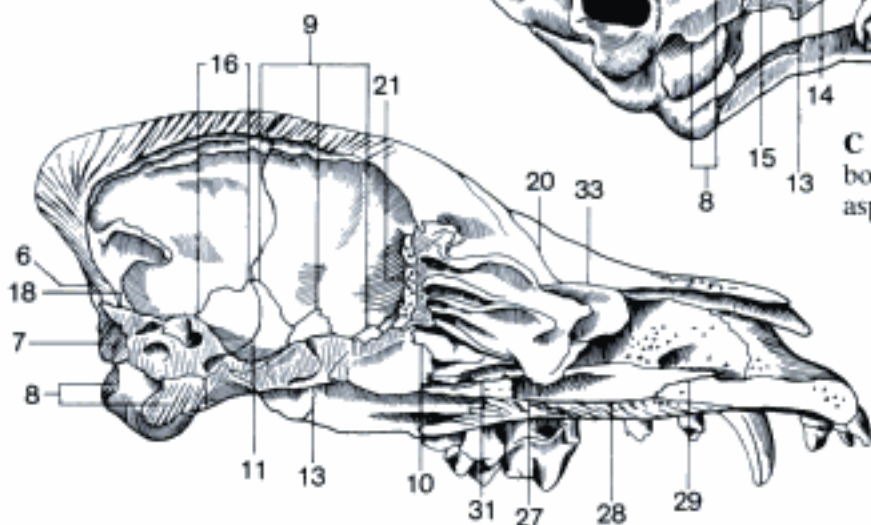
A Skull, right dorsal aspect (eq, young)



B Skull (zygomatic arch, and part of the occipital and pterygoid bones removed), left aspect (su)

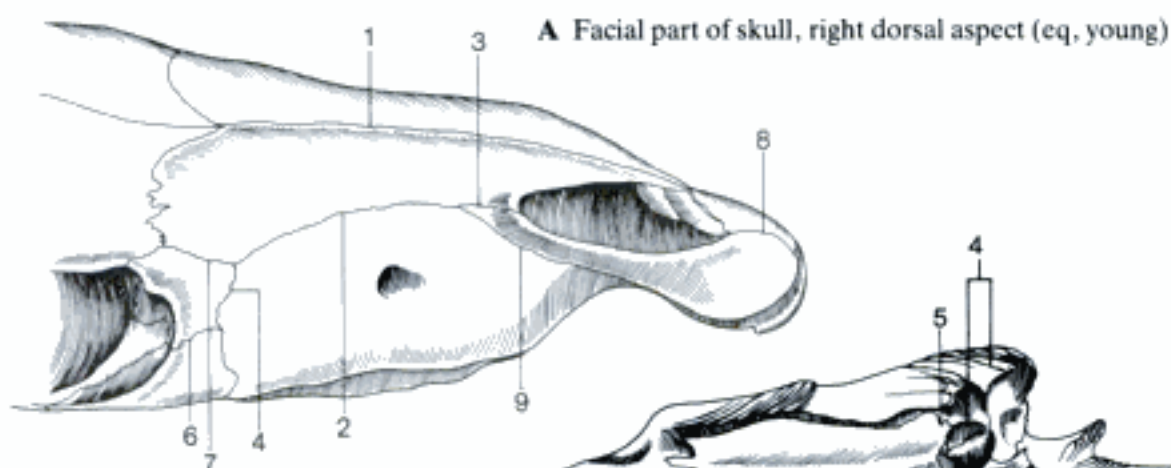


C Skull (zygomatic arch and pterygoid bone removed), right ventrocaudal aspect (ca)

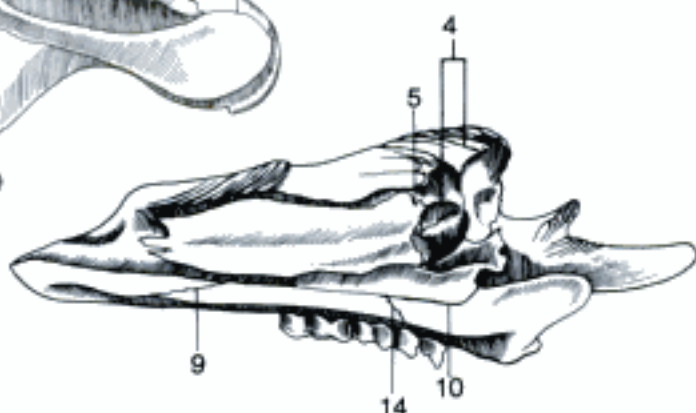


D Skull, paramedian section (occipital and pterygoid bones removed), medial aspect (ca)

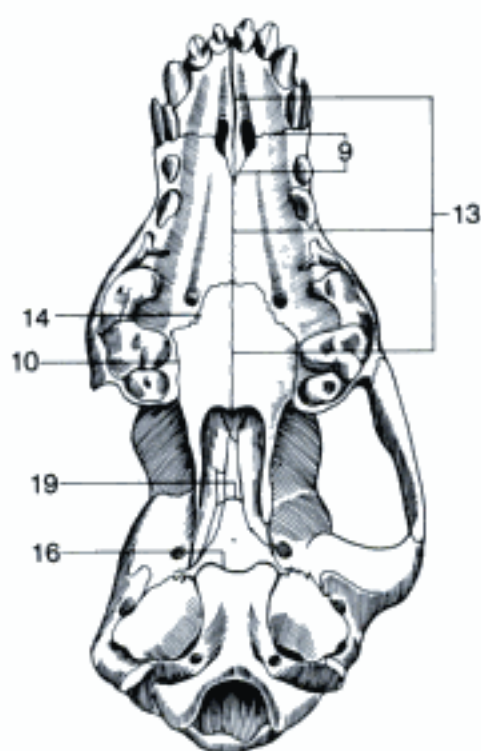
- 1 *Sutura internasalis*. Between right and left nasal bones. A
- 2 *Sutura nasomaxillaris*. Between nasal bone and maxilla in Car, su, and eq, sometimes in bo. In ov, cap, and sometimes in bo there is a Fissura nasomaxillaris. A
- 3 *Sutura nasoincisiva*. Between nasal and incisive bones in Car, su, and eq. A
- 4 *Sutura lacrimomaxillaris*. Between lacrimal bone and maxilla. A B
- 5 *Sutura lacrimoconchalis*. Between lacrimal and ventral nasal conchal bones in su and Ru. B
- 6 *Sutura lacrimozygomatica*. Between lacrimal and zygomatic bones, absent in fe. A
- 7 *Sutura nasolacrimalis*. Between nasal and lacrimal bones in eq. In Ru there is a Fissura nasolacrimalis. A
- 8 *Sutura interincisiva*. Median suture between the bodies of right and left incisive bones in Car and eq. A
- 9 *Sutura maxilloincisiva*. Between maxilla and incisive bone. A B C
- 10 *Sutura palatomaxillaris*. Between Pars perpendicularis of palatine bone and maxilla in the Fossa pterygopalatina. B C
- 11 *Sutura palatolacrimalis*. Between palatine and lacrimal bones in Car. 77 C
- 12 *Sutura palatoethmoidalis*. Between palatine bone and ethmoid, superficially in the Fossa pterygopalatina only in su and bo. 77 B
- 13 *Sutura palatina mediana*. Between the two halves of the hard palate, except the rostral part in su and Ru. C
- 14 *Sutura palatina transversa*. Between Processus palatinus of maxilla and Pars horizontalis of palatine bone. B C
- 15 **SYNCHONDROSES CRANII**. Cartilaginous joints of the skull. Most of them disappear by progressive ossification.
- 16 *Synchondrosis sphenoccipitalis*. Between basisphenoid and occipital bones. C D
- 17 *Synchondrosis sphenopetrosa*. Between basisphenoid and petrosal bones in Car. Remains in the adult as fissure in the macerated skull, contains then fibrocartilage. D
- 18 *Synchondrosis petrooccipitalis*. Between petrosal and occipital bones in Car and Ru. Remains in the adult as fissure in the macerated skull, contains then fibrocartilage. D
- 19 *Synchondrosis intersphenoidalis*. Between pre- and basisphenoid bones. C D
- 20 (*Synchondrosis intraoccipitalis squamolateralis*). Between Pars lateralis and Squama occipitalis. E
- 21 (*Synchondrosis intraoccipitalis basilateralis*). Between Pars basilaris and Squama occipitalis. D E
- 22 **Articulatio temporomandibularis**. Synovial joint between the Ramus mandibulae and the Pars squamosa of the temporal bone. F
- 23 *Capsula articularis*. Joint capsule.
- 24 *Membrana synovialis dorsalis*. Connects Os temporale and Discus articularis. F
- 25 *Membrana synovialis ventralis*. Connects Discus articularis and Mandibula. F
- 26 *Discus articularis*. Disk in the temporomandibular joint, dividing it into two chambers. F
- 27 *Lig. laterale*. Ligament on the lateral surface of the joint capsule. F
- 28 *Lig. caudale*. Elastic ligament from Processus retroarticularis to Collum mandibulae in eq (and Ru). F
- 29 **Articulatio temporohyoidea**. Attachment of Apparatus hyoideus to Os temporale. F
- 30 **Articulatio intermandibularis**. Median connection of the bodies of right and left mandible, in adult su and eq replaced by a synostosis. G
- 31 *Synchondrosis intermandibularis*. The smaller part of Articulatio intermandibularis is formed by cartilage. G
- 32 *Sutura intermandibularis*. The larger part of Articulatio intermandibularis is formed by connective tissue. G



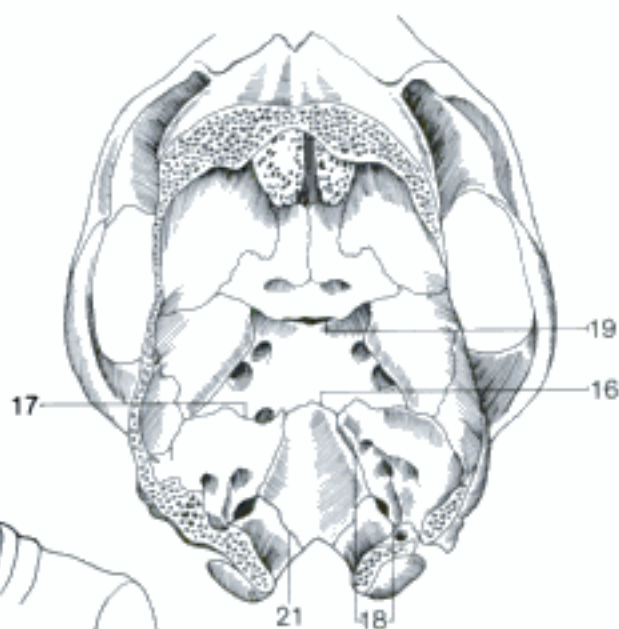
A Facial part of skull, right dorsal aspect (eq, young)



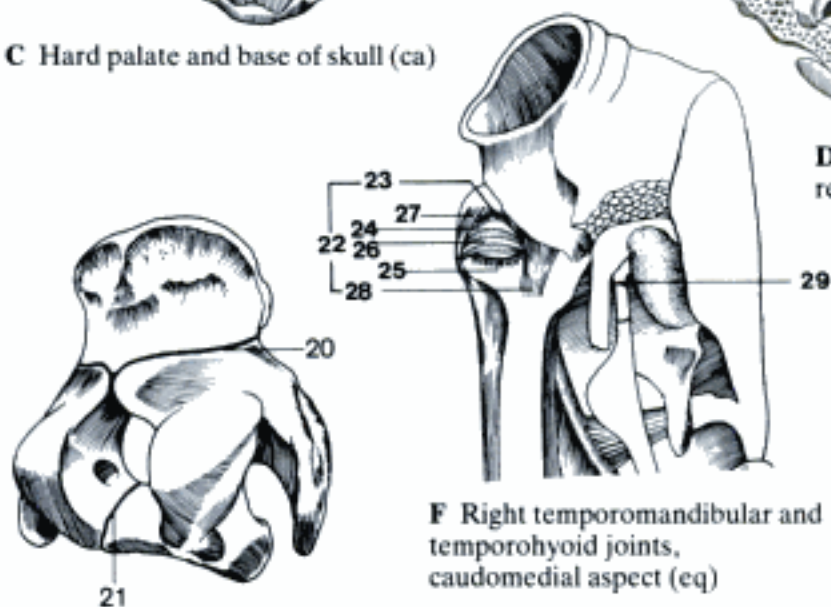
B Right maxilla, incisive, lacrimal and ventral turbinate bones, medial aspect (su)



C Hard palate and base of skull (ca)



D Base of skull (part of left petrosal bone removed), dorsal aspect (ca)



E Os occipitale, right caudal aspect (eq, young)

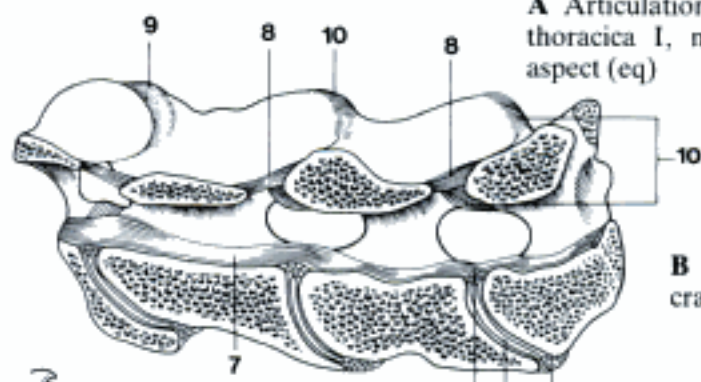
F Right temporomandibular and temporohyoid joints, caudomedial aspect (eq)



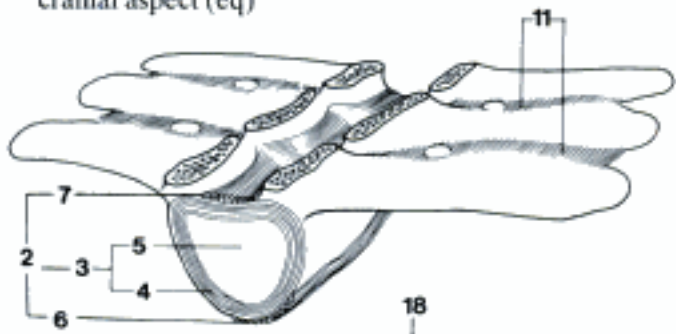
G Articulatio intermandibularis, median section, right half (ca)

- 1 **ARTICULATIONES COLUMNAE VERTEBRALIS, THORACIS ET CRANII.** Joints of the vertebral column, thorax, and skull.
- 2 *Symphysis intervertebralis.* B
- 3 *Discus intervertebralis.* Intervertebral disc, connecting the vertebral bodies. A B D
- 4 *Anulus fibrosus.* Fibrous ring around the nucleus pulposus. A B
- 5 *Nucleus pulposus.* Soft, but noncompressible substance in the center of the intervertebral disc. A B
- 6 *Lig. longitudinale ventrale.* Connects the ventral surfaces of the vertebral bodies from 8th thoracic vertebra to sacrum. B
- 7 *Lig. longitudinale dorsale.* Connects the dorsal surfaces of the vertebral bodies. A B
- 8 *Ligg. flava.* Yellow elastic ligaments connecting the vertebral arches. A
- 9 *Articulationes processuum articularium.* Joints between articular processus. A C D
- 10 *Capsula articularis.* Joint capsule. A C
- 11 *Ligg. intertransversaria.* Between transverse processes of lumbar vertebrae. B D
- 12 *Ligg. interspinalia.* Between spinous processes, absent in Car. C
- 13 *Lig. supraspinale.* Attached to the tips of the spinous processes of thoracic and lumbar vertebrae. C
- 14 *Lig. nuchae.* Nuchal ligament. Modified elastic continuation of Lig. supraspinale in ca, Ru, and eq. C
- 15 *Funiculus nuchae.* From Protuberantia occipitalis externa in Ru and eq, from spinous process of axis in ca to spinous processes of thoracic vertebrae. C
- 16 *Lamina nuchae.* From spinous processes of cervical vertebrae to Funiculus nuchae in Ru and eq. C
- 17 *Articulationes intertransversariae lumbales.* Synovial joints in eq between transverse processes of Vertebrae lumbales V et VI, often also IV et V. D
- 18 *Articulatio lumbosacralis.* Joint between last lumbar vertebra and sacrum. D
- 19 *Lig. iliolumbale.* Lamina from transverse processes of last (Car, su, ov, cap), last two (bo) or last 3–4 (eq) lumbar vertebrae to Crista iliaca. D
- 20 *Articulatio intertransversaria lumbosacralis.* Synovial joint between the transverse process of Vertebra lumbalis VI and Ala ossis sacri in eq. D
- 21 **Articulatio atlantooccipitalis.** Joint between atlas and occipital bone. C E F G
- 22 *Capsula articularis.* E F G
- 23 *Membrana atlantooccipitalis ventralis.* Ventral thickening of the capsule. E
- 24 *Membrana atlantooccipitalis dorsalis.* Connects Arcus dorsalis of atlas and occipital bone. E G
- 25 *Lig. laterale.* From Ala atlantis to occipital bone. E F G
- 26 **Articulatio atlantoaxialis.** Joint between atlas and axis. C E F G
- 27 *Capsula articularis.* E F G
- 28 *Membrana atlantoaxialis dorsalis.* Connection between Arcus dorsalis of atlas and arch of axis. E
- 29 *Lig. atlantoaxiale dorsale.* Elastic ligament between Tuberculum dorsale of atlas and Processus spinosus of axis. E
- 30 *Membrana tectoria.* From the dorsal surface of the body of the axis to the ventral border of the Foramen magnum, also attached inside the atlas. G
- 31 *Lig. transversum atlantis* (Car, su). From one side of the atlas to the other, dorsal to the dens. F
- 32 *Lig. longitudinale dentis.* In Ru and eq from the dorsal surface of the dens to the Arcus ventralis of the atlas. G
- 33 *Lig. apicis dentis* (Car, su, Ru). From the Apex of the dens to the Pars basilaris of the occipital bone. G
- 34 *Ligg. alaria* (Car, su). From lateral border of dens to Condylus occipitalis (Car) or ventral border of Foramen magnum (su). F
- 35 *Lig. atlantoaxiale ventrale.* From Tuberculum ventrale of atlas to Crista ventralis of axis in Ru and eq. E

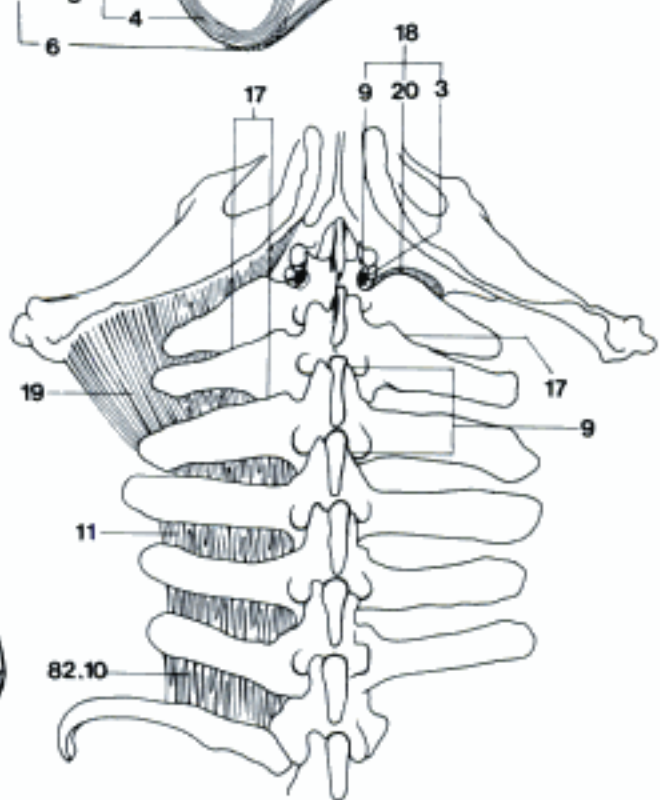
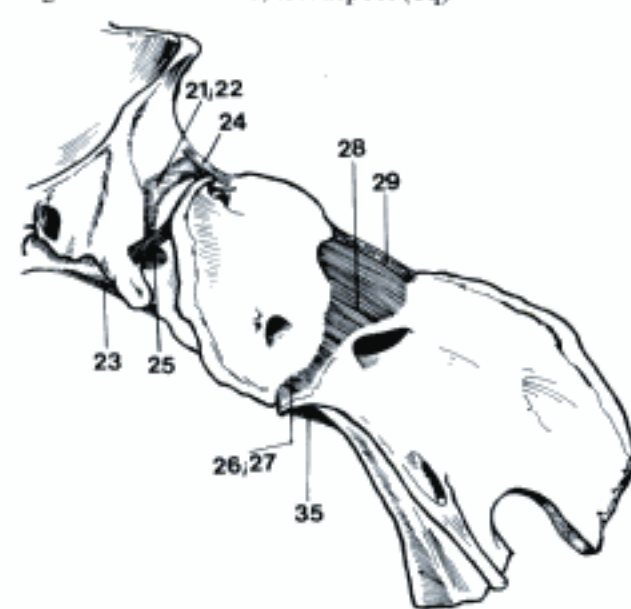
A Articulations of the last Vertebrae cervicales and thoracica I, median section, medial (and dorsal) aspect (eq)



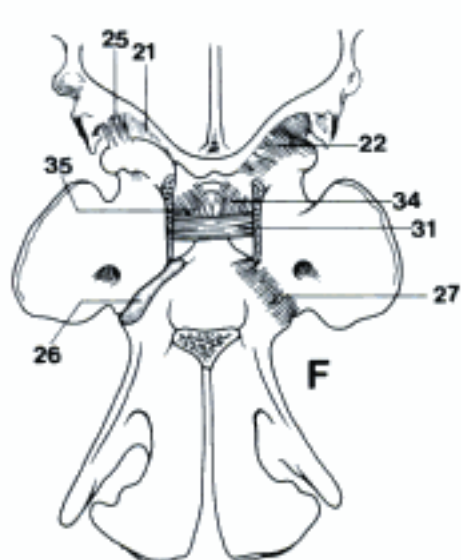
B Vertebrae lumbales (arches removed), left dorso-cranial aspect (eq)



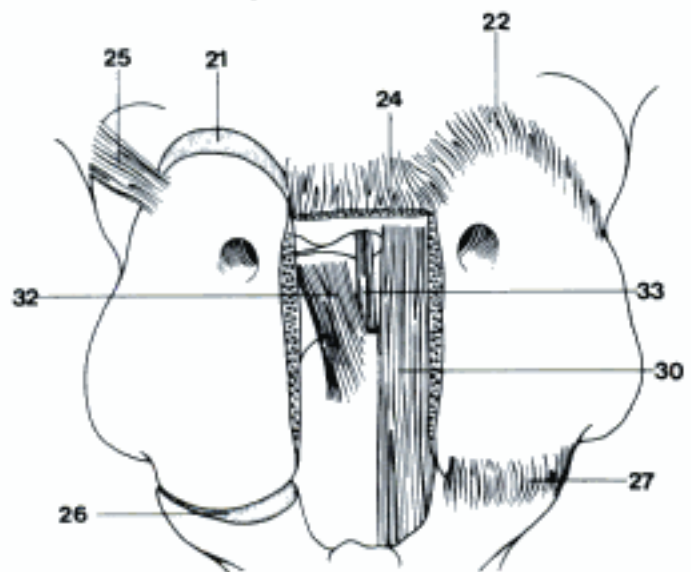
C Ligamentum nuchae, left aspect (eq)



E Articulations of atlas and axis, left aspect (eq)



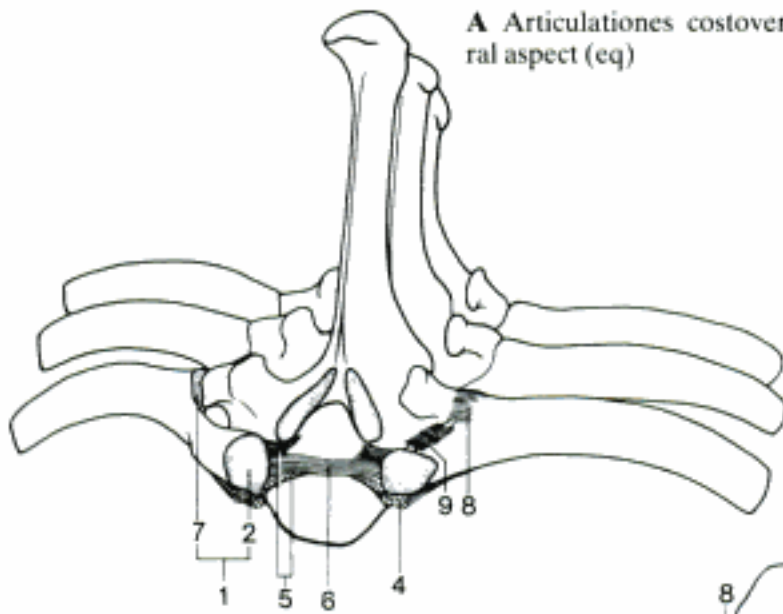
D Articulations of the Vertebrae lumbales, dorso-cranial aspect (eq)



F Articulations of atlas and axis (dorsal arch of atlas removed), dorsal aspect (ca)

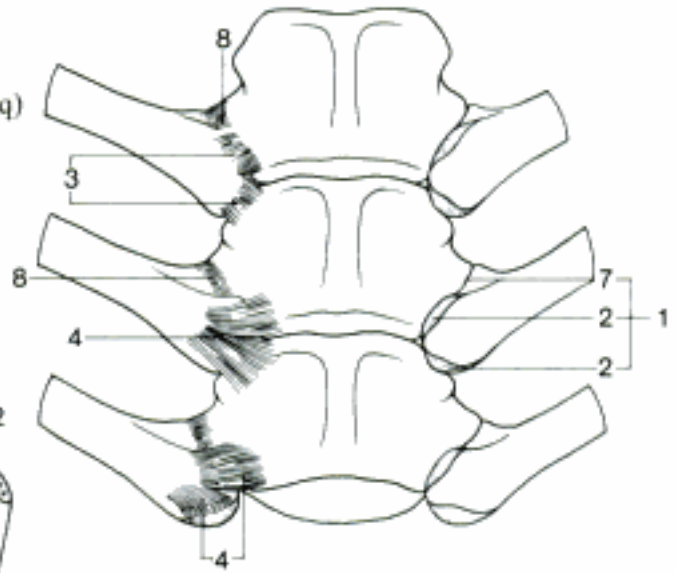
G Articulations of atlas and axis (dorsal arch of atlas removed), dorsal aspect (bo)

- 1 **Articulationes costovertebrales.** Joints between ribs and vertebrae. A B
- 2 **Articulatio capitis costae.** Joint between the head of a rib and the bodies of two vertebrae and intervertebral disc. A B
- 3 *Capsula articularis.* Joint capsule. B
- 4 *Lig. capitis costae radiatum.* Radiates from the ventral surface of the head of a rib to the bodies of two adjacent vertebrae. A B
- 5 *Lig. capitis costae intraarticulare.* From the Crista capitis costae to the dorsal surfaces of two vertebrae and the intervertebral disc. A
- 6 *Lig. intercapitale.* Part of *Lig. capitis costae intraarticulare* which connects the heads of ribs of the same segment. A
- 7 **Articulatio costotransversaria.** Joint between Tuberculum costae and transverse process. A B
- 8 *Capsula articularis.* Joint capsule. A B
- 9 *Lig. costotransversarium.* Between neck of rib and transverse process. A
- 10 *Lig. lumbocostale.* Between last rib and transverse process of the first lumbar vertebra, of different thickness according to species and individually. 81 D
- 11 **Articulationes sternocostales.** Joints between Cartilaginee costales and sternum. C E
- 12 *Capsula articularis.* Joint capsule. C E
- 13 *Ligg. sternocostalia radiata.* Radiating from Cartilago costalis to sternum, especially on the dorsal surface. C
- 14 *Lig. sterni.* Fiber bundles on the dorsal surface of the sternum in bo and eq. C
- 15 *Membrana sterni.* Ligamentous tissue on the ventral surface of the sternum in su and Ru. D
- 16 *Ligg. costoxiphoidea.* Fibers from the last Costa vera (first Costa spuria in eq) to Processus xiphoideus. E
- 17 *Membrana intercostalis externa.* Continuation of *Mm. intercostales externi* at the ventral end of the intercostal space. Well developed only in bo and eq. E
- 18 *Membrana intercostalis interna.* Continuation of *Mm. intercostales interni* at the ventral end of the intercostal space. Well developed only in eq and especially in bo. E
- 19 **Synchondroses sternales.** Cartilaginous joints between parts of the sternum. E
- 20 *Synchondrosis manubriosternalis.* Cartilaginous joint between Manubrium and Corpus sterni in young domestic mammals; in adult only in Car, eq, and sometimes cap. E
- 21 *Synchondroses intersternebrales.* Cartilaginous joints between Sternebrae of the Corpus sterni, ossify in su and Ru. D E
- 22 *Synchondrosis xiphosternalis.* Cartilaginous joint between Corpus sterni and Processus xiphoideus, ossifies in su and Ru. E
- 23 **Articulatio synovialis manubriosternalis.** Synovial joint between Manubrium and Corpus sterni in adult su, bo, ov, and sometimes cap. D
- 24 *Capsula articularis.* Joint capsule. D
- 25 *Lig. sternocostale intraarticulare.* Within the joint cavity, between right and left second ribs and sternum in su, bo, ov and sometimes cap. D
- 26 **Articulationes costochondrales.** Between osseous and cartilaginous parts of the ribs. C D
- 27 **Articulationes intrachondrales.** Synovial joints within the cartilage of 2nd to 5th ribs in su, 2nd to 10th in Ru. Occur sometimes in older ca. D

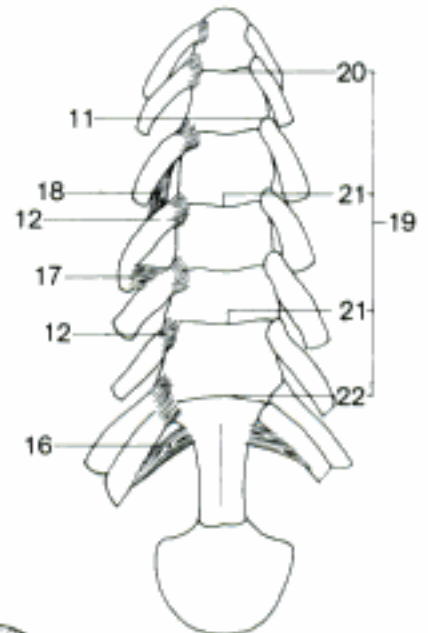
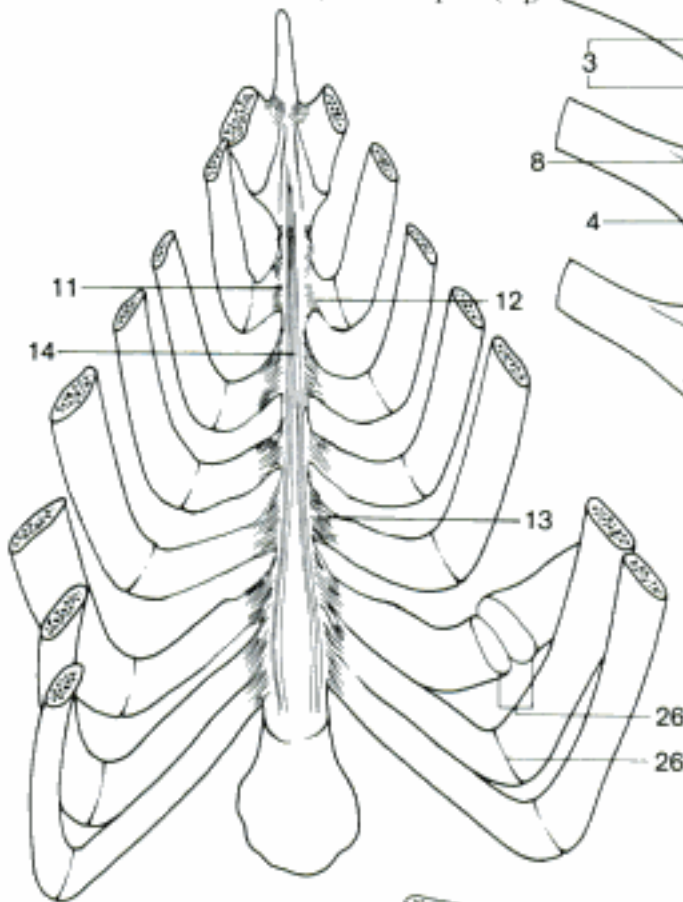


A Articulaciones costovertebrales, craniodorsolateral aspect (eq)

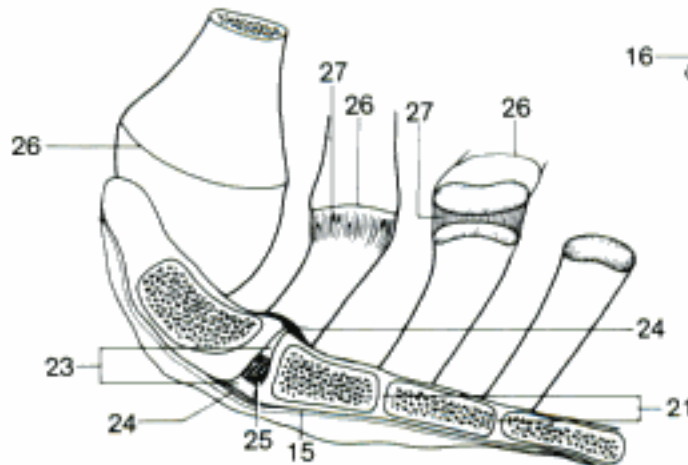
B Articulaciones costovertebrales, ventral aspect (eq)



C Articulaciones sternocostales, dorsal aspect (eq)

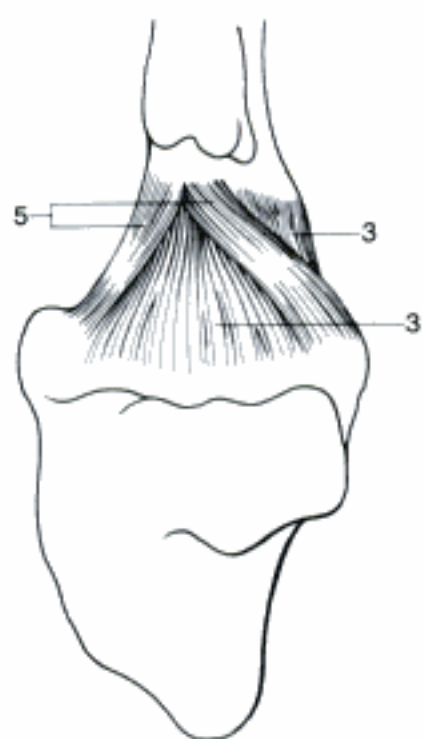
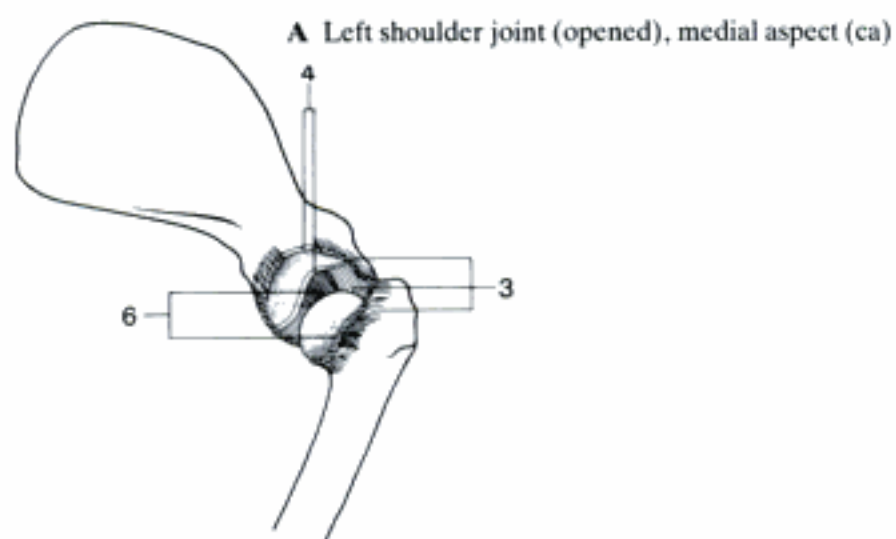


E Articulaciones of sternum and Cartilagines costales, ventral aspect (cap)

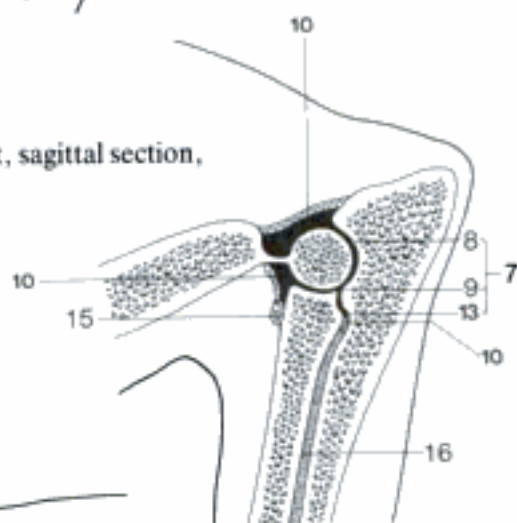


D Articulaciones of sternum and Cartilagines costales, median section, right half (bo)

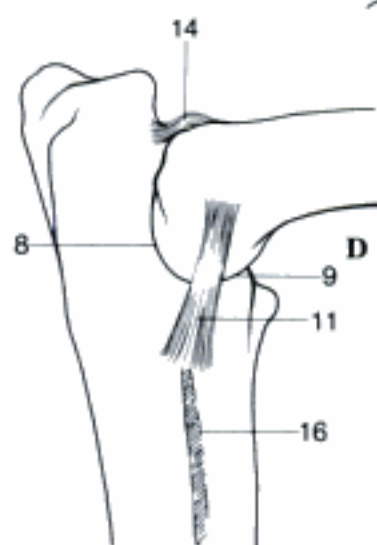
- 1 **ARTICULATIONES MEMBRI THORACICI.** Joints of the thoracic limb.
- 2 **Articulatio humeri.** Shoulder joint. Between scapula and humerus. A B
- 3 *Capsula articularis.* A B
- 4 *Labrum glenoidale.* Glenoid labrum. Fibrocartilaginous rim enlarging the Cavitas glenoidalis. A
- 5 *Lig. coracohumerale.* Thickend part of capsule between Tuberculum supraglenoidale and the bases of Tuberculum majus and Tuberculum minus in Un. B
- 6 *Ligg. glenohumeralia.* Thickend parts in the lateral and medial walls of the capsule in Car. A
- 7 **Articulatio cubiti.** Elbow joint. Between humerus, radius, and ulna. C D E
- 8 *Articulatio humeroulnaris.* C D E
- 9 *Articulatio humeroradialis.* C D E
- 10 *Capsula articularis.* C E
- 11 *Lig. collaterale cubiti mediale.* From Epicondylus medialis to radius, in Car and su also to ulna. D
- 12 *Lig. collaterale cubiti laterale.* From Epicondylus lateralis to radius, in Car, su, and Ru also to ulna. E
- 13 **Articulatio radioulnaris proximalis.** Joint between Circumferentia articularis radii and Incisura radialis ulnae. C E
- 14 *Lig. olecrani.* Elastic ligament from the medial border of Fossa olecrani to olecranon in Car. D E
- 15 *Lig. anulare radii.* Encircles the head of radius, is attached to the edges of the Incisura radialis ulnae in Car. C E
- 16 *Membrana interossea antebrachii.* Connects as membrane radius and ulna only in Car; ossifying connective tissue in Un. C D E
- 17 *Lig. interosseum antebrachii.* Connects radius and ulna in the proximal half of Spatium interosseum in Car, lateral to Membrana interossea antebrachii. E
- 18 **Articulatio radioulnaris distalis.** Joint between Incisura ulnaris radii and Circumferentia articularis ulnae in Car and su. F G
- 19 *Capsula articularis.* F
- 20 *Lig. radioulnare.* Cranial fibers at the distal ends of radius and ulna in Car. F
- 21 **Articulationes manus.** Joints of the manus.
- 22 **Articulatio carpi.** Carpal joint, includes the joints between forearm, carpal and metacarpal bones. F G
- 23 *Lig. collaterale carpi laterale.* Extends from Processus styloideus ulnae to Os carpi ulnare in Car, also to Os carpale IV and metacarpus in Un. F G
- 24 *Lig. collaterale carpi mediale.* Extends from Processus styloideus radii to Os carpi (intermedio-)radiale in Car, also to Os carpale II and metacarpus in Un. F G
- 25 **Articulatio antebrachio-carpea.** Joint between the distal parts of radius and ulna and the proximal row of carpal bones. F
- 26 *Articulatio radiocarpea.* F G
- 27 *Articulatio ulnocarpea.* F
- 28 *Capsula articularis.* G
- 29 *Lig. radiocarpeum dorsale.* Dorsal fibers from radius to Os carpi ulnare (su also intermedium), absent in eq. F
- 30 *Lig. radiocarpeum palmare.* Palmar fibers from radius to Os carpi radiale (eq), intermedium (Car), and ulnare (su, Ru). G
- 31 *Lig. ulnocarpeum palmare.* Palmar fibers from Processus styloideus ulnae to Os carpi radiale, intermedium, in bo ulnare. G
- 32 **Articulationes intercarpeae.** Joints between carpal bones of one row. F G
- 33 **Articulatio mediocarpea.** Joint between proximal and distal rows of carpal bones. F G
- 34 *Capsula articularis.* F
- 35 *Lig. carpi radiatum.* Palmar fibers diverging from Os carpale III. G
- 36 *Ligg. intercarpea dorsalia.* Dorsal ligaments between carpal bones. F
- 37 *Ligg. intercarpea palmaria.* Palmar ligaments between carpal bones. G
- 38 *Ligg. intercarpea interossea.* Interosseous fibers between carpal bones of one row. G



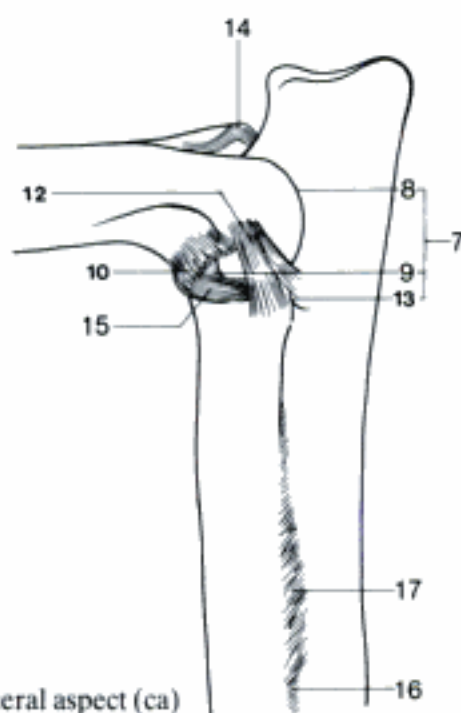
C Left elbow joint, sagittal section, lateral aspect (ca)



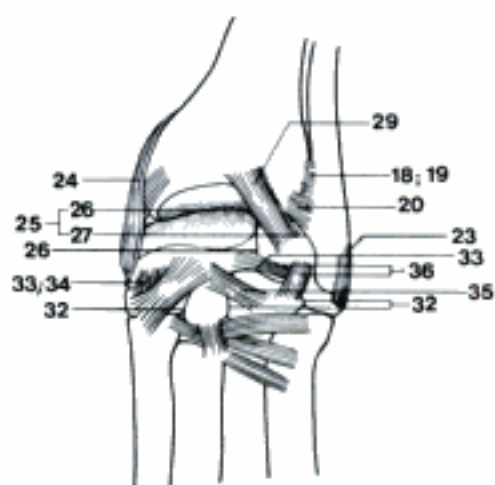
D Left elbow joint, medial aspect (ca)



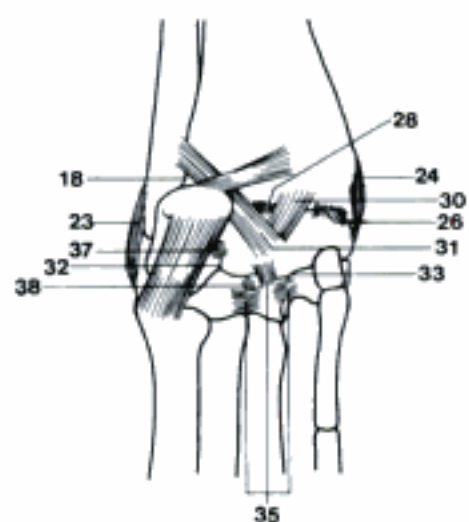
E Left elbow joint, lateral aspect (ca)



F Left carpal joint, dorsal aspect (ca)

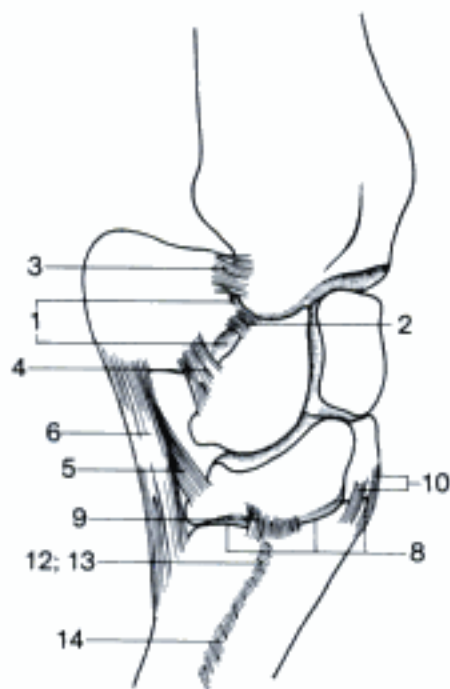


G Left carpal joint, palmar aspect (ca)

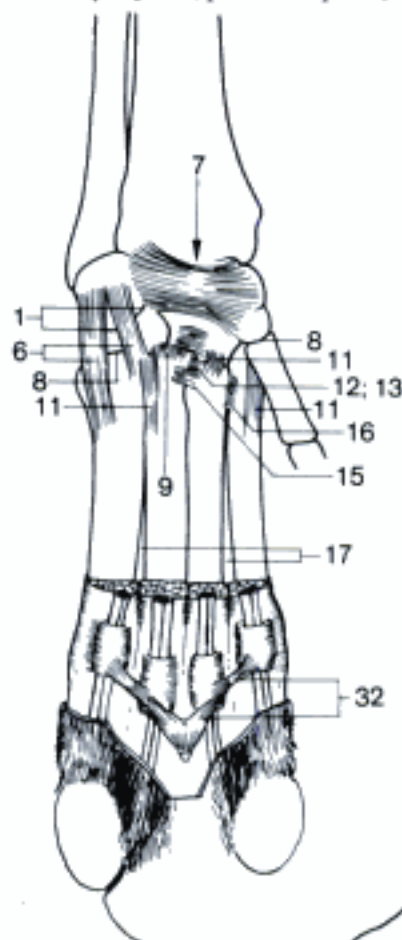


- 1 **Articulatio ossis carpi accessorii [ossis pisiformis]**. Joint between Os carpi accessorium and Os carpi ulnare, in Car also ulna, in eq radius. A B
- 2 *Capsula articularis*. Joint capsule. A
- 3 *Lig. accessorioulnare [pisoulnare]*. Ligament from Os carpi accessorium to ulna (eq radius). A
- 4 *Lig. accessoriocarpoulnare [pisotriquetrum]*. Ligament from Os carpi accessorium to Os carpi ulnare. A
- 5 *Lig. accessorioquartale [pisohamatum]*. Ligament from Os carpi accessorium to Os carpale IV. A
- 6 *Lig. accessoriometacarpeum [pisometacarpeum]*. Ligament from Os carpi accessorium to metacarpus. A B
- 7 *Canalis carpi*. Canal between the proximal row of carpal bones and Retinaculum flexorum. B
- 8 **Articulationes carpometacarpeae**. Joints between distal carpal and metacarpal bones. A B
- 9 *Capsulae articulares*. Joint capsules. A B
- 10 *Ligg. carpometacarpea dorsalia*. Dorsal fibers between carpal and metacarpal bones. A
- 11 *Ligg. carpometacarpea palmaria*. Palmar fibers between carpal and metacarpal bones. B
- 12 **Articulationes intermetacarpeae**. Joints between the bases of the metacarpal bones. A B
- 13 *Capsulae articulares*. Joint capsules. A B
- 14 *Ligg. metacarpea dorsalia*. Dorsal fibers between the bases of metacarpal bones. A
- 15 *Ligg. metacarpea palmaria*. Palmar fibers between the bases of metacarpal bones. B
- 16 *Ligg. metacarpea interossea*. Interosseous fibers between the bases of metacarpal bones. B
- 17 *Spatia interossea metacarpi*. Spaces between metacarpal bones. B
- 18 **Articulationes metacarpophalangeae**. Joints between metacarpal bones and proximal phalanges. C D E F
- 19 *Capsulae articulares*. Joint capsules. C E
- 20 *Recessus dorsales*. Proximal directed dorsal pouch of each joint capsule. C
- 21 *Recessus palmares*. Proximal directed palmar pouch of each joint capsule. C
- 22 *Ligg. collateralia*. Two collateral ligaments of each joint. D E F
- 23 *Ligg. palmaria*. Chondroid tissue containing transverse fibers attached to the sesamoid bones, but extending beyond them in Un, especially proximally, serving as bearing surface for the flexor tendons. C D E F
- 24 *Ligg. sesamoidea collateralia*. Each connects a sesamoid bone to metacarpus and Phalanx proximalis. D E F
- 25 *Lig. metacarpointersesamoideum*. Elastic ligament of eq with two proximal attachments to Os metacarpale III and ending in the Lig. palmare. D
- 26 *Lig. intersesamoideum interdigitale*. Between the axial sesamoid bones in Ru. F
- 27 *Lig. sesamoideum rectum*. From sesamoid bones to the middle phalanx in eq. C D
- 28 *Ligg. sesamoidea obliqua*. From a sesamoid bone to the Phalanx proximalis in eq, lateral and medial to Lig. sesamoideum rectum. D
- 29 *Ligg. sesamoidea brevia*. Short fibers from the distal border of a sesamoid bone to Phalanx proximalis in Un, on both sides of Lig. cruciata. E F
- 30 *Ligg. sesamoidea cruciata*. Crossing fibers from the distal border of a sesamoid bone to the Phalanx proximalis, in Un between the Lig. brevia. E F
- 31 *Ligg. phalangosesamoidea interdigitalia*. Between the Phalanx proximalis of one digit and the axial sesamoid bone of the other in Ru. F
- 32 *Lig. metacarpeum transversum profundum*. Connects the annular ligaments of the flexor tendons of adjacent digitis in Car and su. B
- 33 *Lig. interdigitale proximale*. Short but thick ligament between the proximal halves of Phalanges proximales of digits III and IV in Artiodactyla. F

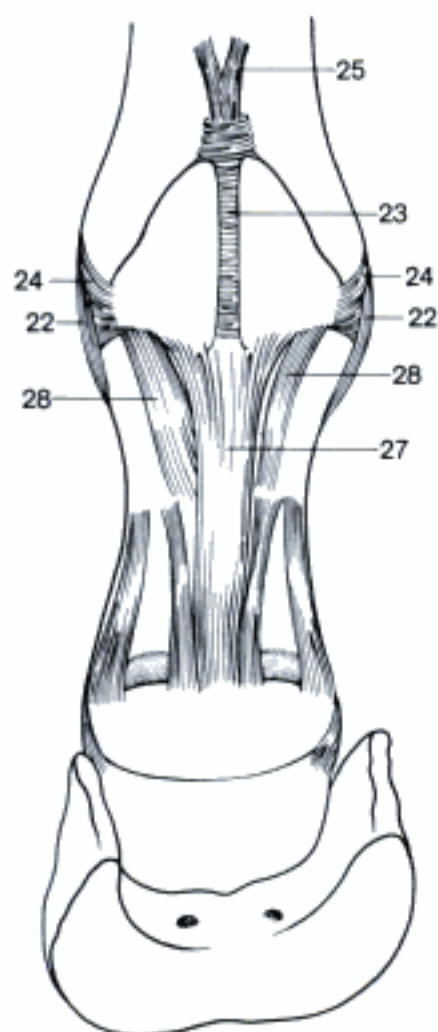
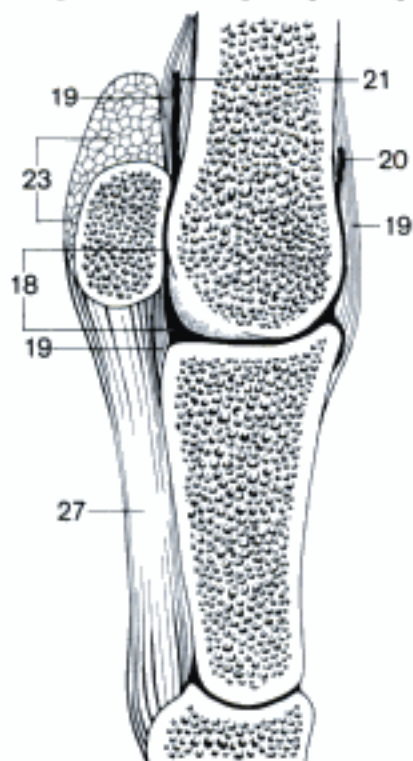
A Right carpal joint, lateral aspect (eq)



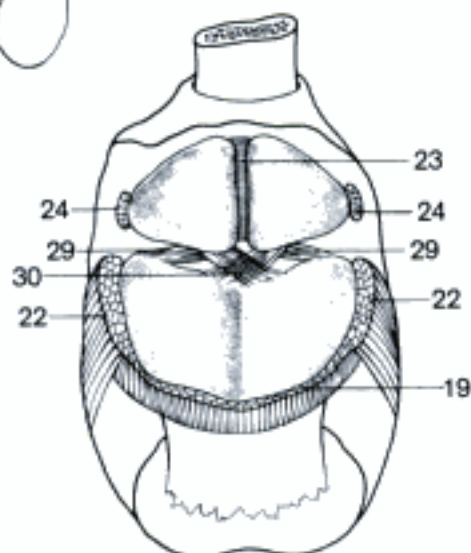
B Left carpal joint, palmar aspect (ca)



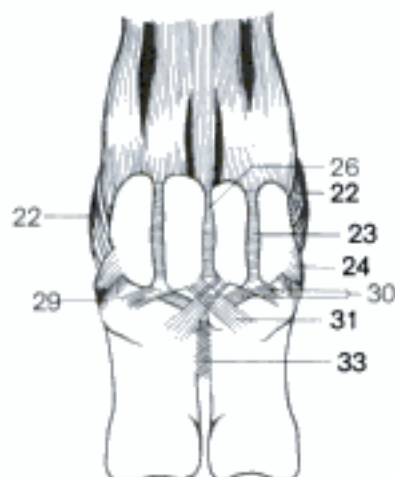
C Metacarpophalangeal joint, sagittal section, right aspect (eq)



D Metacarpophalangeal joint, palmar aspect (eq)

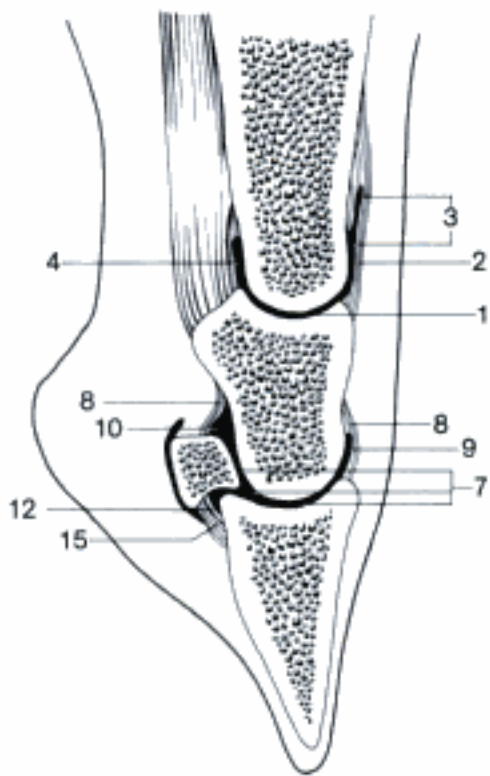


E Metacarpophalangeal joint (metacarpal bone removed), dorsoproximal aspect (eq)

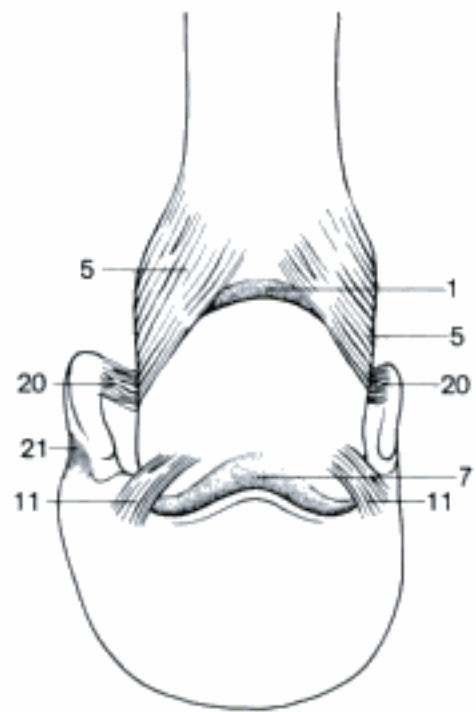


F Metacarpophalangeal joints, palmar aspect (bo)

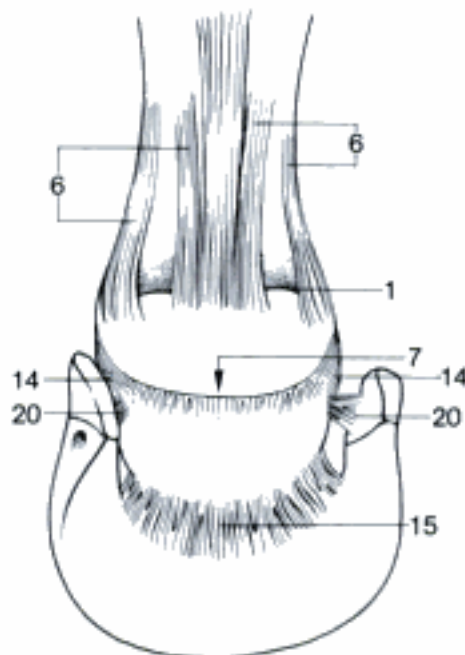
- 1 **Articulationes interphalangeae proximales manus.** Joints between proximal and middle phalanges. A B C D E
- 2 *Capsulae articulares.* Joint capsules. A
- 3 *Recessus dorsales.* Proximally directed dorsal pouch of each joint capsule. A
- 4 *Recessus palmares.* Proximally directed palmar pouch of each joint capsule. A
- 5 *Ligg. collateralia.* Two collateral ligaments of each joint. B D E
- 6 *Ligg. palmaria.* On the third and fourth digits of su and Ru three, in eq four palmar ligaments. C D E
- 7 **Articulationes interphalangeae distales manus.** Joints between middle and distal phalanges. A B C D E
- 8 *Capsulae articulares.* Joint capsules. A
- 9 *Recessus dorsales.* Proximally directed dorsal pouch of each joint capsule. A
- 10 *Recessus palmares.* Proximally directed pouch of each joint capsule. A
- 11 *Ligg. collateralia.* Two collateral ligaments of each joint. B D E
- 12 *Ligg. dorsalia.* Two elastic dorsal ligaments of each joint from Phalanx media to Phalanx distalis in Car, one dorsoaxial in su and Ru. D
- 13 *Ligg. interdigitalia distalia.* Connect digits immediately proximal to the Spatium interdigitale in su and Ru. D
- 14 *Ligg. sesamoidea collateralia.* Connect the Os sesamoideum distale to Phalanx media. C D E
- 15 *Lig. sesamoideum distale impar.* Connects the Os sesamoideum distale and the Phalanx distalis in eq. A C F
- 16 *Lig. sesamoideum distale axiale.* Connects the Os sesamoideum distale and the Phalanx distalis in Ru. D
- 17 *Lig. sesamoideum distale abaxiale.* Connects the Os sesamoideum distale and the Phalanx distalis in Ru. D
- 18 *Ligg. chondrocompedalia.* Extend from Cartilago unguaris to Phalanx proximalis. E F
- 19 *Ligg. chondrocoronalia.* Extend from Cartilago unguaris to Phalanx media. E
- 20 *Ligg. chondrosesamoidea.* Extend from Cartilago unguaris to Os sesamoideum distale. B C
- 21 *Ligg. chondroungularia collateralia.* Extend from Cartilago unguaris to the Processus palmaris of the same side (medial or lateral). B E
- 22 *Ligg. chondroungularia cruciata.* Extend from Cartilago unguaris of one side to that of the other side and to the opposite Processus palmaris. F



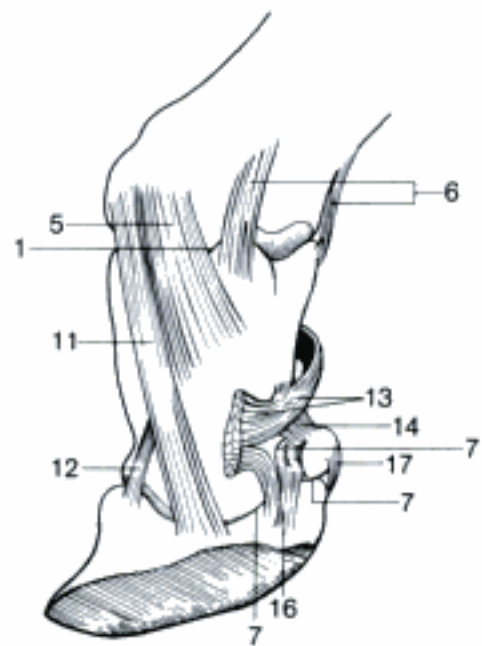
A Interphalangeal joints, sagittal section, right aspect (cq)



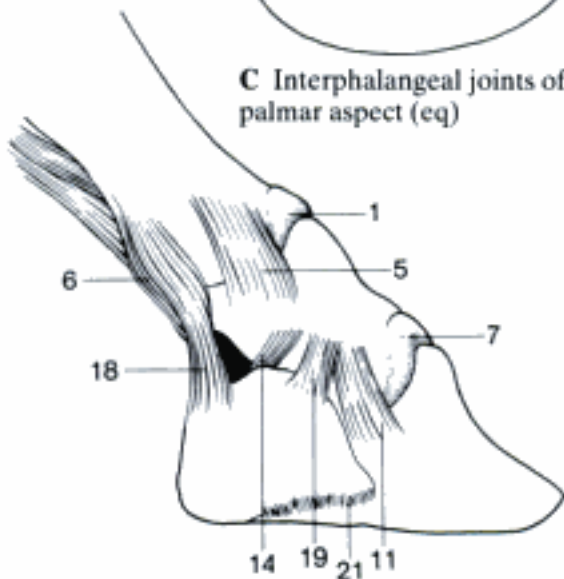
B Interphalangeal joints of right digit, dorsal aspect (cq)



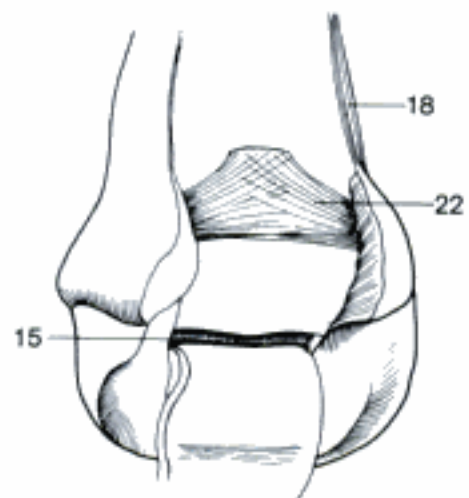
C Interphalangeal joints of right digit, palmar aspect (cq)



D Interphalangeal joints, axiopalmal aspect (bo)



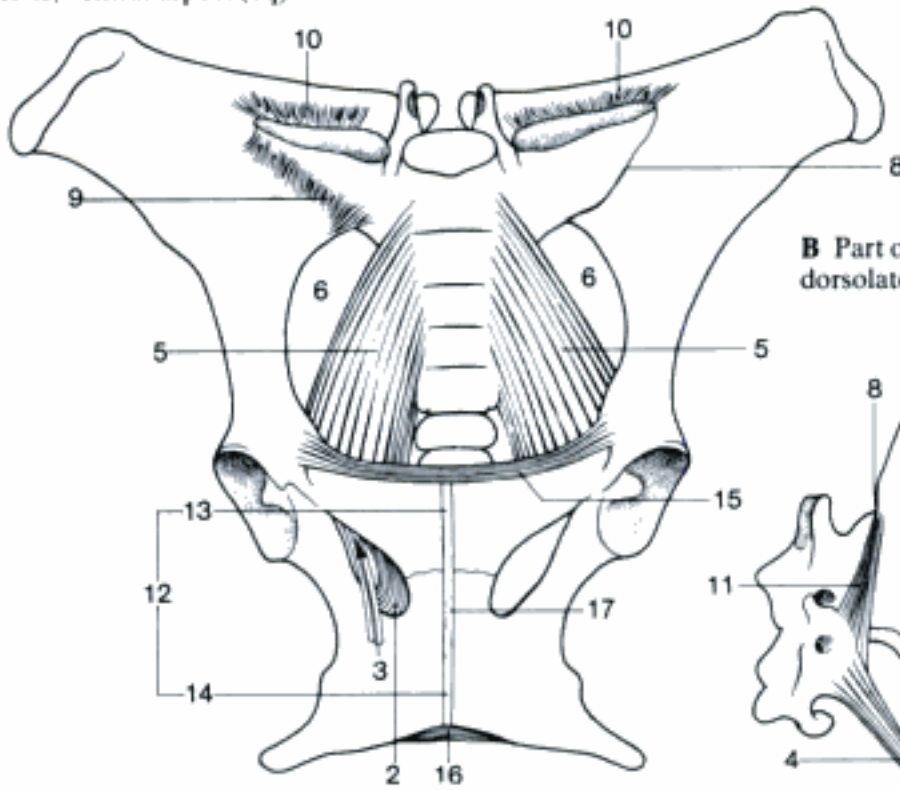
E Ligaments of right lateral hoof cartilage, lateral aspect (cq)



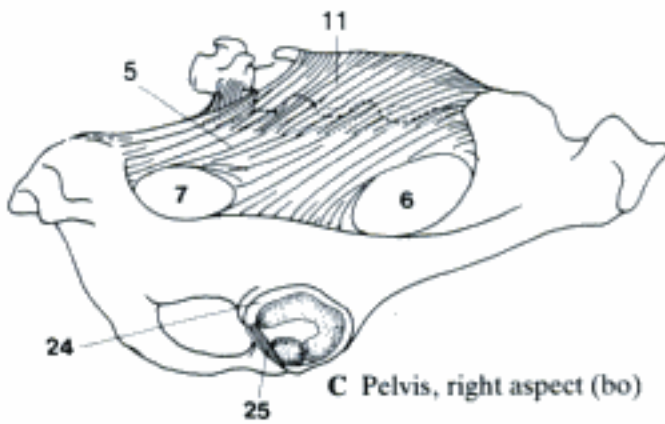
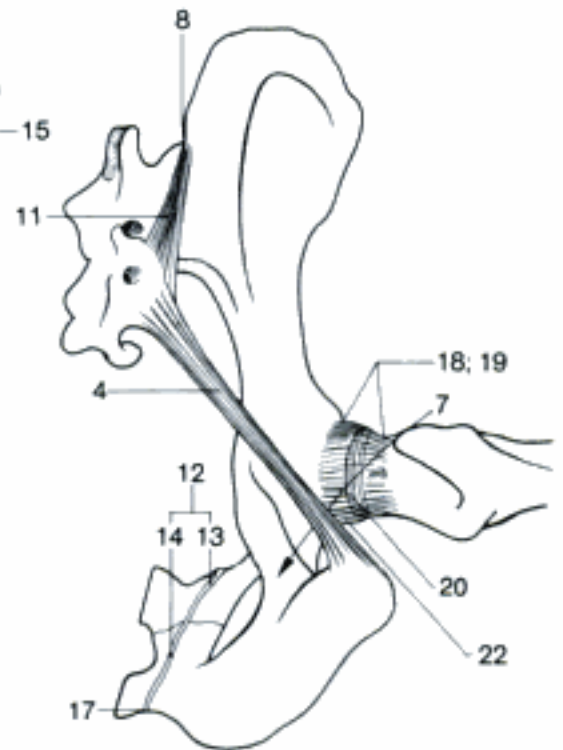
F Ligaments of right lateral hoof cartilage, medio-palmar aspect (cq)

- 1 **ARTICULATIONES MEMBRI PELVINI.** Joints of the pelvic limb.
- 2 *Membrana obturatoria.* Closes the Foramen obturatum in eq. A E
- 3 *Canalis obturatorius.* Canal for the obturator vessels and nerve in the craniolateral part of For. obturatum. A E
- 4 *Lig. sacrotuberale (ca).* Strong ligament from Os sacrum and first Vertebra caudalis to Tuber ischiadicum. B
- 5 *Lig. sacrotuberale latum.* Sacrosiatic ligament, from Os sacrum (Un) and first Vertebra caudalis (su, eq) to Spina ischiadica and Tuber ischiadicum. A C
- 6 *Foramen ischiadicum majus.* Greater sciatic foramen, between Incisura ischiadica major, Os sacrum and Lig. sacrotuberale latum in Un. A C
- 7 *Foramen ischiadicum minus.* Lesser sciatic foramen, between Incisura ischiadica minor and Lig. sacrotuberale (latum in Un). B C
- 8 **Articulatio sacroiliaca.** Sacroiliac joint. Between sacrum and ilium. A B
- 9 *Ligg. sacroiliaca ventralia.* Ventral fibrous lamina from Ala sacralis to Os ilium. A
- 10 *Ligg. sacroiliaca interossea.* Ligaments from Tuberositas sacralis to Tuberositas iliaca. A
- 11 *Ligg. sacroiliaca dorsalia.* Superficial dorsal fibrous structure between sacrum and ilium. B C
- 12 **Symphysis pelvina.** Pelvic symphysis, may gradually ossify earlier (eq) or later. A B E
- 13 *Symphysis pubica.* Pubic symphysis. A B E
- 14 *Symphysis ischiadica.* Ischiadic symphysis, does sometimes not ossify. A B E
- 15 *Lig. pubicum craniale.* Transverse fibers connecting right and left Pecten ossis pubis. A E
- 16 *Lig. arcuatum ischiadicum.* Transverse fibers in the Arcus ischiadicus. A E
- 17 *Lamina fibrocartilaginea intercoxalis.* Median fibrocartilaginous structure between right and left Os coxae. A B E
- 18 **Articulatio coxae.** Hip joint. Between Os coxae and Os femoris. B D E
- 19 *Capsula articularis.* Joint capsule. B D E
- 20 *Zona orbicularis.* Reinforcement in the dorsal part of the capsule, parallel to Margo acetabuli, especially in ca. B
- 21 *Lig. iliofemorale.* Reinforcement in the cranial part of the capsule. D
- 22 *Lig. ischiofemorale.* Reinforcement in the caudal part of the capsule in Car, esp. fe, and su. B
- 23 *Lig. pubofemorale.* Reinforcement in the ventral part of the capsule in su.
- 24 *Labrum acetabulare.* Acetabular labrum. Fibrocartilaginous rim enlarging the acetabulum. C E
- 25 *Lig. transversum acetabuli.* Bridges Incisura acetabuli. C E
- 26 *Lig. capitis ossis femoris.* Ligament of head of femur. Between Fossa acetabuli and Fovea capitis. Carries blood vessels. E
- 27 *Lig. accessorium ossis femoris (eq).* From Tendo prepubicus through Incisura acetabuli to Fovea capitis. E

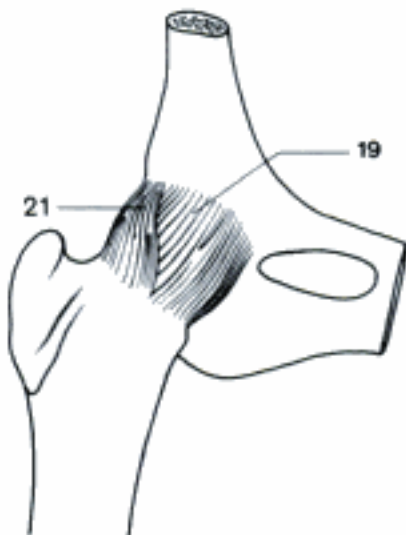
A Pelvis, ventral aspect (eq)



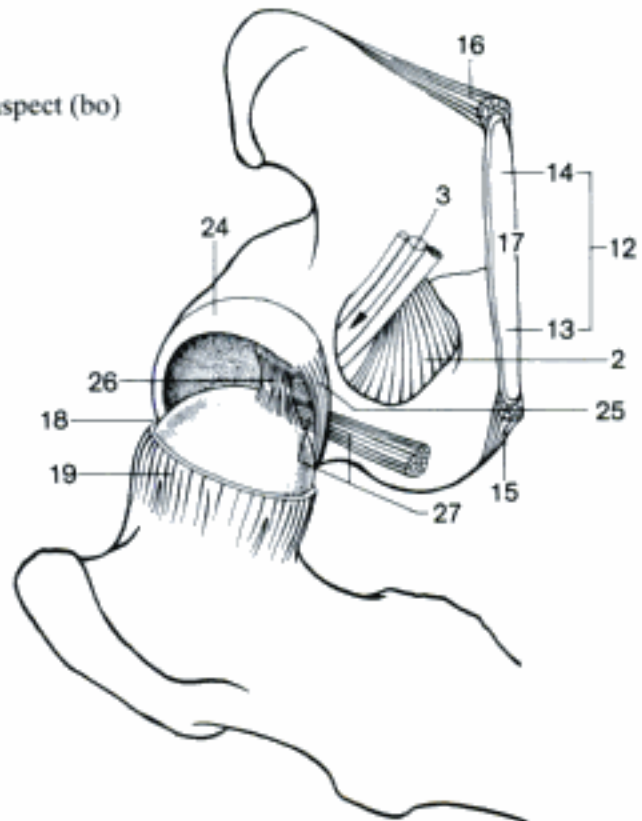
B Part of pelvis and right hip joint, dorsolateral aspect (ca)



C Pelvis, right aspect (bo)

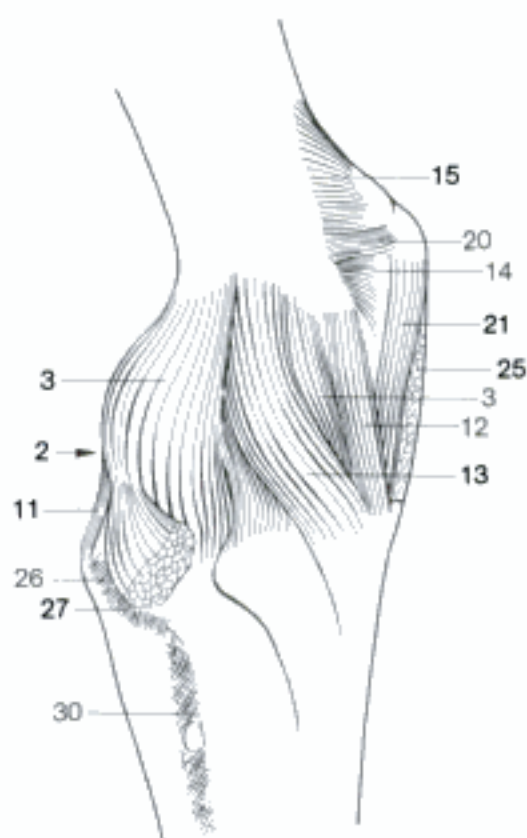


D Right hip joint, cranioventral aspect (ca)

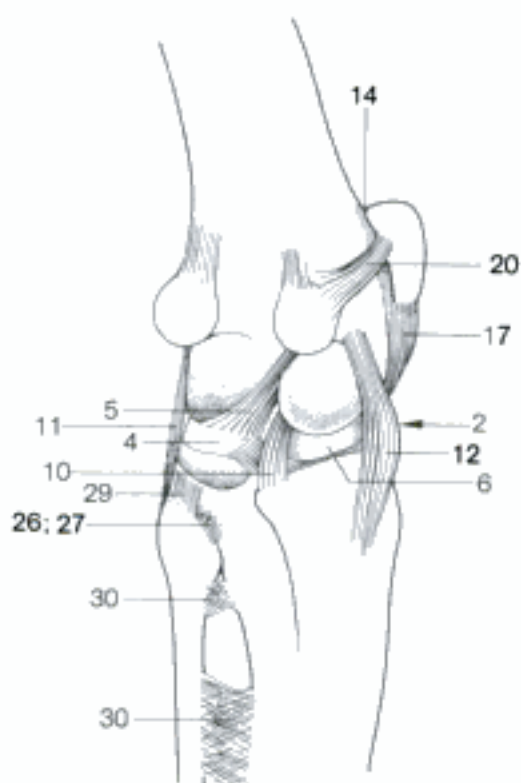


E Left hip joint (opened), caudoventral aspect (eq)

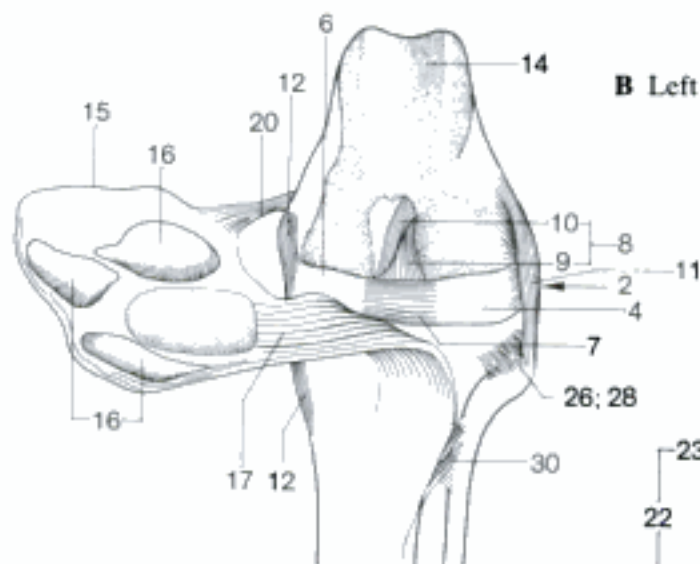
- 1 **Articulatio genus.** Stifle joint.
- 2 **Articulatio femorotibialis.** A B C D
- 3 *Capsula articularis.* Joint capsule. A
- 4 *Meniscus lateralis.* Semilunar fibrocartilage between the lateral condyles of femur and tibia. B C D
- 5 *Lig. meniscofemorale.* From Meniscus lateralis to the inner surface of the medial femoral condyle, caudal to Lig. cruciatum caudale. B
- 6 *Meniscus medialis.* Semilunar fibrocartilage between the medial condyles of femur and tibia. B C D
- 7 *Lig. transversum genus.* Transverse ligament of stifle, connects menisci cranially, especially in ca and su. C
- 8 *Ligg. cruciata genus.* Cruciate ligaments of stifle. C
- 9 *Lig. cruciatum craniale.* From the inner surface of Condylus lat. femoris to Area intercondylaris centralis tibiae. C
- 10 *Lig. cruciatum caudale.* From the inner surface of Condylus med. femoris to Area intercondylaris caud. tibiae. B C
- 11 *Lig. collaterale laterale.* From Epicondylus lat. femoris to Caput fibulae and tibia. A B C D
- 12 *Lig. collaterale mediale.* From Epicondylus med. fem. to tibia. A B C D
- 13 *Lig. popliteum obliquum.* Reinforcement of the caudal wall of the capsule running in lateroproximal-mediiodistal direction. A
- 14 **Articulatio femoropatellaris.** A B C D
- 15 *Capsula articularis.* Joint capsule. A C
- 16 *Fibrocartilagineae parapatellares.* Most developed in ca. C
- 17 *Lig. patellae.* Patellar ligament, from Apex patellae to Tuberositas tibiae. B C
- 18 *Lig. patellae intermedium.* Intermediate patellar ligament in bo and eq. D
- 19 *Retinaculum patellae mediale.* Reinforcement of the capsule medial to the patella, in bo and eq also in distal direction to Tuberositas tibiae. D
- 20 *Lig. femoropatellare mediale.* From medial border or Processus cartilagineus (bo, eq) of patella to femur or Os sesamoideum m. gastrocnemii (Car). A B C D
- 21 *Lig. patellae mediale.* Medial patellar ligament in bo and eq. A D
- 22 *Retinaculum patellae laterale.* Reinforcement of the capsule lateral to the patella, in bo and eq also in distal direction to Tuberositas tibiae. D
- 23 *Lig. femoropatellare laterale.* From lateral border of patella to femur or Os sesamoideum m. gastrocnemii (Car). D
- 24 *Lig. patellae laterale.* Lateral patellar ligament in bo and eq. D
- 25 *Corpus adiposum infrapatellare.* Infrapatellar fat pad, between Stratum fibrosum and Stratum synoviale of the capsule. A
- 26 **Articulatio tibiofibularis proximalis.** Joint between head of fibula and tibia, absent in Ru. A B C
- 27 *Capsula articularis.* Joint capsule. A
- 28 *Lig. capitis fibulae craniale.* Cranial ligament of fibular head to tibia. C
- 29 *Lig. capitis fibulae caudale.* Caudal ligament of fibular head to tibia. B
- 30 *Membrana interossea cruris.* Membrane connecting tibia and fibula. A B C



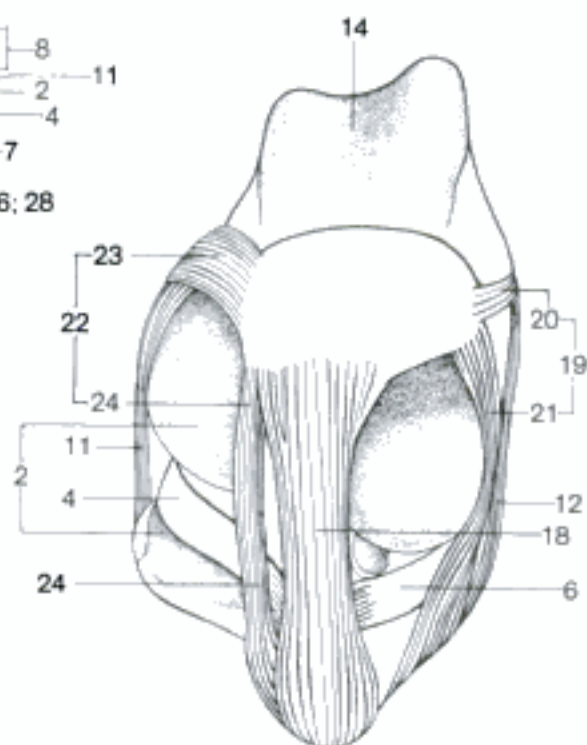
A Left stifle joint, mediocaudal aspect (eq)



B Left stifle joint (opened), mediocaudal aspect (ca)



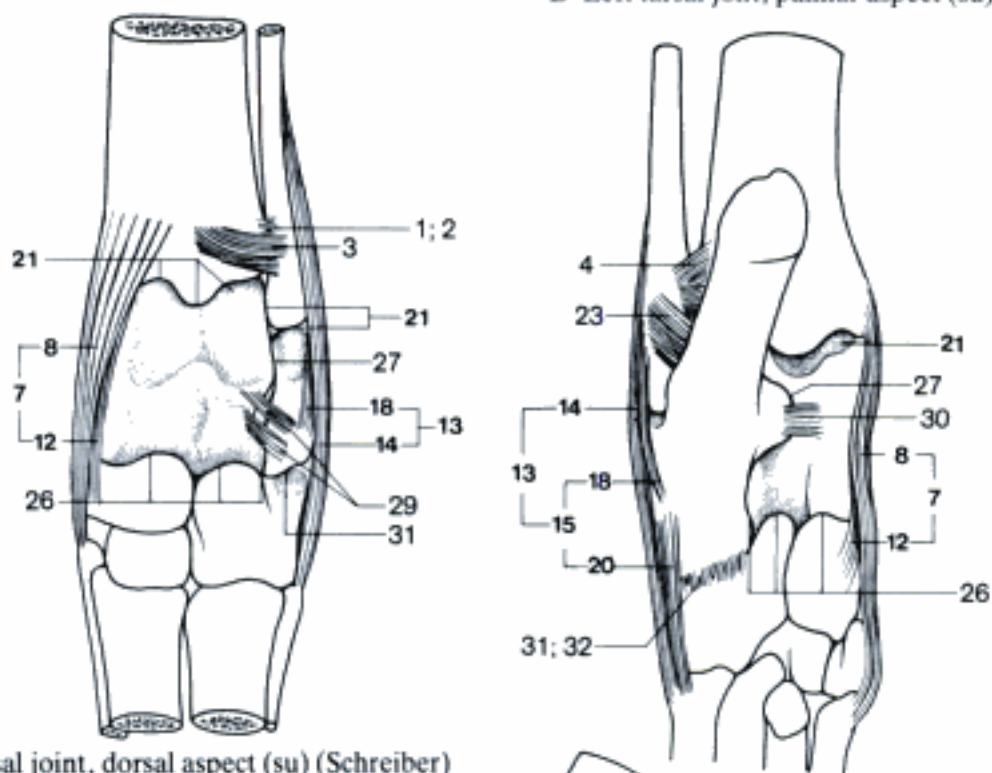
C Left stifle joint (opened), cranial aspect (ca)



D Right stifle joint (opened), cranial aspect (eq)

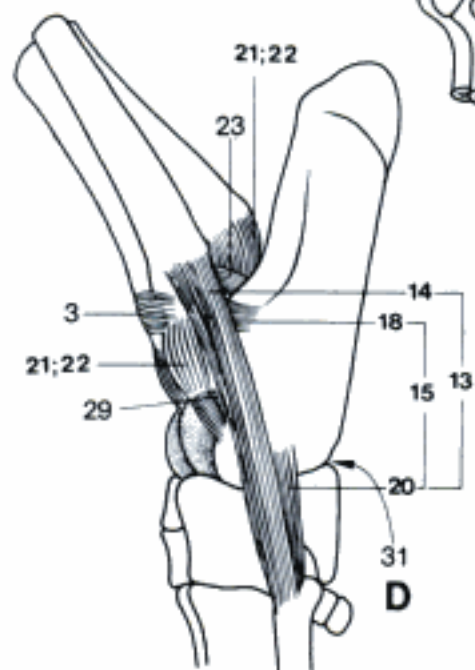
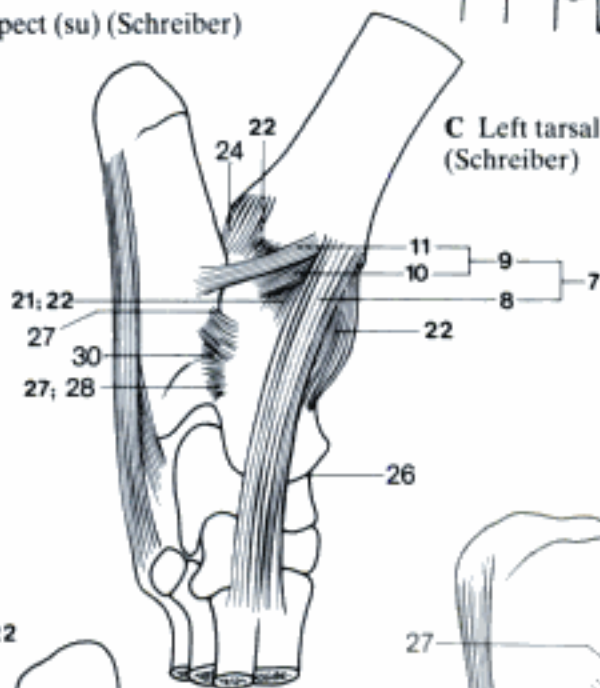
- 1 **Articulatio tibiofibularis distalis.** Distal joint between tibia and fibula, absent in eq. A
- 2 *Capsula articularis.* Joint capsule. A
- 3 *Lig. tibiofibulare craniale.* Cranial ligament between the distal ends of tibia and fibula. A D
- 4 *Lig. tibiofibulare caudale.* Caudal ligament between the distal ends of tibia and fibula. B
- 5 **Articulationes pedis.** Joints of the pes.
- 6 **Articulatio tarsi.** Tarsal joint, includes the joints between crural, tarsal and metatarsal bones. A B C D E
- 7 *Lig. collaterale tarsi mediale.* Consists of the following parts. A B C
- 8 *Lig. collaterale tarsi mediale longum.* Extends from the tibia to the distal tarsal bones and the metatarsus, in fe only to the Os tarsi centrale. A B C
- 9 *Lig. collaterale tarsi mediale breve.* Collective term for the short parts of the Lig. collaterale tarsi mediale. C
- 10 Pars tibiotalaris. Part connecting Malleolus tibiae and talus. C
- 11 Pars tibioalcalanea. Part connecting Malleolus tibiae and calcaneus. C
- 12 Pars tibiocentralis [tibionavicularis]. Part connecting Malleolus tibiae and Os tarsi centrale in su and Ru. A B
- 13 *Lig. collaterale tarsi laterale.* Consists of the following parts. A B D E
- 14 *Lig. collaterale tarsi laterale longum.* Extends from the fibula (in eq Malleolus lateralis of the tibia) to the Os tarsale IV and the metatarsus, in fe only to the calcaneus. A B D E
- 15 *Lig. collaterale tarsi laterale breve.* Collective term for the short parts of the Lig. collaterale tarsi laterale. B D E
- 16 Pars talofibularis. Part connecting Malleolus fibulae and talus in Car.
- 17 Pars tibiotalaris. Part connecting Malleolus lateralis tibiae and talus in eq. E
- 18 Pars calcaneofibularis. Part connecting Malleolus fibulae and calcaneus. A B D
- 19 Pars tibioalcalanea. Part connecting Malleolus lateralis tibiae and calcaneus in eq. E
- 20 Pars calcaneometatarsea. Part connecting calcaneus and metatarsus in Car and su, plantar to Lig. collaterale lat. longum. B D
- 21 **Articulatio tarsocruralis.** Most proximal joint of Articulatio tarsi, between tibia, fibula (except eq), talus and calcaneus (except eq). A B C D E
- 22 *Capsula articularis.* C D
- 23 *Lig. talofibulare plantare.* Short ligament from Malleolus fibulae to the plantar surface of the talus, absent in eq, strong in su and Ru. B D
- 24 *Lig. tibiotalaris plantare (su).* From Malleolus tibiae to the plantar surface of the talus. C
- 25 **Articulationes intertarseae.** Joints between tarsal bones.
- 26 **Articulatio talocalcaneocentralis [talocalcaneonavicularis].** Joint between talus, calcaneus and Os tarsi centrale [naviculare], in su and Ru also Os tarsale IV. A C E
- 27 **Articulatio talocalcanea.** Joint between talus and calcaneus. A B C E
- 28 *Capsula articularis.* C
- 29 *Lig. talocalcaneum laterale.* From talus to the lateral surface of the calcaneus, double in su. A D E
- 30 *Lig. talocalcaneum plantare.* From Sustentaculum tali to the plantar surface of the talus, absent in Ru, double in eq. B C
- 31 **Articulatio calcaneoquartalis [calcaneocuboidea].** Joint between calcaneus and Os tarsale quartum [cuboideum]. A B D E
- 32 *Capsula articularis.* B

B Left tarsal joint, palmar aspect (su) (Schreiber)

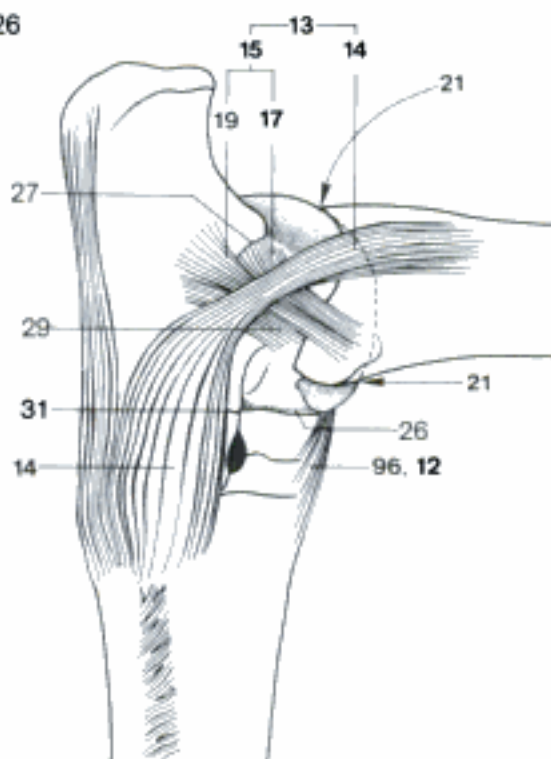


A Left tarsal joint, dorsal aspect (su) (Schreiber)

C Left tarsal joint, medial aspect (su) (Schreiber)



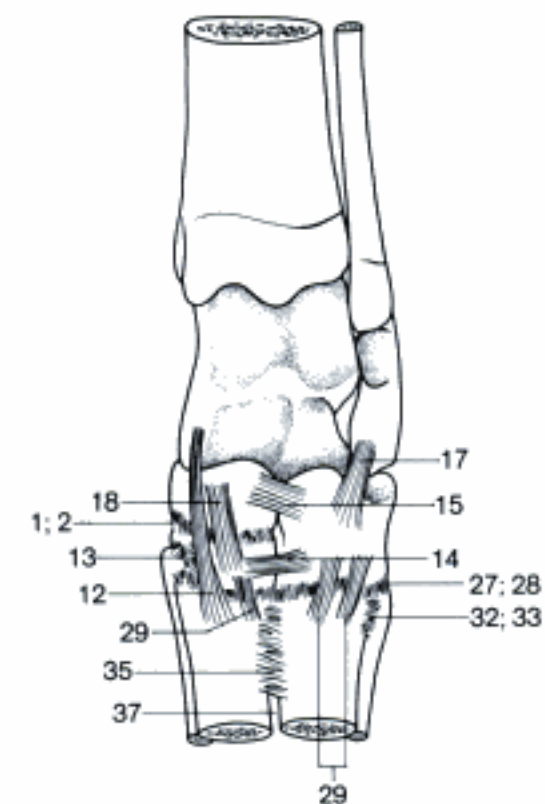
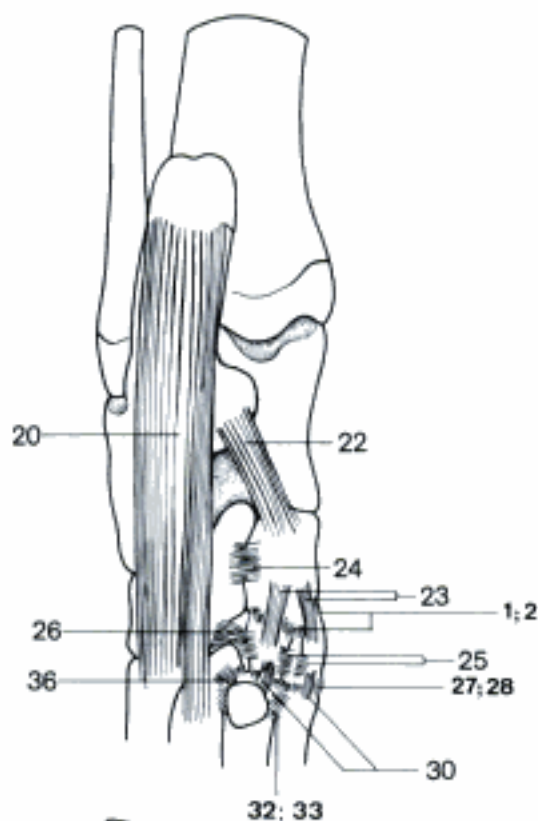
D Left tarsal joint, lateral aspect (su) (Schreiber)



E Right tarsal joint, lateral aspect (eq)

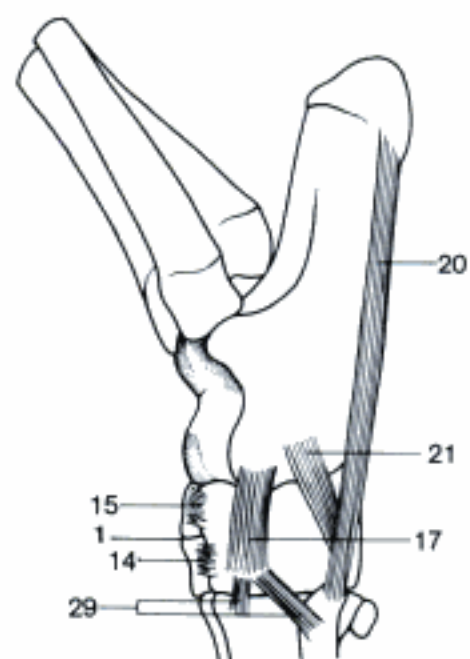
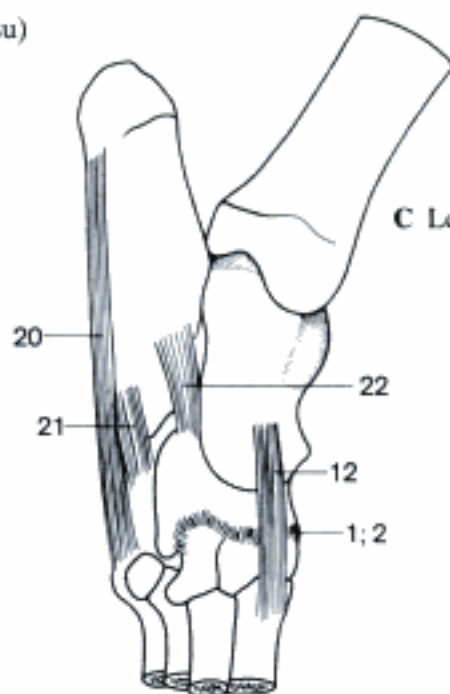
- 1 **Articulatio centrodistalis [cuneonavicularis]**. Joint between Os tarsi centrale and the distal tarsal bones. A B C D E
- 2 *Capsula articularis*. A B C E
- 3 *Ligg. tarsi interossea*.
- 4 *Lig. talocalcaneum interosseum*. Absent in su and Ru. E
- 5 *Lig. talocentrale [talonaviculare] interosseum* (eq). E
- 6 *Lig. centrodistale [cuneonaviculare] interosseum*. E
- 7 *Lig. calcaneoquartale [calcaneocuboideum] interosseum*. E
- 8 *Lig. centroquartale [cuboideonaviculare] interosseum*. E
- 9 *Lig. quartodistale [cuneocuboideum] interosseum*. E
- 10 *Ligg. interdistalia [intercuneiformia] interossea*. E
- 11 *Ligg. tarsi dorsalia*.
- 12 *Lig. talocentrodistometatarsium [talonaviculoconeometatarsium]*. From the medial surface of talus (Tuberculum in eq) in distodorsolateral direction, absent in Car. A C, 95 E
- 13 *Ligg. interdistalia [intercuneiformia] dorsalia*. A
- 14 *Lig. quartodistale [cuneocuboideum] dorsale*. A D
- 15 *Lig. centroquartale [cuboideonaviculare] dorsale*. A D
- 16 *Lig. calcaneocentrale [calcaneonaviculare] dorsale*.
- 17 *Lig. calcaneoquartale [calcaneocuboideum] dorsale*. A D
- 18 *Ligg. centrodistalia [cuneonavicularia] dorsalia* (Car). Occurs also in su. A
- 19 *Ligg. tarsi plantaria*.
- 20 *Lig. plantare longum*. On the plantar surface of calcaneus, Os tarsale IV, and metatarsus. B C D
- 21 *Lig. calcaneoquartale [calcaneocuboideum] plantare*. D
- 22 *Lig. calcaneocentrale [calcaneonaviculare] plantare*. B C
- 23 *Ligg. centrodistalia [cuneonavicularia] plantaria*. B
- 24 *Lig. centroquartale [cuboideonaviculare] plantare*. B
- 25 *Ligg. interdistalia [intercuneiformia] plantaria*. B
- 26 *Lig. quartodistale [cuneocuboideum] plantare*. B
- 27 **Articulationes tarsometatarseeae**. Joints between distal tarsal and metatarsal bones. A B E
- 28 *Capsulae articulares*. A B E
- 29 *Ligg. tarsometatarsea dorsalia*. A D
- 30 *Ligg. tarsometatarsea plantaria*. B
- 31 *Ligg. tarsometatarsea [cuneometatarsea] interossea*. E
- 32 **Articulationes intermetatarseeae**. Joints between the bases of the metatarsal bones. A B E
- 33 *Capsulae articulares*. A B
- 34 *Ligg. metatarsea interossea*. Fibers between the bases of the metatarsal bones. E
- 35 *Ligg. metatarsea dorsalia*. Dorsal fibers between the bases of the metatarsal bones. A
- 36 *Ligg. metatarseea plantaria*. Plantar fibers between the bases of the metatarsal bones. B
- 37 *Spatia interossea metatarsi*. Spaces between the metatarsal bones. A
- 38 **Articulationes metatarsophalangeae**. Vide Art. metacarpophalangeae, but Recessus plantares, Ligg. plantaria, Lig. metatarsointersesamoideum, and Lig. metatarsium transversum profundum.
- 39 **Articulationes interphalangeae pedis**. Vide Art. interphalangeae manus, but Recessus plantares and Ligg. plantaria.

B Left tarsal joint, palmar aspect (su)

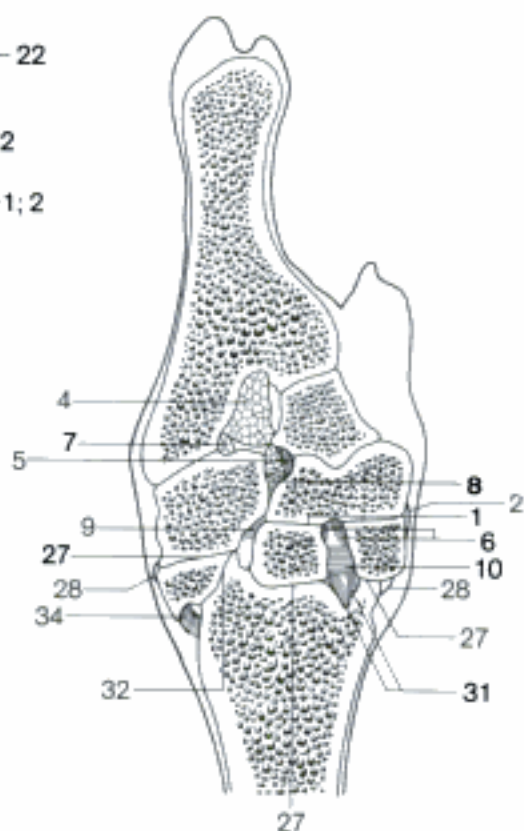


A Left tarsal joint, dorsal aspect (su)

C Left tarsal joint, medial aspect (su)

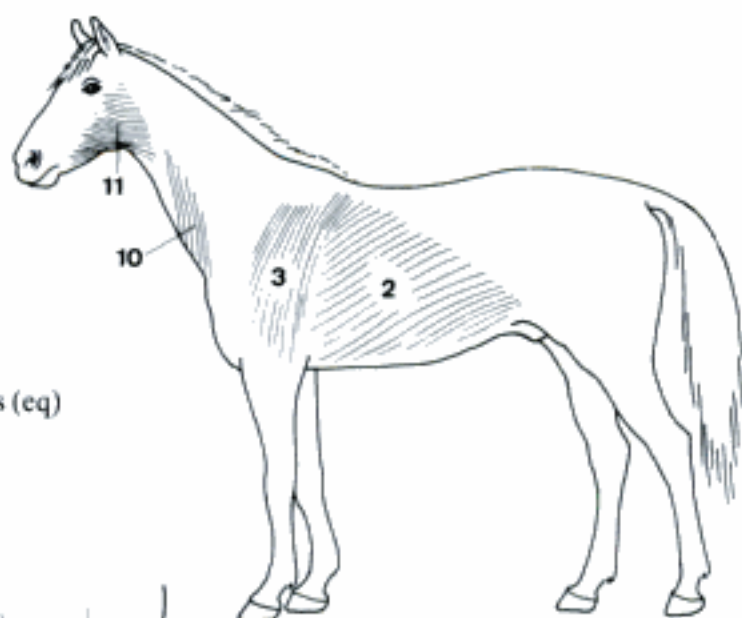


D Left tarsal joint, lateral aspect (su)

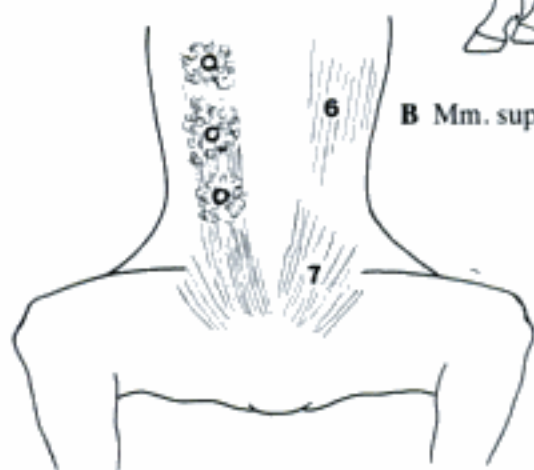


E Right tarsal joint, dorsal section, dorsal aspect (eq)

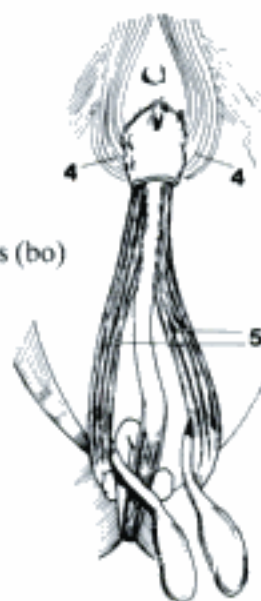
- 1 **MUSCULI CUTANEI.** Muscles located in specific regions of body moving the skin.
- 2 *M. cutaneus trunci.* Covers lateral part of trunk caudal to shoulder and arm. Forms fold of flank. Dips medial to arm with *M. pectoralis profundus.* A
- 3 *M. cutaneus omobrachialis.* Continuation of *M. cutaneus trunci* in Ru and eq lateral to shoulder and arm. May be separated from *M. cutaneus trunci* in bo. A
- 4 *M. preputialis [prae-] cranialis.* Forms ring around Ostium preputiale. C
- 5 *M. preputialis [prae-] caudalis.* Along penis in preputial wall caudal to ostium in Ru, sometimes in su. C
- 6 *M. supramammarius cranialis* (Car). Slip associated with ventral edge of *M. cutaneus trunci.* Passes deep to mammary glands. B
- 7 *M. supramammarius caudalis* (Car). Fibers in inguinal region deep to and between mammary glands. B
- 8 *M. sphincter colli superficialis.* Transverse fibers ventral in neck from sternum to mandible in Car, rudimentary in su. D
- 9 *Platysma.* From nuchal area to Angulus oris in Car and su. D
- 10 *M. cutaneus colli.* Ventral in neck lying obliquely over Sulcus jugularis, in Un. A
- 11 *M. cutaneus faciei.* Continuation of *M. cutaneus colli* to Regio masseterica in Ru and eq, part of *platysma* in Car and su. A
- 12 *M. sphincter colli profundus.* Deep to *platysma,* ventral to ear in masseteric and parotid regions, in Car. D
- 13 **MUSCULI CAPITIS.** Muscles of head.
- 14 *M. rectus capitis ventralis.* From Arcus ventralis atlantis to Pars basilaris ossis occipitalis. Flexes atlantooccipital joint. E
- 15 *M. rectus capitis dorsalis major.* Dorsal to atlantoaxial articulation and atlas. From Processus spinosus axis to Squama occipitalis. Extends atlanto-occipital articulation. E
- 16 *M. rectus capitis dorsalis minor.* Deep to proceeding muscle. From Tuberculum dorsale atlantis to Squama occipitalis. Extends atlanto-occipital articulation. E
- 17 *M. rectus capitis lateralis.* From lateral part of Arcus ventralis atlantis to Processus paracondylaris. Flexes atlantooccipital joint laterally and ventrally. E
- 18 *M. obliquus capitis cranialis.* Fibers run obliquely craniomedially dorsal to atlantooccipital articulation from cranial edge of Ala atlantis to Squama occipitalis. Extends and flexes laterally atlantooccipital articulation. E
- 19 *M. obliquus capitis caudalis.* Fibers run obliquely craniolaterally dorsal to atlas and axis from Processus spinosus and articularis caud. of axis to dorsal surface of Ala atlantis. Rotates atlantoaxial joint. E
- 20 *M. splenius capitis.* Cranial continuation of *M. splenius cervicis.* Fibers run craniolaterally to insert on Squama occipitalis. Elevates head. F
- 21 *M. longus capitis.* Lies ventrolaterally along cervical transverse processes. From Processus transversi of cervical vertebrae 3–6 to cranial portion of Pars basilaris ossis occipitalis. Flexes head and neck. E F



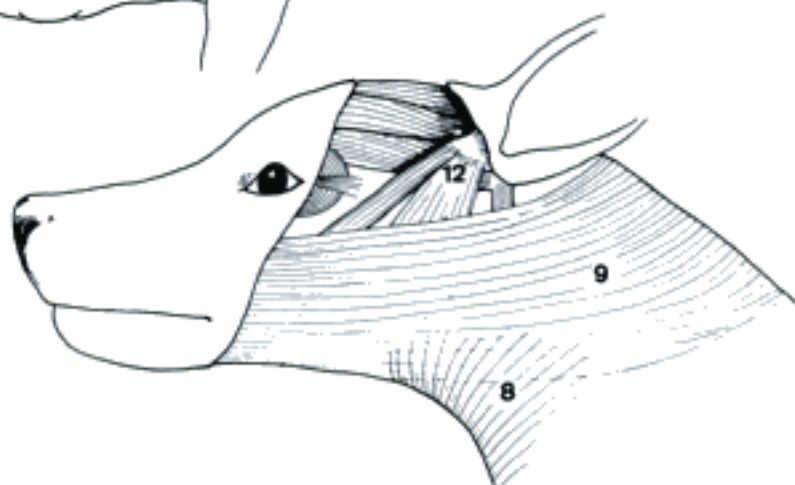A Cutaneous muscles (eq)



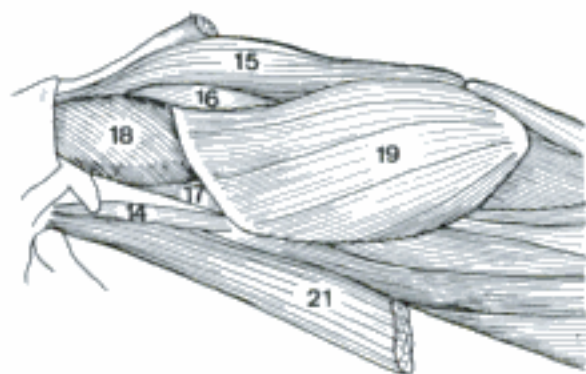
B Mm. supramammarii (fe)



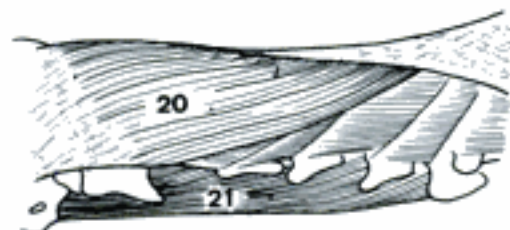
C Mm. preputiales (bo)



D Cutaneous muscles of head and neck (ca)

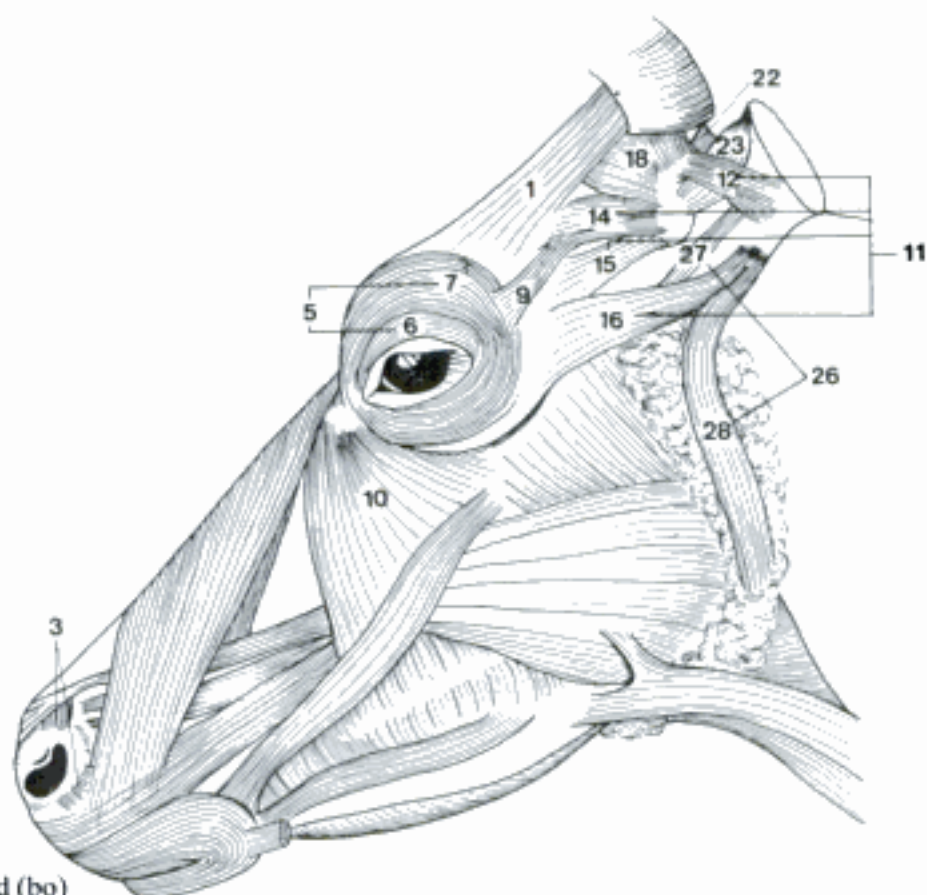


E Deep muscles of the head-neck junction (eq)

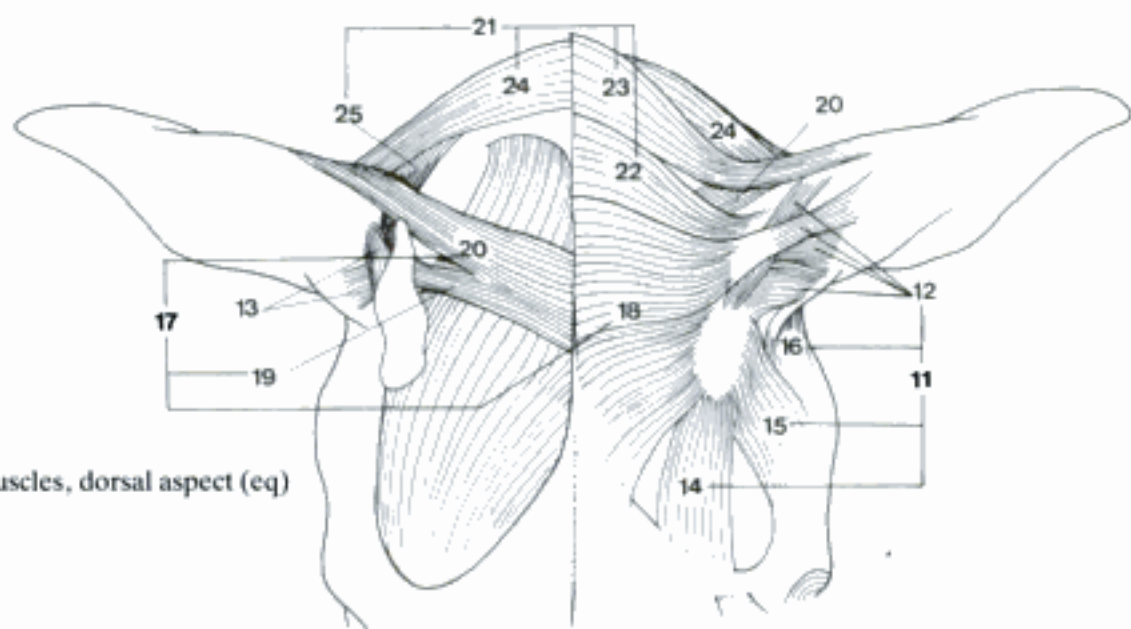


F M. splenius and M. longus capitis (ca)

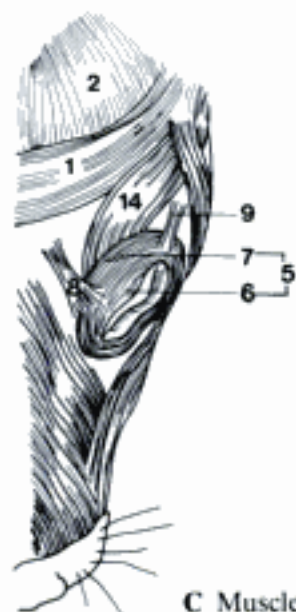
- 1 *M. frontalis*. Cutaneous muscle which lies over frontal bone and *M. temporalis* in Car, su, and Ru. A C
- 2 *M. occipitalis*. Lies in Car over occipital and parietal bone and *M. temporalis*, partly covered by *M. interscutularis*. C
- 3 *M. lateralis nasi*. Small fiber groups ventral and dorsal along Incisura nasomaxillaris and caudal portion of nostril in Ru and eq. Assists in dilating nostril. A D
- 4 *M. dilatator naris apicalis*. Transverse fibers from median line to nostril in Ru and eq. Dilates nostril. D
- 5 *M. orbicularis oculi*. Sphincter of eyelids. A C
- 6 *Pars palpebralis*. Part within eyelid. A C
- 7 *Pars orbitalis*. Part encroaching upon orbit. A C
- 8 *M. levator anguli oculi medialis*. Rostrolaterally directed from frontal bone to medial portion of upper eyelid. Lifts medial portion of upper eyelid. C
- 9 *M. retractor anguli oculi lateralis*. From Fascia temporalis (Car) to lateral ocular angle, in bo continuation of *M. frontoscutularis*. A C
- 10 *M. malaris*. Cutaneous fibers directed ventrally from region of medial ocular angle. A
- 11 *Mm. auriculares rostrales*. From skull rostral to ear. Cartilago scutiformis is in midst of group. A B
- 12 *Mm. scutuloauriculares superficiales*. Several muscles forming superficial group from Cartilago scutiformis to Concha auriculae. Turn Incisura intertragica rostrally. A B
- 13 *Mm. scutuloauriculares profundi*. Major and minor muscles from ventral surface of Cartilago scutiformis to Eminentia conchae. Turn Incisura intertragica caudally. B
- 14 *M. frontoscutularis*. From Linea temporalis in caudal direction to Cartilago scutiformis. Pulls Cartilago scutiformis rostrally. A B C
- 15 *M. zygomaticoscutularis*. Lateral to the preceding muscle. From Processus zygomaticus ossis frontalis to Cartilago scutiformis. Pulls Cartilago scutiformis rostrally. A B
- 16 *M. zygomaticoauricularis*. From Arcus zygomaticus to Concha auriculae. Turns Incisura intertragica rostrally. A B
- 17 *Mm. auriculares dorsales*. From dorsal median line to Cartilago scutiformis or Concha auriculae. B
- 18 *M. interscutularis*. Transverse fibers from dorsal median line (Car, eq), Linea temporalis (su, Ru, eq) to Cartilago scutiformis. B
- 19 *M. parietoscutularis*. Deep to *Mm. inter- et cervicoscutularis*. Detaches from *M. parietoauricularis* to insert on Cartilago scutiformis. B
- 20 *M. parietoauricularis*. Strap-like. Deep to *Mm. inter- et cervicoscutularis*. From parietal bone to Concha auriculae. Raises concha. B
- 21 *Mm. auriculares caudales*. From Nucha to Cartilago scutiformis or Concha auriculae. B
- 22 *M. cervicoscutularis*. Caudal to *M. interscutularis* from Linea temporalis to caudal portion of Cartilago scutiformis. A B
- 23 *M. cervicoauricularis superficialis*. Strap-like. From Crista nuchae or Fasciculus nuchae (Ru) to Concha auriculae. Raises concha. A B
- 24 *M. cervicoauricularis medius*. Caudal and deep to preceding muscle. Turns Incisura intertragica laterally. B
- 25 *M. cervicoauricularis profundus*. Deep to preceding muscle. Turns Incisura intertragica laterally. B
- 26 *Mm. auriculares ventrales*. In parotid region. Depress Concha auriculae. A
- 27 *M. styloauricularis*. Slips over Meatus acusticus ext. cartilagineus. Courses from Mandibula or Pars tympanica ossis temporalis to Concha auriculae. A
- 28 *M. parotidoauricularis [parotideo-]*. Runs dorsally over Gl. parotis to Concha auriculae. A



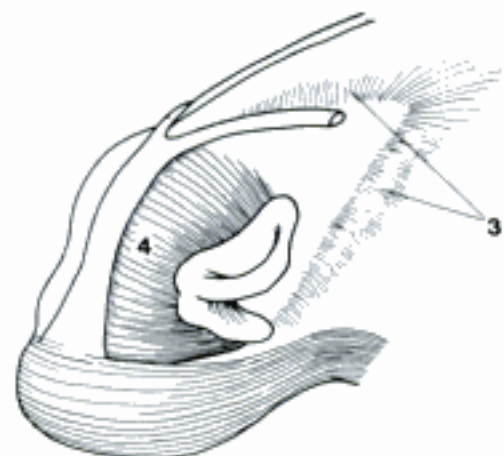
A Muscles of the head (bo)



B Auricular muscles, dorsal aspect (eq)

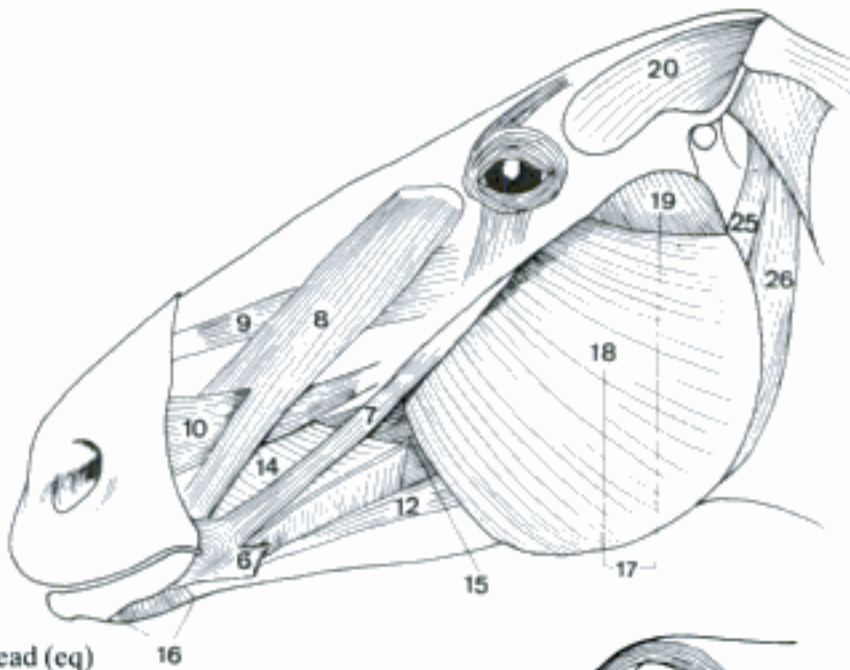


C Muscles of the head, dorsal aspect (ca)

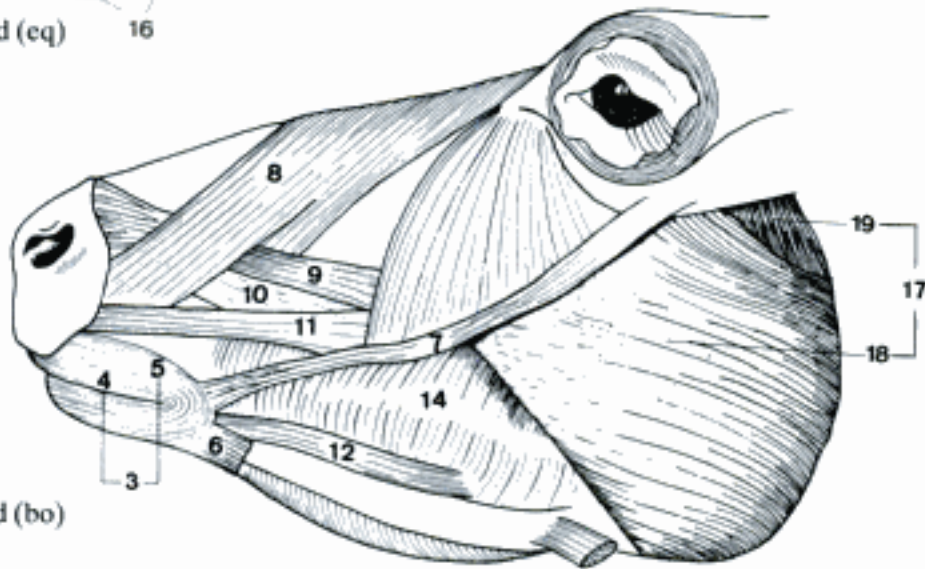


D Muscles of the nose, rostralateral aspect (eq)

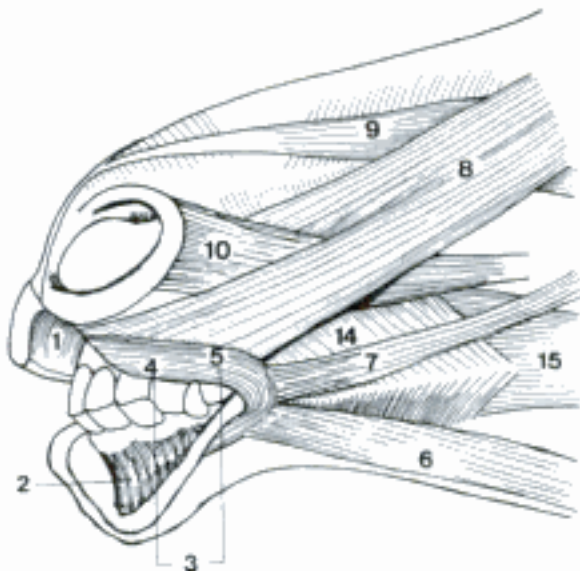
- 1 *M. incisivus superior*. Radiating fibers in upper lip. Raises upper lip. C
- 2 *M. incisivus inferior*. Radiating fibers in lower lip. Depresses lower lip. C
- 3 *M. orbicularis oris*. Sphincter of mouth. B C
- 4 *Pars marginalis*. Part near Rima oris. B C
- 5 *Pars labialis*. Main part within lips. B C
- 6 *M. depressor anguli oris*. Part of Platysma (*M. cutaneus faciei*) at angle of mouth. A B C
- 7 *M. zygomaticus*. Strap-like muscle running from area of Crista facialis (Un) or Cartilago scutiformis (Car) to angle of mouth deep to Platysma. Retracts angle of mouth. A B C
- 8 *M. levator nasolabialis*. Flat muscle arising rostral to Orbita, inserting in upper lip and nostril. Raises upper lip and dilates nostril. A B C
- 9 *M. levator labii superioris*. Arises ventral to preceding muscle and courses rostrally deep to it. In eq tendon joints that of other side to insert in upper lip. In other species tendon spreads out and attaches also to Ala nasi lat. Raises upper lip. A B C
- 10 *M. caninus*. Ventral to preceding muscle. Perforates *M. levator nasolabialis* or is deep to its labial portion. Inserts on upper lip in Car, nostril in eq, both in su and Ru. Dilates nostril and raises upper lip. A B C
- 11 *M. depressor labii superioris*. Arises with but lies ventral to preceding muscle. Inserts with *M. orbicularis oris*. Not a separate muscle in Car and eq. B
- 12 *M. depressor labii inferioris*. Lies along Corpus mandibulae to insert in lower lip. Not present in Car. A B
- 13 *M. buccinator*. Muscle of cheek. A B C
- 14 *Pars buccalis*. Attaches along molar areas of maxilla and mandible. Fibers pass toward each other to form raphe of insertion. A B C
- 15 *Pars molaris*. Deep to preceding part. Longitudinal fibers which extend caudally on to Ramus mandibulae. A C
- 16 *M. mentalis*. From lateral part of Corpus mandibulae to lower lip. Stiffens lower lip. A
- 17 *M. masseter*. Large lateral muscle of mastication. A B
- 18 *Pars superficialis*. From zygomatic arch to insert on caudal and ventral portion of mandible. Fibers course ventrocaudally. A B
- 19 *Pars profunda*. Smaller, deeper portion. Fibers more vertical. A B
- 20 *M. temporalis*. Occupies entire Fossa temporalis from which it originates. Fibers converge to insert on Processus coronoideus mandibulae. Raises mandible to close mouth. A
- 21 *M. pterygoideus lateralis*. Smallest muscle of mastication. From Crista pterygoidea to Fovea pterygoidea mandibulae and Discus articularis. Draws mandible rostrally. D
- 22 *M. pterygoideus medialis*. Large medial muscle of mastication. From pterygoid, basisphenoid, palatine bones and Fossa pterygopalatina to Fossa pterygoidea mandibulae. D
- 23 *M. digastricus*. Two-bellied muscle which opens jaws. From Processus paracondylaris to Pars molaris of Corpus mandibulae. Tendon occurs between two bellies, in Car intermediate tendon is represented by tendinous intersection. D
- 24 *Venter rostralis*. Rostral belly, from intermediate tendon to mandible. D
- 25 *Venter caudalis*. Caudal belly, from Processus paracondylaris to intermediate tendon. A D
- 26 *Pars occipitomandibularis*. Detaches from Venter caudalis and inserts on Ramus mandibulae in eq. A D



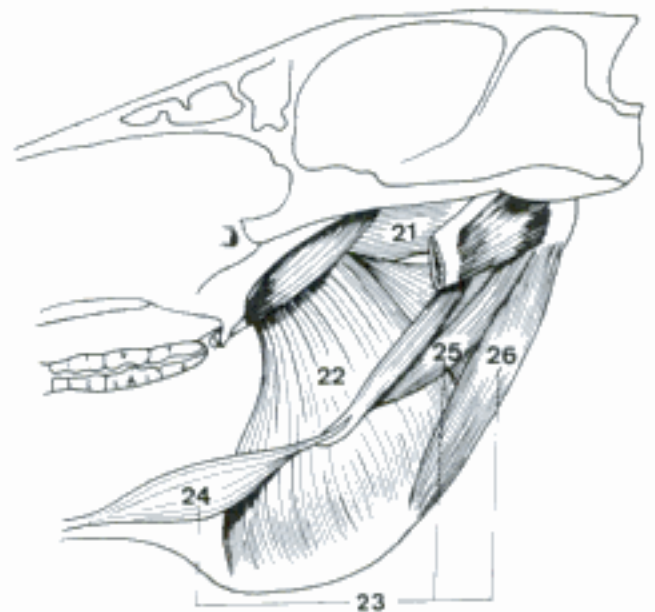
A Muscles of the head (eq) 16



B Muscles of the head (bo)

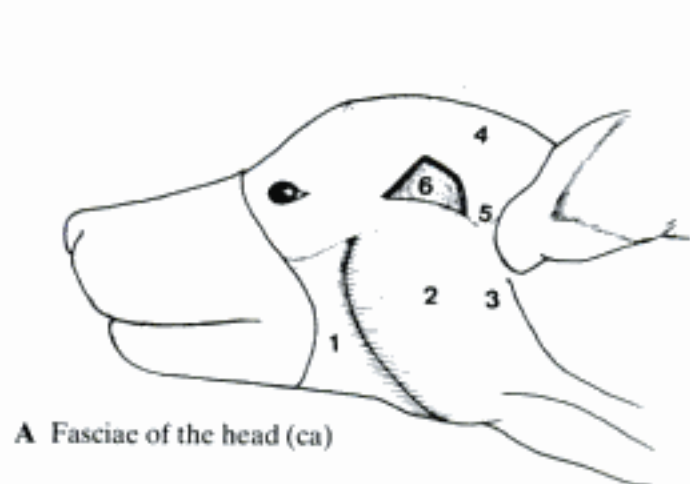


C Rostral muscles of the head (eq)

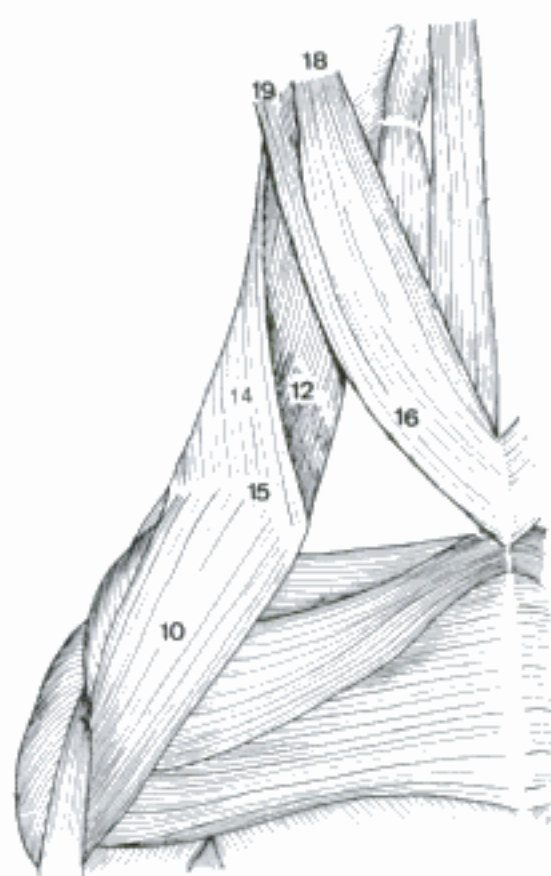


D Right medial muscles of mastication, medial aspect (eq)

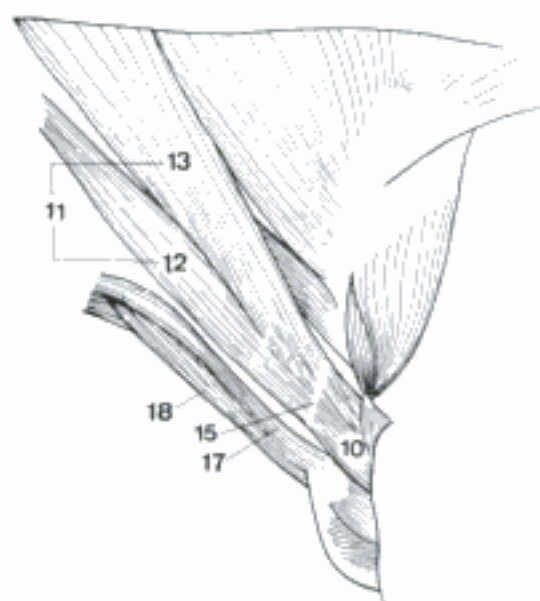
- 1 *Fascia buccopharyngea*. Lies on M. buccinator and continues over mandible to Mm. constrictores pharyngis. A
- 2 *Fascia masseterica*. Covers M. masseter. A
- 3 *Fascia parotidea*. Continues from Fascia masseterica to cover parotid region. A
- 4 *Fascia temporalis*. Covers M. temporalis. A
- 5 *Lamina superficialis*. Spreads over zygomatic arch to join Fascia parotidea. A
- 6 *Lamina profunda*. Attaches ventrally to zygomatic arch. A
- 7 **MUSCULI COLLI**. Muscles primarily in neck plus those associated with hyoid apparatus.
- 8 *M. splenius cervicis*. Continuous with M. splenius capitis, absent in Car. Inserts on transverse processes of cervical vertebrae after arising from Ligamentum nuchae and Fascia thoracolumbalis. Extends neck and draws it laterally. E
- 9 *M. brachiocephalicus*. Parts radiate from Intersectio clavicularis. Extends shoulder joint, pulls head and neck laterally and ventrally. B C E
- 10 *M. cleidobrachialis* [*Pars clavicularis m. deltoidei*]. Lies on cranial surface of arm. From Intersectio clavicularis to Crista humeri. B C E
- 11 *M. cleidocephalicus*. Lies on lateral surface of neck. From Intersectio clavicularis to parts of head (and neck in Car). B C
- 12 Pars mastoidea. Ventral part of M. cleidocephalicus from intersection to mastoid process. B C
- 13 Pars occipitalis (su, Ru). Dorsal part. To Crista nuchae (su), Linea nuchae and Lig. nuchae (Ru). C
- 14 Pars cervicalis (Car). Dorsal part. To dorsal fibrous raphe of cranial portion of neck. B
- 15 *Intersectio clavicularis*. Between M. cleidobrachialis and M. cleidocephalicus, cranial to shoulder joint, difficult to demonstrate in bo and eq. Clavicula is present in fe. B C
- 16 *M. sternocephalicus*. From sternum to Ramus mandibulae in eq, to mastoid process in su and ov, consists of two parts in other species. Flexes head and neck. B C E
- 17 *Pars mandibularis* (bo, cap). Inserts on Fascia masseterica, in bo also on Corpus mandibulae. C
- 18 *Pars mastoidea* (Car, bo, cap). Deep or ventral part. Inserts on mastoid process. B C
- 19 *Pars occipitalis* (Car). Dorsal part. Inserts on occipital bone. B
- 20 *M. longus colli*. Many bundles which lie ventral to vertebral column in cervical and cranial thoracic parts. Flexes neck. D
- 21 *M. scalenus ventralis*. From transverse processes of C3–C6 (su also C1 and C2) to the middle portion of first rib. D
- 22 *M. scalenus medius*. From transverse processes of C6 and C7 to the dorsal portion of first rib. D
- 23 *M. scalenus dorsalis*. Lateral to M. scalenus medius, the dorsal portion of M. scalenus ventralis, and the cranial ribs. Absent in eq and mostly in ov. From transverse processes of (C2, C3) C4–C6 to ribs 2–4, in Car additionally to ribs 8 or 9. Scaleni are inspiratory and flex neck. D



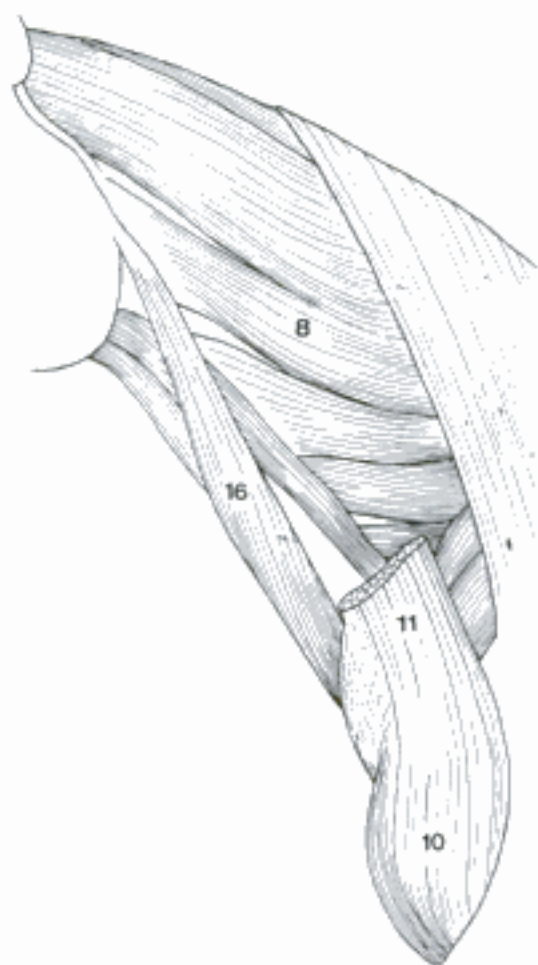
A Fasciae of the head (ca)



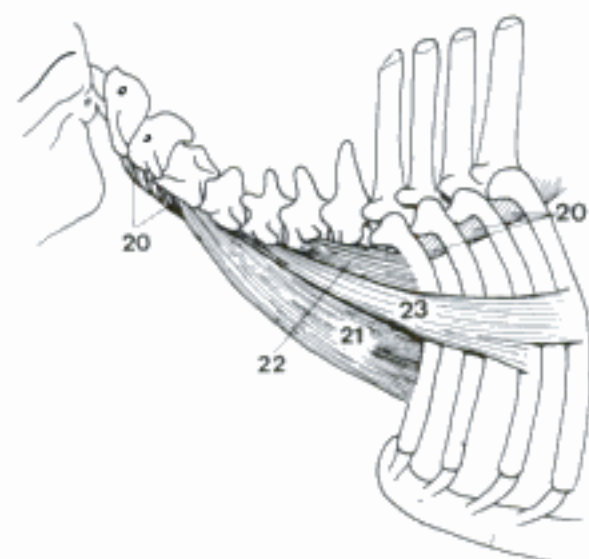
B Right M. brachiocephalicus and M. sternocephalicus, ventral aspect (ca)



C M. brachiocephalicus and M. sternocephalicus (bo)

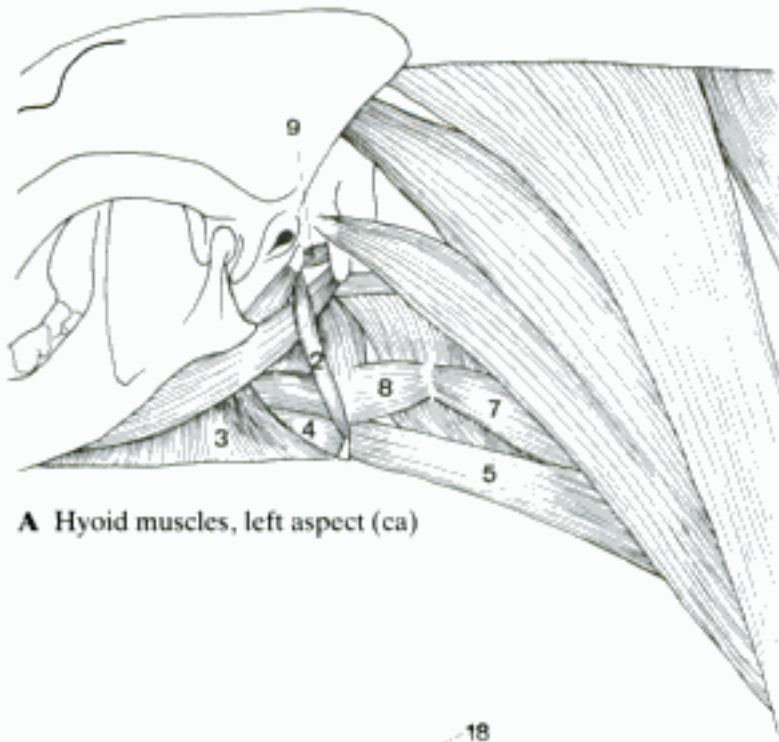


E Muscles of the neck, left aspect (bo)



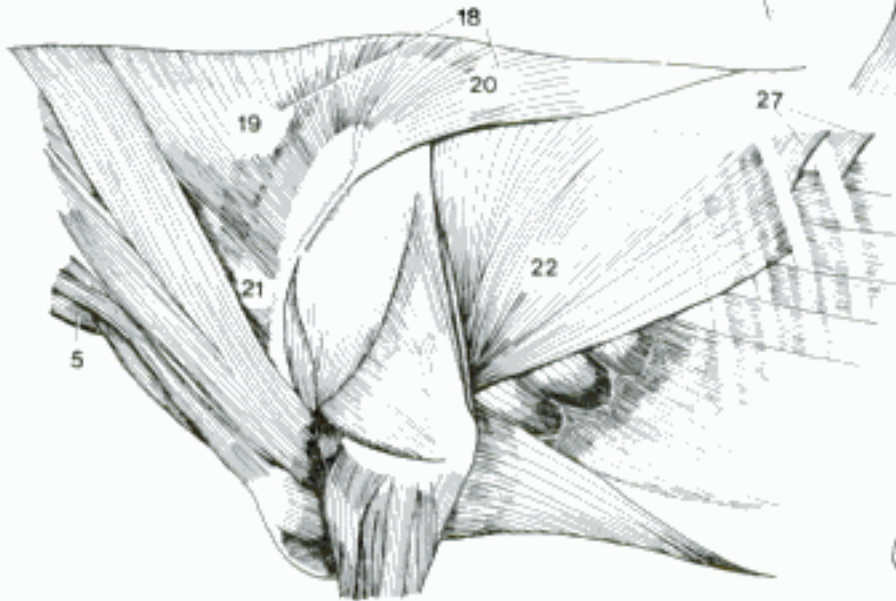
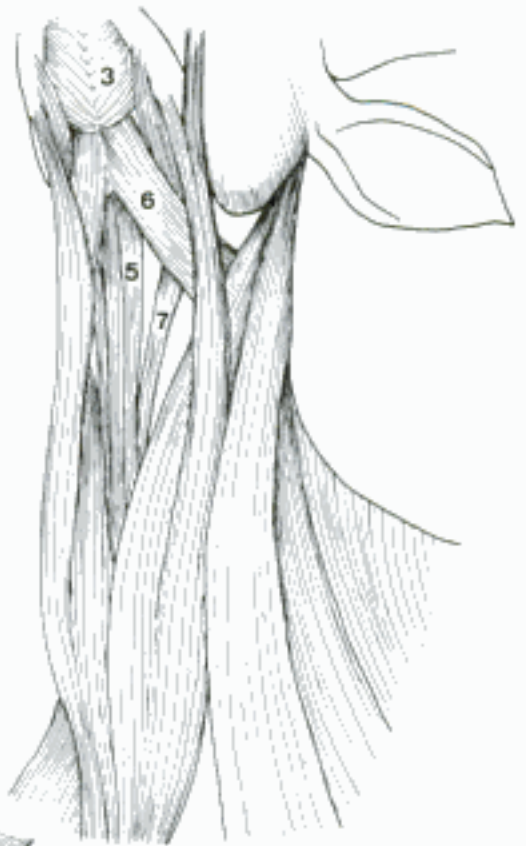D Deep muscles of the neck, left aspect (bo)

- 1 **Mm. hyoidei.** Muscles associated with hyoid apparatus. A B D
- 2 *M. stylohyoideus.* Small muscle from stylohyoid to basihyoid, superficial to *M. digastricus*. Raises basihyoid. A D
- 3 *M. mylohyoideus.* Transverse fibers throughout intermandibular space. From Linea mylohyoidea of mandible to median raphe and basihyoid. Raises floor of oral cavity. A B
- 4 *M. geniohyoideus.* Deep to preceding muscle. From the rostromedial end of the body of mandible to basihyoid. Draws hyoid rostrally. A
- 5 *M. sternohyoideus.* From Manubrium sterni to basihyoid. Pulls basihyoid caudally. A B C
- 6 *M. omohyoideus.* From subscapular fascia in su and eq, from fascia lateral to middle cervical vertebrae in Ru, passing obliquely, deep to *V. jugularis externa*, to basihyoid. Retracts hyoid. B
- 7 *M. sternothyroideus [-thyreoideus].* With and lateral to *M. sternohyoideus*. To thyroid cartilage. Draws larynx caudally. A B
- 8 *M. thyrohyoideus [thyreo-].* Short flat muscle from insertion of *M. sternothyroideus* to thyrohyoid. Draws hyoid caudally and larynx rostrally. A
- 9 *M. occipitohyoideus.* Small muscle from paracondylar process to stylohyoid. Moves stylohyoid caudally. A
- 10 *M. ceratohyoideus.* Fills triangle between thyro- and ceratohyoids. Reduces angle. D
- 11 *M. hyoideus transversus.* Small unpaired band between cerato- or epihyoids. D
- 12 **Fascia cervicalis.** Fascia of neck. Collective term for connective tissue layers of neck. E
- 13 *Lamina superficialis.* From parotid to brachial fascia, deep to cutaneous muscles. Encloses *Mm. sterno-, cleidocephalicus,* and *trapezius*. E
- 14 *Lamina pretrachealis [prae-].* Layer ventral to trachea. Encloses the caudal hyoid muscles. E
- 15 *Lamina prevertebralis [prae-].* Deep layer ventral to *M. longus colli*, dorsal to esophagus and trachea. E
- 16 *Vagina carotica.* Connective tissue sheath for *A. carotis communis* and associated structures. E
- 17 **MUSCULI DORSI.** Extrinsic muscles of thoracic limb and epaxial muscles.
- 18 *M. trapezius.* Broad, triangular muscle of neck and withers. Two continuous parts. Elevates and rotates scapula. C
- 19 *Pars cervicalis.* From median fibrous raphe of neck in Car and su, from *Lig. nuchae* in Ru and eq to *Spina scapulae*. C
- 20 *Pars thoracica.* From *Lig. supraspinale* over withers to dorsal third of *Spina scapulae*. C
- 21 *M. omotransversarius.* From ventral part of *Spina scapulae* and *Fascia brachii* to transverse processes of cranial cervical vertebrae. In eq connected with *M. brachiocephalicus*. Draws shoulder cranially. C
- 22 *M. latissimus dorsi.* Flat triangular muscle caudal to scapula. From superficial layer of *Fascia thoracolumbalis* to *Tuberositas teres major (Un)*, *Crista tuberculi minoris (Car)* of humerus. Flexes shoulder joint. C
- 23 *M. rhomboideus thoracis.* Deep to *M. trapezius*. Fibers course ventrally from spinous processes of cranial thoracic vertebrae to *Margo dorsalis scapulae*. Elevates scapula. F
- 24 *M. rhomboideus cervicis.* From dorsal median raphe of neck (Car, su) or *Lig. nuchae (Ru, eq)* to *Margo dorsalis scapulae*, cranial to *M. rhomboideus thoracis*. F
- 25 *M. rhomboideus capitis (Car, su).* Separates as narrow slip at cranial origin of *M. rhomboideus cervicis*. F
- 26 *M. serratus ventralis cervicis.* Cervical part of large, serrated, fan-shaped muscle. From transverse processes of caudal cervical vertebrae to *Facies serrata scapulae*. Supports trunk. F
- 27 *M. serratus dorsalis caudalis.* From *Fascia thoracolumbalis*. Bundles course cranioventrally to attach to caudal ribs. Expiratory. C
- 28 *M. serratus dorsalis cranialis.* Flat, serrated muscle from *Fascia thoracolumbalis* to cranial ribs. Fibers course caudoventrally. Inspiratory. F

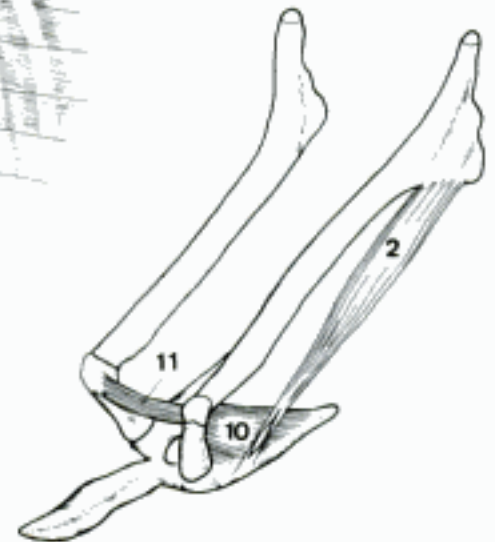


A Hyoid muscles, left aspect (ca)

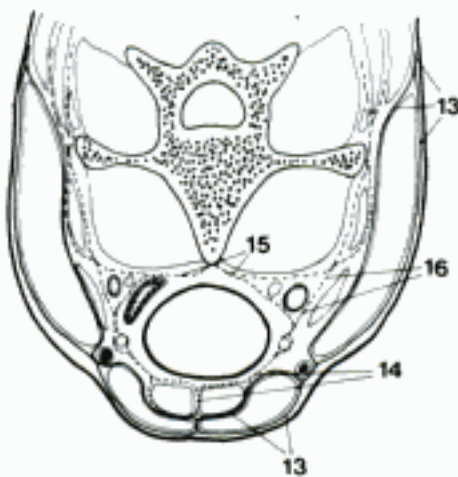
B Hyoid muscles, left ventral aspect (bo)



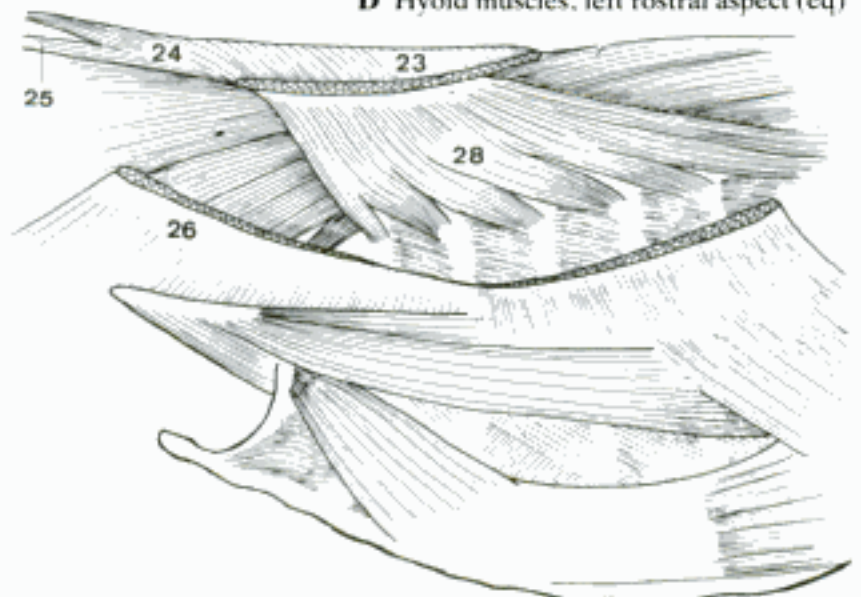
C Superficial muscles of the back, left side (bo)



D Hyoid muscles, left rostral aspect (eq)

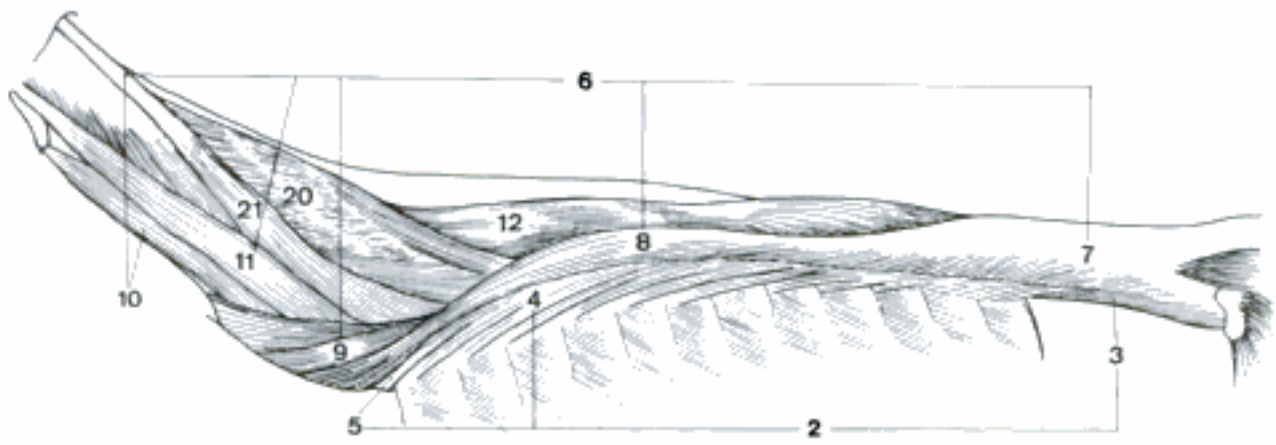


E Fasciae of the neck, transversal section (eq)

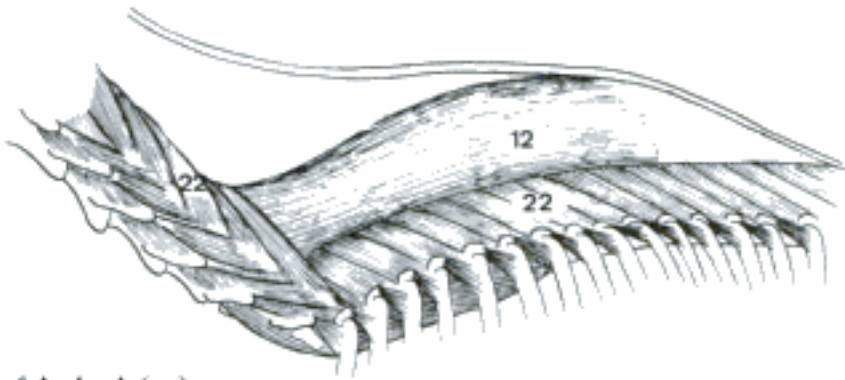


F Deep muscles of the back, left side (ca)

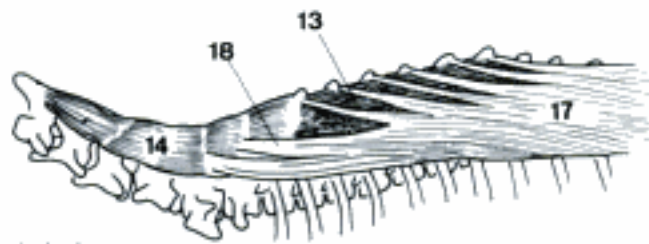
- 1 **M. erector spinae.** Epaxial muscles on dorsal surface of vertebral column and ribs. Extends vertebral column. A
- 2 *M. iliocostalis.* Narrow longitudinal muscle mass. Tendons run cranioventrally over several segments. A
- 3 *M. iliocostalis lumborum.* Lateral portion of muscle mass dorsal to lumbar transverse processes. A
- 4 *M. iliocostalis thoracis.* Lateral to *M. longissimus thoracis.* Continuation forward of *M. iliocostalis lumborum.* Tendinous bundles course as far forward as last cervical transverse process. A
- 5 *M. iliocostalis cervicis.* Only represented as portion to last cervical transverse process in domestic mammals. A
- 6 *M. longissimus.* Forms major portion of epaxial muscle mass. Bundles course cranioventrally several segments. Total extent from ilium to skull. A
- 7 *M. longissimus lumborum.* From Os ilium to continue as *M. longiss. thoracis.* A
- 8 *M. longissimus thoracis.* Bundles end as tendinous leaves. Continues as *M. longiss. cervicis.* A
- 9 *M. longissimus cervicis.* Bundles turn ventrally to insert on last few cervical transverse processes. A
- 10 *M. longissimus atlantis.* Parallel to but ventral to *M. longiss. capitis.* Attaches to Ala atlantis. A
- 11 *M. longissimus capitis.* Cranially directed long muscle arising medial to cervicis to cross atlas and insert on mastoid process. A
- 12 *M. spinalis.* Detaches from medial side of *M. longissimus thoracis* and travels forward near thoracic vertebral spinous processes to cervical vertebral spinous processes, in eq only to middle of neck. A B C
- 13 *M. spinalis thoracis.* Attaches to thoracic vertebral spinous processes and continues forward as *M. spinalis cervicis.* C
- 14 *M. spinalis cervicis.* Medial to *Mm. multifidi* to attach to cervical vertebral spinous processes. C
- 15 **M. transversospinalis.** Collective term for the following muscles.
- 16 *M. semispinalis.* Closely associated with but lateral to *M. spinalis.* Extends vertebral column and head. *M. spinalis,* *M. semispinalis thoracis,* and *M. semispinalis cervicis* are associated in one mass in Car and Ru. C
- 17 *M. semispinalis thoracis.* Bundles detach from Processus mamillares and course over lateral face of *M. spinalis* to dorsal portion of Processus spinosi. Continues as *M. semispinalis cervicis.* C
- 18 *M. semispinalis cervicis.* Fuses with *M. spinalis cervicis* in Car and Ru, absent in su and eq. C
- 19 *M. semispinalis capitis.* Distinct mass of two parts which arises between *M. spinalis thoracis* and *M. longissimus thoracis.* A
- 20 *M. biventer cervicis.* Dorsomedial division. From Fascia thoracolumbalis or thoracic vertebral transverse processes. Courses superficial to *Mm. multifidi* to insert on Os occipitale. A
- 21 *M. complexus.* Ventrolateral division which arises from cervical vertebral articular processes and inserts lateral to *M. biventer cervicis* on Os occipitale. A
- 22 *Mm. multifidi.* Continuous deep series of muscle bundles which course dorsocranially over several segments in lumbar, thoracic, and cervical region. Originate from mamillary, transverse, or articular processes to terminate on spinous processes. Extend vertebral column. B D
- 23 *Mm. rotatores.* Long and short muscle bundles deep to *Mm. multifidi* in cranial thoracic region. Long bundles go dorsocranially from transverse to spinous processes, short are more vertical. Rotate vertebral column. D
- 24 **Mm. interspinales.** From caudal cervical to cranial lumbar regions between spinous processes. Lumbar fibers are deep to *Mm. multifidi.* D



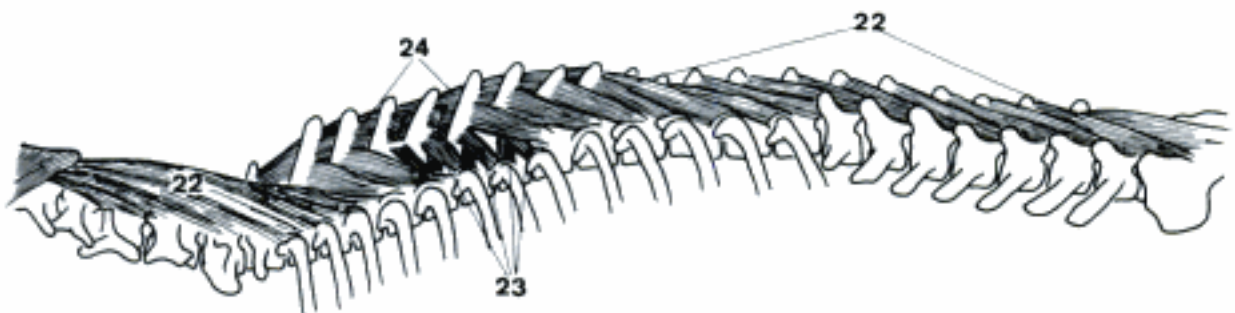
A Deep muscles of the back (bo)



B Deep muscles of the back (eq)

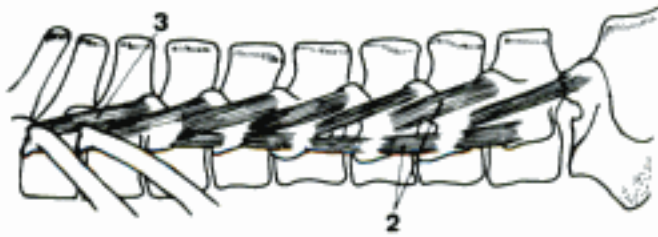

C Deep muscles of the back (ca)

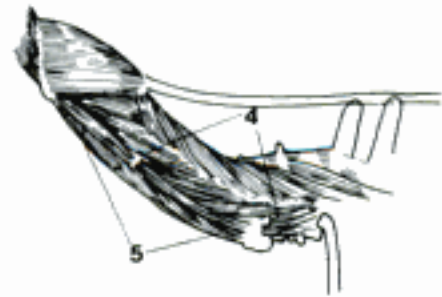

D Short back muscles (ca)

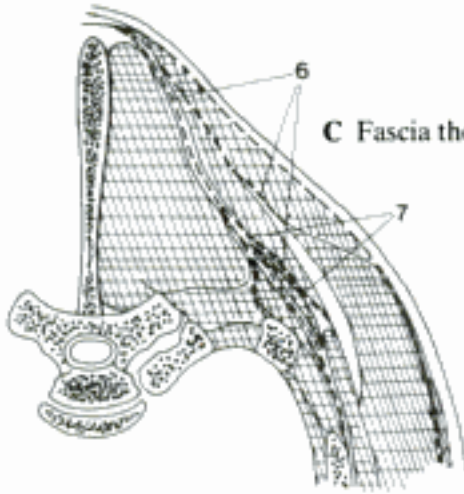
- 1 **Mm. intertransversarii.** Between transverse, or articular and transverse, or mamillary and transverse processes. A B
- 2 *Mm. intertransversarii lumborum.* Medial bundles run ventrocranially from Proc. mamillares to Proc. transversi (or accessorii), lateral lie between transverse processes. A
- 3 *Mm. intransversarii thoracis.* Present in caudal thoracic region as continuation of medial lumbar group. A
- 4 *Mm. intertransversarii dorsales cervicis.* Bundles run cranioventrally from articular to transverse processes. B
- 5 *Mm. intertransversarii ventrales cervicis.* Between transverse processes. B
- 6 *Fascia thoracolumbalis.* Fascia covering M. erector spinae. Divided into superficial layer which gives origin to M. latissimus dorsi, and deep layer which dips deep to scapula, M. splenius and Mm. serrati dorsales arise from it. C
- 7 *Lig. dorsoscapulare.* Extends in eq from spinous processes Th2–Th5 to the medial surface of scapula dorsal to termination of M. serratus ventralis, elastic. C
- 8 *Fascia nuchae.* Dorsal continuation of investment of neck.
- 9 **MUSCULI THORACIS.** Muscles of thoracic wall.
- 10 *Mm. pectorales superficiales.* Run transversely from cranial half of sternum to humerus and Fascia antebrachii. Adduct thoracic limb. D E
- 11 *M. pectoralis descendens.* Cranial portion. From Manubrium sterni to distal end of Crista humeri. D E
- 12 *M. pectoralis transversus.* Broad origin along sternum. Fibers travel laterally to terminate on Crista humeri (Car) or Fascia antebrachii (Un). D E
- 13 *M. pectoralis profundus [M. pectoralis ascendens].* Arises along sternum deep to M. pect. superf. and from fascia caudal to Cartilago xiphoidea. Narrows to ascend to fascia and Tubercula humeri. Adducts thoracic limb and draws it caudally. D
- 14 *M. subclavius.* From the 1st (–4th) costal cartilage. Swings dorsolaterally to deep face of M. brachiocephalicus (su, Ru) and (or) cranial to M. supraspinatus (su, eq). Especially prominent in su and eq where it was formerly called M. pectoralis cleidoscapularis. In Ru it is small, in Car not present. E
- 15 *Fascia pectoralis.* Fascia covering pectoral muscles. D
- 16 *M. serratus ventralis thoracis.* From ribs of cranial half of thorax to caudal part of Facies serrata. Supports thorax between thoracic limbs. D E
- 17 *Mm. levatores costarum.* At proximal ends of intercostal spaces. From transverse process of vertebra caudolaterally to succeeding rib. Inspiratory. F
- 18 *Mm. intercostales externi.* Occupy intercostal spaces superficially from ventral extent of M. levatores costarum to costochondral junction. Fibers run caudoventrally. Inspiratory. E F
- 19 *Mm. intercostales interni.* Throughout length of intercostal and interchondral spaces. Fibers run cranioventrally. Expiratory. F
- 20 *Mm. subcostales.* Muscle bundles at vertebral ends of caudal ribs deep to Mm. intercostales interni. Directed cranioventrally across several ribs, especially ribs 9–11 in Car. F
- 21 *M. retractor costae.* Flat group of fibers coursing cranioventrally from Fascia thoracolumbalis to proximal portion of last rib. F
- 22 *M. transversus thoracis.* On deep surface of ventral thoracic wall. From sternum to costochondral junction of sternal ribs. Bundle direction in general transverse. Expiratory. G
- 23 *M. rectus thoracis.* Flat muscle from first rib to course caudoventrally over several ribs to origin of M. rectus abdominis. Inspiratory. E
- 24 *Fascia endothoracica.* Connective tissue layer between Pleura parietalis and thoracic wall. G



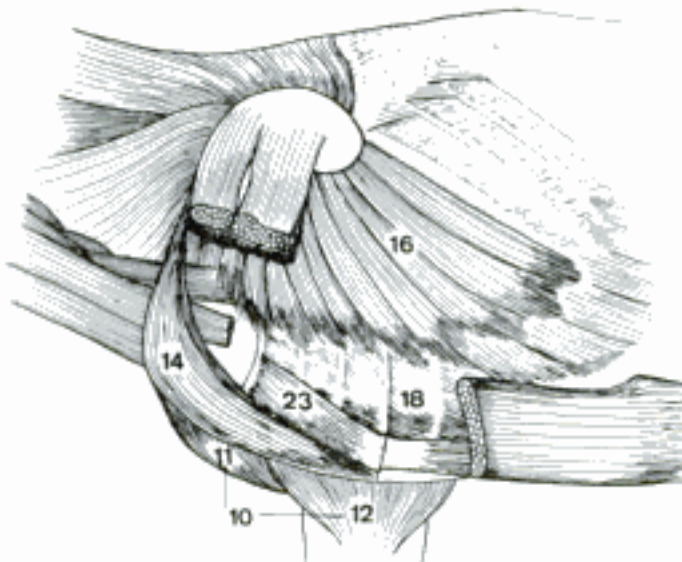
A Mm. intertransversarii lumborum and thoracis (bo)



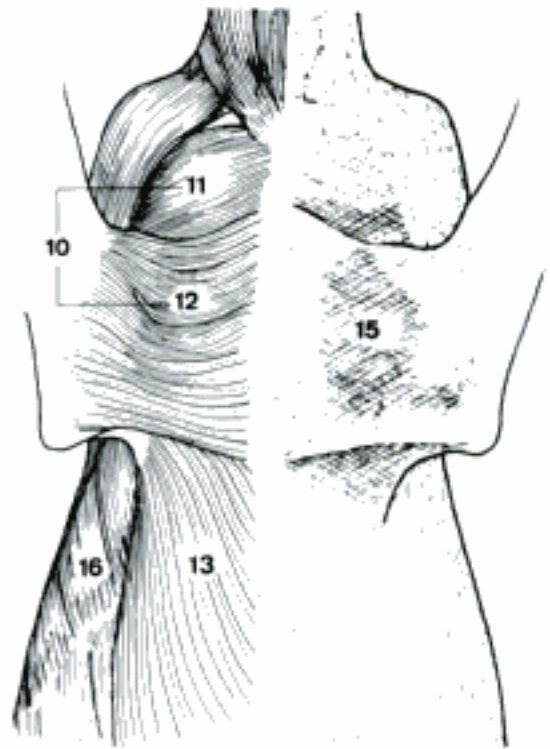
B Mm. intertransversarii of the neck (ca)



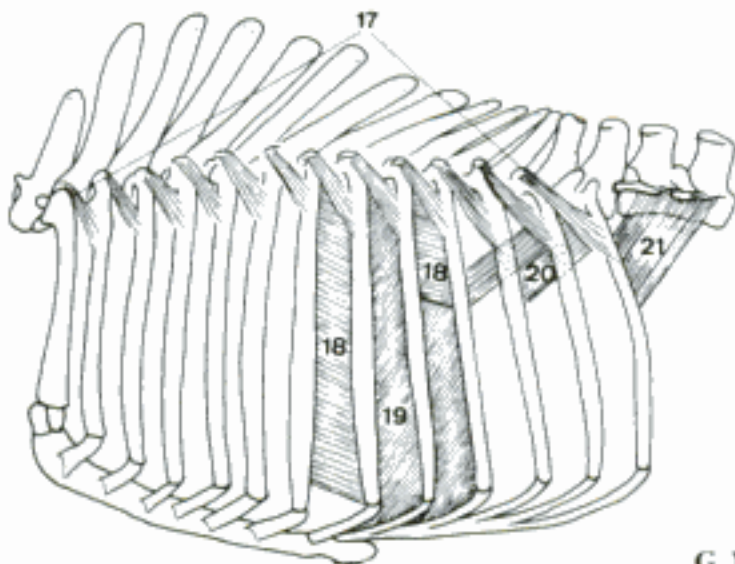
C Fascia thoracolumbalis, transverse section (eq)



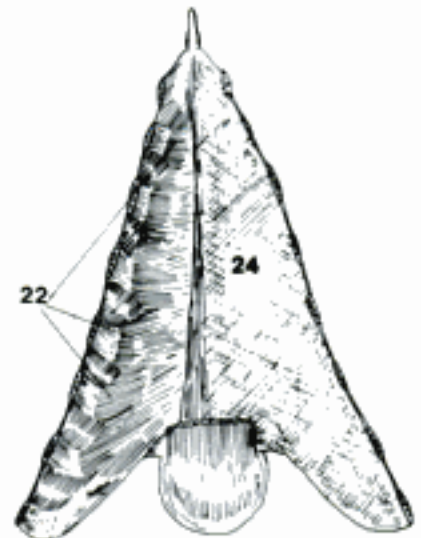
E Muscles of the thorax (eq)



D Muscles and fascia of the thorax, ventral aspect (eq)

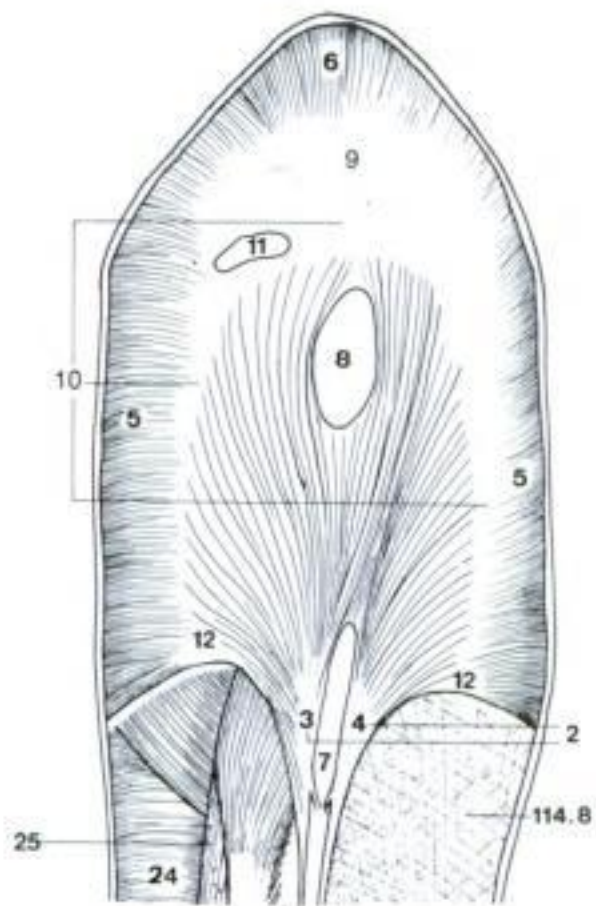


F Muscles of the ribs, left side (bo)

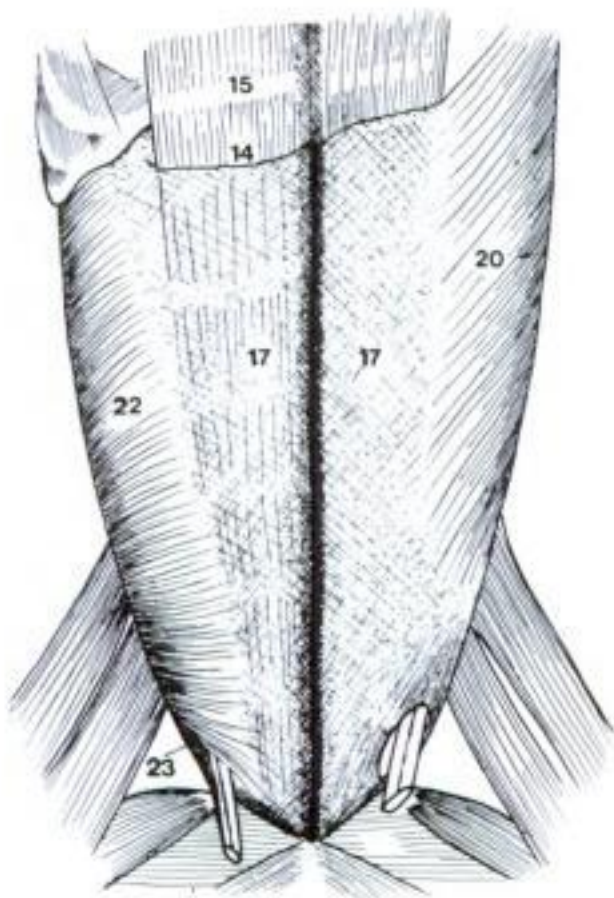


G M. transversus thoracis and Fascia endothoracica, dorsal aspect (eq)

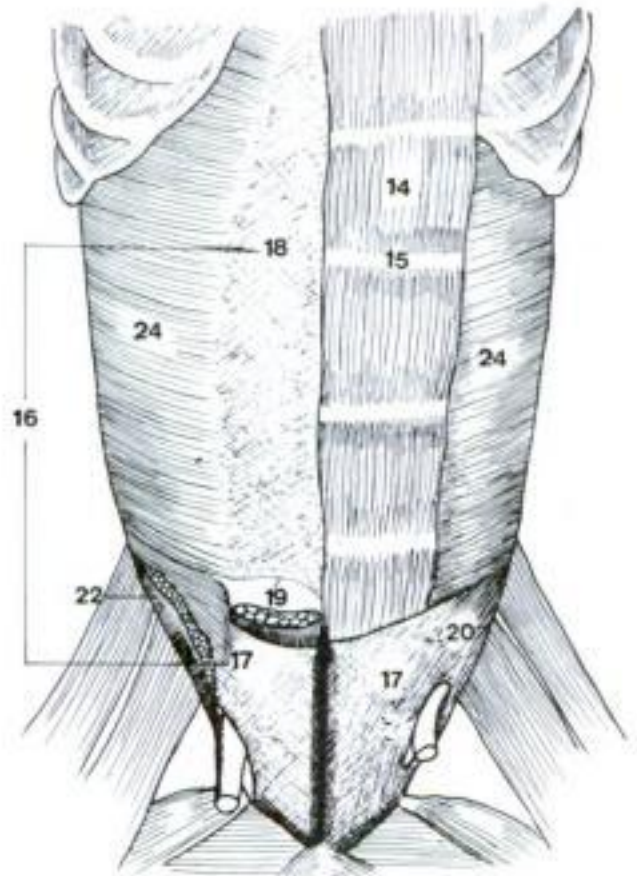
- 1 **Diaphragma.** Musculotendinous partition between thoracic and abdominal cavities. Muscle of inspiration. A
- 2 *Pars lumbalis.* Two crura from cranial lumbar vertebral bodies to spread out in diaphragm. A
- 3 *Crus dextrum.* Larger crus, arising by long tendon from lumbar vertebrae to spread out surrounding esophagus. A
- 4 *Crus sinistrum.* Smaller crus. A
- 5 *Pars costalis.* Arises from caudal ribs. Fibers course to Centrum tendineum. A
- 6 *Pars sternalis.* Continuation of Pars costalis arising from sternum and Cartilago xiphoidea. A
- 7 *Hiatus aorticus.* Opening between cranial tendons at vertebral bodies. A
- 8 *Hiatus esophageus [oesophageus].* Opening in cranioventral portion of Crus dextrum. A
- 9 *Cupula diaphragmatis.* Most cranial portion of diaphragm. A
- 10 *Centrum tendineum.* Tendinous sheet between Pars sternalis, costalis, and lumbalis. A
- 11 *Foramen venae cavae.* Opening in Centrum tendineum for passage of V. cava caud. A
- 12 *Arcus lumbocostalis.* Ventral to psoas muscles where crura turn laterally toward Pars costalis. A
- 13 **MUSCULI ABDOMINIS.** Muscles of abdominal wall. Act to increase intraabdominal pressure.
- 14 *M. rectus abdominis.* Lies parallel to ventral midline. Arises by flat tendon from sternum and costal cartilages, terminates on Os pubis as Tendo prepubicus. B C
- 15 *Intersectiones tendineae.* Sheets of fibrous tissue transversally placed across M. rectus abdominis. B C
- 16 *Vagina m. recti abdominis.* Rectus sheath, formed by aponeuroses of abdominal muscles as they course to Linea alba. C
- 17 *Lamina externa.* Formed by aponeuroses of M. obliquus externus abdominis and M. obliquus internus abdominis. Cranial to Os pubis, aponeurosis of M. transversus abdominis joins Lamina externa in Car. C
- 18 *Lamina interna.* Formed by aponeurosis of M. transversus abdominis. In Car, ov, and cap M. obliquus internus abdominis sends an aponeurotic sheet to Lamina interna cranial to umbilicus. C
- 19 *Linea arcuata.* Caudal border of aponeurosis of M. transversus abdominis. C
- 20 *M. obliquus externus abdominis.* Fibers course obliquely ventrocaudally to form aponeurosis which is expansiv in inguinal region. Arises from lateral surface of ribs and Fascia thoracolumbalis (except Ru). B C
- 21 *Arcus inguinalis [Lig. inguinale].* Thickened caudal portion of aponeurosis of M. obliquus externus abdominis from Tuber coxae to Eminentia iliopubica. 115 A
- 22 *M. obliquus internus abdominis.* Courses ventrocranially to form aponeurosis. Fibers closer to midline in inguinal region where they cover lateral border of M. rectus abdominis and turn caudally. From Fascia thoracolumbalis (except eq) and Tuber coxae. B C
- 23 *M. cremaster.* Caudal detachment of fibers from M. obliquus internus abdominis to Funiculus spermaticus. B
- 24 *M. transversus abdominis.* Forms aponeurosis at lateral border of M. rectus abdominis. From medial surface of ribs and Fascia thoracolumbalis. A D
- 25 *M. quadratus lumborum.* Longitudinal fibers ventral to bodies of last thoracic vertebrae and lumbar vertebral transverse processes. Dorsal to psoas muscles. A



A Diaphragm, caudoventral aspect (ca)

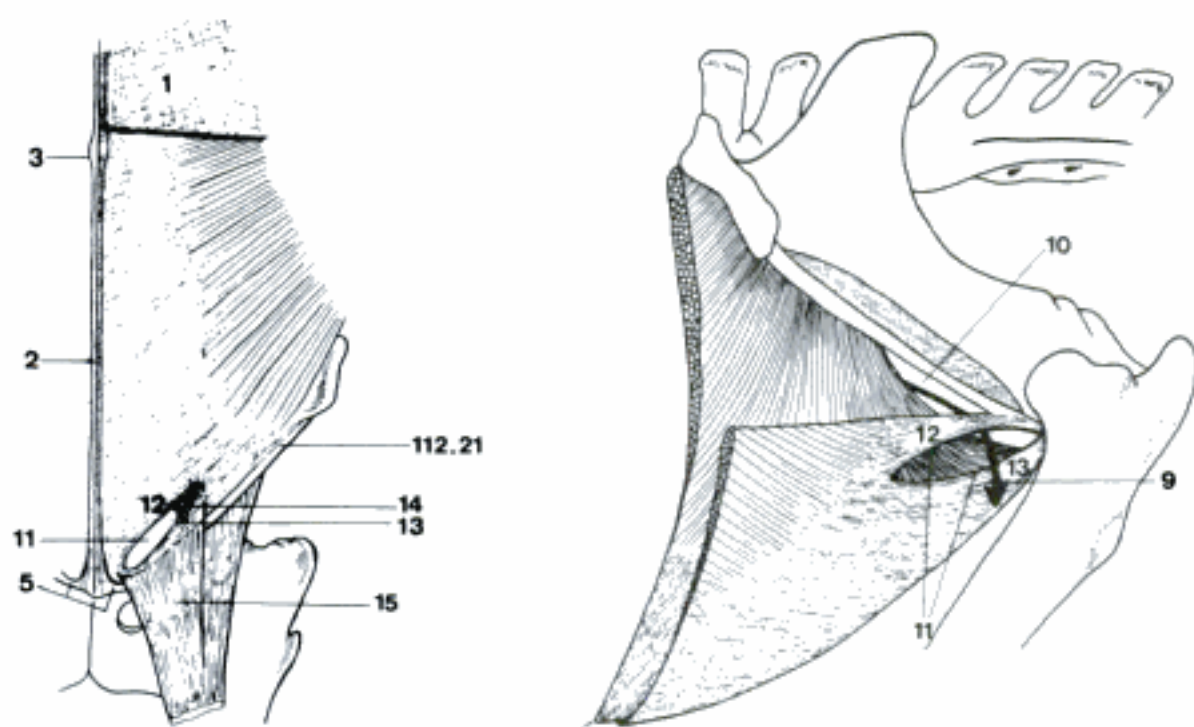


B Abdominal muscles (ca)



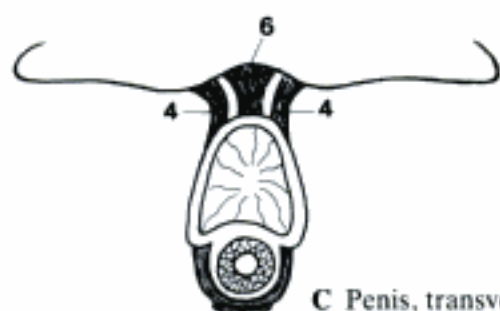
C Abdominal muscles (ca)

- 1 *Tunica flava abdominis*. Modified fascia as elastic sheet over M. obliquus externus abdominis in Un. A
- 2 *Linea alba*. White fibrous line of attachment of aponeuroses on ventral midline from Cartilago xiphoidea to Os pubis. A
- 3 *Anulus umbilicalis*. Widening of Linea alba representing closed umbilicus. A
- 4 *Lig. fundiforme penis*. Lateral elastic strands from Linea alba and fascia to preputium. C
- 5 *Tendo prepubicus [prae-]*. Complex of tendons, mainly of Mm. pectinei and Mm. recti abdominis attached to Rami craniales ossium pubis. A
- 6 *Lig. suspensorium penis*. Median fibrous strands from the caudal part of Symphysis pelvina to penis. C
- 7 *Lig. suspensorium clitoridis*. Median fibrous strands from the caudal part of Symphysis pelvina to clitoris.
- 8 *Fascia transversalis*. Layer of abdominal wall outside peritoneum as far dorsal as tips of lumbar transverse processes. 113 A
- 9 **Canalis inguinalis [Spatium inguinale]**. Area between superficial and deep inguinal rings, these including. B
- 10 *Anulus inguinalis profundus*. Area caudal to last muscle fibers of M. obliquus internus abdominis, lateral to M. rectus abdominis. Caudolateral border is formed by Lig. inguinale. B
- 11 *Anulus inguinalis superficialis*. Slit or oval opening in aponeurosis of M. obliquus externus abdominis in inguinal region. A B
- 12 *Crus mediale*. Aponeurosis forming the craniomedial border of Anulus inguinalis superficialis. A B
- 13 *Crus laterale*. Aponeurosis forming the caudolateral border of Anulus inguinalis superficialis. A B
- 14 *Fibrae intercrurales*. Fibrous strands between Crus med. and Crus lat. reinforcing craniolateral end of Anulus inguinalis superficialis. A
- 15 *Lamina femoralis*. Sheet of aponeurosis of M. obliquus ext. from Crus laterale and Lig. inguinale to medial surface of thigh. A
- 16 **MUSCULI CAUDAE [COCCYGIS]**. Muscles of tail. D
- 17 *M. coccygeus*. Arises from Spina ischiadica. Part of Diaphragma pelvis. Inserts laterally on transverse processes of first few coccygeal vertebrae. Depresses tail; singly also flexes tail laterally. D
- 18 *M. sacrocaudalis [-coccygeus] ventralis medialis*. Medial of two ventral longitudinal muscles. Consists of short segments continuing caudally from last sacral vertebra. D
- 19 *M. sacrocaudalis [-coccygeus] ventralis lateralis*. Arises from last lumbar vertebra (Car) and sacrum. Segments become tendinous. D
- 20 *M. sacrocaudalis [-coccygeus] dorsalis medialis*. Continues caudally from Mm. multifidi at last lumbar vertebra. Composed of substantial segments. D
- 21 *M. sacrocaudalis [coccygeus] dorsalis lateralis*. Arises between M. longissimus and Mm. multifidi as far forward as 1st lumbar vertebra. Consists of long bundles, in Car tendinous on the tail. D
- 22 *Mm. intertransversarii ventrales caudae [coccygis]*. Ventral to transverse processes. Begin caudal to sacrum, are segmented.
- 23 *Mm. intertransversarii dorsales caudae [coccygis]*. Dorsal to ventral group. Begin at sacrum but may not reach tip of tail. D
- 24 *Fascia caudae [coccygis]*. Invests the tail, sends intermuscular septa to vertebrae especially in midline and investing Mm. intertransversarii. D

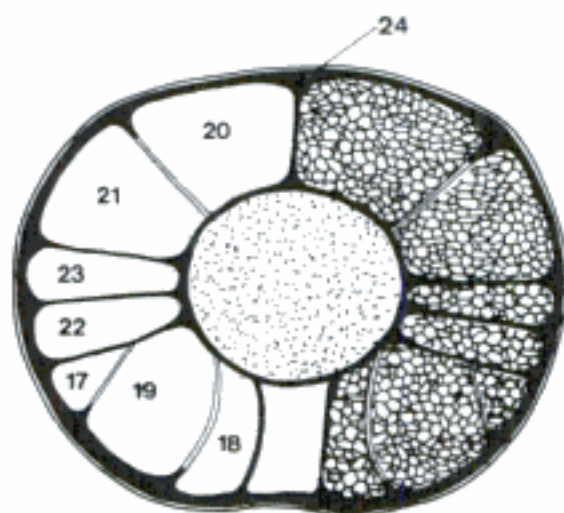


A Left side of ventral abdominal wall, ventral aspect (eq)

B Left Canalis inguinalis, lateral aspect (eq)

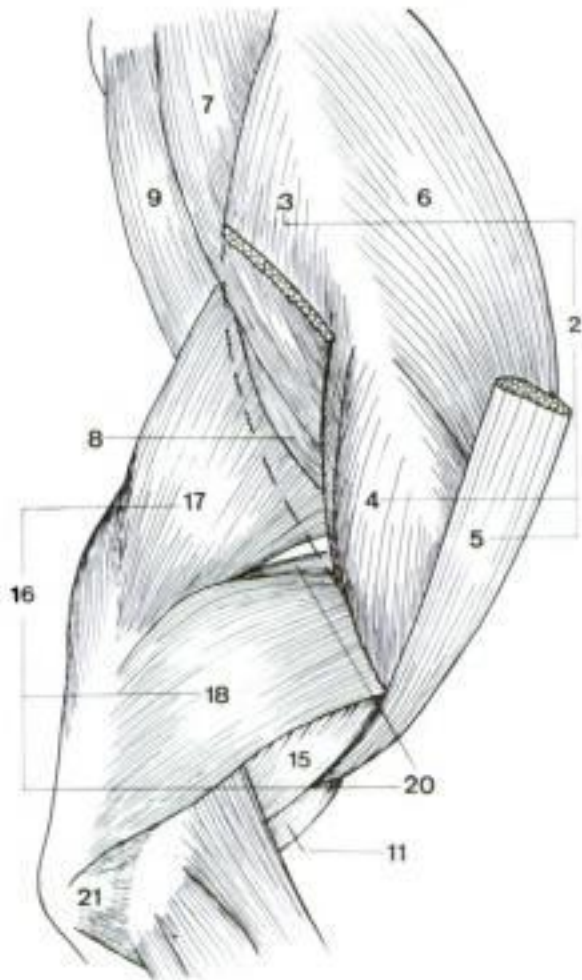


C Penis, transverse section (eq)



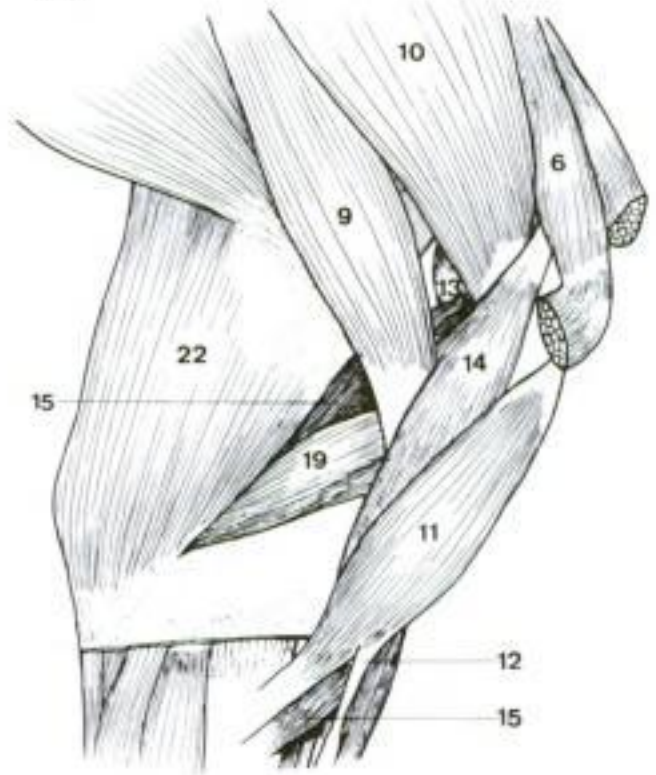
D Muscles and fascia of the tail, transverse section (eq)

- 1 **MUSCULI MEMBRI THORACICI.** Muscles of thoracic limb.
- 2 *M. deltoideus.* Lateral muscle of shoulder. Divided origin, two parts are blended in eq, as there is no acromion. Flexes shoulder joint. A E
- 3 *Pars scapularis.* From Spina scapulae to Tuberositas deltoidea. A C
- 4 *Pars acromialis.* From acromion to Tuberositas deltoidea. A C
- 5 *Pars clavicularis [M. cleidobrachialis].* In domestic mammals the reduction of the Clavicula makes the Pars clavicularis m. deltoidei to a part of M. brachiocephalicus. A
- 6 *M. supraspinatus.* Occupies Fossa supraspinata. Passes over cranial part of shoulder joint to Tuberculum majus, in Un also minus. Extends shoulder joint. A B C E F
- 7 *M. infraspinatus.* Occupies Fossa infraspinata. Crosses lateral part of shoulder joint to roughened area of Tuberculum majus humeri. Acts as lateral collateral ligament of shoulder joint. A C E
- 8 *M. teres minor.* Small round muscle from caudal border of scapula. Along caudal border of M. infraspinatus to terminate distal to it on humerus. Flexes shoulder joint. A C E
- 9 *M. teres major.* From proximal part of caudal border of scapula to terminate with M. latissimus dorsi on Tuberositas teres major (Un) or Crista tuberculi minoris (Car). Flexes shoulder joint. A B C D F
- 10 *M. subscapularis.* Occupies Fossa subscapularis. Inserts on caudal portion of Tuberculum minus. Acts as medial collateral ligament of shoulder joint. B C D F
- 11 *M. biceps brachii.* From Tuberculum supraglenoidale. Passes distally through Sulcus intertubercularis to terminate on Tuberositas radii and fascia. Extends shoulder joint and flexes elbow joint. Tendon runs length of biceps from very strong tendon of origin which acts to fix shoulder joint. A B C D
- 12 *Lacertus fibrosus.* Fibrous insertion of M. biceps brachii on medial surface of M. extensor carpi radialis. Especially developed in eq as part of "check" apparatus. B
- 13 *M. articularis humeri (fe, su, eq).* Small muscle across caudal surface of shoulder joint. B
- 14 *M. coracobrachialis.* Arises by tendon from Processus coracoideus to terminate distal to Tuberculum minus. Extends and adducts shoulder joint. B D F
- 15 *M. brachialis.* Occupies Sulcus m. brachialis. Crosses cranial surface of elbow to terminate near biceps on radius and ulna. Flexes elbow joint. A B E F
- 16 *M. triceps brachii.* Caudal to humerus and shoulder joint. Consists of three or four heads which converge to terminate on olecranon. Extends elbow joint. A
- 17 *Caput longum.* Only head arising from caudal border of scapula. Also flexes shoulder joint. A C D
- 18 *Caput laterale.* Arises on Linea m. tricipitis, in Car also on Crista humeri. A E
- 19 *Caput mediale.* From humerus caudal to Tuberositas teres major (Crista tuberculi minoris in Car). B F
- 20 *Caput accessorium.* Deep to other heads. Arises distal to Caput humeri. Absent in eq. A E F
- 21 *M. anconeus [anconaeus].* From humerus lateral to Fossa olecrani to olecranon. Extends elbow joint. A E F
- 22 *M. tensor fasciae antebrachii.* Lies on medial surface of triceps. Arises from M. latissimus dorsi (Car, Ru, eq) and caudal border of scapula (su, Ru, eq) to terminate on olecranon and Fascia antebrachii. Extends elbow joint and flexes shoulder joint (except Car). B

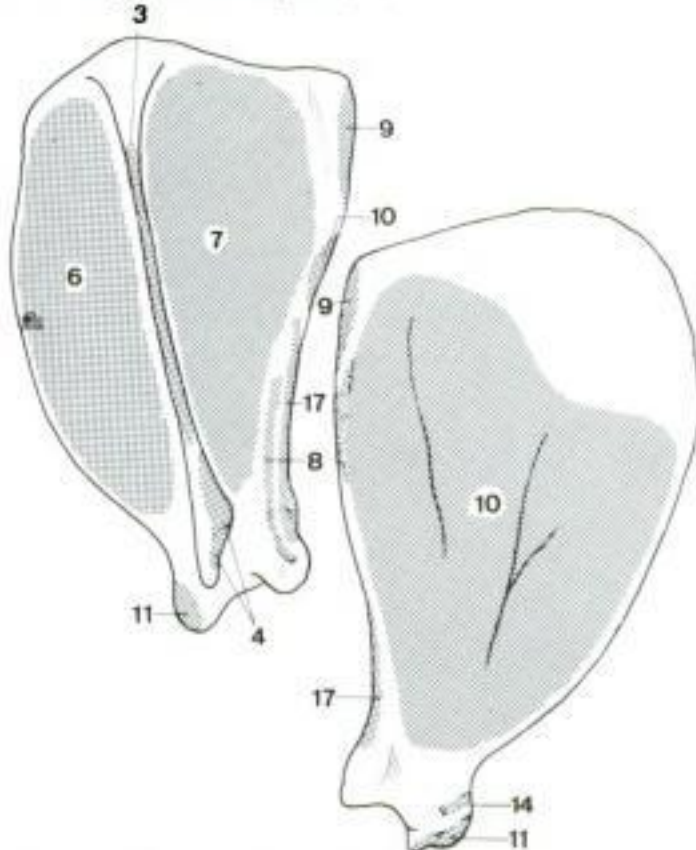


A Muscles of right shoulder and arm, lateral aspect (ca)

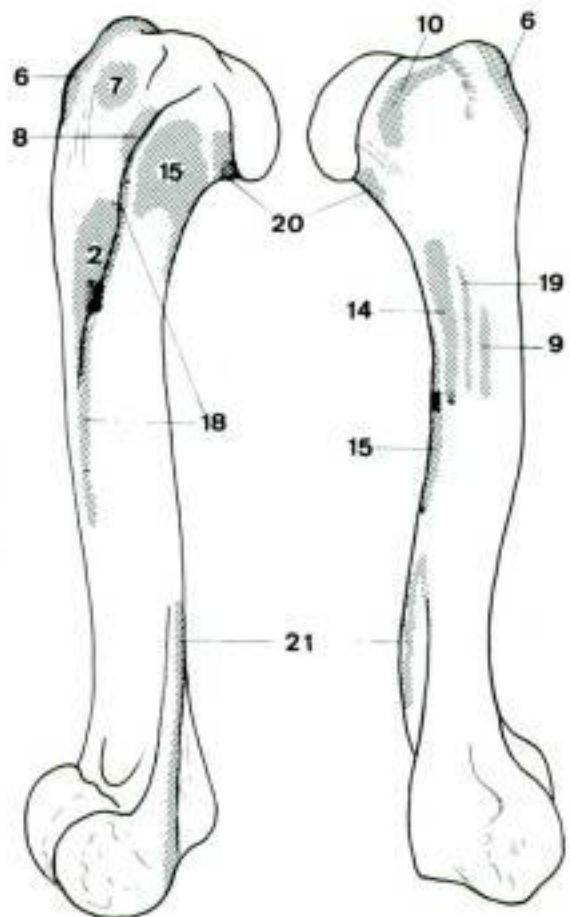
B Muscles of left shoulder and arm, medial aspect (cq)



C Left scapula, lateral aspect (ca)



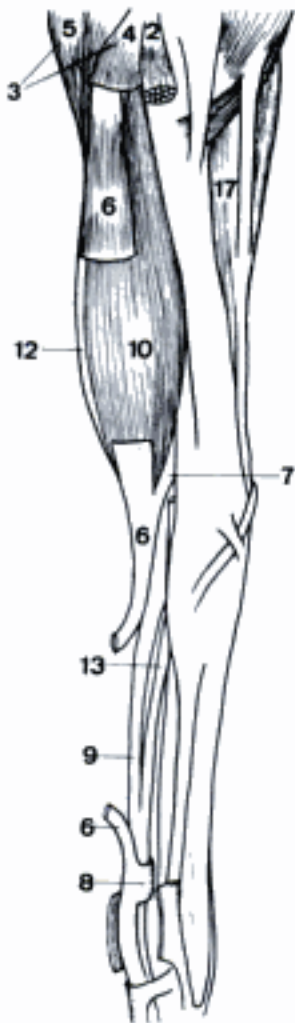D Left scapula, medial aspect (ca)



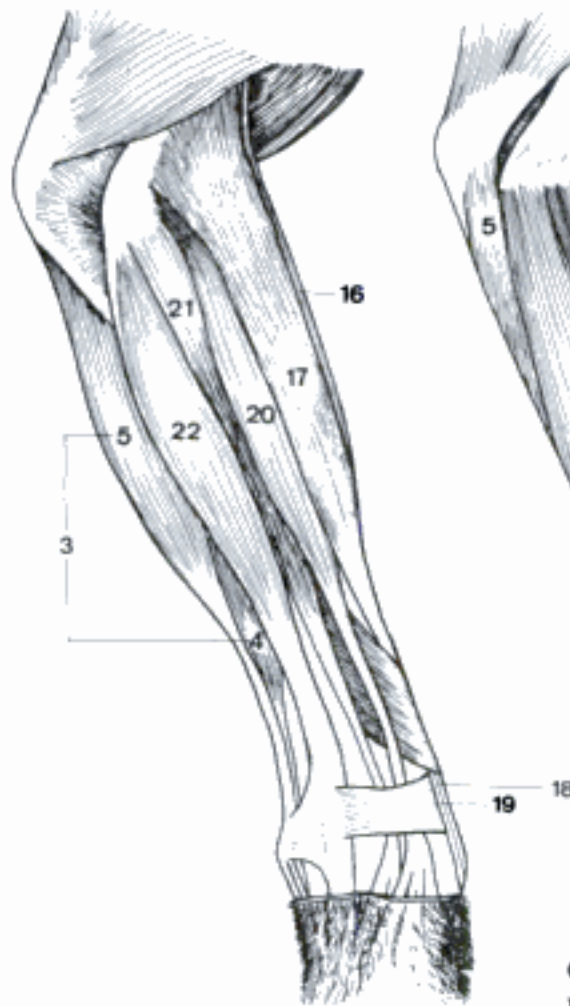E Left humerus, cranio-lateral aspect (ca)

F Left humerus, medial aspect (ca)

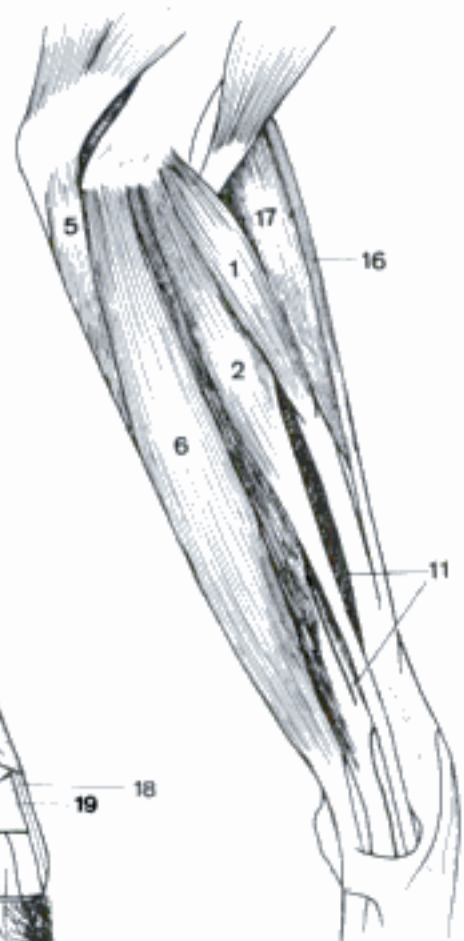
- 1 *M. pronator teres*. From Epicondylus medialis humeri to medial surface of radius. Pronates radioulnar joints. Tendinous in eq. C D
- 2 *M. flexor carpi radialis*. Next caudal from Epicondylus medialis to Basis of Os metacarpale II (Car, eq), III (Car, su, Ru). A C
- 3 *M. flexor carpi ulnaris*. Most caudal of flexor group. The two heads do not unite in Car. Flexes carpal joint. A B
- 4 *Caput humerale*. From Epicondylus medialis to Os carpi accessorium. Deep to *M. flexor digitorum superficialis* in Car. A B
- 5 *Caput ulnare*. From medial side of olecranon to Os carpi accessorium. A B C D
- 6 *M. flexor digitorum [digitalis] superficialis*. From Epicondylus medialis. Tendon divides for major digits. Each divides for passage of deep flexor tendon and terminates on basis of middle phalanx. Flexes carpal and proximal phalangeal joints. A C
- 7 *Lig. accessorium*. From distal portion of radius to superficial digital flexor tendon in eq. A
- 8 *Manica flexoria*. The sleeve formed by each tendon of *M. flexor digit. superficialis* around the corresponding tendon of *M. flexor digit. profundus* at the level of the Articulatio metacarpophalangea. A
- 9 *M. flexor digitorum [digitalis] profundus*. Deep in flexor group. Three heads with combined tendon which divides to terminate on flexor surface of each distal phalanx. Flexes carpal and phalangeal joints. A E
- 10 *Caput humerale*. Contains bulk of muscle. From Epicondylus medialis. A E
- 11 *Caput radiale*. A small slip from middle portion of radius. C D E
- 12 *Caput ulnare*. Arises along ulna, tendinous in eq. A D E
- 13 *Ligamentum accessorium*. Fibrous continuation of palmar carpal ligaments to deep digital flexor tendon in eq. A
- 14 *Mm. interflexorii*. In Car longitudinal bundle from palmar surface of *M. flexor digit. profundus* at carpus. Thin tendons to superficial digital flexor tendons. In su and Ru additional connection between superficial and deep digital flexor at antebrachium. E
- 15 *M. pronator quadratus*. Transverse fibers between radius and ulna in Car. D E
- 16 *M. brachioradialis*. In Car as slender muscle on cranial surface of *M. extensor carpi radialis*, often absent in ca. Supinates antebrachium. B C D
- 17 *M. extensor carpi radialis*. Most cranial major muscle of extensor group. From Crista supracondylaris lateralis humeri to Tuberositas ossis metacarpalis III in Un, metacarpals II and III in ca. Extends carpal joint. A B C
- 18 *M. extensor carpi radialis longus*. Medial division in fe, medial tendon in ca, inserts on metacarpal II. B F
- 19 *M. extensor carpi radialis brevis*. Lateral division in fe, lateral tendon in ca. Inserts on metacarpal III. B F
- 20 *M. extensor digitorum [digitalis] communis*. Arises caudodistal to *M. extensor carpi radialis*. Tendon crosses dorsal surface of carpus to divide for Processus extensorius of distal phalanx of digitis II–IV (Car, su), III and IV (Ru), III (eq). In Ru separated medial portion is formed for digit III, in su there are three portions. Extends carpal and phalangeal joints. B F
- 21 *M. extensor digitorum [digitalis] lateralis*. Lies caudolateral to preceding muscle, but arises from radius and ulna. Tendon terminates on proximal phalanx in eq, goes to digit IV in Ru, IV, V in su, III–V in ca, and II–V in fe. Extends carpal and phalangeal joints of corresponding digits. B F
- 22 *M. extensor carpi ulnaris [M. ulnaris lateralis]*. Most caudolateral of extensor group. From Epicondylus lateralis. Tendon attaches on Os carpi accessorium, but sends tendon on to lateral metacarpal. Lies so far caudal that it acts as a carpal flexor. B



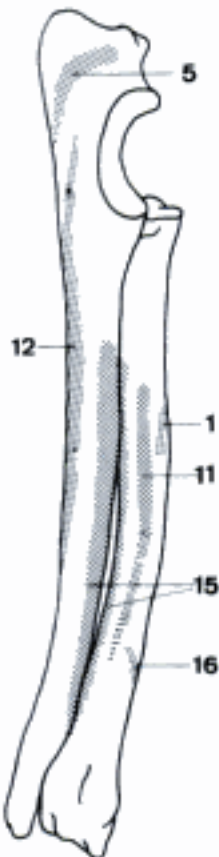
A Muscles of the left forearm, medial aspect (eq)



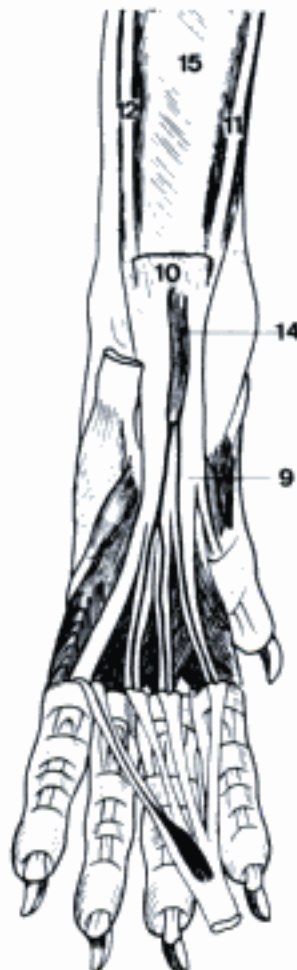B Muscles of the right forearm, lateral aspect (ca)



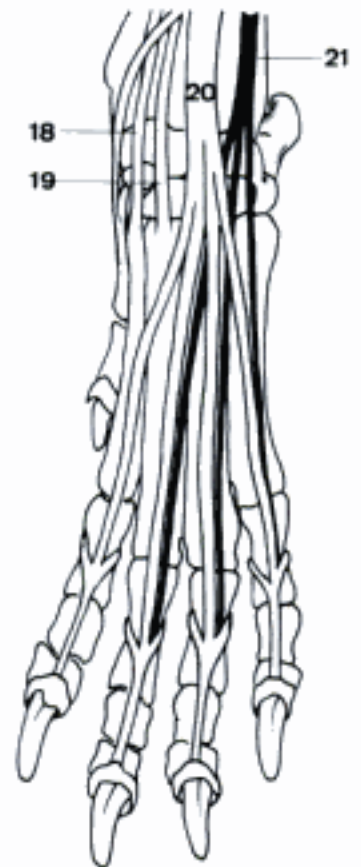C Muscles of the left forearm, medial aspect (ca)



D Bones of the right forearm, medial aspect (ca)

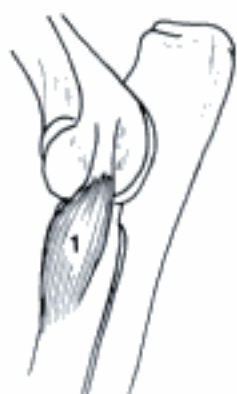

E Muscles of the left manus, palmar aspect (ca)

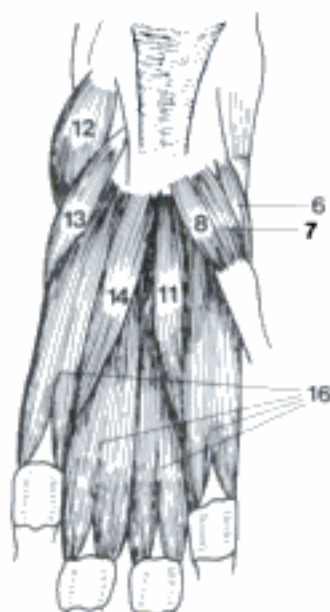


F Muscles of the left manus, dorsal aspect (ca)

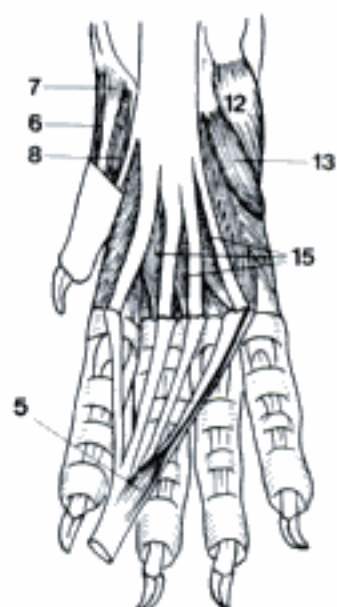
- 1 *M. supinator*. Deep to carpal and digital extensors. From Epicondylus lateralis humeri to proximal fourth of radius. Supinates antebrachium. Present in Car, rudimentary in su. A F
- 2 *M. abductor digiti I [pollicis] longus [M. extensor carpi obliquus]*. From radius (Un) or radius and ulna (Car) obliquely to basis of metacarpal I (Car), II (su, eq), III (Ru). Abducts digit I (Car), extends digit I (Car) and carpus. E F
- 3 *M. extensor digiti I [pollicis]*. Present in Car, it is combined with *M. extensor digiti II*. From middle of ulna between digital extensors to distal end of metacarpal I. E F
- 4 *M. extensor digiti II*. Combined with preceding, tendon to common digital extensor tendon of digit II. E F
- 5 *M. flexor digitorum brevis*. Small muscle on deep surface of *M. flexor digitorum superficialis* in Car. Tendon ends on digit V (ca), digits III–V (fe). C
- 6 *M. abductor digiti I [pollicis] brevis*. Small slip from Retinaculum flexorum to sesamoid or proximal phalanx of digit I in Car. B C
- 7 *M. flexor digiti I [pollicis] brevis*. Lateral to preceding muscle in Car. From Retinaculum flexorum to proximal phalanx of digit I. B C
- 8 *M. adductor digiti I [pollicis]*. Lateral muscle of digit I in Car. B C
- 9 *M. abductor digiti II*. Small muscle of su from Retinaculum flexorum to abaxial side of proximal phalanx of digit II. D
- 10 *M. flexor digiti II*. Lateral to preceding in su. D
- 11 *M. adductor digiti II*. From Retinaculum flexorum between *M. interosseus II* and *M. adductor digiti V* in Car and su. Inserts on proximal phalanx of digit II. B D
- 12 *M. abductor digiti V*. From Os carpi accessorium to abaxial side of proximal phalanx of digit V in Car and su. B C D
- 13 *M. flexor digiti V*. Small bundle of fibers medial to preceding with which it inserts in Car and su. B C D
- 14 *M. adductor digiti V*. From Retinaculum flexorum. Descends medial to *M. interosseus IV* to axial side of proximal phalanx of digit V in Car and su. B D
- 15 *Mm. lumbricales*. Muscle fibers between tendons of *M. flexor digitorum profundus* which run obliquely laterally to insert on proximal phalanges of digits II–V (fe), III–V (ca). Best developed in Car, absent in Ru. Flex metacarpophalangeal joints. C
- 16 *Mm. interossei*. On palmar surface of metacarpal bones except I. Fibers of each divide distally to attach to proximal sesamoids and go on each side of metacarpophalangeal joints to join common extensor tendon. Tendinous in eq and Ru. Support metacarpophalangeal joints. B D
- 17 *Fascia axillaris*. Covers medial muscles of shoulder.
- 18 *Fascia brachii*. Investment of muscles of arm with intermuscular septa. G
- 19 *Fascia antebrachii*. Investment of muscles of antebrachium. H



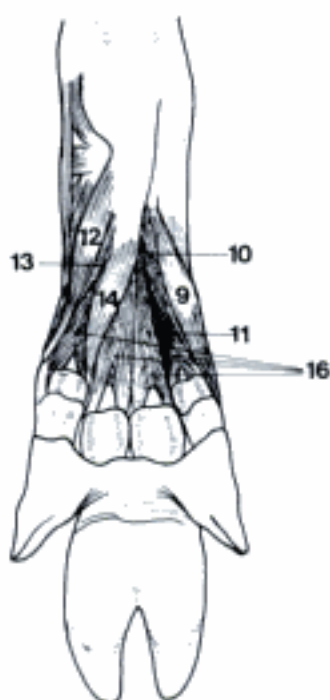
A Left M. supinator, lateral aspect (ca)



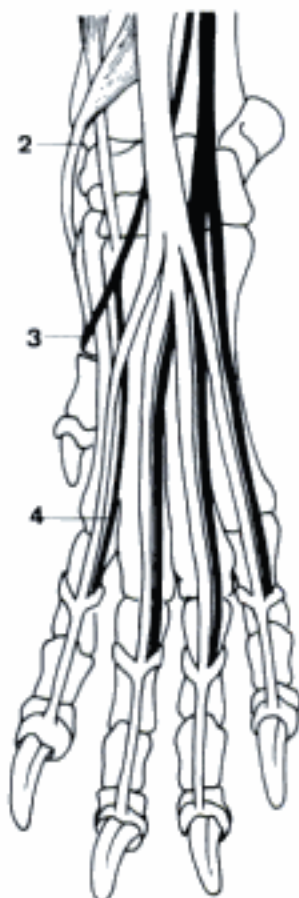
B Muscles of the left manus, palmar aspect (ca)



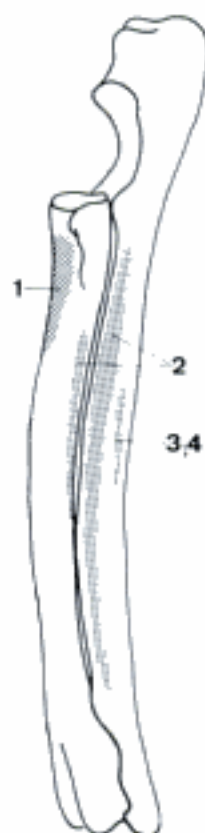
C Muscles and tendons of the right manus, palmar aspect (ca)



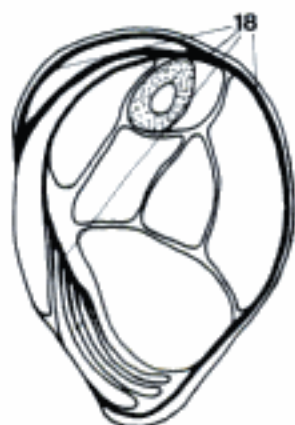D Muscles of the left manus, palmar aspect (su)



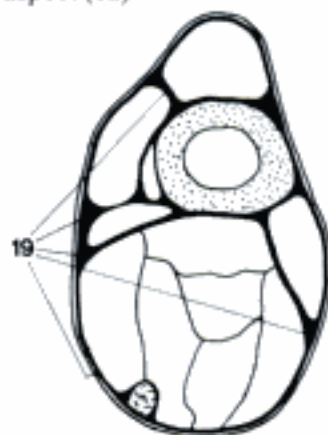
E Tendons of the left manus, dorsal aspect (ca)



F Bones of the left forearm, lateral aspect (ca)

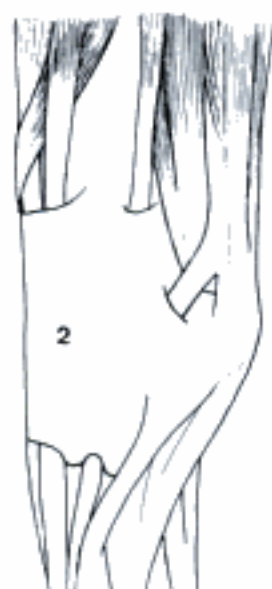

G Right arm, transverse section, proximal surface (ca)

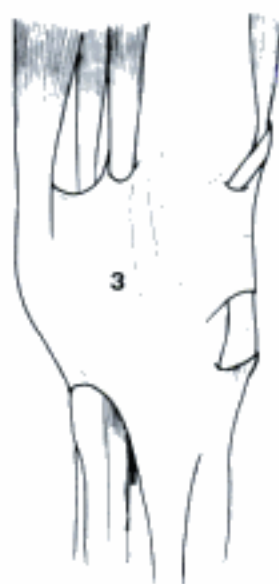

H Left forearm, transverse section, proximal surface (cq)

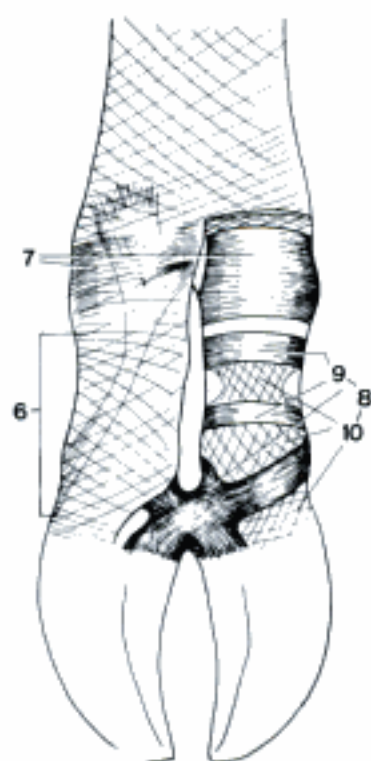
- 1 *Fascia dorsalis manus*. Retains and invests dorsal tendons of manus. D
- 2 *Retinaculum extensorum*. Fascial bands stretching transversely across dorsal surface of carpus retaining extensor tendons. A
- 3 *Retinaculum flexorum*. Especially thick transverse fascial bands from medial carpal bones to Os carpi accessorium forming Canalis carpi. B
- 4 *Canalis carpi*. Canal between the proximal row of carpal bones and Retinaculum flexorum. See 86.7
- 5 *Fascia palmaris*. Retains and invests palmar structures of manus. D
- 6 *Fascia digiti*. Superficial and deep layer, the latter forms annular ligaments. C E
- 7 *Lig. metacarpeum transversum superficiale [Lig. anulare palmare]*. Thickening of fascia of metacarpophalangeal area on palmar surface, transversely oriented. Consists of superficial and deep part in Ru and eq. C E F
- 8 *Vaginae fibrosae digitorum manus*. Transverse and crossed fibers of digital fascia on palmar side. C E
- 9 *Pars anularis vaginae fibrosae [Lig. anulare digiti]*. Strong part with transverse fibers. C E
- 10 *Pars cruciformis vaginae fibrosae*. Thin part with crossed fibers. However in eq the proximal Pars cruciformis is strong and forms with two Partes anulares a quadrilateral sheet. The distal Pars cruciformis forms with the distal Pars anularis a crescenting fibrous sheet in eq. C E
- 11 *Scutum proximale*. Fibrocartilaginous palmar surface of Lig. palmare, providing gliding surface for flexor tendons. F
- 12 *Scutum medium*. Fibrocartilaginous plate that covers the palmar surface of the proximal part of Phalanx media, and also extends proximal to it, providing gliding surface for flexor tendons. F
- 13 *Scutum distale*. Fibrocartilaginous plate that covers the palmar surface of Os sesamoideum distale, but also extends proximal to it, providing gliding surface for deep flexor tendon. F
- 14 *Vaginae synoviales tendinum digitorum manus*. Digital synovial tendon sheath around superficial and deep digital flexor tendons of each digit from distal portion of metacarpus to middle of Phalanx media. See 134.17
- 15 *Vincula tendinum*. Fibers from deep digital flexor tendon to the middle of Lig. sesamoideum rectum in eq. F
- 16 **MUSCULI MEMBRI PELVINI**. Muscles of pelvic limb.
- 17 *M. iliopsoas*. Muscle composed of M. psoas major and M. iliacus, termination on Trochanter minor. Flexes and supinates hip joint. G
- 18 *M. iliacus*. From Facies iliaca. Grooved ventrally for M. psoas major. G
- 19 *M. psoas major*. From ventral surface of lumbar vertebral bodies and transverse processes. Increases on size caudally. G
- 20 *M. psoas minor*. On ventromedial surface of M. psoas major. Flethy origin from lumbar and caudal thoracic vertebral bodies. Long tendon of termination on Tuberculum m. psoas minoris of ilium (Linea arcuata in ca). Flexes vertebral column. G



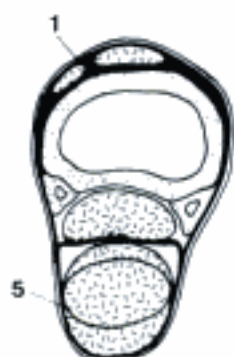A Left Retinaculum extensorum, dorsolateral aspect (eq)



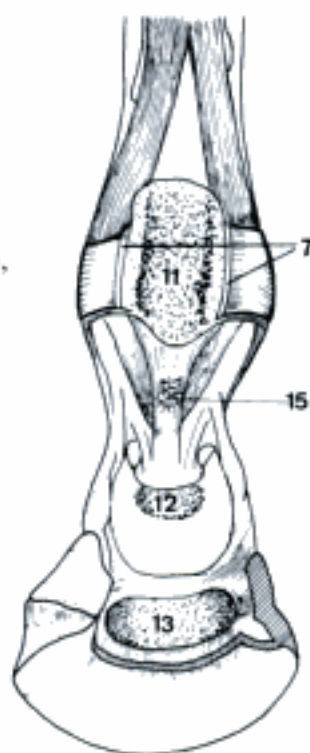
B Left Retinaculum flexorum, medial aspect (eq)



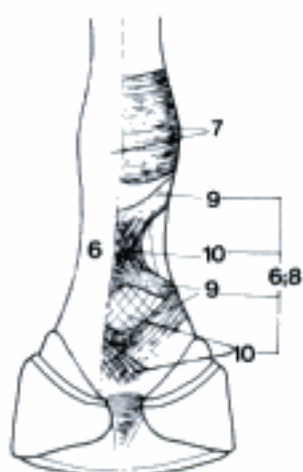
C Fasciae of the digits, palmar aspect (bo)



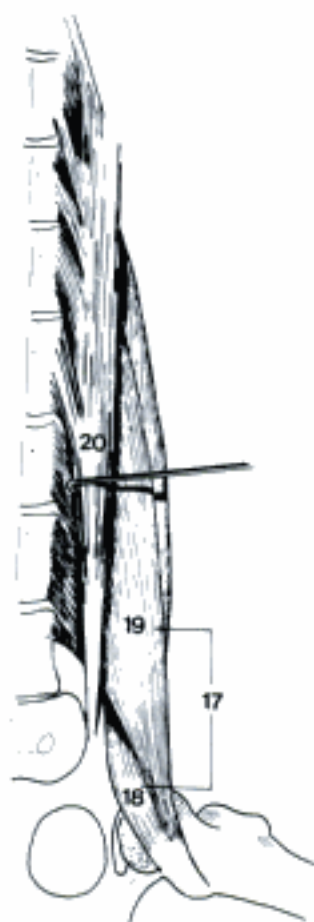D Left metacarpus, transverse section, proximal surface (eq)



F Scuta and Vincula tendinis, palmar aspect (eq)

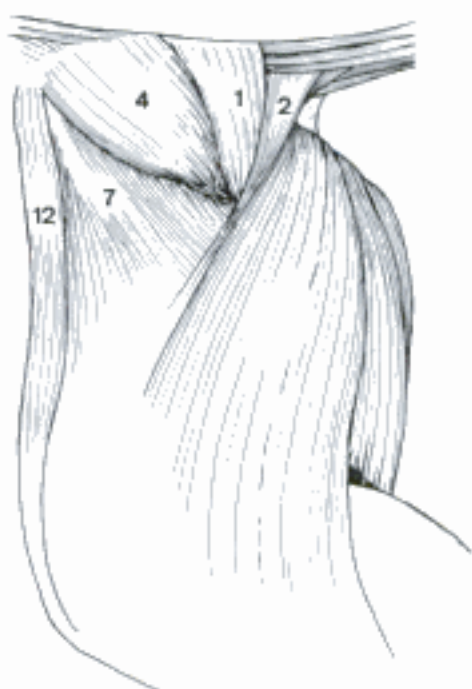

E Fascia of the digit, palmar aspect (eq)

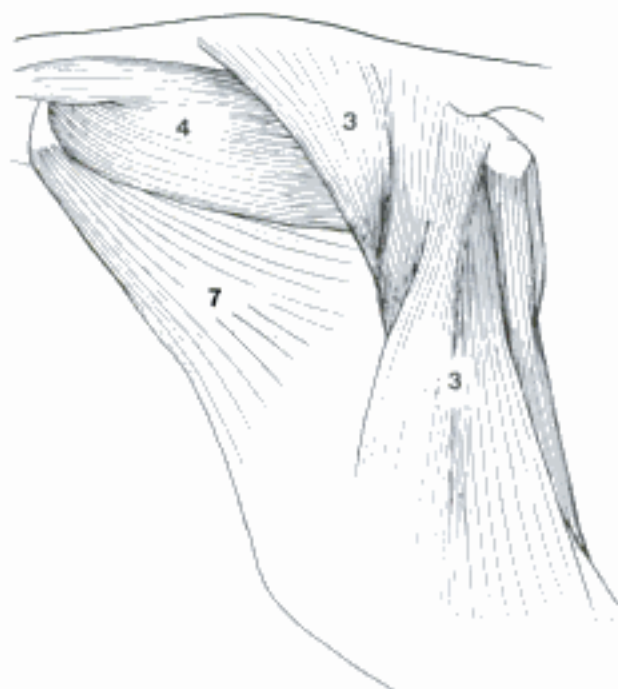


G Left Mm. iliopsoas and psoas minor, ventral aspect (ca)

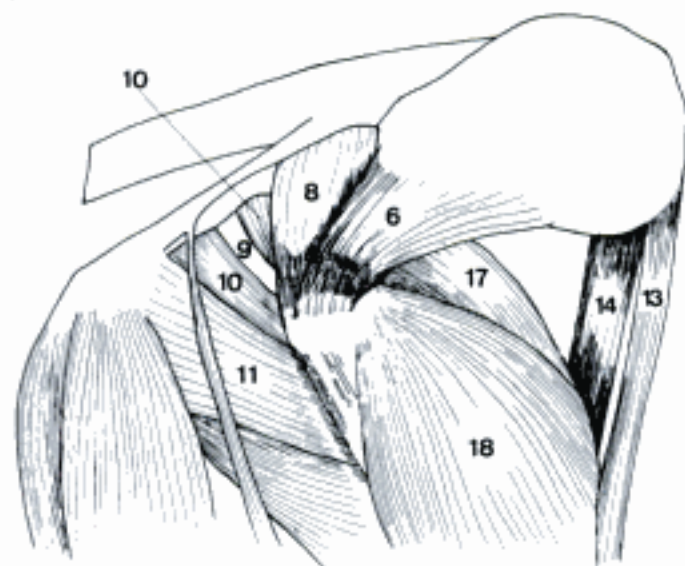
- 1 *M. gluteus [glutaeus] superficialis*. On caudal surface of *M. gluteus medius*. From Fascia glutea and Os sacrum to Tuberositas glutea (Car) or Trochanter tertius (eq). Incorporated with *M. gluteobiceps* in su and Ru. Has cranial head originating with *M. tensor fasciae latae* in eq. Extends hip joint in Car, flexes in eq. A F G
- 2 *M. gluteofemoralis [glutaeo-]*. Caudal to *M. gluteus superficialis* in fe. From first few caudal vertebrae to fascia over caudolateral surface of femur. Extends and abducts hip joint. A
- 3 *M. gluteobiceps [glutaeobiceps]*. Fusion of *M. gluteus superficialis* and cranial portion of *M. biceps femoris* in su and Ru. Extends hip joint. B
- 4 *M. gluteus [glutaeus] medius*. Large muscle of hip. On Facies glutea of ilium and in Un *M. longissimus*. Terminates on Trochanter major. Extends hip joint. A B E F G
- 5 *M. gluteus [glutaeus] accessorius*. Deep portion of *M. gluteus medius* in Un. D
- 6 *M. gluteus [glutaeus] profundus*. Deep gluteal muscle. Attaches to shaft of ilium and Spina ischiadica. Terminates on cranial portion of Trochanter major in Car, su and eq, distal to it in Ru. Abducts hip joint. C D E G
- 7 *M. tensor fasciae latae*. Fan-shaped muscle from Tuber coxae to Fascia lata. Flexes hip joint and tenses Fascia lata. A B
- 8 *M. piriformis*. Deep to caudal portion of *M. gluteus medius* in Car. From Os sacrum and Lig. sacrotuberale (ca) to Trochanter major. Extends hip joint. C
- 9 *M. obturatorius internus*. From internal surface of ischium, pubis and in eq shaft of ilium. Tendon over Incisura ischiadica minor to Fossa trochanterica. The term should be used to refer only to the muscle in Car and eq, innervated by a branch of N. ischiadicus. Supinates hip joint. C F
- 10 *Mm. gemelli*. Twin muscles from lateral border of ischium to Fossa trochanterica. Supinate hip joint. C E F
- 11 *M. quadratus femoris*. From ventral surface of ischium, inserts distal to Fossa trochanterica. Supinates hip joint. C F
- 12 *M. sartorius*. From Fascia iliaca (Un) and Corpus ossis ilii (su) or Tuber coxae (Car) to medial side of proximal portion of tibia by Fascia cruris. Flexes hip joint, adductor in Un. A E
- 13 *Pars cranialis (ca)*. C
- 14 *Pars caudalis (ca)*. C
- 15 *M. articularis coxae*. Small muscle deep to *M. rectus femoris* across hip joint in Car and eq. D E G
- 16 *M. quadriceps femoris*. Large group cranial in thigh. Four heads converge upon patella and terminate by patellar ligaments onto Tuberositas tibiae. Extends stifle joint. C D
- 17 *M. rectus femoris*. Arises from areas cranial to acetabulum. Also flexes hip joint. C D E
- 18 *M. vastus lateralis*. Arises from proximal portion of craniolateral surface of Os femoris, from Trochanter major in Ru. C D F G
- 19 *M. vastus intermedius*. Arises from cranial surface of Os femoris. D F
- 20 *M. vastus medialis*. Arises along medial surface of Os femoris. D F G



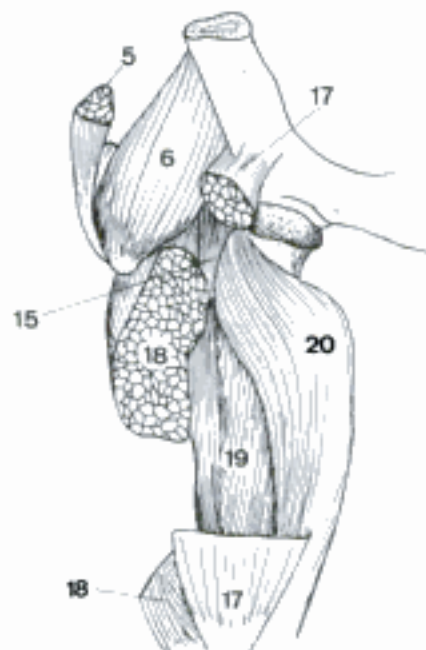
A Muscles of the left hip and thigh, lateral aspect (fe)



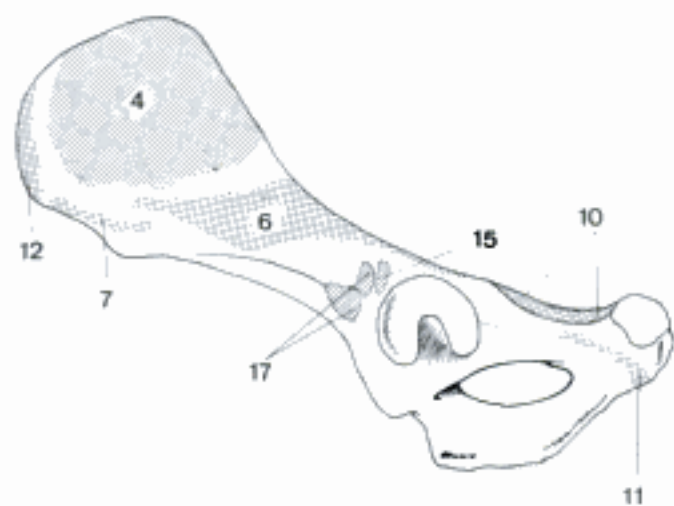
B Muscles of the left hip and thigh, lateral aspect (cap)



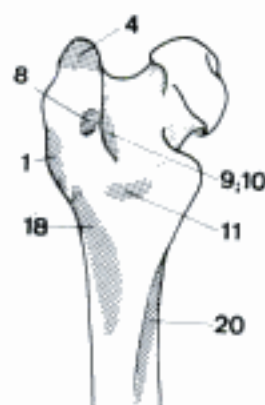
C Deep muscles of the right hip and thigh, lateral aspect (ca)



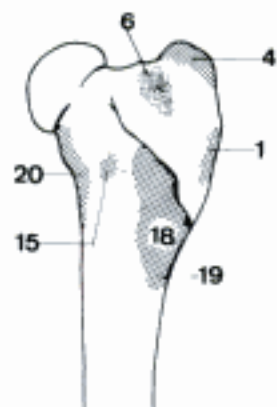
D Deep muscles of the right hip and thigh, cranial aspect (eq)



E Left Os coxae, lateral (and ventral), aspect (ca)

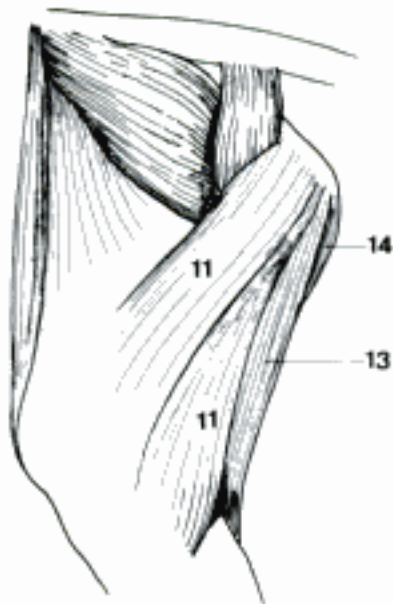


F Proximal part of the left femur, caudal aspect (ca)

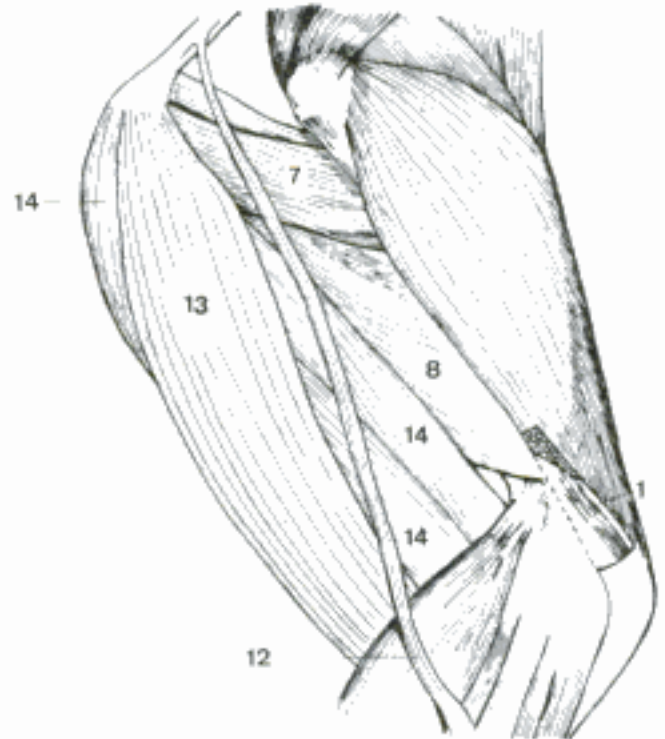


G Proximal part of the left femur, craniolateral aspect (ca)

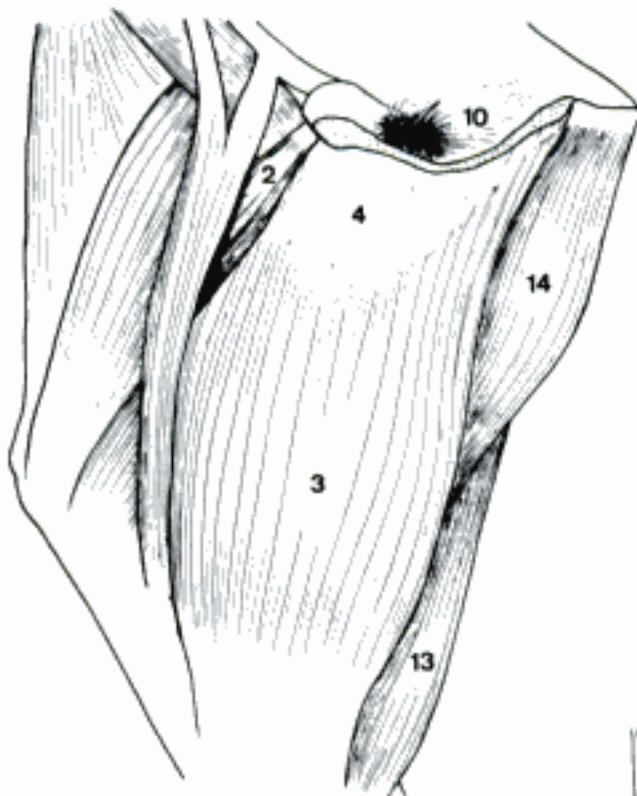
- 1 *M. articularis* genus. Small muscle deep to termination of *M. quadriceps femoris* in Car. Tenses stifle joint capsule. B
- 2 *M. pectineus*. From contra- and ipsilateral Pecten ossis pubis and Eminentia iliopubica to Labium mediale. C
- 3 *M. gracilis*. Flat superficial adductor of thigh. From Symphysis pelvina by Tendo symphysialis to Fascia cruris on medial surface of proximal portion of the crus. C
- 4 *Tendo symphysialis*. Median tendon of origin of *Mm. graciles* and *Mm. adductores*. C
- 5 *M. adductor*. Undivided as in Un or consists of as many as three portions. B E
- 6 *M. adductor longus*. Small fusiform muscle of fe which arises from pubis to terminate on Labium mediale of Facies aspera. In other species part of *M. pectineus*. E
- 7 *M. adductor brevis*. Usually (except fe and often ca) united with magnus. Represents proximal portion. B
- 8 *M. adductor magnus*. Usually (except fe and often ca) united with brevis. From Tendo symphysialis, Ramus caud. ossis pubis, and Ramus ossis ischii to Facies aspera, in eq also Condylus med. femoris. B
- 9 *M. obturatorius externus*. From ventral surface of pelvis. Tendon courses laterally to terminate in Fossa trochanterica. E
- 10 *Pars intrapelvina*. Arises from dorsal surface of floor of pelvis in Artiodactyla. Passes through Foramen obturatum to join main portion of *M. obturatorius externus*. C
- 11 *M. biceps femoris*. Arises by two heads from Os sacrum (eq), Ligamentum sacrotuberale latum, Tuber ischiadicum. Fused with *M. gluteus superficialis* in su and Ru. Termination spreads out lateral to Fascia lata, Fascia cruris, and Tendo calcaneus communis. Extends hip joint and flexes stifle joint in free limb, extends hip, stifle, and tarsal joints when bearing weight. A
- 12 *M. abductor cruris caudalis*. (Car). Long strap-like muscle deep to *M. biceps femoris*. Abducts limb. B
- 13 *M. semitendinosus*. Arises from Tuber ischiadicum, descends over *M. gastrocnemius* to terminate on medial surface of proximal portion of tibia and Tendo calcaneus communis. Has cranial origin from Lig. sacrotuberale latum in su and eq. Extends hip and flexes stifle joint in free limb, extends hip, stifle, and tarsal joints when bearing weight. A B C
- 14 *M. semimembranosus*. From Tuber ischiadicum, cranial origin from Lig. sacrotuberale latum in eq. Terminates on medial condyles of femur and tibia. Is divided longitudinally in Car, su, and Ru. Extends and adducts hip joint. A B C
- 15 *M. tibialis cranialis*. From Facies lateralis tibiae. Terminates medially on tarsal and metatarsal bones. Flexes tarsal joint. D F G
- 16 *M. extensor digitorum [digitalis] longus*. From Fossa extensoria femoris. Tendon splits to terminate on Phalanx distalis of each digit. Has a medial portion with an independent tendon to digit III in Ru, II and III in su. Flexes tarsal, extends stifle and phalangeal joints. D F G
- 17 *M. peroneus [peronaeus, fibularis] tertius*. Tendinous in eq, well developed in Artiodactyla and little in Car. From Fossa extensoria to terminate on proximal part of metatarsus. Extends stifle and flexes tarsal joints. G
- 18 *M. extensor digiti I [hallucis] longus* (Car, su, ov). Delicate muscle from fibula to mediolateral portion of metatarsus. Weak flexor of tarsal joint. F
- 19 *M. peroneus [peronaeus, fibularis] longus*. Arises on Condylus lateralis tibiae and Caput fibulae. Tendon passes over lateral surface of tarsus to terminate on plantar side of medial tarsal or metatarsal bones. Absent in eq. Flexes tarsal joints, pronator in Car. D
- 20 *M. extensor digitorum [digitalis] lateralis*. Arises from proximal portion of fibula. Terminates by uniting with long extensor tendon in eq, of digit V in Car, inserts independently on digits IV and V in su, IV in Ru. Extends phalangeal joints of corresponding digitis. D G
- 21 *M. peroneus [peronaeus, fibularis] brevis*. Terminates on Basis ossis metatarsalis V in Car. Weak flexor of tarsal joint. D



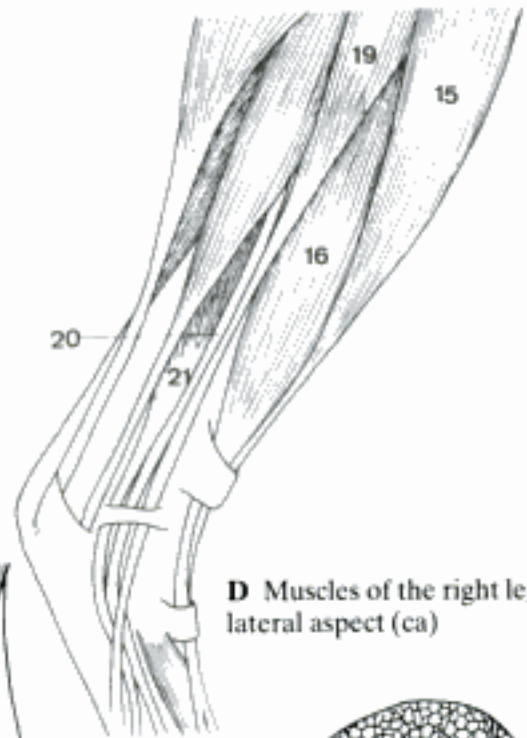
A Muscles of the left thigh, lateral aspect (ca)



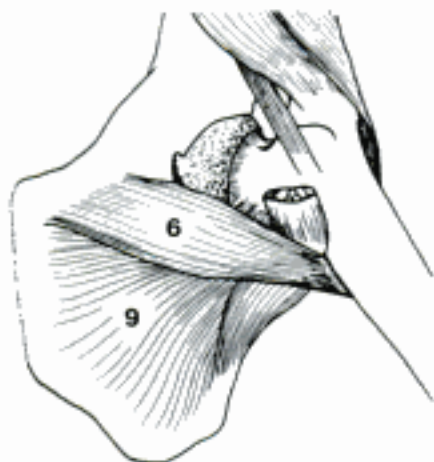
B Muscles of the right thigh, lateral aspect (ca)



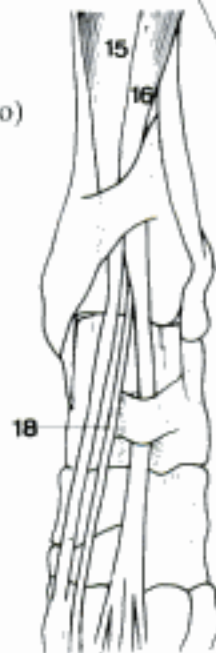C Muscles of the right thigh, medial aspect (bo)



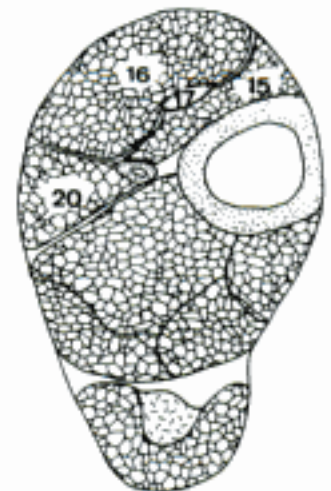
D Muscles of the right leg, lateral aspect (ca)



E Left M. adductor longus and M. obturatorius externus, medioventral aspect (fe)

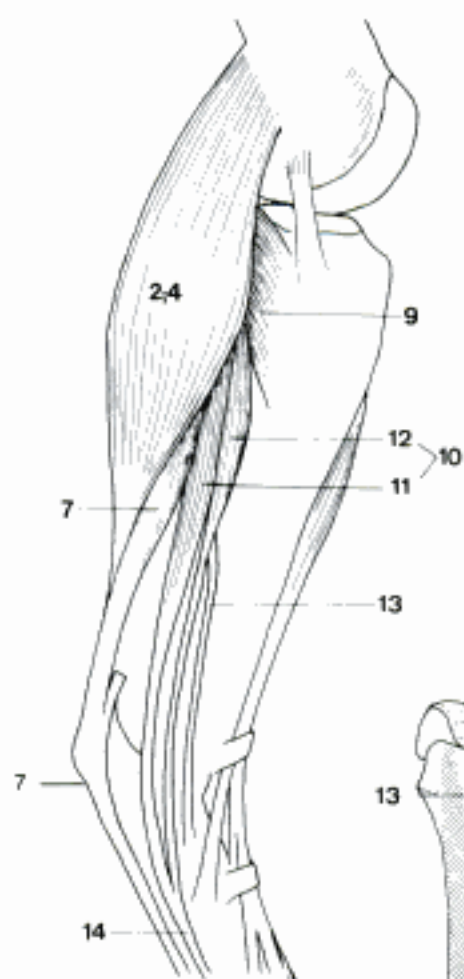


F Left tarsus, dorsal aspect (ca)

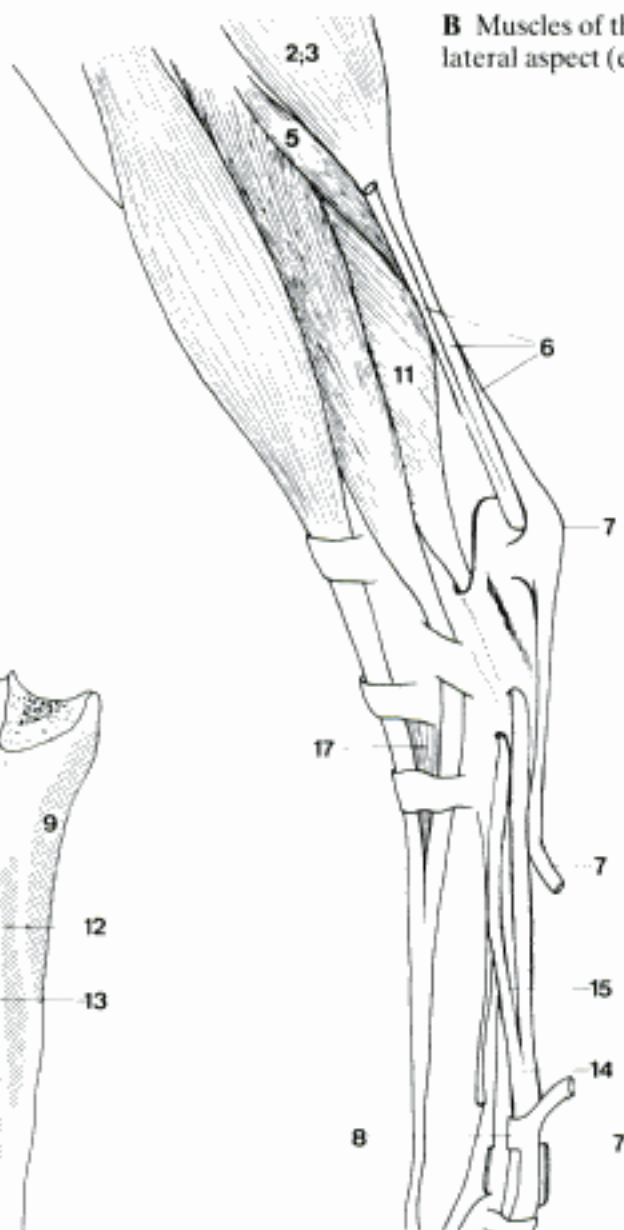


G Left leg, transverse section, proximal surface (eq)

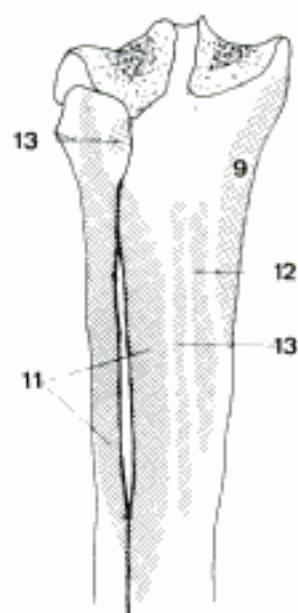
- 1 *M. triceps surae*. Two heads of *M. gastrocnemius* and *M. soleus*. Flexes stifle and extends tarsal joints.
- 2 *M. gastrocnemius*. Consists of two heads, terminates by long tendon on Tuber calcanei. A B
- 3 Caput laterale. From Tuberositas supracondylaris lateralis femoris. B
- 4 Caput mediale. From Tuberositas supracondylaris medialis femoris. A
- 5 *M. soleus*. From fibula to join tendon of Caput laterale *m. gastrocnemii*. Not present in ca. B
- 6 *Tendo calcaneus communis*. Combined tendons of *Mm. triceps surae*, flexor digit. superficialis, biceps femoris, and semitendinosus. Attaches to Tuber calcanei. B
- 7 *M. flexor digitorum [digitalis] superficialis*. Arises from Fossa supracondylaris femoris. Tendon passes medial side of tendon of *M. gastrocnemius* to Tuber calcanei. Descends to digits and inserts on middle phalanx. Tendinous throughout in eq. Flexes stifle and phalangeal, extends tarsal joints. A B D F
- 8 *Manica flexoria*. The sleeve formed by each tendon of *M. flexor digit. superficialis* around the corresponding tendon of *M. flexor digit. profundus* at the level of *Articulatio metatarsophalangea*. B
- 9 *M. popliteus*. Triangular muscle arising by tendon from *Condylus lateralis femoris*. Terminates on *Facies caudalis tibiae* as far as *Linea poplitea*. Flexes and pronates stifle joint. A C
- 10 *Mm. flexores digitorum [digitales] profundi*. The tendons of *Mm. flexores digit. lateralis* and *medialis* (in Un also *M. tibialis caudalis*) unite to deep flexor tendon. This divides to terminate on flexor surface of each distal phalanx. Extend tarsal and flex phalangeal joints. A
- 11 *M. flexor digitorum [digitalis] lateralis*. Main portion of deep flexors. Originates caudal on tibia and fibula. Descends over *Sustentaculum tali*. A B C
- 12 *M. flexor digitorum [digitalis] medialis*. Arises between *M. flexor digit. lateralis* and *M. popliteus*. Long tendon joins deep flexor tendon distal to tarsus. A C
- 13 *M. tibialis caudalis*. Small head of deep flexors. Does not join main tendon in Car. A C
- 14 *Tendo communis*. Common tendon of *Mm. flexores digit. profundi*. A B D F
- 15 *Lig. accessorium*. Fibrous continuation of plantar tarsal ligaments to deep digital flexor tendon in eq. B
- 16 *Mm. interflexorii*. 2 (ca) or 3 (fe) bundles from plantar surface of deep digital flexor tendon to superficial digital flexor tendons. D
- 17 *M. extensor digitorum [digitalis] brevis*. From tarsus to tendons of *M. extensor digit. longus* (in eq also *lateralis*). B
- 18 *M. abductor digiti I [hallucis]*. Lies medial on plantar surface of metatarsus if digit I is present in ca. E
- 19 *M. flexor digiti I [hallucis] brevis*. Middle muscle on plantar surface of metatarsus if digit I is present in ca. E
- 20 *M. adductor digiti I [hallucis]*. Medial muscle on plantar surface of metatarsus if digit I is present in ca. E
- 21 *M. abductor digiti II*. Small muscle in su from plantar surface of tarsus to proximal phalanx of digit II. F
- 22 *M. adductor digiti II*. From plantar tarsal ligaments to axial side of proximal phalanx of digit II in Car and su. E F
- 23 *M. abductor digiti V*. From lateral part of tarsus to proximal phalanx of digit V in su. F
- 24 *M. adductor digiti V*. From plantar tarsal ligaments to axial side of proximal phalanx of digit V in Car and su. E F
- 25 *M. flexor digitorum [digitalis] brevis*. From deep surface of superficial digital flexor tendon to area of metatarsophalangeal joints, esp. in fe. D
- 26 *M. quadratus plantae [M. flexor accessorius]*. From calcaneus to deep digital flexor tendon in ca. D
- 27 *Mm. lumbricales*. From tendons of *M. flexor digitorum profundus* to proximal phalanges of digits III, IV, V in Car. D
- 28 *Mm. interossei*. On plantar surface of *Ossa metatarsalia* to proximal sesamoids. D



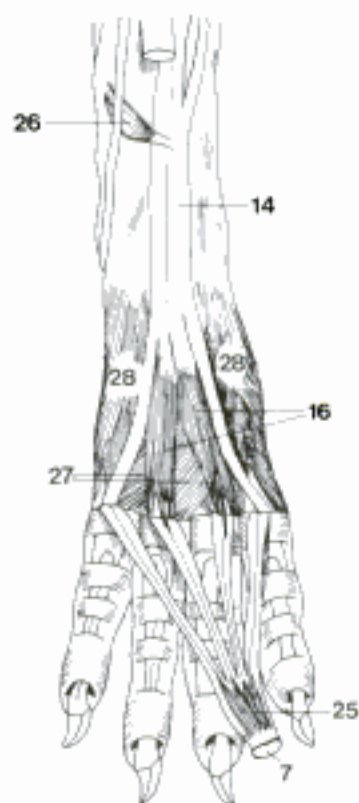
A Muscles of the left leg, medial aspect (ca)



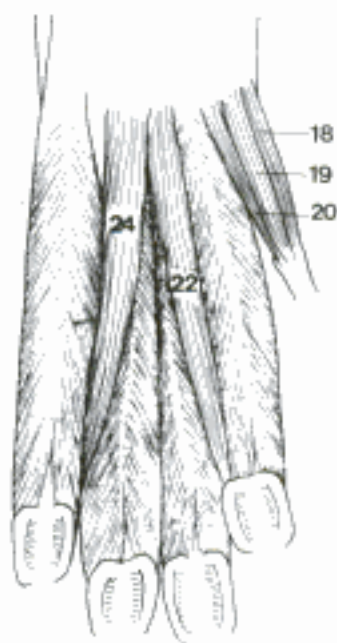
B Muscles of the left leg, lateral aspect (eq)



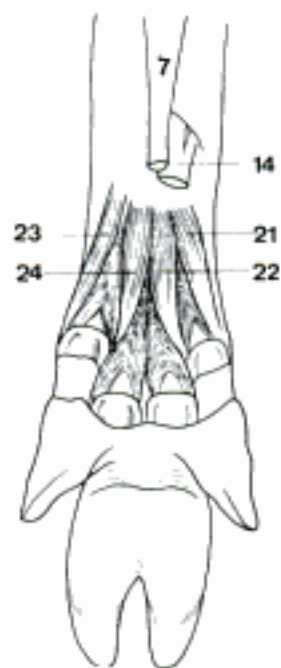
C Bones of the left leg, caudal aspect (ca)



D Left plantar muscles, plantar aspect (ca)



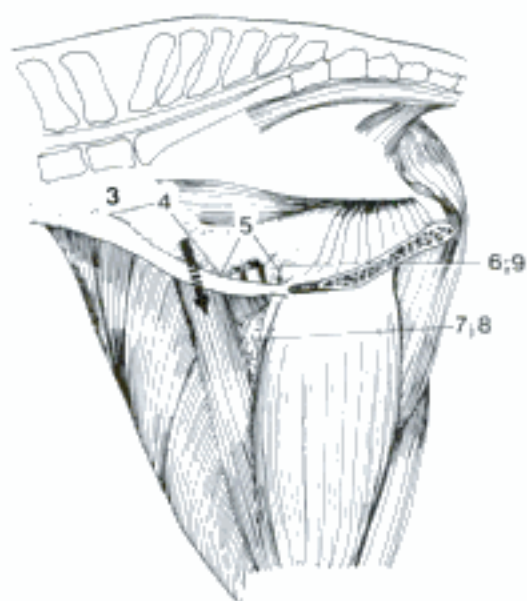
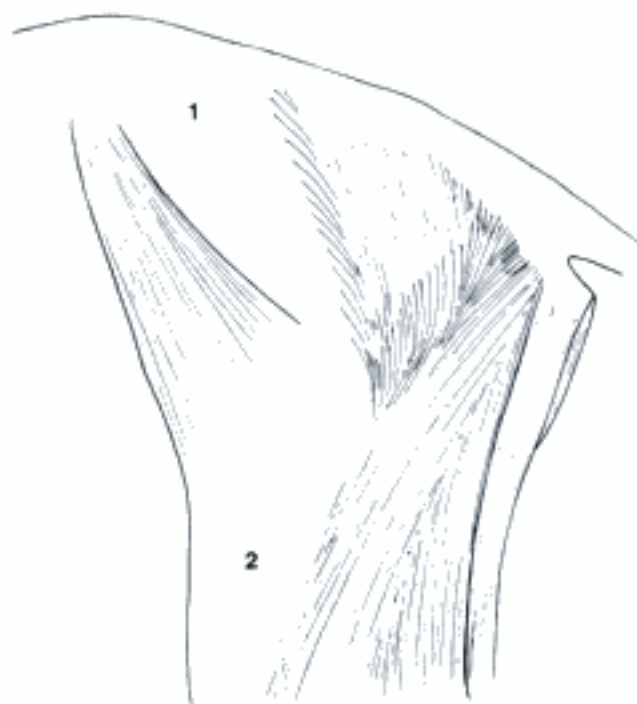
E Left plantar muscles, plantar aspect (ca)



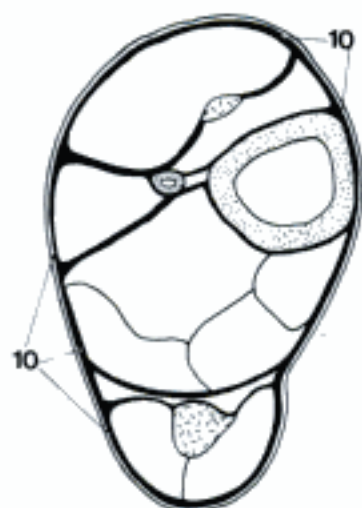
F Left plantar muscles, plantar aspect (su)

- 1 *Fascia glutea [glutaea]*. Thick deep fascia, continuation of Fascia thoracolumbalis over M. gluteus medius. Gluteal muscles arise from it. A
- 2 *Fascia lata*. Continuous with Fascia glutea over lateral surface of thigh. Insertion of M. tensor fasciae latae and M. biceps femoris. A
- 3 *Fascia iliaca*. Associated with iliac and psoas muscles. Dorsal continuation of Fascia transversalis. B
- 4 *Lacuna musculorum*. Compartment for passage of M. iliopsoas between Os ilium and Ligamentum inguinale. B
- 5 *Lacuna vasorum*. Space between Ligamentum inguinale and Os ilium for passage of femoral vessels. Caudomedial to Lacuna musculorum. B
- 6 *Anulus femoralis*. Ring of entrance from abdominal cavity into Canalis femoralis at Ligamentum inguinale. B
- 7 *Trigonum femorale*. Triangle between M. sartorius cranially and M. pectineus caudally. B
- 8 *Canalis femoralis*. Canal in medial area of femur containing femoral vessels and inguinal lymph nodes. B
- 9 *Septum femorale*. Connective tissue across entrance into Canalis femoralis. B
- 10 *Fascia cruris*. Fascia of leg. Gives attachment to muscles of thigh, binds down muscles of leg sending intermuscular septa. C
- 11 *Retinaculum extensorum crurale*. Transverse reinforcement of Fascia cruris binding down M. extensor digit. longus, M. tibialis cranialis, and M. peron. tertius. D E F
- 12 *Retinaculum extensorum tarsale*. Tarsal retaining band binding down M. extensor digitorum longus, absent in Ru. D E F
- 13 *Retinaculum extensorum metatarsale*. Metatarsal retaining band in Ru and eq, binding down long and lateral digital extensor tendons. D
- 14 *Retinaculum mm. peron. [fibularium]*. Retaining band binding down Mm. peronei and extensor digit. lateralis at tarsus. E
- 15 *Retinaculum flexorum*. Plantar retaining band binding down Mm. flexores digit. profundi at tarsus. F
- 16 *Fascia dorsalis pedis*. Retains and invests dorsal tendons of pes. G
- 17 *Fascia plantaris*. Retains and invests plantar structures of pes. G
- 18 *Fascia digiti*. See 122. 6
- 19 *Lig. metatarsium transversum superficiale [Lig. anulare plantare]*. See 122. 7
- 20 *Vaginae fibrosae digitorum pedis*. See 122. 8
- 21 *Pars annularis vaginae fibrosae [Lig. anulare digiti]*. See 122. 9
- 22 *Pars cruciformis vaginae fibrosae*. See 122. 10
- 23 *Scutum proximale*. See 122. 11
- 24 *Scutum medium*. See 122. 12
- 25 *Scutum distale*. See 122. 13
- 26 *Vaginae synoviales tendinum digitorum pedis*. See 122. 14
- 27 *Vincula tendinum*. See 122. 15

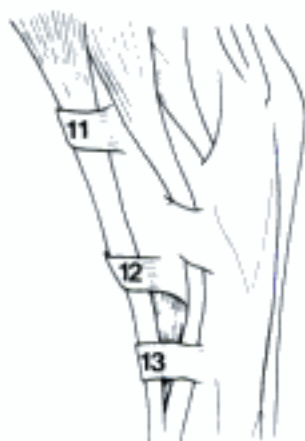A Fasciae of the left hip and thigh (bo)



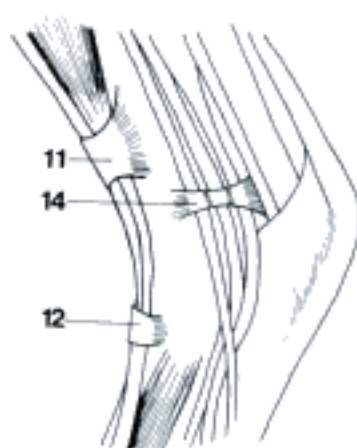
B Pelvis (median section) and right thigh, medial aspect (eq)



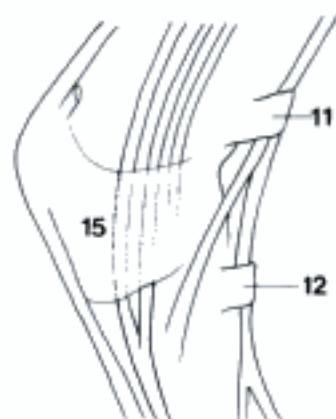
C Left leg, transverse section, proximal surface (eq)



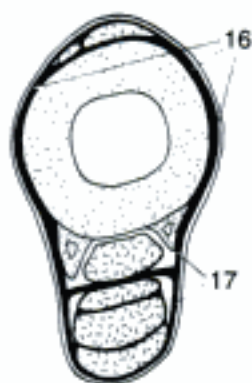
D Left tarsus, lateral aspect (eq)



E Left tarsus, lateral aspect (ca)

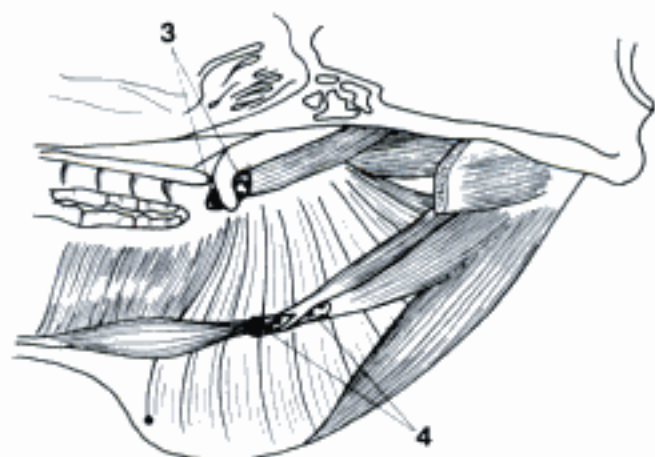


F Left tarsus, medial aspect (ca)

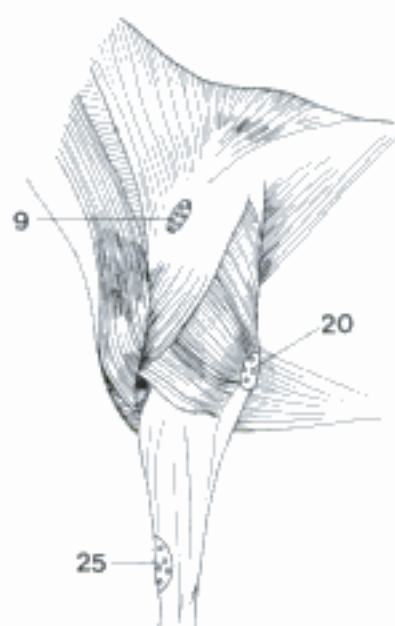


G Left metatarsus, transverse section, proximal surface (eq)

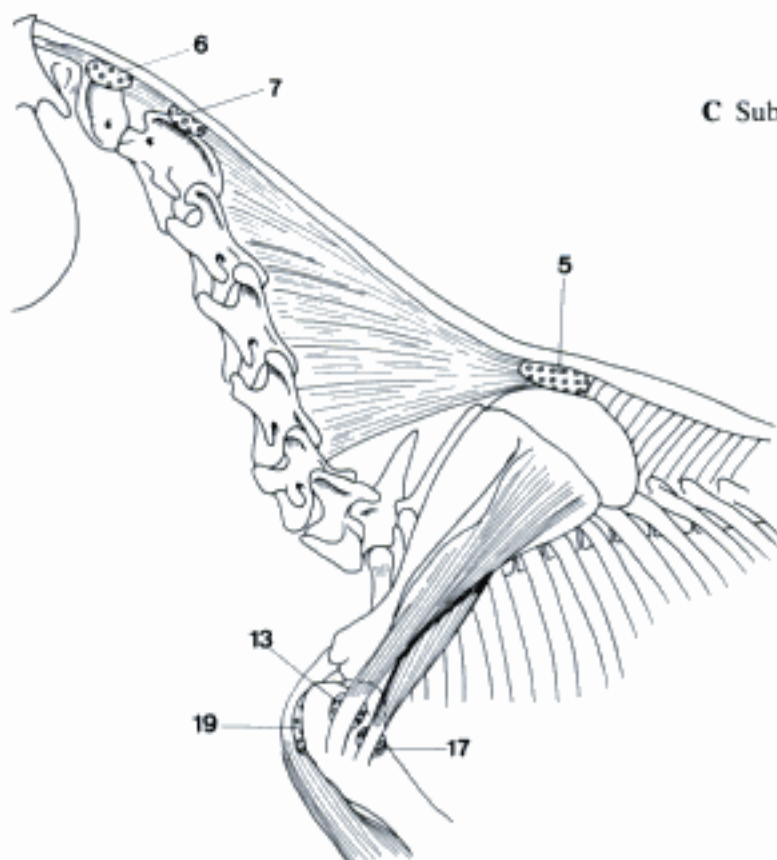
- 1 **Bursae et vaginae synoviales capitis et trunci.** Synovial bursae and tendon sheaths of the head and trunk.
- 2 *Vag. synovialis m. obliqui dorsalis.* Synovial sheath around tendon of *M. obliquus dorsalis bulbi* where it contacts trochlea. See *Mm. bulbi*.
- 3 *B. m. tensoris veli palatini.* Bursa for tendon of *M. tensor veli palatini* where it contacts *Hamulus pterygoideus*. A
- 4 *Vag. tendinis m. digastrici.* Synovial sheath around intermediate tendon of *M. digastricus* where it perforates tendon of insertion of *M. stylohyoideus* in eq. A
- 5 *B. subligamentosa supraspinalis.* Bursa between *Ligamentum nuchae* and the spines of 2nd, 3rd, and 4th thoracic vertebrae in eq. B
- 6 *B. sublingamentosa nuchalis cranialis.* Bursa between *Ligamentum nuchae* and *Mm. recti dorsales* over *Tuberculum dorsale* of atlas in eq, inconstant. B
- 7 *B. subligamentosa nuchalis caudalis.* Bursa between *Ligamentum nuchae* and spine of axis in eq (and ca), inconstant. B
- 8 **Bursae et vaginae synoviales membri thoracici.** Synovial bursae and tendon sheaths of the thoracic limb. Many listed bursae are inconstant.
- 9 *B. subcutanea prescapularis [prae-] (eq).* Bursa between skin and *Tuber spinae scapulae*. C
- 10 *B. subdeltoidea.* Bursa under *Pars acromialis* as it passes over tendon of *M. infraspinatus* in Car and bo. D
- 11 *B. subtendinea m. coracobrachialis.* Bursa under tendon of origin medial to shoulder joint in Un. E
- 12 *Vag. synovialis m. coracobrachialis.* Synovial sheath around tendon of origin in Car. F
- 13 *B. subtendinea m. infraspinati.* Bursa between tendon of insertion and *Pars caudalis* of *Tuberculum majus humeri*. B
- 14 *B. subtendinea m. supraspinati (su).* Bursa between *M. supraspinatus* and *Tuberculum majus humeri*. E
- 15 *B. subtendinea m. subscapularis.* Bursa under tendon of insertion as it passes over shoulder joint, only recess of joint capsule in Car. F
- 16 *B. subtendinea m. teretis majoris (su).* Bursa deep to tendon of insertion occurs sometimes also in ca. E
- 17 *B. subtendinea m. teretis minoris.* Bursa between tendon of insertion and humerus just caudal and distal to that of *M. infraspinatus* in Un. B
- 18 *Vag. synovialis intertubercularis.* In Car, su, and ov the tendon of *M. biceps brachii* is provided with synovial tendon sheath as it passes through *Sulcus intertubercularis humeri*. E F
- 19 *B. intertubercularis.* In cap, bo, and eq there is a synovial bursa for *M. biceps brachii*. B
- 20 *B. subcutanea olecrani.* Bursa between skin and olecranon. C
- 21 *B. intratendinea olecrani.* Bursa between tendons of insertion of *Caput mediale* and *Caput longum m. tricipitis* on olecranon. G
- 22 *B. subtendinea m. tricipitis brachii.* Bursa between tendon of insertion and olecranon. G
- 23 *B. bicipitoradialis.* Bursa between radius and insertion of *M. biceps brachii*. G
- 24 *B. subtendinea m. brachialis.* Bursa beneath tendon of insertion of *M. brachialis* on radius. G
- 25 *B. subcutanea precarpalis [prae-].* Bursa deep to skin on dorsal surface of carpus in Ru and eq. C



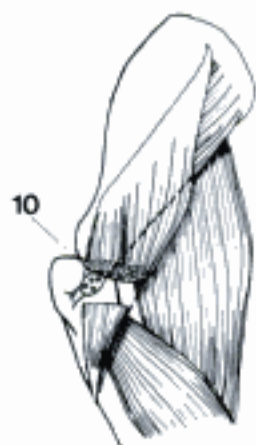
A B. m. tensoris veli palatini and synovial sheath of M. digastricus, right side, medial aspect (eq)



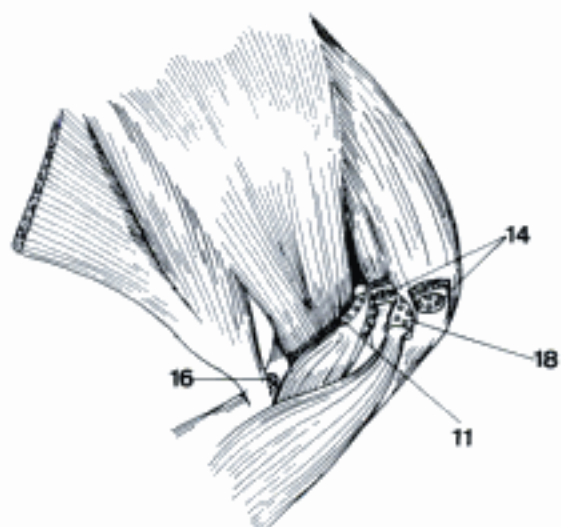
C Subcutaneous bursae of the thoracic limb (eq)



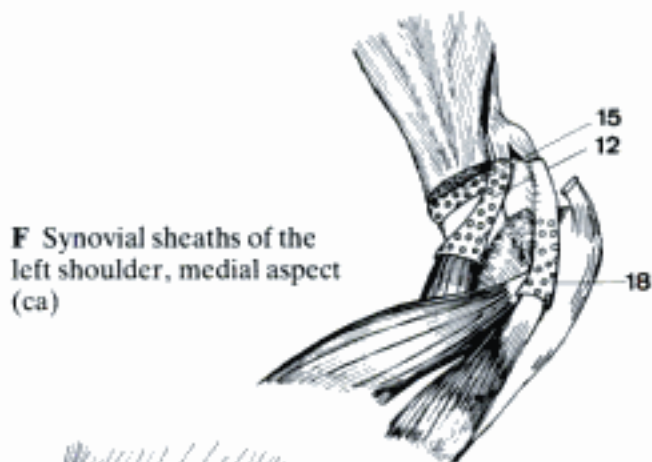
B Bursae of the neck and left shoulder (eq)



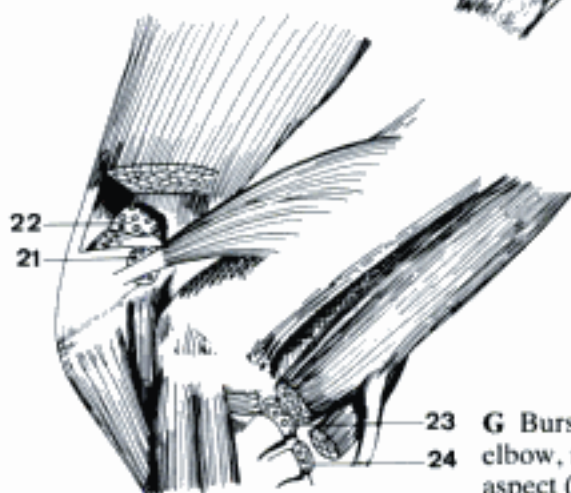
D Left B. subdeltoidea, lateral aspect (ca)



E Bursae of the left shoulder, medial aspect (su)

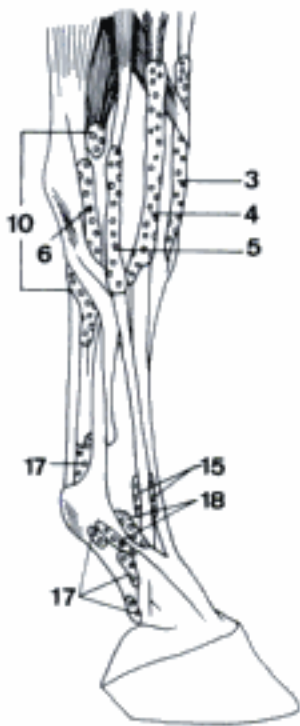


F Synovial sheaths of the left shoulder, medial aspect (ca)

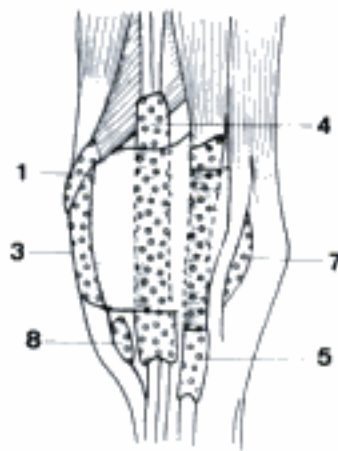


G Bursae of the left elbow, medial aspect (eq)

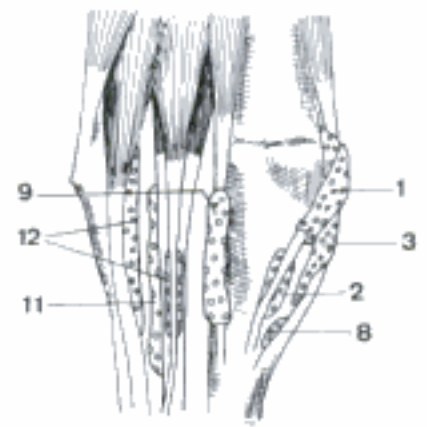
- 1 *Vag. tendinis m. abductoris digiti I [pollicis] longi [m. extensoris carpi obliqui]*. Synovial sheath around tendon of insertion over dorsomedial surface of carpus. B C
- 2 *B. subtendinea m. abductoris digiti I [pollicis] longi [m. extensoris carpi obliqui] (bo, eq)*. C
- 3 *Vag. tendinis m. extensoris carpi radialis*. Synovial sheath around tendon or tendons (Car) of insertion crossing medial part of cranial surface of radius and dorsal surface of carpus. A B C
- 4 *Vag. tendinis m. extensoris digit. communis*. Synovial sheath around tendon or tendons crossing cranial surface of radius and dorsal surface of carpus. A B
- 5 *Vag. tendinis m. extensoris dig. lateralis manus*. Synovial sheath around tendon or tendons crossing lateral surface of carpus, in su in most cases two sheaths. A B
- 6 *Vag. tendinis m. extensoris carpi ulnaris [m. ulnaris lateralis]*. Synovial sheath around long tendon of insertion over lateral surface of carpus in eq. A
- 7 *B. subtendinea m. extensoris carpi ulnaris [m. ulnaris lateralis]*. Bursa deep to long tendon of insertion over lateral surface of carpus in su and Ru, over ulna in Car. B
- 8 *B. subtendinea m. extensoris carpi radialis*. Bursa under insertion at dorsal surface of proximal end of metacarpus in Ru and eq. B C
- 9 *Vag. tendinis m. flexoris carpi radialis*. Synovial sheath around tendon of insertion as it crosses medial portion of palmar surface of carpus. C
- 10 *Vag. synovialis communis mm. flexorum*. Synovial sheath common to both digital flexor tendons in carpal canal and proximal and distal to it in eq. A
- 11 *B. subtendinea m. flexoris digit. profundi*. Bursa deep to tendons in carpal canal in Car, su, and Ru. C
- 12 *Bb. m. flexoris digit. superficialis*. Bursae under two tendons of M. flexor digit. superficialis in Ru, one for superficial tendon in su. C
- 13 *Vag. tendinis m. flexoris carpi ulnaris (Car)*. Synovial tendon sheath around tendon of insertion at Os carpi accessorium. E
- 14 *B. subtendinea m. extensoris digit. communis (Ru, eq)*. Bursa between tendon of medial portion of M. extensor digit. communis and dorsal side of medial metacarpophalangeal joint in Ru and tendon of M. extensor digit. communis and metacarpophalangeal joint in eq. D F
- 15 *B. subtendinea m. extensoris digit. lateralis manus (Ru, eq)*. Bursa between tendon of M. extensor digit. lateralis and dorsal side of lateral metacarpophalangeal joint in Ru and tendon of M. extensor digit. lateralis and metacarpophalangeal joint in eq. A D
- 16 *Vag. distalis tendinum m. extensoris digit. communis (Ru)*. Synovial sheath begins proximal to metacarpophalangeal joints, divides for the both tendons to Phalanx distalis of 3rd and 4th digit. D
- 17 *Vag. synovialis tendinum digitorum manus*. Synovial sheaths common to deep and superficial flexor tendons to each digit in manus. A E F
- 18 *Bb. subtendineae mm. interosorum manus*. Bursa under each tendon as it crosses side of metacarpophalangeal joint on way to common digital extensor tendon in eq. A
- 19 *Bb. podotrochleares manus*. Bursa between deep digital flexor tendon and distal sesamoid bone for each digit in Un. F



A Bursae and synovial sheaths of the right manus, lateral aspect (eq)

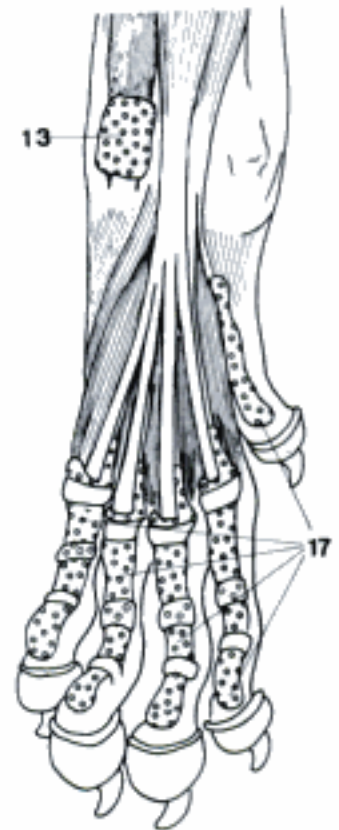
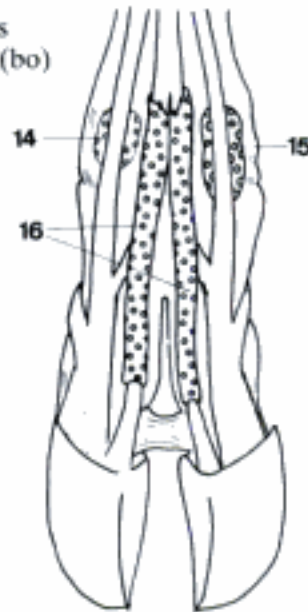


B Bursae and synovial sheaths of the left carpus, dorsolateral aspect (bo)

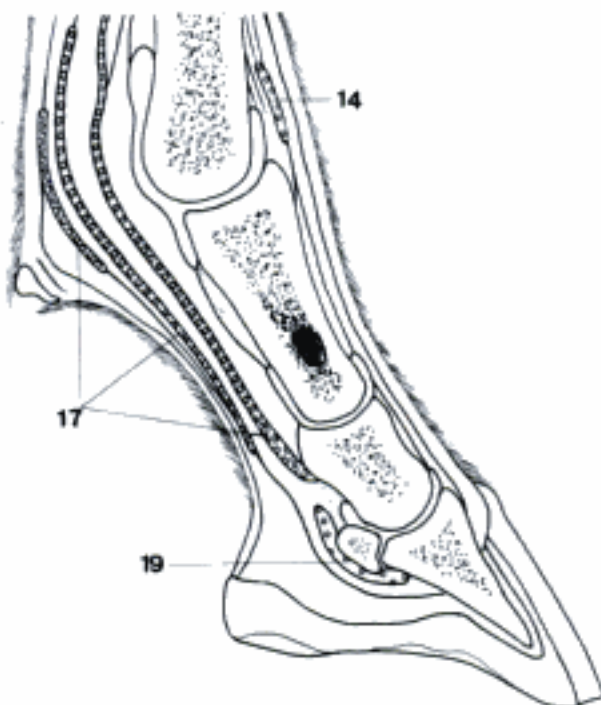


C Bursae and synovial sheaths of the left carpus, medial aspect (bo)

D Bursae and synovial sheaths of the left digits, dorsal aspect (bo)

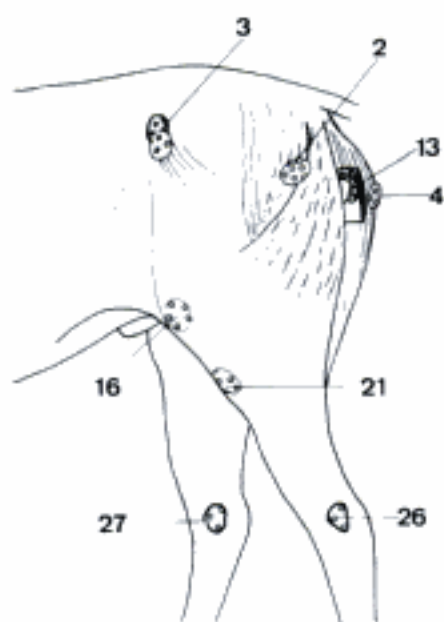


E Synovial sheaths of the left manus, palmar aspect (ca)

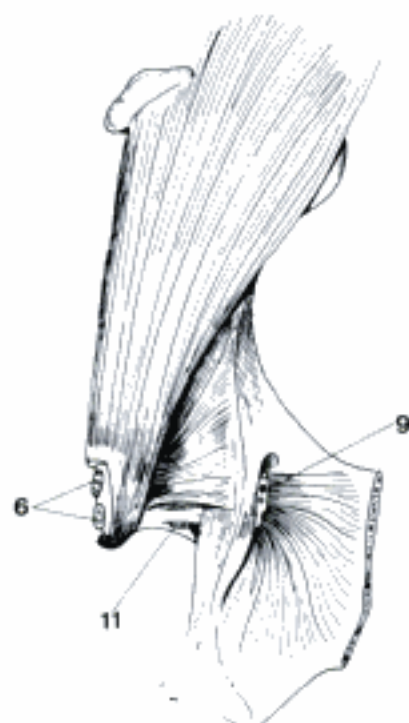


F Bursae and synovial sheaths of the digit, sagittal section (eq)

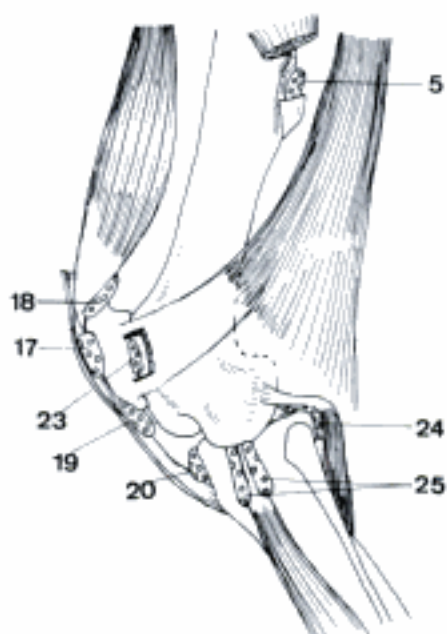
- 1 **Bursae et vaginae synoviales membri pelvini.** Synovial bursae and tendon sheaths of the pelvic limb. Many listed bursae are inconstant.
- 2 *B. subcutanea trochanterica.* Bursa between skin and muscles over Trochanter major in eq. A
- 3 *B. subcutanea iliaca [coxalis].* Bursa between skin and Tuber coxae. A
- 4 *B. subcutanea ischiadica.* Bursa between skin and M. semitendinosus over Tuber ischiadicum in eq, skin and Tuber in bo (and ca). A
- 5 *B. trochanterica m. glutei [glutaei] superficialis.* Bursa between tendon of insertion and Trochanter tertius in eq, Trochanter major in ca. C
- 6 *Bb. trochantericae m. glutei [glutaei] medii.* Bursa deep to tendon of M. gluteus accessorius on Pars cranialis of Trochanter major in eq, 2 or 3 bursae cranial to trochanter in su and Ru. B
- 7 *B. trochanterica m. glutei [glutaei] profundi.* Bursa under insertion of muscle. E
- 8 *B. ischiadica m. obturatorii interni (Car, eq).* Bursa between muscle and Incisura ischiadica minor. F
- 9 *B. ischiadica m. obturatorii externi (su, Ru).* Bursa between Pars intrapelvina and lateral edge of Foramen obturatum. B
- 10 *B. subtendinea m. obturatorii interni (Car, eq).* Bursa in Fossa trochanterica as tendon inserts. F
- 11 *B. subtendinea m. obturatorii externi (su, Ru).* Bursa in Fossa trochanterica as tendon inserts. B
- 12 *B. trochanterica m. bicipitis femoris.* Bursa deep to muscle as it passes over Trochanter major. E
- 13 *B. ischiadica m. semitendinosi.* Bursa deep to long head of muscle as it passes over Tuber ischiadicum in eq. A
- 14 *B. m. recti femoris.* Bursa between origin of muscle and Os ilium, in ca also between muscle and distal third of Corpus ossis femoris. F
- 15 *B. subtendinea iliaca.* Bursa deep to tendon of insertion of M. iliopsoas in bo (and ca). E
- 16 *B. subcutanea prepatellaris [prae-].* Bursa between skin and prepatellar fascia. A
- 17 *B. subfascialis prepatellaris [prae-].* Bursa deep to prepatellar fascia. C F
- 18 *Bb. subtendineae prepatellares [prae-].* Bursae deep to tendons of insertion of components of M. quadriceps femoris. B D
- 19 *B. infrapatellaris proximalis (eq).* Bursa between Lig. patellae intermedium and patella. C
- 20 *B. infrapatellaris distalis.* Bursa between Lig. patellae and tibia. C
- 21 *B. subcutanea tuberositatis tibiae.* Bursa between skin and Tuberositas tibiae. A
- 22 *B. subtendinea m. semitendinosi.* Bursa deep to tendon of insertion of muscle on tibia. D
- 23 *B. subtendinea m. bicipitis femoris distalis.* Bursa under insertion of muscle as it passes over Condylus lateralis femoris in Ru, on its insertion to lateral portion of patella in eq. C
- 24 *Recessus subpopliteus.* Synovial extension beneath tendon of origin of M. popliteus over Condylus lateralis tibiae. C
- 25 *Recessus subextensorius.* Synovial extension beneath tendon of origin of M. extensor digitorum longus and M. peron. III (except Car) as it passes through Sulcus extensorius tibiae. C
- 26 *B. subcutanea malleoli lateralis.* Bursa beneath skin over Malleolus lateralis tibiae. A
- 27 *B. subcutanea malleoli medialis.* Bursa beneath skin over Malleolus medialis tibiae. A



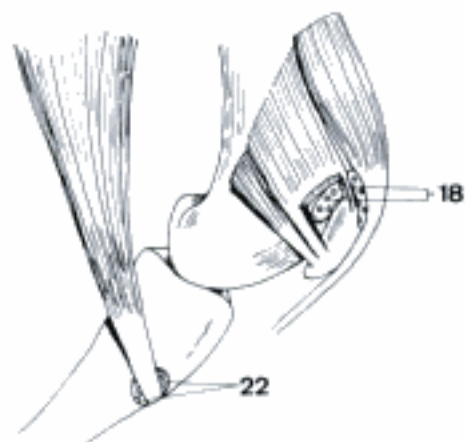
A Subcutaneous bursae of the pelvic limb (eq)



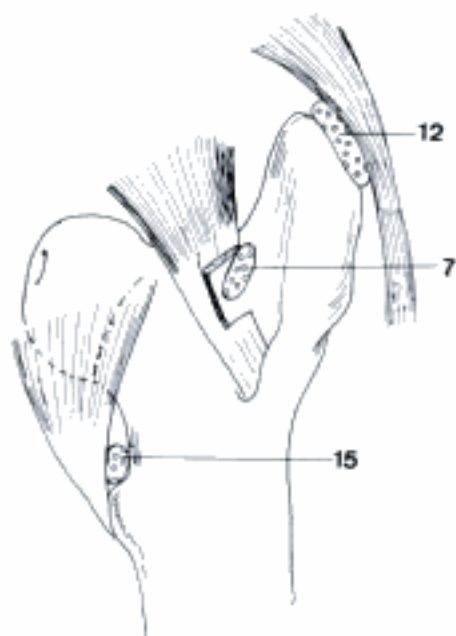
B Bursae of the left hip, dorsal aspect (bo)



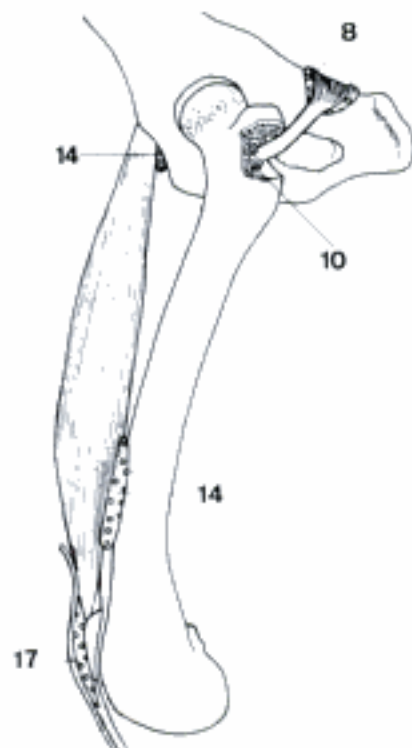
C Bursae and recesses of the left stifle, lateral aspect (eq)



D Bursae of the left stifle, medial aspect (eq)

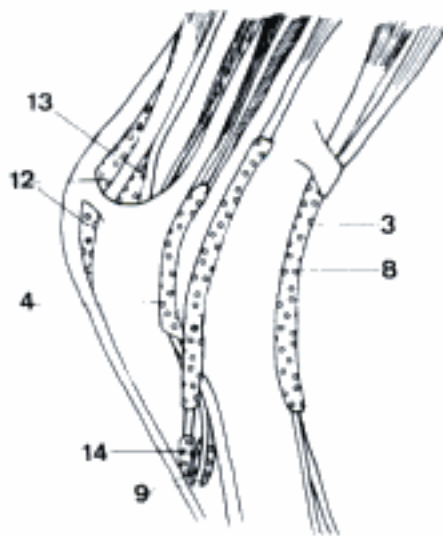


E Bursae of the left thigh, cranial aspect (bo)

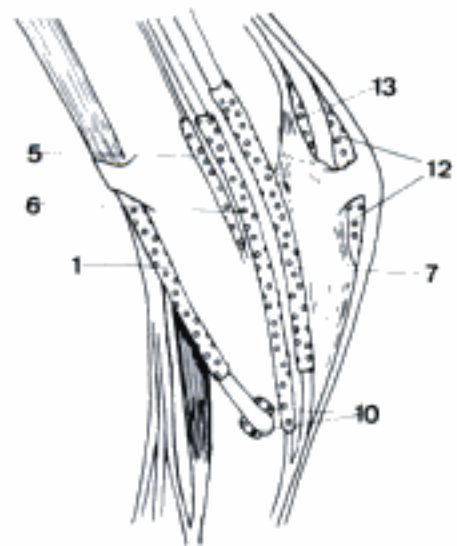


F Bursae of the left thigh and stifle, lateral aspect (ca)

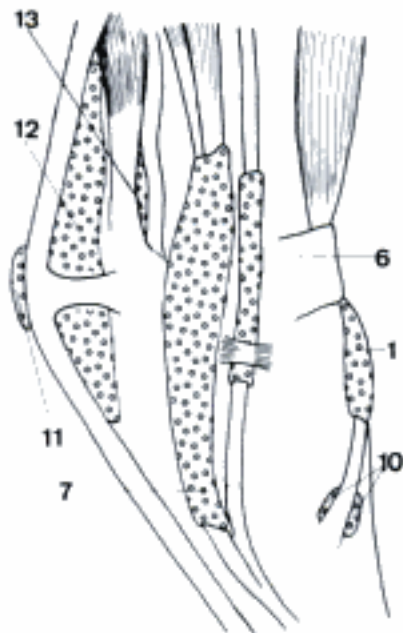
- 1 *Vag. tendinis m. tibialis cranialis*. Synovial sheath around tendon of insertion on dorsomedial surface of tarsus. Fuses with 2 and 3 in su and Ru. B C
- 2 *Vag. tendinis m. peron. [fibularis] tertii (su, Ru)*. Synovial sheath around tendon of insertion on dorsal surface of tarsus. Fuses with 1 and 3. D
- 3 *Vag. tendinum m. extensoris digit. longi*. Synovial sheath around tendons descending over dorsal surface of tarsus. Fuses with 1 and 2 in su and Ru. A D
- 4 *Vag. tendinis m. extensoris digit. lateralis pedis*. Synovial sheath around tendon as it crosses dorsolateral surface of tarsus, includes M. peroneus brevis in Car. A D
- 5 *Vag. tendinis m. tibialis caudalis (ca)*. Synovial sheath around tendon of insertion on medial surface of tarsus. B
- 6 *Vag. tendinis m. flexoris digit. medialis*. Synovial sheath around tendon as it descends on medial surface of tarsus. May be continuous distally with 7 in su and eq. B C
- 7 *Vag. tendinis m. flexoris digit. lateralis*. Synovial sheath of tendon on plantar surface of tarsus, includes M. tibialis caudalis in Un. May be continuous distally with 6 in su and eq. B C
- 8 *Vag. tendinis m. peron. [fibularis] longi lateralis*. Synovial sheath around tendon of insertion as it crosses lateral side of tarsus. A D
- 9 *B. subtendinea m. peron. [fibularis] brevis (Car)*. Bursa between tendon of insertion and distal portion of lateral surface of tarsus. A
- 10 *B. subtendinea m. tibialis cranialis*. Bursa between the tendon of insertion and distal medial portion of tarsus. B C
- 11 *B. subcutanea calcanea*. Bursa between skin and M. flexor digit. superficialis over Tuber calcanei. C
- 12 *B. calcanea m. flexoris digit. superficialis*. Bursa deep to tendon over M. gastrocnemius and Tuber calcanei. Fuses often with 13 in eq. A B C D
- 13 *B. tendinis calcanei*. Bursa deep to Tendo calcaneus of M. triceps surae. Fuses often with 12 in eq. A B C
- 14 *Vag. tendinis m. peron. [fibularis] longi plantaris*. Synovial sheath around distal part of tendon of insertion as it becomes plantar in Ru, recess of joint capsule in Car and su. A
- 15 *B. subtendinea m. peron. [fibularis] longi (su, Ru)*. Bursa between terminal tendon and distal part of plantar surface of tarsus, recess of joint capsule. D
- 16 *B. subtendinea m. extensoris digit. longi (Ru, eq)*. See 134. 14
- 17 *B. subtendinea m. extensoris digit. lateralis pedis (Ru)*. See 134. 15, but exists only in Ru.
- 18 *Vag. distalis tendinum m. extensoris digit. longi (Ru)*. See 134. 16
- 19 *Vagg. synoviales tendinum digitorum pedis*. See 134. 17
- 20 *Bb. subtendineae mm. interosseorum pedis*. See 134. 18
- 21 *Bb. podotrochleares pedis*. See 134. 19



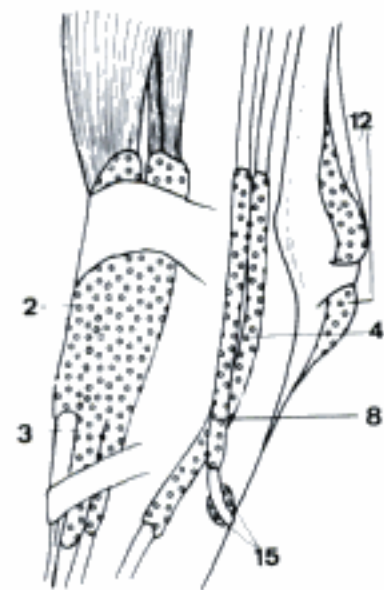
A Bursae and synovial sheaths of the right tarsus, lateral aspect (ca)



B Bursae and synovial sheaths of the right tarsus, medial aspect (ca)

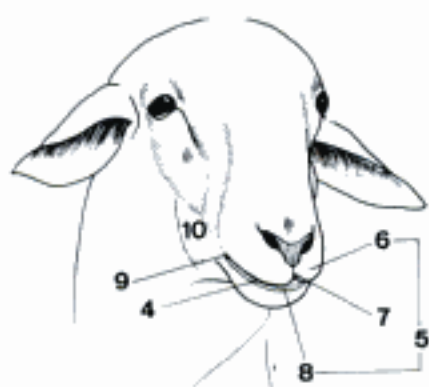


C Bursae and synovial sheaths of the left tarsus, medial aspect (bo)

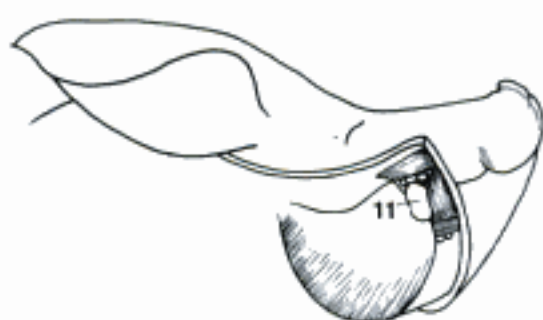

D Bursae and synovial sheaths of the left tarsus, dorsolateral aspect (bo)

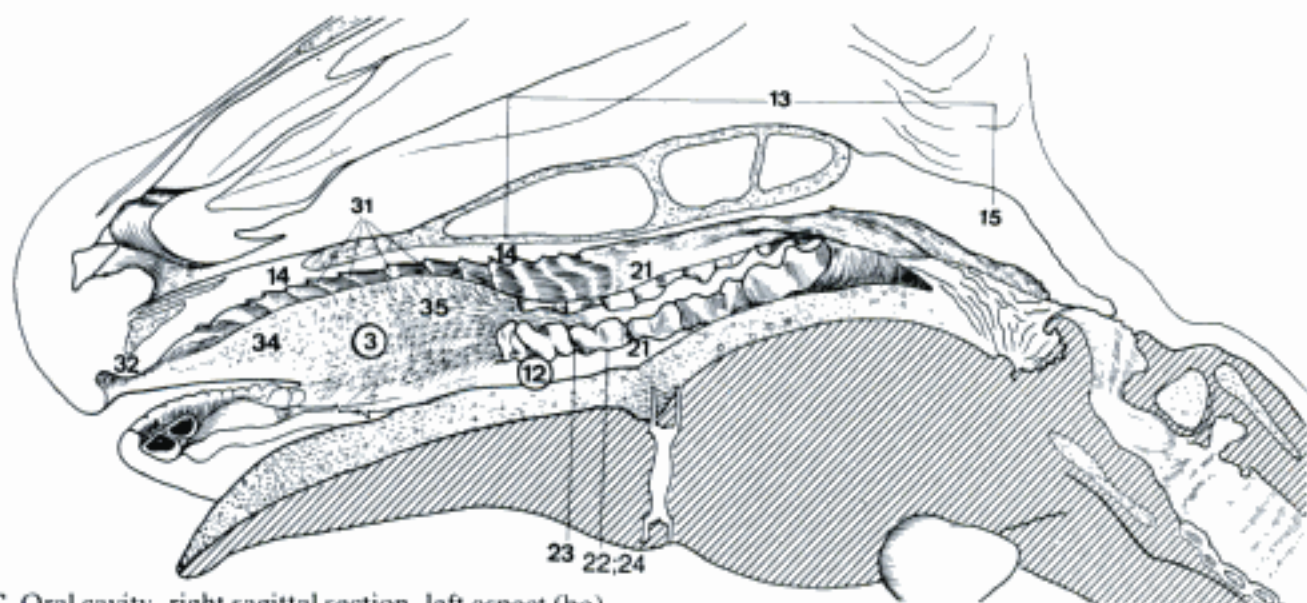
- 1 **APPARATUS DIGESTORIUS.**
- 2 **CAVUM ORIS.** Oral cavity. C
- 3 *Vestibulum oris.* Space between the teeth and lips and cheeks. C D F
- 4 *Rima oris.* Mouth opening, slit between the lips. A
- 5 *Labia oris.* Lips. A
- 6 *Labium superius.* Upper lip. A D
- 7 *Philtrum.* Median groove from the nasal septum to the upper lip. A
- 8 *Labium inferius.* Lower lip. A E
- 9 *Angulus oris.* Corner of the mouth. A E
- 10 *Bucca.* Cheek. A
- 11 *Corpus adiposum buccae.* Buccal fat pad, on the M. buccinator at the rostral border of the M. masseter. B
- 12 *Cavum oris proprium.* Cavity enclosed by the teeth and limited caudally by the Arcus palatoglossus. C F
- 13 *Palatum.* Palate, partition separating the nasal cavity and nasopharynx from the oral cavity and oropharynx. C
- 14 *Palatum durum.* Hard palate, supported by bone. C D
- 15 *Palatum molle [Velum palatinum].* Soft, caudal part of the palate. C
- 16 *Raphe [Rhaphē] palati.* Median line of junction of the halves of the palate. D
- 17 *Recessus sublingualis lateralis.* Space under the tongue, between the Frenulum linguae and the mandible. F
- 18 **Tunica mucosa oris.** Mucous membrane lining the oral cavity. Stratified squamous epithelium, penetrated by the ducts of many submucosal glands.
- 19 *Frenulum labii superioris.* Median fold of mucous membrane between the upper lip and the gingiva. G
- 20 *Frenulum labii inferioris.* Median fold of mucous membrane between the lower lip and the gingiva. E
- 21 *Gingiva.* Gum, the mucous membrane attached to the teeth and alveolar bone. C E
- 22 *Margo gingivalis.* Border of gum around the tooth. C E
- 23 *Papilla gingivalis [interdentalis].* Small mucosal elevation between teeth. C E
- 24 *Sulcus gingivalis.* Groove between gingiva and tooth. C E
- 25 *Caruncula sublingualis.* Flattened projection rostralateral to the Frenulum linguae. The Ductus mandibularis and (except in eq) the Ductus sublingualis major open there. E F
- 26 *Tonsilla sublingualis.* Lymphatic follicles in the vicinity of the Caruncula sublingualis. F
- 27 *Plica sublingualis.* Fold of mucous membrane on the floor of the mouth lateral to the Frenulum linguae. It ends at the Caruncula sublingualis. E F
- 28 *Organum orobasale.* Rudimentary epithelial cords or ducts extending into the Lamina propria from pits or grooves behind the lower central incisors. E F
- 29 *Papilla parotidea.* Small elevation of the buccal mucosa at the orifice of the Ductus parotideus opposite the upper fourth premolar, in bo the second molar. G
- 30 *Papilla zygomatica (Car).* Short fold of buccal mucosa extending caudally from the Papilla parotidea and bearing the orifices of the Ductus glandulae zygomaticae opposite the upper molars. G
- 31 *Rugae palatinae.* Transverse ridges of the mucosa on the hard palate. C D
- 32 *Pulvinus dentalis.* Dental pad, a tough plate of oral mucous membrane which takes the place of the missing upper incisors in Ru. C D
- 33 *Papilla incisiva.* Elevation of mucous membrane at the rostral end of the Raphe palati. It conceals the orifices of the Ductus incisivi. D
- 34 *Papillae labiales.* In ca, on margin of lower lip. In Ru, sharp, cornified, inside the lips. C D E G
- 35 *Papillae buccales (Ru).* Projections of the buccal mucosa covered by cornified epithelium. C
- 36 *Plica pterygomandibularis.* Dorsoventral fold of mucous membrane between the palate and the mandible behind the last molars. G



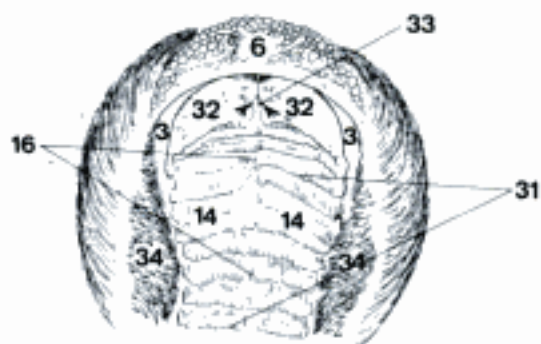
A Oral region, right rostral aspect (ov)



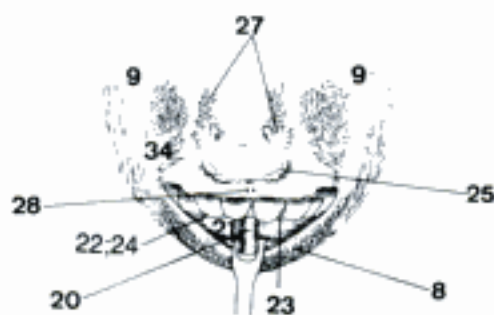
B Buccal region (cutaneous muscles removed) (su)



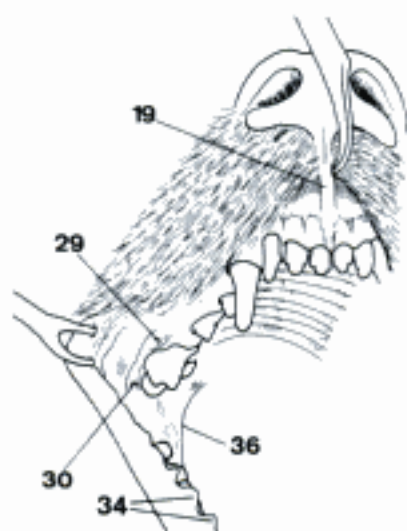
C Oral cavity, right sagittal section, left aspect (bo)



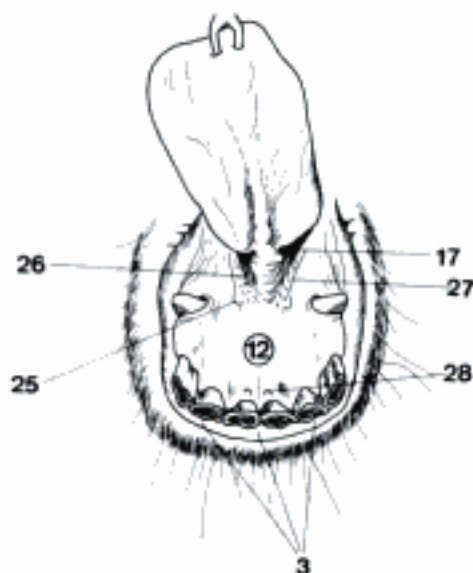
D Hard palate and upper lip (bo)



E Sublingual recess and lower lip (bo)

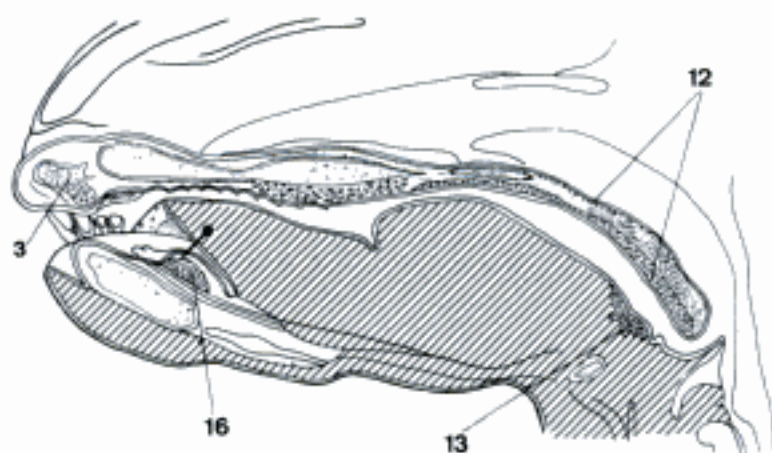


G Right oral vestibule (ca)

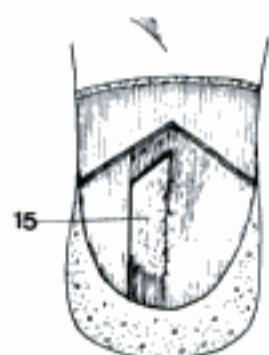


F Sublingual recess and lower lip (eq)

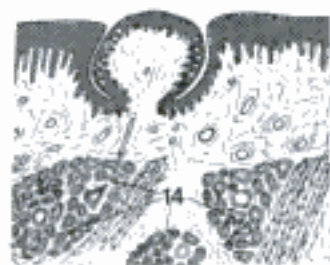
- 1 **Glandulae Oris.** Glands of the mouth, oral glands.
- 2 **Glandulae salivariae minores.** Smaller salivary glands.
- 3 *Gll. labiales.* Glands of the lips. A
- 4 *Gll. buccales.* Glands of the cheeks.
- 5 *Gll. buccales dorsales.* Extend from the angle of the mouth to M. masseter. One layer is superficial to M. buccinator, along the A. labialis superior. Another layer is covered by the superficial part of M. buccinator. Represented by Gl. zygomatica in Car. C
- 6 *Gl. zygomatica.* A major salivary gland of Car, medial to the zygomatic bone and ventral to the orbit. E
- 7 **Ductus glandulae zygomaticae major.** Main duct of Gl. zygomatica. It opens on a papilla opposite the upper first molar. E
- 8 **Ductus glandulae zygomaticae minores.** Microscopic ducts of Gl. zygomatica. E
- 9 *Gll. buccales intermediae (Ru).* Along the dorsal border of the A. labialis inferior between the two layers of M. buccinator. C
- 10 *Gll. buccales ventrales.* Extend from the angle of the mouth to M. masseter, ventral to A. labialis inferior and covered, except for the caudal part, by M. buccinator. C
- 11 *Gll. molares.* Molar glands, the caudal continuation of the *Gll. buccales ventrales* deep to M. masseter. C
- 12 *Gll. palatinae.* Palatine glands on the oropharyngeal side of the soft palate; they occur also on the nasopharyngeal side and in the hard palate of Car, ov and cap. A
- 13 *Gll. linguales.* Lingual glands, mainly on root and margins of the tongue. A
- 14 *Gll. gustatoriae.* Taste glands, whose ducts discharge into the groove of a Papilla vallata. D
- 15 *Gl. lingualis apicalis.* Apical lingual gland, in the musculature of the ventral surface of the apex of tongue in ov. B
- 16 *Gl. paracaruncularis (cap, eq).* Paracaruncular gland, group of small glands near Caruncula sublingualis, in cap continuous with the Gl. sublingualis. A
- 17 **Glandulae salivariae majores.** Larger salivary glands.
- 18 **Gl. sublingualis monostomatica.** It extends along the Ductus mandibularis between M. digastricus and M. masseter medial to the mandible. In Car the caudal part is in contact with the Gl. mandibularis. It is absent in eq. E
- 19 **Ductus sublingualis major.** Duct of the monostomatic sublingual gland. It accompanies the Ductus mandibularis and opens on or near the Caruncula sublingualis. E
- 20 **Gl. sublingualis polystomatica.** Series of small salivary glands with separate ducts, in the submucosa on the floor of the mouth, along the Ductus mandibularis. E
- 21 **Ductus sublinguales minores.** Ducts of the polystomatic sublingual gland. They open along the Plica sublingualis.
- 22 **Gl. mandibularis.** Mandibular gland, covered wholly or in part, depending on the species, by the Gl. parotis. C E
- 23 **Ductus mandibularis.** Runs along the floor of the mouth to the Caruncula sublingualis. E
- 24 **Gl. parotis.** Parotid gland, the most superficial and, except in bo, the largest salivary gland, related dorsally to the base of the ear. C E
- 25 **Pars superficialis.** Part of the gland superficial to the N. facialis. C
- 26 **Pars profunda.** Deep to the N. facialis. C
- 27 **Gl. parotis accessoria.** Small glands may occur along the duct. C
- 28 **Ductus parotideus.** Runs across the lateral surface of M. masseter in Car and ov, ventral to M. masseter in su, bo, cap eq. It ends at the Papilla parotidea. C E



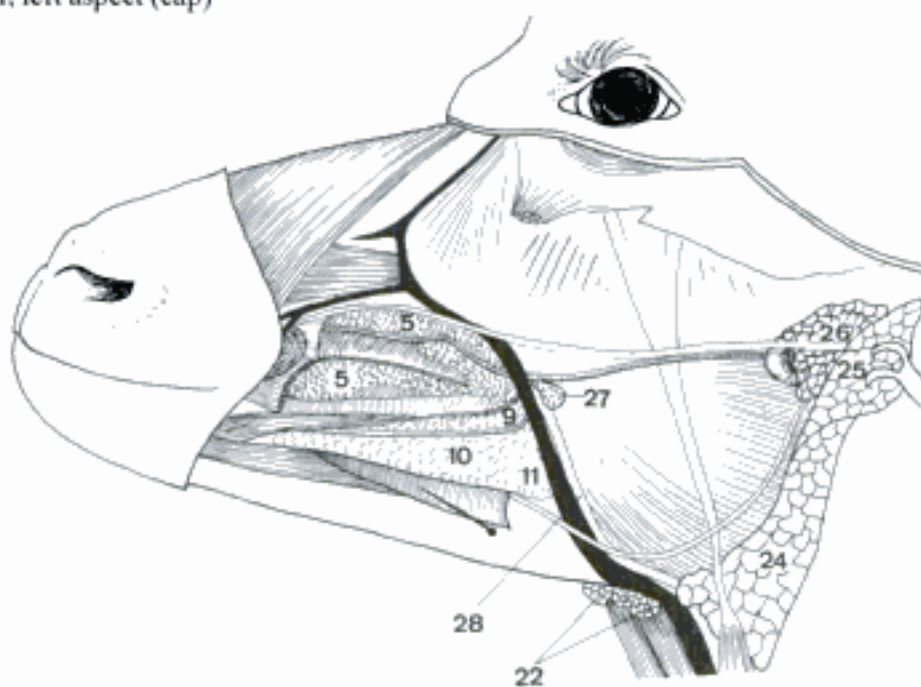
A Oral cavity, sagittal section, left aspect (cap)



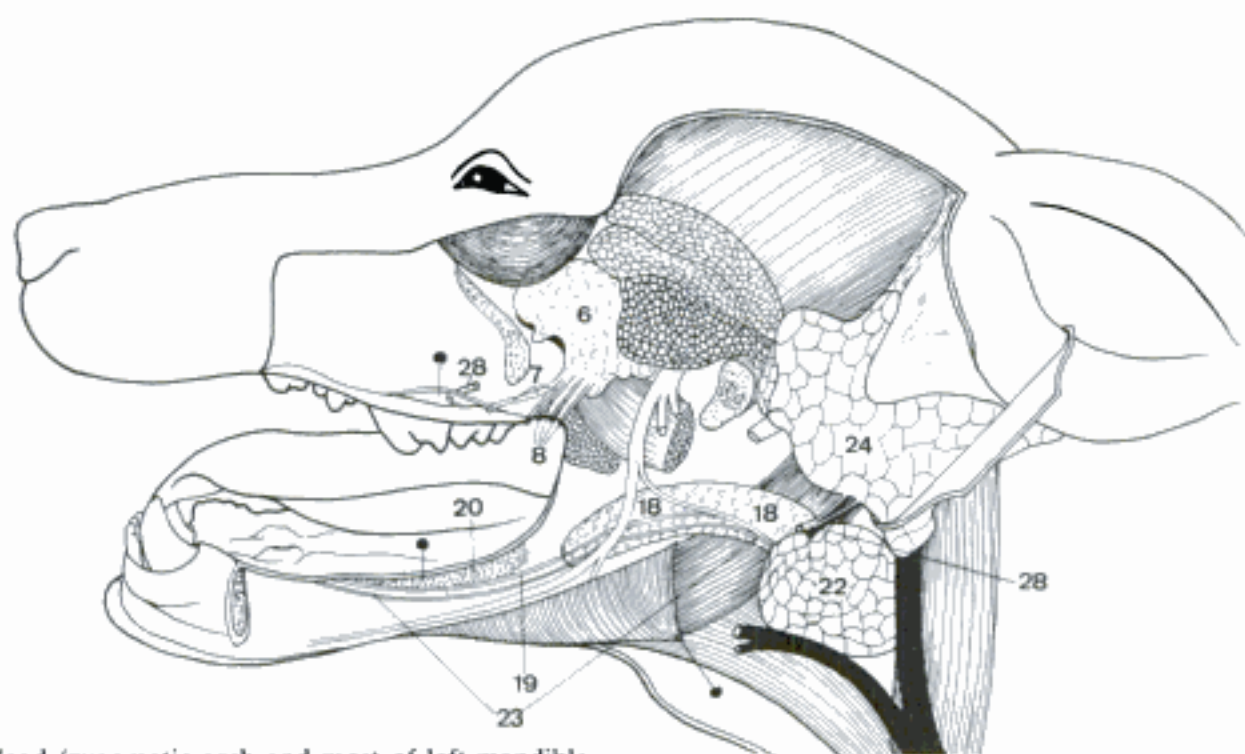
B Tip of tongue (mucosa and superficial musculature removed), ventral surface (ov)



D Vallate papilla, histological section

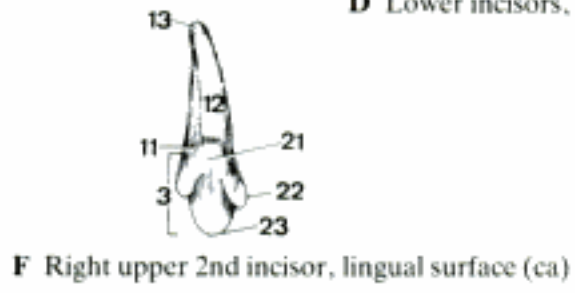
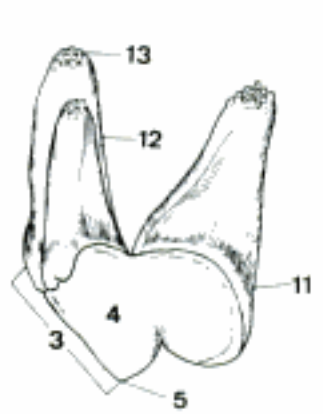
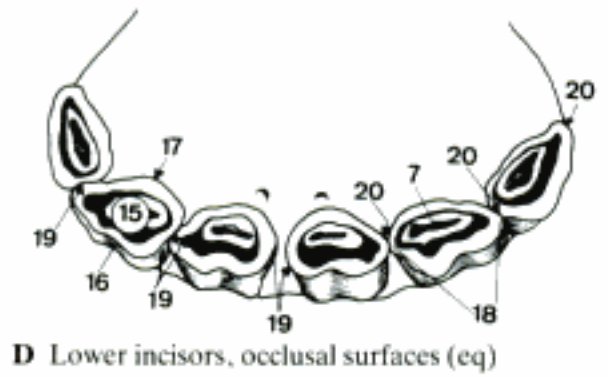
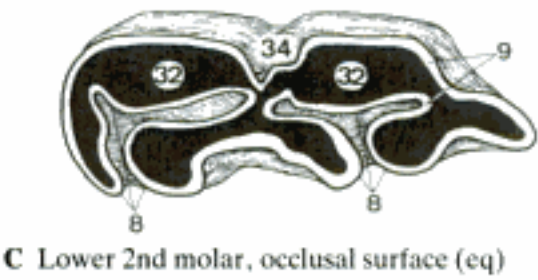
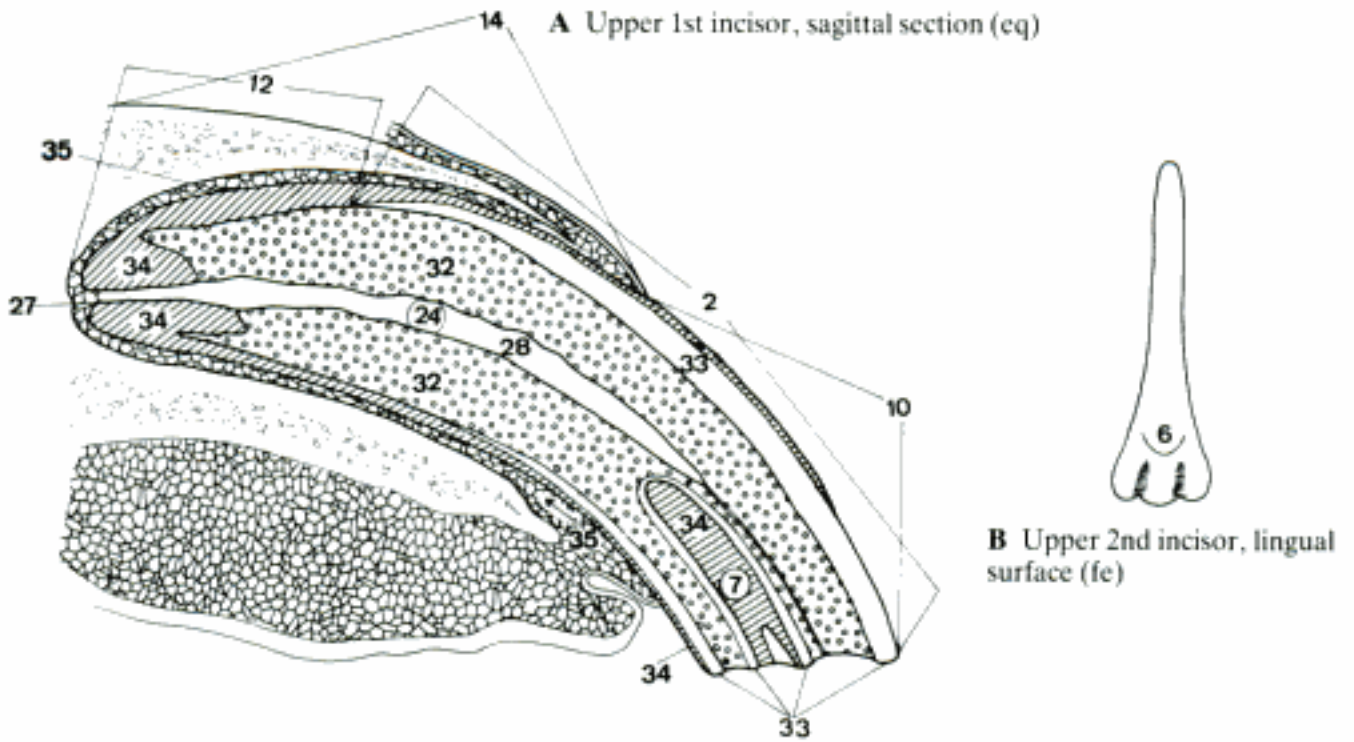


C Head, lateral dissection (cap)

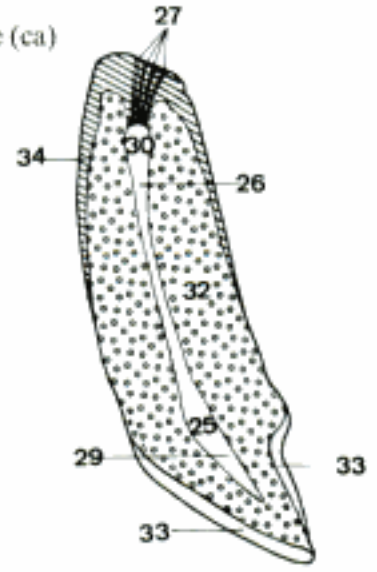


E Head (zygomatic arch and most of left mandible removed), left aspect (ca)

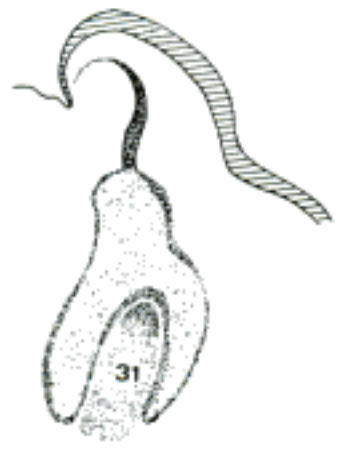- 1 **Dentes.** Teeth.
- 2 *Corpus dentis.* Body of the tooth, applied to hypsodont teeth, in which corona and cervix cannot be distinguished. At includes all of the tooth except the root. A
- 3 *Corona dentis.* Crown, covered by enamel and demarcated from the root by the neck. E F
- 4 *Cuspis [coronae] dentis.* Cusp, one of the main projections on the occlusal surface; it may be pointed or rounded. E
- 5 *Apex cuspidis.* E
- 6 *Tuberculum [coronae] dentis.* Tubercle, a secondary projection of the crown not on the occlusal surface, present on the lingual surface of some incisors of fe and bo. B
- 7 *Infundibulum dentis.* Invagination of enamel on the occlusal surface of incisors (su, eq), premolars, and molars (Ru, eq). A D
- 8 *Plica enameli.* Enamel fold, an infolding from the side of a premolar or molar. C
- 9 *Crista enameli.* Enamel crest, a free occlusal edge of one of the enamel layers of a worn tooth. C
- 10 *Corona clinica.* Clinical crown, the free part of the tooth that projects from the gingiva. A
- 11 *Cervix dentis.* Neck of the tooth, constriction between crown and root. E F
- 12 *Radix dentis.* Root of the tooth. It is not covered by enamel. A E F
- 13 *Apex radialis dentis.* E F
- 14 *Radix clinica.* Clinical root, the part of the tooth that is concealed by the gingiva and alveolus. A
- 15 *Facies occlusalis.* Occlusal surface. It meets the teeth of the opposite jaw. D
- 16 *Facies vestibularis [facialis].* Outer surface, directed toward the Vestibulum oris. D
- 17 *Facies lingualis.* Inner surface, directed toward the tongue. D
- 18 *Facies contactus.* Each tooth, except the last molar, has two contact surfaces, which are related to the adjacent teeth in the same dental arch. D
- 19 *Facies mesialis.* Mesial surface, on the first incisor next to the median plane, on other teeth directed toward the first incisor. D
- 20 *Facies distalis.* The opposite surface from the *Facies mesialis*. D
- 21 *Cingulum.* Ridge on the lingual surface of the crown near the neck, connecting the *Cristae marginales*. It occurs on the incisors of ca and Ru. F
- 22 *Crista marginalis.* Marginal crest, a ridge on each contact border of the lingual surface of the crown of incisor and canine teeth in ca and Ru. F
- 23 *Margo incisalis.* Occlusal border of the incisor teeth. F
- 24 *Cavum dentis [pulpare].* Cavity of the tooth that contains the pulp. A
- 25 *Cavum coronale dentis.* Cavity contained in the crown. H
- 26 *Canalis radialis dentis.* Root canal. H
- 27 *Foramen apicis dentis.* Orifice of the root canal. A H
- 28 *Pulpa dentis.* Pulp of the tooth. A
- 29 *Pulpa coronalis.* Pulp in the crown. H
- 30 *Pulpa radialis.* Pulp in the root canal. H
- 31 *Papilla dentis (ont).* Condensed mesenchyme surrounded by the enamel organ. G
- 32 *Dentinum.* Dentin, the main substance of the tooth, a calcified collagenous matrix permeated by the processes of odontoblasts. A C H
- 33 *Enamelum.* Enamel, the hard white substance covering the dentin in the crown or the body of the tooth. A H
- 34 *Cementum.* Cement, bone-like substance that covers the root. In hypsodont teeth it also covers the *Corpus dentis* and fills the *infundibula* and *plicae*. A C H
- 35 *Periodontium.* Connective tissue that attaches the tooth and gingiva to the alveolus. A



E Upper right 4th premolar (sectorial tooth), lingual surface (ca)

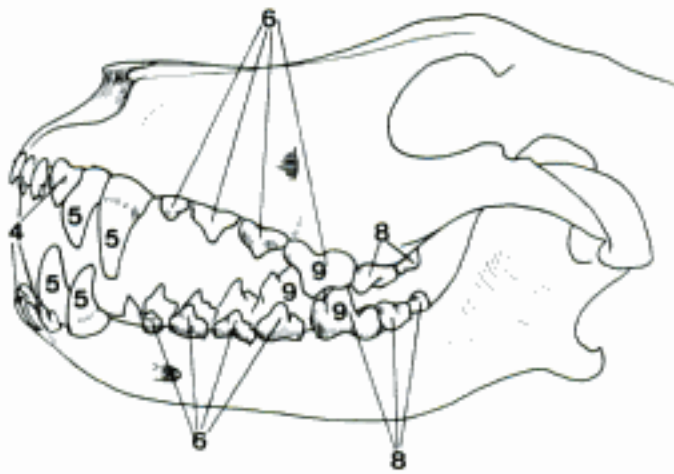


H Upper incisor, sagittal section (ca)

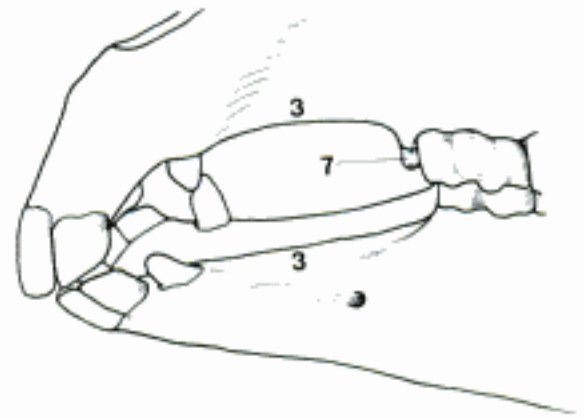


G Tooth germ, histological section (su)

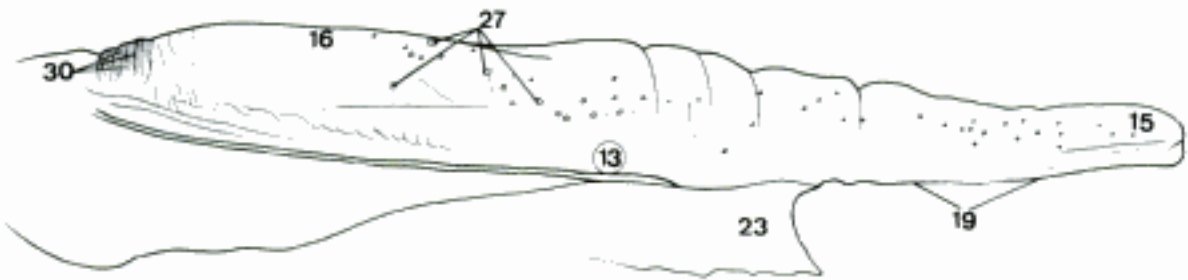
- 1 *Arcus dentalis superior*. Arch formed by all of the upper teeth. A
- 2 *Arcus dentalis inferior*. Arch formed by all of the lower teeth. A
- 3 *Diastema*. Space between two adjacent teeth in the same dental arch. B
- 4 *Dentes incisivi*. Incisors, the first three teeth on either side of the median plane. In Ru a fourth tooth has the form of an incisor. A
- 5 *Dentes canini*. Canine teeth, curved pointed tooth between incisors and premolars. Absent in Ru. A
- 6 *Dentes premolares [prae-]*. The first four cheek teeth in the full eutherian dentition. They are rostral to the molars. All except the first are preceded by deciduous teeth. A
- 7 *Dens lupinus (eq)*. Wolf tooth, the first premolar, which is rudimentary and inconstant. B
- 8 *Dentes molares*. Molars, the last three teeth in each jaw, one or two can be missing. They are not preceded by deciduous teeth. A
- 9 *Dens sectorius (Car)*. Sectorial tooth, the largest cutting tooth in each jaw, the last upper premolar and the first lower molar. A
- 10 *Dentes decidui*. Milk teeth. They are replaced by the permanent incisors, canines and premolars.
- 11 *Dentes permanentes*. Permanent teeth.
- 12 **Lingua**. Tongue. C F
- 13 *Corpus linguae*. Body of the tongue, between apex and root. C
- 14 *Radix linguae*. Root of the tongue, the part caudal to the vallate papillae. G
- 15 *Apex linguae*. Tip of the tongue. C
- 16 *Dorsum linguae*. Dorsal part of the tongue. C
- 17 *Torus linguae (Ru)*. Prominence of the dorsum caudal to the Fossa linguae. D
- 18 *Fossa linguae (bo)*. Deep pit on the dorsum rostral to the torus. D
- 19 *Facies ventralis linguae*. Ventral surface. C
- 20 *Plica fimbriata*. Oblique serrated fold in man, not in domestic mammals.
- 21 *Margo linguae*. Margin of the tongue. D
- 22 *Tunica mucosa linguae*. Mucous membrane of the tongue.
- 23 *Frenulum linguae*. Ventral median fold that attaches the tongue to the floor of the mouth. Double in su and bo. C
- 24 *Papillae linguales*. The lingual papillae cover the dorsal surface of the tongue.
- 25 *Papillae filiformes*. Thread-like cornified epithelial processes in Un, connective tissue core projects into the papilla in Car. D F
- 26 *Papillae conicae*. Large conical papillae with a connective tissue core. D
- 27 *Papillae fungiformes*. Mushroom-shaped elevations of the Tunica mucosa. They bear taste buds. C D F
- 28 *Papillae lentiformes*. Large lens-shaped mechanical papillae. D
- 29 *Papillae vallatae*. Flat papillae surrounded by a circular groove, the inner wall of which bears taste buds. D F G
- 30 *Papillae foliatae*. Parallel folds of Tunica mucosa at the caudal end of the margin of the tongue. The walls of the intervening grooves bear taste buds. Absent in Ru. C G
- 31 *Papillae marginales*. Present in newborn Car and su. E
- 32 *Sulcus medianus linguae*. Median dorsal groove. F
- 33 *Ductus thyroglossus [thyreo-] (ont)*. Epithelial tube that evaginates from the root of the tongue and gives rise to the thyroid gland.
- 34 *Tonsilla lingualis*. Lymphatic follicles (su, bo, eq) and tonsillar papillae (su). G
- 35 *Folliculi linguales*. Rounded elevations of the mucosa, each formed by the lymphatic tissue surrounding a crypt (Fossula tonsillaris). G
- 36 *Papillae tonsillares (su)*. Conical papillae containing lymphatic nodules on the root of the tongue. H



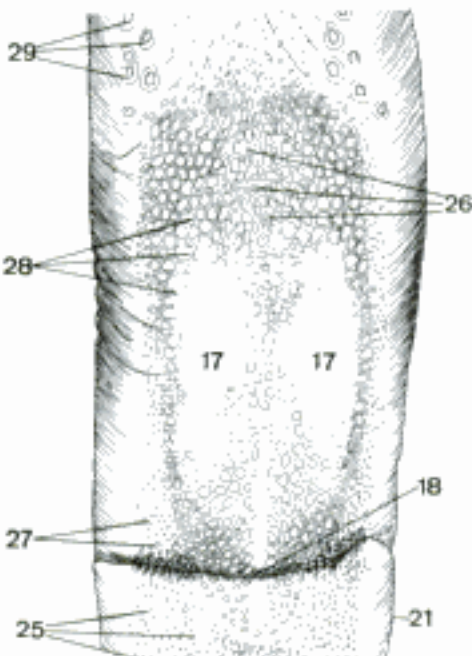
A Dental arches (ca)



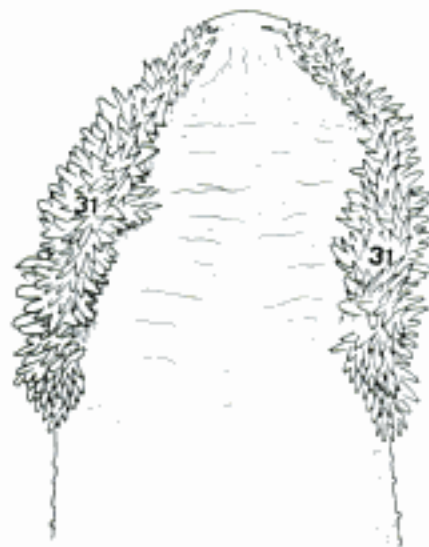
B Incisors, canine teeth and 1st and 2nd premolars (cq)



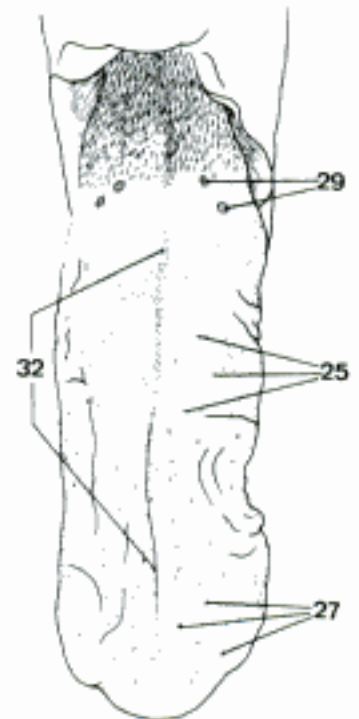
C Tongue, right side (cq)



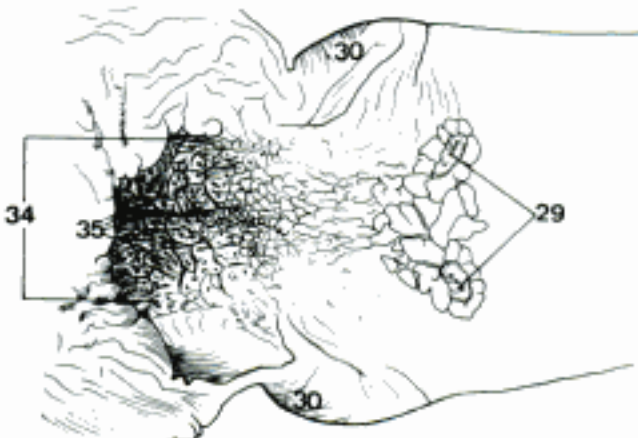
D Part of dorsum of tongue (bo)



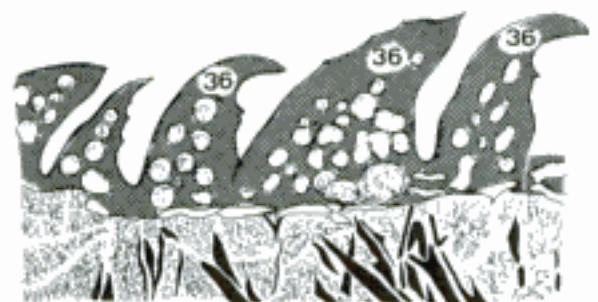E Tip of tongue, dorsal surface (su, newborn) (Habermehl)



F Dorsum of tongue (ca)

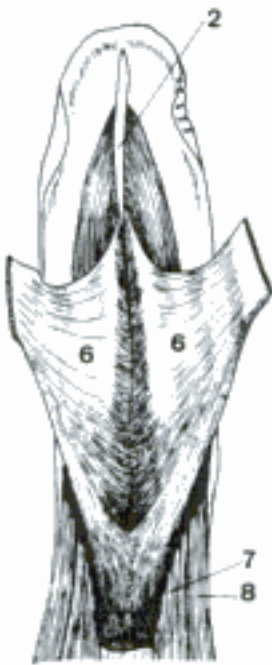

G Root of tongue (cq)

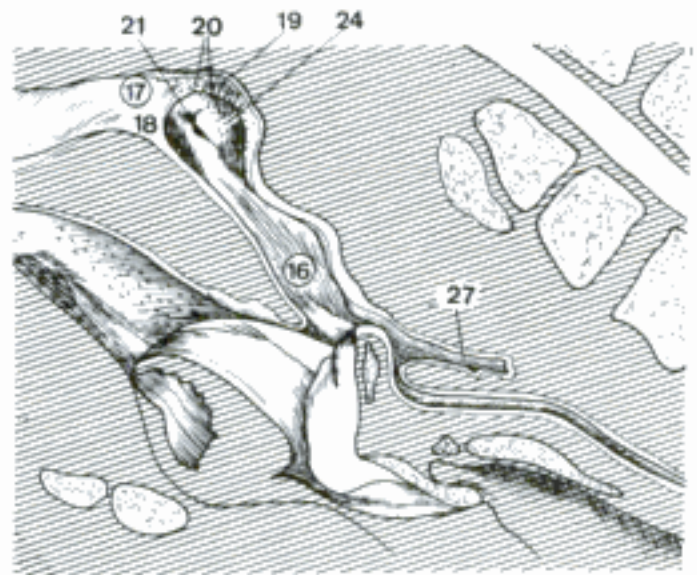


H Tonsillar papillae, histological section (su) (Vollmerhaus)

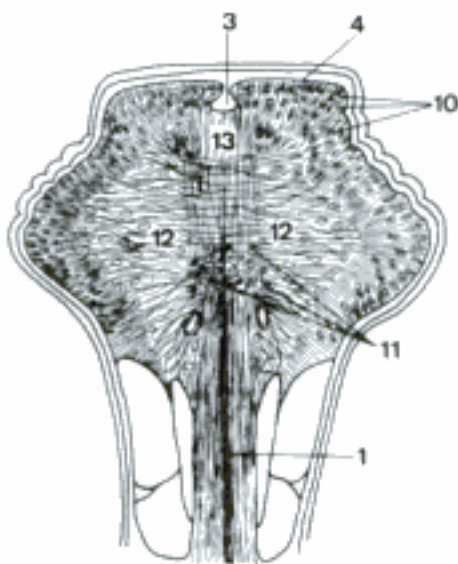
- 1 *Septum linguae*. Sheet of connective tissue in the median plane. B
- 2 *Lyssa (Car)*. The rostral part is a fusiform median structure in the submucosa of the ventral surface of the tongue. It consists of a collagenous sheath enclosing fat, striated muscle, and chondroid cells. It is continued caudally between the Mm. genioglossi by a fibrous cord. A
- 3 *Cartilago dorsi linguae (eq)*. Palpable median dorsal thickening of the lamina propria. It contains isolated chondroid and fat cells. B
- 4 *Aponeurosis linguae*. Dense layer of connective tissue which covers the musculature of the tongue and to which the muscles are attached. On the dorsum it is fused with the Lamina propria mucosae. B
- 5 **Musculi linguae**. Muscles of the tongue.
- 6 *M. genioglossus*. O: Pars incisiva mandibulae. T: Enters the tongue ventrally, parallel to the median plane, as far back as the hyoid bone. Its primary action is to protrude the tongue. A
- 7 *M. hyoglossus*. O: Os hyoideum. T: Enters the tongue between M. genioglossus medially and M. styloglossus laterally. It retracts and depresses the tongue. A
- 8 *M. styloglossus*. O: Ventral end of Stylohyoideum. T: Apex linguae. It is the most lateral of the extrinsic muscles and serves to retract the tongue or turn the apex to one side. A
- 9 *M. lingualis proprius*. Intrinsic musculature of the tongue. B
- 10 *Fibrae longitudinales superficiales*. B
- 11 *Fibrae longitudinales profundae*. Occur in eq. B
- 12 *Fibrae transversae*. B
- 13 *Fibrae perpendiculares*. B
- 14 **PHARYNX**. Musculomembranous junction of the respiratory and digestive tracts between the oral and nasal cavities rostrally and the esophagus and larynx caudally.
- 15 **Cavum pharyngis**. Divided into nasal, oral, and laryngeal parts. The parts of the pharynx in domestic animals do not correspond to those in man because of the long soft palate and the more obtuse cervicocephalic angle.
- 16 *Pars nasalis pharyngis*. The part caudodorsal to the soft palate. It extends from the choanae to the Ostium intrapharyngeum. C
- 17 *Fornix pharyngis*. The most dorsal part of the cavity. C
- 18 *Septum pharyngis (su, Ru)*. Membranous continuation of the Septum nasi in the fornix. C
- 19 *Tonsilla pharyngea*. On the caudodorsal wall of the nasopharynx, in su and Ru on the Septum pharyngis. C
- 20 *Folliculi tonsillares*. Occur in su and eq. C
- 21 *Ostium pharyngeum tubae auditivae*. Pharyngeal opening of the auditory tube. C D
- 22 *Torus tubarius*. Swelling caudodorsal to the Ostium tubae, caused by the medial lamina of the cartilage of the auditory tube. D
- 23 *Torus levatorius*. Low ridge running rostroventrally from the Ostium pharyngeum tubae to the soft palate, and caused by the M. levator veli palatini. D
- 24 *Tonsilla tubaria*. Tubal tonsil, occurs at the Ostium pharyngeum tubae in su and Ru. C
- 25 *Recessus pharyngeus*. Niche at the caudodorsal angle of the nasopharynx in Un. D
- 26 (*Bursa pharyngea*). Median dorsal epithelial pouch. D
- 27 *Diverticulum pharyngeum*. Median caudal blind sac formed by the mucous membrane of the nasopharynx dorsal to the esophagus in su. It has nothing to do with the Bursa pharyngea. C



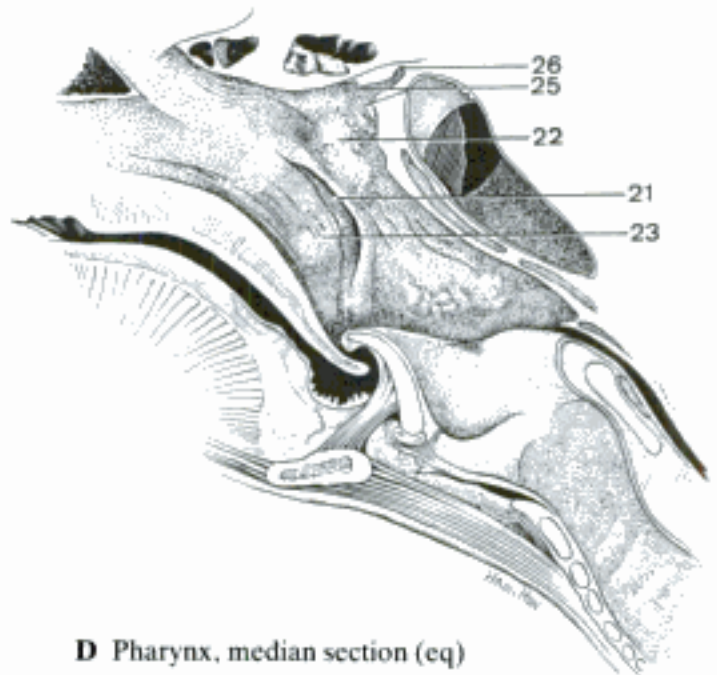
A Tongue (geniohyoid muscles and part of mucosa removed, genioglossal muscles separated), ventral aspect (ca)



C Pharynx, left paramedian section, medial surface (su)

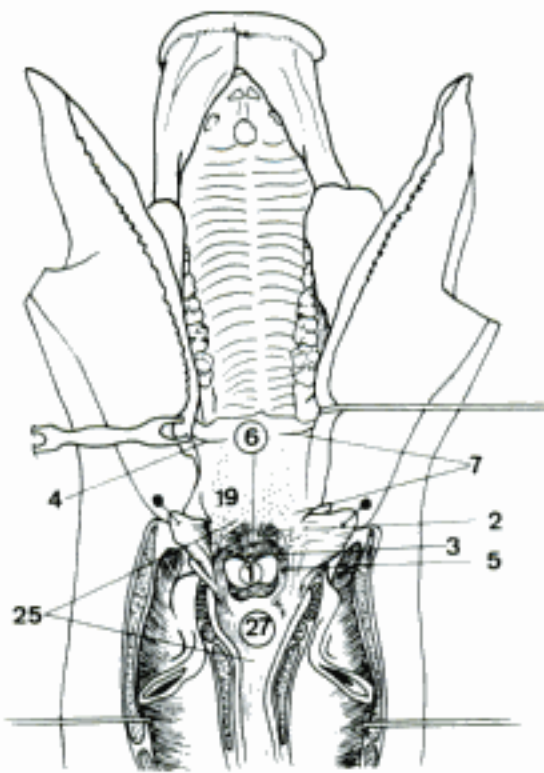


B Tongue, transverse section (eq)

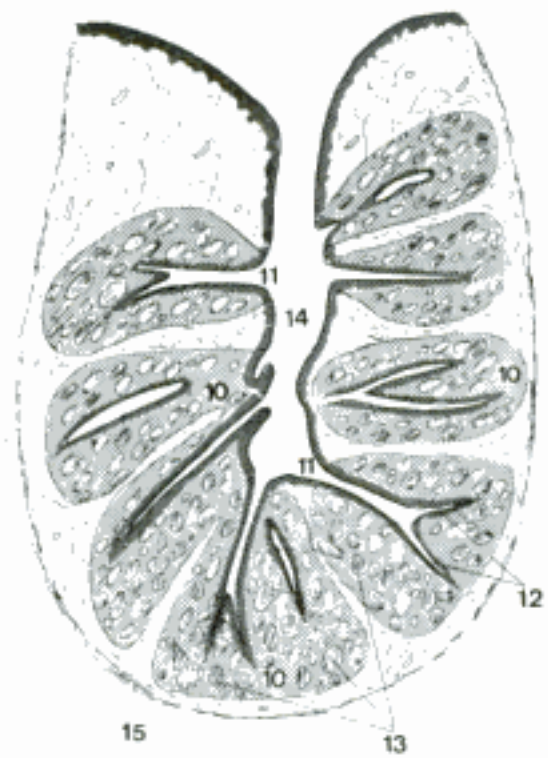


D Pharynx, median section (eq)

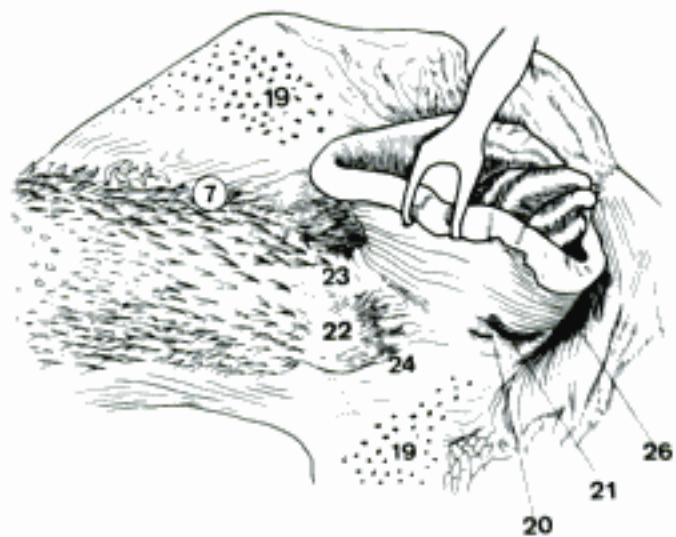
- 1 *Ostium intrapharyngeum*. Passage between Pars nasalis and Pars laryngea pharyngis. It is formed by the free border of the soft palate and the right and left Arcus palatopharyngeus. A
- 2 *Palatum molle [Velum palatinum]*. Soft palate. A D
- 3 *Uvula [palatina] (su)*. Short median projection on the free border of the soft palate. A
- 4 *Arcus palatoglossus*. Ridge or fold of mucosa extending from the soft palate to the tongue at the boundary between mouth and pharynx. A D
- 5 *Arcus palatopharyngeus*. Mucosal fold extending from the free border of the soft palate around the Ostium intrapharyngeum. A D
- 6 *Isthmus faucium*. Orifice between Cavum oris and Pars oralis pharyngis, bounded by Arcus palatoglossi, soft palate, and tongue. A D
- 7 *Pars oralis pharyngis*. Extends from the Arcus palatoglossi to the base of the epiglottis. The cavity corresponding to the posterior part of the human Pars oralis is cut off by the long soft palate and belongs to the Pars nasalis. A
- 8 *Fauces*. Part of the oropharynx just caudal to Arcus palatoglossi. D
- 9 *Tonsilla palatina*. The tonsil related to the lateral attachment of the soft palate between Arcus palatoglossus and palatopharyngeus. It does not occur in su. D
- 10 *Folliculi tonsillares*. A tonsillar follicle is a crypt with its surrounding lymphatic tissue (Lymphonoduli). B
- 11 *Fossulae tonsillares*. A tonsillar fossula is the orifice of a follicle. It opens on the mucosa or into a tonsillar sinus. B
- 12 *Cryptae tonsillares*. A tonsillar crypt is a blind epithelial tubule extending inward from a fossula tonsillaris. B
- 13 *Lymphonoduli [Noduli lymphatici]*. B
- 14 *Sinus tonsillaris*. Deep, narrow-mouthed cavity in the palatine tonsil of Ru. B
- 15 *Capsula tonsillaris*. Tonsillar capsule. B
- 16 *Plica semilunaris*. Fold of mucosa from the ventral surface of the lateral part of the soft palate in Car. It forms the medial wall of the Fossa tonsillaris. D
- 17 *Fossa tonsillaris*. Depression containing the palatine tonsil in Car. D
- 18 *Fossa suprtonsillaris*. Dorsal part of Fossa tonsillaris in fe.
- 19 *Tonsilla veli palatini (su, eq)*. Mass of follicles on the oral surface of the soft palate. A C
- 20 *Tonsilla paraepiglottica (fe, su, ov, cap)*. On the Plica aryepiglottica in fe, lateral to base of epiglottis in su, ov, cap. C
- 21 *Sulcus tonsillaris (su)*. Deep groove in the Tonsilla paraepiglottica. C
- 22 *Vallecula epiglottica*. Depression between the tongue and the epiglottis and between Plica glossoepiglottica mediana and lateralis. C, D
- 23 *Plica glossoepiglottica mediana*. Median fold from the tongue to the epiglottis. C
- 24 *Plica glossoepiglottica lateralis*. Lateral fold from the tongue to the epiglottis. C
- 25 *Pars laryngea pharyngis*. Part of the pharynx ventral to the Ostium intrapharyngeum. It extends from the base of the epiglottis to the esophagus. A D
- 26 *Recessus piriformis*. Channel between epiglottis, Plica aryepiglottica and arytenoid cartilage medially, and Membrana thyrohyoidea and thyroid cartilage laterally. C
- 27 *Vestibulum esophagi [Pars esophagea, oesophagea]*. Part of the laryngopharynx between the arytenoid cartilages and the beginning of the esophagus. A D
- 28 *Limen pharyngoesophageum [-oesophageum] (Car)*. Interior boundary between pharynx and esophagus, formed by a circular fold in fe, by a glandular thickening in Car. D
- 29 *Fascia pharyngobasilaris*. Pharyngeal fascia that attaches to the Basis cranii. D
- 30 *Tela submucosa*. D
- 31 *Tunica mucosa*. Covered by pseudostratified columnar epithelium in the Pars nasalis, by stratified squamous epithelium in the other parts. D
- 32 *Gll. pharyngeae*. D



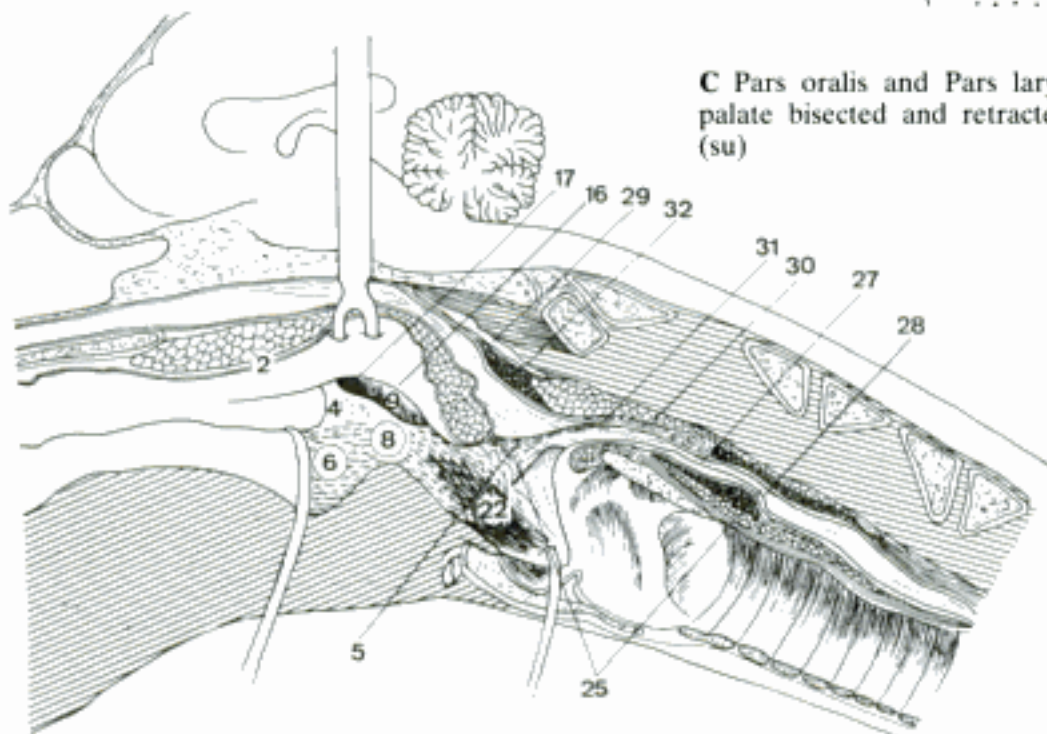
A Palate (tongue and larynx bisected and retracted, esophagus opened), ventral aspect (su)



B Palatine tonsil, histological section (bo)

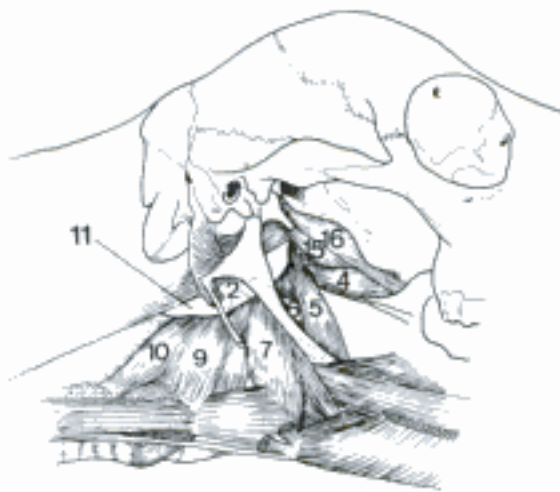


C Pars oralis and Pars laryngea of pharynx (soft palate bisected and retracted), dorsolateral aspect (su)

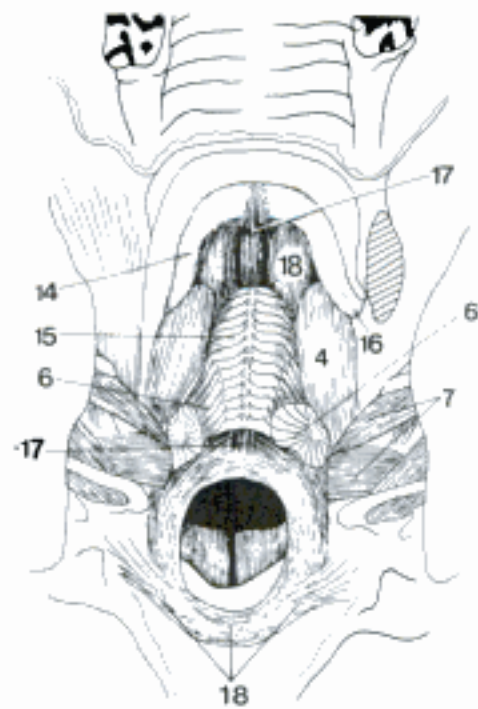


D Pharynx (tongue and epiglottis retracted), median section (ca)

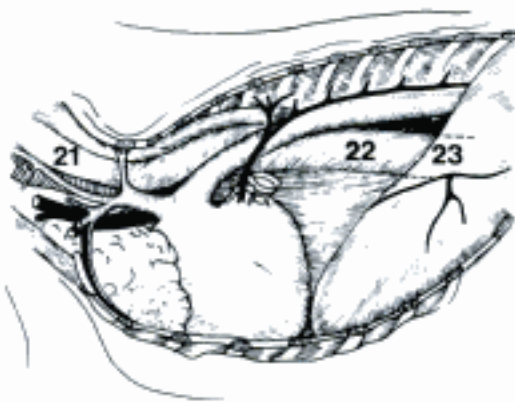
- 1 **Tunica muscularis pharyngis.** The muscular coat of the pharynx is composed of the following striated muscles.
- 2 *Raphe [Rhaphe] pharyngis.* Median dorsal line of termination of the pharyngeal constrictors. A
- 3 *Mm. constrictores pharyngis rostrales.* *M. palatopharyngeus* is listed as a muscle of the soft palate.
- 4 *M. pterygopharyngeus.* O: Os pterygoideum and Aponeurosis palatina, except eq (Os pterygoideum only). T: Raphe pharyngis. A B
- 5 *M. stylopharyngeus rostralis.* O: distal half of the Stylohyoideum. T: Raphe pharyngis. Occurs in Ru and occasionally in eq. A
- 6 *M. stylopharyngeus caudalis.* O: proximal half of the Stylohyoideum. Passes between the rostral constrictors and the *M. hyopharyngeus*. T: wall of pharynx, in bo mainly attached to the thyroid cartilage. Dilator of the pharynx, in bo elevator of the larynx. A B
- 7 *M. hyopharyngeus [M. constrictor pharyngis medius].* O: Ceratohyoideum and Thyrohyoideum. T: Raphe pharyngis. A B E
- 8 *Mm. constrictores pharyngis caudales.*
- 9 *M. thyropharyngeus [thyreo-].* O: Linea obliqua on the thyroid cartilage. T: Raphe pharyngis. A D E
- 10 *M. cricopharyngeus.* O: cricoid cartilage. T: Raphe pharyngis. A D E
- 11 *Spatium retropharyngeum.* A
- 12 *Spatium lateropharyngeum.*
- 13 **Musculi palati et faucium.** Muscles of the palate and fauces.
- 14 *Aponeurosis palatina.* Tendinous lamina in the rostral part of the soft palate, attached to Os palatinum. B
- 15 *M. levator veli palatini.* O: Pars tympanica, in eq also cartilage of the auditory tube. Raises the soft palate. A B
- 16 *M. tensor veli palatini.* Partial O: Os temporale. T: Aponeurosis palatina. Partial O: Os pterygoideum. T: cartilage of auditory tube. A B
- 17 *M. palatinus.* O: Lamina horizontalis ossis palatini; in eq Aponeurosis palatina. T: blends with the *M. palatopharyngeus*. Shortens the soft palate. B
- 18 *M. palatopharyngeus.* O: palatine aponeurosis, *M. palatinus*. T: Raphe pharyngis. Sphincter of the nasopharynx and the Ostium intrapharyngeum. B D
- 19 **CANALIS ALIMENTARIUS.** Esophagus, stomach, and intestines.
- 20 **ESOPHAGUS [OESOPHAGUS].** Tube extending from the pharynx to the stomach.
- 21 *Pars cervicalis.* The part from the pharynx to the first rib. C
- 22 *Pars thoracica.* The part from the first rib to the diaphragm. C
- 23 *Pars abdominalis.* The short part between the diaphragm and the stomach. C
- 24 *Tunica adventitia.* Outer coat of connective tissue. F
- 25 *Tunica muscularis.* Straited muscle, except a caudal segment of smooth muscle in fe, su and eq. D F
- 26 *Tendo cricoesophageus [-oesophageus].* Attaches the esophageal musculature to the cricoid and arytenoid cartilages. D
- 27 *M. esophageus [oesophageus] longitudinalis dorsalis* (Ru, eq). E
- 28 *M. esophageus [oesophageus] longitudinalis lateralis.* O: larynx (Car, Ru) or pharynx (su, eq). T: lateral surface of the esophagus. D E
- 29 *M. esophageus [oesophageus] longitudinalis ventralis.* O: cricoesophageal tendon. E
- 30 *M. bronchoesophageus [-oesophageus].*
- 31 *M. pleuroesophageus [-oesophageus] (ca).*
- 32 *Tela submucosa.*
- 33 *Tunica mucosa.* Covered by stratified squamous epithelium. F
- 34 *Lamina muscularis mucosae.* Incomplete in domestic mammals. F
- 35 *Gll. esophageae [oesophageae].* Mucous glands in the submucosa. In fe, Ru, eq restricted to the cranial end. F



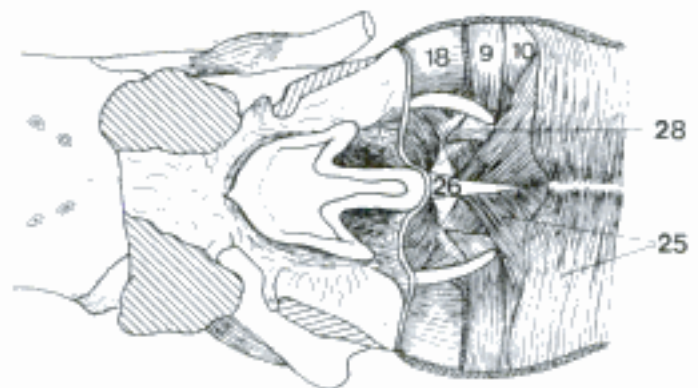
A Pharyngeal muscles, right side (ov) (Habel)



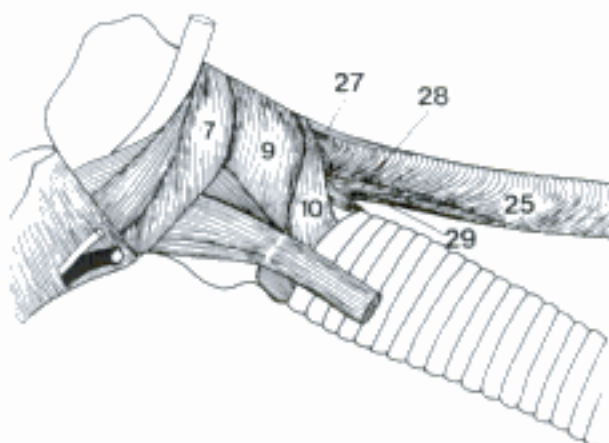
B Muscles of the soft palate (left pterygoid muscles removed), ventral aspect (su)



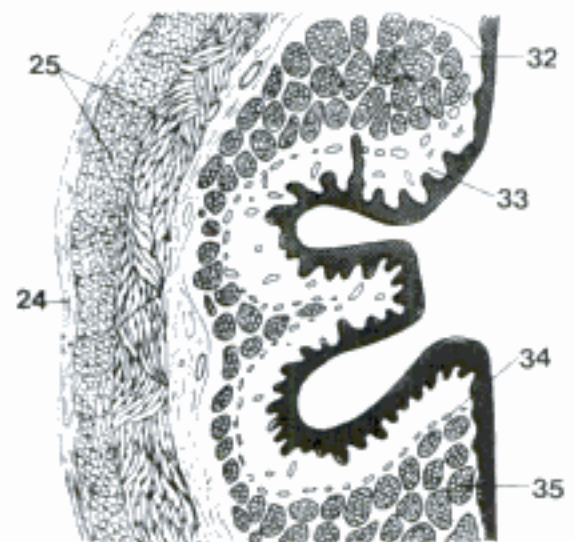
C Thoracic cavity and base of neck, left side (ov) (Habel)



D Muscles of pharynx and esophagus opened dorsally (ca)

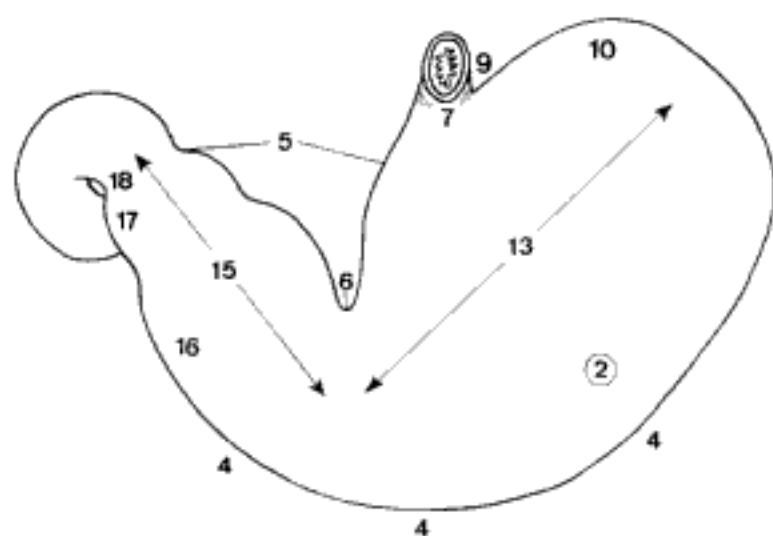


E Muscles of pharynx and esophagus, left side (cap)

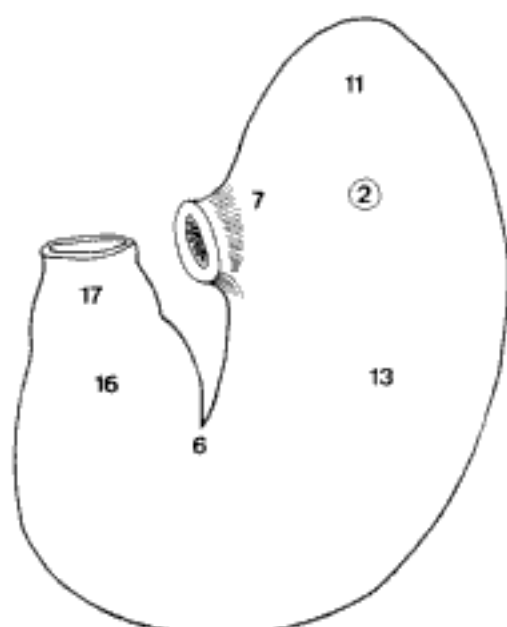


F Esophagus, transverse histological section (ca)

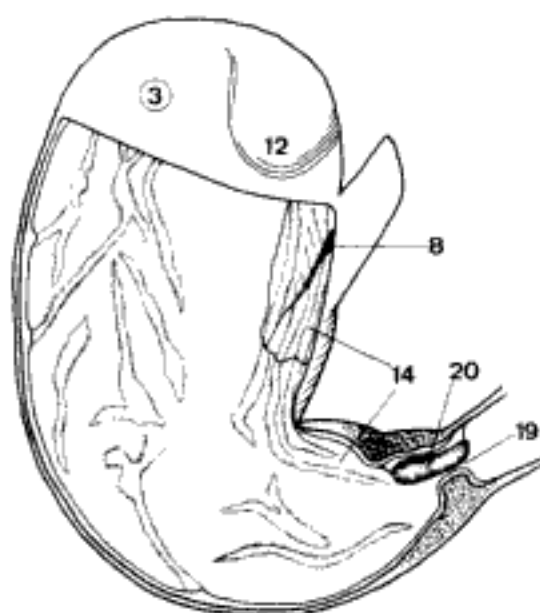
- 1 **VENTRICULUS [GASTER]**. Stomach. It is divided into four compartments in Ru.
- 2 *Facies parietalis*. Surface that faces the abdominal wall and liver. A B
- 3 *Facies visceralis*. Surface that faces the intestines. C
- 4 *Curvatura ventriculi major*. Greater curvature. A
- 5 *Curvatura ventriculi minor*. Lesser curvature. A
- 6 *Incisura angularis*. Notch on the Curvatura minor between Corpus ventriculi and Pars pylorica. A B
- 7 *Pars cardiaca*. Region around the esophageal opening. A B
- 8 *Ostium cardiacum*. Opening between the esophagus and the stomach. C
- 9 *Incisura cardiaca*. Cardiac notch between esophagus and fundus. A
- 10 *Fundus ventriculi*. Blind sac on the left of the cardiac part. The term is derived from the depth of this part of the human stomach as seen from an abdominal incision. The fundus is lined by gastric glands, except su (cardiac glands) and eq (nonglandular). A
- 11 *Saccus cecus [caecus] ventriculi (eq)*. Blind sac, the large Fundus ventriculi of eq. Saccus cecus, Pars cardiaca and the adjacent part of the Corpus ventriculi of eq are lined by stratified squamous epithelium. B
- 12 *Diverticulum ventriculi (su)*. Flattened conical pouch of the fundus. It projects caudally and to the right and is lined by cardiac glands. C
- 13 *Corpus ventriculi*. Main part of the stomach, between the fundus and Pars pylorica. It is lined by Glandulae gastricae [propriae]. A B
- 14 *Sulcus ventriculi*. Gastric groove. It extends along the inside of the Curvatura minor from the cardiac orifice to the pylorus. In Ru the Sulcus ventriculi is divided by the Ostium reticulo-omasicum and Ostium omaso-abomasicum into three segments: Sulcus reticuli, Sulcus omasi, and Sulcus abomasi. C
- 15 *Pars pylorica*. Pyloric part of the stomach, between Incisura angularis and Pylorus. A
- 16 *Antrum pyloricum*. First, wider portion of the Pars pylorica. A B
- 17 *Canalis pyloricus*. Second, short narrow segment of the Pars pylorica, just before the pylorus. A B
- 18 *Pylorus*. Distal constriction of the stomach containing the sphincter. A
- 19 *Ostium pyloricum*. Opening between the stomach and the duodenum. C
- 20 *Torus pyloricus (su, Ru)*. Protuberance in the pylorus formed by the circular muscle at the end of the Curvatura minor, fat, and the mucous membrane. C



A Stomach, parietal surface (ca)

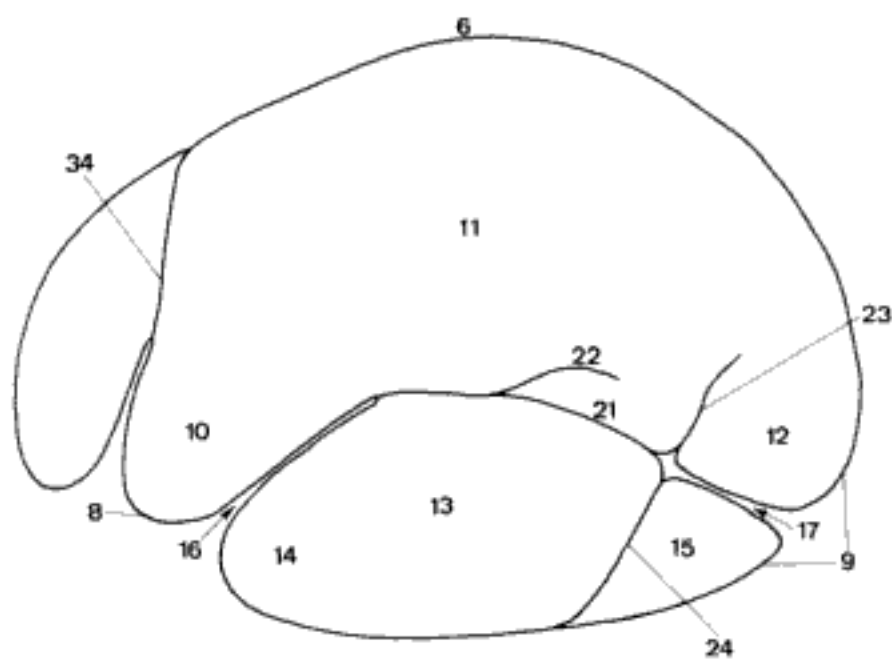


B Stomach, parietal surface (eq)

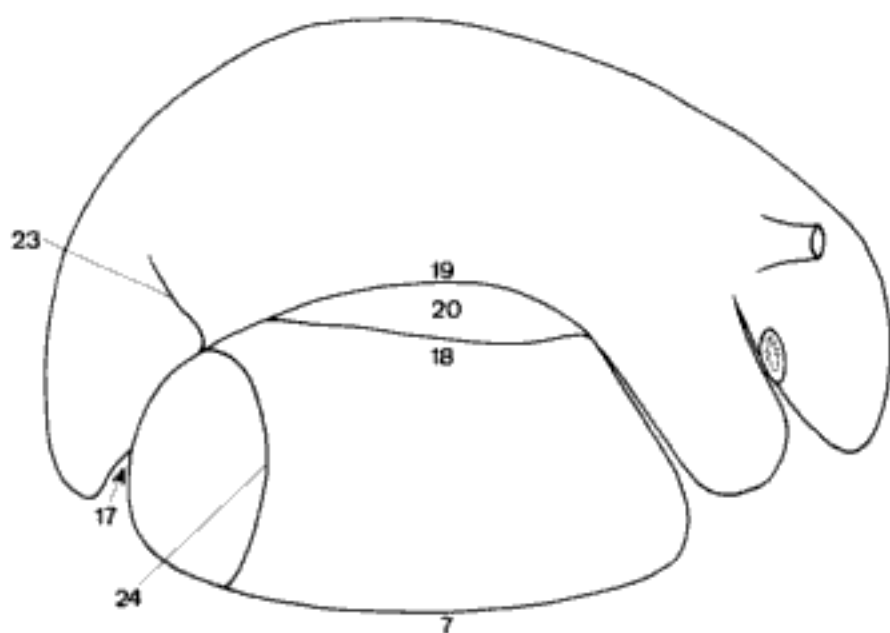


C Stomach (most of the visceral wall removed), visceral aspect (su)

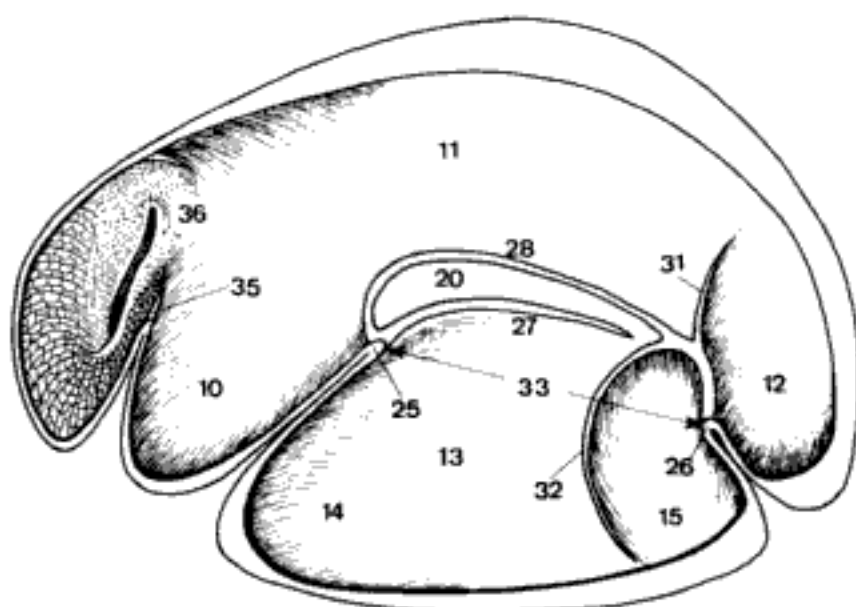
- 1 **Proventriculus.** Forestomach in Ru, divided into three compartments: Rumen, Reticulum, and Omasum.
- 2 *Ruminoreticulum.* Term often employed to indicate the morphological and physiological unity of the two compartments. C
- 3 **Rumen.** Largest compartment of the ruminant stomach. A B C
- 4 *Facies parietalis.* Surface facing the body wall to the left and ventrally. A
- 5 *Facies visceralis.* Surface facing the intestines, to the right. B
- 6 *Curvatura dorsalis.* Dorsal curvature. A
- 7 *Curvatura ventralis.* Ventral curvature. B
- 8 *Extremitas cranialis.* Cranial end, adjacent to the Reticulum. A
- 9 *Extremitas caudalis.* Caudal end, the blind sacs. A
- 10 *Atrium ruminis [Saccus cranialis].* Lies between Reticulum and Saccus ventralis. It is morphologically and functionally distinct from the dorsal sac. A C
- 11 *Saccus dorsalis.* The dorsal sac is dorsal to the longitudinal grooves. A C
- 12 *Saccus cecus [caecus] caudodorsalis.* Caudodorsal blind sac. A C
- 13 *Saccus ventralis.* The ventral sac is ventral to the longitudinal grooves. A C
- 14 *Recessus ruminis.* Cranial end of the ventral sac. A C
- 15 *Saccus cecus [caecus] caudoventralis.* Caudoventral blind sac. A C
- 16 *Sulcus cranialis.* The cranial groove is between Atrium and Recessus ruminis. A
- 17 *Sulcus caudalis.* Separates the caudodorsal from the caudoventral blind sac. A B
- 18 *Sulcus longitudinalis dexter.* Right longitudinal groove. B
- 19 *Sulcus accessorius dexter.* Right accessory groove, dorsal to the right longitudinal groove. B
- 20 *Insula ruminis.* Island of the rumen, elliptical area enclosed by the right longitudinal and accessory grooves. B C
- 21 *Sulcus longitudinalis sinister.* Left longitudinal groove. A
- 22 *Sulcus accessorius sinister.* Left accessory groove, a dorsal branch of the left longitudinal groove. A
- 23 *Sulcus coronarius dorsalis.* Dorsal coronary groove, limits the caudodorsal blind sac. A B
- 24 *Sulcus coronarius ventralis.* Ventral coronary groove, limits the caudoventral blind sac. A B
- 25 *Pila cranialis.* Cranial pillar, a muscular fold projecting into the cavity of the rumen between Atrium and Recessus ruminis. C
- 26 *Pila caudalis.* Caudal pillar, between the caudodorsal and caudoventral blind sacs. C
- 27 *Pila longitudinalis dextra.* Right longitudinal pillar. C
- 28 *Pila accessoria dextra.* Right accessory pillar, dorsal to the right longitudinal pillar. C
- 29 *Pila longitudinalis sinistra.* Left longitudinal pillar, corresponding to the Sulcus longitudinalis sinister.
- 30 *Pila accessoria sinistra.* Dorsal branch of the left longitudinal pillar, corresponding to the Sulcus accessorius sinister.
- 31 *Pila coronaria dorsalis.* Left dorsal coronary pillar, limits the caudodorsal blind sac. C
- 32 *Pila coronaria ventralis.* Left ventral coronary pillar, limits the caudoventral blind sac. C
- 33 *Ostium intraruminale.* Opening between the dorsal and ventral sacs. It is bounded by the cranial, caudal, and longitudinal pillars. C
- 34 *Sulcus ruminoreticularis.* Ruminoreticular groove. A
- 35 *Plica ruminoreticularis.* Ruminoreticular fold. C
- 36 *Ostium ruminoreticulare.* Opening between rumen and reticulum. C



A Rumen and reticulum, left side (bo)

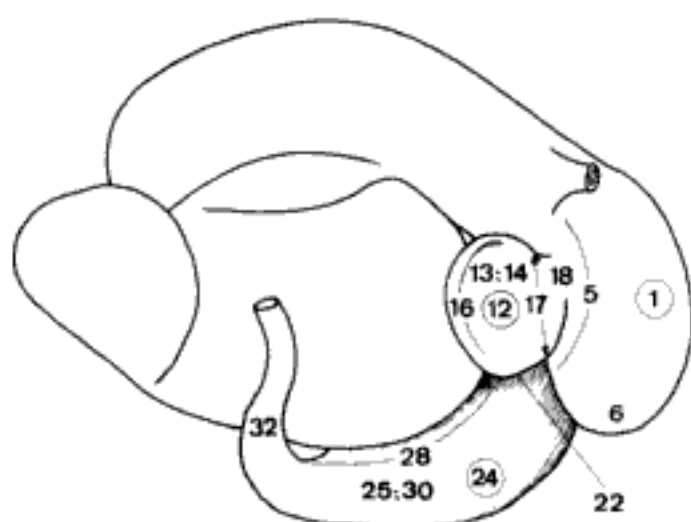


B Rumen and reticulum, right side (bo)

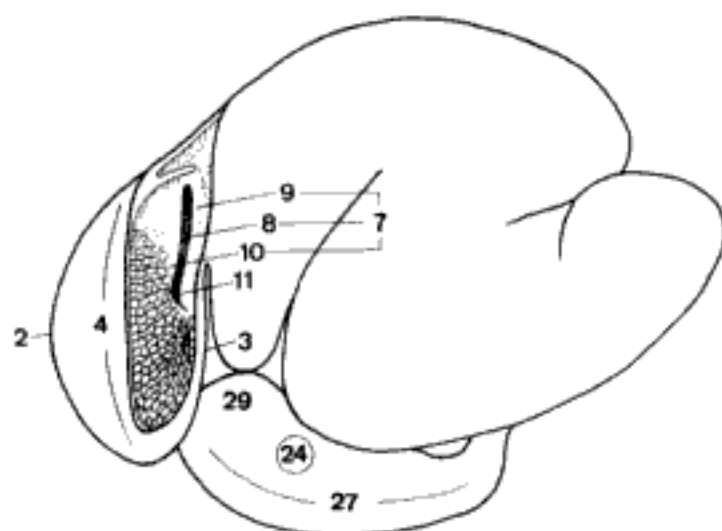


C Rumen and reticulum, interior viewed from the left (bo)

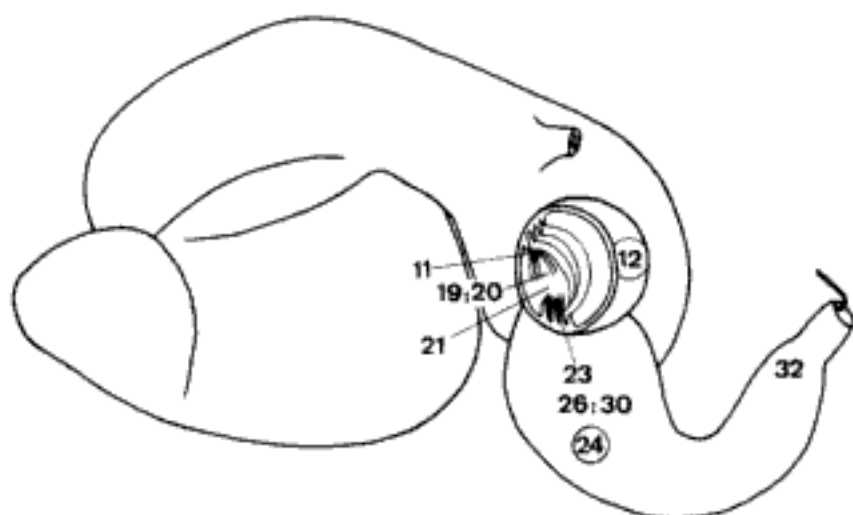
- 1 **Reticulum.** Most cranial compartment of the ruminant stomach, named for its network of mucosal crests. A
- 2 *Facies diaphragmatica.* Surface in contact with the diaphragm. B
- 3 *Facies visceralis.* Surface toward the rumen. B
- 4 *Curvatura major.* The greater curvature courses on the left side and ventrally. B
- 5 *Curvatura minor.* The lesser curvature faces to the right and caudally and is connected to the omasum. A
- 6 *Fundus reticuli.* Rounded ventral portion. A
- 7 *Sulcus reticuli.* The reticular groove extends from the cardiac orifice to the reticulo-omasal orifice along the inside of the lesser curvature. B
- 8 *Fundus sulci reticuli.* Floor of the reticular groove, between the labia. B
- 9 *Labium dextrum,* Right (at the cardiac orifice) lip. B
- 10 *Labium sinistrum.* Left (at the cardiac orifice) lip. B
- 11 *Ostium reticulo-omasicum.* Opening from the reticulum to the omasum. B C
- 12 **Omasum.** Third compartment of the ruminant stomach. A C
- 13 *Corpus omasi.* Body of the omasum, between the Curvatura and the Basis. A
- 14 *Facies parietalis.* Side facing the liver. A
- 15 *Facies visceralis.* Side facing the rumen.
- 16 *Curvatura omasi.* Faces dorsally, caudally, and to the right. A
- 17 *Basis omasi.* The base faces cranially and to the left and is attached to the reticulum and to the abomasum. It contains the Sulcus omasi. A
- 18 *Collum omasi.* The neck is attached to the reticulum and contains the Ostium reticulo-omasicum. A
- 19 *Sulcus omasi.* Short segment of the Sulcus ventriculi in the omasum. It extends from the Ostium reticulo-omasicum to the Ostium omasoabomasicum. C
- 20 *Canalis omasi.* Formed by the Sulcus and the free borders of the Laminae omasi. C
- 21 *Pila omasi.* The transverse muscular pillar at the abomasal end of the Sulcus omasi. C
- 22 *Sulcus omasoabomasicus.* Exterior groove between omasum and abomasum. A
- 23 *Ostium omasoabomasicum.* C
- 24 **Abomasum.** Glandular part of the ruminant stomach. A B C
- 25 *Facies parietalis.* Side facing the abdominal wall. A
- 26 *Facies visceralis.* Side facing the Rumen. C
- 27 *Curvatura major.* Greater curvature. B
- 28 *Curvatura minor.* Lesser curvature. A
- 29 *Fundus abomasi.* Dilation cranial and to the left of the Ostium omasoabomasicum. B
- 30 *Corpus abomasi.* Body of the abomasum. A C
- 31 *Sulcus abomasi.* Groove between mucosal folds along the inside of the lesser curvature. 163 B
- 32 *Pars pylorica.* Pyloric part. A C



A Stomach, right side (ov)

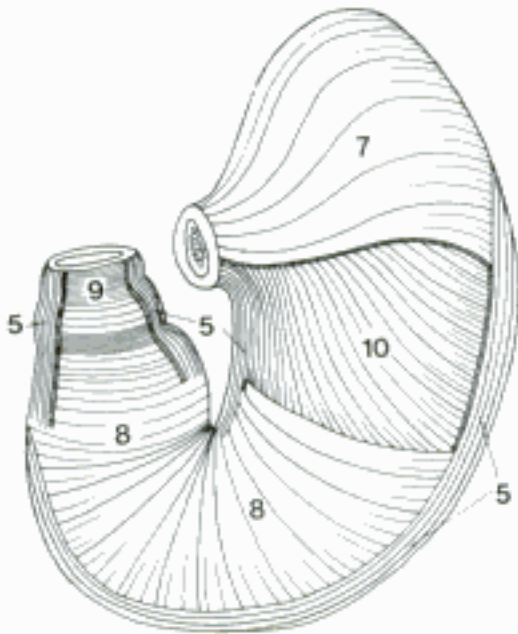


B Stomach, left side (part of the wall of the reticulum removed) (ov)

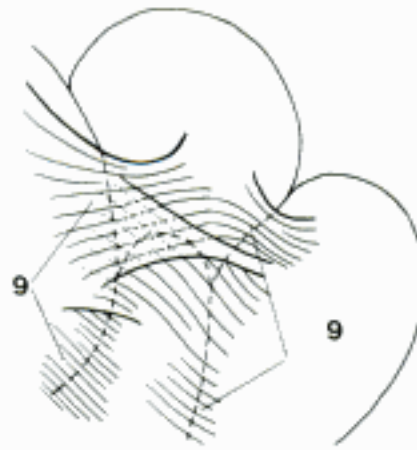


C Stomach, right side (omasum and abomasum drawn cranially and to the right, part of visceral wall of omasum removed) (ov)

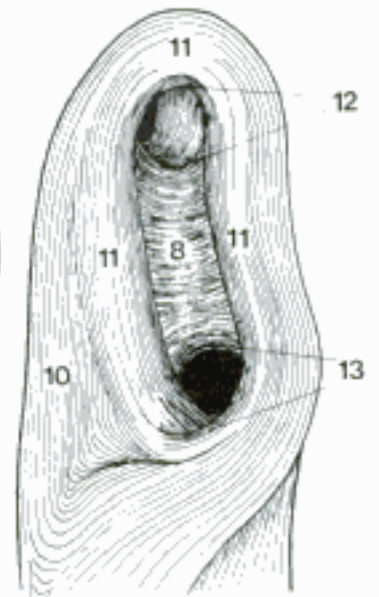
- 1 **Paries ventriculi.** Wall of the stomach.
- 2 *Tunica serosa.* Serous membrane. It is composed of mesothelium and a layer of connective tissue. D
- 3 *Tela subserosa.* Layer of loose connective tissue and fat under the Tunica serosa. D
- 4 *Tunica muscularis.* Main muscular coat. A D
- 5 *Stratum longitudinale.* Outer, longitudinal layer. It is incomplete. A
- 6 *Fibrae ruminoreticuloabomasicae.* Sheets of superficial muscle connecting the Reticulum, Atrium ruminis, Saccus ventralis, and Fundus abomasi on the left side. B
- 7 *Fibrae obliquae externae.* On the parietal and visceral surface of the fundus and cardiac portion of the corpus, the exterior muscle fibers are oblique. A
- 8 *Stratum circulare.* Middle, circular, and most extensive layer. A C
- 9 *M. sphincter pylori.* The thickened circular muscle at the pylorus. A
- 10 *Fibrae obliquae internae.* Internal oblique fibers that spread out from the Pars cardiaca toward the Curvatura major. A C
- 11 *Ansa cardiaca.* Cardiac loop, tract of internal oblique fibers that passes from one side of the Sulcus ventriculi on the other around the Ostium cardiacum. In Ru it forms the longitudinal musculature of the lips of the Sulcus reticuli. C
- 12 *M. sphincter cardiae.* Muscle around the Ostium cardiacum, formed by the Ansa cardiaca and the Stratum circulare. C
- 13 *M. sphincter reticulo-omasicus.* Reticulo-omasal sphincter, formed by fibers from the lips of the Sulcus reticuli and by the circular muscle. C
- 14 *Tela submucosa.* Loose connective tissue under the mucous membrane. D
- 15 *Tunica mucosa.* Mucous membrane. In Car it is entirely glandular, in Un it presents a Pars glandularis and a Pars nonglandularis. D E F G H I
- 16 *Pars glandularis.* Glandular part of the Tunica mucosa. D H
- 17 *Plicae gastricae.* Folds of the mucous membrane, generally longitudinal. H
- 18 *Lamina muscularis mucosae.* Thin sheet of smooth muscle forming the deepest layer of the mucous membrane, gives off bundles into the Lamina propria. D E F G
- 19 *Areae gastricae.* Gastric fields of 1–5 mm in diameter, bounded by a network of Sulci gastrici. D
- 20 *Sulci gastrici.* Grooves between Areae gastricae. D
- 21 *Plicae villosae.* Microscopic projections between the Foveolae gastricae in the Pars pylorica. G
- 22 *Foveolae gastricae.* Microscopic gastric pits, into which glands open. D E F G
- 23 *Glandulae cardiae.* Cardiac glands. In su they occupy the fundus, the diverticulum, and part of the corpus. In other species they are limited to a narrow zone at the beginning of the Pars glandularis. E
- 24 *Glandulae gastricae [propriae].* Proper gastric glands, characterized by zymogenic and parietal cells. They line Corpus and in Car also Fundus ventriculi, in Ru Corpus and Fundus abomasi. F
- 25 *Glandulae pyloricae.* Pyloric glands, found in the Pars pylorica. G
- 26 *Lymphonoduli [Noduli lymphatici] gastrici.* Gastric lymph nodules. E
- 27 *Pars nonglandularis.* Nonglandular part of the Tunica mucosa, covered by stratified squamous epithelium (Un). H
- 28 *Margo plicatus (s u, e q).* Sinuous thick border between the nonglandular and glandular parts. H
- 29 *Papillae ruminis.* Finger-, tongue-, or leaf-shaped projections of the mucous membrane, about 1 cm long. I
- 30 *Cellulae reticuli.* Cells of the reticulum, 4-, 5-, or 6-sided recesses enclosed by Cristae reticuli. I
- 31 *Cristae reticuli.* Reticular crests, permanent folds of the mucous membrane. I
- 32 *Papillae reticuli.* The papillae on the crests and in the cells of the reticulum are conical. I



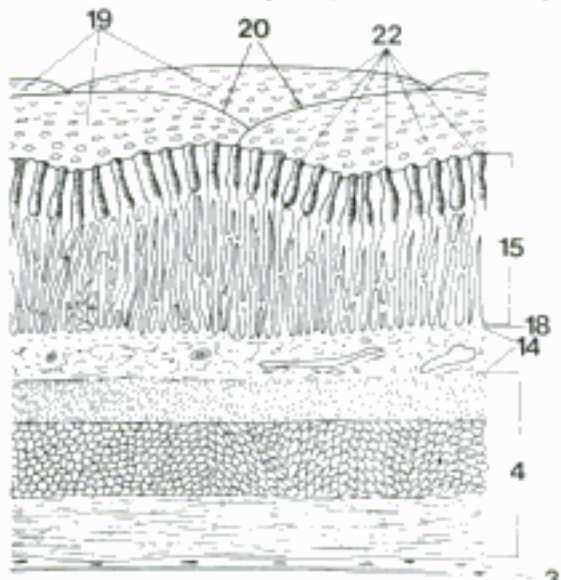
A Stomach musculature (parts of longitudinal, circular, and external oblique layers removed) (eq)



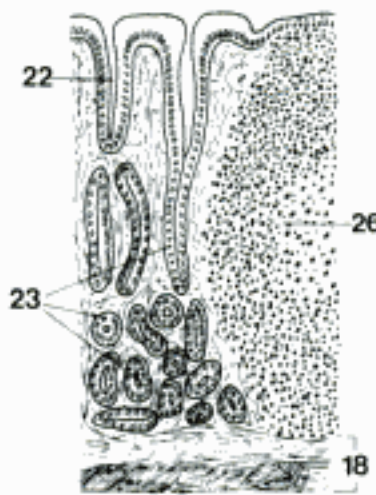
B Parts of ruminant stomach, left side (reticulum left, ventral sac of rumen right, atrium above, fundus of abomasum below) (Hofmann)



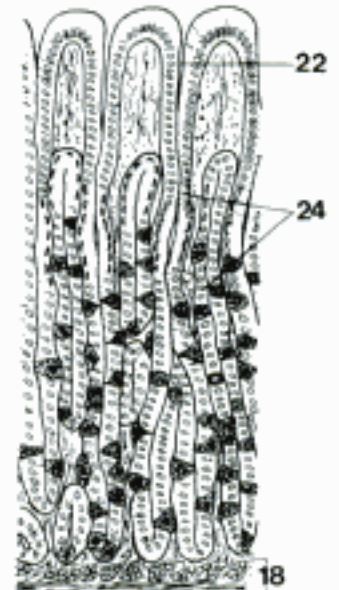
C Musculature of the reticular groove (bo)



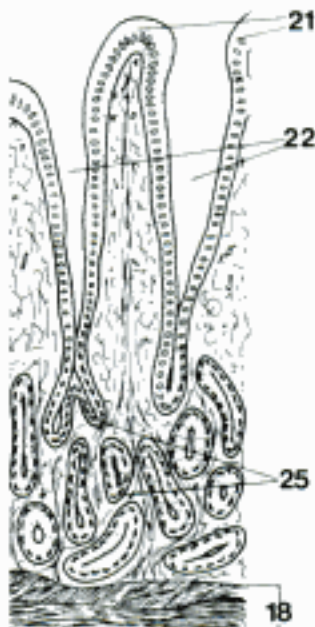
D Glandular stomach wall, stereoscopic



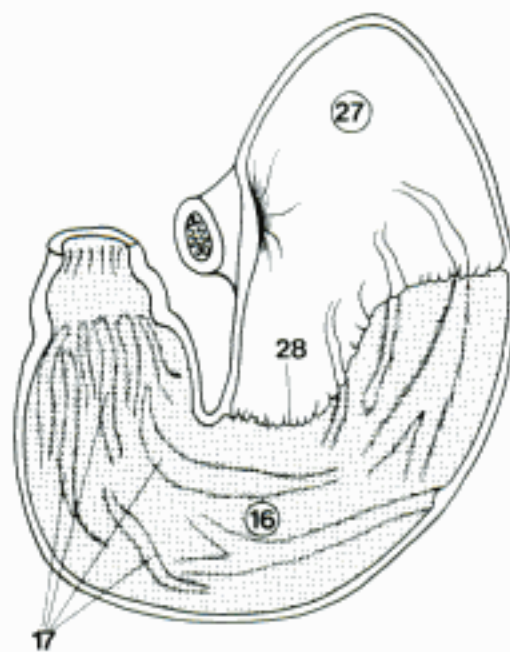
E Cardiac glands (su)



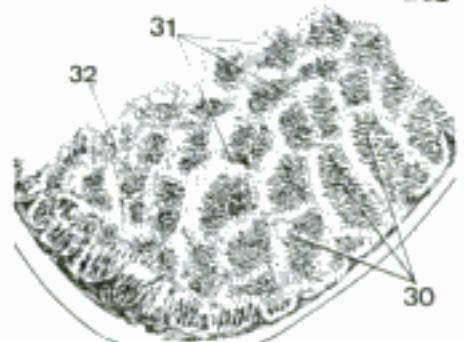

F Proper gastric glands (ca)



G Pyloric glands (ca)

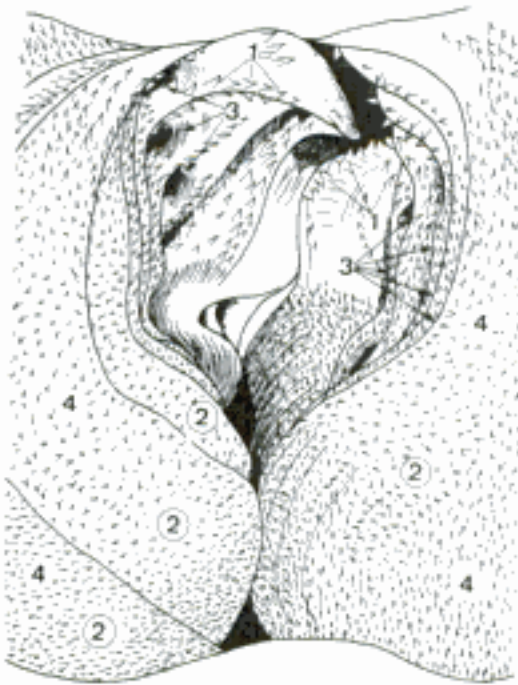


H Gastric mucosa (parietal wall removed) (eq)

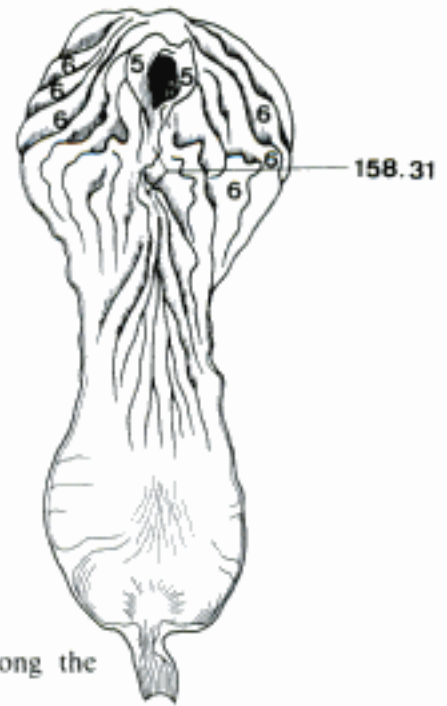


I Mucosa of rumen (above), and reticulum (below) (ov)

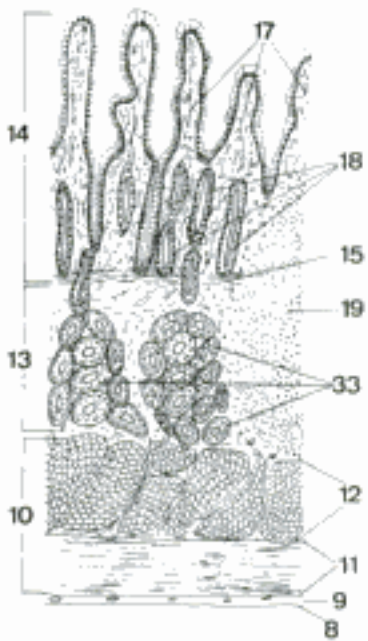
- 1 *Papillae unguiculiformes* (Ru). Long, curved, sharp, claw-shaped projection in and near the Ostium reticulo-omasicum. A
- 2 *Laminae omasi*. Flat parallel folds of mucous membrane extending from the Curvatura toward the Sulcus omasi. A
- 3 *Recessus interlaminares*. Narrow spaces between the laminae. A
- 4 *Papillae omasi*. Omasal papillae, large on the reticular ends and smaller on the abomasal ends of the laminae. A
- 5 *Vela abomasica*. Folds of mucous membrane on both sides of the Ostium omasoabomasicum. B
- 6 *Plicae spirales abomasi*. Large mucosal folds in the fundus and corpus. They extend obliquely toward the Curvatura major and Pars pylorica. B
- 7 **INTESTINUM TENUE**. Small intestine, the duodenum, jejunum, and ileum.
- 8 *Tunica serosa*. Serous membrane, composed of mesothelium and a layer of connective tissue. C
- 9 *Tela subserosa*. Layer of loose connective tissue under the Tunica serosa. C
- 10 *Tunica muscularis*. Main muscular coat. C
- 11 *Stratum longitudinale*. Outer, longitudinal layer. C
- 12 *Stratum circulare*. Inner, circular layer. C
- 13 *Tela submucosa*. Loose connective tissue under the Tunica mucosa. C
- 14 *Tunica mucosa*. The mucous membrane is glandular and bears villi covered by columnar epithelium. C
- 15 *Lamina muscularis mucosae*. Thin sheet of smooth muscle forming the deepest layer of the mucous membrane. It sends bundles into the villi. C
- 16 *Plicae circulares*. Circular folds of mucosa and submucosa. D, E
- 17 *Villi intestinales*. Minute projections of the mucous membrane. They are about 1 mm long and give the surface a velvet-like appearance. C
- 18 *Gll. intestinales*. Intestinal glands. C
- 19 *Lymphonoduli [Noduli lymphatici] solitarii*. Solitary lymph nodules, 0.15–1.5 mm in diameter. C
- 20 *Lymphonoduli [Noduli lymphatici] aggregati*. Aggregated lymph nodules, plaques of lymphatic tissue. D
- 21 **Duodenum**. Part of the small intestine from the Pylorus to the Flexura duodenojejunalis. F
- 22 *Pars cranialis*. Part of the duodenum between the pylorus and the Flexura duodeni cranialis. F
- 23 *Ampulla duodeni*. Duodenal bulb, a dilation of the Pars cranialis. F
- 24 *Ansa sigmoidea*. S-shaped loop, the double curvature of the Pars cranialis in Un. F
- 25 *Flexura duodeni cranialis*. Cranial flexure between Pars cranialis and Pars descendens. F
- 26 *Pars descendens*. Descending part, running caudally on the right side. F
- 27 *Flexura duodeni caudalis*. Caudal flexure between Pars descendens and Pars transversa. F
- 28 *Pars transversa [Pars caudalis]*. Transverse part. F
- 29 *Pars ascendens*. Ascending part, running cranially from the Pars transversa to the Flexura duodenojejunalis. F
- 30 *Flexura duodenojejunalis*. The flexure is marked by an abrupt lengthening of the mesentery. F
- 31 *Papilla duodeni major*. Projection of the duodenal mucosa bearing the opening of the Ductus choledochus and of the Ductus pancreaticus if present. E
- 32 *Papilla duodeni minor*. Projection of the duodenal mucosa bearing the opening of the Ductus pancreaticus accessorius. E
- 33 *Gll. duodenales*. Duodenal glands. Branched, tubuloalveolar mucous glands in the submucosa. According to species they may occupy a short initial part of the duodenum or extend far beyond it. C
- 34 **Jejunum**. Part of the small intestine between duodenum and ileum. F




A Omasal groove (opened by cutting parallel to the laminae) (ov)



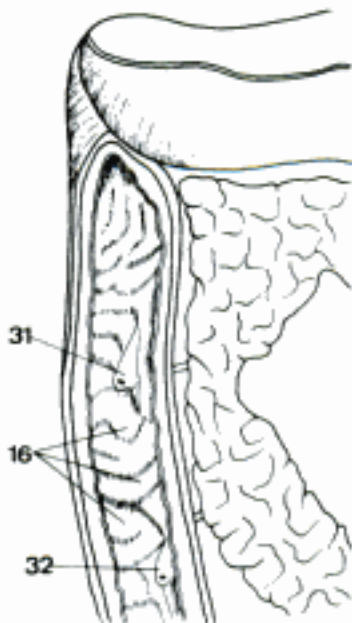
B Abomasum (opened along the greater curvature) (ov)



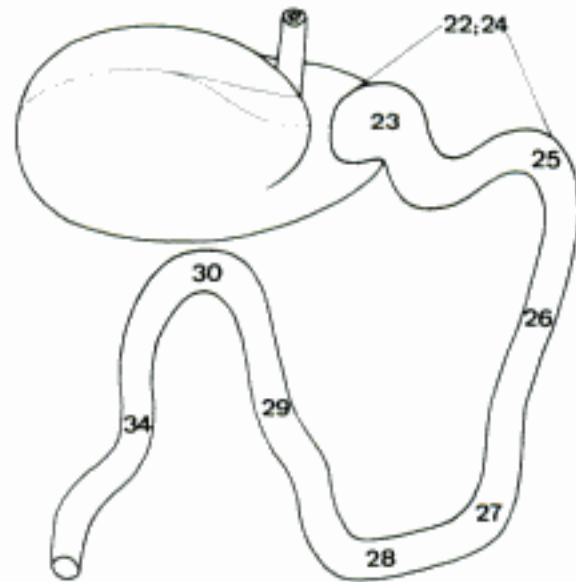
C Duodenum, histological section (bo)



D Jejunal mucosa (eq)

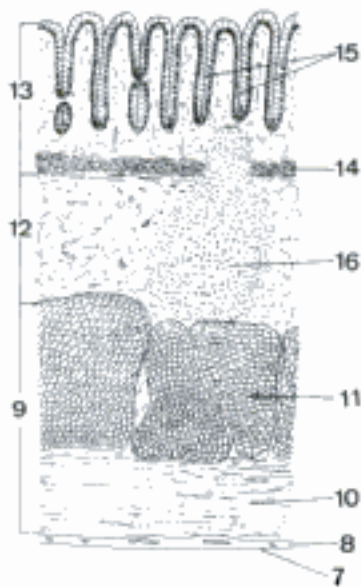


E Descending duodenum (opened ventrally) (ca)

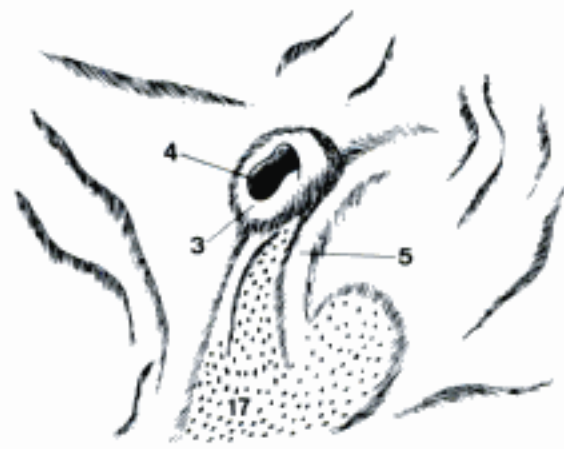

F Stomach and duodenum, dorsal aspect (eq)

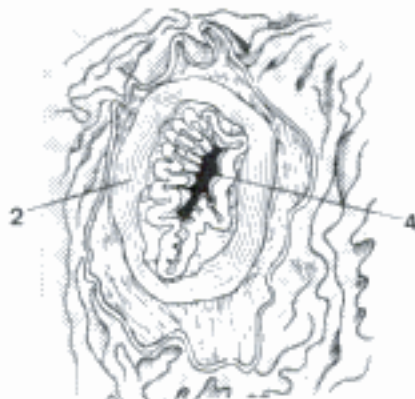
- 1 **Ileum**. Defined in veterinary anatomical literature as the short terminal part of the small intestine to which the Plica ileocecalis is attached. D
- 2 *M. sphincter ilei*. Circular muscular around the terminal ileum. C
- 3 *Papilla ilealis*. Projection of the end of the ileum into the lumen of the large intestine. B E
- 4 *Ostium ileale*. Opening of the ileum. B C
- 5 *Frenulum papillae ilealis*. Fold of Tunica mucosa of the large intestine attached to the Papilla ilealis. B
- 6 **INTESTINUM CRASSUM**. Large intestine, the cecum, colon, rectum, and Canalis analis.
- 7 *Tunica serosa*. Serous membrane, composed of mesothelium and a layer of connective tissue. A
- 8 *Tela subserosa*. Layer of loose connective tissue under the serosa. A
- 9 *Tunica muscularis*. Main muscular coat. A
- 10 *Stratum longitudinale*. Outer, longitudinal layer. A
- 11 *Stratum circulare*. Inner, circular layer. A
- 12 *Tela submucosa*. Loose connective tissue under the Tunica mucosa. A
- 13 *Tunica mucosa*. Mucous membrane. It is glandular, but does not bear villi. A
- 14 *Lamina muscularis mucosae*. Thin sheet of smooth muscle forming the deepest layer of the mucous membrane. It sends bundles between the glands. A
- 15 *Gll. intestinales*. Intestinal glands. A
- 16 *Lymphonoduli [Noduli lymphatici] solitarii*. Solitary lymph nodules, 0.15–1.5 mm in diameter. A
- 17 *Lymphonoduli [Noduli lymphatici] aggregati*. Aggregated lymph nodules, elongated plaques of lymphatic tissue. B
- 18 **Cecum [Caecum]**. Blind intestine. It opens freely into the Colon at the Papilla ilealis, except in eq, where the junction is at the Ostium cecocolicum.
- 19 *Basis ceci [caeci]*. Dorsal dilation of the Cecum in eq. The part cranial to the Papilla ilealis develops from the first part of the embryonic Colon. D E
- 20 *Corpus ceci [caeci]*. Body of the cecum. D E
- 21 *Apex ceci [caeci]*. Apex of the cecum. D
- 22 *Curvatura ceci [caeci] major*. Greater curvature of the cecum. D
- 23 *Curvatura ceci [caeci] minor*. Lesser curvature of the cecum. D
- 24 *Teniae ceci [Taeniae caeci]*. Bands of the cecum in su and eq. The longitudinal layer of the Tunica muscularis is thickened to form the bands and is thin elsewhere.
- 25 *Tenia [Taenia] dorsalis*. Absent in su. D
- 26 *Tenia [Taenia] ventralis*. D
- 27 *Tenia [Taenia] medialis*. D
- 28 *Tenia [Taenia] lateralis*. E
- 29 *Haustra ceci [caeci]*. Sacculations of the cecum between the Teniae and between the Plicae semilunares. D E
- 30 *Plicae semilunares ceci [caeci]*. Semilunar folds of the cecum formed by contraction of the wall between haustra. E
- 31 *Ostium cecocolicum [caeco-]*. Opening from the cecum to the colon. E F
- 32 *Valva cecocolica [caeco-] (eq)*. Cecocolic valve, formed by two mucosal folds. E
- 33 *M. sphincter ceci [caeci]*. Sphincter of the cecum, the muscle around the Ostium cecocolicum in eq. F



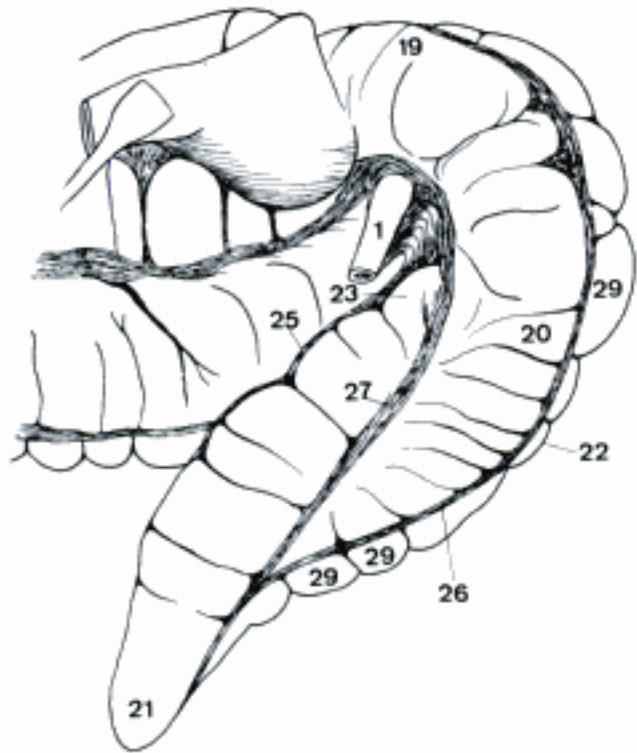
A Colon, histological section



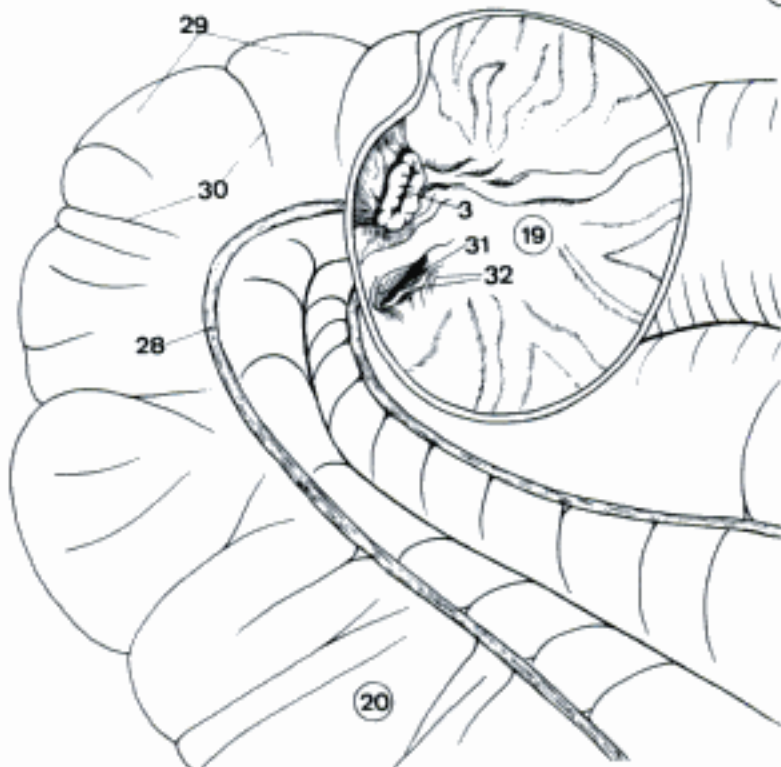
B Ileal papilla (ov)



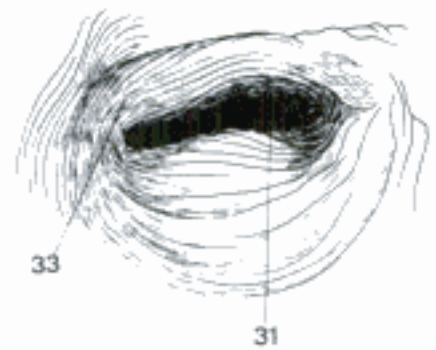
C Ileal papilla (mucosa removed) (cq)



D Cecum, ileum, and large colon, left side (transverse colon retracted) (eq)

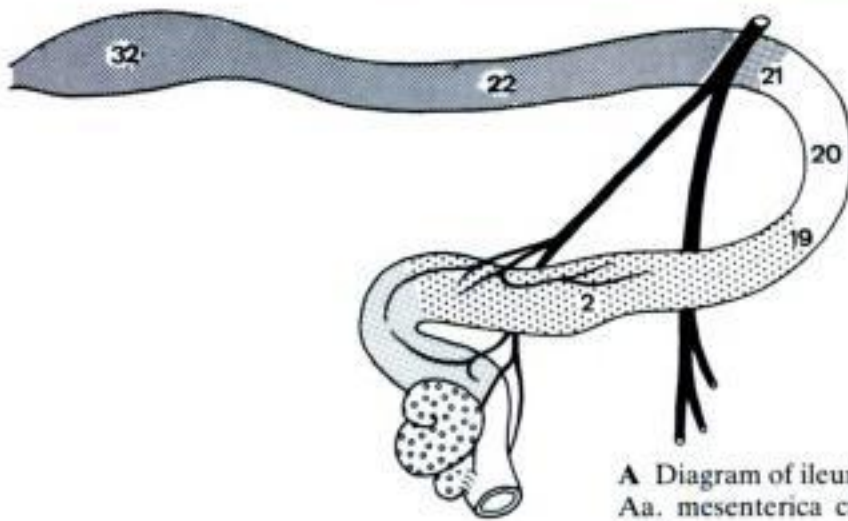


E Cecum and large colon, right side (base of cecum opened) (cq)

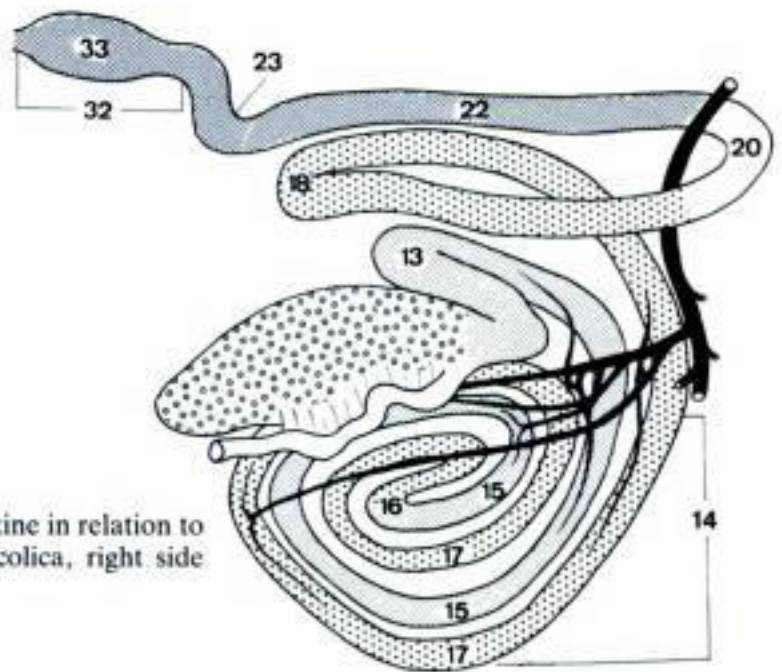


F Cecal sphincter (mucosa removed) (cq)

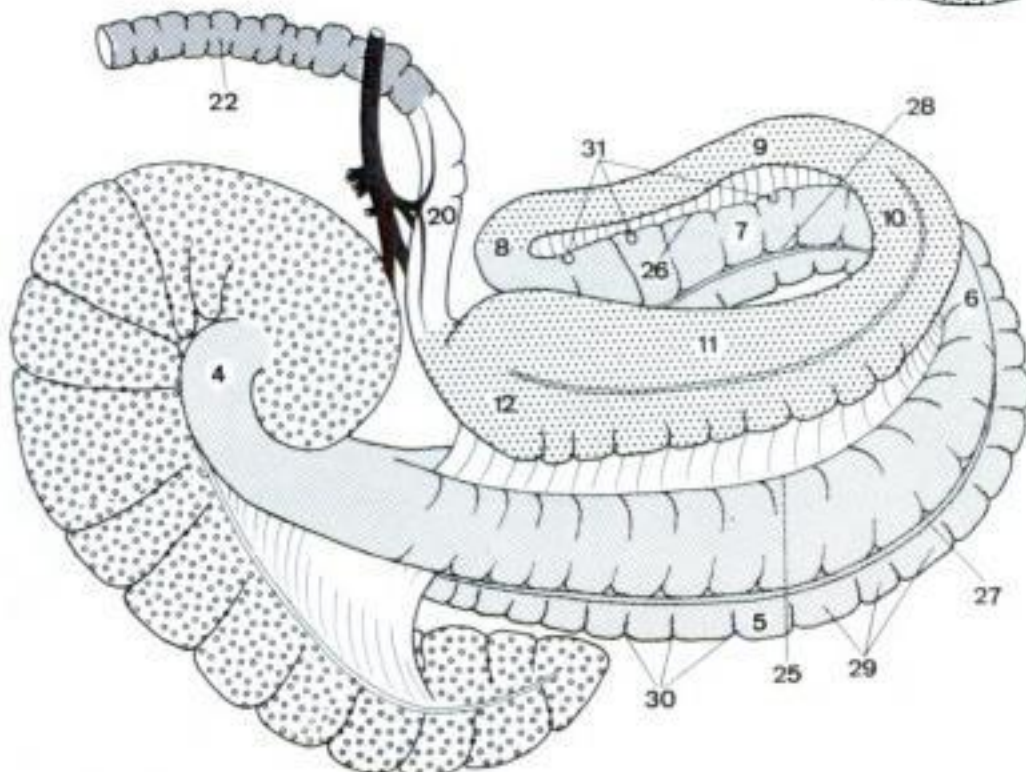
- 1 **Colon.** Part of the large intestine from the cecum to the rectum.
- 2 *Colon ascendens.* Ascending colon, extends from the cecum to the Colon transversum. A B C
- 3 *Colon crassum (eq).* Large colon. It is a loop formed by the Colon ventrale and the Colon dorsale, which bend around to the left side. C
- 4 Collum coli. Neck of the colon. C
- 5 Colon ventrale dextrum. Right ventral colon. It extends from the cecum to the Flexura sternalis, and has four teniae and haustra. C
- 6 Flexura sternalis [diaphragmatica ventralis]. Sternal flexure. C
- 7 Colon ventrale sinistrum. Left ventral colon, extends from the Flexura sternalis to the Flexura pelvina, and has four teniae and haustra. C
- 8 Flexura pelvina. Pelvic flexure. C
- 9 Colon dorsale sinistrum. Left dorsal colon, extends from the Flexura pelvina to the Flexura diaphragmatica. It is smooth and has one tenia in the mesocolic attachment. C
- 10 Flexura diaphragmatica [dorsalis]. Diaphragmatic flexure. C
- 11 Colon dorsale dextrum. Right dorsal colon, the terminal part of the Colon crassum. It joins the Colon transversum and has three teniae. C
- 12 Ampulla coli. Dilation of the Colon dorsale dextrum. C
- 13 *Ansa proximalis coli (Ru).* Proximal loop of the colon, the first part of the Colon ascendens, S-shaped, continued by the Ansa spiralis. B
- 14 *Ansa spiralis coli (su, Ru).* Spiral loop. It is coiled on the left side of the mesentery. B
- 15 Gyri centripetales. Coils in which the ingesta move toward the Flexura centralis. B
- 16 Flexura centralis. Central flexure where the last in-going coil is continuous with the first out-going coil. B
- 17 Gyri centrifugales. Coils in which the ingesta move away from the Flexura centralis toward the Ansa distalis. B
- 18 *Ansa distalis coli (su, Ru).* Distal loop of the colon, the last part of the Colon ascendens. B
- 19 *Flexura coli dextra.* Right flexure of the colon. It connects the Colon ascendens to the Colon transversum. A
- 20 *Colon transversum.* The transverse colon passes from right to left cranial to the cranial mesenteric artery, joining the right and left colic flexures. A B C
- 21 *Flexura coli sinistra.* Left flexure of the colon, connects the Colon transversum to the Colon descendens. A
- 22 *Colon descendens [Colon tenue (eq)].* Descending colon, extends from the Flexura coli sinistra to the rectum. A B C
- 23 *Colon sigmoideum.* Sigmoid colon, an S-shaped curve just cranial to the rectum in bo. B
- 24 *Teniae [Taeniae] coli.* Bands of the colon, formed by longitudinal muscle. There are two in su. In eq the left dorsal colon has one; the right dorsal colon, three; and the ventral colon, four.
- 25 *Tenia [Taenia] mesocolica lateralis.* Lateral mesocolic band in eq. C
- 26 *Tenai [Taenia] mesocolica medialis.* Medial mesocolic band in eq. C
- 27 *Tenia [Taenia] libera laterlis.* Lateral free band. C
- 28 *Tenia [Taenia] libera medialis.* Medial free band. C
- 29 *Haustra coli.* Sacculations of the colon between Teniae and between Plicae semilunares. C
- 30 *Plicae semilunares coli.* Semilunar folds of the colon formed by contraction of the wall between haustra. C
- 31 *Appendices epiploicae.* Pendant fat bodies covered by peritoneum, attached along the Teniae coli. C
- 32 **Rectum.** Pelvic part of the large intestine. It terminates at the Canalis analis. A B
- 33 *Ampulla recti.* Enlargement of the terminal part. B



A Diagram of ileum and large intestine in relation to Aa. mesenterica cranialis and ileocolica, right side (ca)

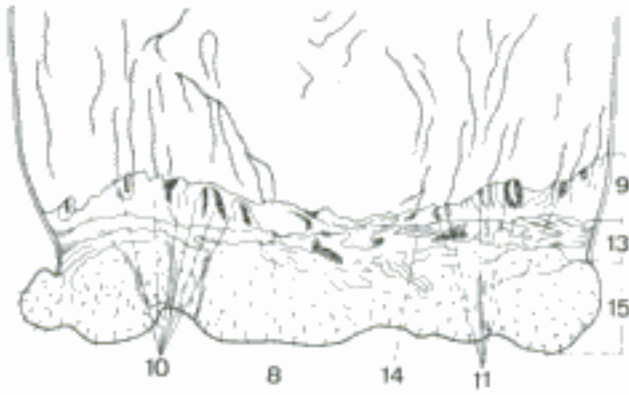


B Diagram of ileum and large intestine in relation to Aa. mesenterica cranialis and ileocolica, right side (bo)

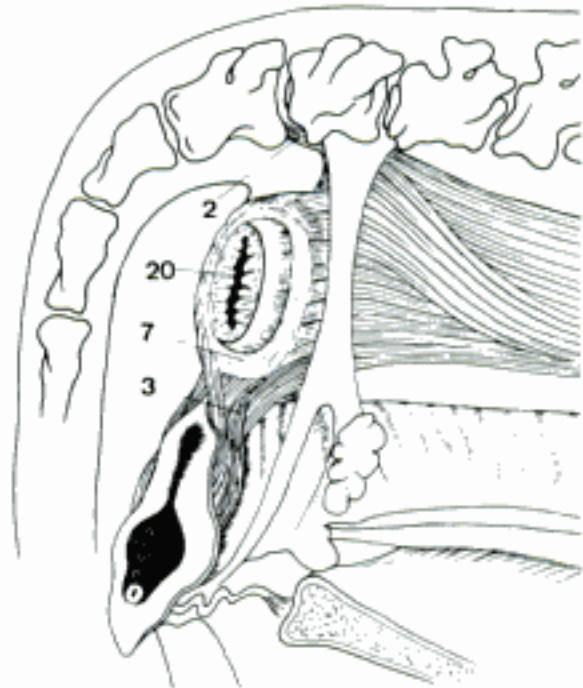


C Large intestine and A. mesenterica cranialis, right side, (left parts of large colon shortened) (eq)

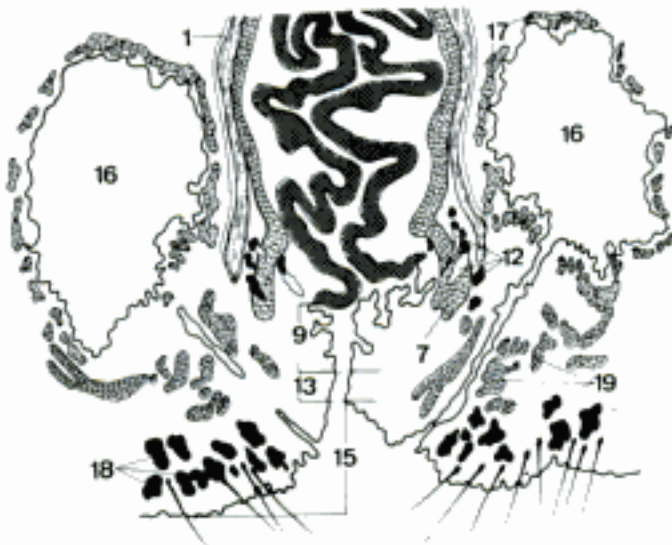- 1 *Tunica adventitia*. Connective tissue covering the retroperitoneal part of the rectum. C
- 2 *M. rectococcygeus*. O: caudal vertebrae 2–7, depending on species. T: rectum. B
- 3 *M. rectourethralis*. O: rectum. T: masc. urethra; fem. vestibule and labia. B
- 4 *Plicae transversales recti*. Temporary constrictions in Ru.
- 5 *Columnae rectales*. Rectal columns in Ru, short longitudinal folds of mucosa extending cranially from the Linea anorectalis.
- 6 **Canalis analis**. Anal canal, the terminal segment of the intestine, lined by stratified squamous epithelium. A
- 7 *M. sphincter ani internus*. Internal anal sphincter, smooth muscle continuous with the Stratum circulare of the rectum. B C
- 8 *Linea anorectalis*. Anorectal line, between rectal mucosa with simple columnar epithelium, and anal canal with stratified squamous epithelium. A
- 9 *Zona columnaris ani (ca, su)*. Columnar zone of the anus, lined by stratified squamous noncornified epithelium. A C
- 10 *Columnae anales*. Anal columns, short longitudinal folds of mucosa extending caudally from the Linea anorectalis, absent in Ru and eq. A
- 11 *Sinus anales*. Anal sinuses, the grooves between the columnae. A
- 12 *Gll. anales*. Anal glands, tubulo-alveolar, in the submucosa or outside the *M. sphincter ani internus*. C
- 13 *Zona intermedia*. Intermediate zone, lined by stratified squamous noncornified epithelium, between *Zona columnaris* and *Linea anocutanea*, narrow in ca. A C
- 14 *Linea anocutanea*. Anocutaneous line, boundary between mucous membrane and skin. A
- 15 *Zona cutanea*. Cutaneous zone, cornified epidermis, skin glands, and hairs. A C
- 16 *Sinus paranalisis (Car)*. Paranal sinus, lateral cutaneous pouch between *Canalis analis* and *M. sphincter ani externus*. C
- 17 *Gll. sinus paranalisis*. Glands of the paranal sinus, *Gll. apocrinae* and *Gll. sebaceae*. C
- 18 *Gll. circumanales (ca)*. Circumanal glands, lobules composed of large polyhedral cells, derived from sebaceous glands, but have no ducts. C
- 19 *M. sphincter ani externus* (vide *Perineum*). C
- 20 *Anus*. Terminal orifice of the intestine. B
- 21 **HEPAR**. Liver.
- 22 *Facies diaphragmatica*. Diaphragmatic surface. F
- 23 *Area nuda*. Bare spot, not covered by *Tunica serosa*. F
- 24 *Sulcus venae cavae*. Groove for the *V. cava caudalis*. F
- 25 *Facies visceralis*. Visceral surface, in contact with the stomach. D
- 26 *Fossa vesicae felleae*. Gall bladder fossa. D E
- 27 *Fissura lig. teretis*. Fissure for the round ligament. D
- 28 *Lig. teres hepatis*. Round ligament of the liver, vestige of the *V. umbilicalis*. D
- 29 *Sulcus venae umbilicalis* (ont). Groove for the umbilical vein. E
- 30 *Fossa ductus venosi* (ont). Groove for the *Ductus venosus*. E
- 31 *Porta hepatis*. Hilus of the liver. D
- 32 *Tuber omentale (Car)*. Omental tuber, prominence of the visceral surface of the left lateral lobe. D
- 33 *Impressio esophagea [oesophagea]*. Esophageal impression on the *Margo dorsalis*. 171 A
- 34 *Impressio gastrica*. Impression of the stomach on the left lobe. 171 A
- 35 *Impressio reticularis*. Impression of the reticulum on the left lobe. 171 B



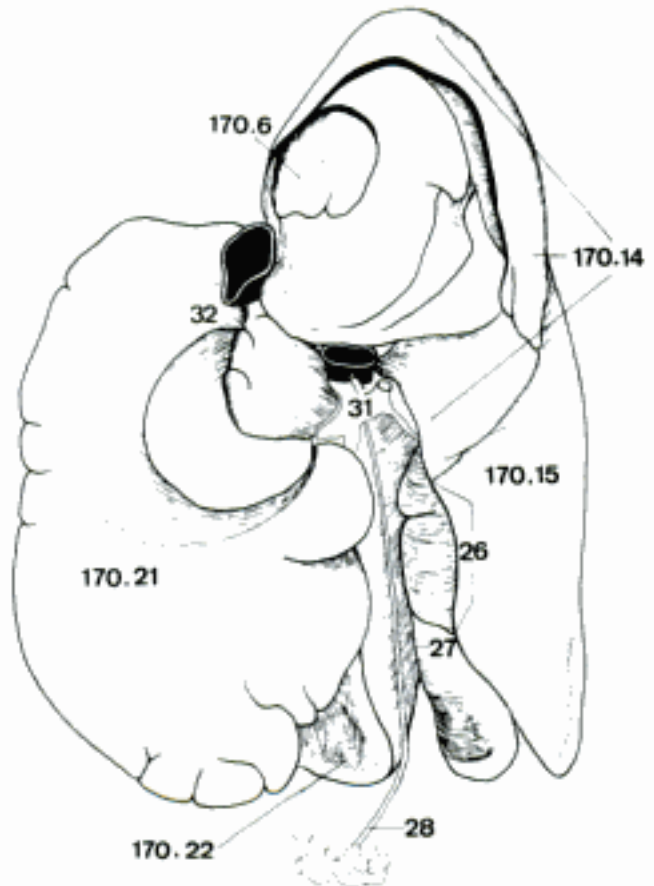
A Anal canal (opened dorsally) (su)



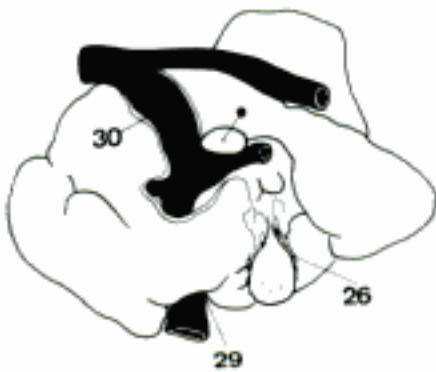B Perineum (bo) (Geiger)



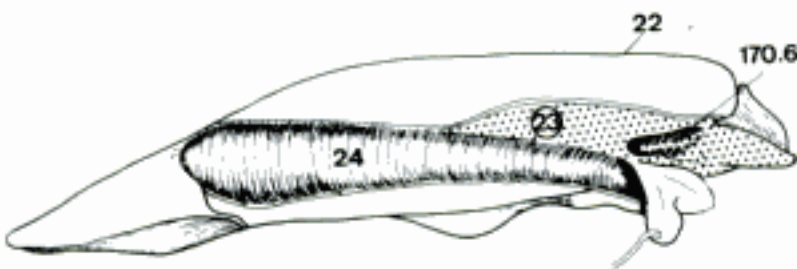
C Anal canal (ca) (Gerisch and Neurand)



D Liver, visceral surface (ca)

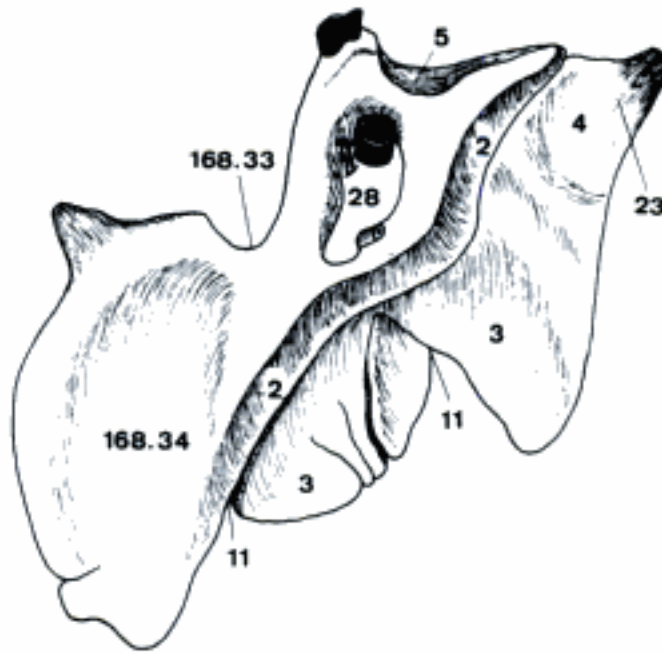


E Liver (Ductus venosus exposed by dissection) (bo, fetus)

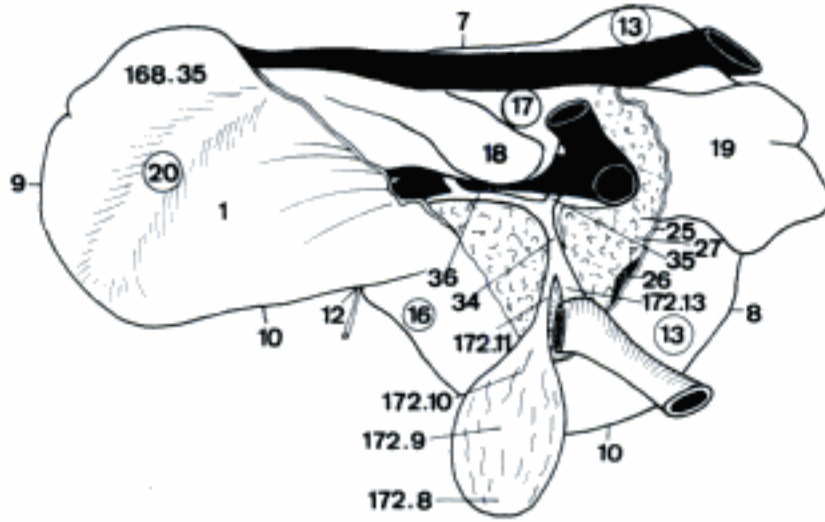


F Liver, dorsal border (adrenal gland reflected) (bo)

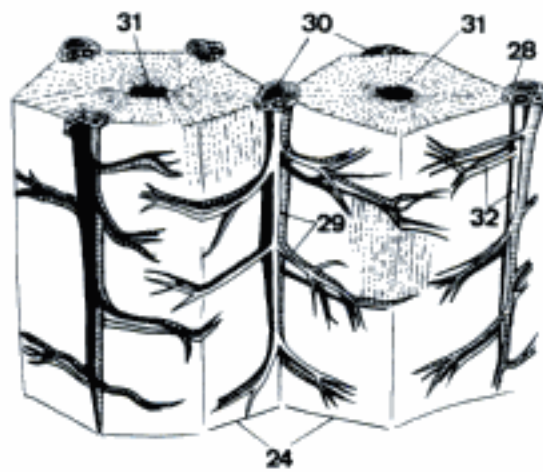
- 1 *Impressio omasica*. Omasal impression, occupies a large part of the visceral surface. B
- 2 *Impressio duodenalis*. Duodenal impression, ventral and to the right of the porta. A
- 3 *Impressio colica*. Colic impression, on the right ventral part of the visceral surface. A
- 4 *Impressio cecalis [caecalis] (eq)*. Cecal impression, on the right lobe. A
- 5 *Impressio renalis*. Renal impression, on the right lobe and caudate process, absent in su. A
- 6 *Impressio adrenalis [supra-]*. Impression by the right adrenal gland on the Lobus caudatus. 169 D F
- 7 *Margo dorsalis*. Dorsal border, in Ru almost median. B
- 8 *Margo dexter*. Right border, in Ru dorso-caudal. B
- 9 *Margo sinister*. Left border, in Ru cranioventral. B
- 10 *Margo ventralis*. Ventral border, in Ru on the right side of the body. B
- 11 *Incisurae interlobares*. Interlobar notches. A
- 12 *Incisura lig. teretis*. Notch for the round ligament. B
- 13 *Lobus hepatis dexter*. Right lobe of the liver in Ru and eq. B
- 14 *Lobus hepatis dexter lateralis*. Right lateral lobe in Car and su. 169 D
- 15 *Lobus hepatis dexter medialis*. Right medial lobe in Car and su. 169 D
- 16 *Lobus quadratus*. Quadrangle lobe, between Fossa vesicae felleae and Incisura lig. teretis. B
- 17 *Lobus caudatus*. Caudate lobe, dorsal to the Porta hepatis. B
- 18 *Processus papillaris*. Papillary process, projection of the Lobus caudatus into the Vestibulum bursae omentalis in Car and Ru. B
- 19 *Processus caudatus*. Caudate process, elongated right projection from the visceral surface of the Lobus caudatus. B
- 20 *Lobus hepatis sinister*. Left lobe of the liver of Ru. B
- 21 *Lobus hepatis sinister lateralis*. Left lateral lobe of the liver of Car, su, eq. 169 D
- 22 *Lobus hepatis sinister medialis*. Left medial lobe of Car, su, eq, between left lateral lobe and Incisura lig. teretis. 169 D
- 23 (*Appendix fibrosa hepatis*). Fibrous appendage, vestige of an atrophied portion at the caudal end of the right lobe in old eq. A
- 24 *Lobuli hepatis*. Hepatic lobules, histological units of the liver, about 1 mm in diameter and 2 mm long. C
- 25 *Tunica serosa*. Serous membrane. B
- 26 *Tela subserosa*. B
- 27 *Tunica fibrosa*. Fibrous coat, the connective tissue on the outer surface of the liver between the parenchyma and the Tela subserosa. B
- 28 *Capsula fibrosa perivascularis*. Fibrous perivascular sheath (of Glisson), ensheathing bile ducts, branches of hepatic artery and portal vein. A C
- 29 *Arteriae interlobulares*. Between the Lobuli hepatis. C
- 30 *Venae interlobulares*. Branches of the portal vein between the Lobuli hepatis. C
- 31 *Venae centrales*. Terminal branches of the hepatic veins in the Lobuli hepatis. C
- 32 *Ductuli interlobulares*. Interlobular bile ductules. C
- 33 *Ductuli biliferi*. Biliferous ductules.
- 34 *Ductus hepaticus communis*. Common hepatic duct, from the junction of the right and left hepatic ducts to the entry of the cystic duct; absent in Car. B
- 35 *Ductus hepaticus dexter*. Right hepatic duct or ducts draining the right part of the liver. B
- 36 *Ductus hepaticus sinister*. Left hepatic duct or ducts draining the left part of the liver. B



A Liver, visceral surface (eq)

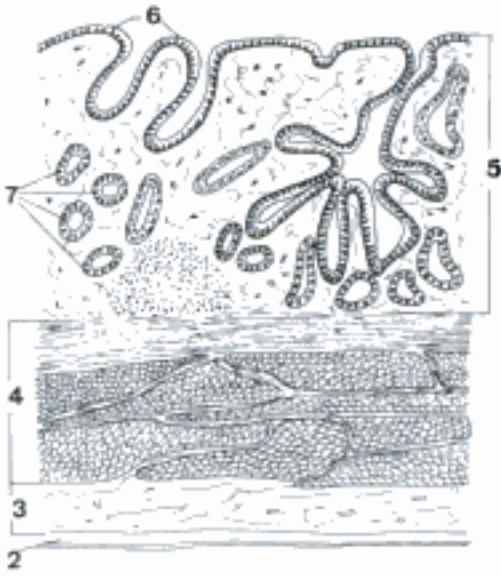

B Liver, visceral surface (rotated clockwise 90 degrees) (bo)

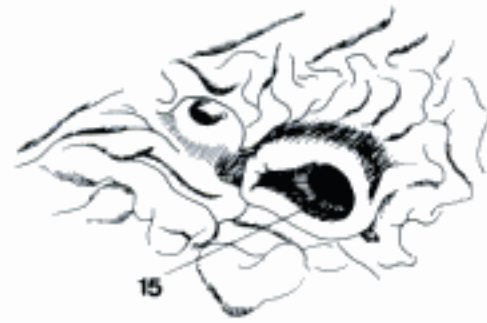

C Lobuli hepatis, stereoscopic

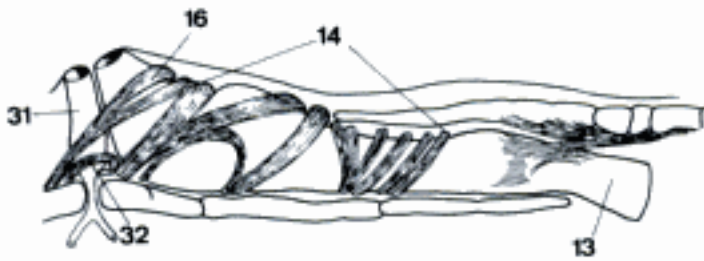
- 1 **Vesica fellea.** Gall bladder.
- 2 *Tunica serosa ves. felleae.* Serous membrane of the gall bladder. A
- 3 *Tela subserosa vesicae felleae.* Loose connective tissue under the serosa. A
- 4 *Tunica muscularis ves. felleae.* Muscular coat of the gall bladder. A
- 5 *Tunica mucosa ves. felleae.* Mucous membrane of the gall bladder, covered by simple columnar epithelium. A
- 6 *Plicae tunicae mucosae ves. felleae.* Folds of the mucous membrane. A
- 7 *Gll. vesicae felleae.* Glands of the gall bladder, numerous tubular glands in the body in Ru, rare and restricted to the neck in Car and su. A
- 8 *Fundus ves. felleae.* Bottom of the gall bladder, the blind end. 171 B
- 9 *Corpus ves. felleae.* Body of the gall bladder. 171 B
- 10 *Collum ves. felleae.* Neck of the gall bladder. 171 B
- 11 *Ductus cysticus.* Duct of the gall bladder. It joins the Ductus hepaticus communis to form the Ductus choledochus. 171 B
- 12 *Ductus hepatocystici.* Hepatocystic ducts, pass directly from the liver into the gall bladder, variably in Car, Ru.
- 13 **Ductus choledochus.** Common bile duct, formed by the union of cystic and common hepatic ducts and ending on the Papilla duodeni major. C 171 B
- 14 *M. sphincter ductus choledochi.* Terminal thickening of the circular muscle of the Ductus choledochus. C
- 15 *Ampulla hepatopancreatica.* Short common terminal duct formed by the bile and pancreatic ducts in the Papilla duodeni major (fe, eq). In ov, cap the bile and pancreatic ducts unite before they reach the duodenum. B
- 16 *M. sphincter ampullae hepatopancreaticae [M. sphincter ampullae].* A tract of muscle fibers passes around the ampulla (fe), or the hepatopancreatic duct (ov, cap), or the terminal parts of both ducts (ca, eq). C
- 17 **PANCREAS.** Large digestive gland associated with the stomach and the cranial and descending parts of the duodenum. D E F
- 18 *Lobus pancreatis dexter.* Right lobe, in the Mesoduodenum descendens. D E F
- 19 *Processus uncinatus (Ru).* Hooked process, extends medially from the right lobe around the caudodorsal surface of the portal vein. D
- 20 *Corpus pancreatis.* Body, the middle part, in contact with the cranial part of the duodenum. E F
- 21 *Tuber omentale.* Ventral prominence of the Corpus pancreatis in the Bursa omentalis. D
- 22 *Lobus pancreatis sinister.* Left lobe, on the visceral surface of the stomach, in Ru dorsal to the rumen. D E F
- 23 *Incisura pancreatis (Car, Ru).* Notch for the portal vein in the Margo caudalis. D E
- 24 *Anulus pancreatis (su, eq).* Ring of the pancreas around the portal vein. F
- 25 *Facies ventralis.* Ventral surface. D E F
- 26 *Facies dorsalis.* Dorsal surface.
- 27 *Margo cranialis.* Cranial border. E F
- 28 *Margo caudalis.* Caudal border. E F
- 29 *Margo dexter.* Right border. E F
- 30 *Margo sinister.* Left border. E F
- 31 *Ductus pancreaticus.* Pancreatic duct, opening on the Papilla duodeni major, main duct in fe, ov, cap, eq, absent in su, bo. C D E F
- 32 *M. sphincter ductus pancreatici.* C
- 33 *Ductus pancreaticus accessorius.* Opening on the Papilla duodeni minor, the largest duct in ca, the only one in su and bo. E F
- 34 *M. sphincter ductus pancreatici accessorii.*
- 35 (*Pancreas accessorium*). Accessory pancreas, reported in ca.



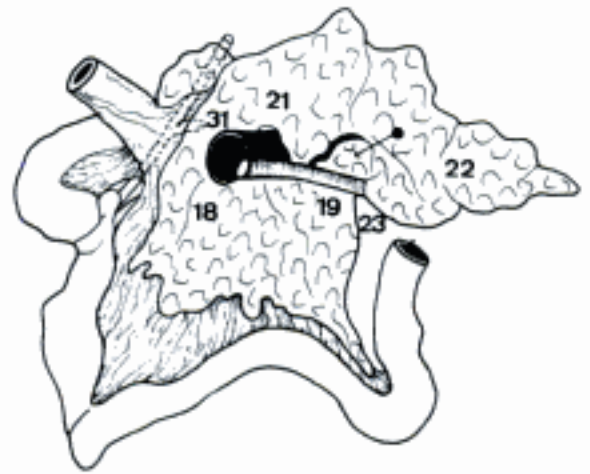
A Gall bladder, histological



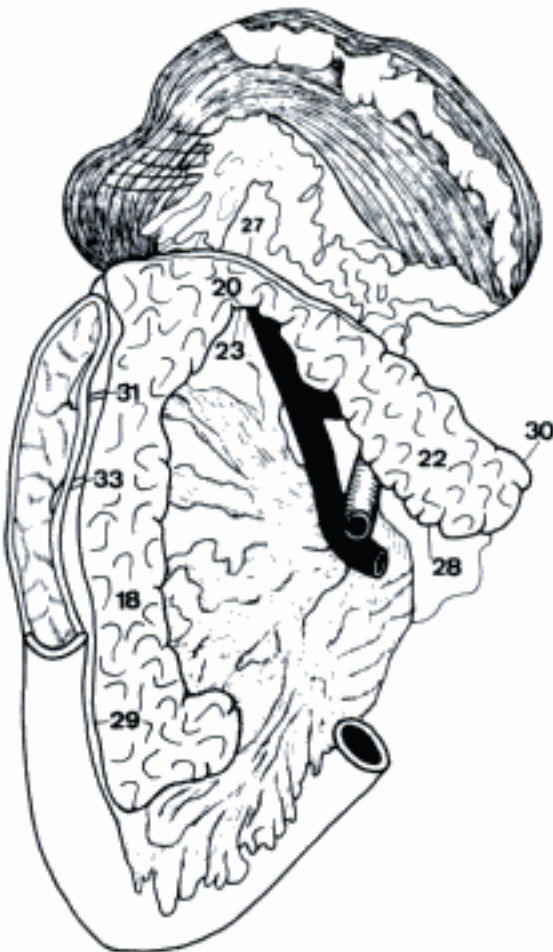
B Major and minor duodenal papillae (eq)



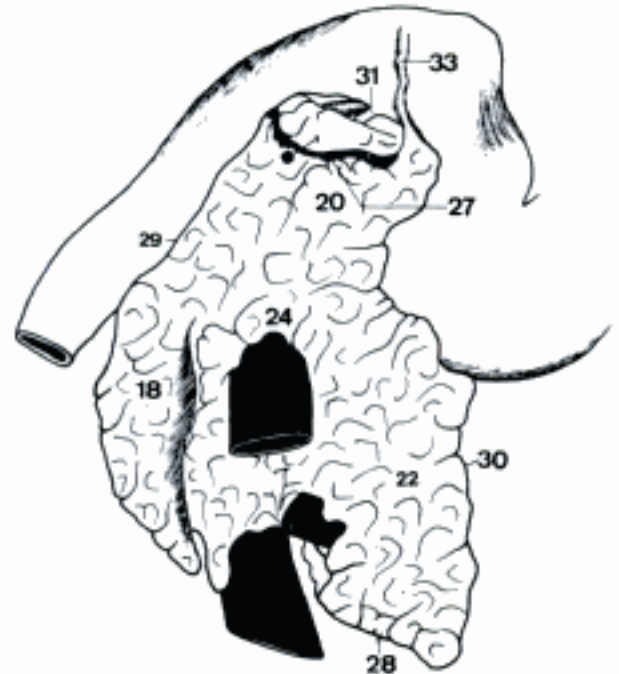
C Major duodenal papilla (ca) (Eichorn and Boyden)



D Pancreas and duodenum, ventral surface (ov)

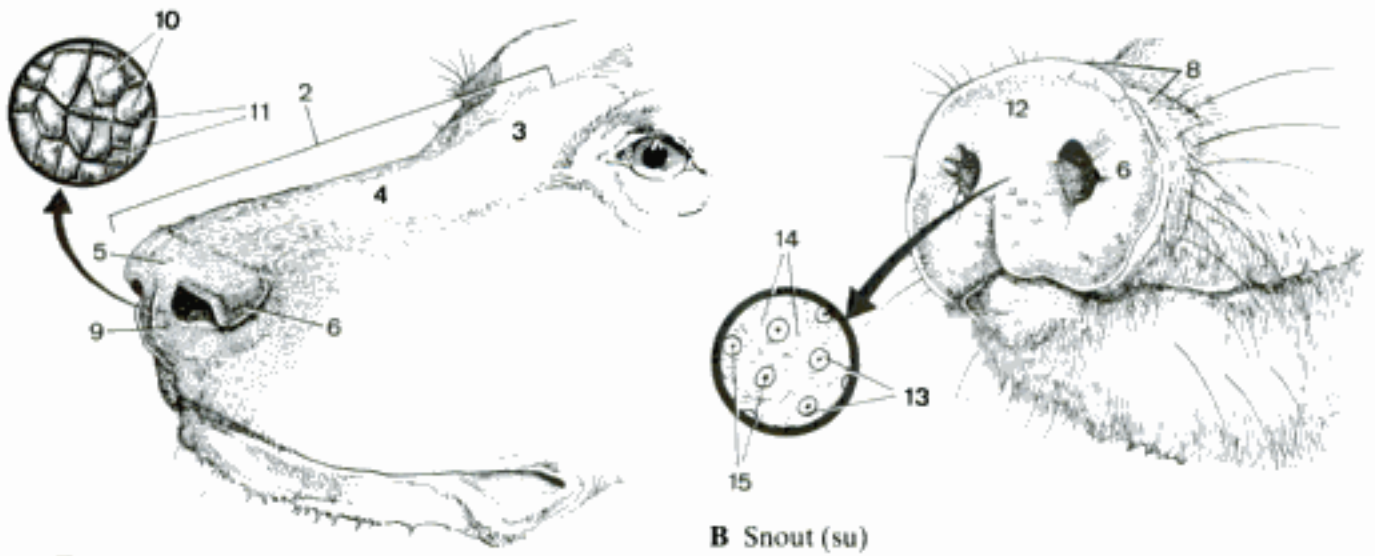


E Pancreas, ventral surface, stomach, and duodenum (ca)



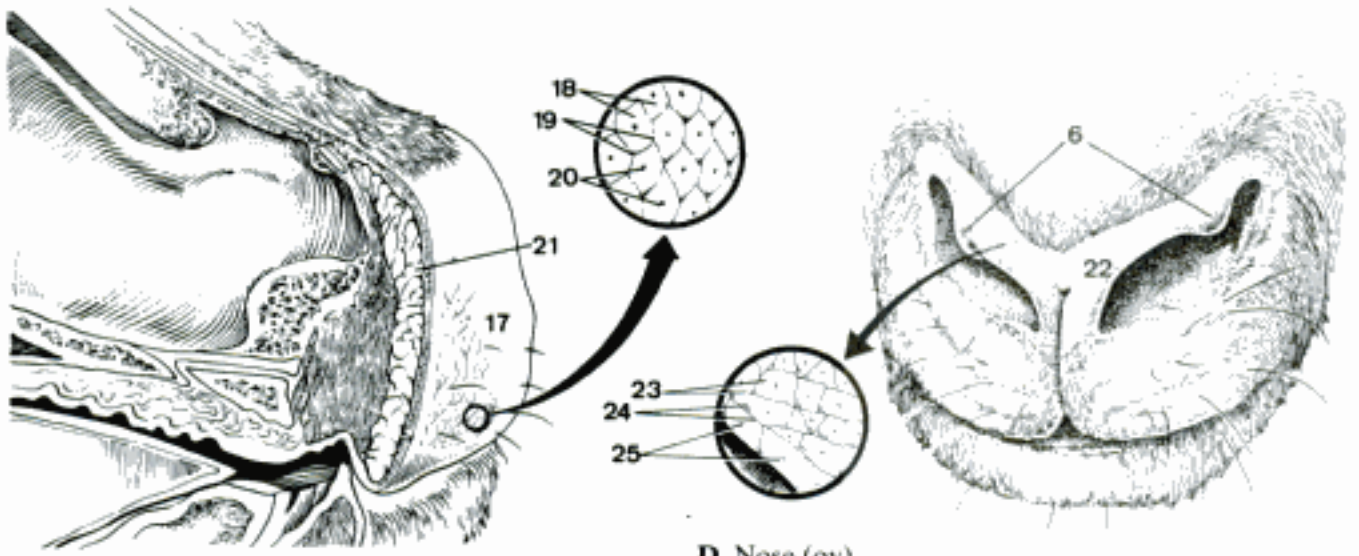
F Pancreas, ventral surface, pylorus, and duodenum (eq)

- 1 **APPARATUS RESPIRATORIUS.**
- 2 **NASUS EXTERNUS.** External nose, the part of the face rostral to the frontal region and dorsal to the infraorbital, buccal, and oral regions. A
- 3 *Radix nasi.* Root of the nose, the caudal end of the external nose. A
- 4 *Dorsum nasi.* Dorsal surface of the nose. A
- 5 *Apex nasi.* Tip of the nose. A
- 6 *Alae nasi.* Right and left wings of the nose, lateral to the nares in ca, su; dorsal in fe, Ru; medial in eq. A B D
- 7 *Pars mobilis septi nasi.* Mobile rostral part of nasal septum. F
- 8 *Rostrum.* Snout. B
- 9 *Planum nasale (Car).* Zone of hairless and nonglandular skin on the Apex nasi. A
- 10 *Areae.* Polygonal fields about 1 mm in diameter, separated by grooves. A
- 11 *Sulci.* Grooves between areae. A
- 12 *Planum rostrale (su).* Skin of the snout-disk, hairless except for sparse, short tactile hairs. B
- 13 *Areae.* Fields about 2 mm in diameter separated by grooves. B
- 14 *Sulci.* Faint grooves in the upper half of the planum. B
- 15 *Foveolae.* Pits into which the glands open. B
- 16 *Glandulae.* Large serous glands in the subcutaneous tissue.
- 17 *Planum nasolabiale (bo).* Hairless skin of the nose and upper lip. C
- 18 *Areae.* Fields about 2–4 mm in diameter, separated by grooves. C
- 19 *Sulci.* Grooves between areae. C
- 20 *Foveolae.* Pits into which glands open. C
- 21 *Glandulae.* Large serous glands in the subcutaneous tissue. C
- 22 *Planum nasale (ov, cap).* Narrow zone of bare skin between the nares and along the free border of the alae. D
- 23 *Areae.* Fields about 2 mm in diameter. D
- 24 *Sulci.* Grooves between areae. D
- 25 *Foveolae.* Pits into which glands open. D
- 26 *Glandulae.* Large serous glands in the subcutaneous tissue.
- 27 *Cartilagine nasii externi.* Cartilages of the external nose. E F
- 28 *Cartilago nasi lateralis dorsalis.* Dorsal lateral nasal cartilage, lateral expansion from the dorsal border of the septal cartilage. E F
- 29 *Cartilago nasi lateralis ventralis.* Ventral lateral nasal cartilage, lateral expansion from the ventral border of the septal cartilage; absent in eq. F
- 30 *Cartilago alaris.* Alar cartilage of eq, comma-shaped, with the broad part (Lamina) in the Ala nasi and the narrow part (Cornu) ventral to the nostril. E
- 31 *Cornu (eq).* Horn of the alar cartilage. E
- 32 *Lamina (eq).* Plate of the alar cartilage. E
- 33 *Cartilago nasalis accessoria lateralis.* Lateral accessory cartilage, attached in Car to the ventral lateral cartilage; in su to the rostral bone; in Ru to the dorsal lateral cartilage. F
- 34 *Cartilago nasalis accessoria medialis.* Medial accessory cartilage in the alar fold. E



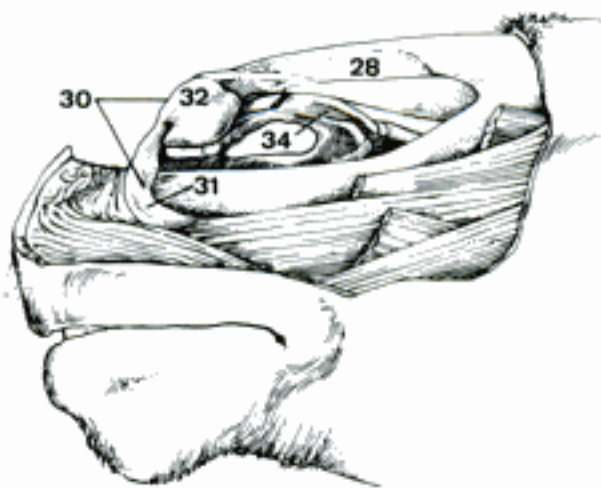
A External nose (ca)

B Snout (su)

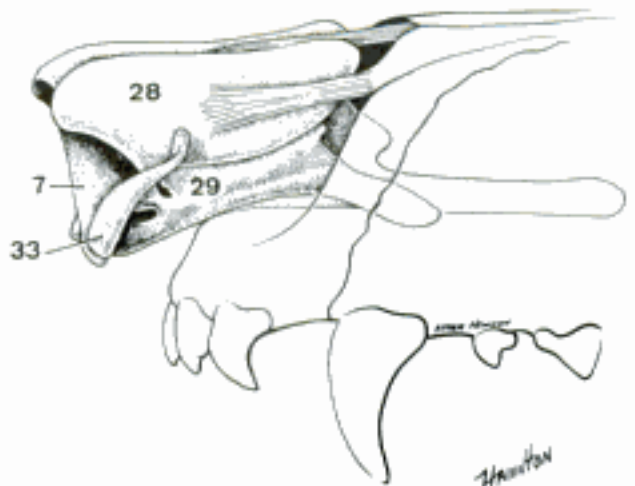


C Nose, sagittal section, rostralateral aspect (bo)

D Nose (ov)



E Nose, lateral dissection (M. lateralis nasi removed) (eq)

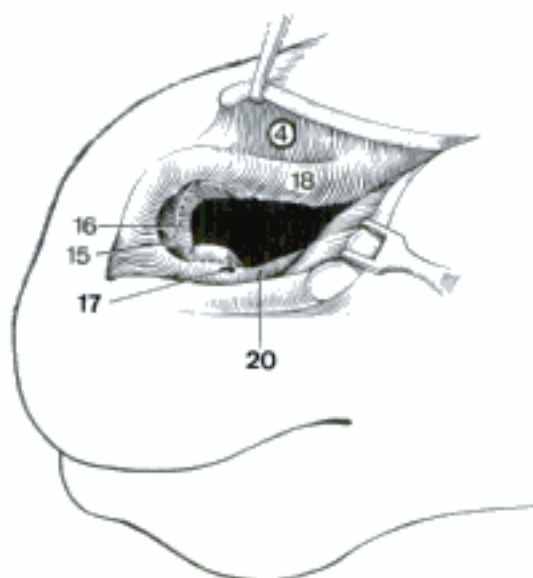


F Cartilages of nose (ca) (Miller, et al.)

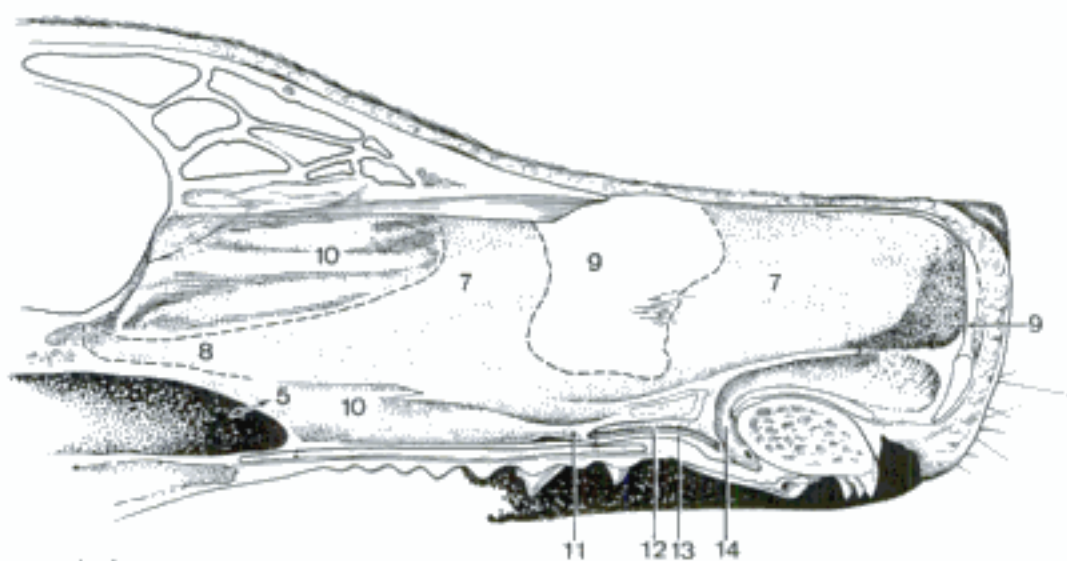
- 1 **CAVUM NASI.** Nasal cavity. D
- 2 *Nares.* Nostrils. A
- 3 *Sulcus alaris.* Alar groove, at the caudolateral angle of the nostril between the ala and the lateroventral border in Car, Ru. A
- 4 *Diverticulum nasi (eq).* Cutaneous blind sac extending from the dorsal angle of the nostril to the caudal end of the Incisura nasoincisiva. Its opening is called the false nostril. B
- 5 *Choanae.* Openings between the nasal cavities and the nasopharynx. C
- 6 *Septum nasi.* Nasal septum, separating the right and left nasal cavities. C
- 7 *Cartilago septi nasi.* Cartilage of the nasal septum. C
- 8 *Processus caudalis.* Caudal process of the cartilage, extending into the angle between Vomer and Lamina perpendicularis of the ethmoid. C
- 9 *Pars membranacea.* Membranous part, between the rostral end of the cartilage and the skin between the nares. The dog has another membranous part in the plane of the osseous nasal aperture, where a large defect in the septal cartilage provides mobility of the rostral portion. C
- 10 *Pars ossea.* Osseous part, composed of Lamina perpendicularis of the ethmoid, Vomer, and in su and bo Os rostrale. C
- 11 *Organum vomeronasale.* Vomeronasal organ, a tubular organ of special sense on the floor of the nasal cavity next to the septum. It extends caudally from the rostral end of the Fissura palatina to a transverse plane that varies with species from the third incisor (su) to the fourth premolar (ov). C
- 12 *Ductus vomeronasalis.* Epithelial tube, blind caudally and opening rostrally into the Ductus incisivus. The medial wall is composed in large part of neurosensory epithelium with axons forming the N. vomeronasalis. C
- 13 *Cartilago vomeronasalis.* Incomplete cartilaginous cylinder partially surrounding the Ductus vomeronasalis and associated glands, vessels, and nerves. It is connected to the nasal cartilages. C
- 14 *Ductus incisivus.* Incisive duct, formerly Ductus nasopalatinus. It extends rostroventrally from the nasal cavity through the Fissura palatina to the oral cavity, where it opens in the groove beside the Papilla incisiva, except in eq, in which the ventral end is blind. The Ductus incisivus receives the Ductus vomeronasalis. C
- 15 *Vestibulum nasi.* Vestibule of the nose, rostral part of the nasal cavity, lined by stratified squamous epithelium. B D
- 16 *Limen nasi.* Boundary between stratified squamous epithelium of the vestibule and respiratory epithelium of the nasal cavity proper. B D
- 17 *Ostium nasolacrimale.* Orifice of the nasolacrimal duct. B D
- 18 *Plica alaris.* Alar fold, a fold of Tunica mucosa supported by the medial accessory cartilage and extending from the rostral end of the ventral concha to the Ala nasi. B D
- 19 *Plica recta.* Straight fold of Tunica mucosa from the dorsal concha to the nostril. It originates as dorsal and ventral branches from the end of the concha in eq. D
- 20 *Plica basalis.* Basal fold of Tunica mucosa. In eq it runs rostroventrally from the ventral concha to the floor of the nasal cavity and contains the nasolacrimal duct. In the other species it begins ventral to the ventral concha and runs rostrally to join the rostral end of the alar fold. B D
- 21 *Plica obliqua (Car).* The oblique fold extends rostroventrally from the straight fold to the lateral side of the alar fold. It contains, near the straight fold, the orifice of the duct of the lateral nasal gland. D
- 22 *Plicae parallelae (Car).* Parallel folds on the dorsolateral wall of the vestibule. They extend rostrorodorsally from the oblique fold. D



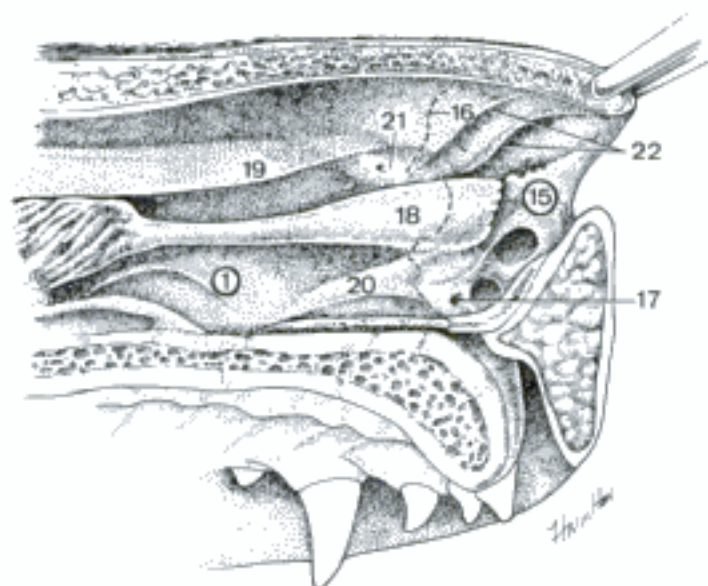
A Nostrils (bo)



B Nasal vestibule and diverticulum (eq)

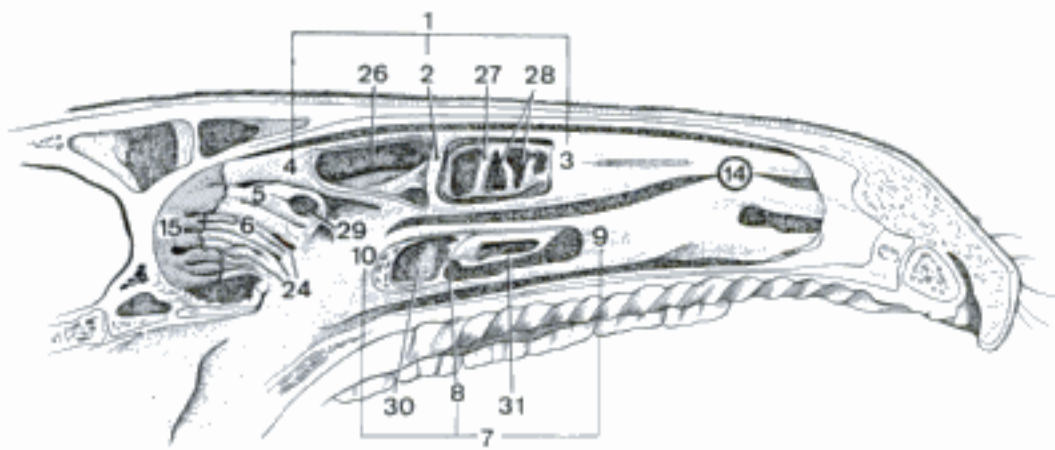


C Nasal septum (ca)

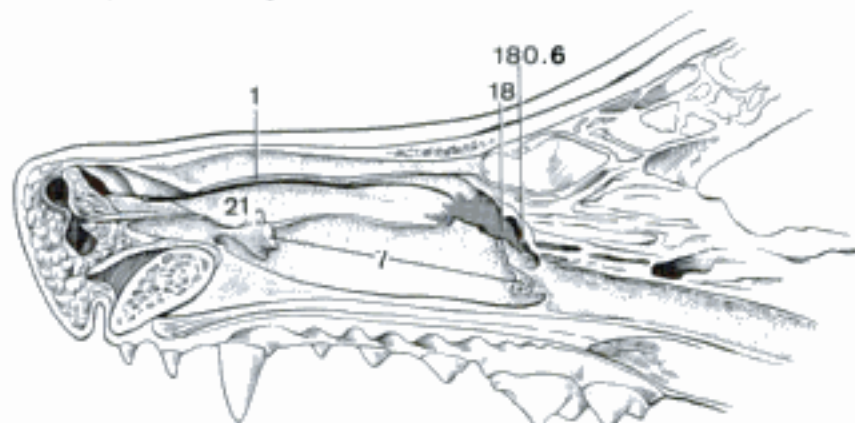


D Rostral part of left nasal cavity (ca)

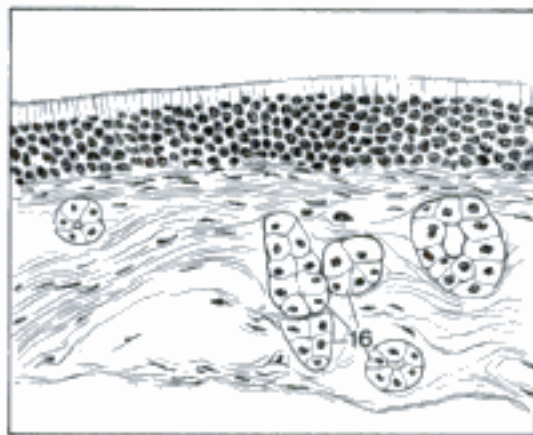
- 1 *Concha nasalis dorsalis*. Dorsal nasal concha, attached to ethmoid and nasal bone, not homologous to *Concha nasalis superior* of man. A B
- 2 *Septum conchae dorsalis (eq)*. Septum of the dorsal concha, transverse partition between rostral and caudal part. A
- 3 *Pars rostralis*. Rostral part of the concha. A
- 4 *Pars caudalis*. Caudal part of the concha. A
- 5 *Concha nasalis media*. Middle nasal concha, wedged between the caudal ends of the dorsal and ventral conchae and the ethmoidal conchae. A
- 6 *Conchae ethmoidales*. The ethmoidal conchae form the labyrinth in the caudal end of the nasal cavity. A
- 7 *Concha nasalis ventralis*. Ventral nasal concha, attached to the maxilla. A B E
- 8 *Septum conchae ventralis (eq)*. Septum of the ventral concha, partition between the rostral and caudal parts. A
- 9 *Pars rostralis*. Rostral part of the concha. A
- 10 *Pars caudalis*. Caudal part of the concha. A
- 11 *Pars dorsalis (su, Ru)*. Dorsal part of the ventral concha, rolled dorsally. E
- 12 *Pars ventralis (su, Ru)*. Ventral part of the ventral concha, rolled ventrally. E
- 13 *Tunica mucosa nasi*. Mucous membrane lining the nasal cavity. E
- 14 *Regio respiratoria*. Respiratory region, covered by pseudostratified columnar ciliated epithelium with goblet cells. A D
- 15 *Regio olfactoria*. Olfactory region, on the caudal parts of the ethmoidal conchae and adjacent nasal septum. It is covered by olfactory epithelium. A C
- 16 *Gll. olfactoriae*. Olfactory glands, tubular, branched seromucous glands in the Lamina propria of the *Regio olfactoria*. C
- 17 *Gll. nasales*. Nasal glands, tubuloalveolar, mixed, in the *Regio respiratoria*, few and small in *Car*. D
- 18 *Gl. nasalis lateralis*. Lateral nasal gland, serous, in the maxillary sinus (recess, *Car*) or the nasomaxillary aperture. Absent in *bo*. B
- 19 *Plexus cavernosi nasales*. Cavernous plexuses of the nose, dense venous networks in the submucosa. E
- 20 *Meatus nasi dorsalis*. Dorsal nasal meatus, passage between dorsal concha and dorsal wall of the nasal cavity. E
- 21 *Meatus nasi medius*. Middle nasal meatus, between dorsal and ventral conchae. B E
- 22 *Meatus nasi ventralis*. Ventral nasal meatus, between ventral concha and floor of the nasal cavity. E
- 23 *Meatus nasi communis*. Common nasal meatus, sagittal passage along the septum. E
- 24 *Meatus ethmoidales*. Ethmoidal meatuses, passages between the ethmoidal conchae. A
- 25 **SINUS PARANASALES**. Paranasal sinuses.
- 26 *Sinus conchae dorsalis*. Dorsal conchal sinus, cavity enclosed by the caudal part of concha. A
- 27 *Bulla conchalis dorsalis*. Dorsal conchal bulla, enclosure formed by the rolled-up free border of the rostral part of the dorsal concha. A
- 28 *Cellulae*. Cells, compartments formed by transverse septa. A
- 29 *Sinus conchae mediae*. Middle conchal sinus. A
- 30 *Sinus conchae ventralis*. Ventral conchal sinus, cavity enclosed by the caudal part of the ventral concha. A
- 31 *Bulla conchalis ventralis*. Ventral conchal bulla, enclosure formed by the rolled-up free border of the ventral concha. A E
- 32 *Cellulae*. Cells, compartments formed by transverse septa. E



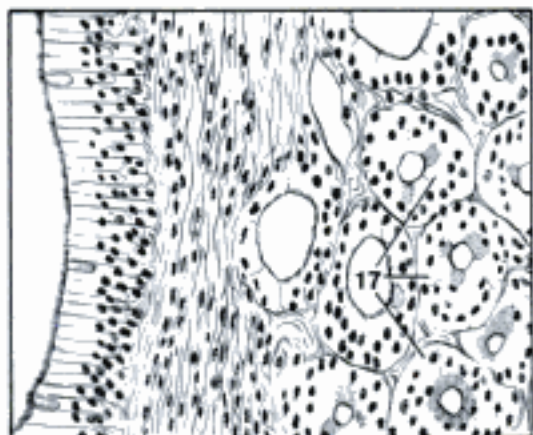
A Nasal cavity (septum removed), medial aspect (eq)



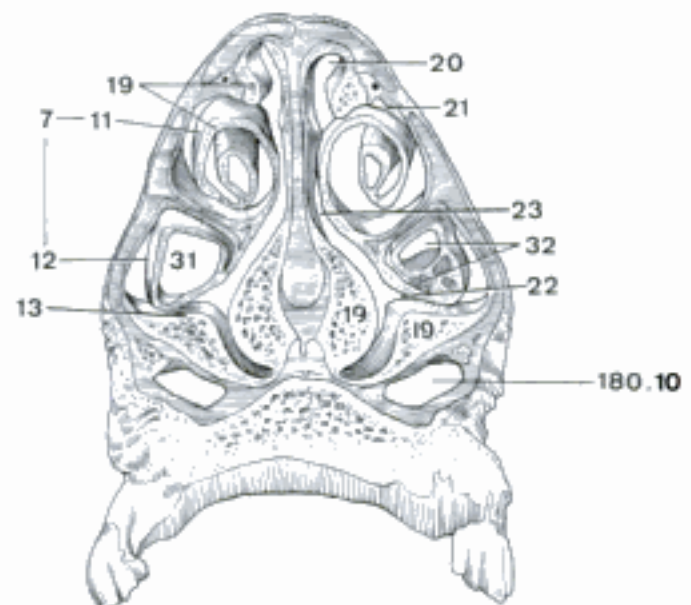
B Nasal cavity, medial aspect of right sagittal section (conchae largely removed) (ca)



C Tunica mucosa of olfactory region, histological section (ca)

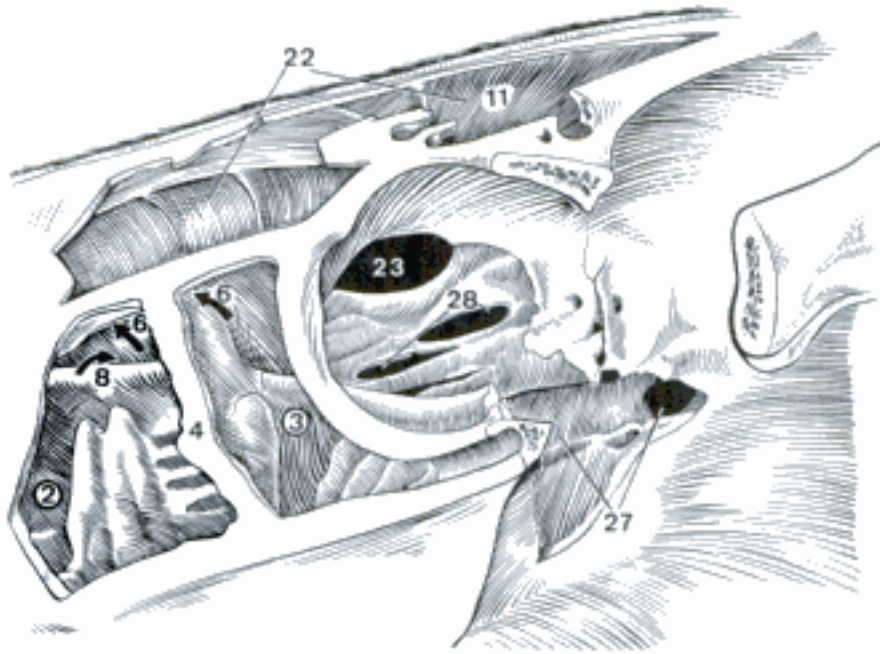


D Tunica mucosa of respiratory region, histological section (bo)

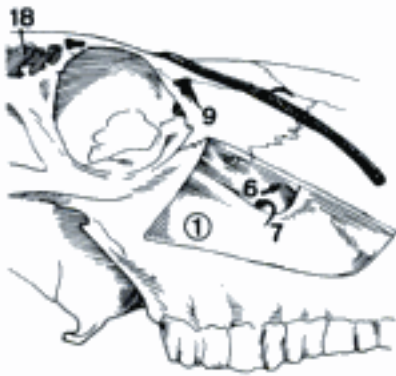


E Nasal cavity, transverse section rostral to 2nd pre-molar (bo)

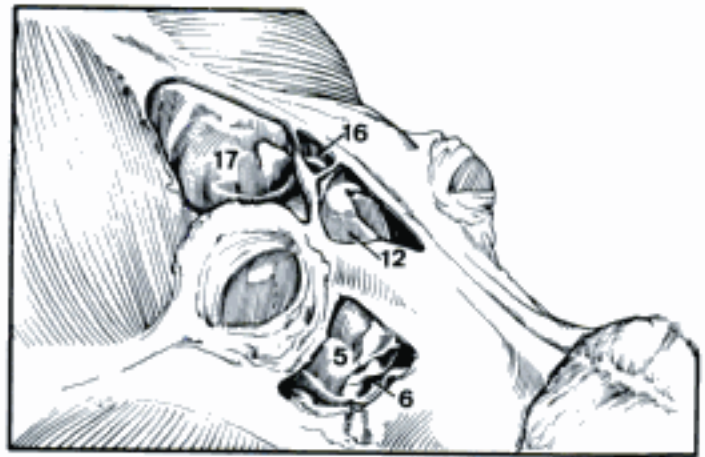
- 1 *Sinus maxillaris*. Maxillary sinus, between external and internal plates of facial bones. B
- 2 *Sinus maxillaris rostralis*. Rostral maxillary sinus in eq, separated by the maxillary septum from the caudal maxillary sinus. It opens freely into the ventral conchal sinus. A
- 3 *Sinus maxillaris caudalis*. Caudal maxillary sinus in eq, separated by the maxillary septum from the rostral maxillary sinus, communicates with the frontal and sphenopalatine sinuses. A
- 4 *Septum sinuum maxillarium*. Maxillary septum, between the rostral and caudal maxillary sinuses in eq. A
- 5 *Recessus maxillaris (Car)*. Maxillary recess, between the ethmoid medially and the maxillary, palatine, and lacrimal bones laterally. C E
- 6 *Apertura nasomaxillaris*. Nasomaxillary opening, from the maxillary sinus or recess to the middle nasal meatus. A B C, 179 B
- 7 *Apertura maxillopalatina (Ru)*. Maxillopalatine opening, wide passage over the infraorbital canal from the maxillary to the palatine sinus. B
- 8 *Apertura conchomaxillaris (eq)*. Conchomaxillary opening, passage from the ventral conchal sinus to the rostral maxillary sinus. A
- 9 *Sinus lacrimalis (su, Ru)*. Lacrimal sinus, in the lacrimal bone. B D
- 10 *Sinus palatinus*. Palatine sinus. In Ru in the hard palate, in eq in the Lamina perpendicularis of the palatine bone. 179 E
- 11 *Sinus frontalis*. Frontal sinus in fe and eq. Other species have more than one frontal sinus on each side. A E
- 12 *Sinus frontalis rostralis*. Rostral frontal sinus in ca. C
- 13 *Sinus frontalis rostralis medialis*. Medial rostral frontal sinus in su and bo. D
- 14 *Sinus frontalis rostralis intermedius*. Middle rostral frontal sinus in bo. D
- 15 *Sinus frontalis rostralis lateralis*. Lateral rostral frontal sinus in su and bo. D
- 16 *Sinus frontalis medialis*. Medial frontal sinus in ca, ov, cap. C
- 17 *Sinus frontalis lateralis*. Lateral frontal sinus in ca, ov, cap. C
- 18 *Sinus frontalis caudalis*. Caudal frontal sinus in su and bo. B D
- 19 *Aperturae sinuum frontaliuum*. Openings of the frontal sinuses. D
- 20 *Septa sinuum frontaliuum*. Septa of the frontal sinuses, complete partitions between frontal sinuses. D
- 21 *Lamellae intrasinuales*. Intrasinual lamellae, plates of bone that project into a sinus. D
- 22 *Sinus conchfrontalis*. Conchofrontal sinus is a compound term for the frontal sinus and the dorsal conchal sinus, which are continuous in eq. A
- 23 *Apertura frontomaxillaris (eq)*. Frontomaxillary opening, between frontal and maxillary sinuses.
- 24 *Sinus sphenoidalis*. Sphenoidal sinus, cavity in the sphenoid bones. Absent in ca, ov, cap. E
- 25 *Septum sinuum sphenoidalium*. Septum between right and left sphenoidal sinuses. E
- 26 *Apertura sinus sphenoidalis*. Opening of the sphenoidal sinus. E
- 27 *Sinus sphenopalatinus (eq)*. Sphenopalatine sinus. The sphenoid and palatine sinuses are continuous and open into the caudal maxillary sinus. A
- 28 *Cellulae ethmoidales*. Ethmoidal cells, enclosed by the ethmoidal conchae. A E



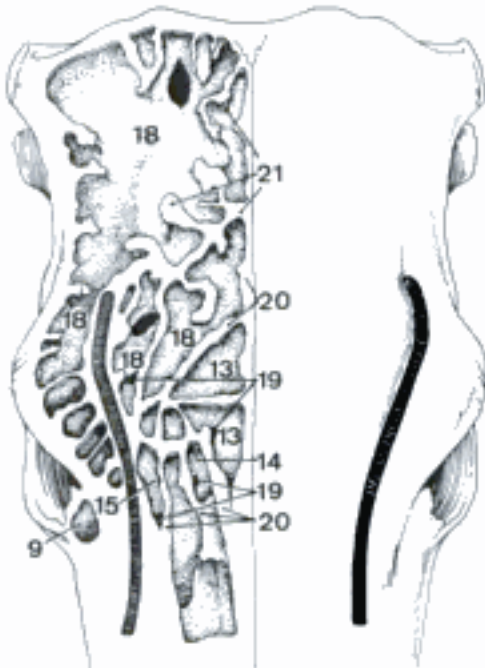
A Paranasal sinuses (medial wall of orbit removed), lateral aspect (eq)



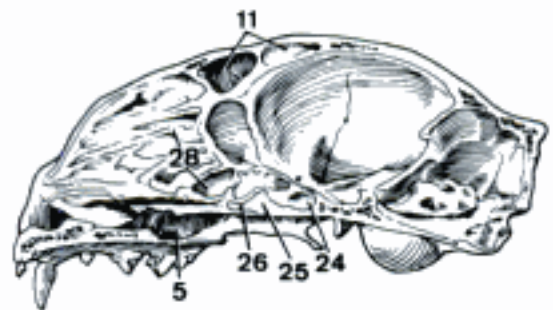
B Maxillary sinus (bo)



C Frontal sinuses and maxillary recess (infraorbital canal removed) (ca)

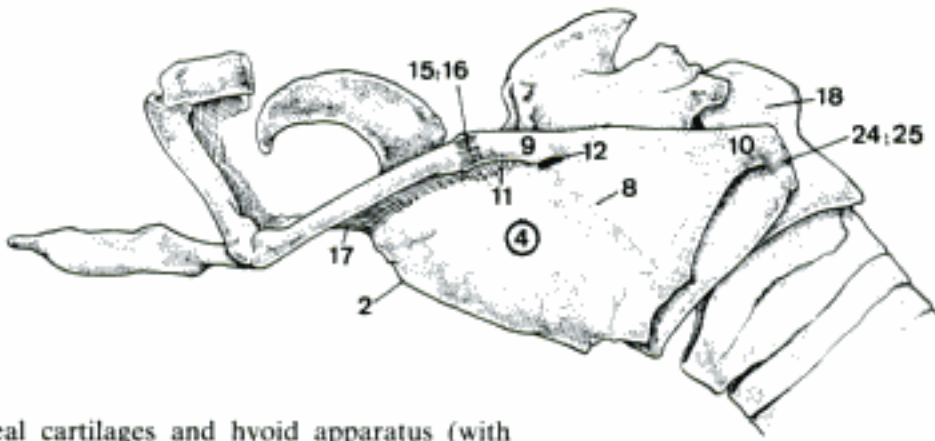


D Right frontal sinuses (bo)

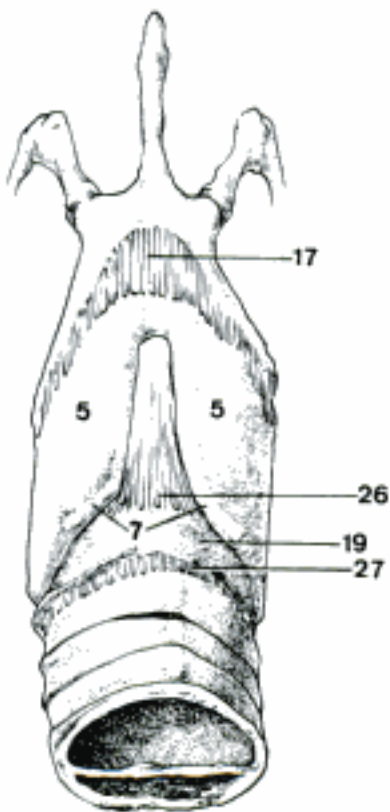


E Skull, medial aspect of right sagittal section (fe)

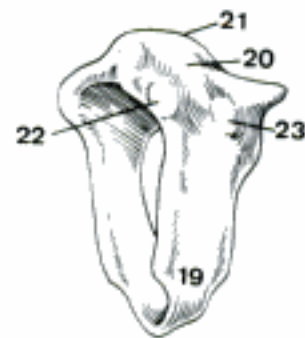
- 1 **LARYNX**. Organ of voice and closure between pharynx and trachea.
- 2 *Prominentia laryngea*. Ventral prominence of thyroid cartilage. A D
- 3 **Cartilagine laryngis**.
- 4 **Cartilago thyroidea [thyreoidea]**. Thyroid cartilage. A D
- 5 *Lamina [dextra et sinistra]*. Right and left lamina, plates joined ventrally to form the thyroid cartilage. B D
- 6 *Incisura thyroidea [thyreoidea] rostralis*. Rostral thyroid notch in Ru. D
- 7 *Incisura thyroidea [thyreoidea] caudalis*. Caudal thyroid notch. B D
- 8 *Linea obliqua*. Oblique line on the lateral surface of the lamina for attachment of muscles. A
- 9 *Cornu rostrale*. Rostral horn, absent in su; articulates with the hyoid bone. A D
- 10 *Cornu caudale*. Caudal horn, articulates with the cricoid cartilage. A D
- 11 *Fissura thyroidea [thyreoidea]*. Thyroid fissure, between the rostral horn and the lamina. A
- 12 *Foramen thyroideum [thyreoideum]*. Thyroid foramen, in the caudal end of the thyroid fissure. A
- 13 *Facies articularis cricoidea*. Articular surface for cricoid cartilage on caudal horn. This is a syndesmosis in Ru. D
- 14 *Facies articularis hyoidea*. Articular surface for hyoid bone on rostral horn. D
- 15 *Articulatio thyrohyoidea [thyreo-]*. Thyrohyoid joint. A
- 16 *Capsula articularis thyrohyoidea [thyreo-]*. Thyrohyoid joint capsule, absent in Car and su which have a syndesmosis here. A
- 17 *Membrana thyrohyoidea [thyreo-]*. Thyrohyoid membrane, from the rostral border of the thyroid lamina to the basi-hyoid and thyrohyoid bones. A B
- 18 **Cartilago cricoidea**. Cricoid cartilage, the ring-shaped cartilage attached to the trachea. A C
- 19 *Arcus cartilaginis cricoideae*. Arch of the cricoid cartilage, the narrow ventral part. B C
- 20 *Lamina cartilaginis cricoideae*. Lamina of the cricoid cartilage, broad dorsal part. C
- 21 *Crista mediana*. Median crest on the lamina. C
- 22 *Facies articularis arytenoidea [arytaenoidea]*. Articular surface for the arytenoid cartilage. C
- 23 *Facies articularis thyroidea [thyreoidea]*. Articular surface for the thyroid cartilage. C
- 24 *Articulatio cricothyroidea [-thyreoidea]*. Cricothyroid joint. A
- 25 *Capsula articularis cricothyroidea [-thyreoidea]*. Capsule of the cricothyroid joint. Absent in Ru, which have a syndesmosis here. A
- 26 *Lig. cricothyroideum [-thyreoideum]*. Cricothyroid ligament, from the cricoid cartilage to the thyroid laminae. B
- 27 *Lig. cricotracheale*. Cricotracheal ligament, the membrane between the cricoid cartilage and the first tracheal ring. B



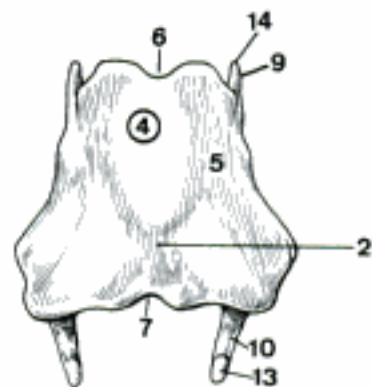
A Laryngeal cartilages and hyoid apparatus (with stylohyoid cut off), lateral aspect (eq)



B Laryngeal cartilages and hyoid apparatus (with stylohyoid cut off), ventral aspect (eq)

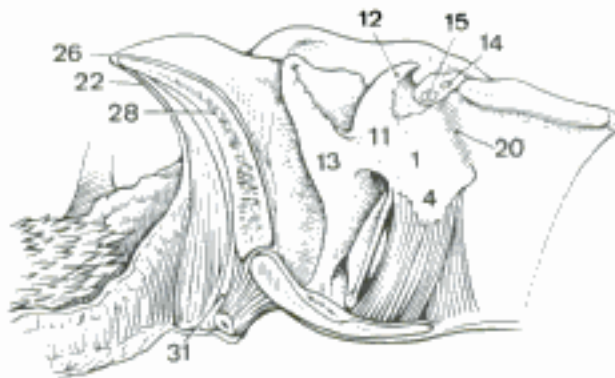


C Cricoid cartilage, rostralateral aspect (eq)

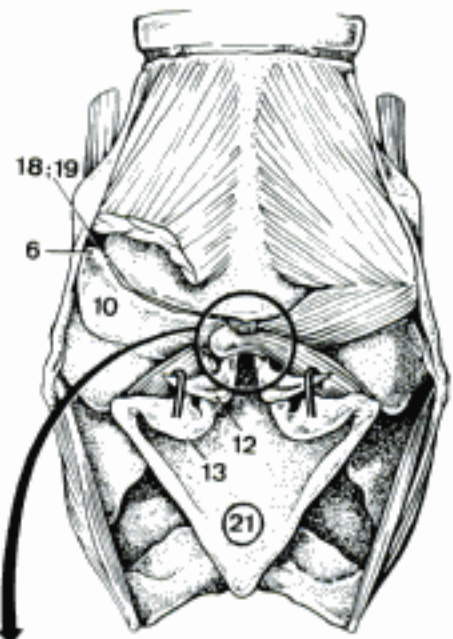


D Thyroid cartilage, ventral aspect (bo)

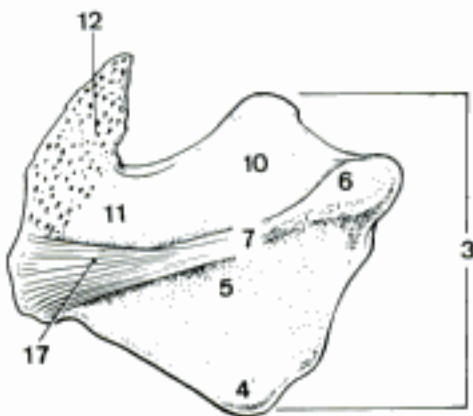
- 1 **Cartilago arytenoidea [arytaenoidea]**. Arytenoid cartilage. Flattened pyramidal lever that opens and closes the glottis. A C D
- 2 **Facies articularis**. Articular surface for the cricoid cartilage. D
- 3 **Basis cartilaginis arytenoideae [arytaenoideae]**. Base of the arytenoid cartilage, facing caudally toward the cricoid. C D
- 4 **Processus vocalis**. Vocal process, ventral projection for attachment of the vocal ligament. A C D
- 5 **Facies lateralis**. Lateral surface, separated from the dorsal surface by the Crista arcuata. C
- 6 **Processus muscularis**. Muscular process, at the caudal end of the Crista arcuata. B C
- 7 **Crista arcuata**. Arcuate crest, separates lateral and dorsal surfaces. C
- 8 **Facies medialis**. Medial surface, forms the dorsal part of the glottis. D
- 9 **Processus medialis**. Medial process, attachment of the Lig. arytenoideum transversum. B
- 10 **Facies dorsalis**. Dorsal surface. B C
- 11 **Apex cartilaginis arytenoideae [arytaenoideae]**. Apex of the arytenoid cartilage, craniodorsal angle to which the corniculate process is attached. A C
- 12 **Processus corniculatus**. Corniculate process, absent in fe. A B C
- 13 **Processus cuneiformis (ca)**. Cuneiform process, attached to the apex of the arytenoid, supports the Plica aryepiglottica and the Plica vestibuli. A B
- 14 **Cartilago interarytenoidea [-arytaenoidea]**. Interarytenoid cartilage, dorsal to the Lig. arytenoideum transversum and just rostral to the cricoid in ca and su. A B
- 15 **Cartilago sesamoidea**. Sesamoid cartilage, lies across the dorsal surface of the arytenoid cartilages caudal to the corniculate processes in Car. In ca it may be paired. A B
- 16 **Lig. arytenoideum [arytaenoideum] transversum**. Transverse arytenoid ligament, between the medial processes of the arytenoid cartilages. B
- 17 **Lig. arycorniculatum**. Arycorniculate ligament, from the Crista arcuata to the ventral half of the free border of the corniculate process. C
- 18 **Articulatio cricoarytenoidea [-arytaenoidea]**. Cricoarytenoid joint. B
- 19 **Capsula articularis cricoarytenoidea [-arytaenoidea]**. Cricoarytenoid joint capsule. B D
- 20 **Lig. cricoarytenoideum [-arytaenoideum]**. Cricoarytenoid ligament, from the cricoid lamina to the base of the arytenoid cartilage. A
- 21 **Epiglottis**. Most rostral part of the larynx. B E
- 22 **Facies lingualis**. Lingual surface. A
- 23 **Facies laryngea**. Laryngeal surface. E
- 24 **Margines laterales**. Lateral borders. E
- 25 **Basis**. Base, attached to the thyroid cartilage. E
- 26 **Apex**. Free rostral tip. A
- 27 **Petiolus epiglotticus**. Stem of the epiglottis, a median projection from the base. E
- 28 **Cartilago epiglottica**. Epiglottic cartilage. A
- 29 **Processus cuneiformis (eq)**. Cuneiform process, projects in the vestibular fold. E
- 30 **Lig. thyroepiglotticum [thyreo-]**. Thyroepiglottic ligament, attaches the base of the epiglottis to the thyroid cartilage. E
- 31 **Lig. hyoepiglotticum**. Hyoepiglottic ligament, from the basihyoid, keratohyoid, and, in su, also from the thyrohyoid, to the epiglottis. A



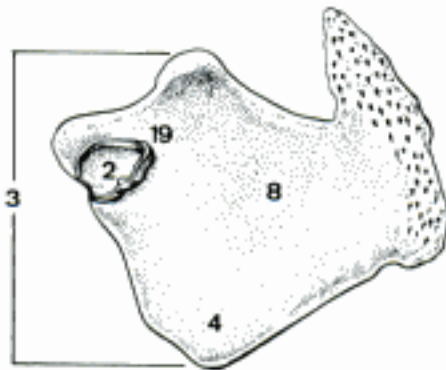
A Larynx, median section (mucosa partly removed) (ca)



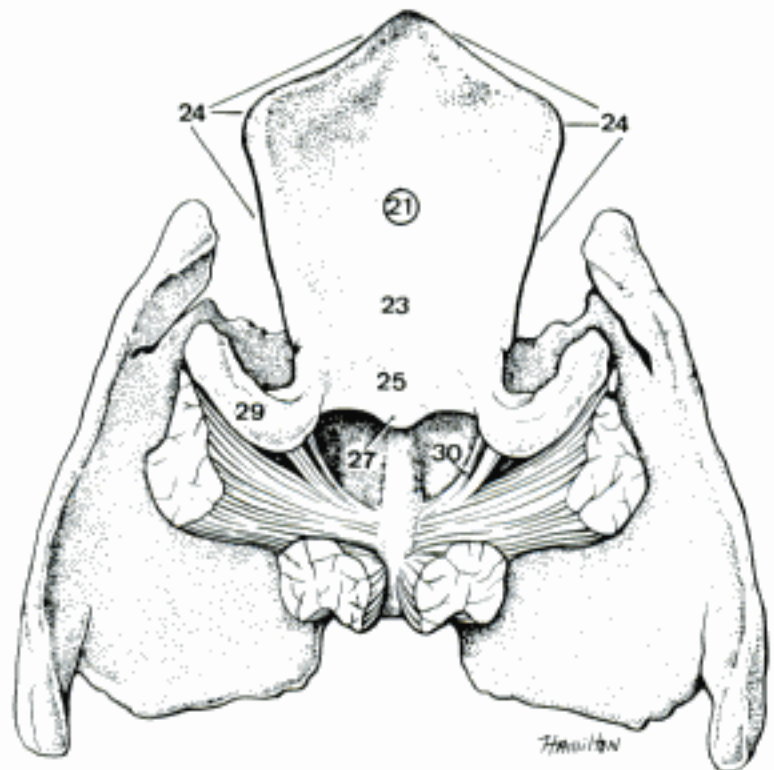
B Larynx (right *M. arytenoideus transversus* and terminations of *M. cricoarytenoideus dorsalis* and *M. ventricularis* removed), dorsal aspect (ca)



C Left arytenoid cartilage, lateral surface (eq)

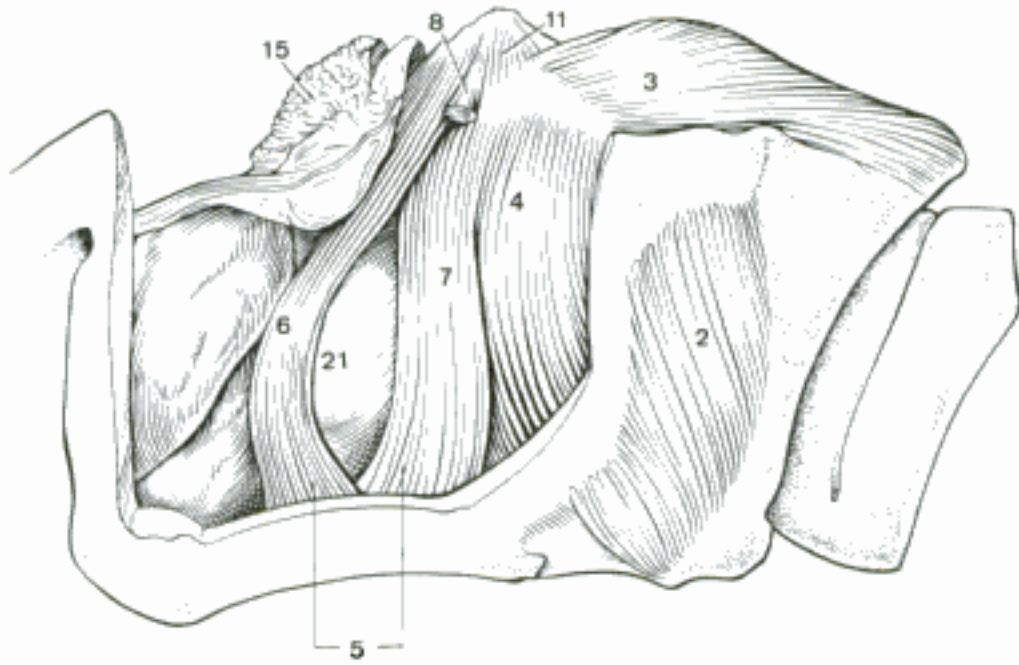


D Left arytenoid cartilage, medial surface (eq)

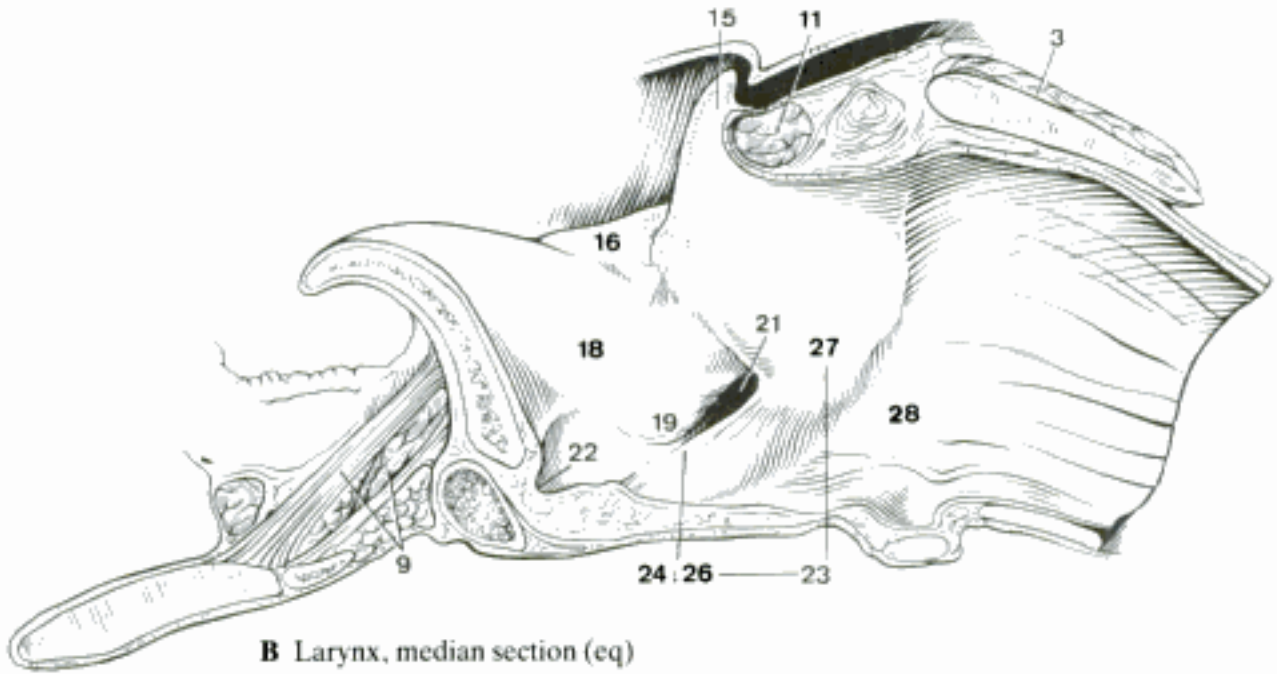


E Epiglottis and thyroid cartilage (the stumps of *Mm. ventricularis* and *vocalis* remain), caudodorsal aspect (eq)

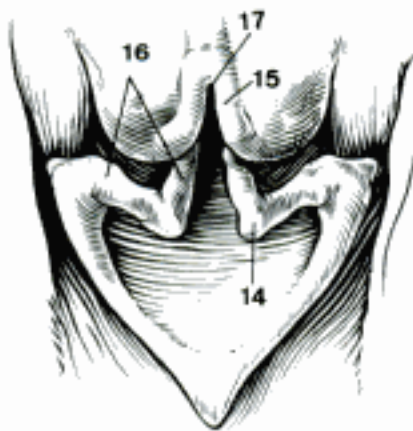
- 1 **Musculi laryngis.**
- 2 *M. cricothyroideus* [-thyroideus]. O: cricoid arch. T: thyroid lamina. Tenses the vocal folds. A D
- 3 *M. cricoarytenoideus* [-arytaenoideus] *dorsalis*. O: cricoid lamina. T: Processus muscularis. Opens the glottis. A B
- 4 *M. cricoarytenoideus* [-arytaenoideus] *lateralis*. O: cricoid arch. T: Processus muscularis. Closes the glottis. A D
- 5 *M. thyroarytenoideus* [thyroarytaenoideus]. O: thyroid cartilage, epiglottis, Lig. cricothyroideum. T: Crista arcuata, muscular and vocal processes. A
- 6 *M. ventricularis*. Rostral part of *M. thyroarytenoideus* in ca and eq. A D
- 7 *M. vocalis*. In ca and eq, from thyroid cartilage and Lig. cricothyroideum to Crista arcuata and Processus vocalis. A D
- 8 *M. thyroarytenoideus* [thyroarytaenoideus] *accessorius* (eq). O: thyroid cartilage. T: *M. arytenoideus transversus*. A
- 9 *M. hyoepiglotticus*. O: varies with species, basihyoid, keratohyoid, or both. T: epiglottic cartilage. B
- 10 *M. tensor ventriculi laryngis* (eq) O: Processus cuneiformis. T: ventral part of laryngeal ventricle.
- 11 *M. arytenoideus* [arytaenoideus] *transversus*. O: Crista arcuata of arytenoid cartilage. T: Contralateral muscle. A B
- 12 **Cavum laryngis.** Cavity of the larynx.
- 13 *Aditus laryngis*. Entrance to the larynx, bounded by the epiglottis, Plicae aryepiglotticae, and Tubercula corniculata (in fe arytenoid cartilages). C
- 14 *Tuberculum cuneiforme* (ca). In the Plica aryepiglottica, formed by the Processus cuneiformis. C
- 15 *Tuberculum corniculatum*. Mucosal eminence formed by the Processus corniculatus, absent in fe. A B C
- 16 *Plica aryepiglottica*. From epiglottis to arytenoid cartilage in ca, eq, cricoid fe, mucosa caudal to Tuberculum corniculatum su, Ru. B C
- 17 *Incisura interarytenoidea* [-arytaenoidea]. Interarytenoid notch, between the Processus corniculati. C
- 18 *Vestibulum laryngis*. Vestibule of the larynx, between the aditus and the vocal folds. B D
- 19 *Plica vestibularis*. Vestibular fold. In ca, eq supported by Lig. vestibulare and cuneiform cartilage, in fe fold of mucosa; absent in su, Ru. B D
- 20 *Rima vestibuli*. Vestibular cleft, between right and left vestibular folds. D
- 21 *Ventriculus laryngis*. Laryngeal ventricle, between vestibular and vocal folds in ca, eq, two parts of the vocal fold in su. A B D
- 22 *Recessus laryngis medianus*. Median laryngeal recess, caudal to the epiglottis. B
- 23 *Glottis*. Vocal apparatus of the larynx, consists of vocal folds, arytenoid cartilages and Rima glottidis. B
- 24 *Plica vocalis*. Vocal fold, covers Lig. vocale and *M. vocalis* or the caudal part of *M. thyroarytenoideus*. B D
- 25 *Rima glottidis*. Cleft of the glottis, between vocal folds and arytenoid cartilages. D
- 26 *Pars intermembranacea*. Intermembranous part, between the vocal folds. B
- 27 *Pars intercartilaginea*. Intercartilaginous part, between the mucosa-covered arytenoid cartilages. B
- 28 *Cavum infraglotticum*. Infraglottic cavity, caudal to the glottis. B D
- 29 *Tunica mucosa*. Mucous membrane. Stratified squamous epithelium to the vocal folds, pseudostratified ciliated epithelium in the rest, including the Ventriculi laryngis in eq. D
- 30 *Membrana fibroelastica laryngis*. From the epiglottis to Lig. vestibulare and from Lig. vocale to the cricoid. D
- 31 *Lig. vestibulare*. Ca: thyroid cartilage to Processus cuneiformis; su: epiglottis to Processus corniculatus; eq; Processus cuneiformis to arytenoid cartilage. Absent in fe, Ru. D
- 32 *Lig. vocale*. From thyroid cartilage and Lig. cricothyroideum to Processus vocalis. D
- 33 *Gll. laryngeae*. Laryngeal glands. D
- 34 *Lymphonoduli* [Noduli lymphatici] *laryngei*. Lymph nodules of the larynx. D



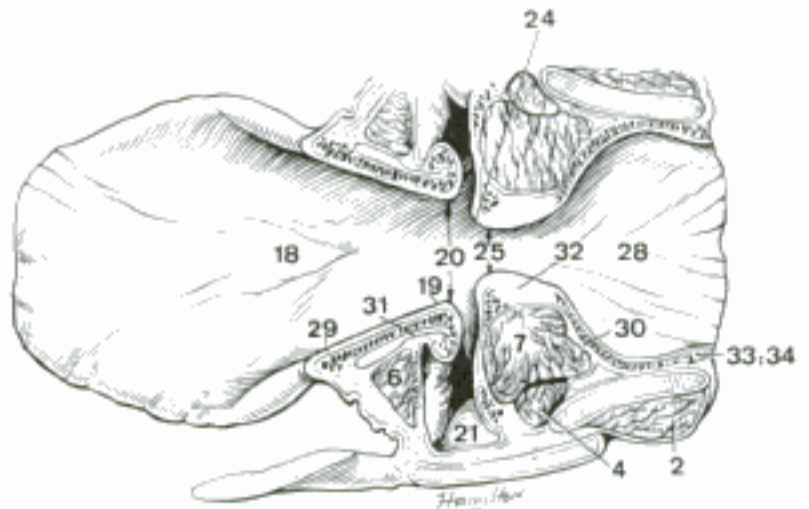
A Laryngeal muscles (most of the thyroid cartilage removed), left lateral aspect (eq)



B Larynx, median section (eq)

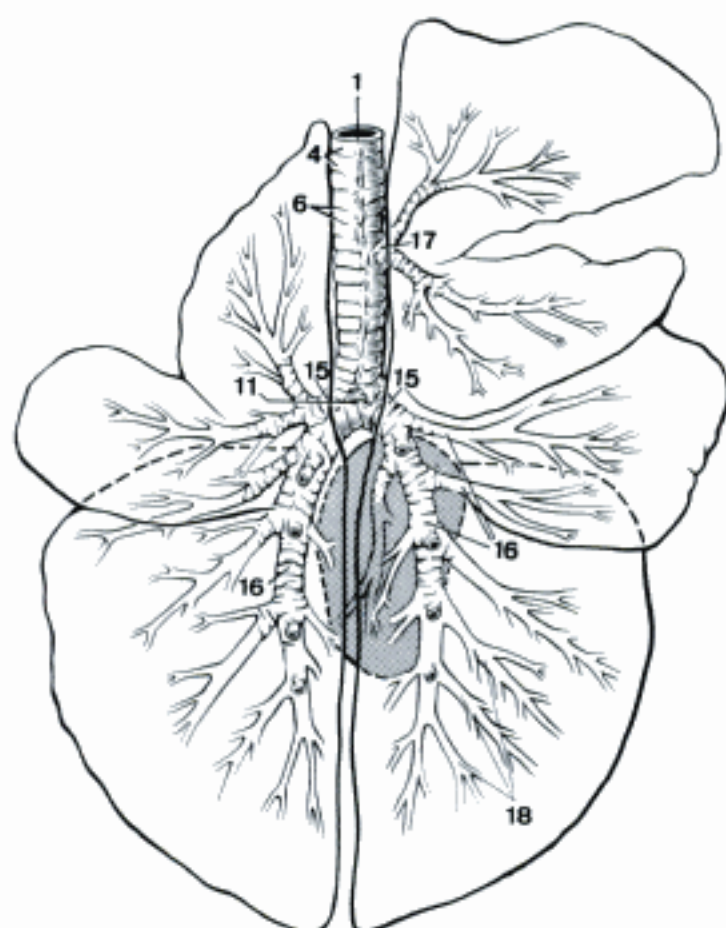


C Aditus laryngis (ca)

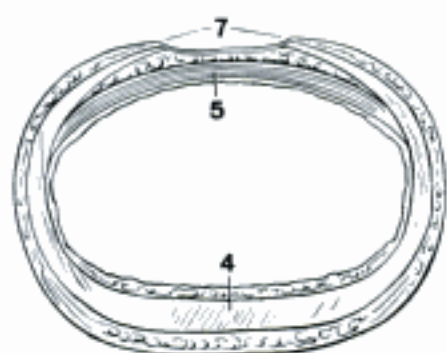


D Larynx, section perpendicular to vocal folds (eq)

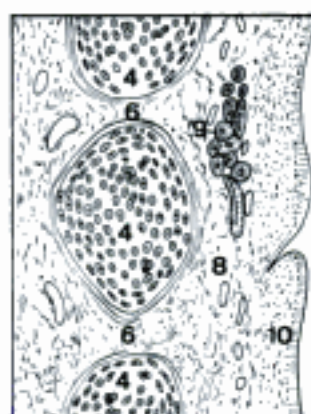
- 1 **TRACHEA.** Windpipe. A B
- 2 *Pars cervicalis.* Cervical part.
- 3 *Pars thoracica.* Thoracic part.
- 4 *Cartilagine tracheales.* Tracheal cartilages, annular bands interrupted dorsally. A B C
- 5 *Musculus trachealis.* Tracheal muscle, transverse bands of smooth muscle connecting the dorsal ends of the tracheal cartilages. The muscle is attached inside the cartilage except Car, where it is outside. B
- 6 *Ligg. anularia [trachealia].* Annular ligaments, the connective tissue between the tracheal cartilages. A C
- 7 *Paries membranaceus.* Membranous wall, when the dorsal ends of the tracheal cartilages do not meet. B
- 8 *Tela submucosa.* Loose vascular connective tissue under the mucous membrane. C
- 9 *Gll. tracheales.* Tracheal glands, mixed glands in the submucosa. C
- 10 *Tunica mucosa.* Mucous membrane, covered with pseudostratified ciliated epithelium. C
- 11 *Bifurcatio trachea.* Tracheal bifurcation, where the right and left main bronchi arise. A D
- 12 *Carina tracheae.* Crest in the lumen on the caudal side of the bifurcation. D
- 13 **BRONCHI.** Branches of the trachea and their subdivisions.
- 14 *Arbor bronchalis.* Bronchial tree. A
- 15 *Bronchus principalis [dexter et sinister].* Right and left main bronchus. A D
- 16 *Bronchi lobares.* Lobar bronchi; each serves one whole lobe. A
- 17 *Bronchus trachealis (su, Ru).* Bronchus of the right cranial lobe, separate origin from the trachea. A
- 18 *Bronchi segmentales.* Segmental bronchi; each serves one whole Segmentum bronchopulmonale. A
- 19 *Cartilagine bronchales.* Bronchial cartilages. D E
- 20 *Tela submucosa.* Loose vascular connective tissue outside the mucosa. E
- 21 *Gll. bronchales.* Bronchial glands, mixed glands in the submucosa. E
- 22 *Tunica mucosa.* Mucous membrane, covered by pseudostratified ciliated epithelium. E
- 23 *Lamina muscularis mucosae.* The bronchial musculature lies between the mucosa and submucosa. E
- 24 *Lymphonoduli [Noduli lymphatici] bronchales.* Bronchial lymph nodules.
- 25 **PULMO [DEXTER ET SINISTER].** Lung, right and left. F G
- 26 *Basis pulmonis.* Base of the lung, caudal part. Its surface is in contact with the diaphragm. F
- 27 *Apex pulmonis.* Apex of the lung, the cranial extremity. F
- 28 *Facies costalis.* Costal surface, in contact with the costal pleura. F
- 29 *Facies medialis.* Medial surface. G
- 30 *Pars vertebralis.* Vertebral part, the dorsal zone along the vertebrae. G
- 31 *Pars mediastinalis.* Mediastinal part, in contact with the Mediastinum. G
- 32 *Impressio cardiaca.* Cardiac impression. G
- 33 *Impressio aortica.* Aortic impression. G
- 34 *Impressio esophagea [oesophagea].* Esophageal impression. G



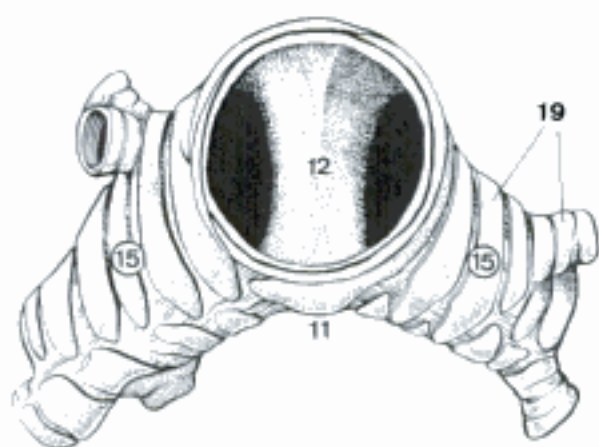
A Bronchial tree, dorsal aspect (bo) (Getty)



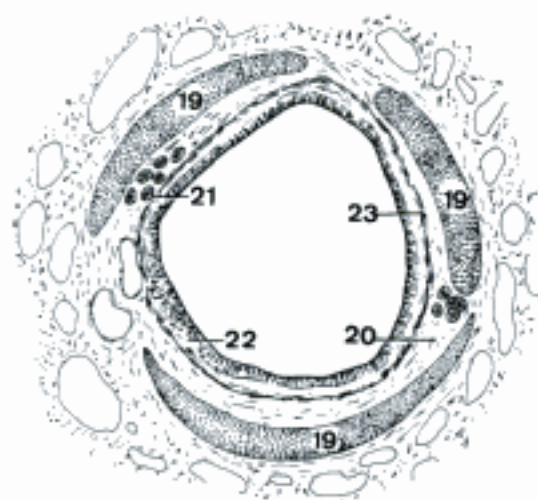
B Trachea, transverse section (eq)



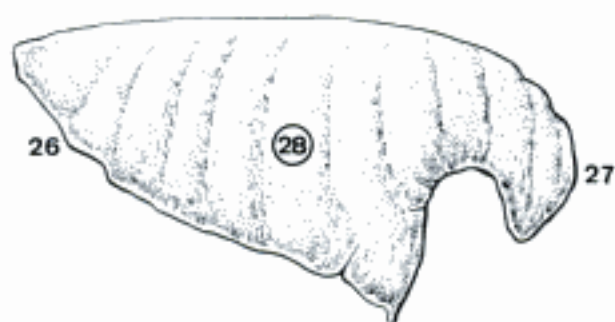C Trachea, longitudinal section (su) (Trautmann and Fiebiger)



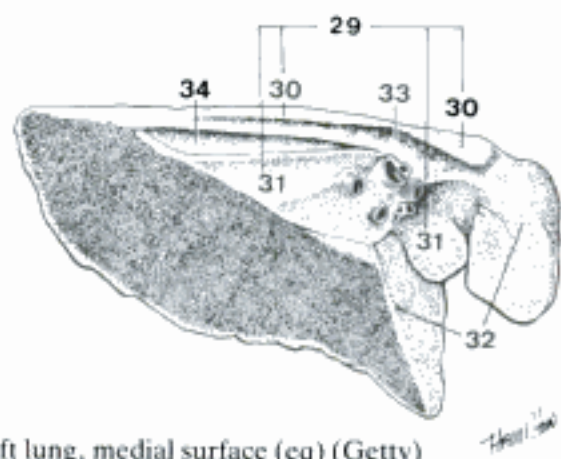
D Bifurcation of trachea, cranial aspect of section (eq)



E Bronchus, transverse section (eq) (Trautmann and Fiebiger)

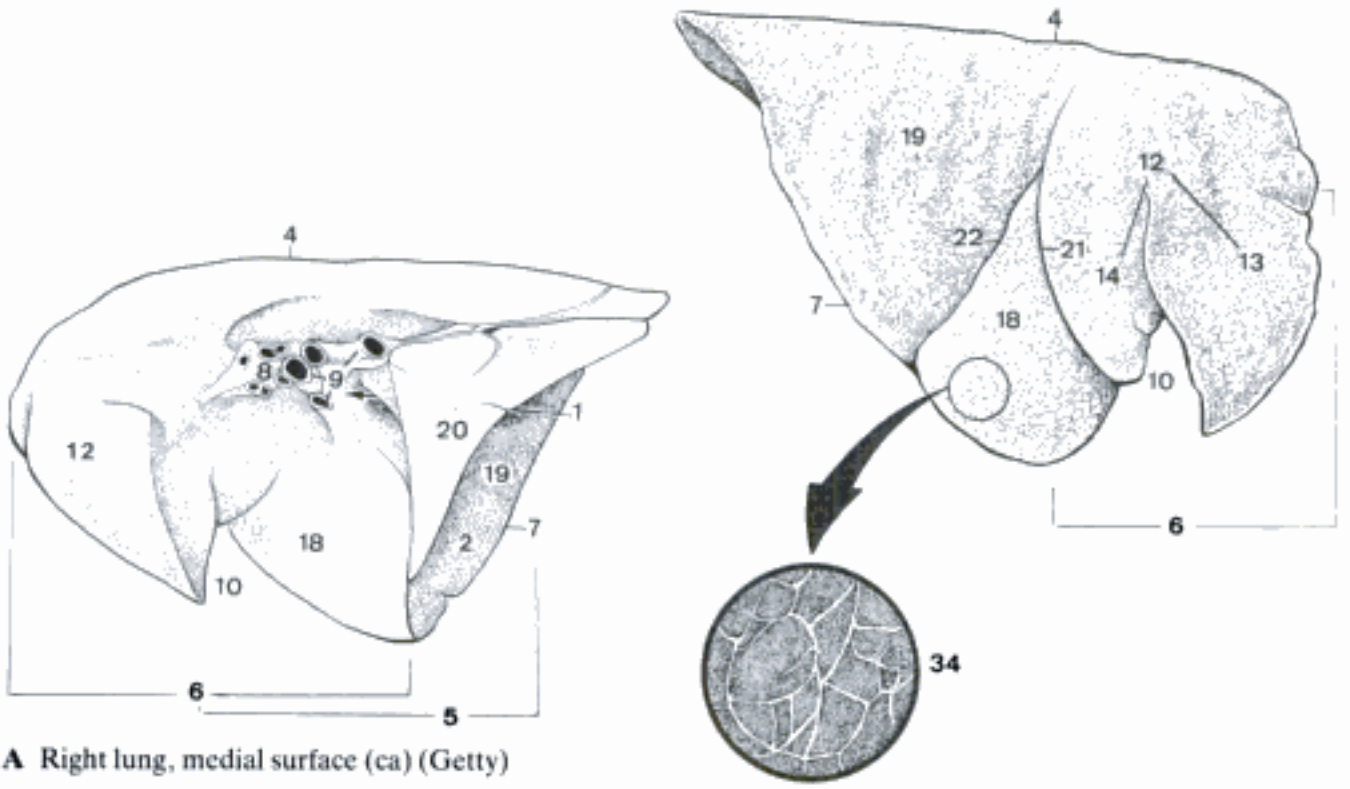


F Right lung, costal surface (eq) (Getty)



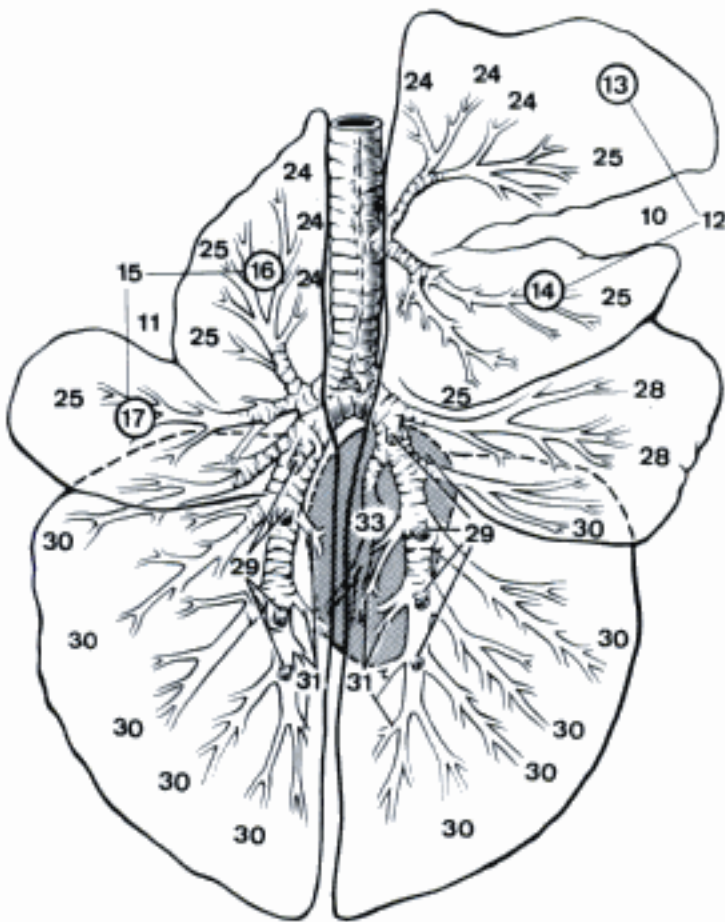
G Left lung, medial surface (eq) (Getty)

- 1 *Sulcus venae cavae caudalis*. Groove for the caudal vena cava in the right lung between accessory lobe and middle and caudal lobes. A
- 2 *Facies diaphragmatica*. Diaphragmatic surface. A
- 3 *Facies interlobares*. Interlobar surfaces in the fissures between lobes.
- 4 *Margo dorsalis [obtusus]*. Dorsal or thick border. A B
- 5 *Margo acutus*. Thin border. A
- 6 *Margo ventralis*. Ventral border, cranial to the tip of the middle lobe of the right lung or along the ventral border of the cranial lobe of the left lung. A B
- 7 *Margo basalis*. Basal border, where costal and diaphragmatic surfaces meet. A B
- 8 *Hilus pulmonis*. Hilus of the lung, area where bronchus and vessels enter. A
- 9 *Radix pulmonis*. Root of the lung, composed of the structures that enter the lung at the Hilus. A
- 10 *Incisura cardiaca pulmonis dextri*. Cardiac notch of the right lung. A B C
- 11 *Incisura cardiaca pulmonis sinistri*. Cardiac notch of the left lung. C
- 12 *Lobus cranialis [pulm. dext.]*. Cranial lobe of the right lung. The scheme of lobation is determined by origin and division of the lobar bronchi. A B C
- 13 *Pars cranialis*. Cranial part in Ru. B C
- 14 *Pars caudalis*. Caudal part in Ru. B C
- 15 *Lobus cranialis [pulm. sin.]*. Cranial lobe of the left lung, divided into cranial and caudal parts (except eq). C
- 16 *Pars cranialis [Culmen]*. Cranial part. C
- 17 *Pars caudalis [Lingula]*. Caudal part. C
- 18 *Lobus medius [pulm. dext.]*. Middle lobe of the right lung (except eq). A B
- 19 *Lobus caudalis*. Caudal lobe. A B
- 20 *Lobus accessorius [pulm. dext.]*. Accessory lobe of the right lung. A
- 21 *Fissura interlobaris cranialis [pulm. dext.]*. Cranial interlobar fissure of the right lung, between cranial and middle lobes. B
- 22 *Fissura interlobaris caudalis*. Caudal interlobar fissure, between middle and caudal lobes of the right lung, cranial and caudal lobes of the left lung. B
- 23 **Segmenta bronchopulmonalia**. Bronchopulmonary segments, segmentation based on the bronchi. C
- 24 *Segmenta dorsalia lobi cranialis*. Dorsal segments of the cranial lobe. C
- 25 *Segmenta ventralia lobi cranialis*. Ventral segments of the cranial lobe. C
- 26 *Segmenta medialis lobi cranialis*. Medial segments of the cranial lobe.
- 27 *Segmenta lateralia lobi cranialis*. Lateral segments of the cranial lobe.
- 28 *Segmenta lobi medii*. Segments of the middle lobe. C
- 29 *Segmenta dorsalia lobi caudalis*. Dorsal segments of the caudal lobe. C
- 30 *Segmenta ventralia lobi caudalis*. Ventral segments of the caudal lobe. C
- 31 *Segmenta medialis lobi caudalis*. Medial segments of the caudal lobe. C
- 32 *Segmenta lateralia lobi caudalis*. Lateral segments of the caudal lobe.
- 33 *Segmentum accessorium*. Accessory segment. C
- 34 *Lobuli pulmonis*. Pulmonary lobules. A primary lobule is about 1 mm in diameter, a secondary a polyhedron with sides about 1 cm across. It contains about 50 primary lobules. B
- 35 *Bronchuli*. Bronchioles, less than 1 mm in diameter, without cartilage. D
- 36 *Bronchuli respiratorii*. Respiratory bronchioles, less than 0,5 mm in diameter, bear alveoli and branch. D
- 37 *Ductuli alveolares*. Alveolar ducts, walls riddled with the openings of alveoli. D
- 38 *Sacculi alveolares*. Alveolar sacs, bearing alveoli. D
- 39 *Alveoli pulmonis*. Pulmonary alveoli, the smallest respiratory chambers. D

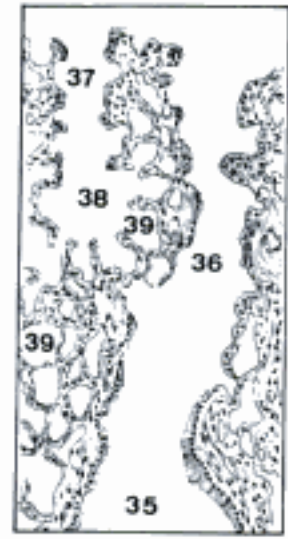


A Right lung, medial surface (ca) (Getty)

B Right lung, costal surface (bo) (Getty)

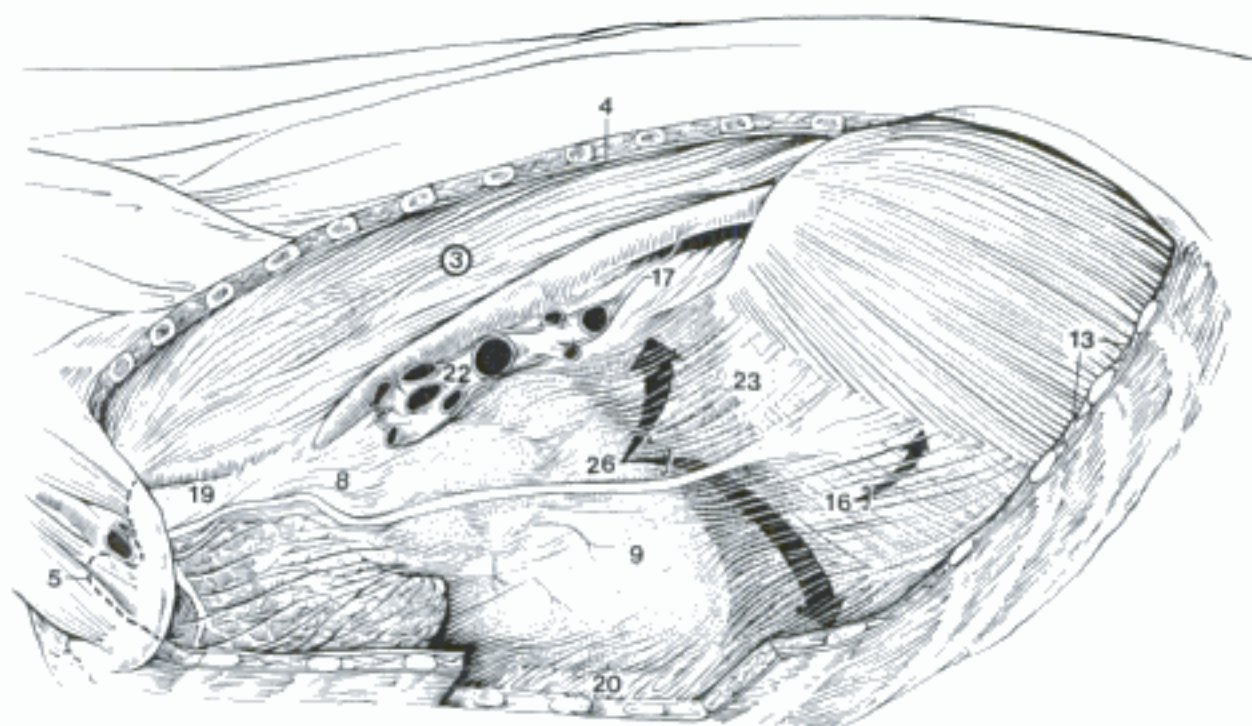


C Segmenta bronchopulmonalia, dorsal aspect (bo) (Getty)

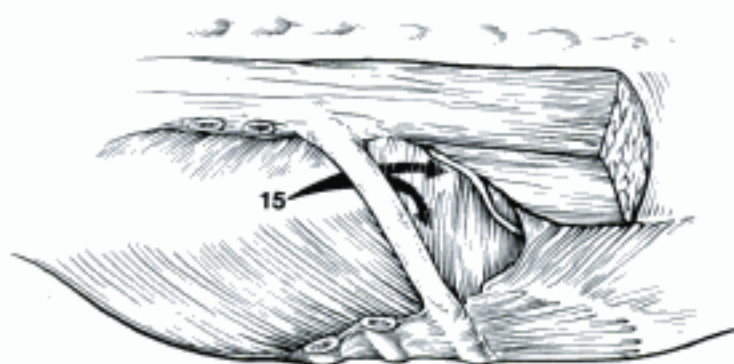


D Lung, histological section (ca)

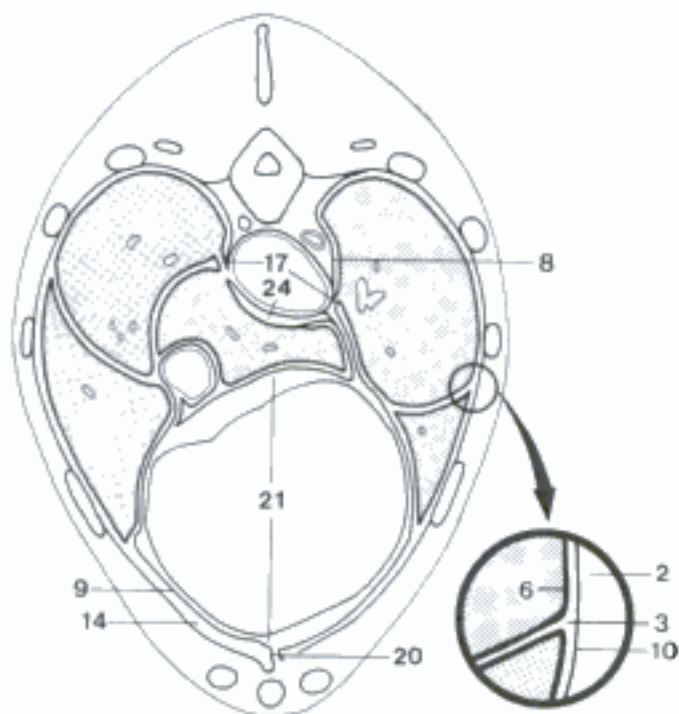
- 1 **CAVUM THORACIS.** Thoracic cavity. Its walls are formed by ribs, thoracic vertebrae, sternum, and associated muscles, including diaphragm. It is a truncated cone, flattened laterally in quadrupeds, with the apex between the first ribs, and a concave oblique base at the diaphragm.
- 2 *Fascia endothoracica.* Endothoracic fascia, connective tissue lining the thoracic walls outside of the Pleura parietalis. C
- 3 *Cavum pleurae.* Pleural cavity, right and left, potential space between Pleura parietalis and pulmonalis and between the lobes of the lung. A C
- 4 *Pleura.* Serous membrane that lines the thoracic cavity on either side of the mediastinum, and covers the lung. The Pleura parietalis is continuous with the Pleura pulmonalis at the root of the lung and the Lig. pulmonale. A
- 5 *Cupula pleurae.* Blind end of the pleural cavity at the thoracic inlet. A
- 6 *Pleura pulmonalis.* Pulmonary pleura, serous covering of the lung. C
- 7 *Pleura parietalis.* Parietal pleura, lining the walls of each pleural cavity.
- 8 *Pleura mediastinalis.* Mediastinal pleura. Part of the Pleura parietalis that covers the mediastinum. A C
- 9 *Pleura pericardiaca.* Pericardial pleura, Part of the Pleura mediastinalis that covers the Pericardium fibrosum. A C
- 10 *Pleura costalis.* Costal pleura, part of the Pleura parietalis that lines the ribs and intercostal muscles. C
- 11 *Pleura diaphragmatica.* Diaphragmatic pleura, part of the Pleura parietalis covering the diaphragm. D
- 12 *Recessus pleurales.* Pleural recesses, clefts between reflected layers of Pleura parietalis allowing for movement of the walls and expansion of the lungs.
- 13 *Recessus costodiaphragmaticus.* Costodiaphragmatic recess, between Pleura costalis and diaphragmatica, caudoventral to the basal border of the lung. A D
- 14 *Recessus costomediastinalis.* Costomediastinal recess, between Pleura costalis and mediastinalis. C
- 15 *Recessus lumbodiaphragmaticus.* In Car, su, ov, cap the Pleura extends caudal to the vertebral end of the last rib to the first lumbar vertebra. B
- 16 *Recessus mediastinodiaphragmaticus sinister.* Left mediastinodiaphragmatic recess. Extension of the Recessus mediastini by leftward deviation of the attachment of mediastinum to the diaphragm. A D
- 17 *Lig. pulmonale.* Pulmonary lig., formed by the continuity of Pleura mediastinalis and pulmonalis caudal to the root of the lung. A C
- 18 *Mediastinum.* Deviant connective tissue septum and Pleurae mediastinales between the right and left pleural cavities. It contains most of the structures in the thoracic cavity except the lungs.
- 19 *Mediastinum craniale.* Cranial to the pericardium, contains great vessels, trachea, esophagus. A
- 20 *Mediastinum ventrale.* Between pericardium and sternum. A C
- 21 *Mediastinum medium.* Middle mediastinum, containing heart and pericardium. C
- 22 *Mediastinum dorsale.* Between pericardium and vertebrae. A
- 23 *Mediastinum caudale.* Caudal to the pericardium, the dorsal part contains aorta, esophagus; the ventral part is thin and attached to the left side of the diaphragm. A D
- 24 *Cavum mediastini serosum [Bursa infracardiaca].* Serous cavity of the mediastinum on the right side of the esophagus in the Mediastinum caudale, extension of the Bursa omentalis. C D
- 25 *Plica venae cavae.* Fold for the vena cava, from the pericardium to the diaphragm, continuous ventrally with the Mediastinum caudale. D
- 26 *Recessus mediastini.* Mediastinal recess, evagination of the right pleural cavity between the Mediastinum caudale and the Plica venae cavae, contains the accessory lobe of the right lung. A D



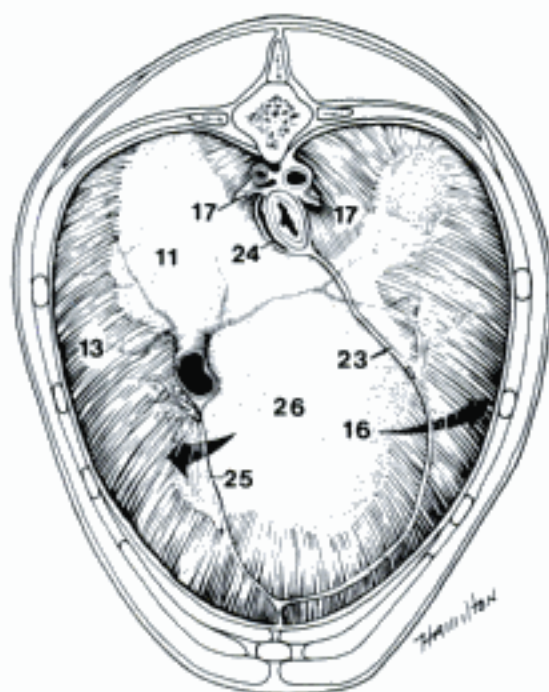
A Left pleural cavity (lung and ribs 2–12 removed)
(ca)



B Left thoracolumbar region, dorsolateral aspect
(ca)

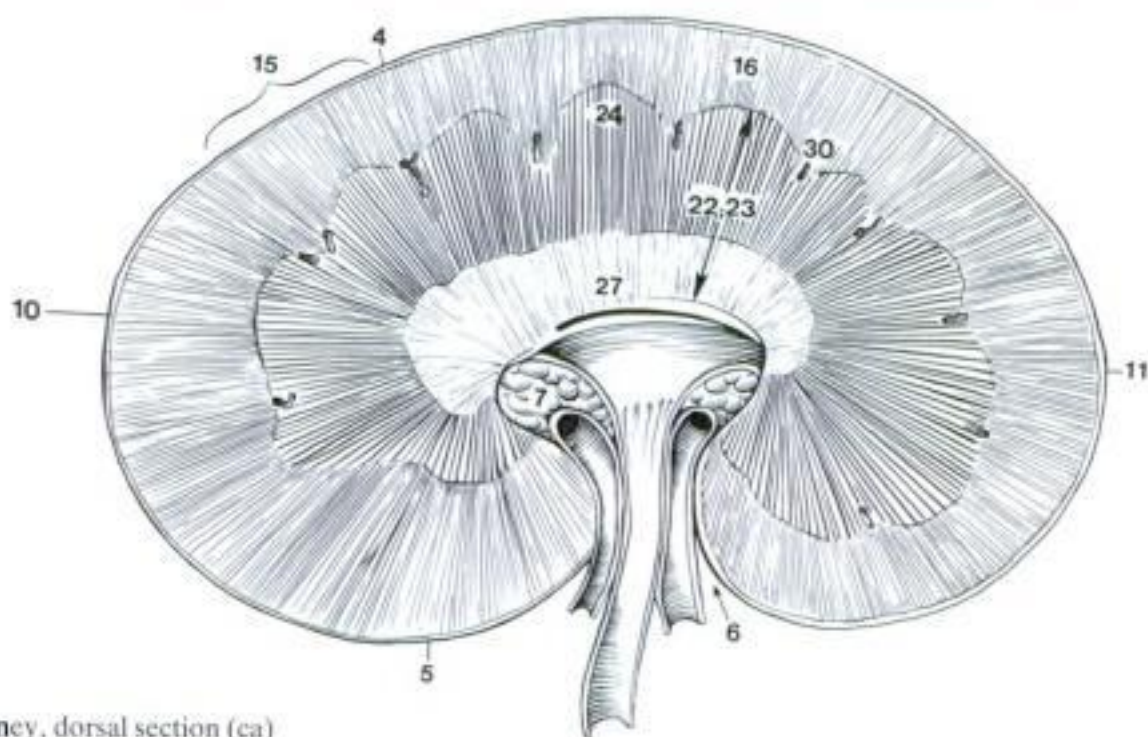


C Thorax, transverse section (ca)

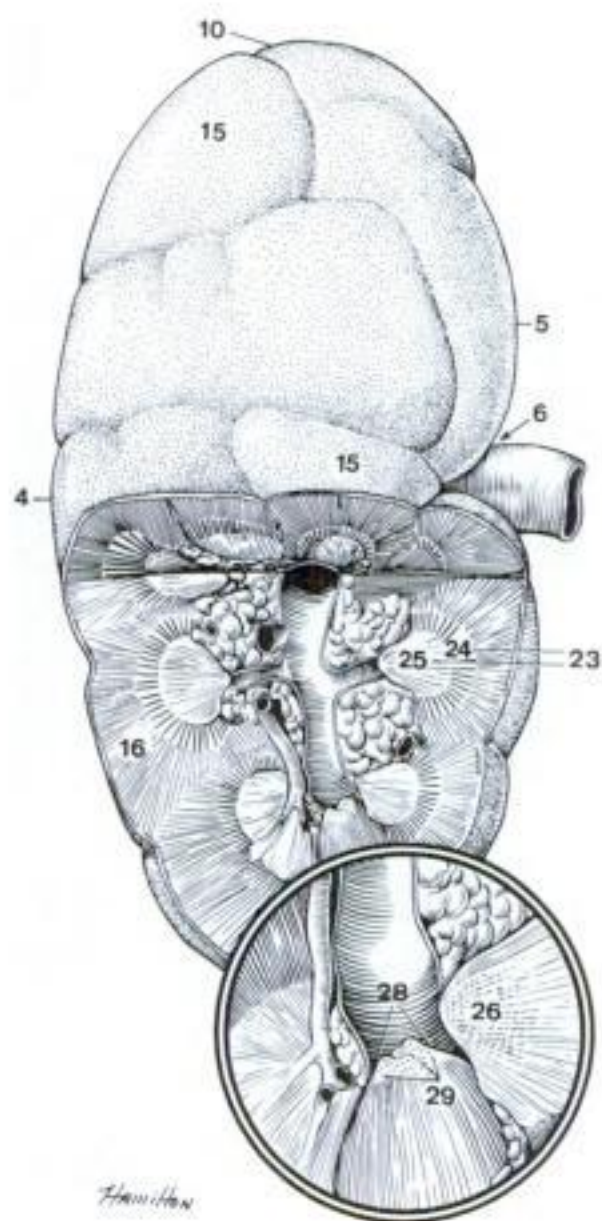


D Diaphragm, cranial aspect (ca)

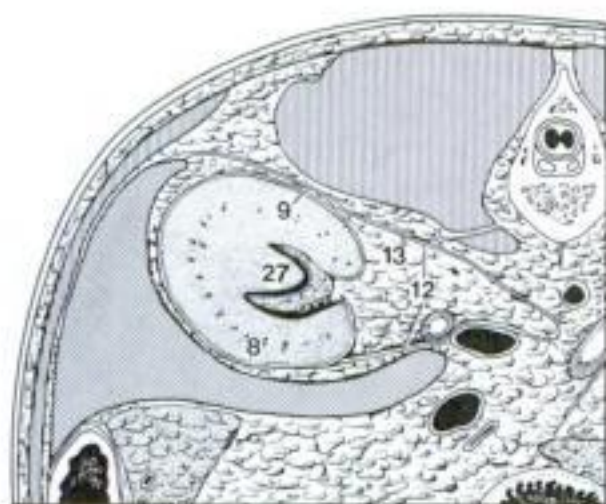
- 1 **APPARATUS UROGENITALIS.**
- 2 **ORGANA URINARIA.** Urinary organs.
- 3 **Ren.** Kidney. A B
- 4 *Margo lateralis.* Lateral border. A B
- 5 *Margo medialis.* Medial border. A B
- 6 *Hilus renalis.* Renal hilus, the point on the medial border where the vessels and the ureter are attached. A B
- 7 *Sinus renalis.* Renal sinus, a cavity in the kidney at the hilus. It contains fat and connective tissue surrounding the renal pelvis and vessels. A
- 8 *Facies ventralis.* Ventral surface. C
- 9 *Facies dorsalis.* Dorsal surface. C
- 10 *Extremitas cranialis.* Cranial end. A B
- 11 *Extremitas caudalis.* Caudal end. A
- 12 *Fascia renalis.* Renal fascia, two layers enclose the kidney and the *Capsula adiposa.* C
- 13 *Capsula adiposa.* Fat capsule. It surrounds the kidney outside the *Capsula fibrosa.* C
- 14 *Capsula fibrosa.* Fibrous capsule on the surface of the kidney. D
- 15 *Lobi renales.* Renal lobes. Each consists of a renal pyramid and its cortical cap. Lobation is visible on the developing kidney of all species, but only in bo does it persist on the surface. It is indicated in other adult mammals by the renal pyramids and interlobar vessels seen in section. A B
- 16 *Cortex renis.* Renal cortex, outer layer of the kidney. It covers the bases of the pyramids and extends between them as *Columnae renales.* A B
- 17 *Lobuli corticales.* Cortical lobules. Each lobule consists of a medullary ray and the surrounding *Pars convoluta.* D
- 18 *Pars convoluta.* Consists of convoluted tubules and renal corpuscles. D
- 19 *Corpuscula renis.* Renal corpuscles. About 0.1–0.3 mm in diameter, consist of a glomerulus invaginated into a capsule. D
- 20 *Glomeruli [Glomerula].* A. glomerulus is a knot of capillaries in a *Corpusculum renis.* D
- 21 *Pars radiata.* Medullary rays, bundles of straight tubules extending from the medulla into the cortex. Each ray is the core of a cortical lobule. D
- 22 *Medulla renis.* Renal medulla, consists of the pyramids. A
- 23 *Pyramides renales.* Renal pyramids. The base of each is at the cortex and the apex is a renal papilla in the pelvis or calyx. A B
- 24 *Basis pyramidis.* Base of the pyramid, covered by the cortex. A B
- 25 *Papillae renales.* Apices of the pyramids. They are separate, each with its own calyx in su, bo, but fused to form a crest in Car, ov, cap, eq. B
- 26 *Ductus papillares.* Papillary ducts, large terminal ducts with columnar epithelium. B
- 27 *Crista renalis.* Renal crest. In Car, ov, cap, eq the *Papillae renales* are fused to form the *Crista renalis.* A C
- 28 *Area cribrosa.* Cribriform area of the papilla or crest perforated by the openings of the papillary ducts. B
- 29 *Foramina papillaria.* Openings of the papillary ducts. B
- 30 *Columnae renales.* Renal columns, sections of crests of cortical tissue extending into the medulla around and between the pyramids. A
- 31 *Tubuli renales.* Renal tubules. D



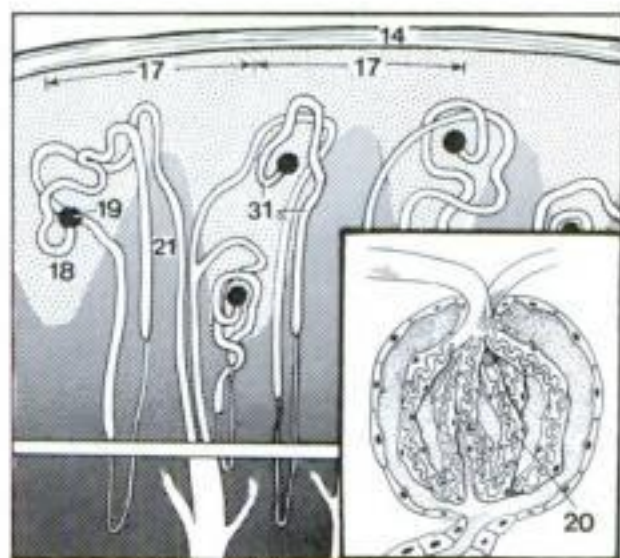
A Kidney, dorsal section (ca)



B Kidney, dorsal surface and partial section (bo)

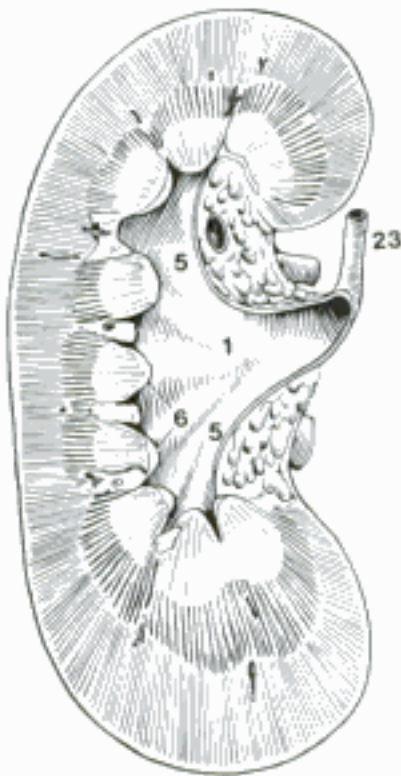


C Right kidney in situ, transverse section (ca)

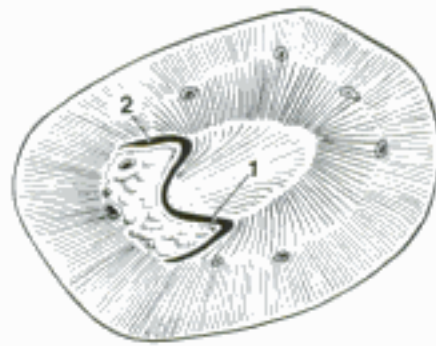


D Kidney, histological diagram

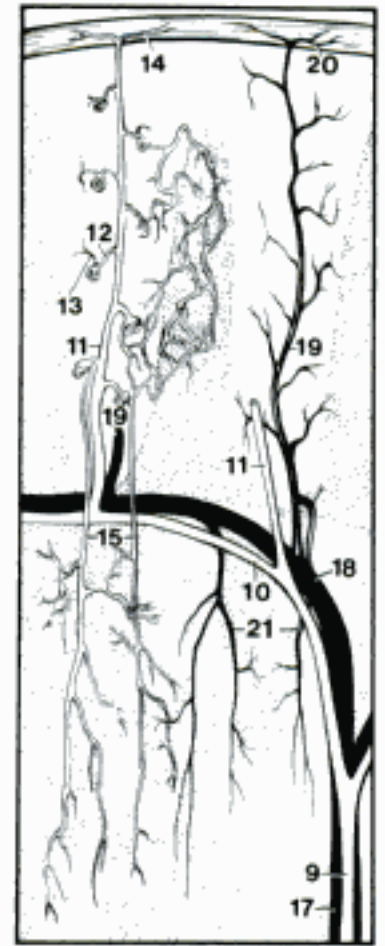
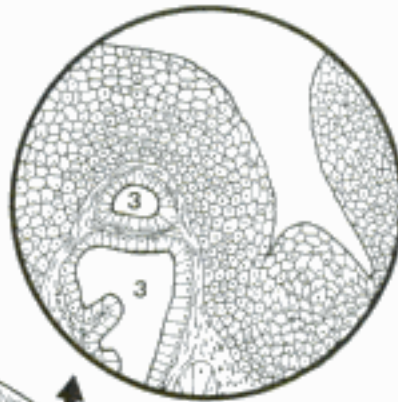- 1 *Pelvis renalis*. Renal pelvis, the dilation at the beginning of the ureter in the renal sinus, absent from bo. A B D
- 2 *Recessus pelvis*. Recess of the pelvis, one of several expansions of the pelvis. Each recess embraces a ridge formed by a pyramid leading to the renal crest. The interlobar vessels run in grooves between the recesses. B
- 3 *Gll. pelvis renalis (eq)*. Mucous glands. D
- 4 *Calices renales*. Renal calices. In su, bo, in which the papillae are separate, each papilla is surrounded by a cup-like branch of the pelvis or ureter.
- 5 *Calices renales majores*. Major renal calices, the primary branches of the pelvis or ureter. A
- 6 *Calices renales minores*. Minor renal calices, those receiving papillae. A
- 7 *Recessus terminales*. Terminal recesses, tubular diverticula of the equine renal pelvis which extend into the cranial and caudal ends of the kidney. D
- 8 **Arteriae renis**. Arteries of the kidney. C
- 9 *Arteriae interlobares renis*. The interlobar arteries run from the sinus toward the cortex between the pyramids. C D
- 10 *Arteriae arcuatae*. Arched arteries, branches arising from the Aa. interlobares. C
- 11 *Arteriae interlobulares*. Interlobular arteries arise from the Aa. arcuatae and penetrate the Pars convoluta of the cortex. C
- 12 *Arteriola glomerularis afferens*. Afferent vessel to the glomerulus from an A. interlobularis. C
- 13 *Arteriola glomerularis efferens*. Efferent vessel from the glomerulus to capillaries between tubules. C
- 14 **Rami capsulares**. Capsular branches from Aa. interlobulares to the fibrous capsule of the kidney. C
- 15 *Arteriolae rectae*. Straight arterioles, descend from the Arteriolae glomerulares efferentes or Aa. arcuatae into the medulla. C
- 16 **Venae renis**. Veins of the kidney. C
- 17 *Venae interlobares*. Interlobar veins, between the renal pyramids. C D
- 18 *Venae arcuatae*. Arched veins. They form arches between Vv. interlobares at the corticomedullary junction. C
- 19 *Venae interlobulares*. In the Pars convoluta of the cortex. C
- 20 *Venulae stellatae*. Stellate venules, capsular branches of Vv. interlobulares, visible in ca, ov, cap, eq. C
- 21 *Venulae rectae*. Straight venules drain the medulla to the Vv. arcuatae. C
- 22 *Venae capsulares (fe)*. Capsular veins that branch off the V. renalis at the hilus and form a characteristic network. E
- 23 **Ureter**. Duct from kidney to bladder. A D E
- 24 *Pars abdominalis*. Abdominal part.
- 25 *Pars pelvina*. Pelvic part.
- 26 *Tunica adventitia*. External coat of connective tissue. F
- 27 *Tunica muscularis*. Muscular coat. F
- 28 *Tunica mucosa*. Mucous membrane, lined by transitional epithelium. F
- 29 *Gll. uretericae (eq)*. Ureteral glands, mucous glands in the renal end of the ureter. F



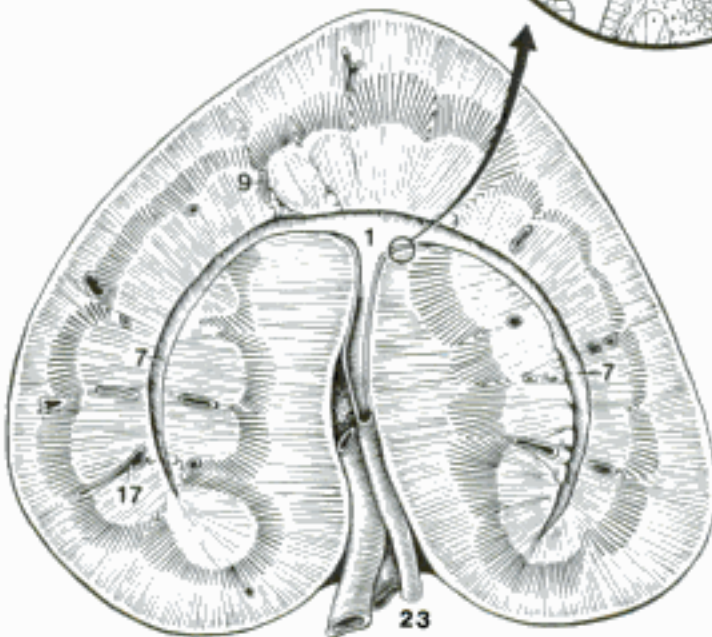
A Kidney, dorsal section through hilus (su)



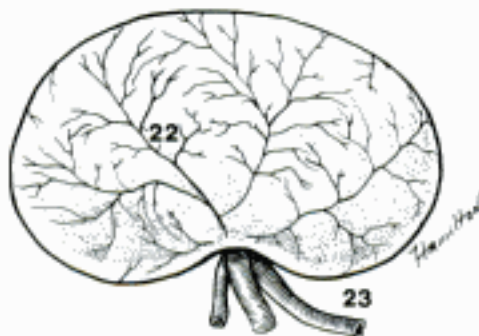B Kidney, transverse section (ca)



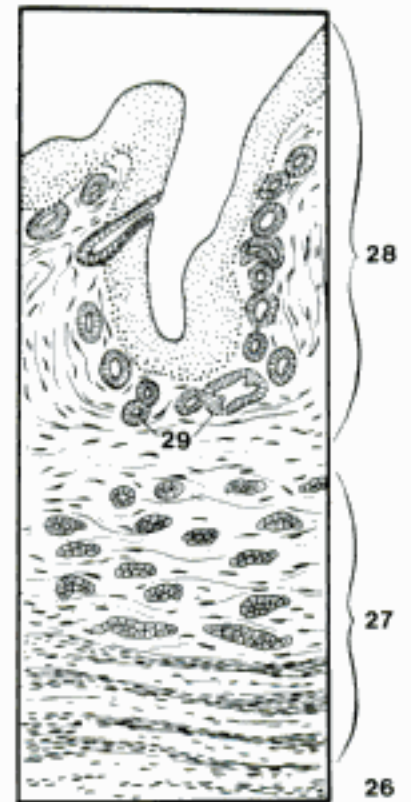
C Diagram of renal vessels (in the cortex, Pars radiata stippled, convoluta white)



D Right kidney, dorsal section through hilus (eq)

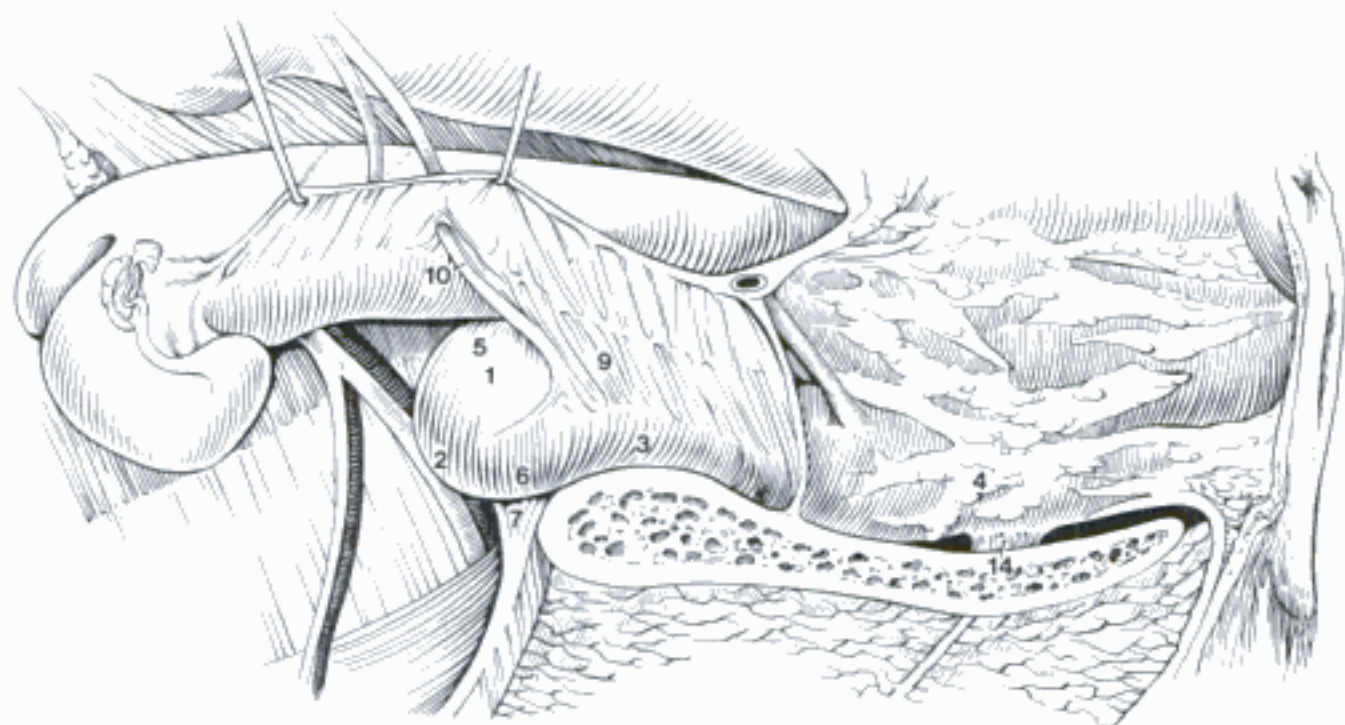


E Left kidney, ventral surface (fe)

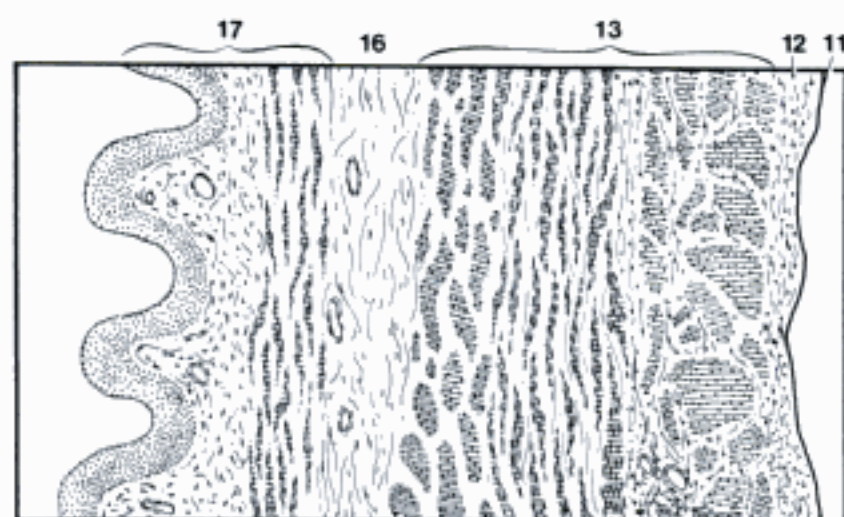


F Ureter, histological section (eq)

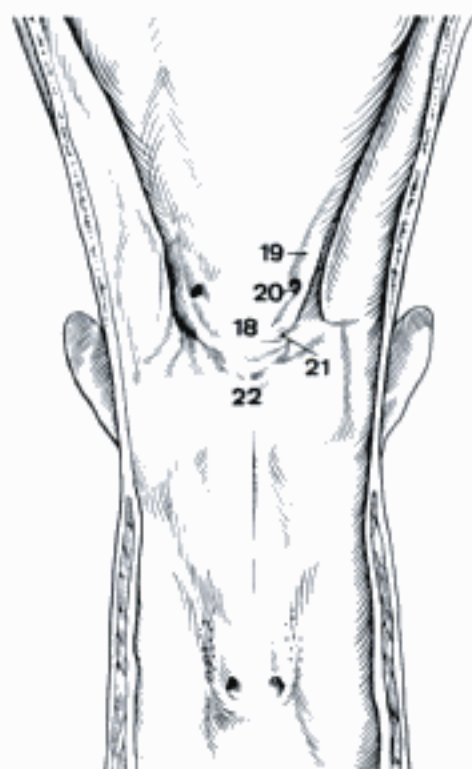
- 1 **Vesica urinaria.** Urinary bladder. A C
- 2 *Apex vesicae* [*Vertex vesicae*]. Apex of the bladder, the blind cranial end. A C
- 3 *Corpus vesicae.* Body of the bladder. The dorsal wall of the bladder does not form a *Fundus vesicae* in domestic mammals. A C
- 4 *Cervix vesicae.* Neck of the bladder. A
- 5 *Facies dorsalis.* Dorsal surface. A
- 6 *Facies ventralis.* Ventral surface. A
- 7 *Lig. vesicae medianum.* Middle lig. of the bladder, a peritoneal fold attaching the ventral surface of the bladder to the Symphysis pelvina and the Linea alba. In the fetus it contains the Urachus in its free border. The NA term *Plica umbilicalis mediana* is not appropriate for quadrupeds because the bladder is not retroperitoneal as in man, and the ligament has a more obvious relation to the bladder than to the umbilicus. A C
- 8 *Urachus* (ont). Fetal duct from the bladder through the umbilical cord to the allantoic cavity. It is enclosed in the *Lig. vesicae medianum*. C
- 9 *Lig. vesicae laterale.* Lateral lig. of the bladder, a peritoneal fold attached to the dorsolateral pelvic wall in the male and to the broad lig. in the female. It contains the *Lig. teres vesicae*. The NA term *Plica umbilicalis medialis* is not descriptive in quadrupeds because the lateral lig. does not approach the umbilicus in the adult, nor is it medial to any other lig. of the bladder. A C
- 10 *Lig. teres vesicae.* Round lig. of the bladder, vestige of the A. umbilicalis in the *Lig. vesicae laterale*. A C
- 11 *Tunica serosa.* Serous coat, the visceral peritoneum on the bladder. B
- 12 *Tela subserosa.* Subserous tissue, the connective tissue between serous and muscular layers. B
- 13 *Tunica muscularis.* Muscular coat, smooth muscle of the wall of the bladder. The term *M. sphincter vesicae* was omitted because there is no evidence of such a sphincter apart from the striated *M. urethralis*. B
- 14 *M. pubovesicalis.* Smooth muscle in the *Lig. pubovesicale* from the Symphysis pubica to the *Cervix vesicae*. A
- 15 *M. rectourethralis.* O: ventral longitudinal muscle of the rectum. T: in the male, on the urethra; in the female, in the smooth muscle of the vestibule and labia. In the bull it is variable in occurrence and position. C
- 16 *Tela submucosa.* Loose vascular connective tissue under the *Tunica mucosa*. B
- 17 *Tunica mucosa.* Mucous membrane, covered by transitional epithelium. B
- 18 *Trigonum vesicae.* Triangle of the bladder, smooth area of mucous membrane between the ureteral and urethral orifices. D
- 19 *Columna ureterica.* Ureteral column, the elevation of the mucosa produced by the ureter in its course in the wall of the bladder. D
- 20 *Ostium ureteris.* Opening of the ureter. D
- 21 *Plica ureterica.* Ureteral fold, in veterinary anatomy, the lateral boundary of the *Trigonum vesicae*. In the BNA the term was used for a different structure, the *Plica interureterica* (NA), not described in domestic mammals. D
- 22 *Ostium urethrae internum.* Internal urethral orifice. D



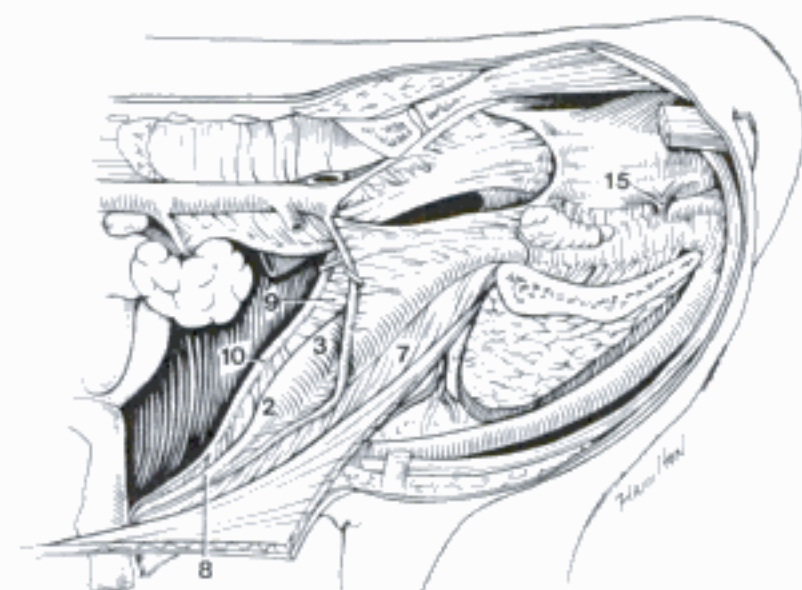
A Genital organs and bladder in situ (the cut edge of the broad ligament is held by hooks), lateral aspect (bo fem)



B Wall of urinary bladder, histological section (bo) (Trautmann and Fiebiger)

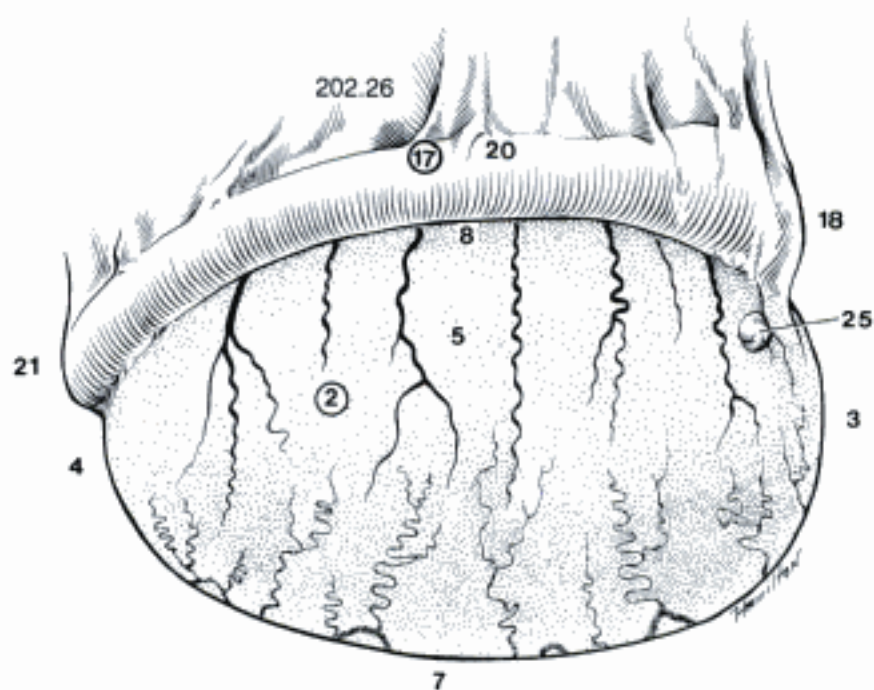


D Urinary bladder and male urethra (opened ventrally) (eq)

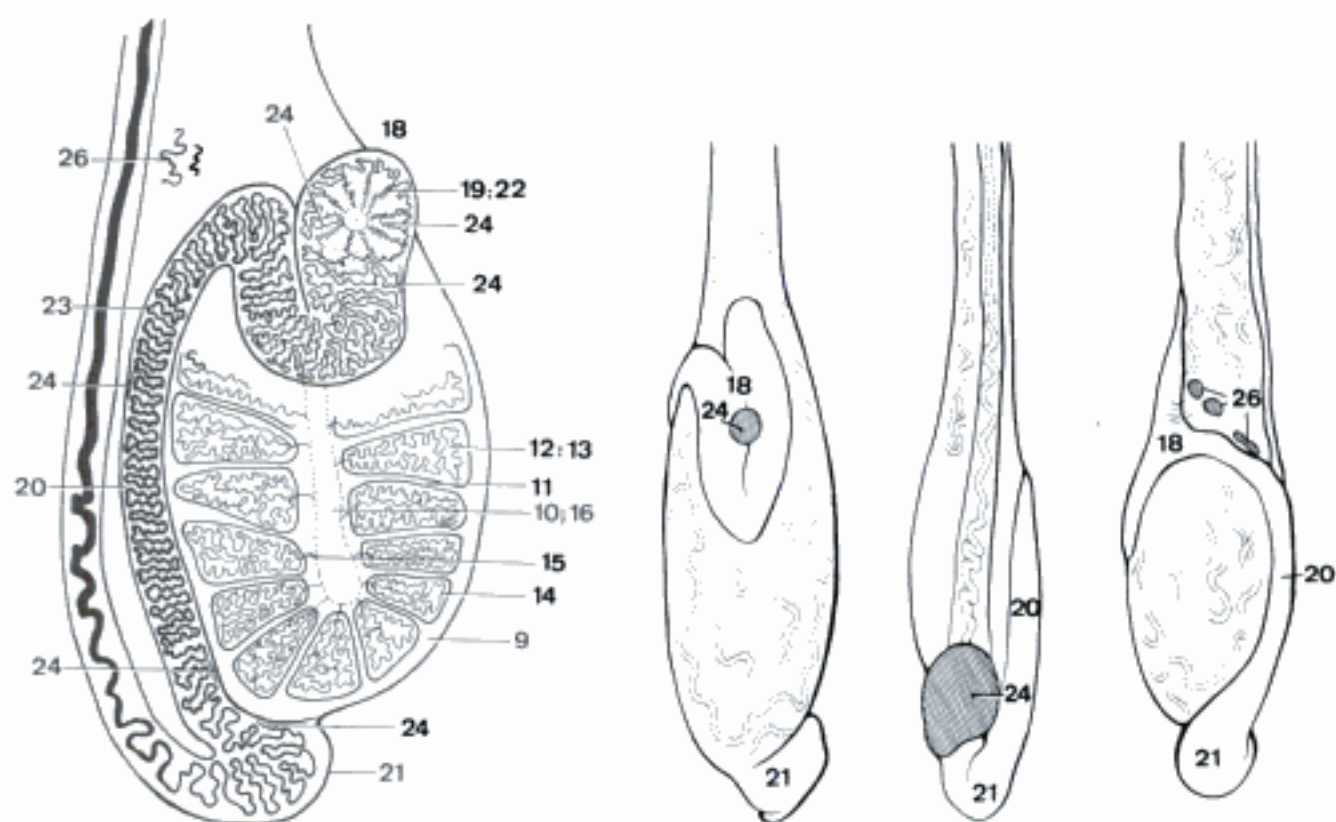


C Urogenital organs in situ, left lateral aspect (bo masc, newborn) (Popesko)

- 1 **ORGANA GENITALIA MASCULINA.** Male genital organs.
- 2 **Testis.** Testicle. A B
- 3 *Extremitas capitata.* Head end, related to the Caput epididymidis, cranial in most species, but dorsal in Ru. A
- 4 *Extremitas caudata.* Tail end, related to the Cauda epididymidis, caudal in most species, but ventral in Ru. A
- 5 *Facies lateralis.* Lateral surface. The corresponding surface is caudal in Ru. A
- 6 *Facies medialis.* Medial surface. The corresponding surface is cranial in Ru.
- 7 *Margo liber.* Free border, ventral in most species, but caudal in su, lateral in Ru. A
- 8 *Margo epididymalis.* Epididymal border, dorsal in most species, but cranial in su medial in Ru. A
- 9 *Tunica albuginea.* Dense white capsule of the testis. B
- 10 *Mediastinum testis.* Axial strand of connective tissue from which the septula radiate. It is absent in eq. B
- 11 *Septula testis.* Interlobular connective tissue partitions extending from the Mediastinum testis to the Tunica albuginea. B
- 12 *Lobuli testis.* Lobules of the testis. B
- 13 *Parenchyma testis.* The seminiferous tubules. B
- 14 *Tubuli seminiferi contorti.* Convolut-ed seminiferous tubules. B
- 15 *Tubuli seminiferi recti.* Straight semi-niferous tubules, from the convoluted tubules to the Rete testis. B
- 16 *Rete testis.* Network of ducts in the Mediastinum testis connecting the Tubuli seminiferi recti to the Ductuli efferentes. It is absent in eq. B
- 17 **Epididymis.** Organ attached to the testis and formed by the coiled Ductuli efferentes testis and the Ductus epididymidis. A B
- 18 *Caput epididymidis.* Head of the epididymis, contains the Lobuli epididymidis. In Ru it has descending and ascending limbs. A B C
- 19 *Ductuli efferentes testis.* Efferent ductules, lead from the Rete testis to the Ductus epididymidis. They are coiled to form the Lobuli epididymidis. B
- 20 *Corpus epididymidis.* Body of the epididymis, consists of the coiled duct. A B C
- 21 *Cauda epididymidis.* Tail of the epididymis, continous with the Ductus deferens. A B C
- 22 *Lobuli epididymidis [Coni epididymidis].* Lobules of the epididymis, containing the coiled Ductuli efferentes testis in the Caput epididymidis. B
- 23 *Ductus epididymidis.* Duct of the epididymis, convoluted to form the epididymis, 70–80 m long in eq. B
- 24 (*Ductuli aberrantes*). Aberrant ductules, blind branches of the Ductus epididymidis or of Ductuli efferentes testis. They are rare vestiges of the mesonephric tubules, appearing as cysts on the epididymis. B C
- 25 (*Appendix testis*). Appendage of the testicle, a wrinkled wart-like process on the testis near the Caput epididymidis. It is a vestige of the cranial end of the paramesonephric duct and occurs often in eq. A
- 26 (*Paradidymis*). Detached mesonephric tubules in the spermatic cord just proximal to the head of the epididymis. B C



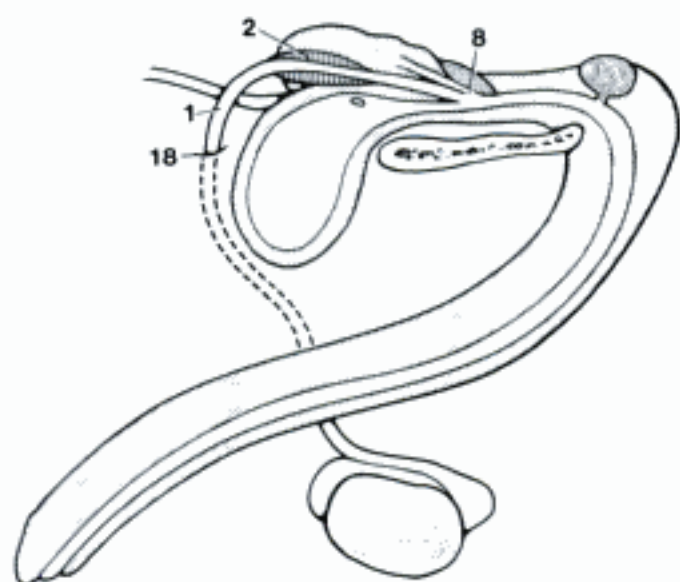
A Right testis and epididymis, lateral surface (eq)



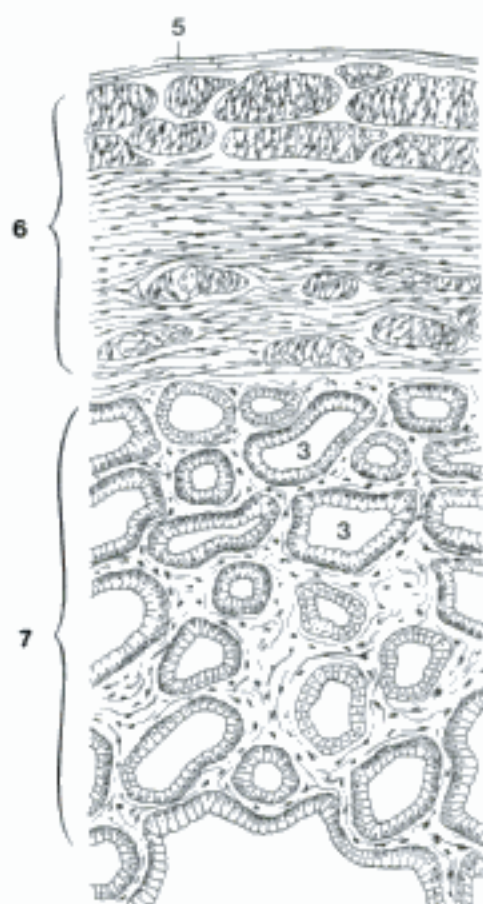
B Diagram of testis and epididymis (bo) (Blom and Christensen, 1960, Paul H. Winther, del.)

C Testis and epididymis. Left: free border, right testis; middle: epididymal border, right testis; right: caudal surface, left testis (bo, young) (Blom and Christensen, 1958)

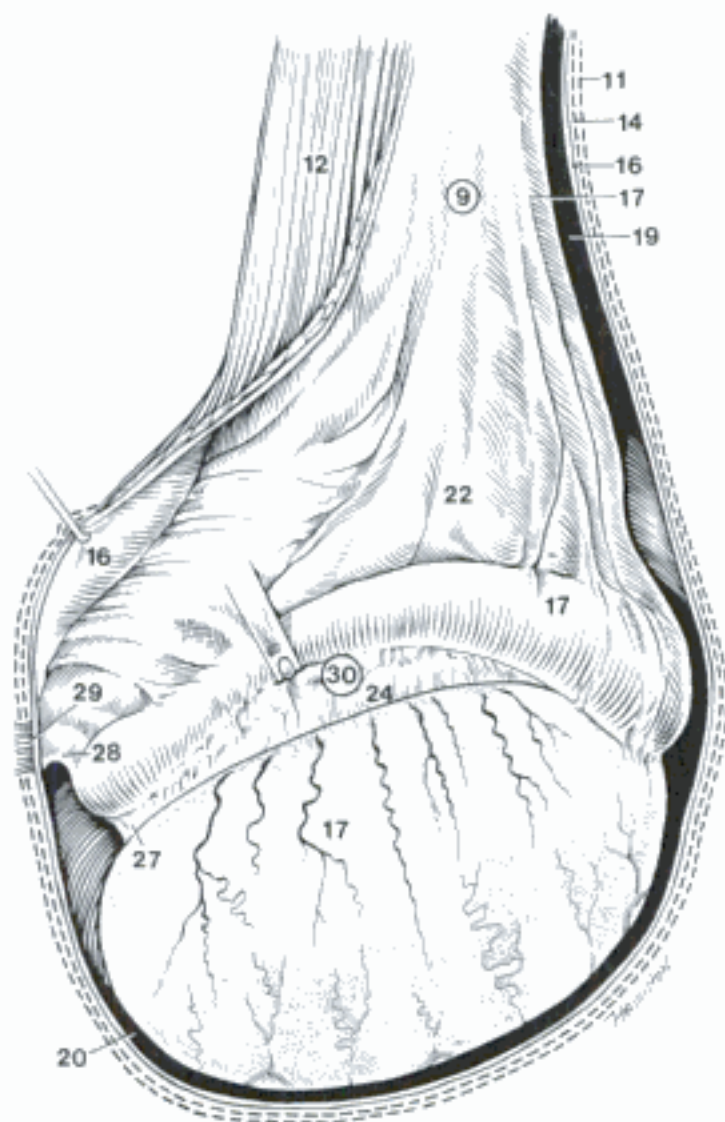
- 1 **Ductus deferens.** Deferent duct. Extends from the epididymis through the Funniculus spermaticus to the Colliculus seminalis in the urethra. A D
- 2 *Ampulla ductus deferentis.* Enlargement of the terminal part of the Ductus deferens, produced by a glandular thickening of its wall, absent in fe, su. A B
- 3 *Gll. ampullae.* Glands of the ampulla. In domestic mammals they are branched tubular glands. B
- 4 *Tunica adventitia.* Outer connective tissue coat of the Ductus deferens in its retroperitoneal course.
- 5 *Tunica serosa.* Serous coat of the Ductus deferens, present in quadrupeds. B
- 6 *Tunica muscularis.* Smooth muscle of the Ductus deferens. B
- 7 *Tunica mucosa.* Mucous membrane. B
- 8 *Ductus ejaculatorius.* Ejaculatory duct, short, inconstant common excretory passage in the Colliculus seminalis for the Ductus deferens and the duct of the Glandula vesicularis. A
- 9 **Funiculus spermaticus.** Spermatic cord, including the blood vessels, lymphatics, and nerves of the testis and epididymis, together with the Ductus deferens and the Lamina visceralis tunicae vaginalis. C D
- 10 **Tunicae funiculi spermatici et testis.** Coverings of the spermatic cord and testicle.
- 11 *Fascia spermatica externa.* External spermatic fascia, continuous with Fascia m. obliqui externi abdominis. C D
- 12 *M. cremaster.* Striated muscle on the Tunica vaginalis. O: Fascia iliaca. T: Tunica vaginalis near the testis. It lies between the internal and external spermatic fascia and draws the testis toward the inguinal canal. C D
- 13 *Fascia cremasterica.* Cremasteric fascia on the M. cremaster. D
- 14 *Fascia spermatica interna.* Internal spermatic fascia, continuous with Fascia transversalis. C D
- 15 *Tunica vaginalis.* Vaginal tunic, the serous membranes covering the spermatic cord and testis. D
- 16 *Lamina parietalis.* Parietal layer, continuous with the parietal peritoneum. C D
- 17 *Lamina visceralis.* Visceral layer, adherent to the testis, epididymis and spermatic cord. C D
- 18 *Anulus vaginalis.* Vaginal ring, where the peritoneum is evaginated to form the Lamina parietalis of the Tunica vaginalis. A
- 19 *Canalis vaginalis.* Vaginal canal, potential space between Lamina parietalis and visceralis around the spermatic cord. C D
- 20 *Cavum vaginale.* Vaginal cavity, between Lamina parietalis and visceralis around the testis. C
- 21 *Mesorchium.* Peritoneal fold containing vessels and nerves of testis. D
- 22 *Mesorchium proximale [Plica vasculosa].* Proximal mesorchium (vascular fold). It extends from the origin of the testicular vessels to the mesepididymis. C
- 23 *Mesofuniculus.* Strip of Mesorchium between origin of Mesoductus deferens and Lamina parietalis. D
- 24 *Mesorchium distale.* Extends from Mesepididymis to the testis. C
- 25 *Mesoductus deferens [Plica ductus deferentis].* Attaches the Ductus deferens to the mesorchium and to the abdominal and pelvic walls. D
- 26 *Mesepididymis.* Attaches the epididymis. 201 A
- 27 *Lig. testis proprium.* Proper lig. of the testis, from the testis to the tail of the epididymis. C
- 28 *Lig. caudae epididymidis.* Between the tail of the epididymis and the Lamina parietalis (Un). In Car the tail of the epididymis is adherent to the Fascia spermatica interna. C
- 29 *Lig. scroti.* Scrotal lig., strand of connective tissue between Tunica dartos and Lig. caudae epididymidis (Un) or the tail of the epididymis (Car). C
- 30 *Bursa testicularis [Sinus epididymalis].* Testicular bursa [epididymal sinus], formed by Mesorchium distale, testis, and epididymis. C



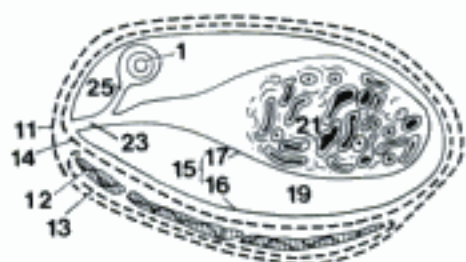
A Diagram of male genital organs, showing right testis (eq) (Nickel, et al.; 1979)



B Ampulla of Ductus deferens, histological section (bo)

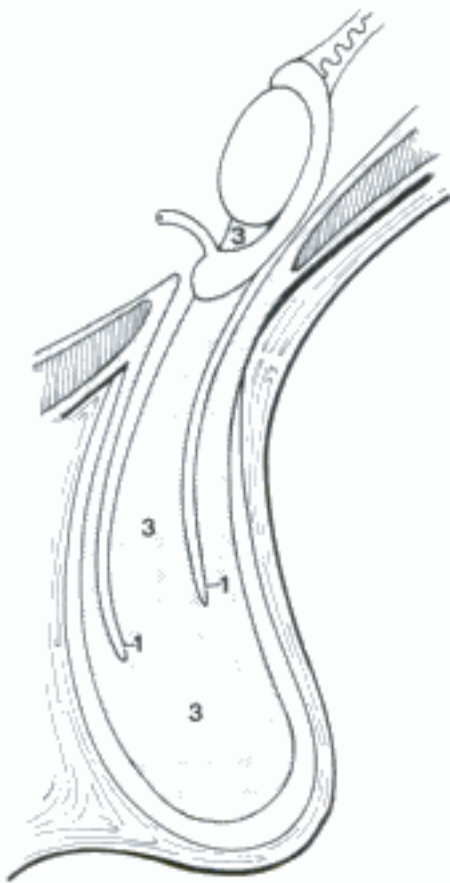


C Right testis and spermatic cord, lateral surface (fasciae, M. cremaster and parietal tunic opened) (eq)

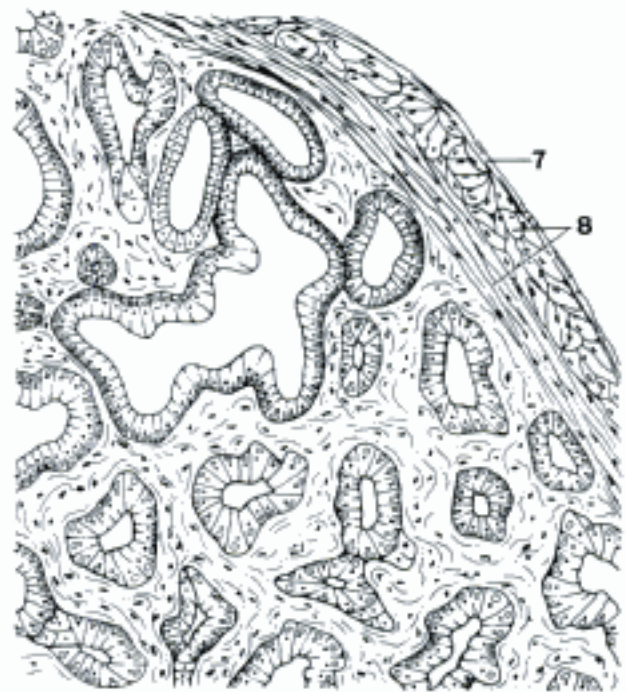


D Right spermatic cord, transected, distal surface (eq)

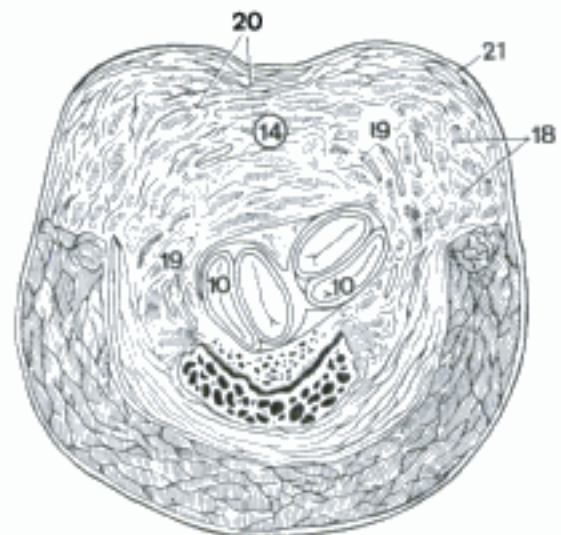- 1 *Processus vaginalis peritonei* [*peritonaei*] (ont). Vaginal process, cylindrical evagination of peritoneum into the inguinal canal before the descent of the testis; thereafter it is called the Tunica vaginalis. In adult females the Processus vaginalis is often present in ca and rarely in fe. A
- 2 *Descensus testis* (ont). Descent of the testicle from its original position to the scrotum. A
- 3 *Gubernaculum testis* (ont). Guide of the testicle, a mesenchymal tract from the testis to the tail of the epididymis and thence to the deep inguinal ring and through the inguinal canal. The vestiges of the gubernaculum are the Lig. proprium testis and the Lig. caudae epididymidis. A
- 4 **Glandulae genitales accessoriae.** Accessory genital glands. C
- 5 **Ampulla ductus deferentis.** See 202.2. C
- 6 **Glandula vesicularis (Un).** Vesicular gland. In su, Ru, a compound tubular lobulated gland on the neck of the bladder; in eq, a flask-shaped organ with a muscular wall and a central collecting space, folds of the Tunica mucosa form a complex system of glandular recesses. B C
- 7 *Tunica adventitia.* Outer connective tissue coat of the gland. B
- 8 *Tunica muscularis.* A continuous muscular coat is present only in eq. B
- 9 *Tunica mucosa.* Mucous membrane (eq).
- 10 *Ductus excretorius.* Excretory duct, opens on the Colliculus seminalis, sometimes via a Ductus ejaculatorius. D
- 11 **Prostata.** Prostate, gland secreting into the pelvic part of the male urethra. C
- 12 *Facies ventralis.* Ventral surface.
- 13 *Facies dorsalis.* Dorsal surface. C
- 14 *Corpus prostatae.* Body of the prostate, at the beginning of the pelvic urethra in Car, su, bo and eq. D
- 15 *Pars disseminata prostatae.* Disseminate part of the prostate. It forms a glandular layer in the wall of the pelvic urethra in su, bo, cap, but is deficient ventrally in ov, and is represented only by a few lobules in Car. E
- 16 *Lobus [dexter et sinister].* Right and left lobes. In eq, right and left lobes are connected by an isthmus; in Car they are partially divided by a groove. C
- 17 *Isthmus prostatae.* Isthmus of the prostate. In eq, it lies between the lobes, across the dorsal surface of the neck of the bladder. C
- 18 *Parenchyma.* Glandular substance. D E
- 19 *Ductuli prostatici.* Prostatic ductules. Numerous excretory ductules open into the urethra. D
- 20 *Substantia muscularis.* Muscular substance. The septa that radiate through the gland to the capsule contain much smooth muscle. D E
- 21 *Capsula prostatae.* Capsule of the prostate, containing smooth muscle. D E
- 22 **Glandula bulbourethralis.** Bulbourethral gland. Secreting into the caudal end of the pelvic urethra, it bulges dorsolaterally between M. urethralis and M. bulbospongiosus. In su it extends cranially the full length of the pelvic urethra. It is absent in ca. C
- 23 *Ductus gl. bulbourethralis.* Duct of the bulbourethral gland. 211 D



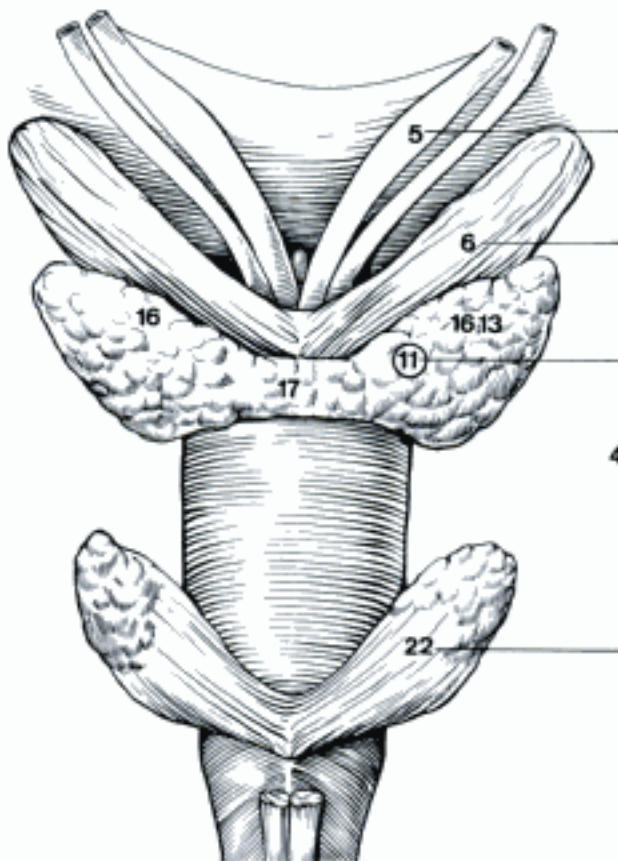
A Descensus testis, diagrammatic section through inguinal canal (su) (Backhouse and Butler)



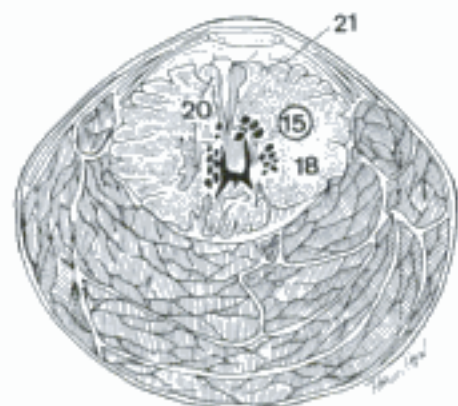
B Vesicular gland, histological section (bo)



D Body of the prostate, transverse section of pelvic part of urethra and Stratum spongiosum (deferent ducts medial and dorsal to 10) (bo)



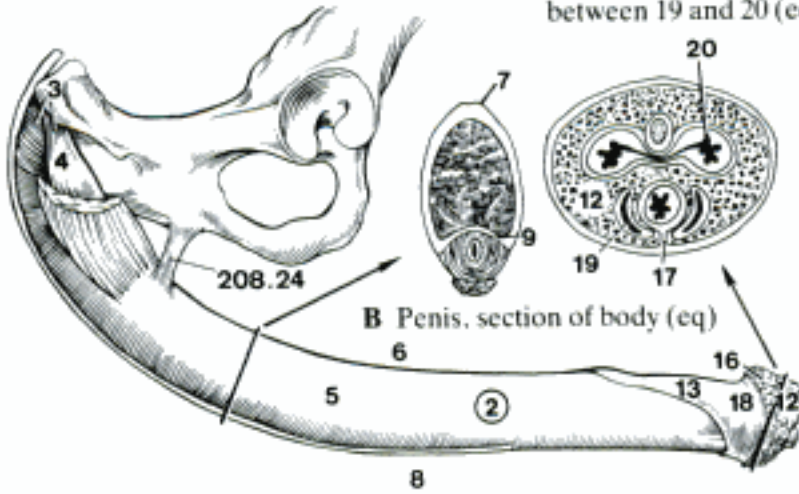
C Glandulae genitales accessoriae, dorsal aspect (eq) (Nickel, et al., 1979)



E Disseminate prostate (ventral and lateral parts of the section consist of *M. urethralis*) (bo)

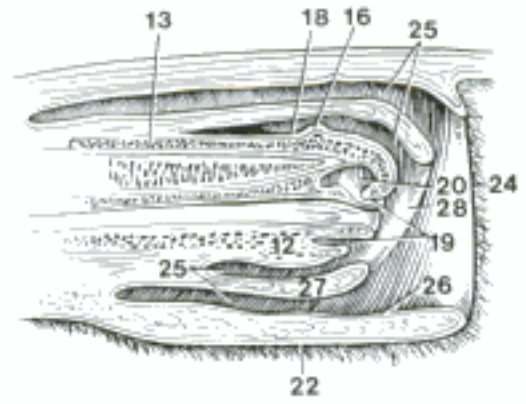
- 1 **PARTES GENITALES MASCULINAE EXTERNAE.** External male genitalia: penis, prepuce, and scrotum.
- 2 **Penis.** Male organ of copulation. A
- 3 *Radix penis.* Root of the penis, composed of the two Crura and the Bulbus penis. A
- 4 *Crus penis.* Proximal end of each Corpus cavernosum penis attached to the Arcus ischiadicus and covered by M. ischiocavernosus. A
- 5 *Corpus penis.* Body of the penis, the shaft from the root to the glans. A
- 6 *Dorsum penis.* Back of the penis when erect, the surface opposite the urethral surface. A
- 7 *Sulcus dorsalis penis.* Dorsal groove of the penis (eq). B
- 8 *Facies urethralis.* Urethral surface. A
- 9 *Sulcus urethralis.* Urethral groove in the body of the penis, containing Corpus spongiosum and urethra. B
- 10 *Flexura sigmoidea penis (su, Ru).* S-shaped bend in the flaccid penis between the thighs. E H
- 11 *Pars libera penis.* Free part of the penis, distal to the attachment of the prepuce. E F H
- 12 *Glans penis.* Head of the penis, containing the Corpus spongiosum glandis. The glans of Ru was formerly called the Galea glandis in the belief that the whole Pars libera penis was the glans. A glans is a cushion outside the Tunica albuginea corporum cavernosorum. A C D E F G
- 13 *Processus dorsalis glandis (eq).* Dorsal process of the glans. It extends caudally about 10 cm. A D
- 14 *Pars longa glandis (ca).* Long part of the glans, the distal, cylindrical part. G
- 15 *Bulbus glandis (ca).* Bulb of the glans, the proximal part. G
- 16 *Corona glandis.* Crown of the glans. A D G
- 17 *Septum glandis.* Septum of the glans, incomplete median ventral septum. C
- 18 *Collum glandis.* Neck of the glans, constriction proximal to the Corona glandis. A D
- 19 *Fossa glandis (eq).* Fossa of the glans, circular excavation around the Processus urethralis. C D
- 20 *Sinus urethralis (eq).* Urethral sinus, a dorsal diverticulum of the Fossa glandis. C D
- 21 *Preputium [Praeputium].* Sheath, foreskin, surrounding the Pars libera penis when not erect. H
- 22 *Lamina externa.* External layer of the fold of skin forming the prepuce. D
- 23 *Raphe preputii [Rhaphe praeputii].* Median ventral seam of the prepuce, continuous with the Raphe scroti. F
- 24 *Ostium preputiale [prae-].* Preputial orifice where the Lamina externa is reflected as the Lamina interna. D E
- 25 *Cavum preputiale [prae-].* Preputial cavity, between the Lamina interna and the Pars libera penis. In eq the cavity is divided by the Plica preputialis into two concentric recesses. D E H
- 26 *Lamina interna.* Internal layer of the fold of skin forming the prepuce. It is attached to the penis at the proximal end of the Pars libera, where it is continuous with the skin of the free end of penis and glans. D G
- 27 *Plica preputialis [prae-] (eq).* Preputial fold, a cylindrical fold of the Lamina interna, reflected at the Anulus preputialis. D
- 28 *Anulus preputialis [prae-] (eq).* Preputial ring, a thickened band of skin at the distal reflection of the preputial fold. D
- 29 *Diverticulum preputiale [prae-] (su).* Large dorsal sac connected with the cranial end of the preputial cavity. H
- 30 *Frenulum preputii [prae-].* Rudimentary fold of skin connecting the Raphe preputii to Raphe penis in fe, Ru. F

C Glans penis, cut caudal to opening between 19 and 20 (eq)

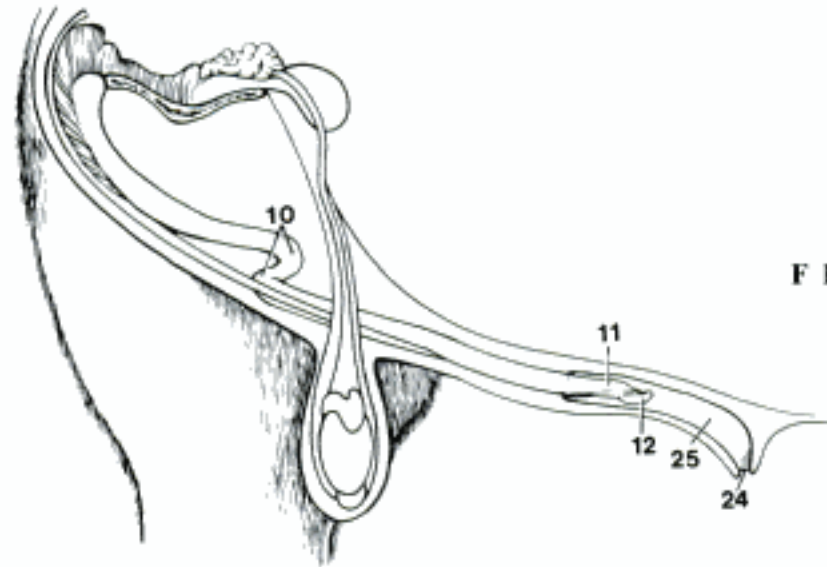


A Penis, dissection (right M. ischiocavernosus partly removed) (eq)

B Penis, section of body (eq)



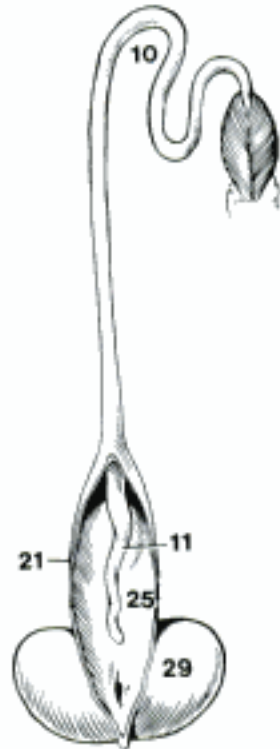D Penis, prepuce and abdominal wall, longitudinal section (eq)



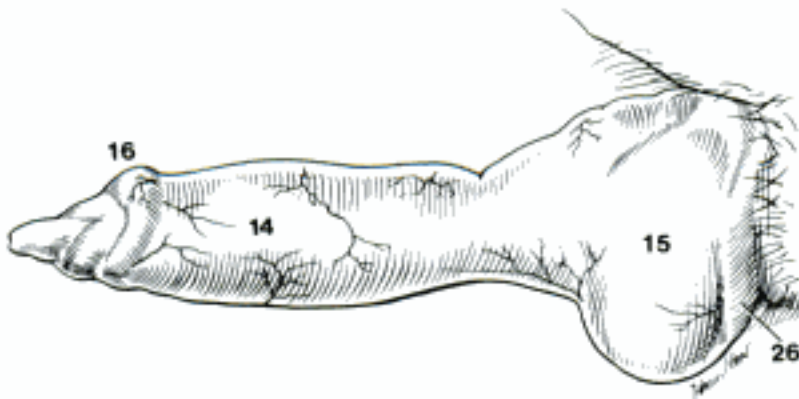
E Penis and prepuce (right wall of prepuce removed) (bo)



F Pars libera penis, right lateral surface (bo)

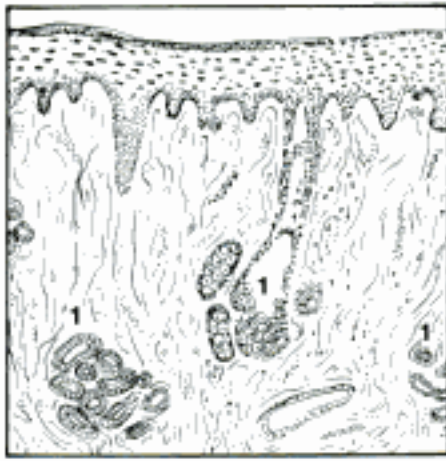


H Prepuce and penis (prepuce opened and portion with orifice removed), ventral aspect (su) Ellenberger and Baum)

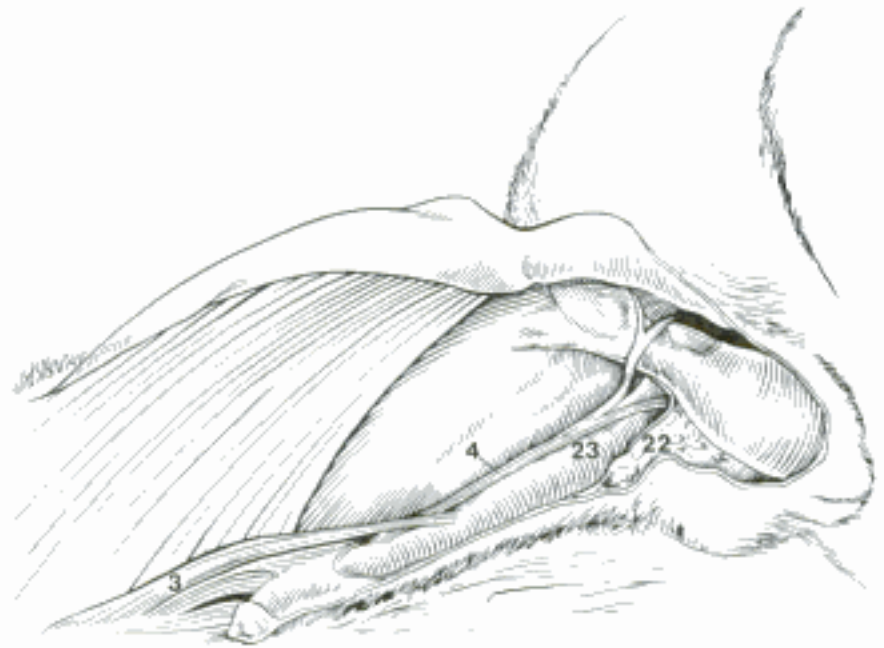

G Glans penis, erect, left craniolateral aspect (ca) (Hart and Kitchell)

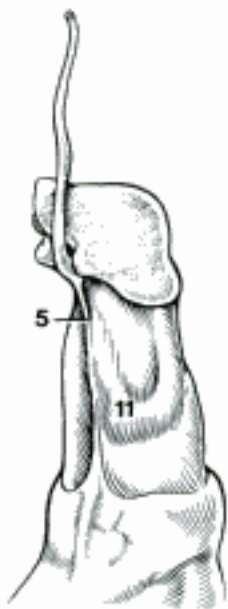
- 1 Gll. preputiales [prae-]. Preputial glands, modified sebaceous and sudoriferous glands in the Lamina interna near the preputial orifice, in eq they extend to the preputial ring. A
- 2 Lymphonoduli [Noduli lymphatici] preputiales [prae-]. Preputial lymph nodules.
- 3 *M. preputialis [prae-] cranialis*. Cutaneous muscle, absent in eq. O: Superficial fascia in the xiphoid region; in bo, also transverse from M. cutaneus trunci to Ostium praeputiale T: prepuce; right and left muscles form a loop around the orifice. B
- 4 *M. preputialis [prae-] caudalis*. Cutaneous muscle in fe, Ru; rudimentary in ca, su; absent in eq. O: in fe, on M. sphincter ani externus; in Ru, inguinal fascia lateral and medial to Tunica vaginalis. T: prepuce. B
- 5 *Raphe [Rhaphe] penis*. Seam on the free part of the penis from the Fenum preputii to the glans in su and Ru. The former term Raphe glandis (Ru) is omitted because the greater part of this raphe is not on the glans. C
- 6 *Corpus cavernosum penis*. Cavernous body of the penis. Right and left Corpora cavernosa are fused in the body of the penis. D G
- 7 *Os penis*. Bone of the penis (Car), ossified distal part of the fused Corpora cavernosa in the Glans penis. D
- 8 *Corpus spongiosum penis*. Spongy body of the penis, erectile tissue surrounding the urethra, formerly Corpus cavernosum urethrae. D
- 9 *Corpus spongiosum glandis*. Spongy body of the glans, continuous with the Corpus spongiosum penis. D
- 10 *Bulbus penis*. Bulb of the penis, caudal expansion of the Corpus spongiosum penis, formerly Bulbus urethrae. D
- 11 *Tuberculum spongiosum*. Spongy tubercle (ov), rounded process of the Corpus spongiosum on the left side of the Pars libera penis. C
- 12 *Tunica albuginea corporum cavernosorum*. Dense white fibrous coat around the Corpora cavernosa. D F G
- 13 *Lig. apicale penis*. Apical lig. of the penis (bo, cap), a thick longitudinal band arising from the dorsal surface of the Tunica albuginea distal to the sigmoid flexure and inserted into the Tunica albuginea near the apex. E
- 14 *Tunica albuginea corporis spongiosi*. Fibrous coat of the spongy body. F
- 15 *Septum penis*. Median septum between the Corpora cavernosa penis. F
- 16 *Trabeculae corporum cavernosorum*. Fibromuscular partitions between the Cavernae corporum cavernosorum. F
- 17 *Trabeculae corporis spongiosi*. Fibromuscular partitions between the Cavernae corporis spongiosi. F
- 18 *Cavernae corporum cavernosorum*. Vascular spaces of the cavernous bodies. F
- 19 *Cavernae corporis spongiosi*. Vascular spaces of the spongy body. F
- 20 *Arteriae helicinae*. Helicine arteries, terminal branches of the A. profunda penis, coiled and closed in the flaccid state, open to the cavernae in erection. F
- 21 *Venae cavernosae*. Veins draining the cavernous spaces of the erectile tissue. F
- 22 *Fascia penis superficialis*. Superficial fascia of the penis. It extends to the glans and into the prepuce and is continuous with the superficial perineal fascia, the Septum scroti, and the external spermatic fascia. B G
- 23 *Fascia penis profunda*. Deep fascia of the penis. Closely surrounds Corpora cavernosa and Corpus spongiosum, blends with the suspensory ligament of the penis, and is continuous with the Membrane perinei. B G
- 24 *Lig. suspensorium penis*. Suspensory lig. of the penis, bilateral collagenous laminae that extend from the caudal part of the Symphysis pelvina to the Corpora cavernosa, enclosing the dorsal vessels and nerves of the penis. 207 A
- 25 *Lig. fundiforme penis*. Sling-shaped ligament of the penis, bilateral elastic bands from the median ventral surface of the Tendo prepubicus. They pass around the sides of the penis and blend with the Septum scroti. G



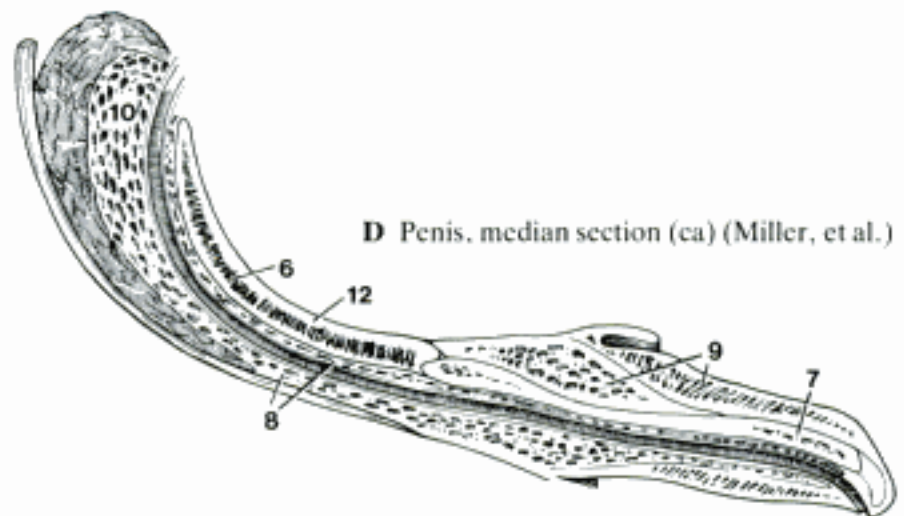
A Lamina interna of prepuce, histological section (eq) (Krage)



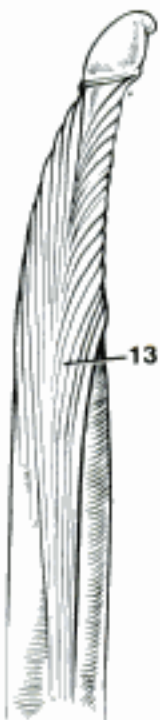
B Preputial muscles (external spermatic fascia fenestrated over M. cremaster), left ventral aspect (cap)



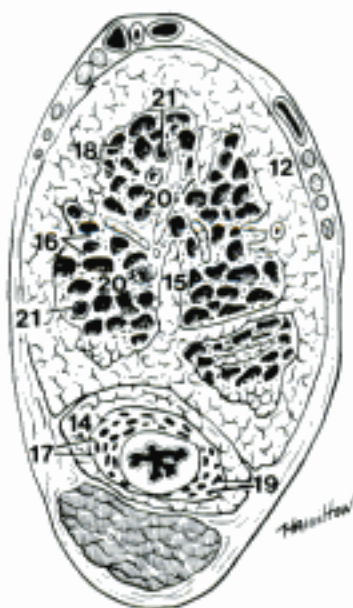C Penis, left ventral aspect (ov) (Nickel, et al., 1979)



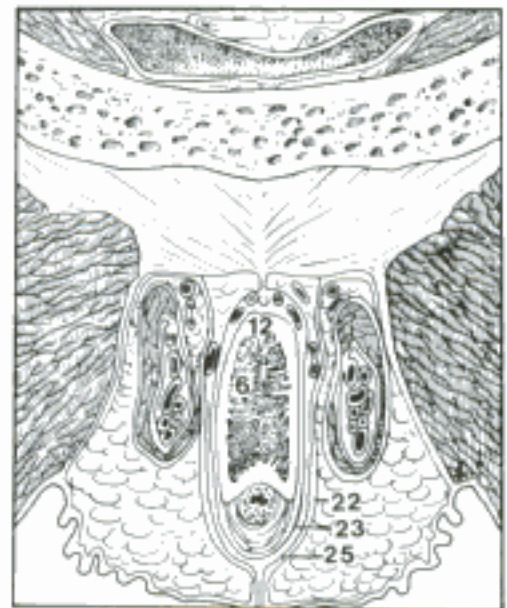
D Penis, median section (ca) (Miller, et al.)



E Penis (skin and superficial fascia removed, except from the glans), dorsal aspect (bo)

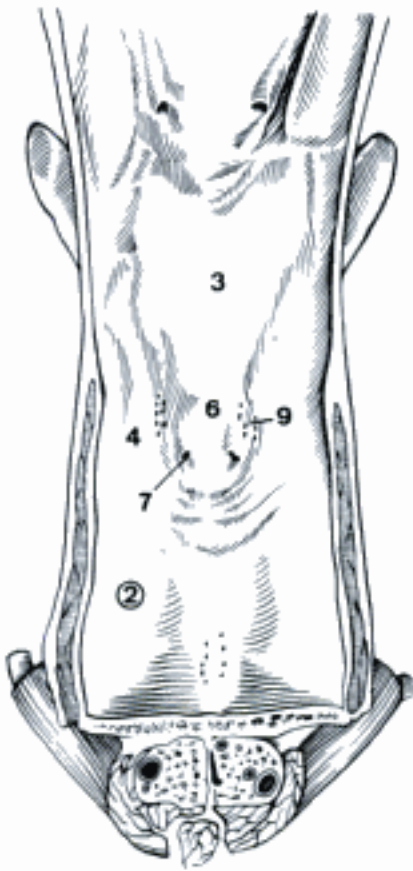


F Penis, histological section (fe)

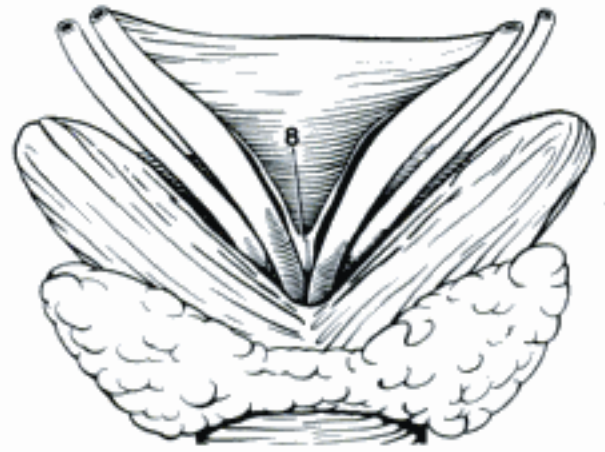


G Penis, transverse section through prepubic tendon, cranial to scrotum (spermatic cords cut obliquely) (eq)

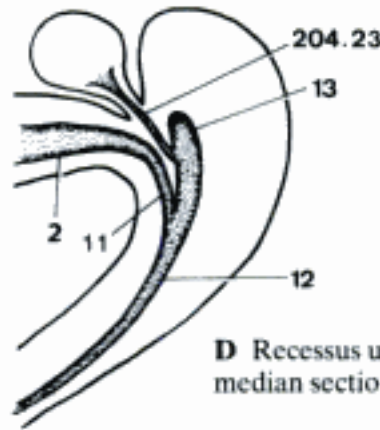
- 1 **Urethra masculina.** Male urethra, excretory passage for urine and semen.
- 2 *Pars pelvina.* Pelvic part. A D
- 3 *Pars preprostatica [prae-].* Part between the bladder and the Prostata, longest in fe. A
- 4 *Pars prostatica.* Part associated with the Prostata. A C
- 5 *Crista urethralis.* Urethral crest, dorsal longitudinal mucosal ridge from the junction of the Plicae uretericae to the Colliculus seminalis. It extends farther caudally in some species. C
- 6 *Colliculus seminalis.* Seminal hillock, an eminence on the Crista urethralis, bearing on each side the Ostium ejaculatorium or separate openings of the Ductus deferens and the excretory duct of the vesicular gland. A
- 7 *Ostium ejaculatorium.* Ejaculatory orifice, the opening of the Ductus ejaculatorius on the Colliculus seminalis. A
- 8 *Uterus masculinus.* Rudimentary male uterus, largest and most constant in eq. The cranial part is often bifurcated and lies in the genital fold between the ampullae. The caudal end may open on the Colliculus seminalis. B
- 9 *Sinus prostaticus.* Recess between the Crista urethralis and the lateral urethral wall where the Ductuli prostatici open. A C
- 10 *Stratum spongiosum.* Spongy layer, cavernous tissue surrounding the pelvic urethra. C F
- 11 *Isthmus urethrae.* Narrow segment of the urethra where it turns around the ischial arch. D
- 12 *Pars penina.* Penile part of urethra. It is surrounded by the Corpus spongiosum. D E
- 13 *Recessus urethralis (su, Ru).* Caudodorsal to the urethra at the Arcus ischiadicus. Opens ventrally into the urethra. D
- 14 *Fossa navicularis urethrae.* Navicular fossa of the urethra, a slight dilatation near the distal end in eq. E
- 15 *Processus urethrae.* Urethral process, free distal part of the urethra. It is longest in ov, cap; absent in fe, su. E
- 16 *Ostium urethrae externum.* External urethral orifice. E
- 17 *Tunica muscularis.* Smooth muscle of the pelvic urethra. It surrounds the Pars disseminata prostatae where that is present, or the Stratum spongiosum. It is not to be confused with the thick, striated M. urethralis external to it. C F
- 18 *Tunica mucosa.* Mucous membrane, covered by transitional epithelium, except near the external orifice, where it becomes stratified squamous. F
- 19 *Lacunae urethrales.* Pockets formed by the surface epithelium. F
- 20 *Gll. urethrales.* Urethral glands, isolated small branched glands in the Pars pelvina in ca, eq, and also in the Pars penina of su, eq. F
- 21 **Scrotum.** Cutaneous pouch containing the testes. G
- 22 *Cutis scroti.* Skin of the scrotum. G
- 23 *Raphe [Rhaphe] scroti.* Median seam of the Cutis scroti. G
- 24 *Tunica dartos.* Layer of smooth muscle in the subcutaneous tissue. It wrinkles the skin. G
- 25 *Septum scroti.* Scrotal septum. Median partition formed by the Tunica dartos. G



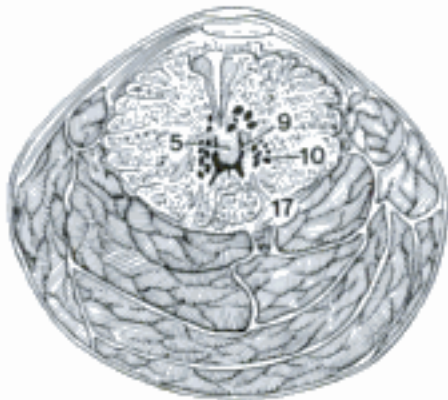
A Pelvic part of urethra, opened ventrally (the bulb of the penis is shown in section at the bottom, and the Trigonum vesicae above) (eq)



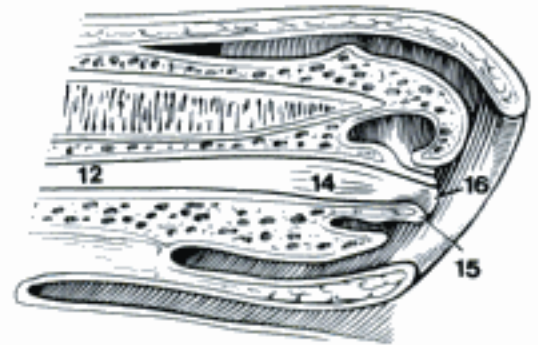
B Uterus masculinus, dorsal aspect (eq)



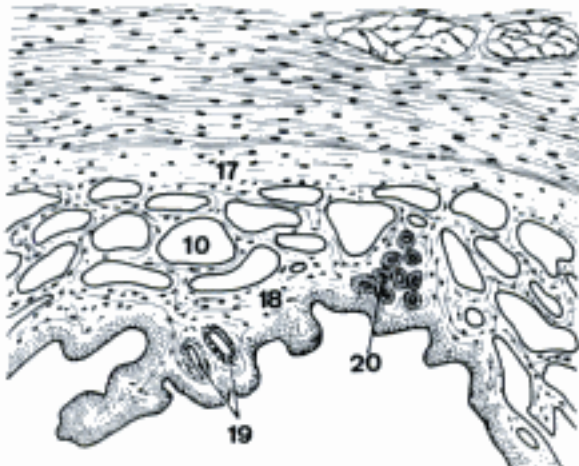
D Recessus urethralis median section (bo) (Garrett)



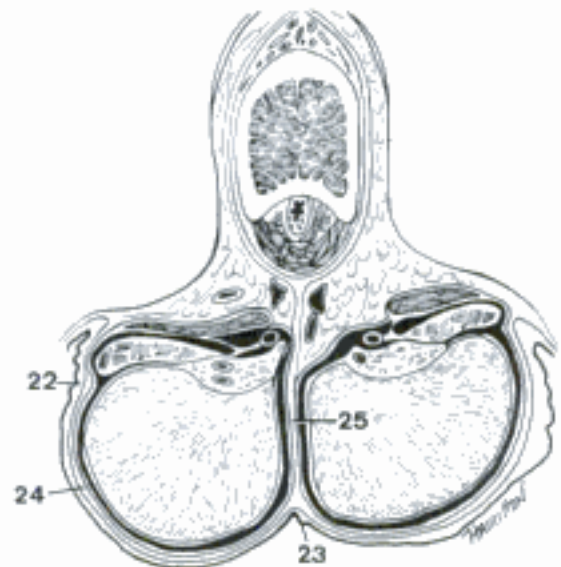
C Prostatic part of urethra, transverse section (M. urethralis is shown on the ventral and lateral surfaces) (bo)



E Penis and prepuce, median section (eq)

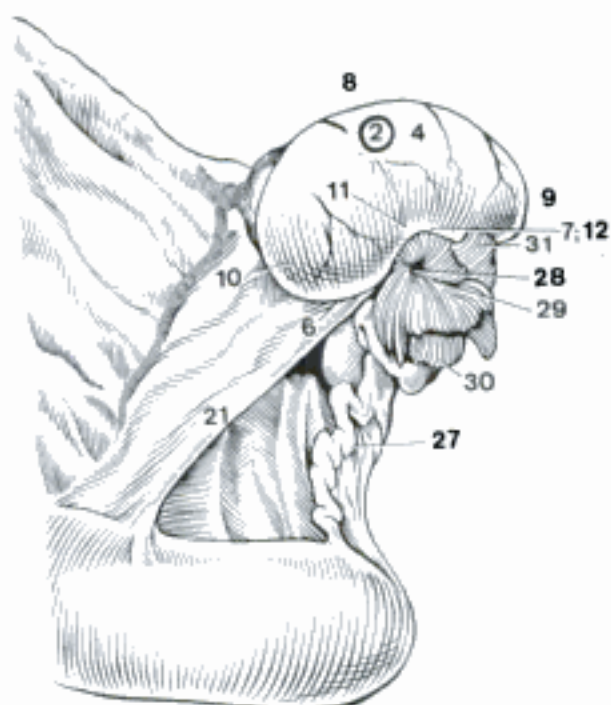


F Pelvic part of urethra, histological section (ca)

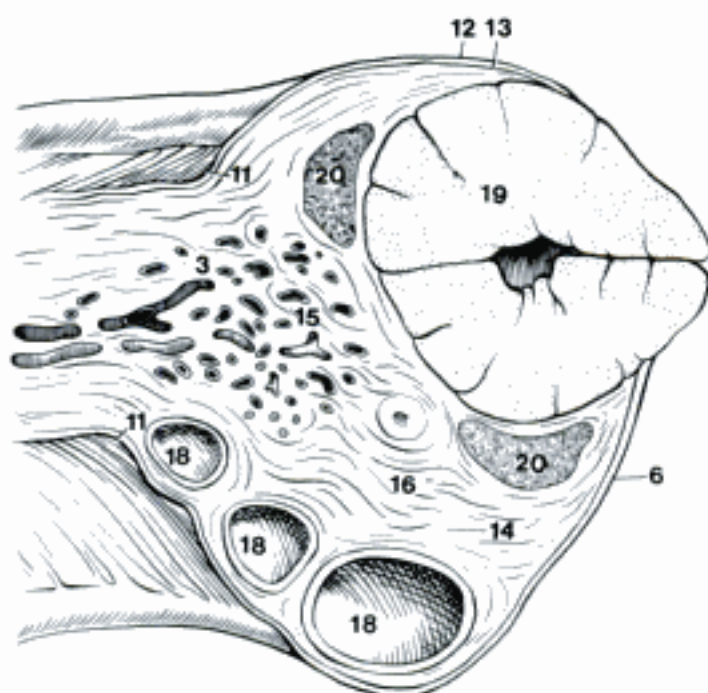


G Scrotum and penis, transverse section, caudal aspect (eq)

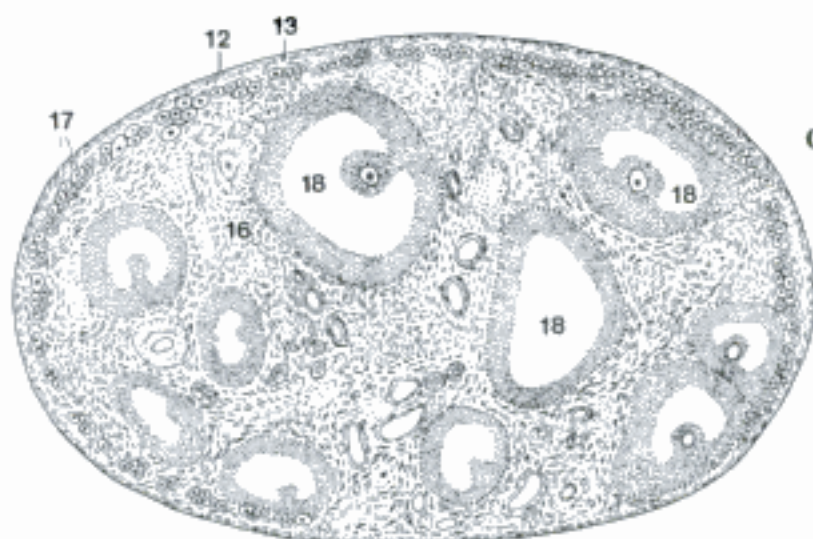
- 1 **ORGANA GENITALIA FEMININA.** Female genital organs.
- 2 **Ovarium.** Ovary. A B C
- 3 *Hilus ovarii.* Hilus of ovary, area of attachment of mesovarium and entrance of ovarian vessels. B
- 4 *Facies medialis.* Medial surface. A
- 5 *Facies lateralis.* Lateral surface.
- 6 *Margo liber.* Free border. A
- 7 *Fossa ovarii (e q).* Ovarian fossa, depression on the free border where ovulation occurs. A
- 8 *Margo mesovaricus.* Mesovarian border. A
- 9 *Extremitas tubaria.* Tubal end, the end nearer to the Infundibulum tubae, opposite to the Extremitas uterina. A
- 10 *Extremitas uterina.* Uterine end, the end attached to the uterus by the proper ligament. A
- 11 *Margo limitans peritonei [peritonaei].* Terminal border of the peritoneum, the line of attachment of the mesovarium to the ovary, also the transition from squamous mesothelium to cuboidal superficial epithelium; in eq, the termination of the Zona vasculosa around the Fossa ovarii. A B
- 12 *Epithelium superficiale.* The superficial epithelium of the ovary in the young animal is cuboidal, and is restricted to the Fossa ovarii in eq. A B C
- 13 *Tunica albuginea.* Dense white capsule of the ovary. B C
- 14 *Cortex ovarii [Zona parenchymatosa].* Although in most species the tissue containing the follicles is peripheral and may be called a cortex, in eq it is central and requires a non-topographic name, parenchymatous zone. B
- 15 *Medulla ovarii [Zona vasculosa].* In eq the vascular zone is peripheral and cannot be called a medulla, as it is in other species. B
- 16 *Stroma ovarii.* Connective tissue of the ovary. B C
- 17 *Folliculi ovarici primarii.* Primary ovarian follicles, consist of an ovocyte surrounded by one or more layers of follicular cells before the appearance of an antrum filled with Liquor folliculi. C
- 18 *Folliculi ovarici vesiculosi.* Vesicular follicles have a fluid-filled cavity that enlarges with maturation. B C
- 19 *Corpus luteum.* Yellow body, developed from cells of the Stratum granulosum and Theca interna after ovulation. B
- 20 *Corpus albicans.* White body remaining after degeneration of a Corpus luteum. The color varies with species. It is red in bo. B
- 21 *Lig. ovarii proprium.* Proper lig. of the ovary, band of connective tissue covered with peritoneum between Extremitas uterina ovarii and the apex of the uterine horn or nearby mesometrium. A
- 22 **Epoöphoron.** Complex of vestigial tubules occasionally giving rise to cysts in the mesovarium and mesosalpinx. D
- 23 *Ductus epoöphori longitudinalis.* Duct of the epoöphoron, the vestige of the cranial part of the mesonephric duct. D
- 24 *Ductuli transversi.* Transverse ductules, remnants of mesonephric tubules which run from the hilus of the ovary through the mesovarium and mesosalpinx to the Ductus epoöphori. D
- 25 *Appendices vesiculosae.* Vesicular appendages, pedunculated cysts near the Infundibulum tubae. D
- 26 **Paroöphoron.** Group of caudal mesonephric tubules in the Mesosalpinx near the Extremitas uterina ovarii. D
- 27 **Tuba uterina.** Uterine tube, the conduit for ova from the ovary to the uterus. A
- 28 *Ostium abdominale tubae uterinae.* Abdominal opening of the uterine tube in the infundibulum. A
- 29 *Infundibulum tubae uterinae.* Funnelshaped ovarian end of the tube. A
- 30 *Fimbriae tubae.* Fringe of processes around the opening of the infundibulum. A
- 31 *Fimbria ovarica.* Ovarian fimbria, attached to the ovary. A



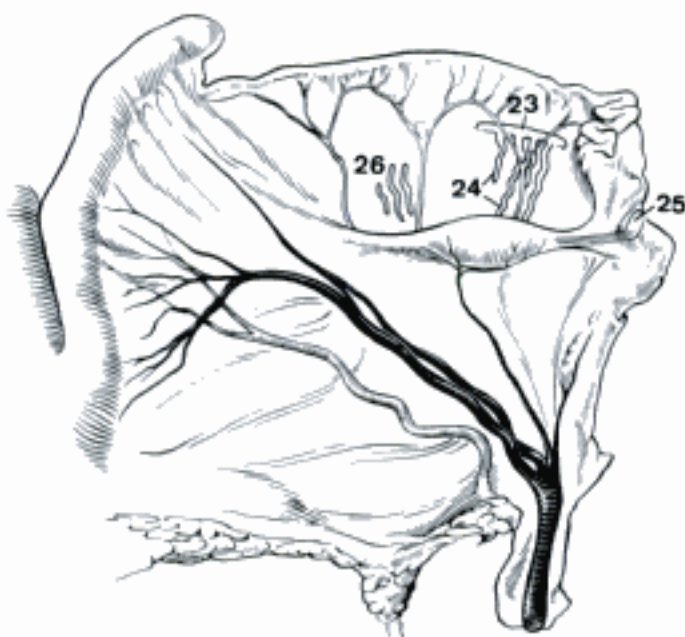A Ovary and ovarian bursa, medial aspect (eq)



B Ovary and mesovarium, gross section (bo)

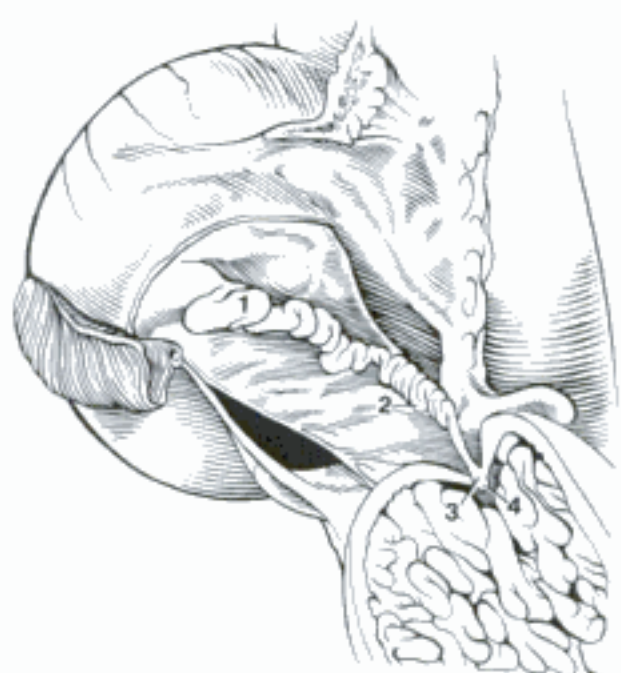


C Ovary, histological section (fc)

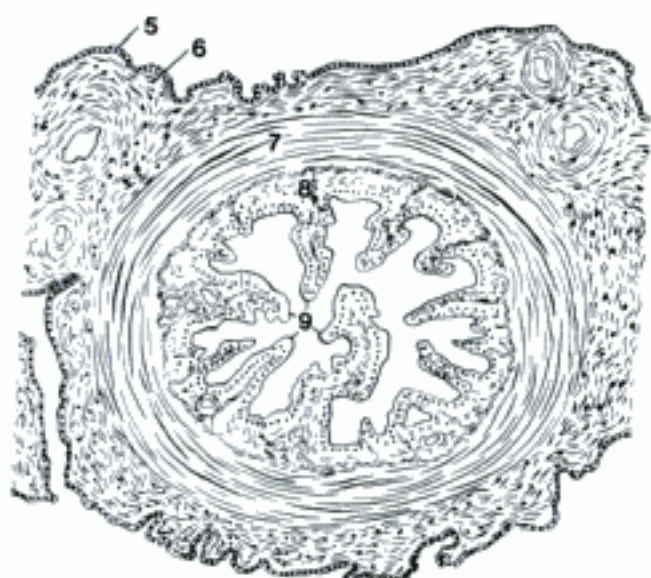


D Right ovary and uterine horn, epoöphoron and paroöphoron, dorsal aspect (ov)

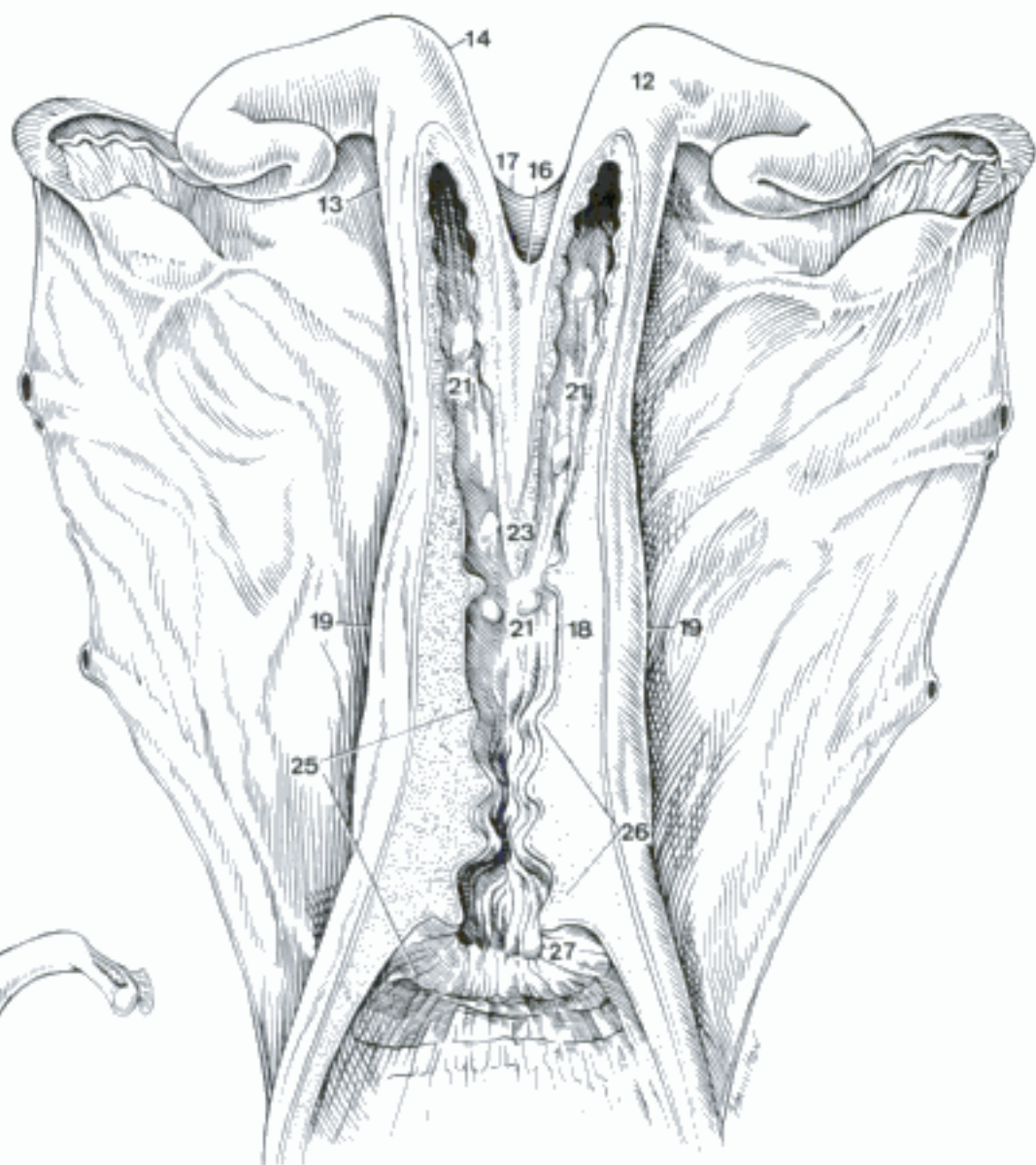
- 1 *Ampulla tubae uterinae*. Relatively wide part from the abdominal opening to the isthmus. A B
- 2 *Isthmus tubae uterinae*. Narrow portion leading to the uterus. A
- 3 *Pars uterina*. Uterine part. In Car, eq, the part of the tube in the wall of the uterus is distinct and ends on a papilla. In su, Ru, the tube is gradually continuous with the uterine horn. A
- 4 *Ostium uterinum tubae*. Uterine orifice of the tube. A
- 5 *Tunica serosa*. Serous coat. B
- 6 *Tela subserosa*. Layer of loose connective tissue under the Tunica serosa. B
- 7 *Tunica muscularis*. Smooth muscle coat. It is thickest in the Pars uterina. B
- 8 *Tunica mucosa*. Mucous membrane lining the tube. B
- 9 *Plicae tubariae*. Tubal folds of mucous membrane. B
- 10 **Uterus**. Womb, organ of gestation. C D
- 11 *Uterus bicornis*. Uterus with two horns and a single body and cervix, as in domestic mammals. C D
- 12 *Cornu uteri [dextrum et sinistrum]*. Right and left horns of the uterus. D
- 13 *Margo mesometricus*. Mesometrial border, the side of the uterine horn attached to the mesometrium. D
- 14 *Margo liber*. Free border, the side of the uterine horn opposite to the mesometrium. D
- 15 *Lig. intercornuale*. Intercornual lig. in ov, cap. Fold of serosa containing smooth muscle, crosses the acute angle between the cornua.
- 16 *Lig. intercornuale dorsale (bo)*. D
- 17 *Lig. intercornuale ventrale (bo)*. D
- 18 *Corpus uteri*. Body of the uterus, undivided part between the cornua and the cervix. D
- 19 *Margo uteri [dexter et sinister]*. Right and left borders of the corpus and cervix to which the mesometrium is attached. D
- 20 *Facies dorsalis*. Dorsal surface. C
- 21 *Cavum uteri*. Cavity of the uterus. D
- 22 *Facies ventralis*. Ventral surface.
- 23 *Velum uteri*. Median partition formed by the fusion of the medial walls of the uterine horns in Car, su, Ru, D
- 24 *Fundus uteri*. Cranial end of the body of the uterus in eq. C
- 25 *Cervix uteri*. Neck of the uterus, thick-walled vaginal end which effects the closure of the uterus. D
- 26 *Portio prevaginalis [prae-] [cervicis]*. Part of the cervix cranial to the vagina. D
- 27 *Portio vaginalis [cervicis]*. Part of the cervix that projects into the vagina. D



A Ovary, uterine tube, and mesosalpinx, lateral surface (uterine horn, lower right, has been opened) (eq)



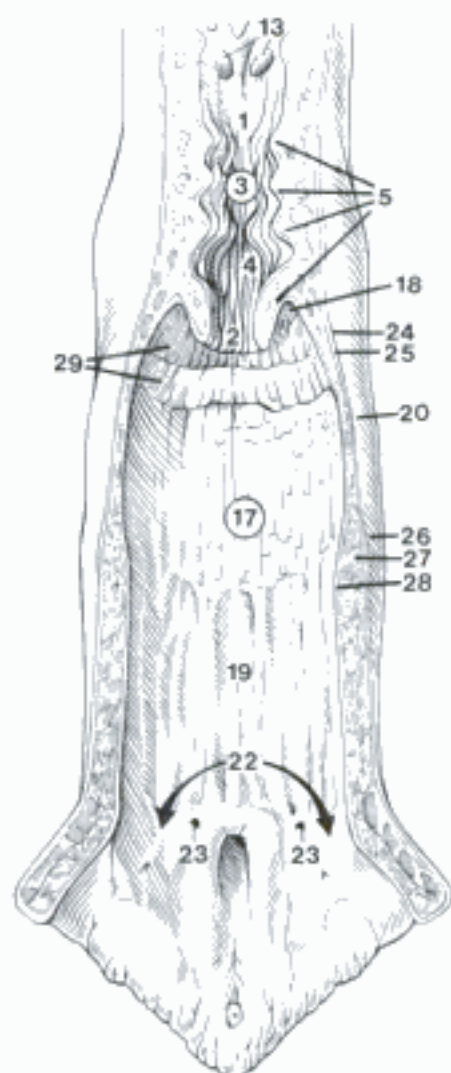
B Ampulla of uterine tube, histological section (bo)



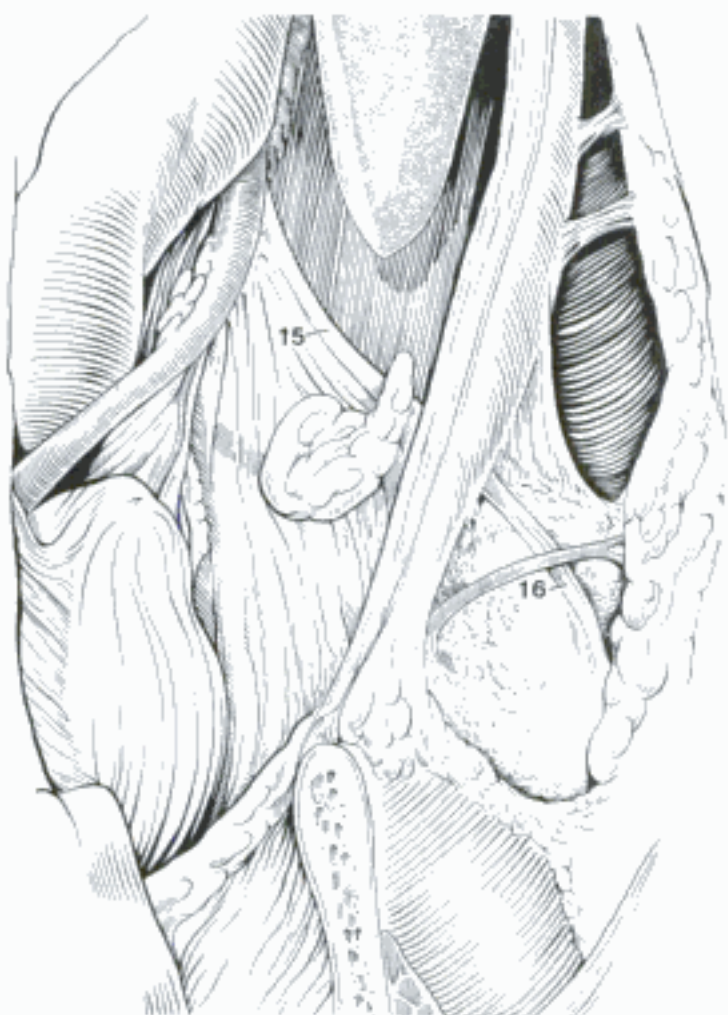C Uterus, dorsal surface (ovaries displaced laterally) (eq)

D Uterus, opened dorsally (bo)

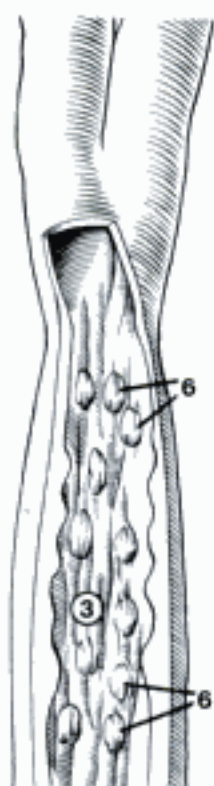
- 1 *Ostium uteri internum*. Internal orifice of the uterus, between the body of the uterus and the cervix. A
- 2 *Ostium uteri externum*. External orifice of the uterus, between the cervix and the vagina. A E
- 3 *Canalis cervicis uteri*. Cervical canal. A C
- 4 *Plicae longitudinales*. Longitudinal folds of cervical mucosa. A
- 5 *Plicae circulares (Ru)*. Circular or crescentic folds of cervical mucosa which close the canal. A
- 6 *Pulvini cervicales (su)*. Cervical cushions, interdigitating processes which close the canal. C
- 7 *Gll. cervicales*. Cervical glands. Simple tubular glands in Car, su, ov, cap, but the cervical mucus is secreted primarily by the epithelium.
- 8 *Parametrium*. Connective tissue, smooth muscle, vessels, and nerves between the peritoneal laminae of the mesometrium. D
- 9 *Tunica serosa [Perimetrium]*. Visceral peritoneum on the uterus. D
- 10 *Tela subserosa*. Layer of loose connective tissue under the Tunica serosa. D
- 11 *Tunica muscularis [Myometrium]*. Smooth muscle of the uterus. The inner, circular and oblique, layer is thick, the outer longitudinal is associated with the perimetrium. A vascular layer separates circular and longitudinal layers. D
- 12 *Tunica mucosa [Endometrium]*. Mucous membrane. It has a thick glandular Lamina propria and is covered by columnar epithelium. D
- 13 *Carunculae*. Caruncles, eminences of the endometrium in Ru. They enlarge in pregnancy and receive the chorionic villi of the cotyledons to form placentomes. A
- 14 *Gll. uterini*. Uterine glands. Branched tubular glands extend through the endometrium. D
- 15 *Lig. teres uteri*. Round ligament of the uterus. It extends from the tip of the uterine horn to the deep inguinal ring, enclosed in a lateral fold of the Lig. latum. B
- 16 *Processus vaginalis peritonei [peritonaei]*. Vaginal process of the peritoneum in the inguinal canal. In males it becomes the Tunica vaginalis after the descent of the testis. In females it persists often in ca, rarely in fe. B
- 17 **Vagina**. Canal from the cervix to the hymen or vestibule. A E
- 18 *Fornix vaginae*. Fornix of the vagina, the cranial blind pouch of the vagina surrounding the Portio vaginalis cervicis. A E
- 19 *Paries ventralis*. Ventral wall of the vagina. A
- 20 *Paries dorsalis*. Dorsal wall of the vagina. A
- 21 *Hymen*. Fold of mucosa just cranial to the transverse plane of the urethral orifice, marking the Ostium vaginae in virgins. It is poorly developed in domestic mammals. E
- 22 *Ostium vaginae*. Opening of the vagina into the vestibule. It is marked by the hymen or a transverse plane just cranial to the urethral orifice. A
- 23 (*Ductus deferens vestigialis*). Remnant of the caudal part of the mesonephric duct, formerly called Gartner's duct. It is often present in the floor of the bovine vagina, opening craniolateral to the urethral orifice. A
- 24 *Tunica serosa*. Peritoneal covering of the cranial end of the vagina. A
- 25 *Tela subserosa*. Loose connective tissue under the serosa. A
- 26 *Tunica adventitia*. Connective tissue covering the retroperitoneal part of the vagina. A
- 27 *Tunica muscularis*. Smooth muscle of the vaginal wall. A
- 28 *Tunica mucosa*. Mucous membrane. The lining epithelium varies from secretory columnar to stratified squamous according to species and stage of the estrus cycle. A
- 29 *Rugae vaginales*. Vaginal ridges, around the cervix in the fornix vaginae of bo. A
- 30 *Lymphonoduli [Noduli lymphatici] vaginales*. In the Lamina propria.



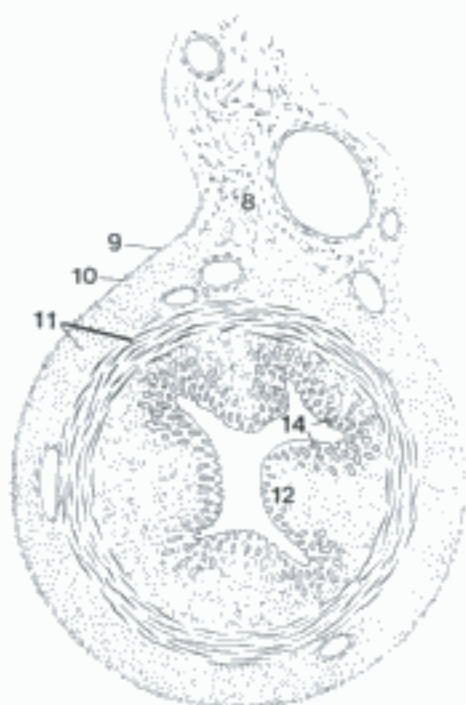
A Cervix and vagina, opened dorsally (bo)



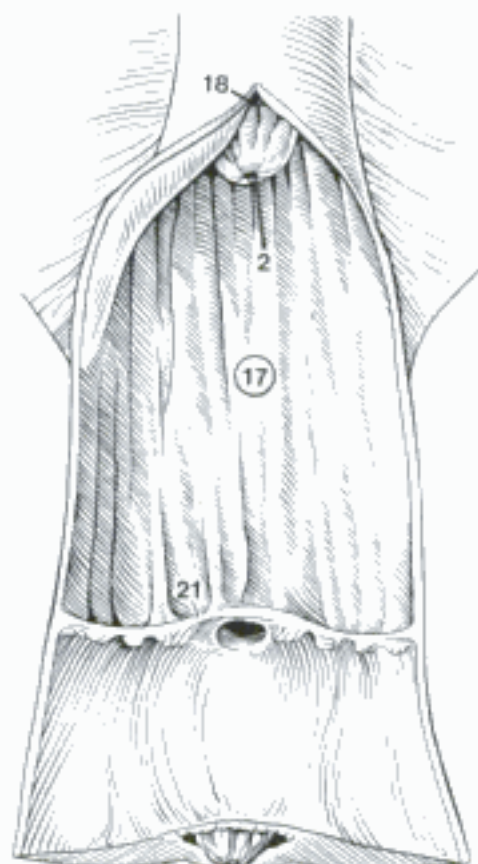
B Left inguinal region (abdomen opened midventrally, mammae and fat separated from the abdominal wall) (ca fem)



C Cervix, opened dorsally (su)

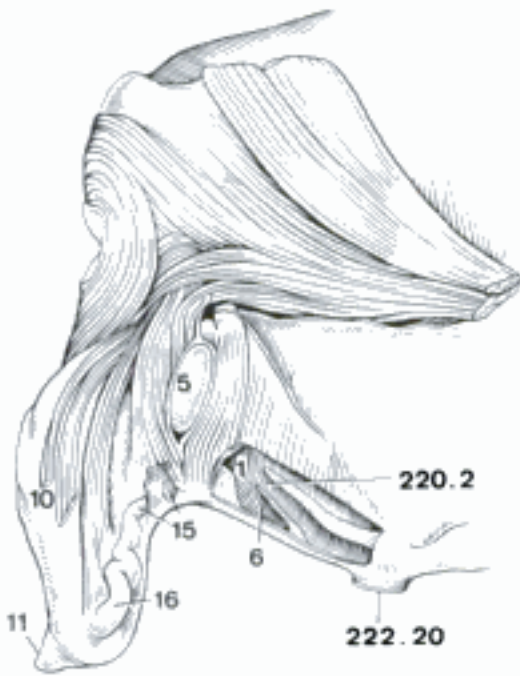


D Uterine horn with mesometrium, histological section (fe)

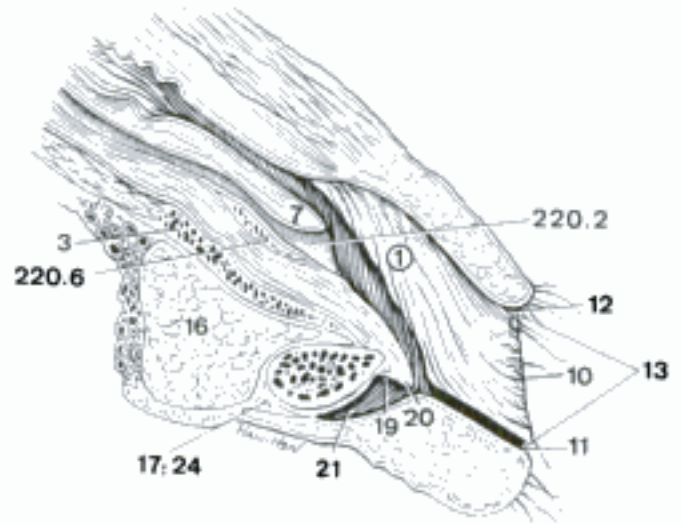


E Vagina and vestibule, opened dorsally (eq)

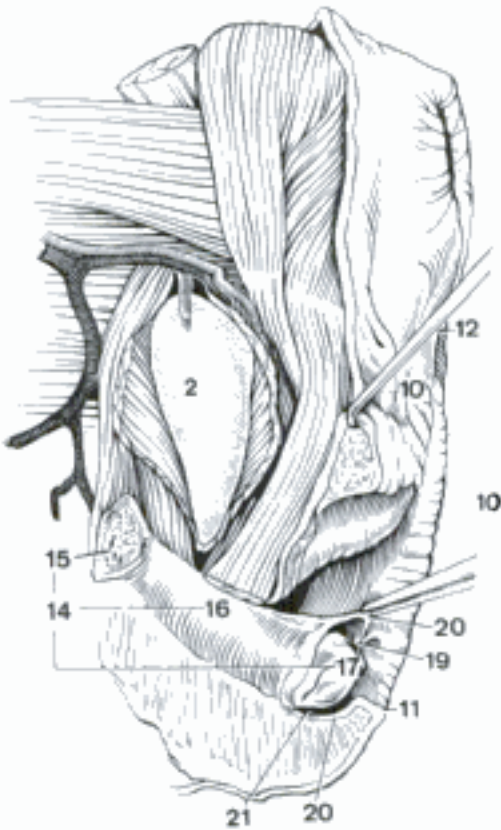
- 1 **Vestibulum vaginae.** Vestibule, the part of the female genital canal from the hymen to the labia. The human vestibule is so shallow that it is included with the external genitalia. In quadrupeds, where it is much deeper (in fe it is about the same length as the vagina) it is not an external organ. A B E
- 2 *Bulbus vestibuli.* Vestibular bulb, cavernous tissue in the lateral wall of the vestibule in ca, eq. C
- 3 *Pars intermedia bulborum.* Commissure of bulbi. B
- 4 *Gll. vestibulares minores.* Minor vestibular gll., microscopic branched tubular glands in the ventral and lateral walls.
- 5 *Gl. vestibularis major.* Major vestibular gland (fe, bo, ov), a lobulated gland cranial to Membrana perinei and M. constrictor vestibuli. The duct opens on the lateral wall of the vestibule. A
- 6 *Diverticulum suburethrale (su, Ru).* Suburethral diverticulum, a blind sac ventral to the urethra and opening into the urethral orifice. A
- 7 *Tuberculum urethrale (ca).* Urethral tubercle, an elevation bearing the urethral orifice. B
- 8 **PARTES GENITALES FEMININAE EXTERNAE.** External female genitalia, the vulva and clitoris. The vestibule in domestic mammals is not considered an external organ.
- 9 **Pudendum Femininum [Vulva].** Labia and their commissures.
- 10 *Labium pudeni [vulvae].* Lip of the vulva. Major and minor labia are not distinguishable in domestic mammals, with the possible exception of Car. The outer surface of the labium is covered with sparsely haired skin, and the inner surface with Tunica mucosa bearing stratified squamous epithelium. A B C D
- 11 *Commissura labiorum ventralis.* Ventral commissure of the labia. A B C D
- 12 *Commissura labiorum dorsalis.* Dorsal commissure of the labia. B C
- 13 *Rima pudendi [vulvae].* Pudendal fissure between right and left labia, the external urogenital opening. B
- 14 **Clitoris.** Rudimentary partial homologue of the penis in the ventral wall of the vestibule. C
- 15 *Crus clitoridis.* Crus of the clitoris. Right and left crura are attached to the ischial arch and join the body of the clitoris. A C
- 16 *Corpus clitoridis.* Body of the clitoris, composed of the fused Corpora cavernosa. It is tortuous in bo. A B C
- 17 *Glans clitoridis.* Glans of the clitoris, best developed in ca and eq. B C D
- 18 *Sinus clitoridis (eq).* Three clitoral sinuses open on dorsal surface of glans, near frenulum. The median sinus occupies the central part of glans. The lateral sinuses are shallow and inconstant. D
- 19 *Frenulum clitoridis.* Median dorsal attachment of glans to vestibular wall of Preputium in ca, eq. In other species the separation of Preputium from glans is insufficient to isolate a Frenulum. B C
- 20 *Preputium [Praeputium] clitoridis.* Prepuce of the clitoris. In domestic mammals the prepuce is formed by the ventral commissure of the labia and by a transverse fold of vestibular mucosa to which the frenulum is attached. B C D
- 21 *Fossa clitoridis.* Fossa of the clitoris, the preputial cavity, it is almost obliterated by adhesion of the prepuce to the glans in fe, su, Ru. B C D
- 22 *Corpus cavernosum clitoridis.* Cavernous body of the clitoris. Right and left cavernous bodies are fused to form the body of the clitoris. In ca most of the erectile tissue is replaced by fat. In fe it contains a cartilage corresponding to the Os penis. In Un it is mostly fibrous. E
- 23 *Septum corporum cavernosorum.* Partial septum between the cavernous bodies. E
- 24 *Corpus spongiosum glandis (ca, eq).* Spongy body of the glans, continuous with the Pars intermedia bulborum. B
- 25 *Fascia clitoridis.* Fascia of the clitoris. E



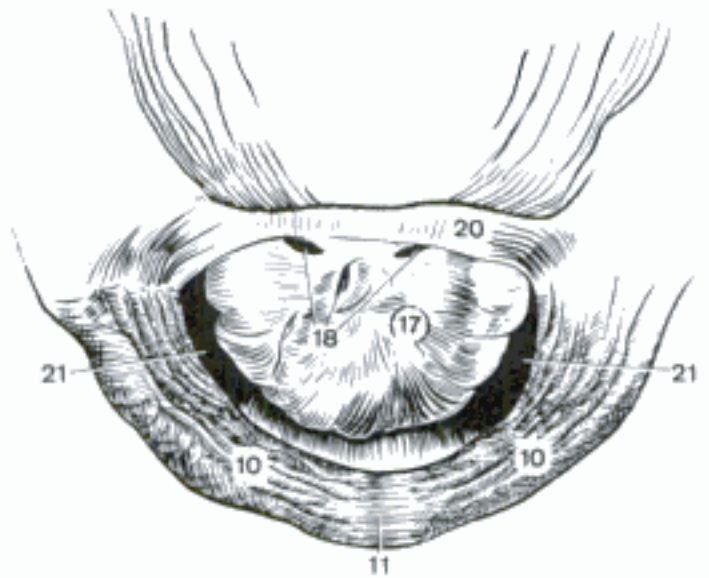
A Female genital organs (lateral wall fenestrated) (bo)



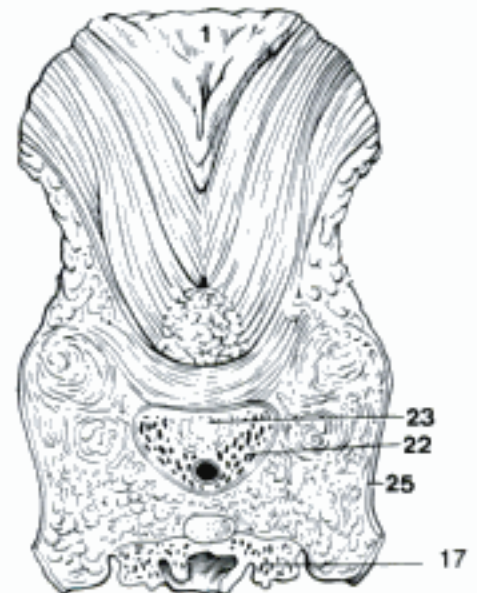
B Female genital organs, median section (ca)



C Female genital organs, left lateral aspect (ventral part of left labium removed and M. constrictor vestibuli cut to expose 2) (eq)

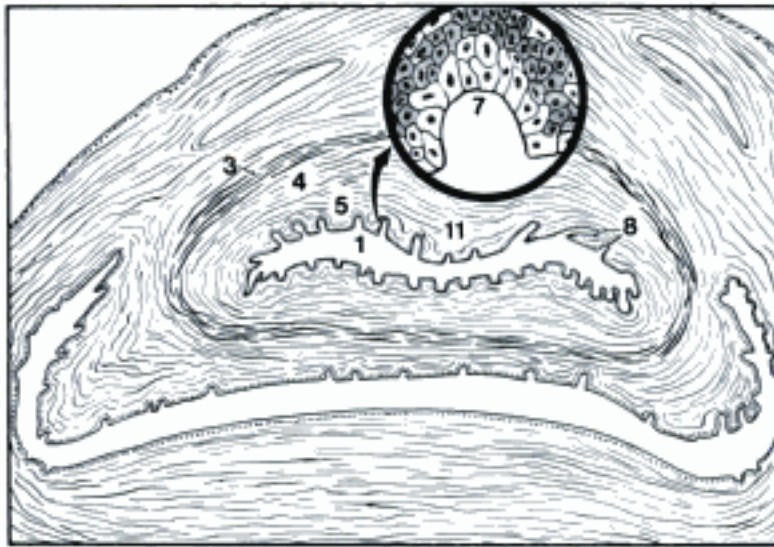


D Glans clitoridis (eq) (De Schaepdrijver, et al.)

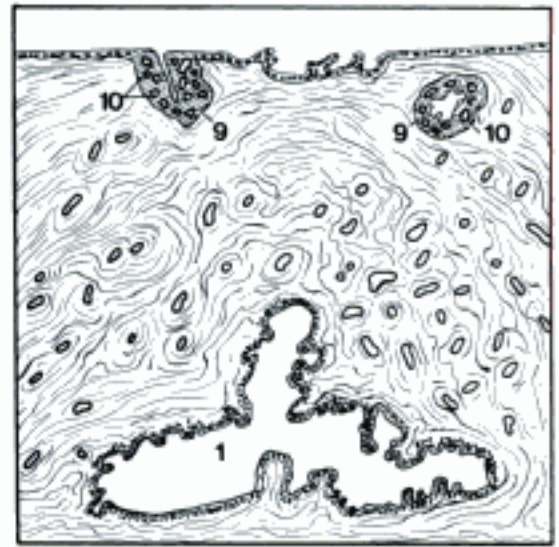


E Corpus clitoridis, transverse section ventral to vestibule (17 is the ventral process of the glans) (eq)

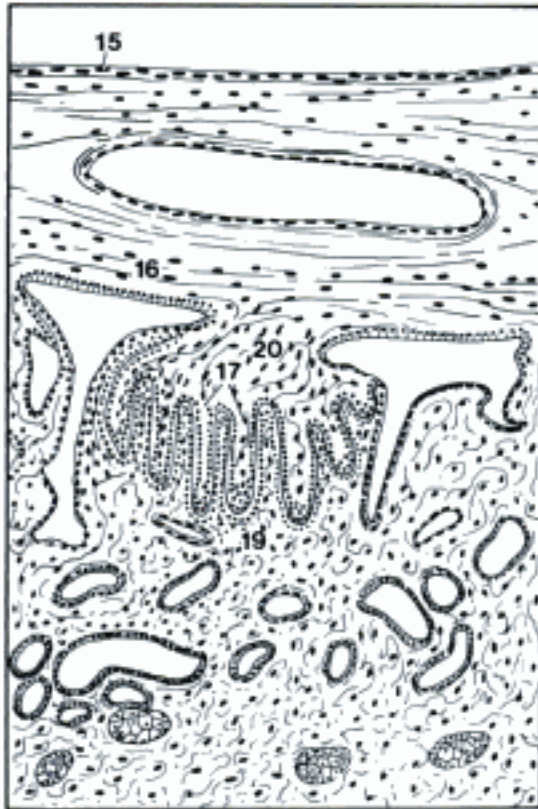- 1 **Urethra Feminina.** Female urethra, corresponds to the male preprostatic part. A B
- 2 *Ostium urethrae externum.* External urethral orifice. 219 A
- 3 *Tunica adventitia.* Loose connective tissue covering the urethra. A
- 4 *Tunica muscularis.* Muscular coat, smooth muscle of the wall. A
- 5 *Tunica mucosa.* Mucous membrane, lined by stratified epithelium, squamous at the end, cuboidal to columnar in the middle, transitional near the bladder. A
- 6 *Stratum spongiosum.* Spongy layer, cavernous tissue around the urethra. 219 B
- 7 *Gll. urethrales.* Urethral glands in bo, may open either on the surface or into a lacuna. A
- 8 *Lacunae urethrales.* Tubular evaginations of the surface epithelium in su, bo, eq. A
- 9 (*Ductus paraurethrales*). Paraurethral ducts in fe, su, ov, blind epithelial tubules, 1–2 cm long, in the angle between the urethra and the vagina. In fe, su, they are the ducts of small paraurethral glands, which are absent in ov. They open near the urethral orifice. B
- 10 (*Gll. paraurethrales*). Paraurethral glands, appended to the paraurethral ducts in fe, su. B
- 11 *Crista urethralis.* Urethral crest, dorsal longitudinal mucosal ridge extending from the junction of the Plicae uretericae caudally to the middle of the urethra. A
- 12 **TERMINI ONTOGENETICI.** Developmental terms.
- 13 *Membranae fetales.* Fetal membranes. D E
- 14 *Amnion.* Inner membrane, separated from the fetus only by amniotic fluid, lined by ectoderm. D E
- 15 *Allantois.* Fluid-filled sac which completely separates the Amnion from the chorion in Car, eq, but only partially in su, Ru. It communicates through the urachus with the bladder, and is lined by endoderm. Its covering of visceral mesoderm fuses with the chorion where they are in contact. C D
- 16 *Chorion.* Outer membrane, composed of an outer layer of trophoblast and an inner layer of somatic mesoderm. C D E
- 17 *Villi chorii.* Chorionic villi, vascular processes which penetrate the uterine part of the placenta to varying degrees in different species. C
- 18 *Placenta.* Organ of interchange between dam and fetus. C D E
- 19 *Pars uterina.* Uterine part, the layers of endometrium incorporated in the placenta. C
- 20 *Pars fetalis.* Fetal part, the portions of the fetal membranes incorporated in the placenta. C
- 21 *Placenta diffusa.* Diffuse placenta. The chorion is covered everywhere except the tips of the sac by villi (eq) or a network of short folds (su). C
- 22 *Placenta multiplex.* Cotyledonary placenta in Ru. The chorionic villi are concentrated in areas called cotyledons opposite the uterine caruncles. D
- 23 *Placentomus.* Placentome (from tomus, a part), one of the parts of a cotyledonary placenta, composed of a cotyledon and a caruncle. D
- 24 *Caruncula.* Caruncle, a non-glandular knob on the endometrium which enlarges in gestation and is invaded by the villi of a cotyledon to form a placentome. D
- 25 *Cotyledon.* Mass of chorionic villi which invade a caruncle to form a placentome. D
- 26 *Placenta zonaria.* Zonary placenta (Car), restricted to a belt around the middle of the chorionic sac. E
- 27 *Funiculus umbilicalis.* Umbilical cord. D
- 28 *Mesonephros.* Embryonic excretory organ, gives rise to the Ductuli efferentes testis and various vestigial tubules. F
- 29 *Ductus mesonephricus.* Mesonephric duct, gives rise to Ductus epididymidis, Ductus deferens, and various vestigial tubules. F
- 30 *Ductus paramesonephricus.* Paramesonephric duct, gives rise to uterine tube and horn, fuses with the contralateral duct to body of uterus and vagina. F
- 31 *Sinus urogenitalis.* Urogenital sinus, the ventral part of the cloaca after it is separated from the rectum. F



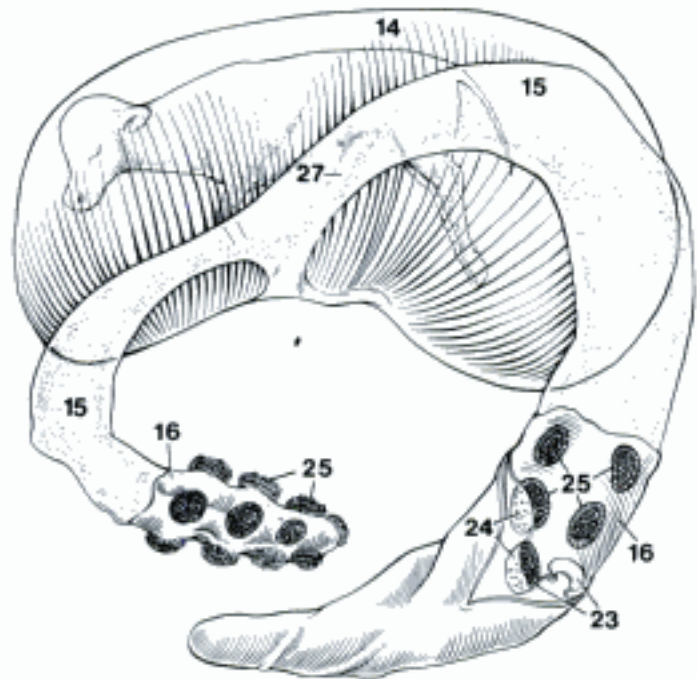
A Female urethra, transverse section (above the urethra the vestigial deferent ducts, and below the suburethral diverticulum (bo) (Schmaltz)



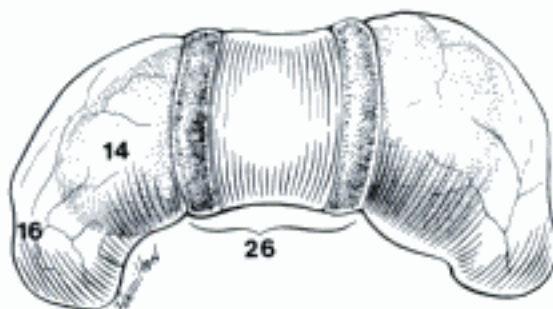
B Female urethra, transverse section (vaginal mucosa above) (su)



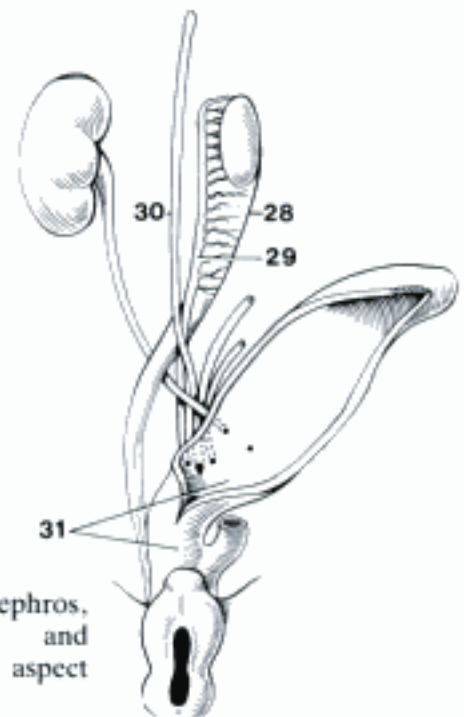
C Placenta diffusa, schematic histological section (eq) (Zietzschmann and Krölling)



D Placenta multipex (uterus removed, except the end of the non-gravid horn. Two cotyledons partly separated from their caruncles) (bo)



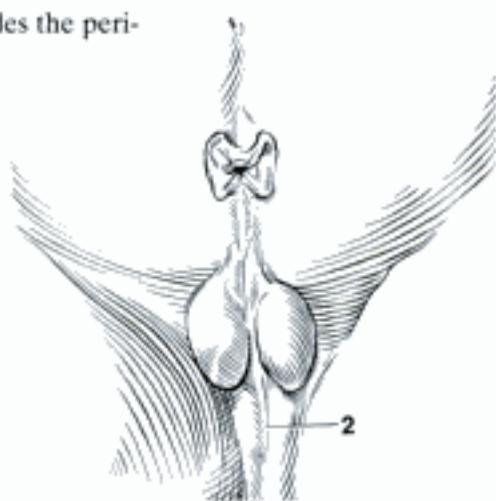
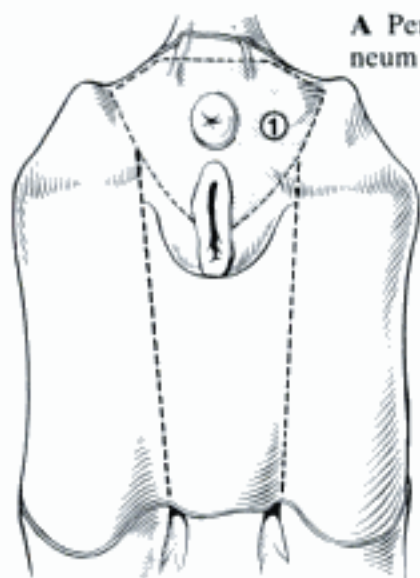
E Placenta zonaria (ca)



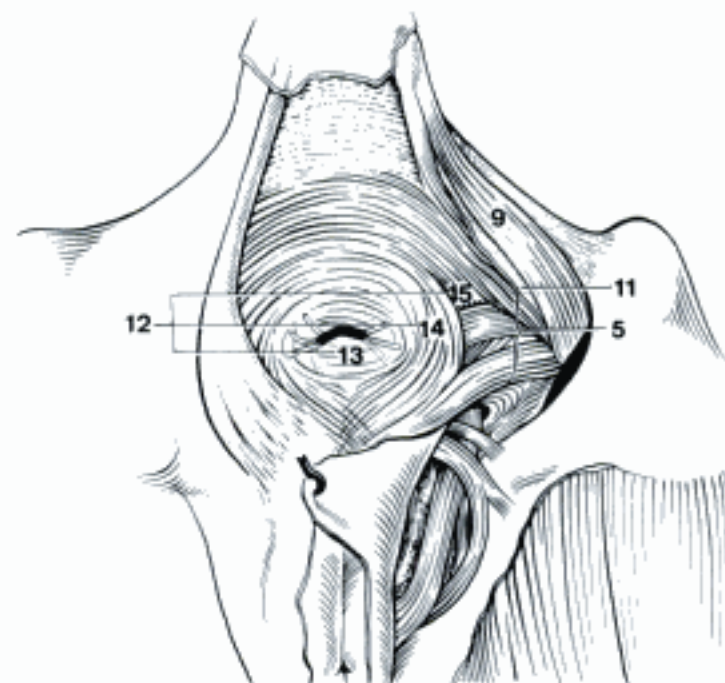
F Right metanephros, mesonephros, and cloaca, ventral aspect (Hertwig)

- 1 **PERINEUM.** Part of the body wall that closes the Apertura pelvis caudalis and surrounds the anal and urogenital canals. A
- 2 *Raphe [Rhaphe].* Median cutaneous seam prolonging the Raphe scroti on the perineum in eq. B
- 3 *Musculi perinei.* Muscles of the perineum.
- 4 *Diaphragma pelvis.* Pelvic diaphragm, composed of M. levator ani and M. coccygeus and the internal and external fasciae. C
- 5 *M. levator ani.* Lateral to the rectum, medial to M. coccygeus. Car: divided into Mm. iliocaudalis and pubocaudalis. Un: O: Spina ischiadica or Lig. sacrotuberale latum. T: M. sphincter ani externus, in su also caudal vertebrae 2–5. C E F
- 6 *M. iliocaudalis [-coccygeus] (Car).* O: Corpus ossis ilii. T: caudal vertebrae 1–3 in fe, 3–7 in ca; also M. sphincter ani externus by means of the fascia. D
- 7 *M. pubocaudalis [-coccygeus] (Car).* O: Ramus cranialis ossis pubis, Symphysis pelvina. T: caudal vertebrae 1–3 in fe, 3–7 in ca; also M. sphincter ani externus by means of the fascia. D
- 8 (*Arcus tendineus m. levatoris ani*). Tendinous arch of M. levator ani, reinforcement of the Fascia obturatoria extending from the caudal end of the Symphysis pelvina to the Spina ischiadica at the origin of M. levator ani in Ru, eq. E
- 9 *M. coccygeus.* O: Spina ischiadica. T: caudal vertebrae 1–4. C E
- 10 *Fascia diaphragmatis pelvis interna.* Medial to Mm. coccygeus and levator, at their borders joining the external fascia, caudally reflected on the rectum. E
- 11 *Fascia diaphragmatis pelvis externa.* Lateral to Mm. coccygeus and levator, at their borders joining the internal fascia, dorsally continuous with the deep caudal fascia. C
- 12 *M. sphincter ani externus.* External anal sphincter, striated muscle surrounding the M. sphincter ani internus. C
- 13 *Pars cutanea.* Cutaneous part, thin fiber-bundles passing dorsoventrally around the anus or radially. C
- 14 *Pars superficialis.* Superficial part, main part in Un, with the most circular fibers. Many fiber bundles pass through a ventral decussation into M. constrictor vulvae, or end on M. bulbospongiosus in the male. In eq divided into a large circular caudal portion and a small, paired cranial portion. C F
- 15 *Pars profunda.* Deep part, intimately associated or continuous with the M. levator ani. C
- 16 *Fascia pelvis.* Pelvic fascia, in the pelvic cavity. E
- 17 *F. pelvis parietalis.* Parietal pelvic fascia, lining the walls of the pelvic cavity, includes Fascia diaphragmatis pelvis interna and Fascia obturatoria. E
- 18 *Fascia obturatoria.* On the dorsal surface of M. obturatorius internus in Car and eq, Pars pelvina of M. obturatorius externus in su and Ru. E
- 19 *Arcus tendineus fasciae pelvis.* Tendinous arch of the pelvic fascia, indistinct zone on the Fascia diaphragmatis pelvis interna along the ventral border of M. levator ani where the Septum rectovaginale is attached in Ru, eq. E
- 20 *Lig. pubovesicale.* From Symphysis pelvina to Cervix vesicae. 219 A
- 21 *F. pelvis visceralis.* Covering the pelvic organs. E
- 22 *Fascia prostatae.* Prostatic fascia, covering the prostate.
- 23 *Septum rectovaginale.* Attached laterally to the Arcus tendineus fasciae pelvis extending in a dorsal plane between rectum and vagina. E
- 24 *Septum perineale.* Quadrilateral sheet of fascia in eq. From the dorsal surface of the vestibule deep to the M. constrictor vulvae, it extends dorsocranially to the Pars rectalis m. retractoris clitoridis and the rectum. The ventral part of the M. levator ani is attached to its craniolateral angle, the M. constrictor vestibuli originates from its lateral border. F

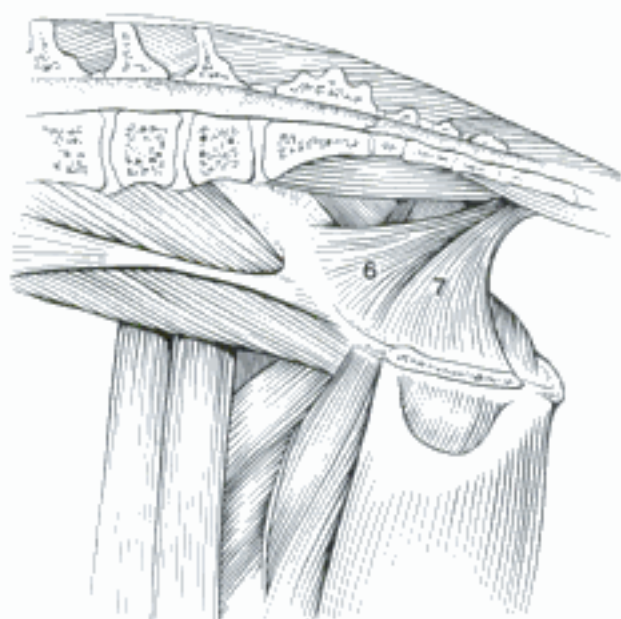A Perineum (gray; perineal region includes the perineum and extends to the udder) (bo)



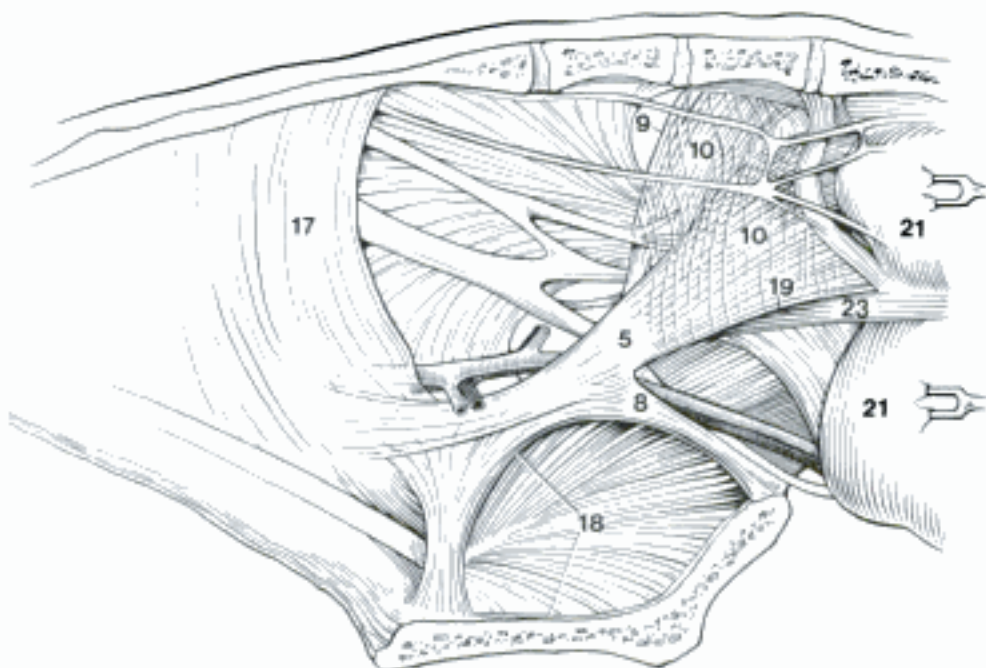
B Male genitalia, ventral surface (eq)



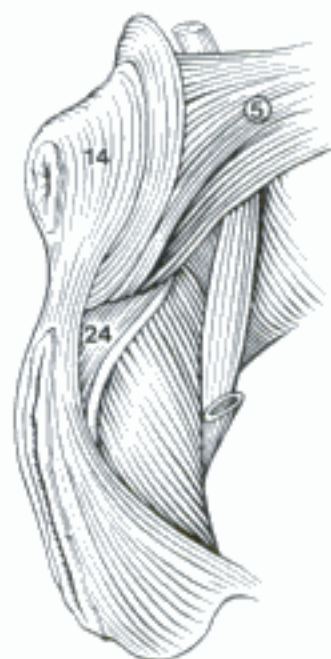
C Pelvic diaphragm (bo)



D Pelvic wall, medial aspect (ca)
(Nickel, et al., 1954)

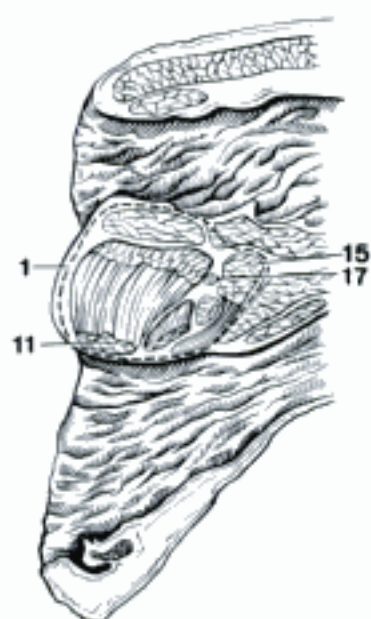


E Fascia pelvis, medial aspect (rectum and vagina reflected caudally, 17 and 18 partly removed) (bo)

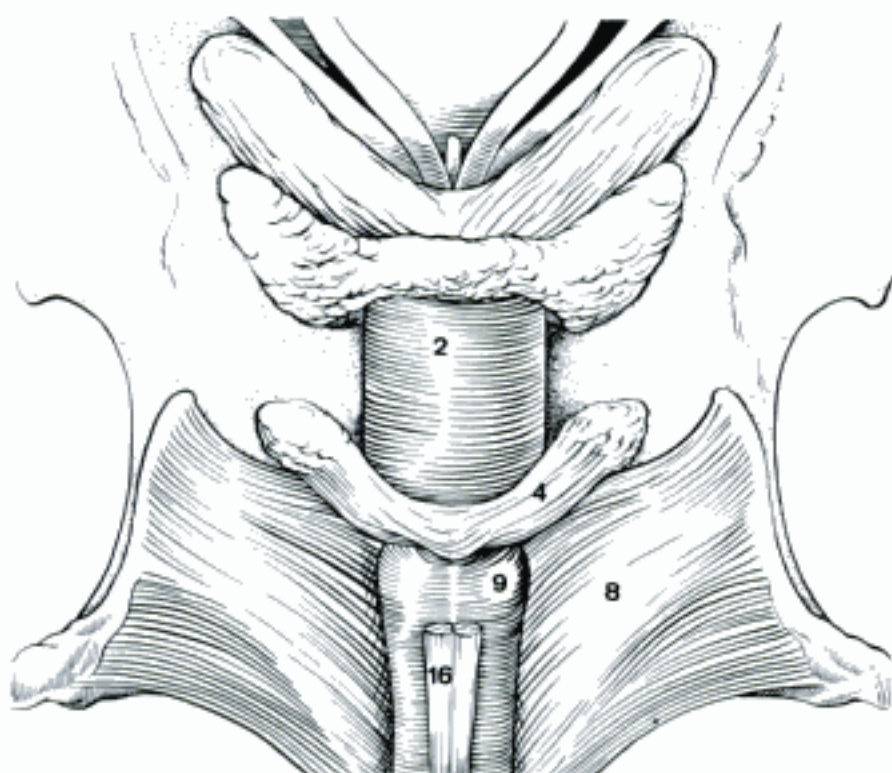


F Perineal muscles, caudolateral aspect (eq)

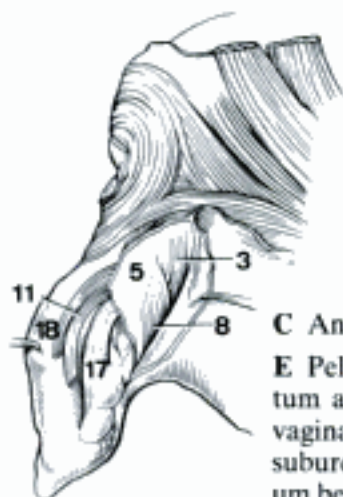
- 1 *Centrum tendineum perinei* [*Corpus perineale*]. Tendinous center of the perineum [perineal body]. Fibromuscular node between anus and vulva or the Bulbus penis, where are attached: Mm. sphincter ani externus, bulbospongiosus, levator ani, and transversus perinei superficialis. A D
- 2 *M. urethralis*. Striated muscle of pelvic urethra, which it surrounds in male. In female originates from sides of vagina and forms a sling ventral to urethra. B E
- 3 *M. ischiourethralis*. O: Arcus ischiadicus. T: in ca, on Lig. transversum perinei. Compresses V. dorsalis penis. In the mare it terminates on dorsolateral wall of vagina; in other Un, on M. urethralis. Lies between Fascia pelvis parietalis and Membrana perinei. C
- 4 *M. bulboglandularis*. Striated muscle on Gl. bulbourethralis (male) or Gl. vestibularis major (female). B
- 5 *Membrana perinei*. Perineal membrane. Deep perineal fascia that closes the urogenital triangle between Arcus ischiadicus and Diaphragma pelvis. Attached to male urethra or Vestibulum vaginae between M. urethralis and M. bulbospongiosus. C D
- 6 *Lig. transversum perinei*. Transverse perineal ligament. Ventral band of Membrana perinei attached to Ossa ischii across Symphysis ischiadica.
- 7 *M. transversus perinei superficialis*. Rudimentary band of muscle in Ru, eq. O: fascia in the region of the Tuber ischiadicum. T: Centrum tendineum perinei. D
- 8 *M. ischiocavernosus*. O: Tuber ischiadicum in male, Arcus ischiadicus in female. T: Corpus penis at junction of crura, encloses Crus penis. It is rudimentary in female. B C
- 9 *M. bulbospongiosus*. Formerly M. bulbocavernosus. O: Tunica albuginea lateral to Corpus spongiosum penis, which is compressed by the muscle. T: median septum. B F. In female domestic mammals, because of the elongated vestibule, M. bulbospongiosus is divided into the following two muscles.
- 10 *M. constrictor vestibuli*. O: in Car, ov, cap, from M. sphincter ani externus; in bo, eq, from ventral border of M. levator ani; in eq, also from Septum perineale and M. retractor clitoridis. T: an aponeurosis joins right and left muscles ventral to the vestibule. Other attachments are vestibule, clitoris, and urogenital diaphragm, depending on species. D
- 11 *M. constrictor vulvae*. Striated muscle in the labium. O: superficial part of M. sphincter ani externus. T: labium and, in Ru, eq, perineal fascia ventrolateral to vulva. A C D
- 12 *M. retractor penis*. Predominantly smooth. O: caudal vertebrae 1–4, depending on species; sacrum in su. Passes ventrally between rectum and M. levator ani. F
- 13 *M. retractor clitoridis*. See 12. In su the vertebral origin is absent, Pars clitoridea originates from the rectum. D
- 14 *Pars analis*. Anal part, caudal portion inserted dorsally and laterally on and under anal sphincters in Car. F
- 15 *Pars rectalis*. Rectal part, cranial portion inserted on lateral wall of rectum. Absent in sow, and sometimes in ca, in eq it joins contralateral muscle ventral to rectum, and was formerly known as suspensory lig. of the anus. A F
- 16 *Pars penina*. Penile part, runs on urethral surface of the penis, except across Flexura sigmoidea in su, Ru. B F
- 17 *Pars clitoridea*. Clitoridean part, absent in ca. Passes deep to M. constrictor vestibuli to reach the labium and (exc. eq) the clitoris. A C D
- 18 *Fascia perinei superficialis*. Superficial fascia of the perineal region. C
- 19 *M. longitudinalis perinei cutaneus*. Fine fiber bundles that extend from anus to vulva just under the skin.
- 20 *M. sphincter labiorum cutaneus*. Cutaneous sphincter of the labia. It lies between M. constrictor vulvae and skin.
- 21 *Fossa ischiorectalis*. Ischiorectal fossa, fat-filled space between Diaphragma pelvis medially, Lig. sacrotuberale laterally, Fascia obturatoria ventrally. D E
- 22 *Corpus adiposum fossae ischiorectalis*. Fat pad of ischiorectal fossa. E
- 23 *Canalis pudendalis*. Pudendal canal, fascial conduit in Fossa ischiorectalis for internal pudendal vessels and the pudendal nerve. E



A Anus, perineal body, and vulva, median section (eq)

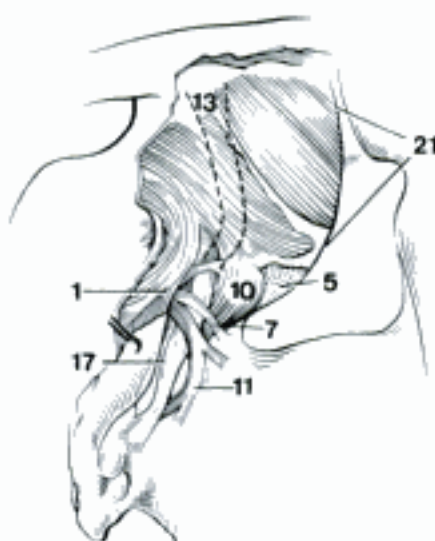


B Pelvic part of urethra and root of the penis, dorsal surface (eq) (Nickel, et al., 1979)

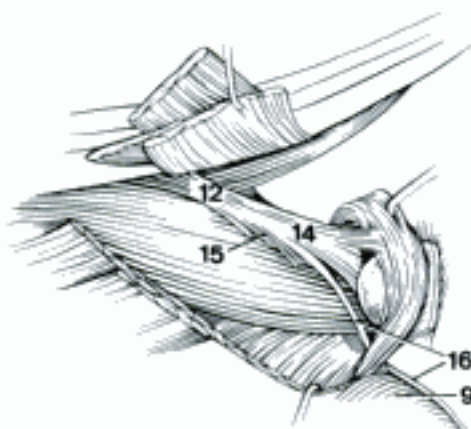
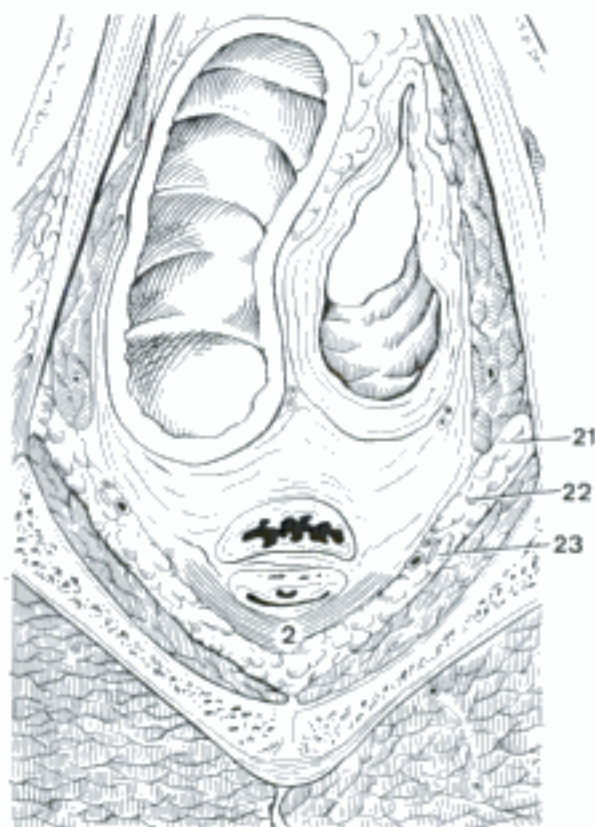


C Anus and vulva, right side (bo)

E Pelvic cavity (rectum and cecum above; vagina, urethra, and suburethral diverticulum below) (bo fem)

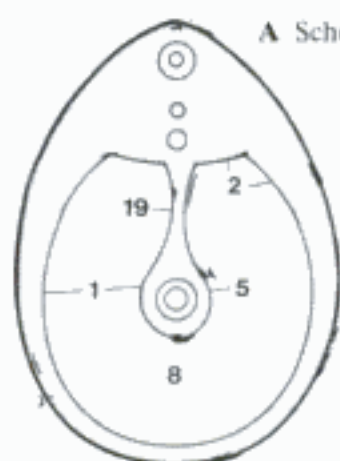


D Perineum, caudolateral aspect (bo fem)



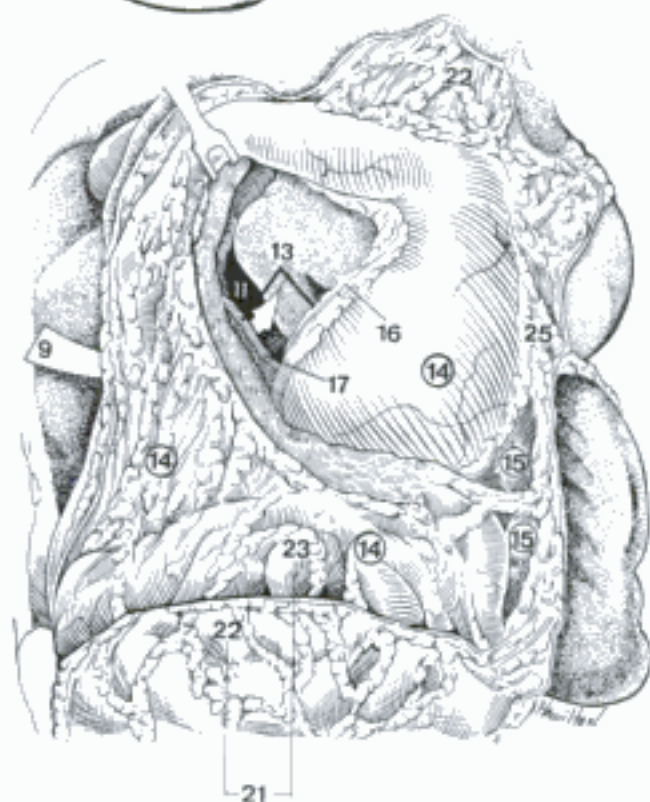
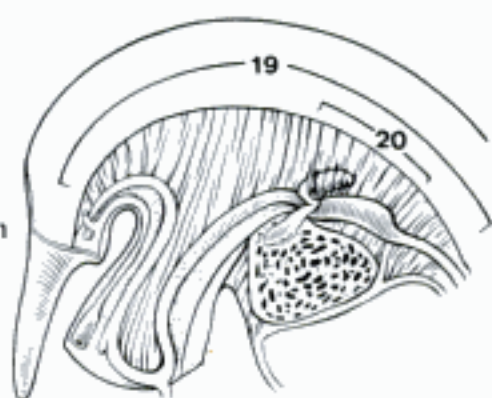
F Perineal muscles, lateral aspect (muscles of pelvic diaphragma transsected and retracted) (ca) (Miller, et al.)

- 1 **PERITONEUM [PERITONAEUM]**. Serous membrane lining the abdominal, pelvic, and scrotal cavities, and covering the organs contained therein. A
- 2 *Peritoneum [Peritoneum] parietale*. Serous membrane on the walls of the above cavities. A
- 3 *Tunica serosa*. Serous membrane, composed of a layer of mesothelium and a layer of connective tissue.
- 4 *Tela subserosa*. Layer of loose connective tissue and fat present under the serosa in certain areas.
- 5 *Peritoneum [Peritoneum] viscerale*. Serous membrane covering the organs. A
- 6 *Tunica serosa*. See 3.
- 7 *Tela subserosa*. See 4.
- 8 *Cavum peritonei [peritoneaei]*. Peritoneal cavity, the potential space containing peritoneal fluid between the parietal and visceral peritoneum. A
- 9 *Foramen omentale [epiploicum]*. Omental [epiploic] foramen, opening from the greater peritoneal sac to the Vestibulum bursae omentalis. It passes between V. cava caudalis and V. portae. C D
- 10 *Bursa omentalis*. Omental bursa, lesser peritoneal sac, the potential space enclosed by the two omenta, the stomach and the liver. C E
- 11 *Vestibulum bursae omentalis*. Vestibule of the omental bursa, enclosed by Omentum minus, stomach and liver. C D E
- 12 *Recessus dorsalis omentalis*. Dorsal omental recess. A minor diverticulum of the vestibule between right crus of the diaphragm and liver, and between esophagus and Vena cava caudalis. D
- 13 *Aditus ad recessum caudalem*. Opening to caudal recess from vestibule. It is bounded by Plica gastropancreatica, Plica hepatopancreatica, Curvatura ventriculi minor, and duodenum. C D E
- 14 *Recessus caudalis omentalis*. Caudal omental recess, cavity enclosed by the Omentum majus. C E
- 15 *Recessus lienalis*. Splenic recess, the left extremity of the Bursa omentalis, enclosed by the Ligg. gastrophrenicum, gastrolienale, and phrenicolienale. C
- 16 *Plica gastropancreatica*. Fold of the wall of the bursa containing left gastric vessels. C D
- 17 *Plica hepatopancreatica*. Fold of the wall of the bursa containing A. hepatica. C D
- 18 *Recessus supraomentalis*. Supraomental recess (Ru), the part of the peritoneal cavity dorsal to the Omentum majus. It contains the intestinal mass. E
- 19 *Mesenterium dorsale primitivum (ont)*. Primitive dorsal mesentery, double peritoneal sheet connecting dorsal body wall to the gut. A B
- 20 *Mesogastrium dorsale (ont)*. Dorsal mesogastrium, the primordium of the Omentum majus. B
- 21 *Omentum majus [Epiploön]*. Greater omentum, peritoneal sac between intestines and ventral abdominal wall, encloses the Recessus caudalis omentalis. C E
- 22 *Paries superficialis*. Superficial wall, part of the Omentum majus from Curvatura ventriculi major to the caudal reflection. C E
- 23 *Paries profundus*. Deep wall, from its dorsal attachment to the caudal reflection. C E
- 24 *Lig. gastrophrenicum*. Gastrophrenic lig., part of the Omentum majus, extends from the diaphragm to the fundus of the stomach. D
- 25 *Lig. gastrolienale*. Gastrosplenic lig., part of the Omentum majus between stomach and spleen. C D
- 26 *Lig. phrenicolienale [lienorenale]*. Phrenicosplenic lig., part of the Omentum majus from the diaphragm to the spleen. In eq its ventral portion is attached to the left kidney. D
- 27 *Velum omentale (ca)*. This sagittal membrane connects Paries profundus of Omentum majus with the left surface of Mesocolon descendens. It has a free caudal border. D

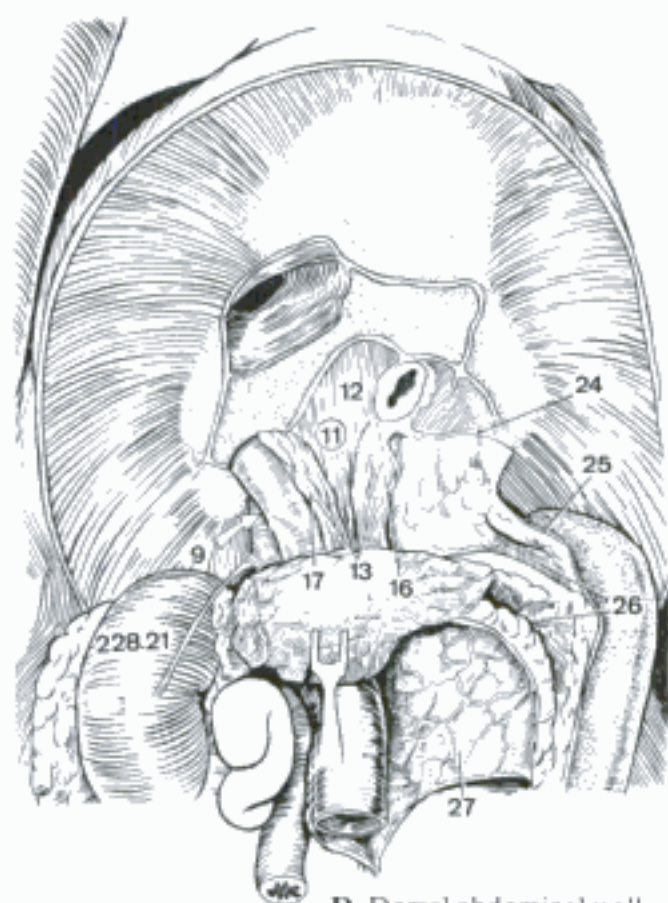


A Schematic transection of embryo

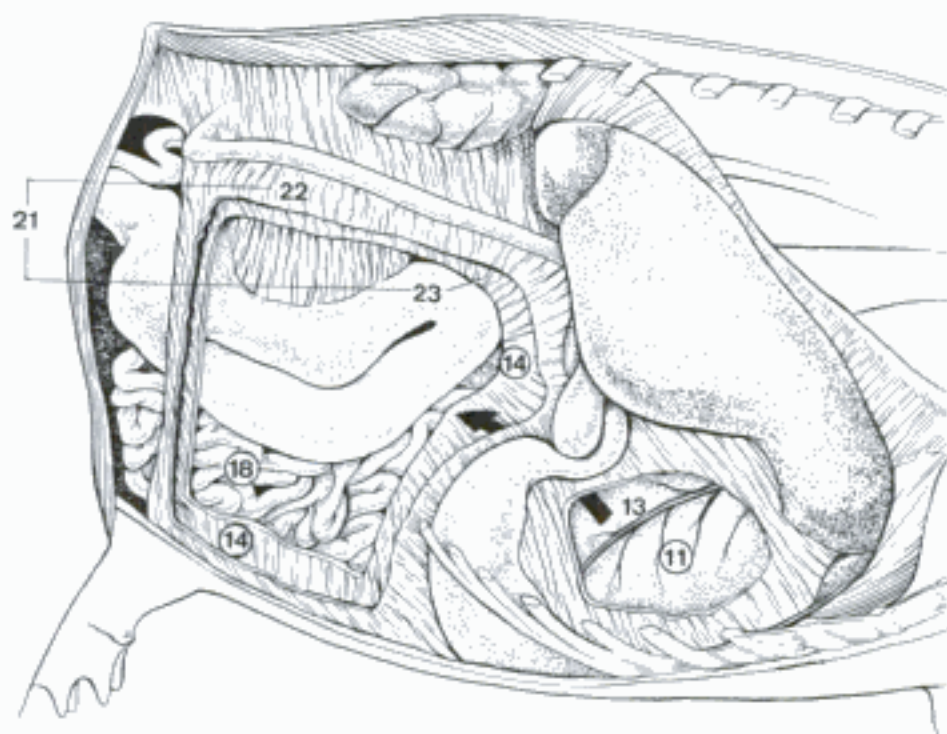
B Embryo, median dissection (su, 10 mm) (Arey)



C Bursa omentalis (superficial wall reflected cranially with stomach; 13 is on papillary process of liver) (ca)

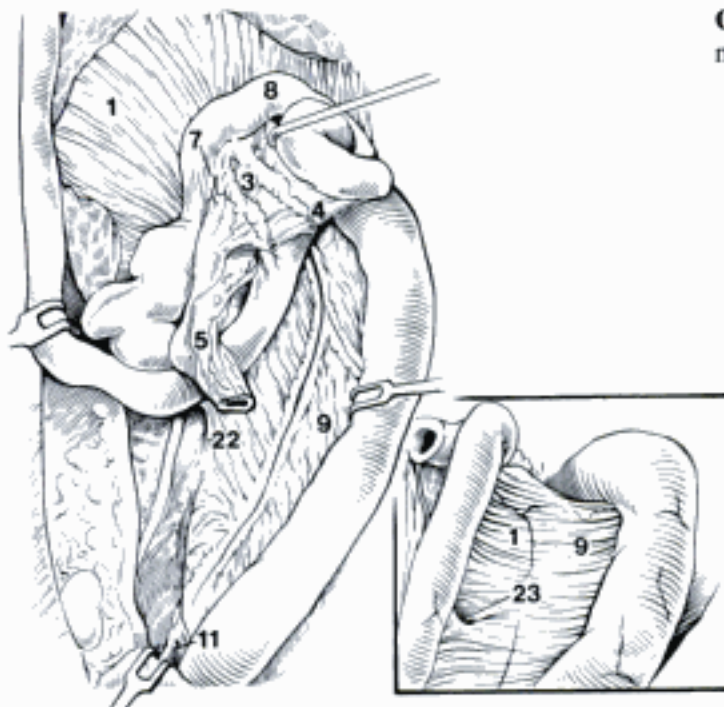


D Dorsal abdominal wall (stomach, liver, and right lobe of pancreas removed), caudoventral aspect (ca)



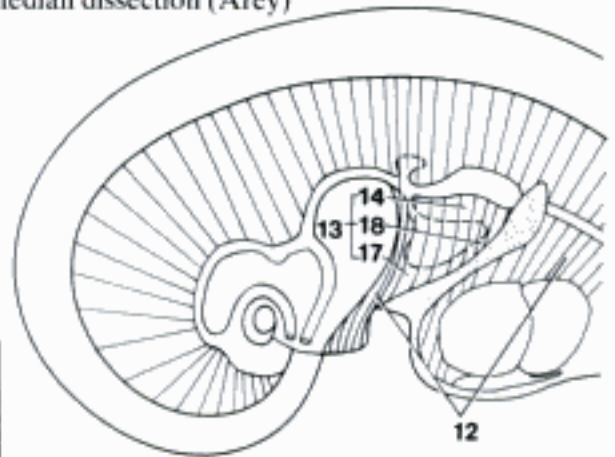
E Bursa omentalis (greater omentum fenestrated to show omasum) (bo)

- 1 *Mesoduodenum*. Mesentery of the duodenum. A B
- 2 *Mesenterium*. Mesentery in the specific sense, attached to Jejunum and Ileum.
- 3 *Radix mesenterii*. Root of the mesentery, dorsal attachment containing A. mesenterica cranialis. A
- 4 *Mesojejunum*. Mesentery of the jejunum. A
- 5 *Mesoileum*. Mesentery of the ileum. A
- 6 *Mesocolon*. Mesentery of the colon.
- 7 *Mesocolon ascendens*. Ascending mesocolon, attached to Colon ascendens. A
- 8 *Mesocolon transversum*. Transverse mesocolon, attached to Colon transversum. A
- 9 *Mesocolon descendens*. Descending mesocolon, attached to Colon descendens. A B
- 10 *Mesocolon sigmoideum*. Sigmoid mesocolon, attached to Colon sigmoideum in bo.
- 11 *Mesorectum*. Attached to rectum. A
- 12 *Mesenterium ventrale primitivum (ont)*. Primitive ventral mesentery, connecting esophagus, stomach, and cranial part of the duodenum to ventral body wall. C
- 13 *Mesogastrium ventrale (ont)*. Ventral mesogastrium, connects stomach to ventral abdominal wall. It is divided by the developing liver into Omentum minus and hepatic ligaments. C
- 14 *Omentum minus*. Lesser omentum, connects Curvatura ventriculi minor and Pars cranialis duodeni to the visceral surface of the liver. C D F
- 15 *Lig. hepatogastricum*. Hepatogastric lig., the greater part of the Omentum minus, from liver to stomach. D
- 16 *Lig. hepatoduodenale*. Hepatoduodenal lig., the free right border of the Omentum minus. It connects liver to Pars cranialis duodeni, contains V. portae, A. hepatica, and Ductus choledochus, and forms the ventral boundary of the Foramen omentale. D
- 17 *Lig. falciforme hepatis*. Falciform lig. of the liver, a derivative of the primitive ventral mesentery between parietal surface of the liver, and diaphragm and ventral abdominal wall. In ca, the caudal portion, extending to the umbilicus, is usually filled with fat. C D E F
- 18 *Lig. coronarium hepatis*. Coronary lig., attaches liver to diaphragm, surrounding Area nuda and Sulcus venae cavae, and connecting Ligg. triangularia and falciforme. C F
- 19 *Lig. triangulare dextrum*. Right triangular lig., right free fold of the Lig. coronarium between right lobe of the liver and diaphragm. F
- 20 *Lig. triangulare sinistrum*. Left triangular lig., left free fold of the Lig. coronarium between left lobe of the liver and diaphragm. E F
- 21 *Lig. hepatorenale*. Hepatorenal lig., between Processus caudatus and right kidney. 227 D
- 22 *Plica duodenocolica*. Duodenocolic fold, a fold of peritoneum between Duodenum ascendens and Colon descendens (Mesocolon descendens in ca). A
- 23 *Recessus duodenalis caudalis*. Caudal duodenal recess (ca), small blind sac in the peritoneum on the attached surface of the end of the Duodenum ascendens. It opens cranially. B

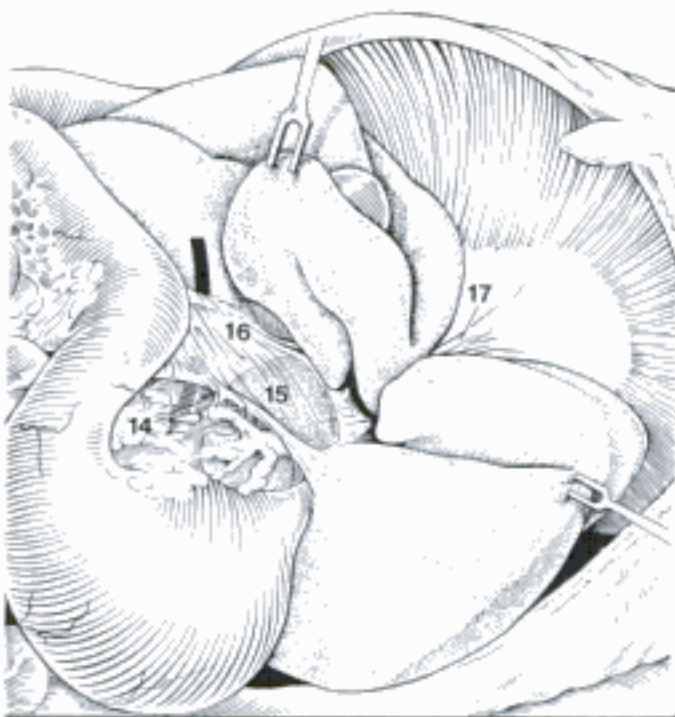

A Mesenteries, ventral aspect (most of jejunum removed) (ca)

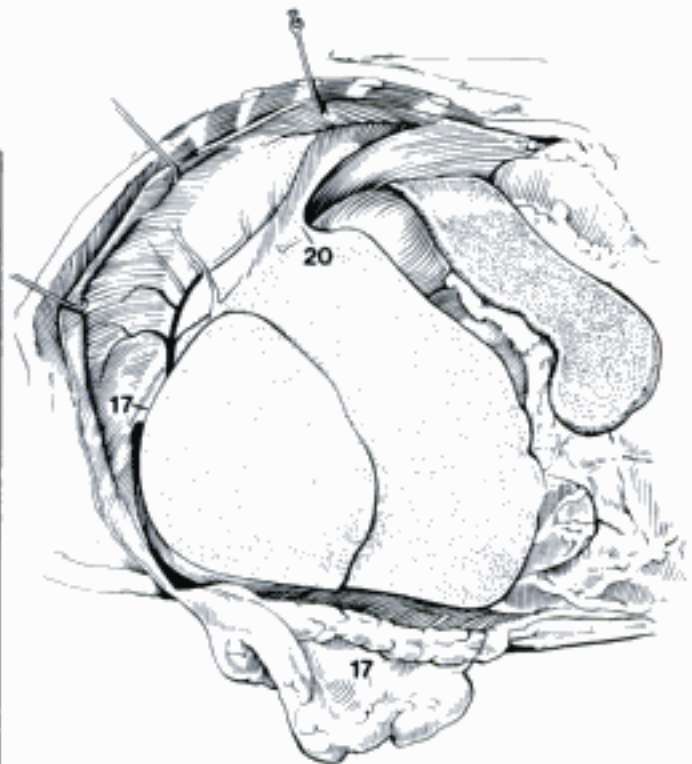
C Diagram of early Embryo, median dissection (Arey)



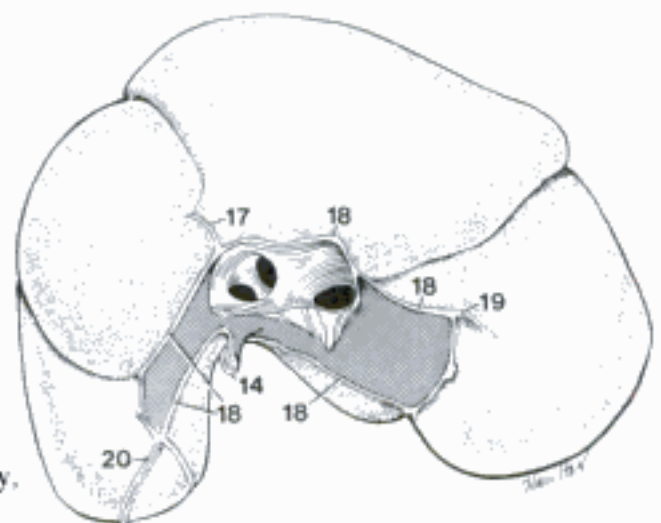
B Caudal duodenal recess, left ventrolateral aspect (duodenojejunal flexure and descending colon shown) (ca)



D Lesser omentum, left caudoventral aspect (left ribs 7–13 removed. Arrow indicates omental foramen) (ca)

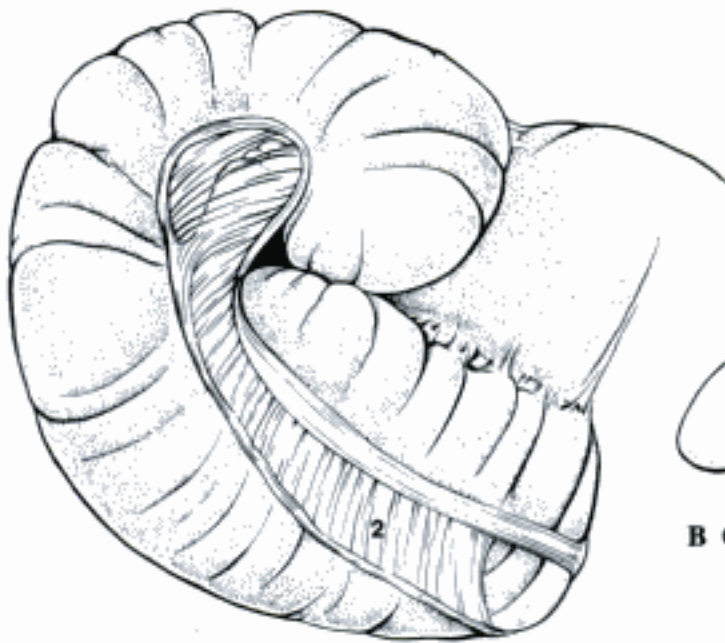


E Liver in situ, left lateral aspect (diaphragm retained by hooks) (ca)

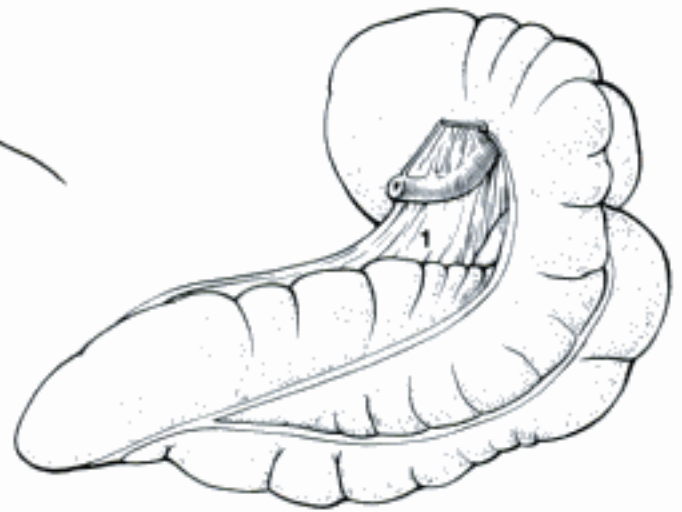


F Liver, diaphragmatic surface (dorsal recumbency, fixed in situ) (ca)

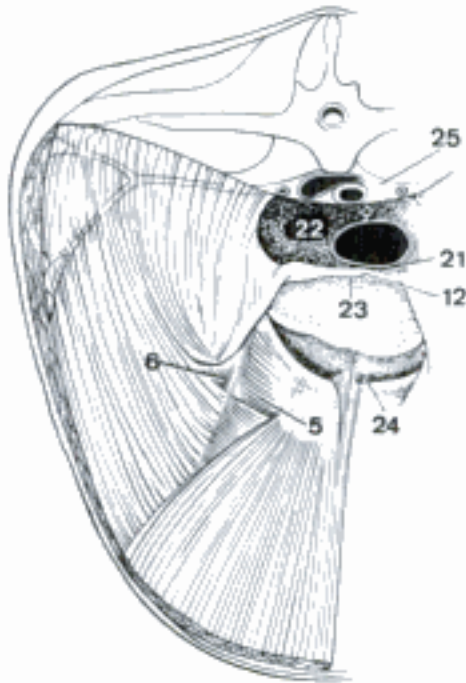
- 1 *Plica ileocecalis* [-caecalis]. Ileocecal fold, between the antimesenteric surface of ileum and cecum. In eq it is attached to the Tenia dorsalis ceci. B
- 2 *Plica cecocolica* [caeco-] (e q). Cecocolic fold between Tenia libera lateralis of the right ventral colon and Tenia lateralis ceci. A
- 3 *Lig. vesicae medianum*. (See 198.7)
- 4 *Lig. vesicae laterale*. (See 198.9)
- 5 *Trigonum inguinale*. Inguinal triangle, bounded by Lig. inguinale, lateral border of M. rectus abdominis, and the line formed by Truncus pudendoepigastricus and A. epigastrica caudalis. C
- 6 *Fossa inguinalis lateralis*. Lateral inguinal fossa, depression over the Anulus inguinalis profundus lateral to the A. epigastrica caudalis. C
- 7 *Mesorchium*. (See 202.21)
- 8 *Mesoductus deferens*. (See 202.25)
- 9 *Mesepididymis*. (See 202.26)
- 10 *Bursa testicularis* [Sinus epididymalis]. (See p. 202.30)
- 11 *Processus vaginalis peritonei* [peritoneaei] (ont). (See 204.1)
- 12 *Plica genitalis*. Genital fold, separates Excavatio rectogenitalis from Excavatio vesicogenitalis in the male, contains the Ductus deferens. C
- 13 *Lig. latum uteri*. Broad lig. of the uterus, fold of peritoneum attaching the intraperitoneal female genital organs to the dorsolateral body wall. D
- 14 *Mesometrium*. Part of the broad lig. attached to the uterus. D
- 15 *Mesosalpinx*. Fold laterally detached from broad ligament, contains uterine tube, forms lateral wall of ovarian bursa, completely surrounds ovary in Car and su. D
- 16 *Mesovarium*. Part of the broad lig. attached to the ovary, contains the ovarian vessels and is homologous to the mesorchium. D
- 17 *Mesovarium proximale*. From the abdominal wall to the origin of mesosalpinx. D
- 18 *Mesovarium distale*. From the origin of Mesosalpinx to the ovary. D
- 19 *Bursa ovarica*. Ovarian bursa, cavity enclosed by mesosalpinx, distal mesovarium, and ovary. D
- 20 *Lig. suspensorium ovarii*. Free border of the mesovarium. D
- 21 *Excavatio rectogenitalis*. Rectogenital pouch, recess of the peritoneal cavity between rectum and Plica genitalis (male), uterus and Ligg. lata (female). C
- 22 *Fossa pararectalis*. Extension of Excavatio rectogenitalis lateral to rectum and mesorectum. C
- 23 *Excavatio vesicogenitalis*. Vesicogenital pouch, recess of the peritoneal cavity between bladder and Plica genitalis (male), uterus and Ligg. lata (female). C
- 24 *Excavatio pubovesicalis*. Pubovesical pouch, peritoneal recess ventral to bladder and Ligg. vesicae lateralia. C
- 25 *Spatium retroperitoneale* [-peritoneaeale]. Space filled with connective tissue and fat between peritoneum and body wall. C
- 26 **GLANDULAE ENDOCRINAE**. Endocrine glands, ductless glands that secrete hormones into the bloodstream.
- 27 **Glandula thyroidea** [thyreoidea]. Thyroid gland, on the cranial end of the trachea. E F
- 28 *Lobus* [dexter et sinister]. Lobe, right and left. E
- 29 *Isthmus glandularis* (Car, bo). Glandular band connecting the caudal ends of the lobes, may be absent in Car. E
- 30 *Isthmus fibrosus* (ov, cap, eq). Connecting fibrous band between the caudal ends of the lobes, sometimes absent.
- 31 *Lobus pyramidalis*. Pyramidal lobe, variable median ventral lobe projecting cranially, occurs in man and su. F
- 32 *Capsula fibrosa*. Capsule. G
- 33 *Stroma*. Connective tissue framework. G
- 34 *Parenchyma*. Glandular substance, composed of follicles. G
- 35 *Lobuli*. Lobules. E
- 36 *Folliculi*. Follicles, epithelial sacs containing colloid. G
- 37 (*Gll. thyroideae* [thyreoideae] *accessoriae*). Small nodules of thyroid tissue anywhere between tongue and heart.



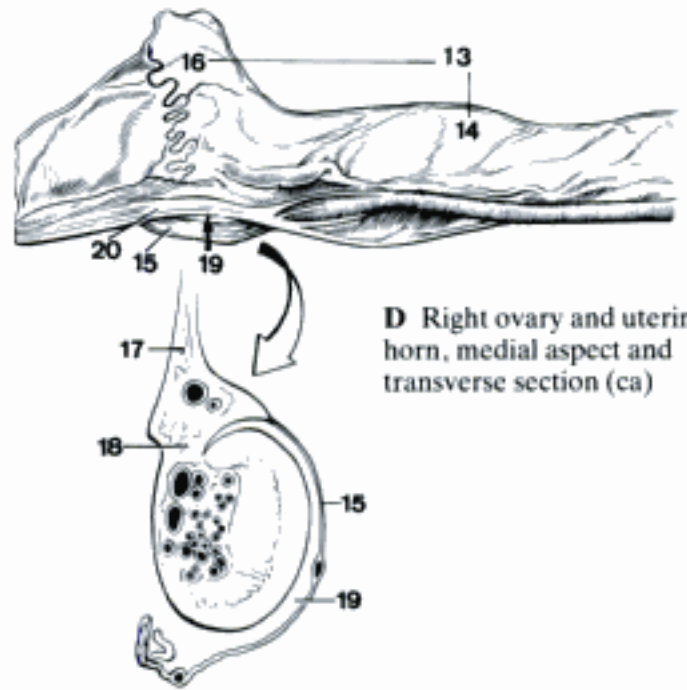
A Cecum and right dorsal and ventral colon, right lateral aspect (eq)



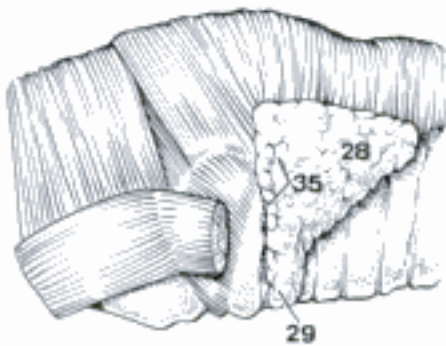
B Cecum and ileum, medial aspect (eq) (Getty)



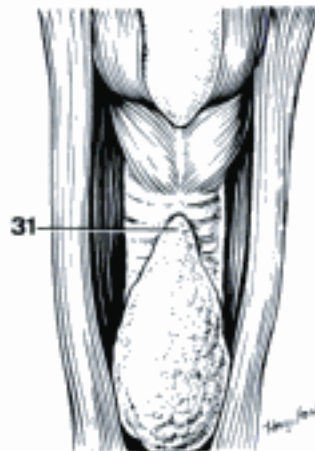
C Abdominal and pelvic cavities, cranial aspect (eq) (Getty)



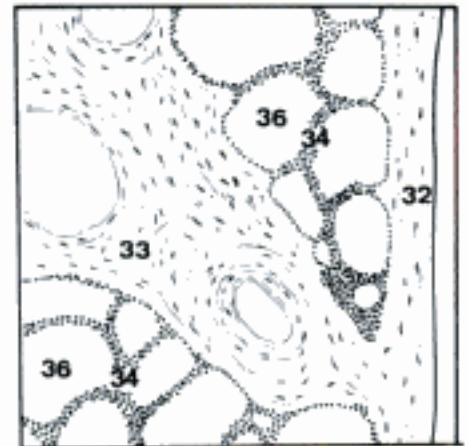
D Right ovary and uterine horn, medial aspect and transverse section (ca)



E Thyroid gland, lateral aspect (bo)

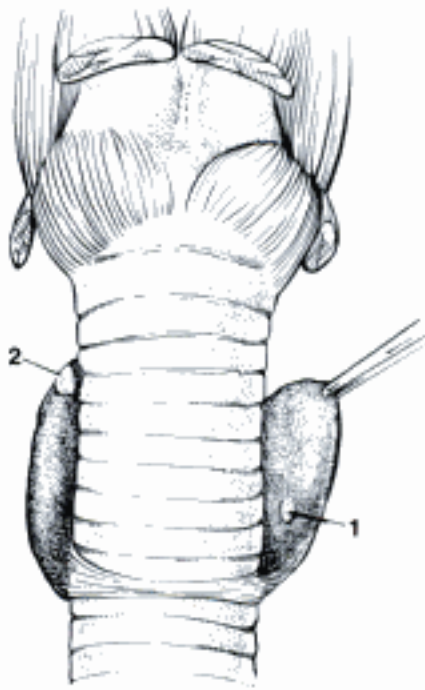


F Thyroid gland, ventral aspect (su)

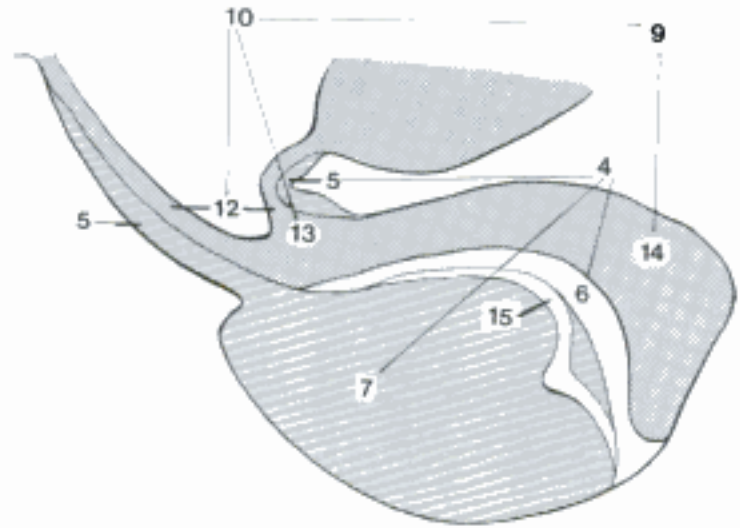


G Thyroid gland, histological section (ca)

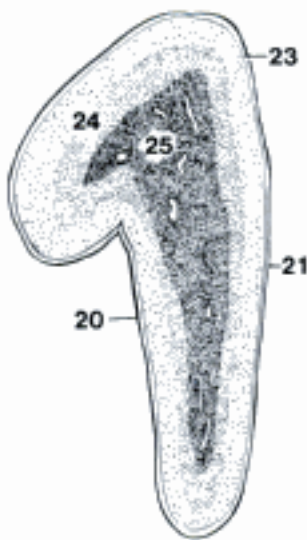
- 1 **Glandula parathyroidea [-thyroidea] interna [IV]**. Internal parathyroid gl., from the fourth pharyngeal pouch. In the thyroid lobe in Car, absent in su, embedded in the medial surface of the thyroid lobe in Ru, on the surface of the cranial half of the thyroid lobe in eq. A
- 2 **Glandula parathyroidea [-thyroidea] externa [III]**. External parathyroid gl., from the third pharyngeal pouch. On the lateral surface of the thyroid lobe in Car, near the end of the A. carotis communis in su and Ru, near the thoracic inlet in eq. A
- 3 **Hypophysis [Glandula pituitaria]**. Pituitary gland, in a fossa on the basisphenoid. Neural and glandular components provide link between hypothalamus and endocrine glands. B
- 4 **Adenohypophysis**. Glandular lobe, derived from the stomodeal epithelium. The term anterior lobe is not applicable to domestic mammals. B
- 5 **Pars tuberalis**. Tuberal part, covers the infundibulum up to the Tuber cinereum. B
- 6 **Pars intermedia**. Intermediate part, lies between Pars distalis and Neurohypophysis, surrounds the Neurohypophysis in Car and eq. B
- 7 **Pars distalis**. Distal part, largest part of the Adenohypophysis. B
- 8 (**Pars pharyngea**). Pharyngeal part, a remnant of the Saccus hypophysialis (Rathke's pouch) in the dorsal mucosa of the nasopharynx (Car, eq).
- 9 **Neurohypophysis**. Ventral outgrowth of the hypothalamus, composed of infundibulum and neural lobe. In a caudodorsal groove of the Adenohypophysis in su, Ru, surrounded by it in Car, eq. Therefore the term posterior lobe is not suitable for domestic mammals. B
- 10 **Infundibulum**. Funnel-shaped stalk of the Neurohypophysis. B
- 11 **Radix**. Root, the histological zone where the nerve fibers of the infundibulum join the Tuber cinereum.
- 12 **Pars cava**. Hollow part, containing a recess of the third ventricle. B
- 13 **Pars compacta**. Solid part. B
- 14 **Lobus nervosus**. Neural lobe, part of the Neurohypophysis distal to the Diaphragma sellae. B
- 15 **Cavum hypophysis**. Cavity of the hypophysis, a remnant of the cavity of the Saccus hypophysialis (Rathke's pouch) between Pars intermedia and Pars distalis, absent in eq. B
- 16 **Glandula pinealis** (vide Epithalamus). Pineal gland.
- 17 **Glandula adrenalis [suprarenalis]**. Adrenal gland, medial to the cranial half of the kidney, but the left gland in bo is cranial to the kidney near the A. mesenterica cranialis. C D
- 18 **Facies ventralis**. Ventral surface. D
- 19 **Facies dorsalis**. Dorsal surface.
- 20 **Margo lateralis**. Lateral border. C
- 21 **Margo medialis**. Medial border. C
- 22 **Hilus**. Depression on the medial border where the vein joins the gland. D
- 23 **Capsula**. Capsule, connective tissue covering. C
- 24 **Cortex**. Outer yellowish portion consisting of cords and clusters of epithelial cells. C
- 25 **Medulla**. Central brown zone of chromaffin (adrenalin secreting) cells and sympathetic ganglion cells. C
- 26 (**Gll. adrenales [suprarenales] accessoriae**). Accessory adrenal glands, may contain cortical and medullary tissue, retroperitoneally in the lumbar region.
- 27 **Insulae pancreaticae**. Pancreatic islets, small (.04-.2 mm) groups of endocrine cells which secrete insulin and glucagon. E
- 28 **Thymus** (vide Systema lymphaticum).



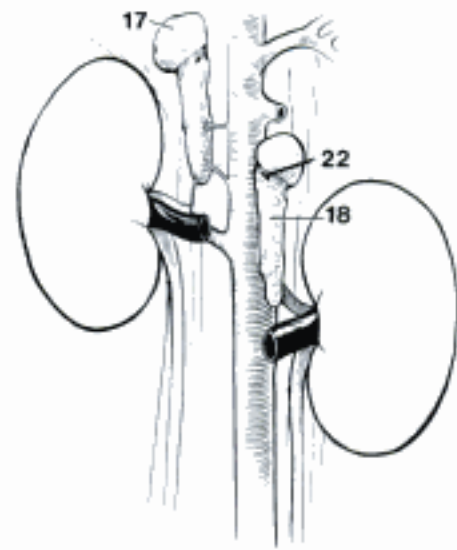
A Larynx and trachea, thyroid and parathyroid glands, ventral aspect (ca)



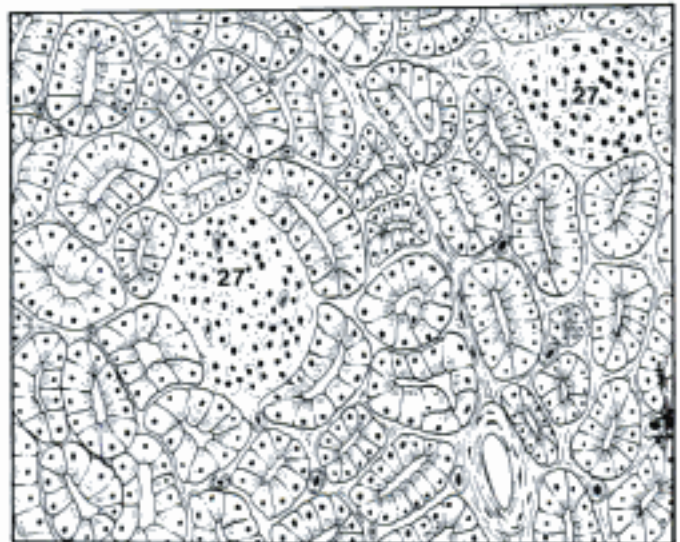
B Hypophysis, median section (bo)



C Right adrenal gland, sectioned in a dorsal plane, ventral aspect (ca)

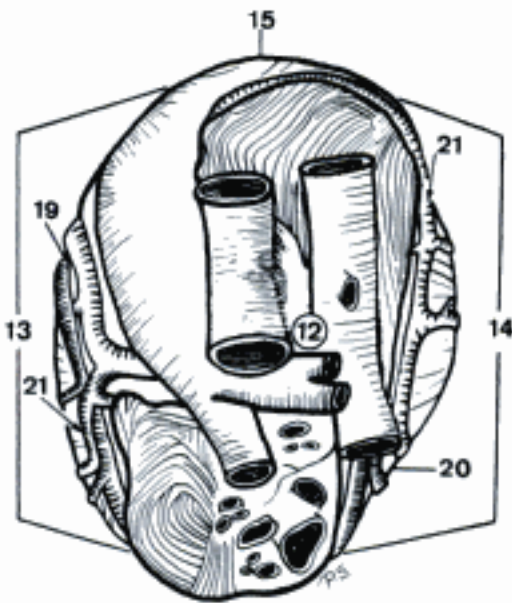


D Adrenal glands and kidneys, ventral aspect (Vv. cava caudalis and phrenicoabdominalis removed) (ca)



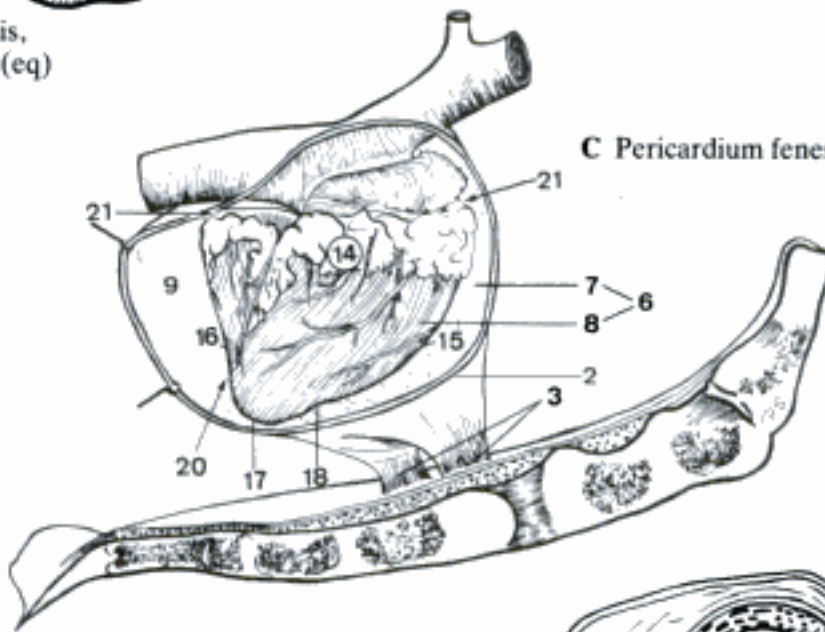
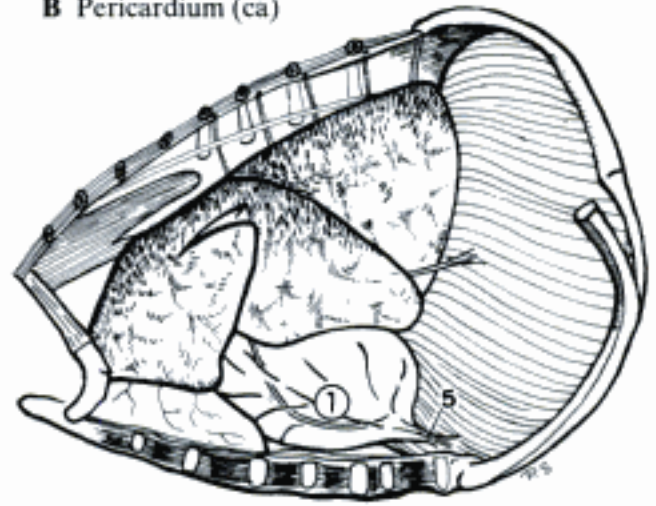
E Pancreatic islets, histological section (su)

- 1 **PERICARDIUM.** Conical sack-like structure enclosing the heart and the roots of the largest vessels. Covered by Pleura pericardiaca. Consists of an outer fibrous and an inner bilaminar serous portion. B C D E
- 2 *Pericardium fibrosum.* Outer fibrous part of pericardium. C D E
- 3 *Ligg. sternopericardiaca.* Bilateral connective band between Pericardium fibrosum and sternum (Ru). C
- 4 *Lig. sternopericardiacum.* Singular connective band between pericardium fibrosum and sternum (eq). E
- 5 *Lig. phrenicopericardiacum.* Band between Pericardium fibrosum and Diaphragma (Car, su). B
- 6 *Pericardium serosum.* Closed sac surrounded by Pericardium fibrosum. Encloses a cavity into which about one-half of its wall is invaginated by the heart to form the Lamina visceralis, while its uninvaginated Lamina parietalis is firmly fused with Pericardium fibrosum. C D E
- 7 *Lamina parietalis.* Serous internal covering of Pericardium fibrosum. C D E
- 8 *Lamina visceralis [Epicardium].* Serous covering of the surface of the heart and the roots of the great vessels. C D E
- 9 *Cavum pericardii.* Body cavity between Lamina parietalis and Lamina visceralis of Pericardium serosum. Contains a small amount of serous fluid. C D E
- 10 *Sinus transversus pericardii.* Tunnel-shaped extension of Cavum pericardii between the united Aorta and Truncus pulmonalis, and the concave wall-parts of the adjacent atria. D E
- 11 **COR.** Heart. Cone-shaped (Un) to ovoid (Car) hollow muscular organ enclosed by pericardium. Center of the vascular system. A C E
- 12 *Basis cordis.* Dorsocranially (Car, su) to dorsally (Ru, eq) directed upper surface of the heart, ventrally marked out by Sulcus coronarius. A E
- 13 *Facies auricularis.* Heart surface marked by the tips of Auriculae atriorum, facing the left thoracic wall. A E
- 14 *Facies atrialis.* Heart surface on the side of the atrial mass. Opposite Facies auricularis, it faces the right thoracic wall. A C
- 15 *Margo ventricularis dexter.* Part of the cranially situated convex border of the heart, which belongs to Ventriculus dexter. A C E
- 16 *Margo ventricularis sinister.* Side of Ventriculus sinister turned to Diaphragma, forming the caudal border of the heart. C E
- 17 *Apex cordis.* By Ventriculus sinister formed tip, opposite to Basis cordis. C E
- 18 *Incisura apicis cordis.* Notch underneath Margo ventricularis dexter near Apex cordis. Formed by the continuation of Sulcus interventricularis paraconalis. C E
- 19 *Sulcus interventricularis paraconalis.* Longitudinal groove on Facies auricularis. Descends from Sulcus coronarius, along Conus arteriosus, outside of Septum interventriculare. A E
- 20 *Sulcus interventricularis subsinu- osus.* Longitudinal groove on Facies atrialis outside of Septum interventriculare. Begins at Sulcus coronarius, ventral to Sinus venarum cavarum and Sinus coronarius. A C
- 21 *Sulcus coronarius.* Groove that encircles the heart completely, except at Conus arteriosus. Indicates externally the limit between Atria and Ventriculi cordis. A C

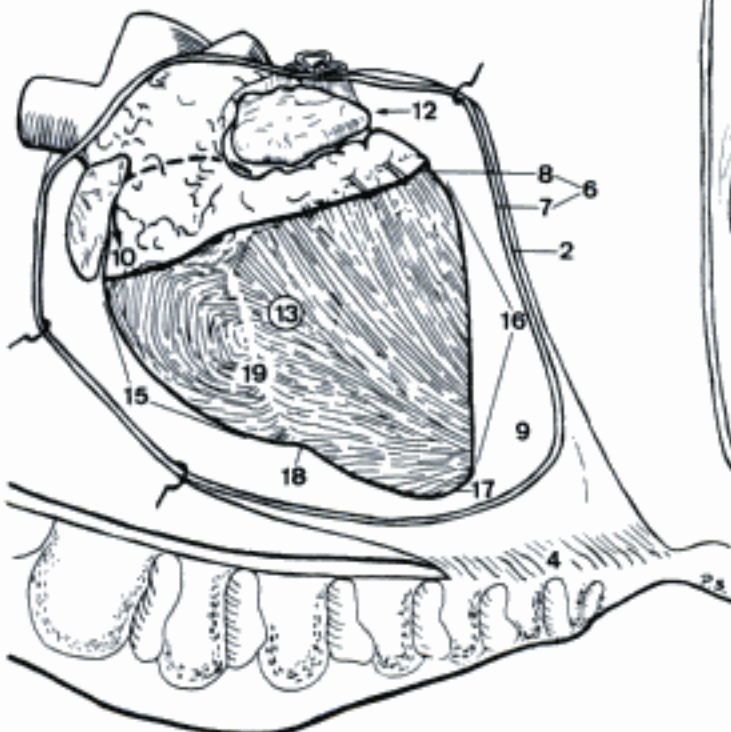


A Basis cordis, dorsal aspect (eq)

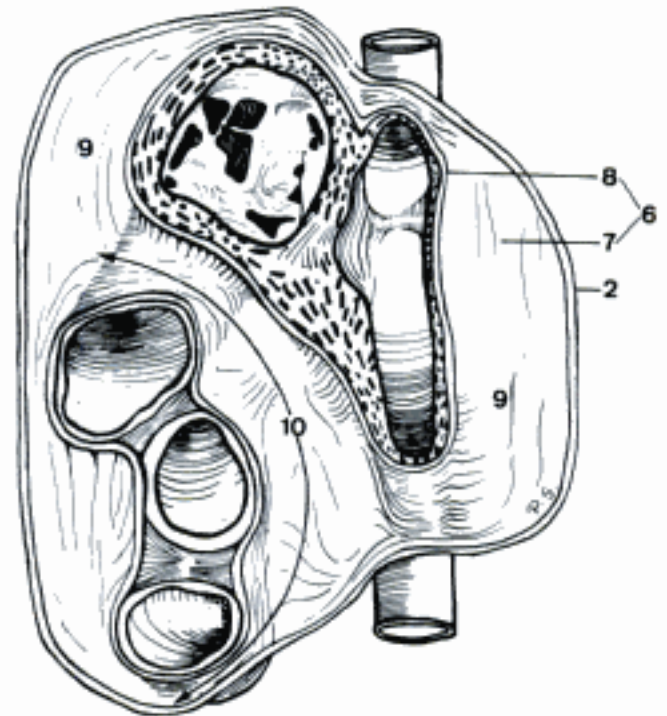
B Pericardium (ca)



C Pericardium fenestrated, heart (bo, young)

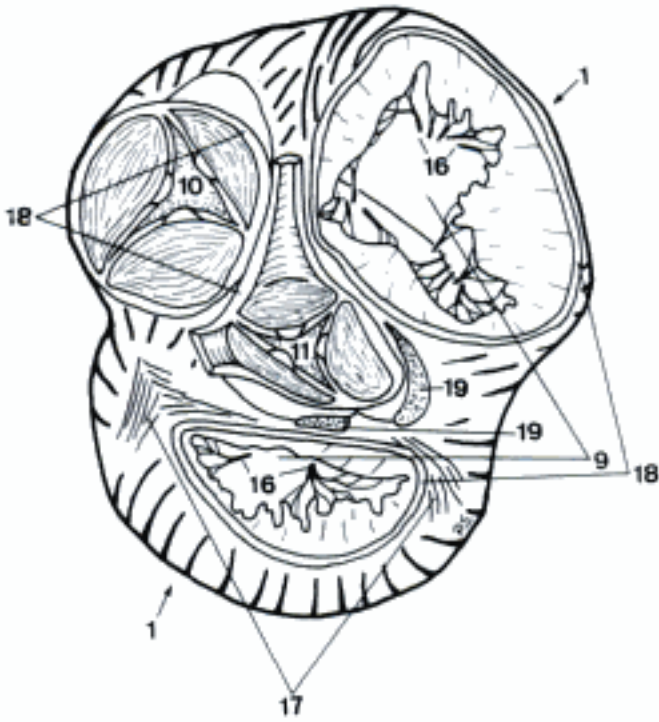


D Dorsal wall of Pericardium, ventral aspect (eq)

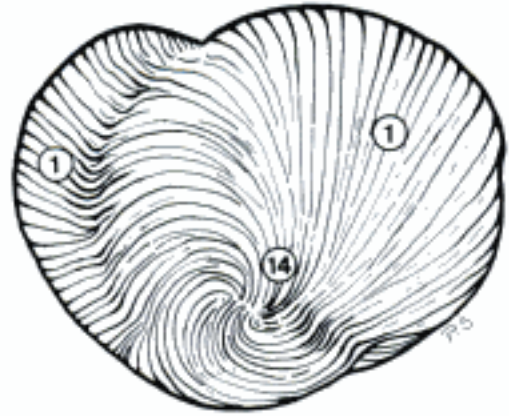

E Pericardium fenestrated, heart, left aspect (eq)

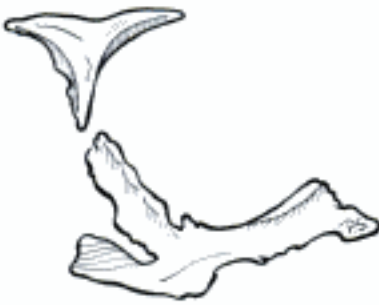- 1 *Ventriculus cordis*. Each of both heart chambers ventral to the level of Sulcus coronarius. A B D
- 2 *Septum interventriculare*. Longitudinal partition-wall between both Ventriculi cordis, externally indicated by Sulci interventriculares. D E
- 3 *Pars muscularis*. Larger and thicker portion of Septum interventriculare, formed by myocardium of the two contiguous ventricular septal walls. D
- 4 *Pars membranacea*. Very small dorsal membranous portion of Septum interventriculare. D
- 5 *Septum atrioventriculare*. Small membranous contact-wall between Atrium dextrum and Ventriculus sinister. Situated dorsal to the base of Cuspis septalis of Valva atrioventricularis dextra. D
- 6 *Atrium cordis*. Each of both chambers at Basis cordis. At the level of Sulcus coronarius separated from the corresponding Ventriculus cordis by an Anulus fibrosus. D E
- 7 *Auricula atrii*. Blind, ear-shaped diverticulum of the left and right Atrium cordis. D
- 8 *Septum interatriale*. Muscular partition between both Atria cordis. D
- 9 *Ostium atrioventriculare [dext. et sin.]*. By Anuli fibrosi surrounded large openings of the left and right Atrium cordis into the corresponding Ventriculus cordis. A
- 10 *Ostium trunci pulmonalis*. Opening of Ventriculus dexter into Truncus pulmonalis. Surrounded by an Anulus fibrosus to which a valve system is attached. A
- 11 *Ostium aortae*. Opening of Ventriculus sinister into Aorta ascendens. Surrounded by an Anulus fibrosus to which a valve system is attached. A D
- 12 *Trabeculae carnae*. Subendocardial myocardial ridges of the ventricle-wall, projecting into the lumen of the heart. D
- 13 *Foramina venarum minimarum*. Openings of Vv. cordis minimae. D
- 14 *Vortex cordis*. Swirl of myocardial fibers at Apex cordis. B
- 15 *Musculi papillares*. Conical myocardial projections into the ventricular lumen. Connected with the atrioventricular cusps by Chordae tendineae. D E
- 16 *Chordae tendineae*. Fibromuscular cords between Valvae atrioventriculares and the apices of Mm. papillares. A D
- 17 *Trigona fibrosa*. Pair of adjacent triangular areas of dense connective tissue, located between both Ostia atrioventricularia and Ostium aortae. A
- 18 *Anuli fibrosi*. Connective tissue rings surrounding Ostia atrioventricularia, Ostium aortae, and Ostium trunci pulmonalis. Give rise to the corresponding valve systems. A
- 19 *Cartilago cordis*. Amount of cartilage in or near the aortic Anulus fibrosus (Car, su, eq). Sometimes absent (Car), frequently senilely calcified (su, eq) or plural (eq). A
- 20 *Ossa cordis*. Pair of bones in the aortic Anulus fibrosus. Usually single in ov. C
- 21 **Myocardium**. Striated cardiac musculature including the internal conducting system. D E
- 22 *Nodus sinuatrialis*. Small complex of special cardiac muscle tissue located at Sulcus terminalis near Ostium venae caeve cranialis. E
- 23 *Nodus atrioventricularis*. Small complex of special cardiac muscle tissue located in the base of the septal wall of Atrium dextrum, close to the opening of Sinus coronarius. E
- 24 *Fasciculus atrioventricularis*. Bundle of modified cardiac muscle fibers. Contains Nodus atrioventricularis in its first section, and conducts from the atrial to the ventricular, esp. papillary musculature. E
- 25 *Truncus [fasc. atriovent.]*. Section of the Fasciculus atrioventricularis before its division at Septum interventriculare. E
- 26 *Crus [dextrum et sinistrum]*. Right and left limbs of the atrioventricular conducting system that finally ramify inside Mm. papillares. E
- 27 **Endocardium**. Glistening membrane lining the internal surface of the heart chambers. D E



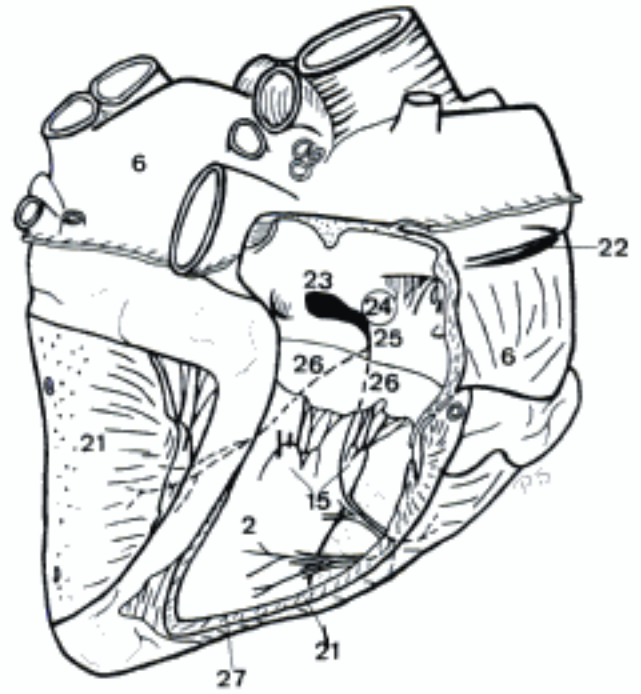
A Ventriculi cordis (atria removed), dorsal aspect (eq)



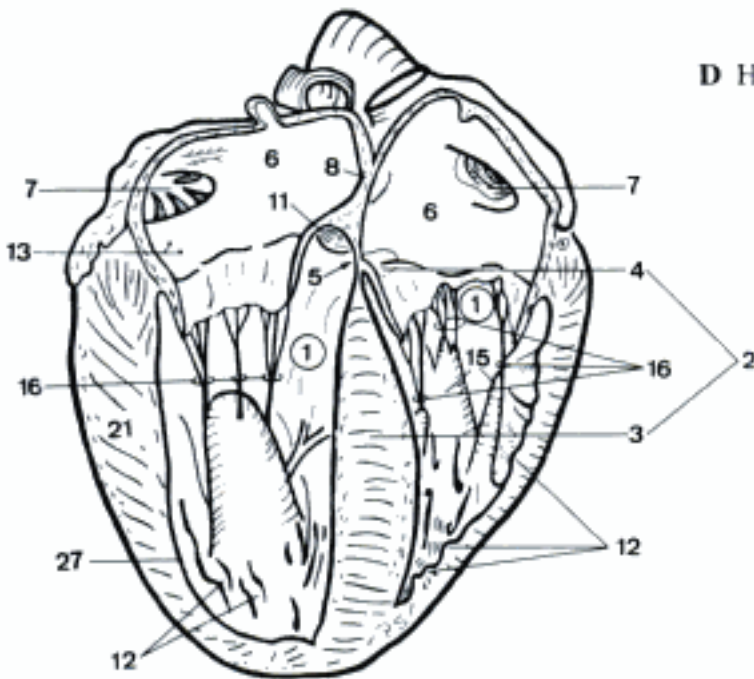
B Apex cordis, ventral aspect (eq)



C Ossa cordis, right caudodorsal aspect (bo)

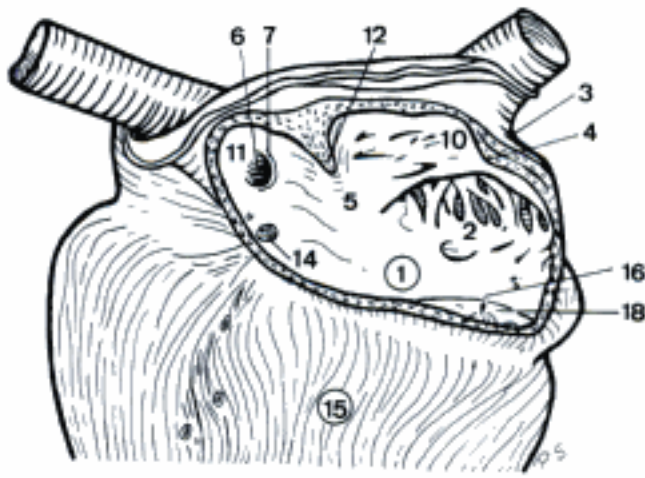


D Heart, sagittal section, left part, right aspect (fe)

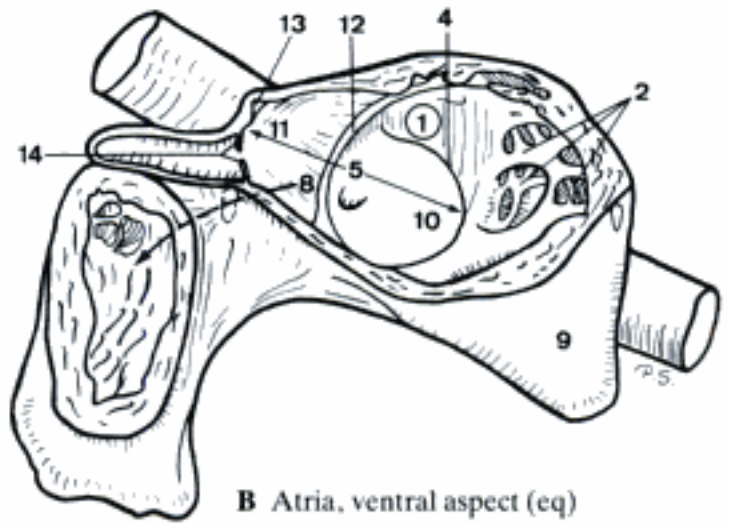


E Facies atrialis of the heart (ventricular walls partly removed) (eq)

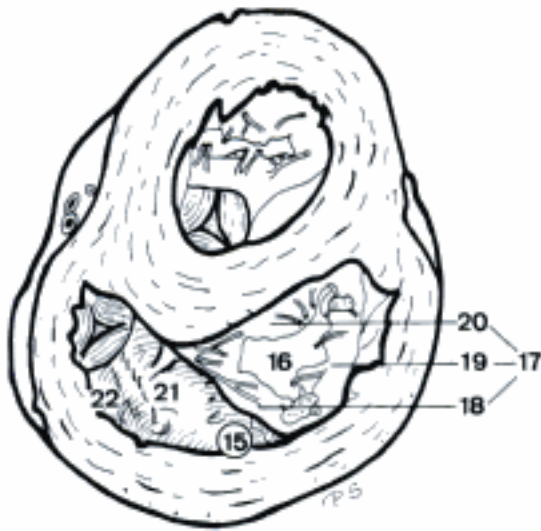- 1 **Atrium dextrum.** Atrium on the right cranial part of Basis cordis, situated dorsal (Un) or dorsocranial (Car) to Ventriculus dexter. A B
- 2 *Mm. pectinati.* Muscular ridges on the wall of Auricula dextra and Atrium dextrum proper. Most of them radiate from Crista terminalis. A B
- 3 *Sulcus terminalis.* Often poorly defined (esp. Car) external groove opposite Crista terminalis. A
- 4 *Crista terminalis.* Internal muscular ridge on the wall of Atrium dextrum between Sinus venarum cavarum and Atrium dextrum proper. A B
- 5 *Sinus venarum cavarum.* Smooth-walled part of Atrium dextrum between the wide openings of both Vv. caeve and Ostium atrioventriculare dextrum, bounded by Septum interatriale and Crista terminalis. A B
- 6 *Fossa ovalis.* Depression in the septal wall of Atrium dextrum at Ostium venae caeve caudalis, caudal to Tuberculum intervenosum. Remnant of the fetal Foramen ovale. A
- 7 *Limbus fossae ovalis.* Elevated rim of Fossa ovalis. A
- 8 *Foramen ovale (ont).* Orifice in Septum interatriale, sometimes persisting in adults. B
- 9 *Auricula dextra.* Blind diverticulum of Atrium dextrum. Curves around the right and cranial surfaces of Aorta ascendens. B
- 10 *Ostium venae caeve cranialis.* Craniodorsally situated opening of V. cava cranialis into Sinus venarum cavarum. A B
- 11 *Ostium venae caeve caudalis.* Caudally situated opening of V. cava caudalis into Sinus venarum cavarum. A B
- 12 *Tuberculum intervenosum.* Internal transverse ridge on the dorsal wall of Atrium dextrum, placed between the openings of both Vv. caeve. A B
- 13 *Valvula venae caeve caudalis.* Valve-like fold near Ostium venae caeve caudalis, frequently disappeared (adults) or absent (foal). B
- 14 *Valvula sinus coronarii.* Semilunar fold at the orifice of Sinus coronarius. May be indistinct or even absent, esp. in eq. A B
- 15 **Ventriculus dexter.** Heart chamber that constitutes the right cranial part of the ventricular mass. A C D
- 16 *Ostium atrioventriculare dextrum.* Opening between Atrium dextrum and Ventriculus dexter. A C D
- 17 *Valva atrioventricularis dextra [Valva tricuspidalis].* The entire valve system of Ostium atrioventriculare dextrum, basically composed of three large cusps, possibly accompanied by small intermediate cusps. C D
- 18 *Cuspis angularis.* Cusp in the cranial corner of Ostium atrioventriculare dextrum. Arises from the septal and parietal walls of Ventriculus dexter. A C D
- 19 *Cuspis parietalis.* Cusp arising from the parietal margin of Ostium atrioventriculare dextrum. C D
- 20 *Cuspis septalis.* Cusp arising from the septal margin of Ostium atrioventriculare dextrum. C D
- 21 *Crista supraventricularis.* Muscular ridge which separates Ostium atrioventriculare dextrum from Conus arteriosus. C
- 22 *Conus arteriosus.* Dilatation at the left craniodorsal angle of Ventriculus dexter from which Truncus pulmonalis arises. C D



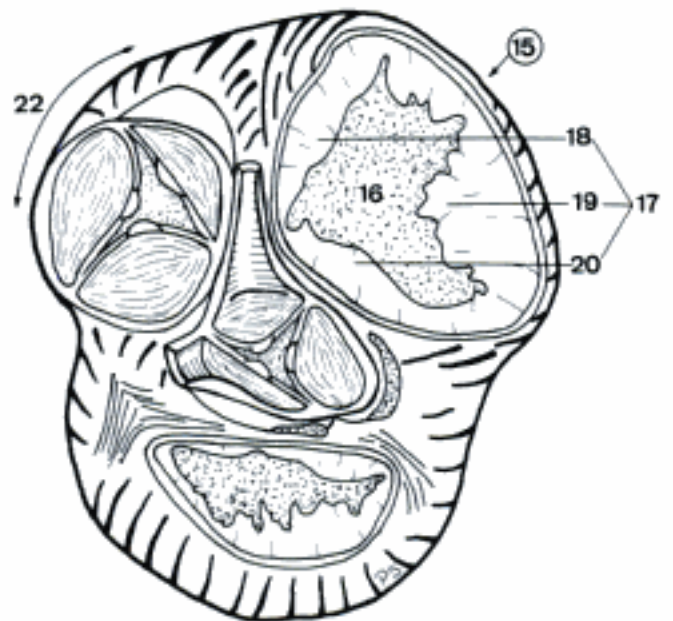
A Heart, Atrium dextrum opened (eq)



B Atria, ventral aspect (eq)

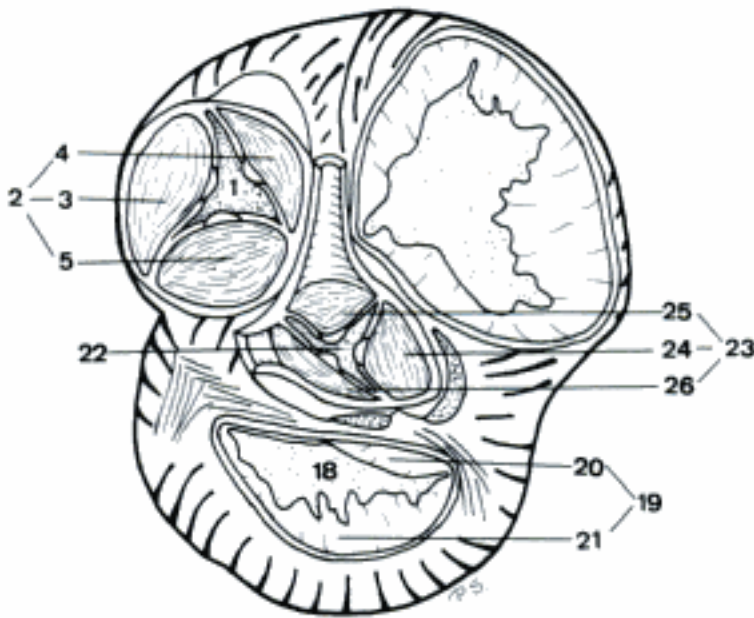


C Ventriculi, horizontal section, ventral aspect (cap)

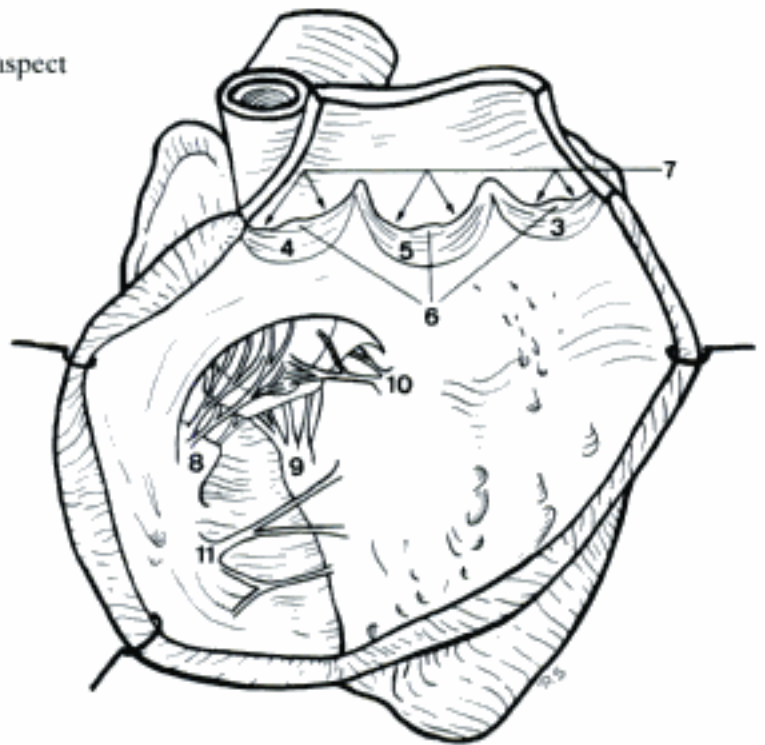


D Heart (atria removed), dorsal aspect (eq)

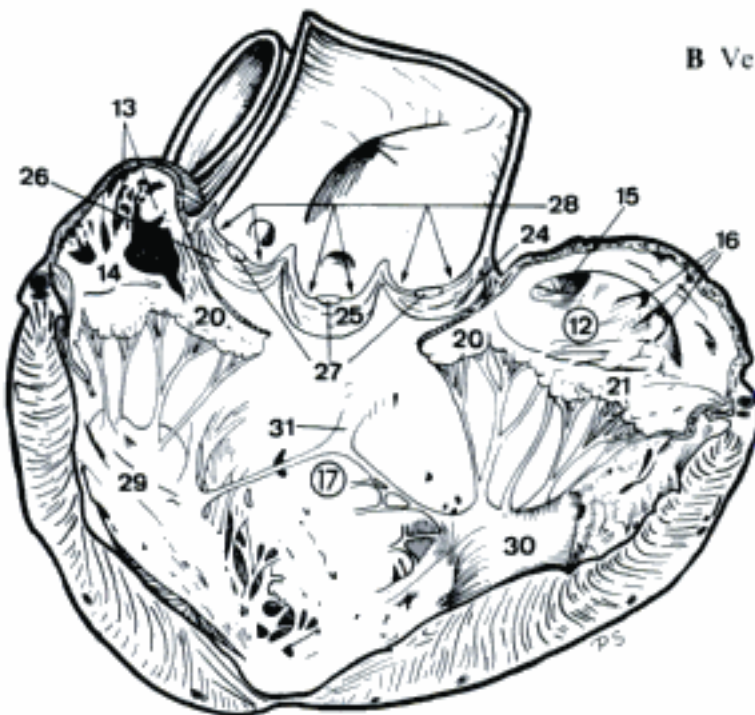
- 1 *Ostium trunci pulmonalis*. Opening between Conus arteriosus and Truncus pulmonalis. A
- 2 *Valva trunci pulmonalis*. Valve apparatus composed of three crescent-shaped leaflets, attached to the Anulus fibrosus of Ostium trunci pulmonalis. A
- 3 *Valvula semilunaris intermedia*. Left-cranially situated semilunar cusp. A B
- 4 *Valvula semilunaris dextra*. Right-cranially situated semilunar cusp. A B
- 5 *Valvula semilunaris sinistra*. Caudally situated semilunar cusp. A B
- 6 *Noduli valvularum semilunarium*. Small elevations near the middle of the free concave margins of Valvulae semilunares. B
- 7 *Lunulae valvularum semilunarium*. Crescentic ridges on the free cusp rims, extending on both sides of each Nodus valvulae semilunaris. B
- 8 *Musculus papillaris magnus*. Eminent and usually largest M. papillaris of Ventriculus dexter, situated on the parietal wall (Un) or related to the septal wall (Car) of that heart chamber. B
- 9 *Musculi papillares parvi*. Generally grouped, medium-sized Mm. papillares. Mostly caudally situated on the septal wall. B
- 10 *Musculus papillaris subarteriosus*. Situated on the septal wall, ventral to Ostium trunci pulmonalis. B
- 11 *Trabecula septomarginalis*. Myocardial strand extending from Septum interventriculare to the opposite parietal wall. Frequently plural and branched. B
- 12 **Atrium sinister**. Atrium on the left caudal half of Basis cordis, dorsal to Ventriculus sinister. C
- 13 *Mm. pectinati*. Muscular ridges on wall of Auricula sinistra. C
- 14 *Auricula sinistra*. Blind diverticulum of Atrium sinister. Extends around the caudal surface of Truncus pulmonalis, pointing to the left thoracic wall. C
- 15 *Valvula foraminis ovalis*. Floor of Fossa ovalis located on Septum interatriale. C
- 16 *Ostia venarum pulmonalium*. Entrances of Vv. pulmonales into the left atrium. C
- 17 **Ventriculus sinister**. Heart chamber that constitutes the left caudal portion of the ventricular mass. C
- 18 *Ostium atrioventriculare sinistrum*. Opening between Atrium sinistrum and Ventriculus sinister. A
- 19 *Valva atrioventricularis sinistra [Valva bicuspidalis, mitralis]*. Entire valve system of Ostium atrioventriculare sinistrum, basically composed of two large cusps, usually attended by accessory intermediate cusps. A
- 20 *Cuspis septalis*. Cusp arising from the septal margin of Ostium atrioventriculare sinistrum, separating the latter from Ostium aortae. A C
- 21 *Cuspis parietalis*. Cusp arising from the parietal margin of Ostium atrioventriculare sinistrum. A C
- 22 *Ostium aortae*. Opening of Ventriculus sinister into Aorta ascendens. A
- 23 *Valva aortae*. Valve apparatus composed of three crescent-shaped leaflets, attached on the Anulus fibrosus of Ostium aortae. A
- 24 *Valvula semilunaris septalis*. Right-caudally situated semilunar cusp facing Septum interatriale. A C
- 25 *Valvula semilunaris dextra*. Cranially situated semilunar cusp facing Ventriculus dexter. A C
- 26 *Valvula semilunaris sinistra*. Left caudally situated semilunar cusp facing the centre of Ventriculus sinister. A C
- 27 *Noduli valvularum semilunarium*. Small elevations near the middle of the free concave margins of Valvulae semilunares. C
- 28 *Lunulae valvularum semilunarium*. Crescentic ridges on the free cusp rims extending on both sides of each Nodus valvulae semilunaris. C
- 29 *Musculus papillaris subauricularis*. Located on the parietal wall, ventral to Auricula sinistra. C
- 30 *Musculus papillaris subatrialis*. Located on the parietal wall, ventral to Atrium sinistrum. C
- 31 *Trabecula septomarginalis*. From Septum interventriculare, branches to the Mm. papillares. C



A Ventriculi cordis (atria removed), dorsal aspect (eq)

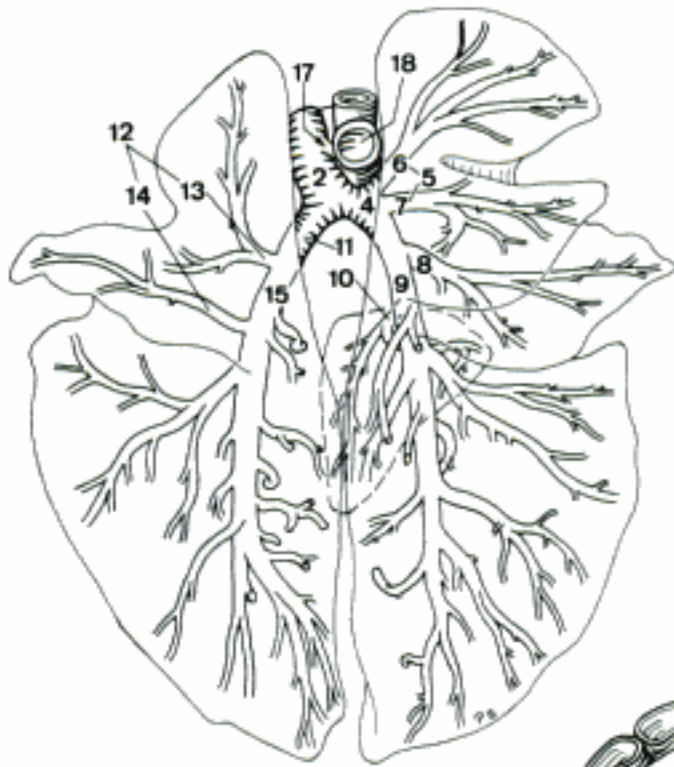

B Ventriculus dexter, opened, cranial aspect (eq)

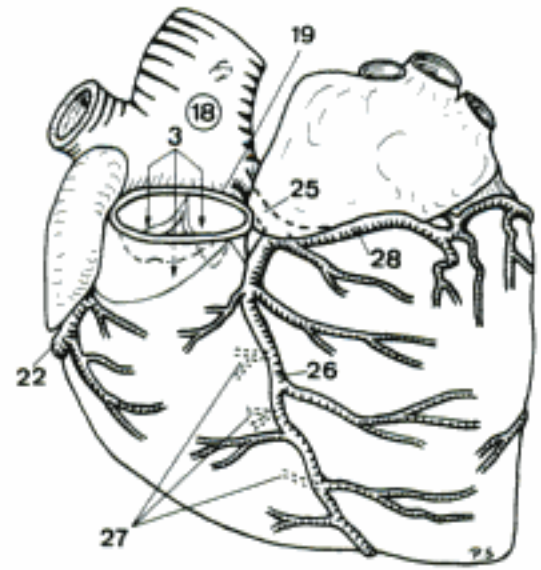


C Atrium sinistrum and Ventriculus sinister, opened, caudal aspect (eq)

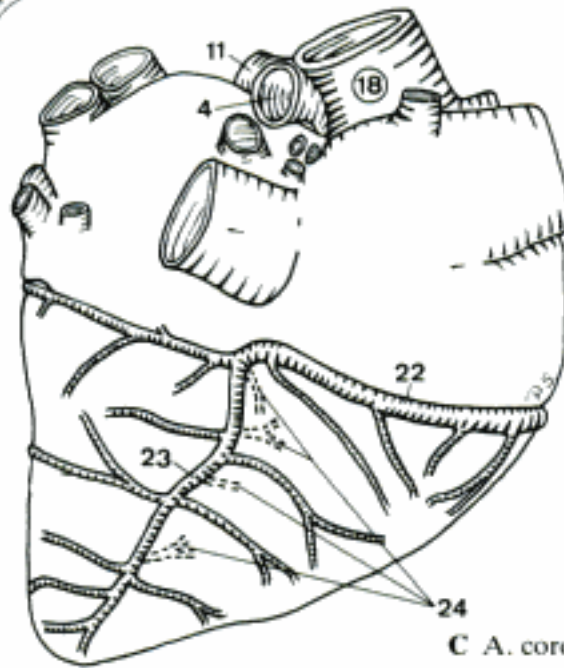
- 1 **ARTERIAE.** Arteries, conveying the blood from the heart to the lungs and the periphery.
- 2 **TRUNCUS PULMONALIS.** Arterial trunk between Conus arteriosus and the beginning of Aa. pulmonales. A E
- 3 *Sinus trunci pulmonalis.* Three dilatations of Truncus pulmonalis, dorsal to the roots of Valvulae semilunares. B D
- 4 **A. pulmonalis dextra.** Passes on the caudal side of Aorta ascendens into the hilus of the right lung, crossing the ventral aspect of trachea. A C
- 5 *Ramus lobi cranialis.* Branch to Lobus cranialis of the right lung. A
- 6 *Ramus ascendens.* To the cranial part of the divided Lobus cranialis. (Ru). A
- 7 *Ramus descendens.* To the caudal part of the divided Lobus cranialis. (Ru). A
- 8 *Ramus lobi medii.* Branch to Lobus medius of the right lung (absent in eq). A
- 9 *Ramus lobi caudalis.* Branch to Lobus caudalis of the right lung. A
- 10 *Ramus lobi accessorii.* Enters Lobus accessorius of the right lung. A
- 11 **A. pulmonalis sinistra.** Enters the hilus of the left lung. A C E
- 12 *Ramus lobi cranialis.* Branch to Lobus cranialis of the left lung. A
- 13 *Ramus ascendens.* To the cranial part of the divided Lobus cranialis (absent in eq). A
- 14 *Ramus descendens.* To the caudal part of the divided Lobus cranialis (absent in eq). A
- 15 *Ramus lobi caudalis.* Branch to Lobus caudalis of the left lung. A
- 16 *Ductus arteriosus* (ont). Patent duct between Truncus pulmonalis and Arcus aortae. E
- 17 *Ligamentum arteriosum.* Fibrous remnant of the fetal Ductus arteriosus. A
- 18 **AORTA.** Main artery of the body. Arises from Ventriculus sinister. A B C E
- 19 **AORTA ASCENDENS.** Craniodorsally directed initial part of aorta. Located within pericardium and continues in Arcus aortae. B
- 20 *Bulbus aortae.* Bulb of the aorta, internally occupied by Sinus aortae. D
- 21 *Sinus aortae.* Three dilatations of the aortic wall, each of them located dorsal to the corresponding Valvula semilunaris. D
- 22 *A. coronaria dextra.* Arises from the Sinus aortae above Valvula semilunaris dextra and follows, subepicardially, the right part of Sulcus coronarius. B C D
- 23 *Ramus interventricularis subsinuus.* Branch of A. coronaria dextra that descends in Sulcus interventricularis subsinuus (su, eq, sometimes fe). C
- 24 **Rami septales.** Run into Septum interventriculare. C
- 25 *A. coronaria sinistra.* Arises from the Sinus aortae above Valvula semilunaris sinistra. B D E
- 26 *Ramus interventricularis paraconalis.* Descends in Sulcus interventricularis paraconalis. B D E
- 27 **Rami septales.** Run into Septum interventriculare. B D
- 28 *Ramus circumflexus.* Continuation of A. coronaria sinistra into the left and caudal parts of Sulcus coronarius, also reaching the right caudal part of it. B D E
- 29 **Ramus intermedius** [marginis ventricularis sinistri]. Branch that descends in the longitudinal groove on Margo ventricularis sinister (Car, su, Ru). D E
- 30 **Ramus interventricularis subsinuus.** Branch of Ramus circumflexus that descends in Sulcus interventricularis subsinuus (Car, Ru, exceptionally eq). D
- 31 **Rami septales.** Arise from the preceding mentioned Ramus interventricularis subsinuus and run into Septum interventriculare. D



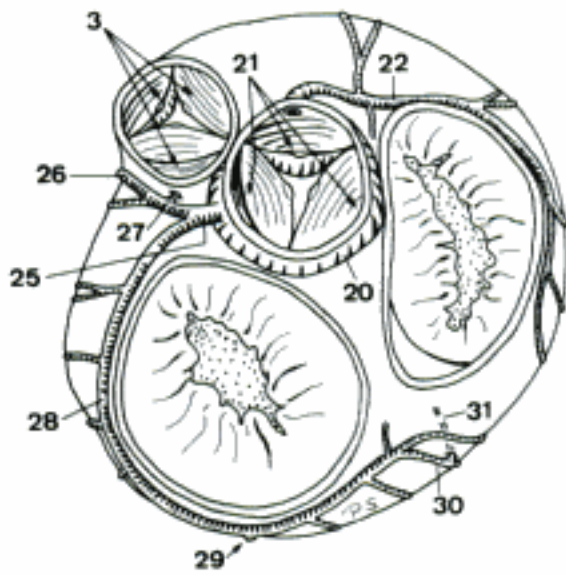
A Truncus pulmonalis, dorsal aspect of horizontally spread lungs (cap)



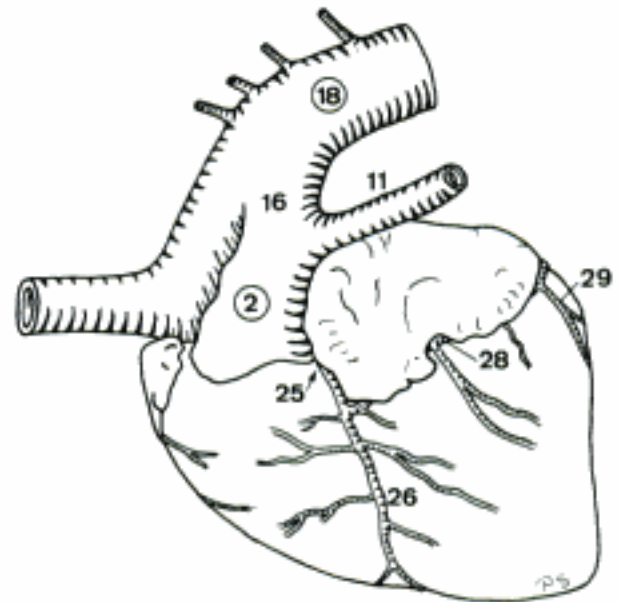
B A. coronaria sinistra (eq)



C A. coronaria dextra (eq)

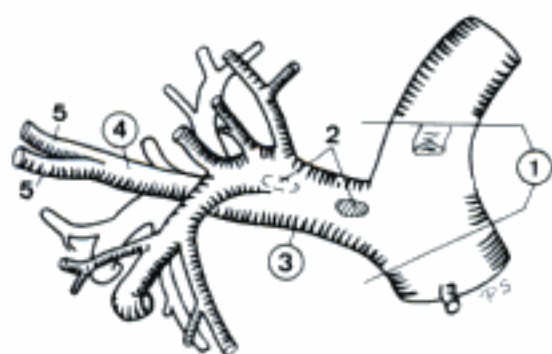


D Heart (atria removed), dorsal aspect (ca)

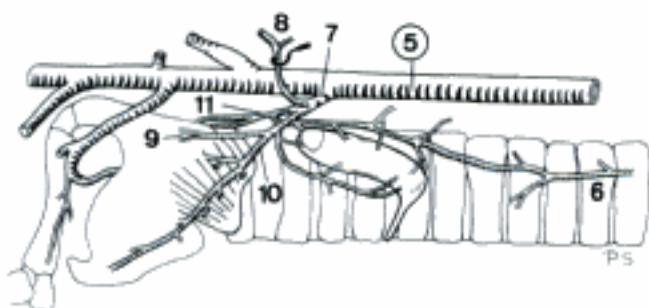


E Facies auricularis of the heart (bo, fetus)

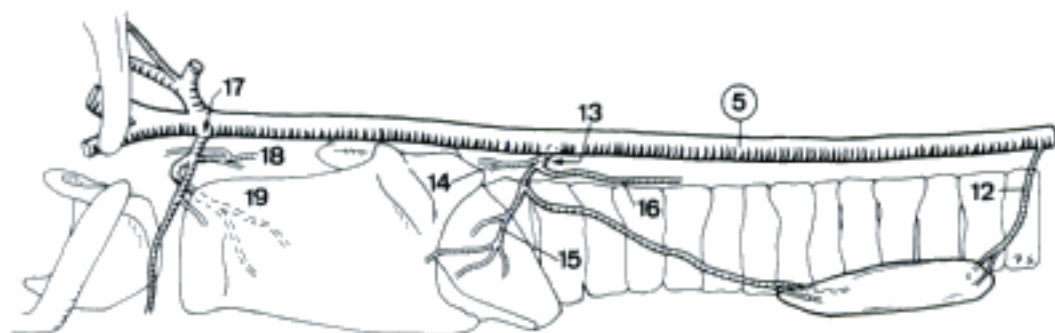
- 1 **ARCUS AORTAE.** Caudodorsally curved segment between Aorta ascendens and Aorta descendens, begins intrapericardially. A
 - 2 *Corpora paraaortica.* Paraganglia, scattered along Arcus aortae and the roots of its great vessels. A
 - 3 **TRUNCUS BRACHIOCEPHALICUS.** Craniodorsally directed large trunk arising from Arcus aortae. Extends to the bifurcation into A. subclavia dextra and Truncus bicaroticus or, the latter being absent, A. carotis communis dextra. A
 - 4 **TRUNCUS BICAROTICUS.** Common trunk for the left and right A. carotis communis. Arises from Truncus brachiocephalicus and is usually (Car) or exceptionally (su, Ru, eq) absent. A
 - 5 **ARTERIA CAROTIS COMMUNIS.** Cranially directed bilateral stem for A. carotis externa and A. carotis interna. Arises from Truncus brachiocephalicus via the occasional Truncus bicaroticus. A B C D E
- CARNIVORA
- 6 **A. thyroidea [thyroidea] caudalis.** Rarely present and variably arising artery that runs cranially towards the caudal part of Gl. thyroidea. B
 - 7 **A. thyroidea [thyroidea] cranialis.** Curves branched to the cranial pole of Gl. thyroidea. B
 - 8 *Ramus sternocleidomastoideus.* To M. sternocephalicus and M. cleidomastoideus. B
 - 9 *Ramus pharyngeus.* Courses craniodorsally and supplies Mm. constrictores pharyngis. B
 - 10 *Ramus cricothyroideus [-thyroideus].* Runs craniocaudally, branches enter the M. cricothyroideus. B
 - 11 *Ramus laryngeus caudalis.* Runs parallel to N. laryngeus caudalis and enters larynx from caudally. B
- SUS
- 12 **A. thyroidea [thyroidea] caudalis sinistra.** Penetrates into the caudal pole of Gl. thyroidea. Inconstant. C
 - 13 **A. thyroidea [thyroidea] cranialis.** Branches enter the cranial part of Gl. thyroidea. Inconstant. C
 - 14 *Ramus pharyngeus.* Cranially directed supply for Mm. constrictores pharyngis caudales. C
 - 15 *Ramus cricothyroideus [-thyroideus].* To M. cricothyroideus. C
 - 16 *Ramus laryngeus caudalis.* Passes caudally, accompanying N. laryngeus caudalis. C
 - 17 **A. laryngea cranialis.** Arises close to the terminal division of A. carotis communis and accompanies N. laryngeus cranialis to larynx. C
 - 18 *Ramus pharyngeus.* To Mm. constrictores pharyngis caudales. C
 - 19 *Ramus laryngeus.* Continuation of A. laryngea cranialis that enters larynx cranially and reaches the medial aspect of Cartilago thyroidea. C
- RUMINANTIA
- 20 **Rami sternocleidomastoidei.** Variably originated branches for M. sternomastoideus and M. cleidomastoideus. D E
 - 21 **A. thyroidea [thyroidea] caudalis.** Enters the caudal pole of Gl. thyroidea. Inconstant. D E
 - 22 **A. thyroidea [thyroidea] cranialis.** Curves to the cranial pole of Gl. thyroidea, branches enter it. D E
 - 23 *Ramus pharyngeus.* To the pharyngeal wall. D E
 - 24 *Ramus cricothyroideus [-thyroideus] (bo, ov).* Supplies M. cricothyroideus. D E
 - 25 *Ramus laryngeus caudalis.* Runs parallel to N. laryngeus caudalis and enters larynx between Cartilago thyroidea and Cartilago cricoidea. D E
 - 26 **A. laryngea cranialis.** Runs craniocaudally to larynx. D E
 - 27 *Ramus pharyngeus.* For the pharyngeal wall and its constrictor musculature. D E
 - 28 *Ramus laryngeus.* Continuation of the parent stem that enters larynx. D E
 - 29 **A. pharyngea ascendens.** Runs craniomedially to the dorsal wall of pharynx. D E
 - 30 *Rami palatini (bo).* To Palatum molle. D
 - 31 *Rami tonsillares (bo).* Pass to Tonsillae. D
 - 32 *Rami pharyngei.* Small branches supplying the pharyngeal wall and its musculature. D E
 - 33 **A. palatina ascendens (ov, cap).** Courses craniomedially to Palatum molle. E



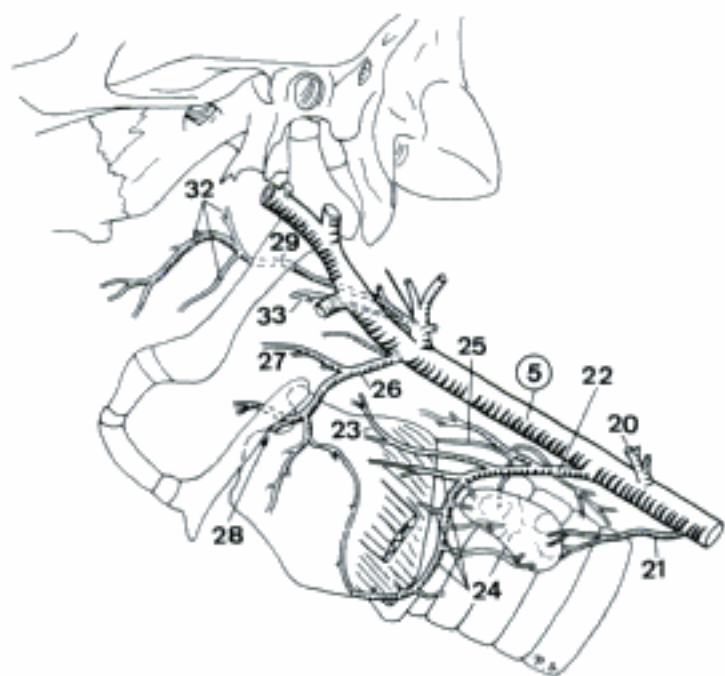
A Arcus aortae, left aspect (cq)



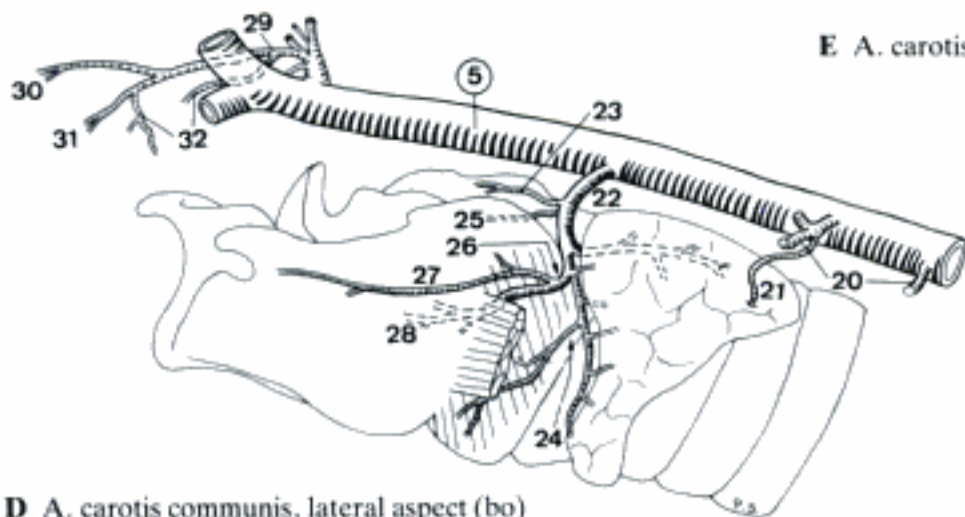
B Left Aa. thyroideae, lateral aspect (ca)



C A. carotis communis, lateral aspect (su)



D A. carotis communis, lateral aspect (bo)



E A. carotis communis, lateral aspect (ov)

EQUUS

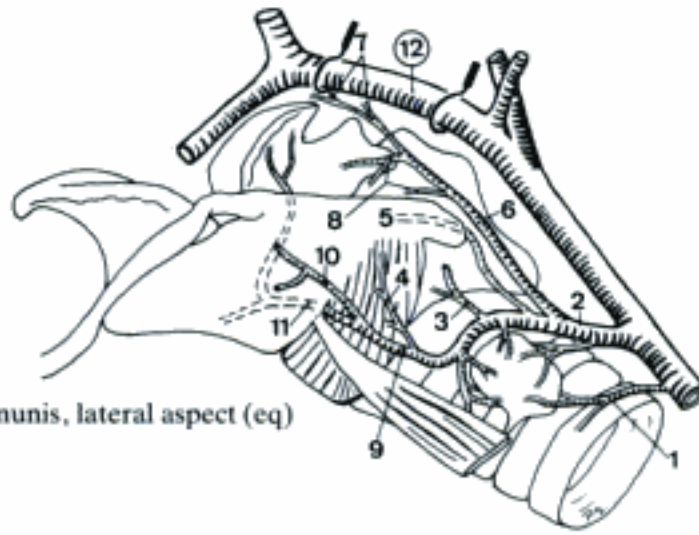
- 1 **(A. thyroidea [thyroidea] caudalis).** Inconstant vessel which sends branches into the caudal part of Gl. thyroidea. A
- 2 **A. thyroidea [thyroidea] cranialis.** Curves around the cranial pole of Gl. thyroidea into which it sends several branches. A
- 3 *Ramus pharyngeus.* Courses cranially into the caudal part of the pharyngeal wall. A
- 4 *Ramus cricothyroideus [-thyroideus].* To M. cricothyroideus. A
- 5 *Ramus laryngeus caudalis.* Runs parallel to N. laryngeus caudalis to the larynx. A
- 6 *A. pharyngea ascendens.* Passes dorsocranially into the pharyngeal musculature. A
- 7 *Rami palatini.* To Palatum molle. A
- 8 *Rami pharyngei.* Enter the caudal half of pharyngeal wall. A
- 9 *A. laryngea cranialis.* Courses cranioventrally to larynx. A
- 10 *Ramus pharyngeus.* To Mm. constrictores pharyngis. A
- 11 *Ramus laryngeus.* Enters larynx between Cartilagine thyroidea and cricoidea. A
- 19 *Ramus pharyngeus.* Dorsally directed supply for Mm. hyo-, thyro-, and cricopharyngei. B
- 20 *Ramus laryngeus.* Enters larynx through Fissura thyroidea. B
- 21 **A. pharyngea ascendens.** Runs dorsorostally to the medial aspect of Bulla tympanica and anastomoses with A. carotis interna. B D
- 22 *Rami palatini.* To Palatum molle. May be singular in fe. D
- 23 *Rami pharyngei.* Primarily to the cranial part of pharynx. D
- 24 **A. lingualis.** Courses rostroventrally and enters the tongue between Os hyoideum and M. hyoglossus. B D
- 25 *A. palatina ascendens.* Usually represented by two small vessels, supplies Radix linguae, Palatum molle and the adjacent part of pharynx. B D
- 26 *Rami perihyoidei.* Supply the structures around Os hyoideum and Tonsilla palatina. B D
- 27 *A. profunda linguae.* Rostral continuation of A. lingualis, coursing on the lateral aspect of M. genioglossus towards Apex linguae. D
- 28 *Rami dorsales linguae.* Run flexuously to Dorsum linguae. D
- 29 **A. facialis.** Courses cranioventrally, crosses Margo ventralis of Mandibula and ascends along the rostral border of M. masseter. B C
- 30 *Ramus glandularis.* To Gl. mandibularis and Gl. sublinguales. B
- 31 *A. sublingualis.* Courses rostrally along the medial aspect of Margo ventralis of Mandibula and ramifies on the floor of the mouth after piercing M. mylohyoideus. B C D
- 32 *A. submentalis.* Follows Margo ventralis of Mandibula ventral to M. mylohyoideus to the chin. C D
- 33 *A. labialis inferior.* Passes rostrally to the lower lip. B C
- 34 *Aa. angulares oris.* Run to Angulus oris. C
- 35 *A. labialis superior.* Courses rostrally to the upper lip. C
- 36 *Ramus anastomoticus cum a. infraorbitali.* Connection to A. infraorbitalis. C
- 37 *A. angularis oculi (fe).* Curves caudo-dorsally towards Angulus oculi medialis. C

TERMINUS COMMUNIS

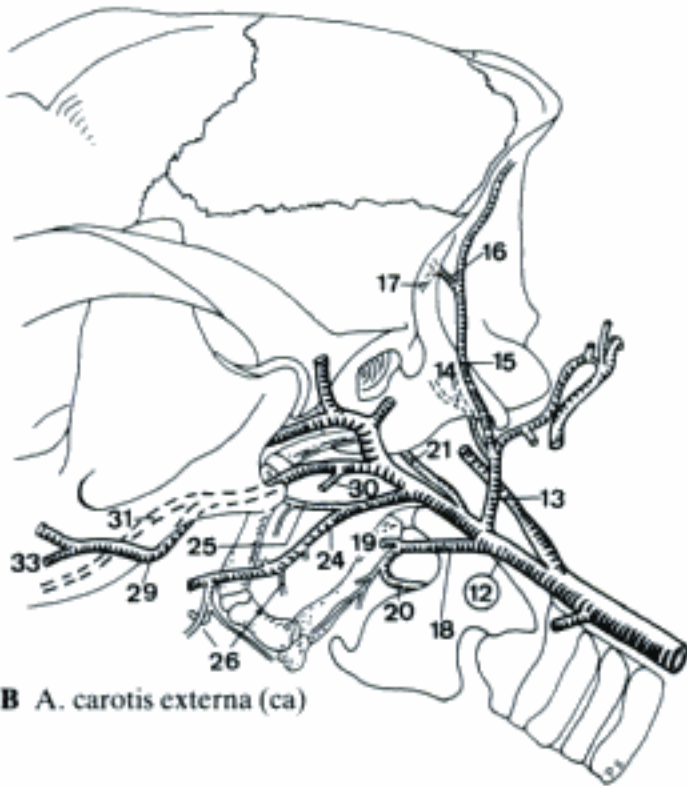
- 12 **A. CAROTIS EXTERNA.** Continuation of A. carotis communis beyond the origin of A. carotis interna (Car, su, eq) or A. occipitalis (adult Ru). A B D

CARNIVORA

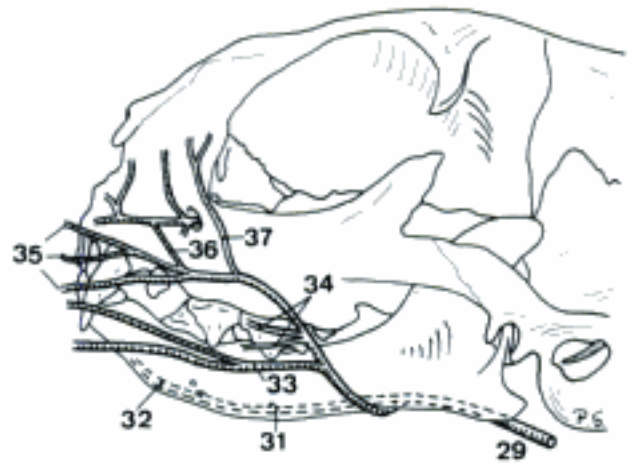
- 13 **A. occipitalis.** Extends dorsally to the neck and the occipital region of the skull. B D
- 14 *A. condylaris.* Courses in Fossa condylaris ventralis and reaches Cavum cranii through Canalis n. hypoglossi and Foramen jugulare. B
- 15 *Ramus occipitalis.* Branched continuation of A. occipitalis beyond the contact with Ramus anastomoticus cum a. occipitali from A. vertebralis. B
- 16 *A. meningea caudalis (ca).* Enters Meatus temporalis via Foramen mastoideum and reaches Cavum cranii where it ramifies in Dura mater encephali. B
- 17 *A. tympanica caudalis.* Supplies Auris media and Auris interna. B
- 18 **A. laryngea cranialis.** Courses ventrally towards larynx. B D



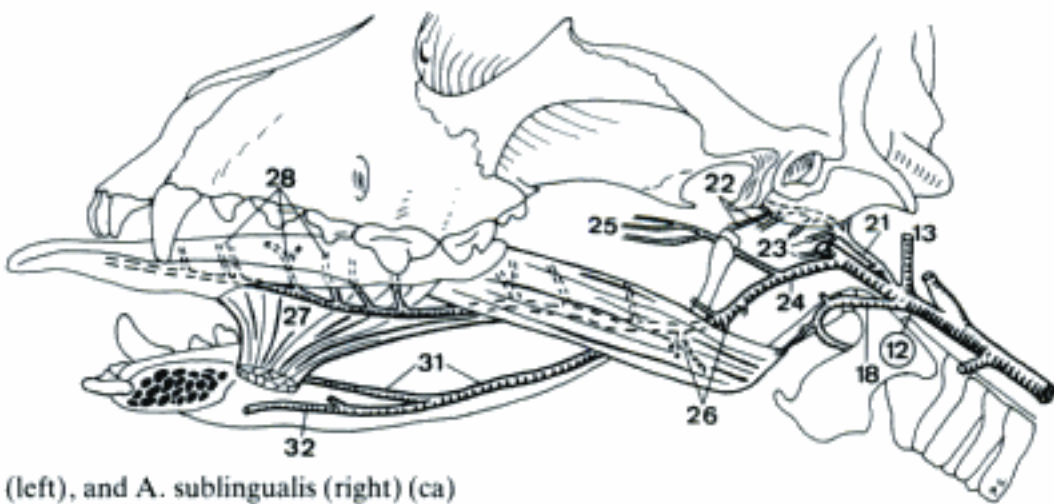
A A. carotis communis, lateral aspect (eq)



B A. carotis externa (ca)

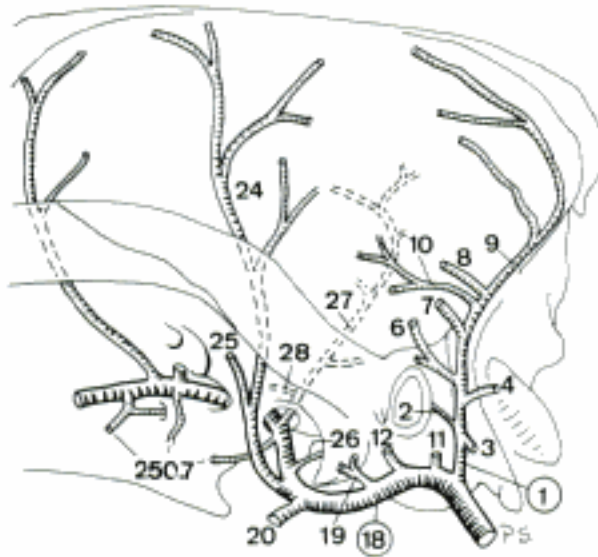


C A. facialis (fe)

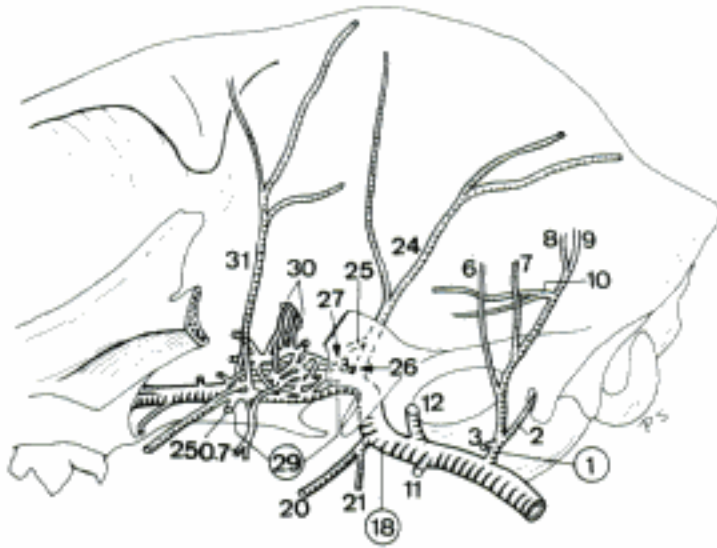


D A. lingualis (left), and A. sublingualis (right) (ca)

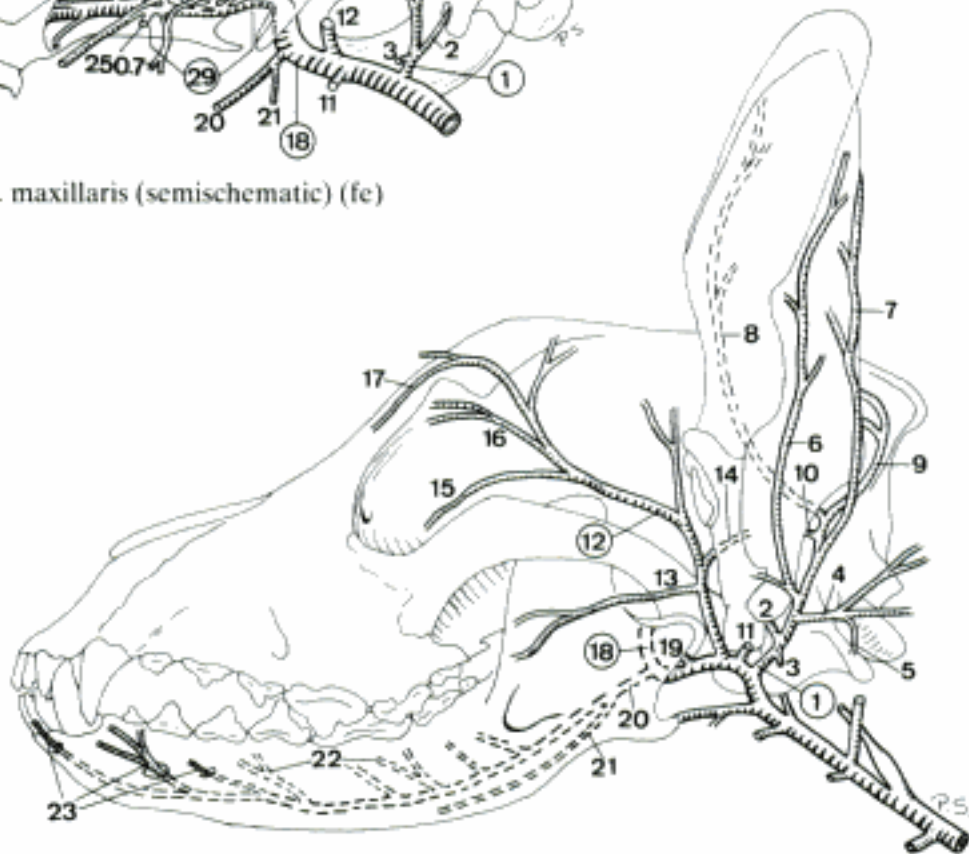
- 1 **A. auricularis caudalis.** Circles around the caudal part of the base of the ear. A B C
- 2 *A. stylomastoidea.* Enters Foramen stylomastoideum, passes to Auris media. A B C
- 3 *Ramus parotideus.* Variable branch for Gl. parotis. A B C
- 4 *Ramus sternocleidomastoideus (ca).* Occasionally double branch to the conjoined tendons of M. sternomastoideus and M. cleidomastoideus. A C
- 5 *Ramus glandularis.* To Gl. mandibularis. C
- 6 *Ramus auricularis lateralis.* On Dorsum auriculae along Margo antitragicus. Frequently double (esp. fe). A B C
- 7 *Ramus auricularis intermedius.* Runs in the middle of Dorsum auriculae. A B C
- 8 *Ramus auricularis medialis.* On Dorsum auriculae along Margo tragicus. A B C
- 9 *Ramus occipitalis.* Enters the caudal border of M. temporalis. A B C
- 10 *A. auricularis profunda.* Sends branches to the internal surface of Auris externa and ramifies in Mm. auriculares and M. temporalis. A B C
- 11 **A. parotidea.** Main vessel to Gl. parotis. A B C
- 12 **A. temporalis superficialis.** Courses dorsally, bends rostrally. A B C
- 13 *A. transversa faciei.* Emerges from the medial aspect of Gl. parotis, continues rostrally. C
- 14 *A. auricularis rostralis.* Courses between Gl. parotis and M. temporalis to Auricula. C
- 15 *A. palpebralis inferior lateralis.* Enters Palpebra inferior from lateral. C
- 16 *A. palpebralis superior lateralis.* Enters Palpebra superior from lateral. C
- 17 *A. dorsalis nasi caudalis (ca).* Runs rostrally to Regio dorsalis nasi. C
- 18 **A. maxillaris.** Traverses Canalis alaris (ca) to Fossa pterygopalatina. A B C
- 19 *Ramus articularis temporomandibularis.* Sometimes plural. A C
- 20 *A. alveolaris interior.* Courses between Ramus mandibulae and M. pterygoideus medialis, enters Canalis mandibulae. A B C
- 21 *Ramus mylohyoideus.* To M. mylohyoideus. B C
- 22 *Rami dentales.* Branches for teeth. C
- 23 *Rami mentales.* Emerge through Foramina mentalia. C
- 24 *A. temporalis profunda caudalis.* To M. temporalis. A B
- 25 *A. masseterica.* Passes through Incisura mandibulae to M. masseter. A B
- 26 *A. tympanica rostralis.* Passes to Auris media through Fissura petrotympanica. A B
- 27 *A. meningea media.* Passes through Foramen ovale, Incisura spinosa, or Foramen spinosum to Dura mater. A B
- 28 *Ramus anastomoticus cum a. carotide interna.* Joins the homonymous branch of A. ophthalmica externa (ca) or Rami retis (fe), to reach A. carotis interna. A
- 29 *Rete mirabile a. maxillaris (fe).* Extracranial network formed by A. maxillaris. B
- 30 *Rami retis.* Pierce through Fissura orbitalis to Circulus arteriosus cerebri directly or by joining A. carotis interna. B
- 31 *A. temporalis profunda rostralis.* Ramifies in M. temporalis. B
- 32 *Ramus anastomoticus cum a. ophthalmica interna.* Joins A. ophthalmica interna medial to N. opticus. 251 A
- 33 *A. centralis retinae.* Collective term for the extrabulbar stem vessels of Arterio-lae retinae.
- 34 *Aa. ciliares posteriores longae.* Lateral and medial, perforate anterior part of sclera, supply Tunica vasculosa bulbi. 251 A
- 35 *Aa. ciliares posteriores breves.* Penetrate sclera near Area cribrosa, supply Choroidea. 251 A
- 36 *Aa. episclerales.* On the external surface of sclera.
- 37 *Rami musculares.* Primarily for Mm. bulbi. 251 A
- 38 *Aa. ciliares anteriores.* Penetrate sclera near Sulcus sclerae, supply Tunicae fibrosa and vasculosa bulbi.
- 39 *Aa. episclerales.* Course on the outer surface of sclera.
- 40 *Aa. conjunctivales posteriores.* To Tunica conjunctiva.



A *A. maxillaris*, lateral aspect (ca)

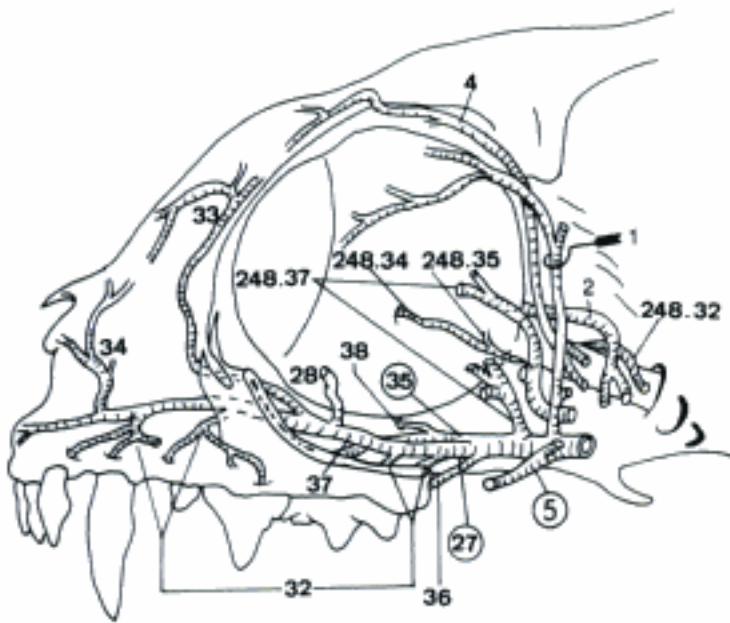


B *A. maxillaris* (semischematic) (fe)

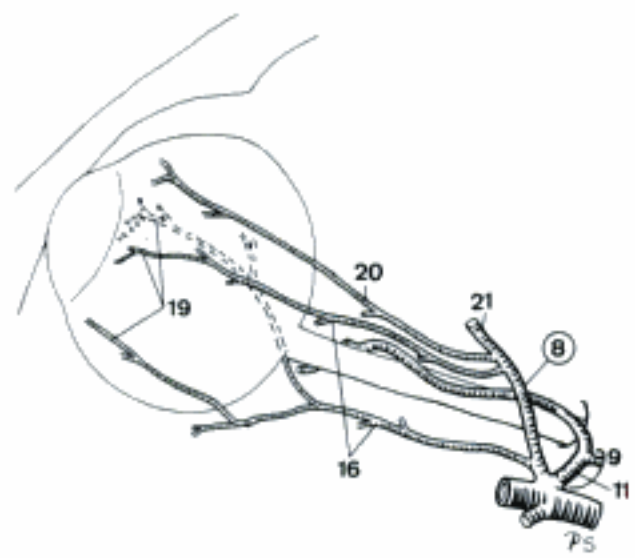


C Branches of *A. carotis externa* (ca)

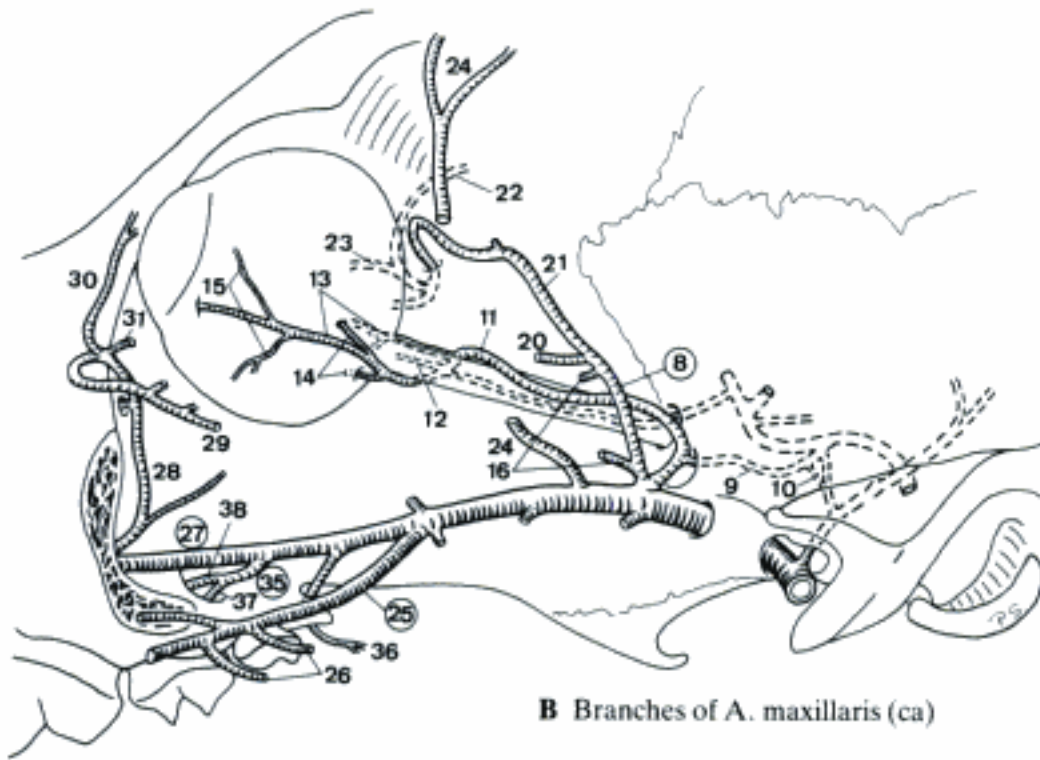
- 1 *A. lacrimalis*. Accompanies N. lacrimalis to Gl. lacrimalis. A
- 2 *A. ethmoidalis externa*. Courses into Cavum cranii via Foramen ethmoidale. A
- 3 Aa. nasales septales caudales. Pass through Lamina cribrosa into Cavum nasi.
- 4 *A. supraorbitalis*. Perforates periorbita and crosses the dorsomedial border of orbita. A
- 5 *A. buccalis*. Courses ventrorostrally to the cheek. A
- 6 Rami glandulares zygomatici. To Gl. zygomatica.
- 7 *Rami pterygoidei*. Variable branches to Mm. pterygoidei. 249 A B
- 8 *A. ophthalmica externa (ca)*. Leaves A. maxillaris rostral to Canalis alaris, enters periorbita and runs rostradorsally. B C
- 9 *Ramus anastomoticus cum a. carotide interna*. Pierces through Fissura orbitalis into Cavum cranii, anastomoses with A. carotis interna. B C
- 10 *Ramus anastomoticus cum a. meningea media*. Intracranially arisen branch to *Ramus anastomoticus cum a. carotide interna* of A. meningea media. B
- 11 *Ramus anastomoticus cum a. ophthalmica interna*. See 248.32. B C
- 12 A. centralis retinae. See 248.33. B
- 13 Aa. ciliares posteriores longae. See 248.34. B
- 14 Aa. ciliares posteriores breves. See 248.35. B
- 15 Aa. episclerales. See 248.36. B
- 16 *Rami musculares*. See 248.37. B C
- 17 Aa. ciliares anteriores. See 248.38
- 18 Aa. episclerales. See 248.39
- 19 Aa. conjunctivales posteriores. See 248.40 C
- 20 *A. lacrimalis*. See 1. B C
- 21 *A. ethmoidalis externa*. See 2. B C
- 22 A. meningea rostralis. Ramifies in dura at the caudal margin of Lamina cribrosa. B
- 23 Aa. nasales septales caudales. See 3. B
- 24 *A. temporalis profunda rostralis (ca)*. Enters M. temporalis near the middle of its rostral border. B
- 25 *A. buccalis (ca)*. See 5. B
- 26 *Rami glandulares zygomatici*. See 6. B
- 27 *A. infraorbitalis*. Enters Canalis infraorbitalis via Foramen maxillare and emerges through Foramen infraorbitale. A B D
- 28 *A. malaris*. Passes dorsorostrally to Angulus oculi medialis. A B D
- 29 A. palpebralis inferior medialis. Enters the medial part of Palpebra inferior. B D
- 30 A. palpebralis superior medialis. Supplies the medial part of Palpebra superior. B D
- 31 A. palpebrae tertiae. To Plica semilunaris conjunctivae. B D
- 32 *Rami dentales*. To the superior teeth. A D
- 33 *A. dorsalis nasi rostralis*. Passes through Canalis infraorbitalis (fe) and runs rostradorsally to Regio dorsalis nasi. A D
- 34 *A. lateralis nasi*. To Regio lateralis nasi and Labium superius. A D
- 35 *A. palatina descendens*. Rostroventral continuation of A. maxillaris at the rostral end of Fossa pterygopalatina. A B D
- 36 *A. palatina minor*. Courses to Palatum durum and Palatum molle. A B D
- 37 *A. palatina major*. Traverses Canalis palatinus major and continues rostrally inside Sulcus palatinus. A B D
- 38 *A. sphenopalatina*. Courses towards Cavum nasi via Foramen sphenopalatinum. A B D
- 39 Aa. nasales caudales, laterales et septales. To Cavum nasi. D



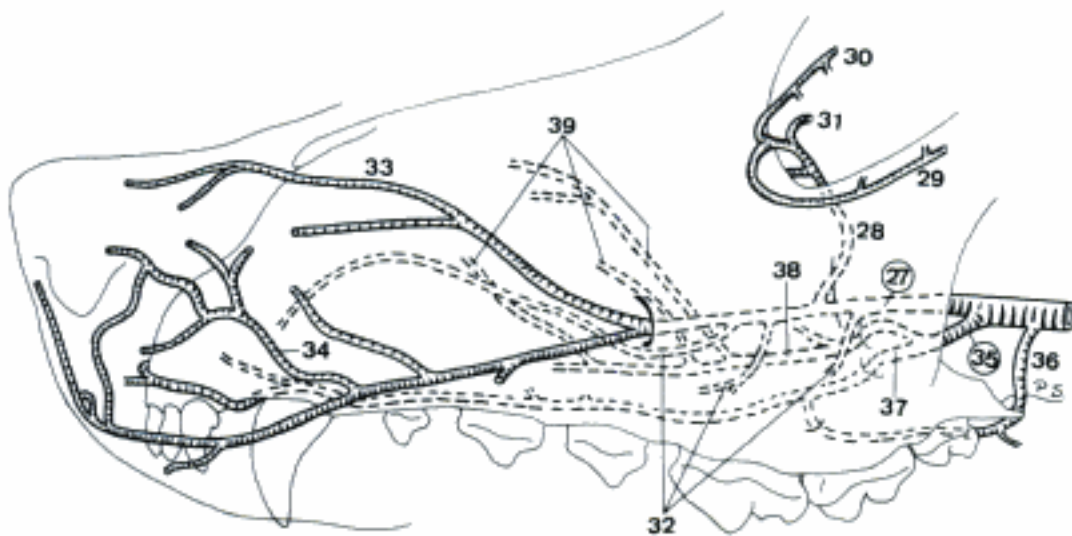
A Branches of *A. Carotis externa* (fe)



C *A. ophthalmica externa*, lateral aspect (ca)



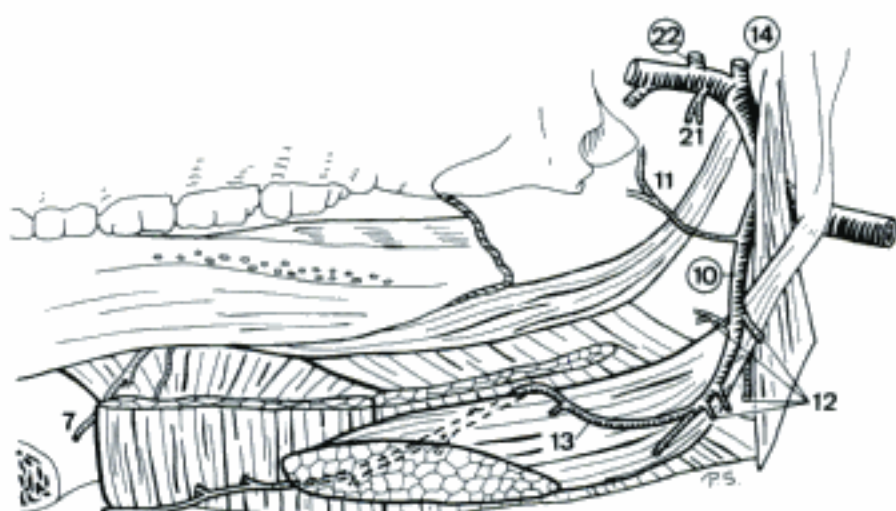
B Branches of *A. maxillaris* (ca)



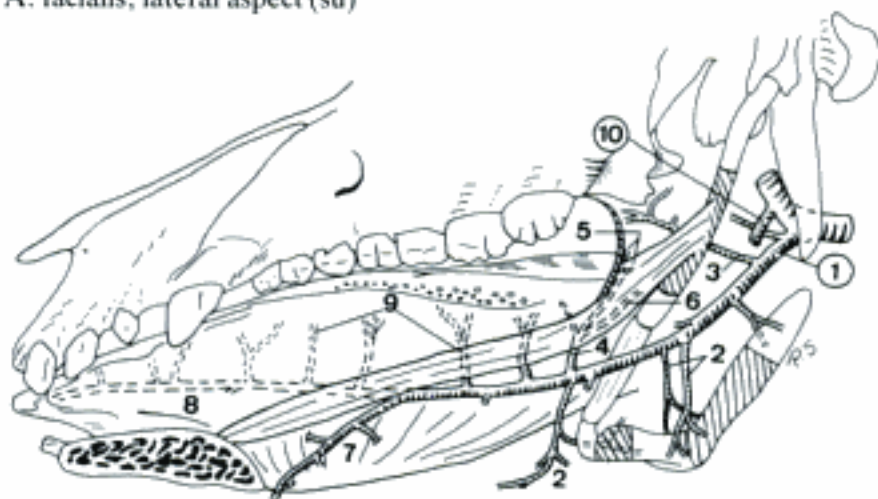
D Terminal branches of *A. maxillaris* (ca)

SUS

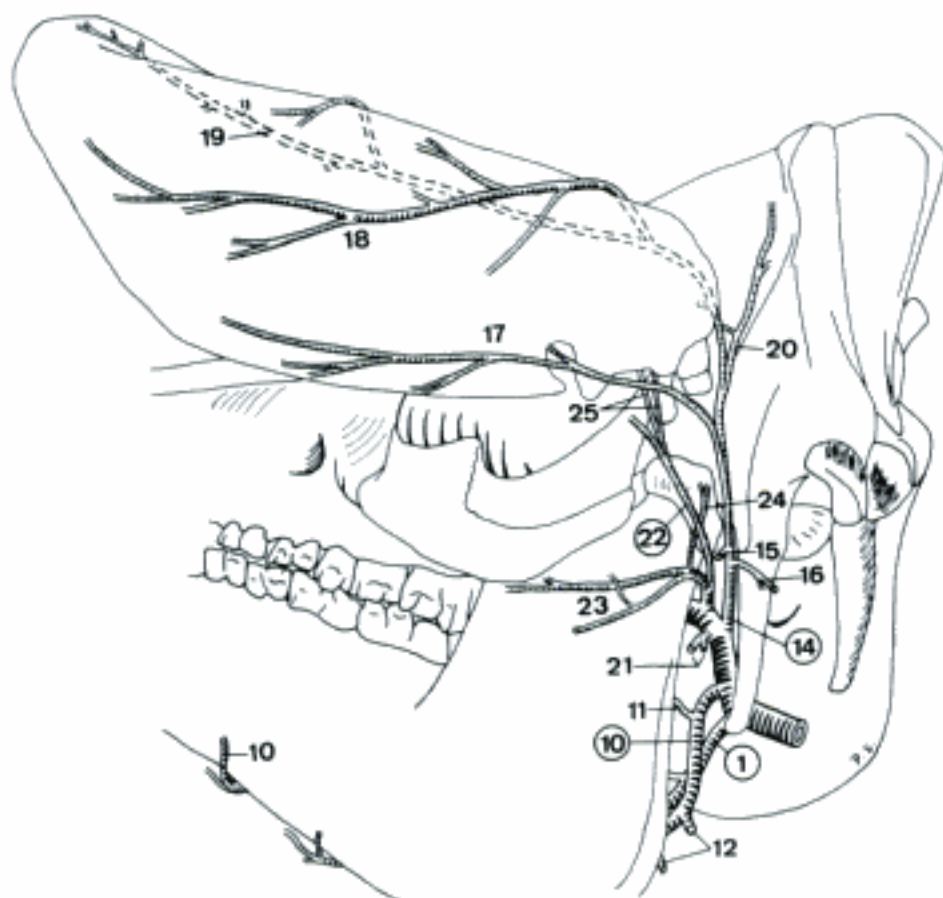
- 1 **A. lingualis.** Enters the tongue between Os hyoideum and M. hyoglossus. B C
- 2 *Rami perihyoidei.* Branching vessels around Os hyoideum. Mainly tend to the median plane. B
- 3 *A. palatina ascendens.* Courses at the medial aspect of Stylohyoideum into Palatum molle and its musculature. B
- 4 *A. pharyngea ascendens.* Dorsally directed vessel which may be double. B
- 5 *Rami palatini.* Supply Mm. palati. B
- 6 *Rami pharyngei.* Ramify in the pharyngeal wall. B
- 7 *A. sublingualis.* Runs rostrally over the lateral aspect of M. genioglossus at the dorsal border of M. geniohyoideus and supplies the floor of the mouth and Gl. sublingualis polystomatica. A B
- 8 *A. profunda linguae.* Flexuous rostral continuation of A. lingualis along the lateral aspect of M. genioglossus. B
- 9 *Rami dorsales linguae.* Course on the medial aspect of M. hyoglossus and M. styloglossus towards Dorsum linguae. B
- 10 **A. facialis.** Runs rostroventrally and enters with plural branches the ventral part of M. masseter after crossing Margo ventralis of Mandibula. A B C
- 11 *Ramus pharyngeus.* To the lateral pharyngeal wall. A C
- 12 *Rami glandulares.* To Gl. mandibularis, Gl. parotis and Gl. sublingualis monostomatica. A C
- 13 *A. submentalis.* Courses rostrally on the ventrolateral aspect of M. mylohyoideus. A
- 14 **A. auricularis caudalis.** Runs dorsally to the caudal aspect of the ear and ramifies variably. A C
- 15 *Ramus parotideus.* To Gl. parotis. C
- 16 *Ramus sternocleidomastoideus.* To M. cleidocephalicus and M. sternomastoideus. C
- 17 *Ramus auricularis lateralis.* Courses apically on Dorsum auriculae, following Margo antitragicus. C
- 18 *Ramus auricularis intermedius.* Runs towards Apex auriculae on the middle of Dorsum auriculae. C
- 19 *Ramus auricularis medialis.* Courses apically on Dorsum auriculae along Margo tragicus. C
- 20 *A. auricularis profunda.* Ramifies in Mm. auriculares and M. temporalis and also supplies the surface of Auris externa. C
- 21 **Rami parotidei.** To Gl. parotis. A C
- 22 **A. temporalis superficialis.** Courses dorsally across the lateral aspect of Arcus zygomaticus. A C
- 23 *A. transversa faciei.* Crosses Collum mandibulae laterally and continues rostrally. C
- 24 *Ramus articularis temporomandibularis.* Courses dorsally to Articulatio temporomandibularis. C
- 25 *Aa. auriculares rostrales.* Run caudally to Meatus acusticus externus and supply Mm. auriculares and the internal surface of Auris externa. C



A A. facialis, lateral aspect (su)

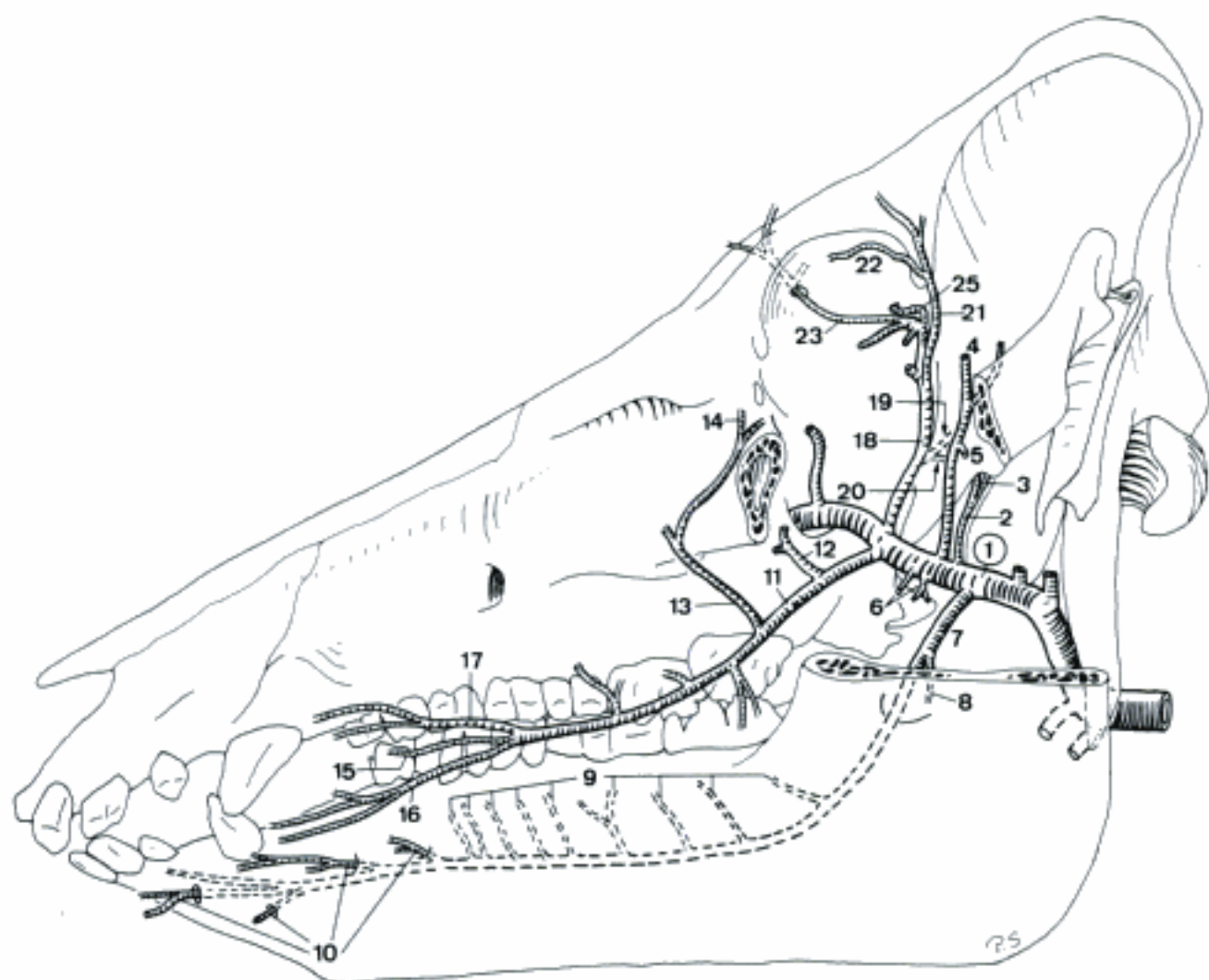


B A. lingualis, lateral aspect (su)

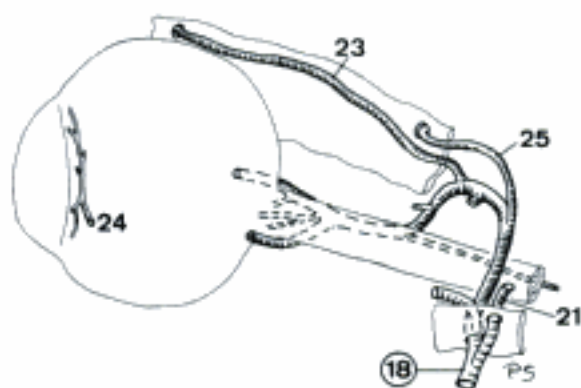


C Branches of A. carotis externa, caudolateral aspect (su)

- 1 **A. maxillaris.** Pursues a flexuous course to Fossa pterygopalatina. A
- 2 *A. meningea media.* Passes caudomedially through Incisura spinosa into dura. A
- 3 *Ramus ad rete mirabile epidurale rostrale.* Concurs in the formation of Rete mirabile epidurale rostrale. A
- 4 *A. temporalis profunda caudalis.* Crosses the medial aspect of Arcus zygomaticus and enters M. temporalis. A
- 5 *A. masseterica.* Passes via Incisura mandibulae into M. masseter. A
- 6 *Rami pterygoidei.* Branches for the homonymous muscles. A
- 7 *A. alveolaris inferior.* Runs rostroventrally and enters through Foramen mandibulae in Canalis mandibulae. A
- 8 *Ramus mylohyoideus.* Branch for M. mylohyoideus. A
- 9 *Rami dentales.* To the mandibular teeth. A
- 10 *Rami mentales.* Emerge via Foramina mentalia lateralia and ramify in Regio mentalis and Labium inferius. A
- 11 *A. buccalis.* Courses between Tuber maxillae and Ramus mandibulae to the cheek and ramifies at the rostral border of M. masseter. A
- 12 *A. temporalis profunda rostralis.* Passes dorsally into M. temporalis. A
- 13 *A. angularis oculi.* Runs rostradorsally and curves then caudodorsally to Angulus oculi medialis. A
- 14 *A. palpebralis inferior medialis.* Runs to the medial part of Palpebra inferior and supplies it. A
- 15 *A. angularis oris.* Passes rostroventrally to Angulus oris. A
- 16 *A. labialis inferior.* Runs rostroventrally to supply Labium inferius and Gl. buccales ventrales. A
- 17 *A. labialis superior.* Supplies Labium superius and Gl. buccales dorsales. A
- 18 *A. ophthalmica externa.* Pierces through periorbita and passes between Mm. recti dorsalis and lateralis to the dorsal aspect of M. retractor bulbi. A B
- 19 *A. meningea rostralis.* Enters Foramen orbitorotundum to supply dura. A
- 20 *Ramus ad rete mirabile epidurale rostrale.* Intracranially arisen branch that concurs in the formation of Rete mirabile epidurale rostrale. A
- 21 *A. supratrochlearis.* Pierces through periorbita, curves upon Mm. bulbi and perforates the periorbita again to reach Processus zygomaticus of Os frontale. A B
- 22 *A. palpebralis superior medialis.* Courses medially along the rostral aspect of Processus zygomaticus and supplies the medial part of Palpebra superior. A
- 23 *A. supraorbitalis.* Penetrates through periorbita into Canalis supraorbitalis and may emerge through Foramen supraorbitale. A B
- 24 *Aa. ciliares anteriores.* Perforate sclera near Sulcus sclerae and supply Tunica vasculosa bulbi. B
- 25 *A. ethmoidalis externa.* Perforates periorbita, enters Cavum cranii via Foramen ethmoidale and comes through Lamina cribrosa towards Cavum nasi. A B

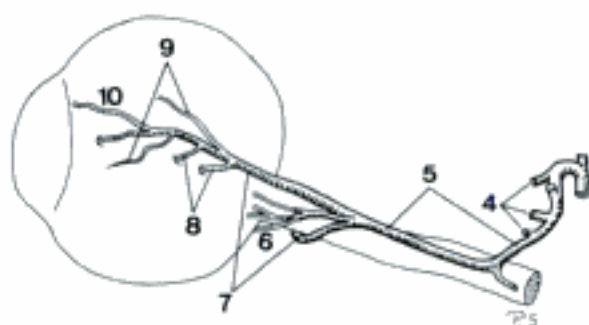


A A. maxillaris (su)

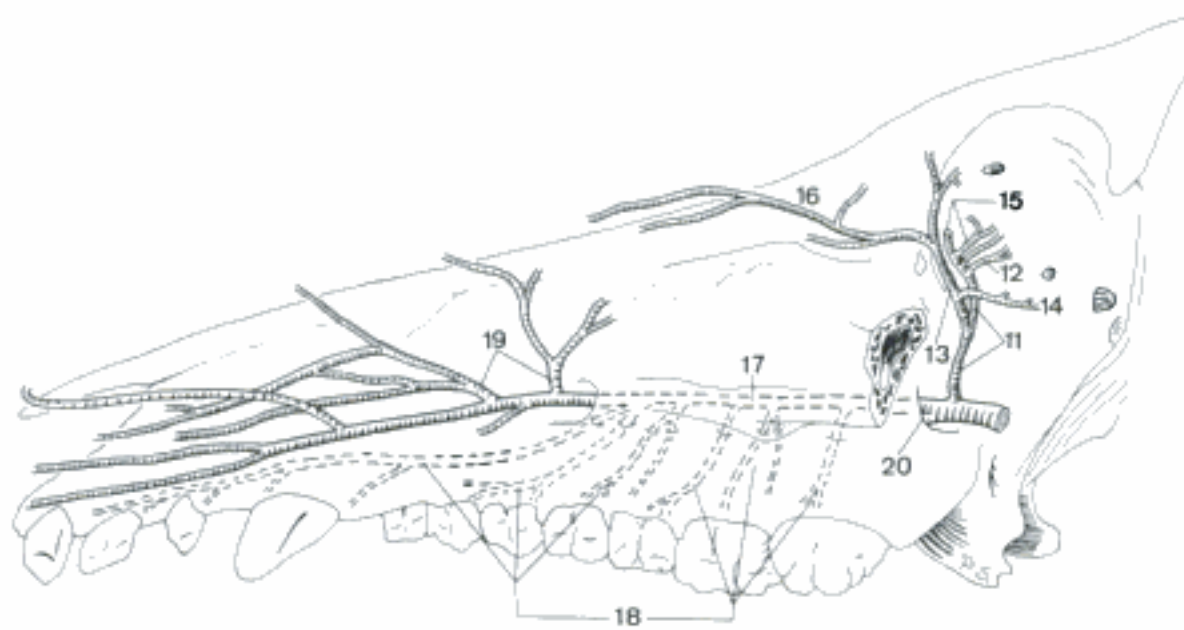


B A. ophthalmica externa (periorbita partly represented), lateral aspect (su)

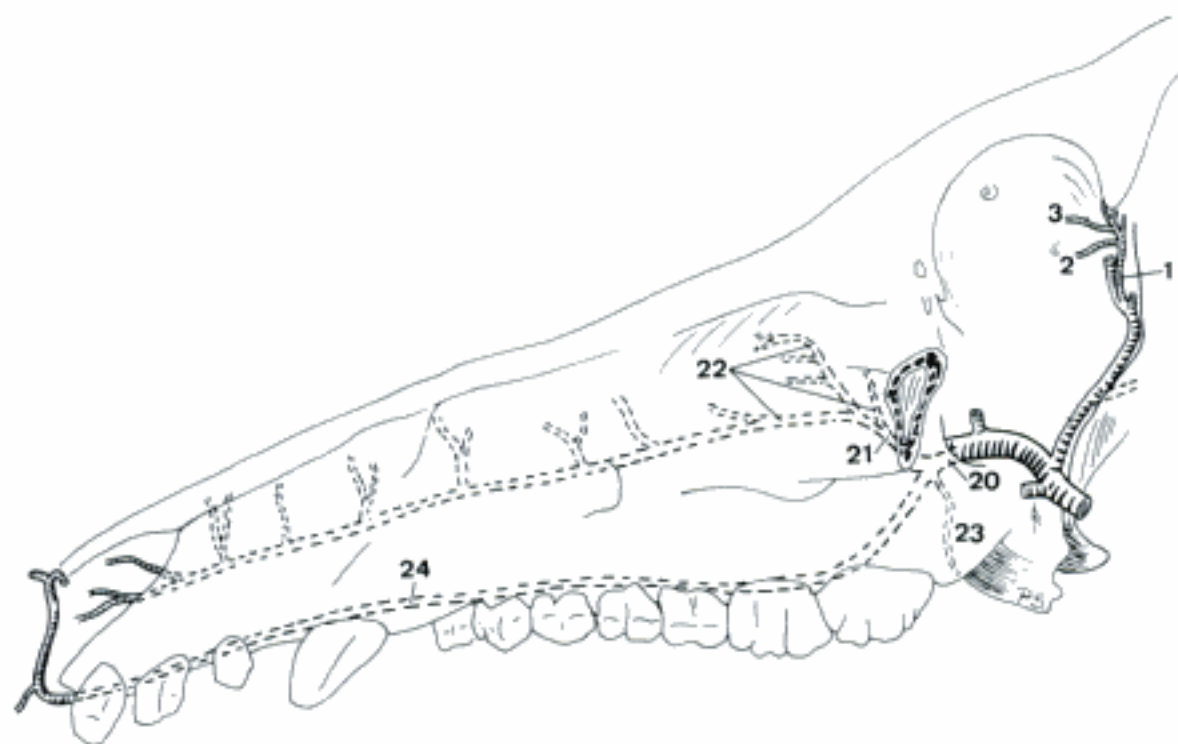
- 1 *A. lacrimalis*. Courses rostr dorsally within periorbita to Gl. lacrimalis. C
- 2 *A. palpebralis inferior lateralis*. Enters Palpebra inferior from lateral. C
- 3 *A. palpebralis superior lateralis*. Courses to the lateral aspect of Palpebra superior. C
- 4 *Rami musculares*. Variable branches for Mm. bulbi. A
- 5 *Ramus anastomoticus cum a. ophthalmica interna*. Joins *A. ophthalmica interna* on the medial aspect of Nervus opticus and continues rostrally. A
- 6 *A. centralis retinae*. Collective term for the extrabulbar stem vessels of the Arteriolae retinae. A
- 7 *Aa. ciliares posteriores longae*. Pair of vessels which perforate the anteriolateral and anteriomedial aspect of sclera to supply Tunica vasculosa bulbi. A
- 8 *Aa. ciliares posteriores breves*. Branches of *Aa. ciliares posteriores longae* which perforate sclera near N. opticus, and ramify in choroidea. A
- 9 *Aa. episclerales*. Branches of *Aa. ciliares posteriores longae* which run on the outer surface of sclera and supply it. A
- 10 *Aa. conjunctivales posteriores*. Extend along sclera into Tunica conjunctiva. A
- 11 *A. malaris*. Crosses the medial aspect of Processus temporalis of Os zygomaticum, pierces through periorbita and courses towards Angulus oculi medialis. B
- 12 *A. palpebrae tertiae*. Supplies Palpebra tertia. B
- 13 *Ramus frontalis*. Arises outside periorbita and continues upon the ventromedial part of Orbita to Angulus oculi medialis. B
- 14 *A. palpebralis inferior medial*. Enters Palpebra inferior from medial. B
- 15 *Aa. conjunctivales anteriores*. Supply Tunica conjunctiva. B
- 16 *A. dorsalis nasi*. Emerges from Orbita and courses to Regio dorsalis nasi. Actually given off by Ramus frontalis. B
- 17 *A. infraorbitalis*. Enters Canalis infraorbitalis through Foramen maxillare and emerges through Foramen infraorbitale. B
- 18 *Rami dentales*. To the superior teeth. B
- 19 *Aa. laterales nasi*. Run rostrally and dorsally in Regio lateralis nasi. B
- 20 *A. palatina descendens*. Courses rostroventrally at the rostral end of Fossa pterygopalatina. B C
- 21 *A. sphenopalatina*. Courses towards Cavum nasi through Foramen sphenopalatinum. C
- 22 *Aa. nasales caudales, laterales et septales*. Ramify in Tunica mucosa nasi. C
- 23 *A. palatina minor*. Courses between Processus pyramidalis of Os palatinum and Tuber maxillae to Palatum molle. Inconstant. C
- 24 *A. palatina major*. Courses rostrally through Canalis palatinus major and continues rostrally in Sulcus palatinus. Sends branches to Palatum durum, to its heterolateral counterpart, to the snout and, via Fissura palatina, to Tunica mucosa nasi. C



A Arteries of the right eye, medial aspect (su)



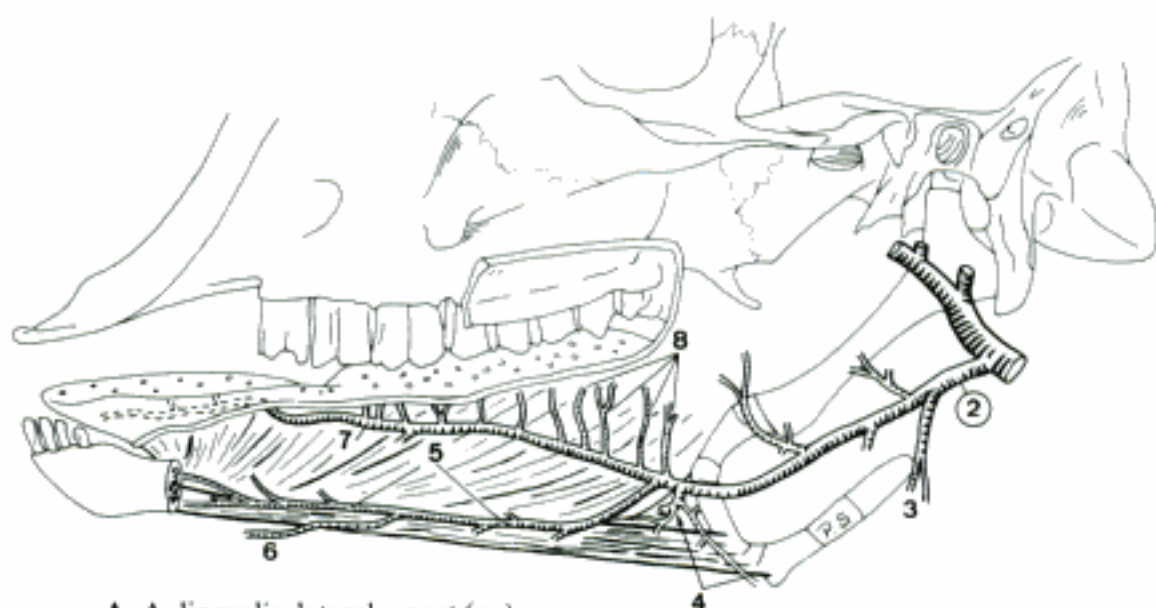B A. infraorbitalis and A. malaris (su)



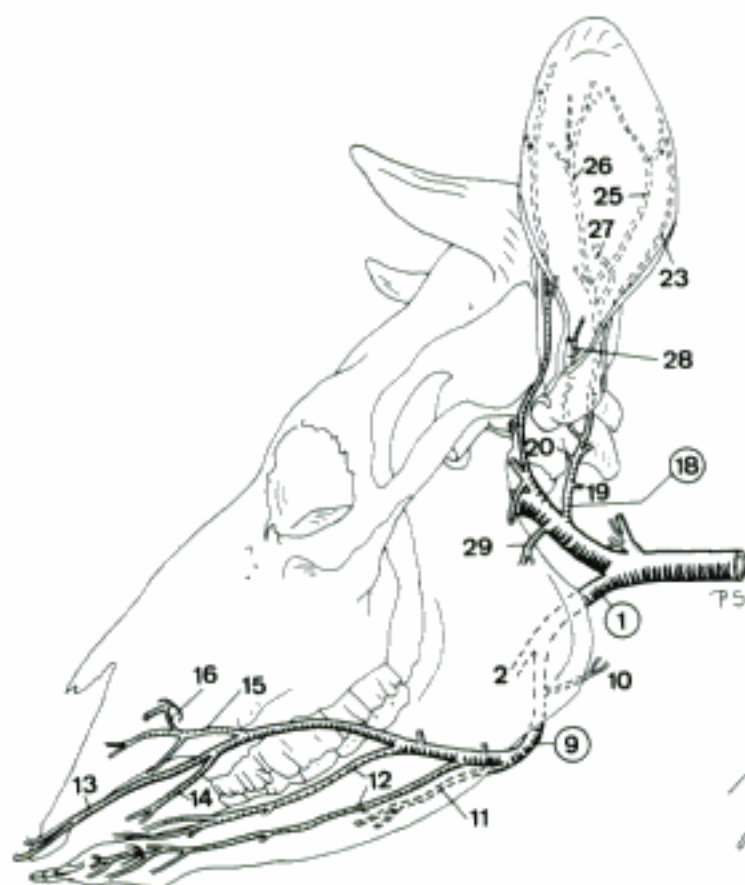
C A. maxillaris (su)

RUMINANTIA

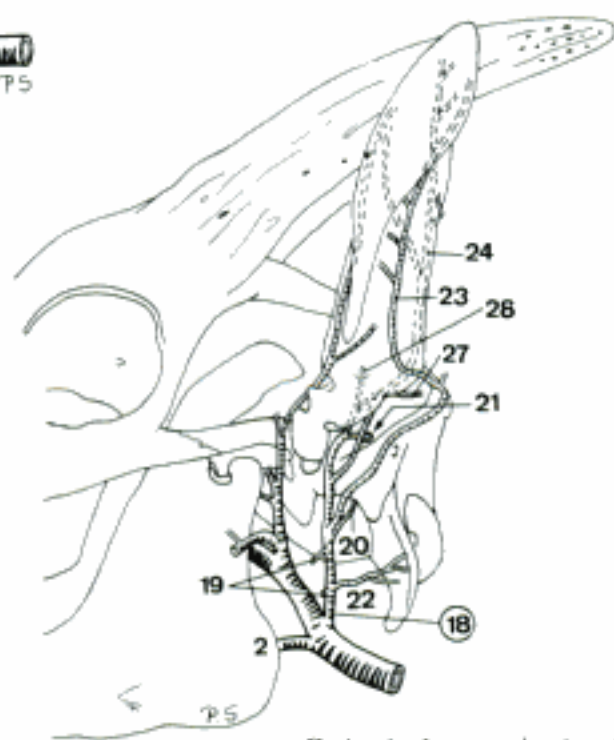
- 1 **Truncus linguofacialis.** Common trunk for A. lingualis and A. facialis. Usually present in bo, A. facialis absent in ov and cap. B
- 2 **A. lingualis.** Courses rostroventrally and enters the tongue at the medial aspect of M. hyoglossus. A B C
- 3 **Rami glandulares.** Variable branches to Gl. mandibularis. A
- 4 **Rami perihyoidei.** Surround Os hyoideum and usually anastomose by a distinct branch with their heterolateral counterparts. A
- 5 **A. sublingualis.** Courses rostrally on the medial aspect of M. hyoglossus. May be unilaterally regressed (ov, cap). A
- 6 **A. submentalis (ov, cap).** Occasionally present, perforates M. mylohyoideus and continues superficially to the chin. A
- 7 **A. profunda linguae.** Passes rostrally along the lateral aspect of M. genioglossus. A
- 8 **Rami dorsales linguae.** Arise inside the tongue and course towards Dorsum linguae. A
- 9 **A. facialis (bo).** Courses rostroventrally, crosses Margo ventralis of Mandibula and ascends along the rostral border of M. masseter. B
- 10 **Ramus glandularis.** Occasionally plural branch to Gl. mandibularis. B
- 11 **A. submentalis.** Runs rostrally on the ventrolateral aspect of M. mylohyoideus. B
- 12 **Aa. labiales inferiores.** Rostrally directed pair of vessels for Labium inferius. B
- 13 **A. labialis superior.** Passes rostrally into Labium superius and Planum nasolabiale. B
- 14 **A. angularis oris.** Supplies Angulus oris. Very small or absent. B
- 15 **Ramus lateralis nasi rostralis.** Runs on the lateral aspect of the nose. Frequently represented by several branches. B
- 16 **Ramus anastomoticus cum a. infraorbitali.** Communication with branches of A. infraorbitalis. B
- 17 **Ramus angularis oculi.** Variable and inconstant branch towards Angulus oculi medialis.
- 18 **A. auricularis caudalis.** Courses caudodorsally towards the base of the ear. B C
- 19 **Rami parotidei.** To Gl. parotis. B C
- 20 **A. stylomastoidea.** Passes through Foramen stylomastoideum into Canalis facialis and ramifies in Auris media. B C
- 21 **Ramus meningeus (ov, cap).** Enters Os temporale near Porus acusticus externus and traverses Meatus temporalis into Cavum cranii where it supplies meninges. C
- 22 **Ramus sternocleidomastoideus (cap).** To M. sternomastoideus and M. cleidocephalicus. C
- 23 **Ramus auricularis lateralis.** Runs on Dorsum auriculae along Margo antitragicus towards the Apex auriculae. B C
- 24 **Ramus auricularis intermedius (ov, cap).** Runs apically on the middle of Dorsum auriculae. Occurs exceptionally in bo. C
- 25 **Ramus auricularis intermedius lateralis (bo).** Lateral intermediate branch that runs apically on Dorsum auriculae. B
- 26 **Ramus auricularis intermedius medialis (bo).** Medial intermediate branch that runs apically on Dorsum auriculae. B
- 27 **Ramus occipitalis.** Runs towards Regio occipitalis. B C
- 28 **A. auricularis profunda.** Sends a branch to the internal surface of Auris externa and also supplies Mm. auriculares and M. temporalis. B C
- 29 **Ramus massetericus (bo).** Runs rostroventrally into the caudal part of M. masseter. B



A A. lingualis, lateral aspect (ov)

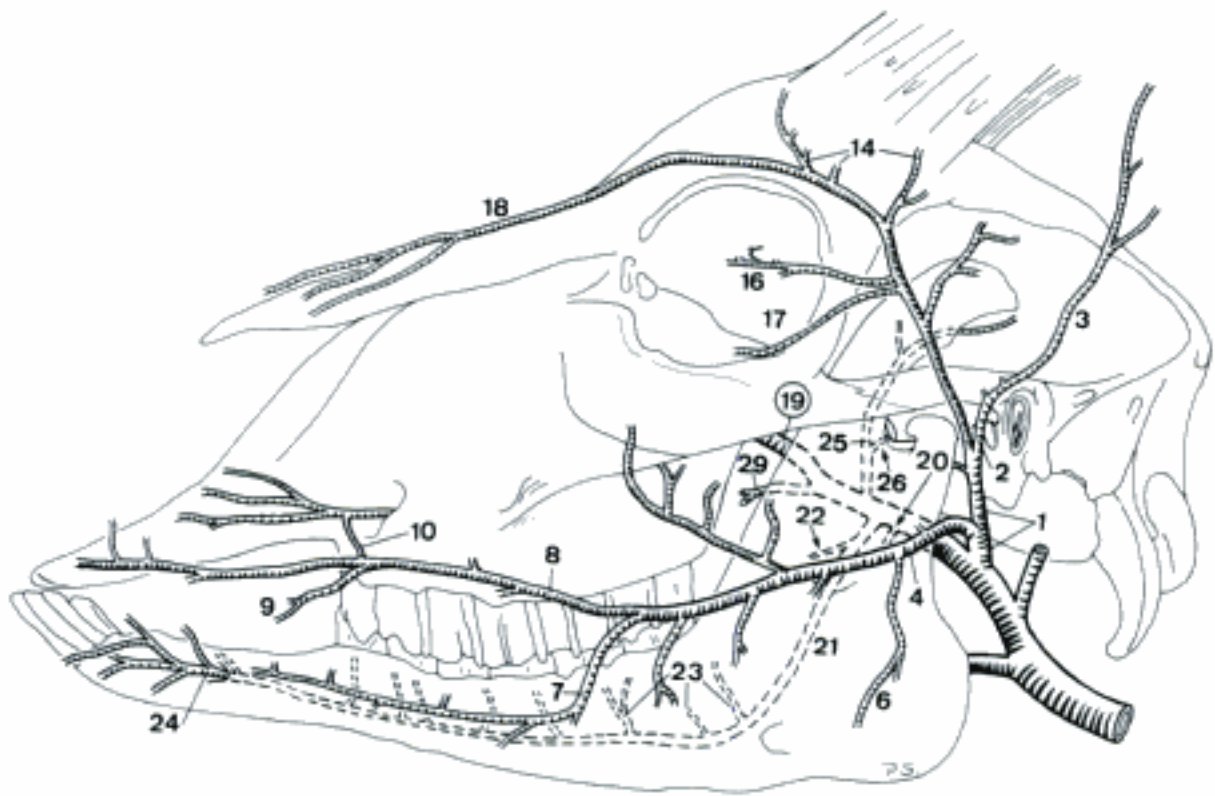


B Arteries of the head (bo)

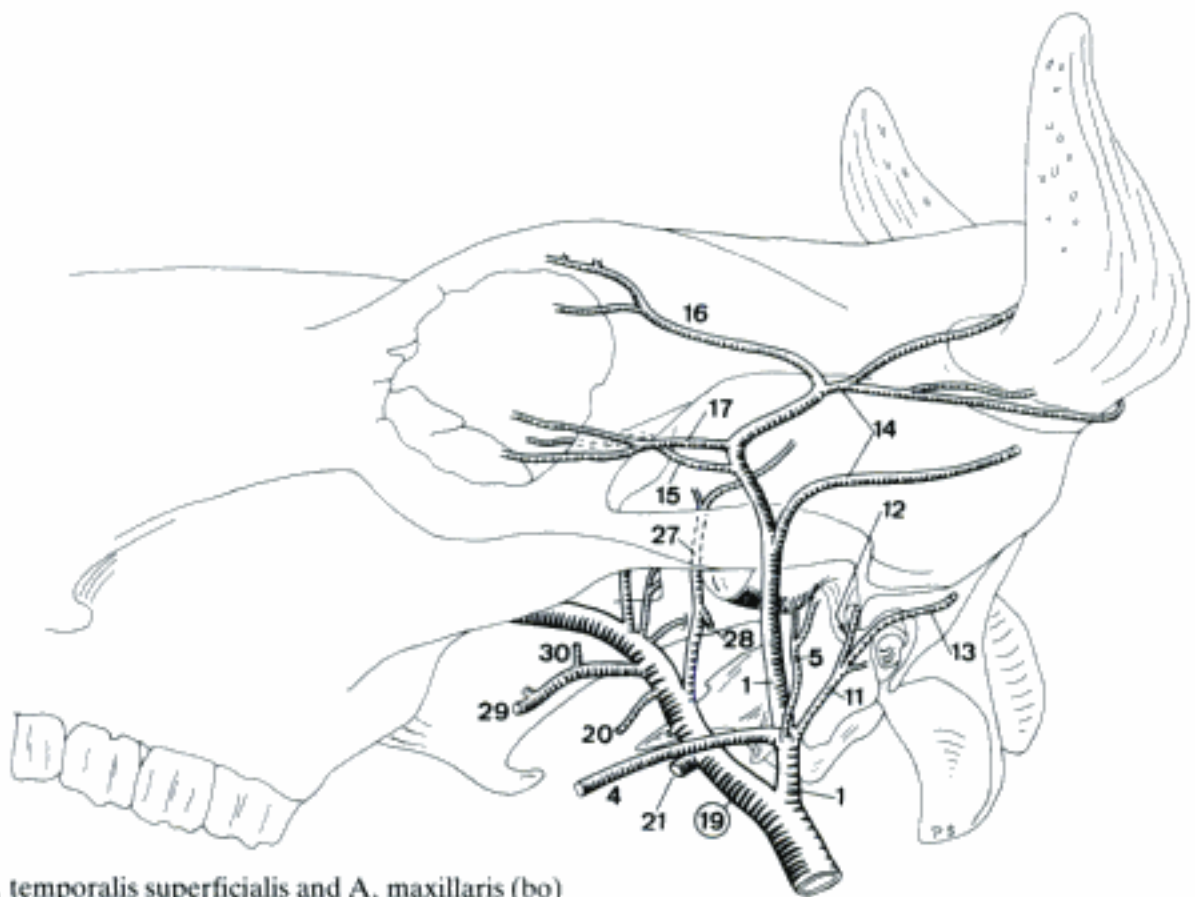


C Auricular arteries (cap)

- 1 **A. temporalis superficialis.** Courses dorsally across the lateral aspect of Arcus zygomaticus and ramifies in Regio frontalis. A B
- 2 *A. auricularis rostralis (ov, cap).* Crosses the lateral aspect of Arcus zygomaticus and reaches the cranial part of the base of the ear. A
- 3 *Ramus auricularis medialis.* Runs on Dorsum auriculae along Margo tragicus towards the ear-tip. A
- 4 *A. transversa faciei.* Crosses Ramus mandibulae and courses rostroventrally on the lateral surface of M. masseter. A B
- 5 *Ramus articularis temporomandibularis (bo).* To the homonymous joint. B
- 6 *Ramus massetericus (ov, cap).* To M. masseter. A
- 7 *A. labialis inferior (ov, cap).* Runs in Labium inferius. A
- 8 *A. labialis superior (ov, cap).* Courses in Labium superius. A
- 9 *A. angularis oris.* Tends to Angulus oris. A
- 10 *Ramus anastomoticus cum a. infraorbitali.* Usually plural communication with A. infraorbitalis. A
- 11 *A. auricularis rostralis (bo).* Runs towards the rostral aspect of the base of the ear. B
- 12 *Ramus meningeus.* Courses through Meatus temporalis into Cavum cranii where it ramifies in meninges. B
- 13 *Ramus auricularis medialis.* Courses towards the Apex auriculae on Dorsum auriculae, parallel to Margo tragicus. B
- 14 *A. cornualis.* Courses caudomedially to Basis cornus. Developed to variable size, dependent on the development of the horn, often represented by several vessels. A B
- 15 *Ramus lacrimalis (bo, ov).* Branch which arises at variable level and, after piercing through periorbita, courses into Gl. lacrimalis. B
- 16 *A. palpebralis superior lateralis.* Courses rostromedially into Palpebra superior. A B
- 17 *A. palpebralis inferior lateralis.* Runs rostromedially into Palpebra inferior. Often absent in ov. A B
- 18 *A. dorsalis nasi (cap).* Courses rostrally on Dorsum nasi. A
- 19 **A. maxillaris.** Passes rostradorsally to Fossa pterygopalatina. A B
- 20 *Ramus pterygoideus.* Variable branch for Mm. pterygoidei. A B
- 21 *A. alveolaris inferior.* Pierces through Foramen mandibulae and courses within Canalis mandibulae. A B
- 22 *Ramus mylohyoideus.* To M. mylohyoideus. Arises before its parent vessel entered Canalis mandibulae. A
- 23 *Rami dentales.* To the mandibular teeth. A
- 24 *A. mentalis.* Continuation of A. alveolaris inferior which emerges from Foramen mentale. A
- 25 *A. temporalis profunda (ov, cap).* Pursues a short rostral course, bends dorsally, and ramifies in M. temporalis. A
- 26 *Ramus articularis temporomandibularis.* To the homonymous joint. A
- 27 *A. temporalis profunda caudalis (bo).* Supplies M. temporalis. B
- 28 *A. masseterica.* Passes through Incisura mandibulae into M. masseter. B
- 29 *A. buccalis.* Courses over Tuber maxillae into the caudal part of the cheek. A B
- 30 *A. temporalis profunda rostralis (bo).* Runs into M. temporalis. B

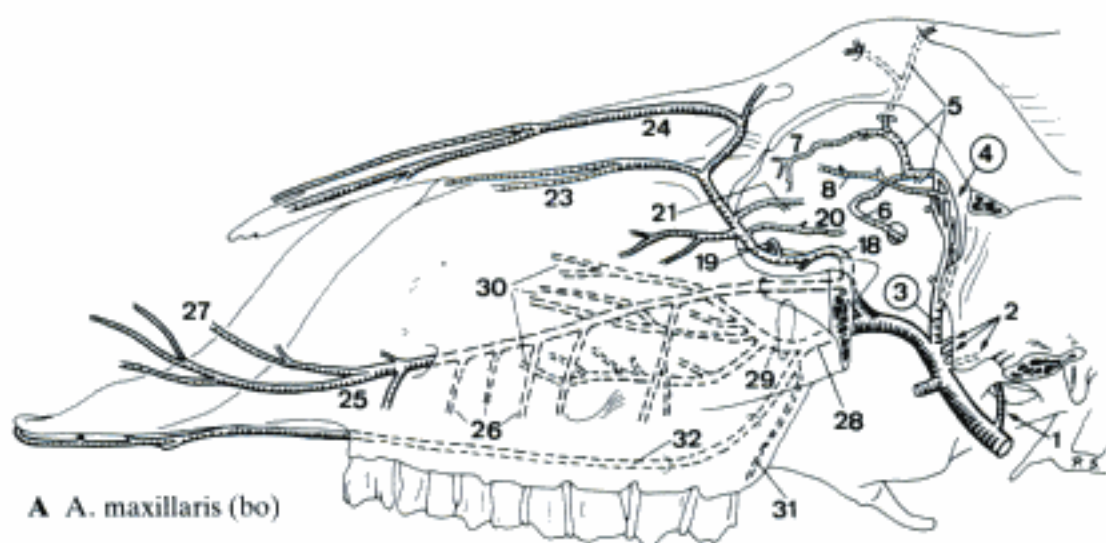


A Arteries of the head (cap)

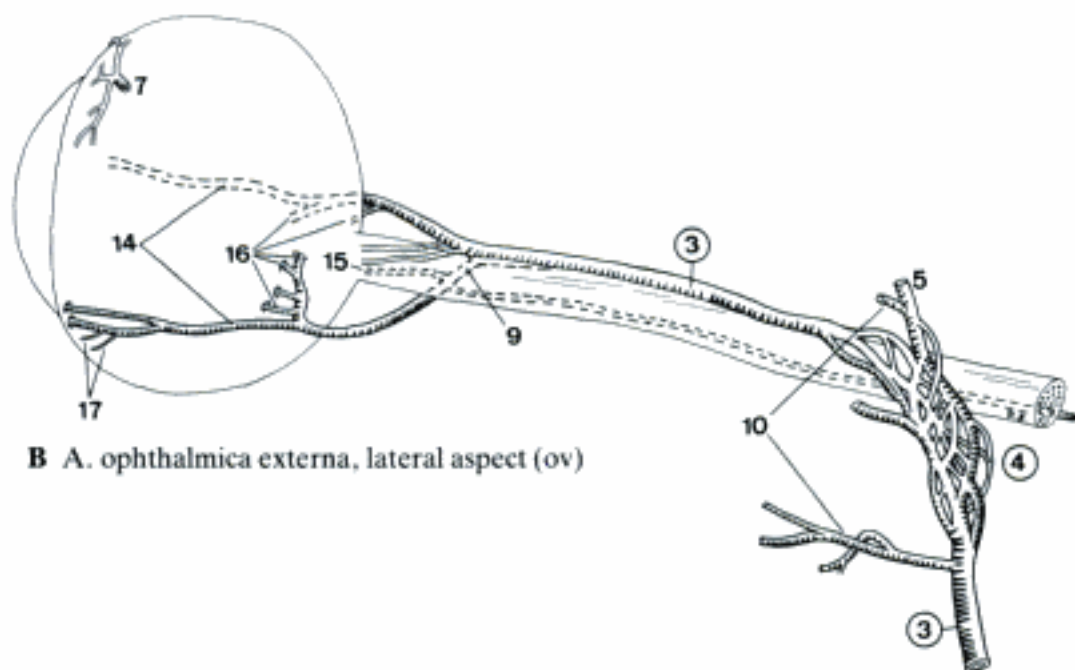


B A. temporalis superficialis and A. maxillaris (bo)

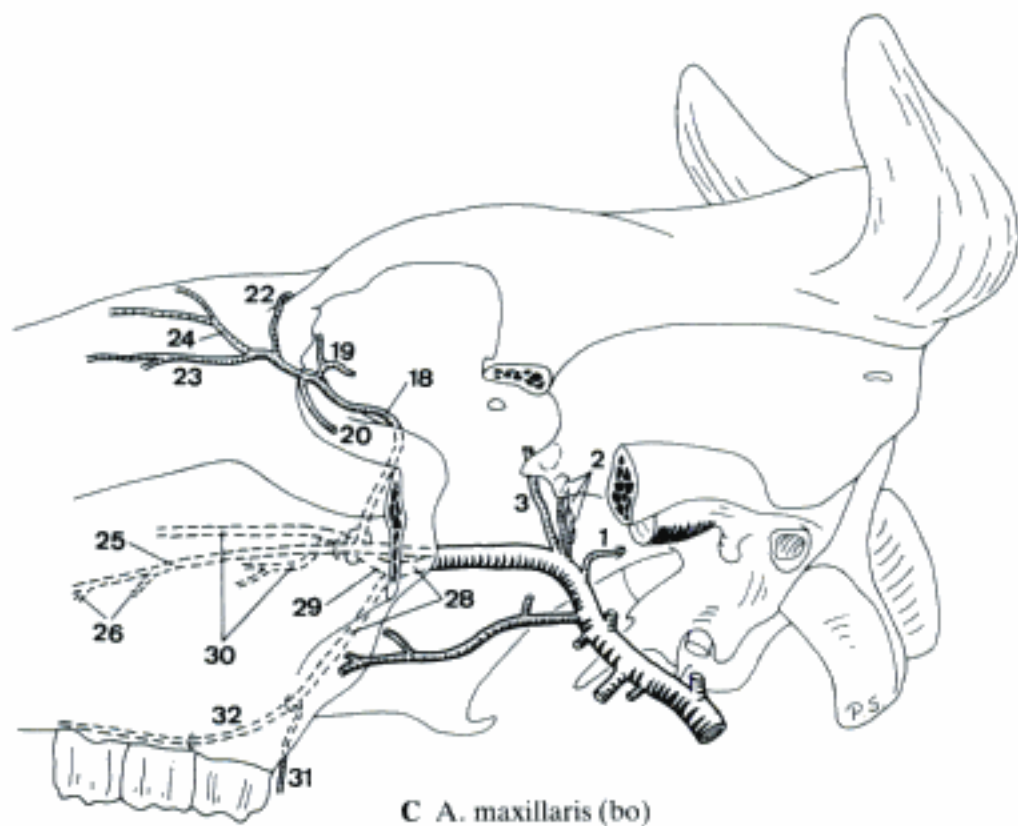
- 1 *Ramus caudalis ad rete mirabile epidurale rostrale*. Passes through Foramen ovale to rete, may also pierce the skull near Foramen ovale. A C
- 2 *Rami rostrales ad rete mirabile epidurale rostrale*. Course through Foramen orbitotundum to Rete mirabile epidurale rostrale. A C
- 3 *A. ophthalmica externa*. Perforates periorbita, passes between Mm. recti dorsalis and lateralis upon M. retractor bulbi, and continues rostrally upon N. opticus. A B C
- 4 *Rete mirabile ophthalmicum*. Arterial network in the course of *A. ophthalmica externa*. A B
- 5 *A. supraorbitalis*. Passes through Canalis supraorbitalis to Regio frontalis (bo, sometimes ov). A B
- 6 *A. ethmoidalis externa*. Enters through Foramen ethmoidale in Cavum cranii and continues through Lamina cribrosa towards Cavum nasi. A
- 7 *Aa. conjunctivales anteriores*. Variably originating vessels to Tunica conjunctiva. A B
- 8 *A. lacrimalis*. Courses along M. rectus dorsalis into Gl. lacrimalis. Absent in ov. A
- 9 *Ramus anastomoticus cum a. ophthalmica interna*. Short branch which joins *A. ophthalmica interna* at the rostromedial aspect of N. opticus. B
- 10 *Rami musculares*. Mainly to Mm. bulbi. Mostly arisen from Rete mirabile ophthalmicum. B
- 11 *Aa. ciliares anteriores*. Perforate the anterior aspect of sclera and ramify in choroidea.
- 12 *Aa. episclerales*. Course on sclera and supply it.
- 13 *Aa. conjunctivales posteriores*. Run along sclera to Tunica conjunctiva.
- 14 *Aa. ciliares posteriores longae*. Pair of vessels which run anteriorly on the lateral and medial aspect of Bulbus oculi and penetrate sclera to Tunica vasculosa. B
- 15 *A. centralis retinae*. Usually double parent trunk for the Arteriola retinae. B
- 16 *Aa. ciliares posteriores breves*. Perforate sclera near Area cribrosa and ramify in choroidea. B
- 17 *Aa. episclerales*. Supply sclera from the outside. B
- 18 *A. malaris*. Passes dorso-rostrally in Orbita to Angulus oculi medialis and continues onto the lateral aspect of the face. A C
- 19 *A. palpebrae tertiae*. Supplies Palpebra tertia. A C
- 20 *A. palpebralis inferior medialis*. Courses laterally, supplying Palpebra inferior. A C
- 21 *A. palpebralis superior medialis (ov, cap)*. Courses laterally in Palpebra superior. Inconstant (esp. ov). A
- 22 *A. angularis oculi (bo)*. Passes caudally to Angulus oculi medialis. C
- 23 *A. lateralis nasi caudalis*. Courses rostrally on Regio nasalis. C
- 24 *A. dorsalis nasi (bo, ov)*. Courses rostrally on the dorsal surface of the nose. A C
- 25 *A. infraorbitalis*. Pierces through Foramen maxillare in Canalis infraorbitalis and, after emerging from Foramen infraorbitale, ramifies on the lateral aspect of the face. A C
- 26 *Rami dentales*. To the superior teeth. A C
- 27 *A. lateralis nasi rostralis*. To Regio nasalis. A
- 28 *A. palatina descendens*. Rostroventrally directed continuation of *A. maxillaris*. A C
- 29 *A. sphenopalatina*. Courses through Foramen sphenopalatinum towards Cavum nasi. A C
- 30 *Aa. nasales caudales, laterales et septales*. Supply the caudoventral parts of Tunica mucosa nasi. A C
- 31 *A. palatina minor*. Supplies Palatum molle and the adjacent structures. A C
- 32 *A. palatina major*. Traverses Canalis palatinus major, continues rostrally in Sulcus palatinus, supplies Palatum durum, and, anastomosing with its heterolateral counterpart, also Tunica mucosa nasi. A C



A A. maxillaris (bo)



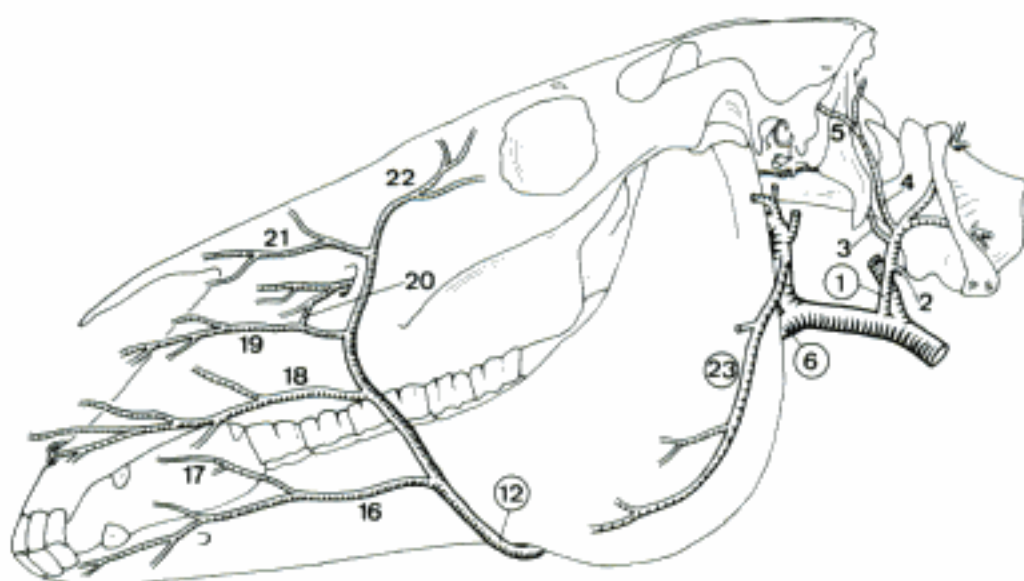
B A. ophthalmica externa, lateral aspect (ov)



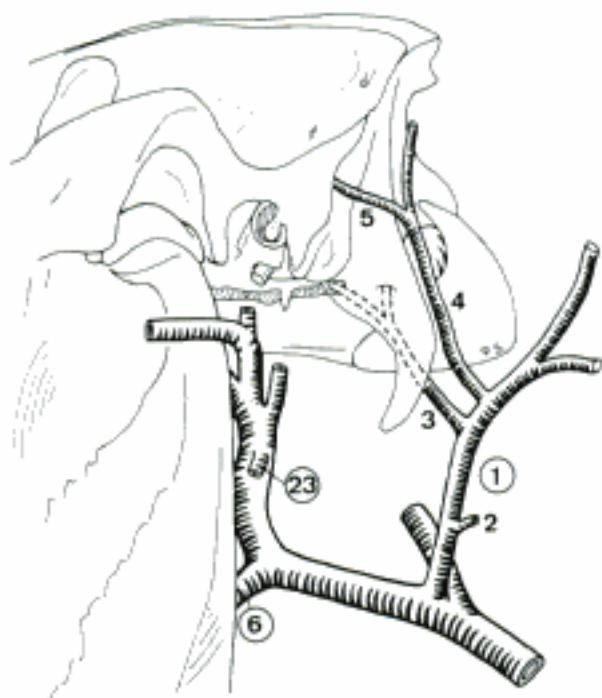C A. maxillaris (bo)

EQUUS

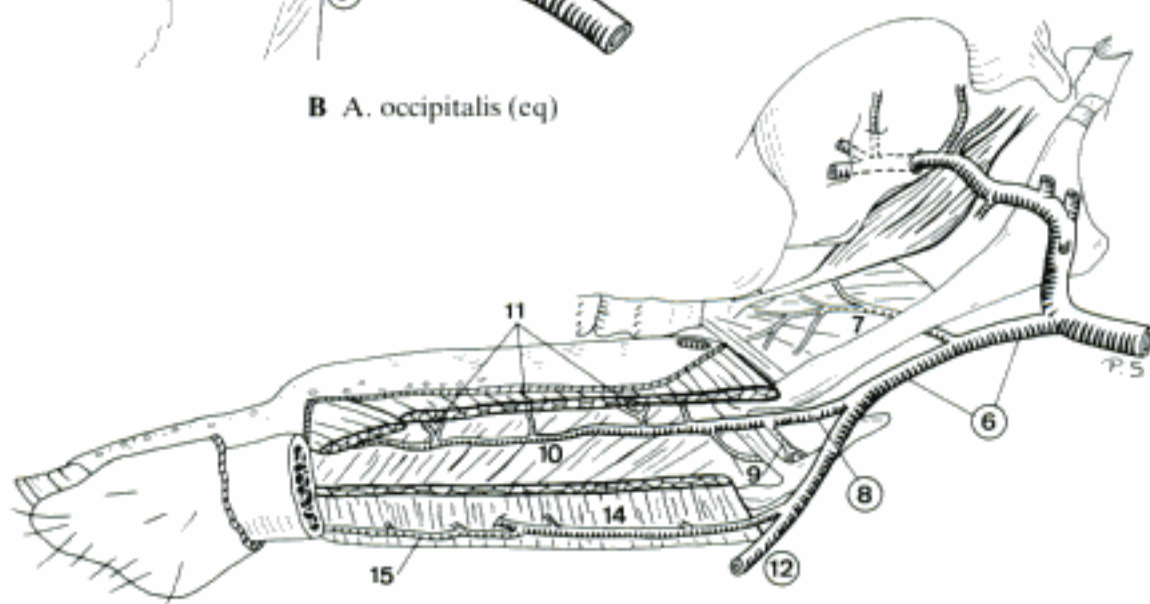
- 1 **A. occipitalis.** Arises in common with, or immediately rostrally to *A. carotis interna* and pursues a somewhat flexuous course to Fossa atlantis. A B
- 2 *Ramus glandularis.* To Gl. mandibularis. A B
- 3 *A. condylaris.* Passes rostradorsally and divides in muscular and meningeal branches. The latter enter cranium via Foramen jugulare and Canalis n. hypoglossi. A B
- 4 *Ramus occipitalis.* Continuation of the parent stem beyond its contact with *Ramus anastomoticus cum a. occipitali* from *A. vertebralis*. Extends towards Crista nuchae. A B
- 5 *A. meningeae caudalis.* Runs rostradorsally, comes through Foramen mastoideum into Meatus temporalis and reaches Cavum cranii to supply dura. A B
- 6 **Truncus linguofacialis.** Exceptionally absent common trunk for *A. lingualis* and *A. facialis*, from which also *A. palatina ascendens* arises. Runs rostroventrally along Stylohyoideum on the medial aspect of *M. stylohyoideus*. A B C
- 7 **A. palatina ascendens.** Runs rostrally between Stylohyoideum and *M. stylopharyngeus* and chiefly supplies Palatum molle. C
- 8 **A. lingualis.** Usually enters the tongue between *M. hyoglossus* and *M. ceratohyoideus*. C
- 9 *Rami perihyoidei.* Branching vessels which arise near Os hyoideum and supply the latter, pharynx, and epiglottis. C
- 10 *A. profunda linguae.* Runs rostrally in the tongue along the lateral aspect of *M. genioglossus*. C
- 11 *Rami dorsales linguae.* Course to Dorsum linguae. C
- 12 **A. facialis.** Courses rostroventrally on the medial surface of *M. pterygoideus medialis*, turns around Incisura vasorum facialis and ascends on the face at the rostral border of *M. masseter*. A C
- 13 *Ramus pharyngeus.* Inconstant branch to the pharyngeal wall.
- 14 *A. sublingualis.* Courses rostroventrally between Mandibula and *M. mylohyoideus* and, after perforating the latter, runs along the ventral border of Gl. sublingualis polystomatica to the floor of the mouth. C
- 15 *A. submentalis.* Runs rostrally on the ventrolateral aspect of *M. mylohyoideus*. C
- 16 *A. labialis inferior.* Passes rostrally to Labium inferius. A
- 17 *A. angularis oris.* To Angulus oris. A
- 18 *A. labialis superior.* Courses rostrally to Labium superius. A
- 19 *A. lateralis nasi.* Often double supply for Regio lateralis nasi. A
- 20 *Ramus anastomoticus cum a. infraorbitali.* Communication with branches of *A. infraorbitalis*. A
- 21 *A. dorsalis nasi.* Passes rostradorsally to Regio dorsalis nasi. A
- 22 *A. angularis oculi.* Curves towards Angulus oculi medialis. A
- 23 **Ramus massetericus.** Courses cranioventrally across Ramus mandibulae and continues on the ventral aspect of *M. masseter*. A B



A A. facialis (eq)

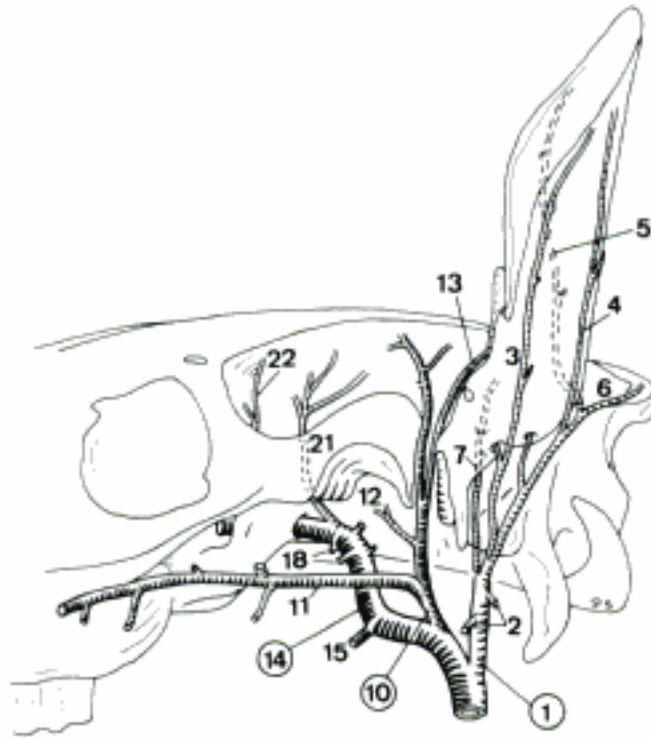


B A. occipitalis (eq)

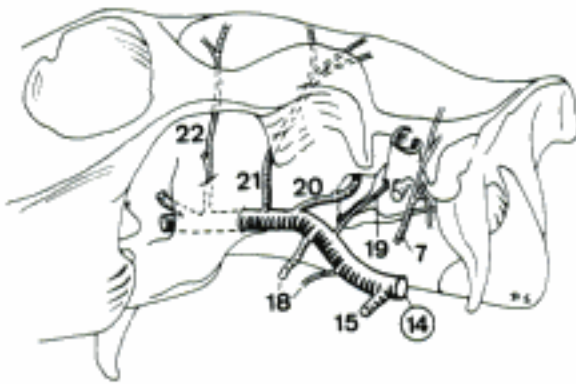


C Truncus linguofacialis, lateral aspect (eq)

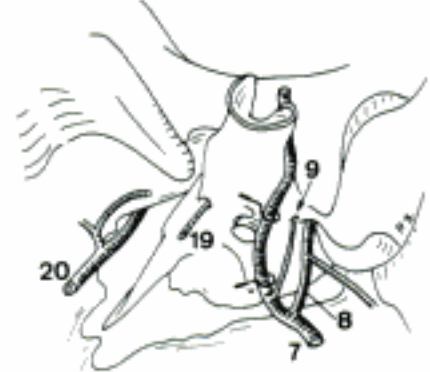
- 1 **A. auricularis caudalis.** Passes dorsally to the base of the ear. A D
- 2 *Rami parotidei.* Several branches to Gl. parotis. A
- 3 *Ramus auricularis lateralis.* Runs towards the Apex auriculae on Dorsum auriculae, following Margo antitragicus. A
- 4 *Ramus auricularis intermedius.* Passes apically in the middle of Dorsum auriculae. A
- 5 *Ramus auricularis medialis.* Runs apically along Margo tragicus on Dorsum auriculae. A
- 6 *Ramus occipitalis.* Courses towards Regio occipitalis and Regio temporalis. A
- 7 *A. auricularis profunda.* Courses between Meatus acusticus externus and Processus mastoideus and gives off muscular branches and one or more branches to the interior of Auris externa. A B C
- 8 *A. stylomastoidea.* Passes through or near Foramen stylomastoideum into Cavum tympani. C
- 9 *A. tympanica caudalis.* Supplies Auris media and its muscles. C
- 10 **A. temporalis superficialis.** Passes dorsally between Auris externa and Articulatio temporomandibularis and finally divides in muscular branches at the level of M. temporalis. A D
- 11 *A. transversa faciei.* Courses rostrally upon M. masseter and enters this muscle. A D
- 12 *Ramus articularis temporomandibularis.* To the homonymous joint. A
- 13 *A. auricularis rostralis.* Courses to the rostral part of the base of the ear. A
- 14 **A. maxillaris.** Curves to Basis cranii externa and passes through Canalis alaris to Fossa pterygopalatina. A B D
- 15 *A. alveolaris inferior.* Passes ventro-rostrally and pierces through Foramen mandibulae into Canalis mandibulae. A B D
- 16 *Rami dentales.* To the mandibular teeth. D
- 17 *A. mentalis.* Emerges through Foramen mentale. D
- 18 *Rami pterygoidei.* To Mm. pterygoidei. A B
- 19 *A. tympanica rostralis.* Courses along Tuba auditiva and pierces through Fissura petrotympanica into Auris media. B C
- 20 *A. meningea media.* Runs caudally, enters Cavum cranii through Incisura spinosa and supplies dura. B C
- 21 *A. temporalis profunda caudalis.* Passes caudodorsally into M. temporalis. A B
- 22 *A. temporalis profunda rostralis.* Emerges from Canalis alaris through Foramen alare parvum and chiefly supplies M. temporalis. A B



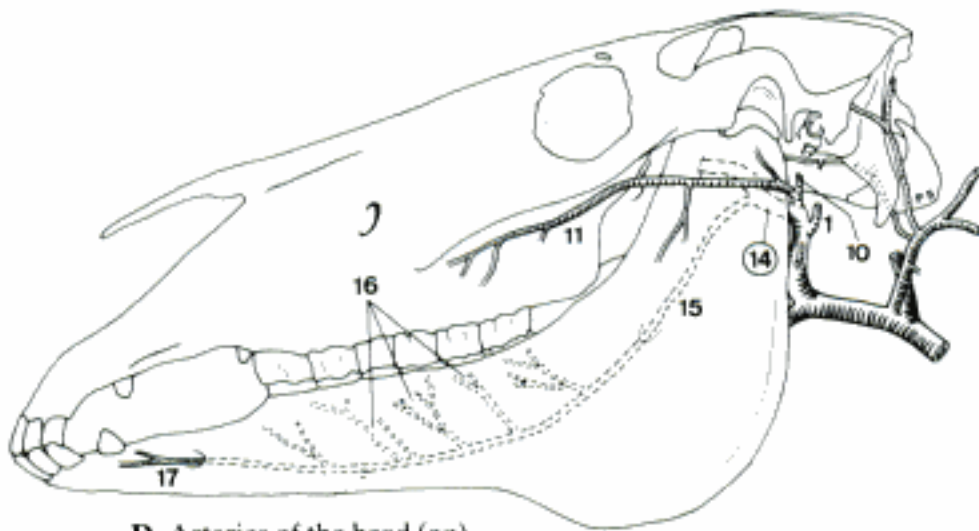
A Auricular arteries (eq)



B A. maxillaris, ventrolateral aspect (eq)

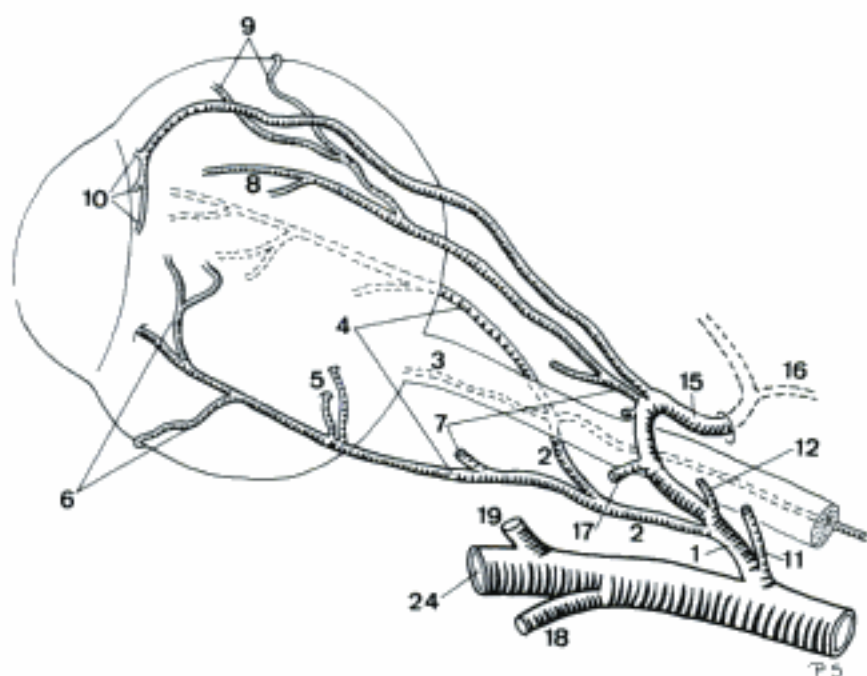


C Arteries in relation to left temporal bone, ventrolateral aspect (eq)

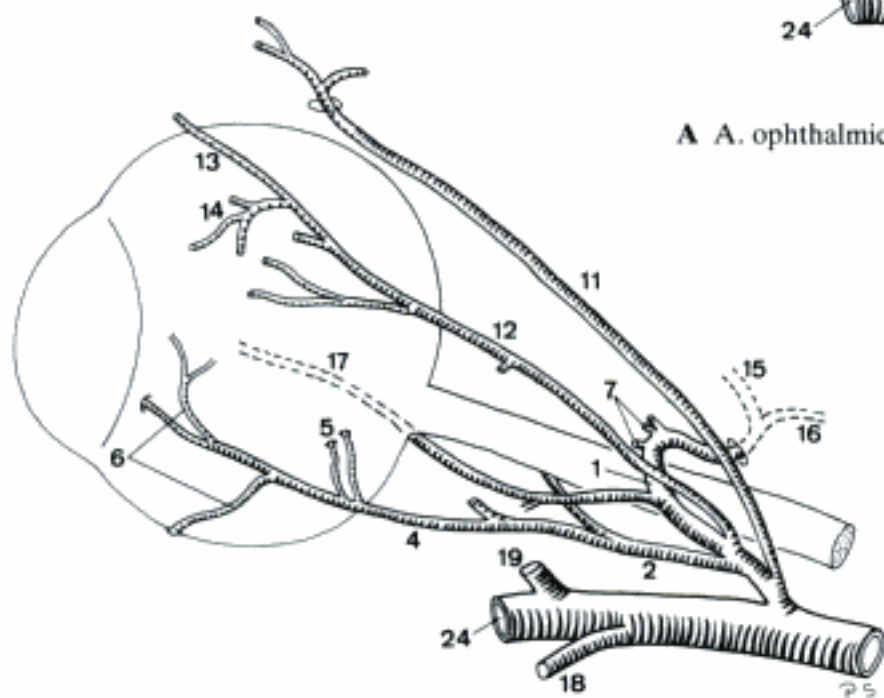


D Arteries of the head (eq)

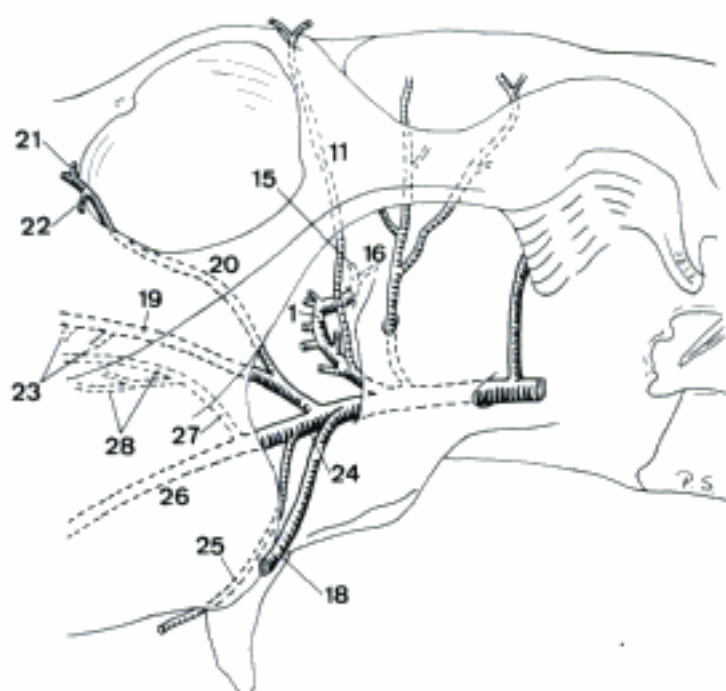
- 1 *A. ophthalmica externa*. Leaves Canalis alaris through Foramen alare rostrale, enters periorbita, courses between Mm. recti dorsalis and lateralis, to the dorsal aspect of M. retractor bulbi. A B C
- 2 *Ramus anastomoticus cum a. ophthalmica interna*. Courses to the medial aspect of N. opticus where it joins *A. ophthalmica interna*. A B
- 3 *A. centralis retinae*. Collective term for the extrabulbar stem vessels for the Arteriolae retinae. A
- 4 *Aa. ciliares posteriores longae*. Lateral and medial arteries that pierce the posterior part of sclera and run anteriorly in Lamina suprachoroidea to Corpus ciliare and iris. A B
- 5 *Aa. ciliares posteriores breves*. Short branches of *Aa. ciliares posteriores longae* that perforate sclera near Area cribrosa and ramify in choroidea. A B
- 6 *Aa. episclerales*. Supply sclera from outside. A B
- 7 *Rami musculares*. Variably arising branches for Mm. bulbi. A B
- 8 *Aa. ciliares anteriores*. Pierce through sclera near Sulcus sclerae and ramify in Tunica vasculosa. A
- 9 *Aa. episclerales*. Course on sclera and supply it. A
- 10 *Aa. conjunctivales posteriores*. To Tunica conjunctiva. A
- 11 *A. supraorbitalis*. Pierces through Foramen supraorbitale. A B C
- 12 *A. lacrimalis*. Runs rostradorsally within periorbita into Gl. lacrimalis. A B
- 13 *A. palpebralis superior lateralis*. Courses from lateral in Palpebra superior. B
- 14 *A. palpebralis inferior lateralis*. Enters Palpebra inferior from lateral. B
- 15 *A. ethmoidalis externa*. Enters Cavum cranii via Foramen ethmoidale and passes through Lamina cribrosa towards Cavum nasi. A B C
- 16 *A. meningeae rostralis*. Arises at Fossa ethmoidalis and ramifies in the rostral part of dura. A B C
- 17 *A. palpebrae tertiae*. To Palpebra tertia. A B
- 18 *A. buccalis*. Courses between Tuber maxillae and Ramus mandibulae, ramifies in the cheek structures. A B C
- 19 *A. infraorbitalis*. Passes through Foramen maxillare in Canalis infraorbitalis and emerges from Foramen infraorbitale with variable size. A B C
- 20 *A. malaris*. Passes between periorbita and the rostromedial wall of Orbita into structures at Angulus oculi medialis. C
- 21 *A. palpebralis superior medialis*. Pursues a lateral course in Palpebra superior. C
- 22 *A. palpebralis inferior medialis*. Supplies the medial part of Palpebra inferior. C
- 23 *Rami dentales*. To the superior teeth. C
- 24 *A. palatina descendens*. Variably dividing rostroventral continuation of *A. maxillaris*. A B C
- 25 *A. palatina minor*. Runs rostroventrally at the medial side of Tuber maxillae to Palatum molle. May be absent. C
- 26 *A. palatina major*. Traverses Canalis palatinus major and continues rostrally in Sulcus palatinus. Anastomoses with its heterolateral counterpart and then enters as a single vessel in Canalis interincisivus. C
- 27 *A. sphenopalatina*. Passes through Foramen sphenopalatinum into Cavum nasi. C
- 28 *Aa. nasales caudales, laterales et septales*. Supply the caudoventral parts of Tunica mucosa nasi. C



A A. ophthalmica externa, lateral aspect (eq)



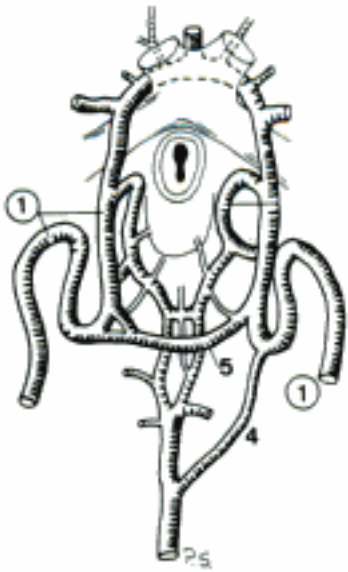
B A. ophthalmica externa, lateral aspect (eq)



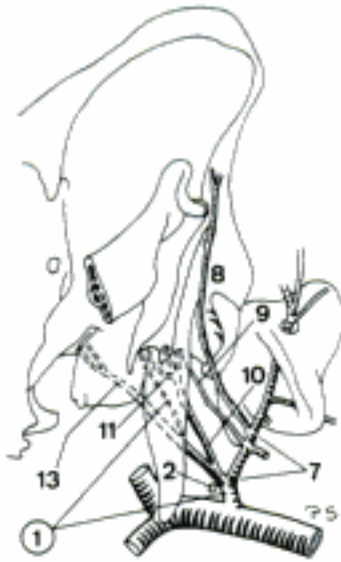
C A. maxillaris, ventrolateral aspect (eq)

TERMINI COMMUNES

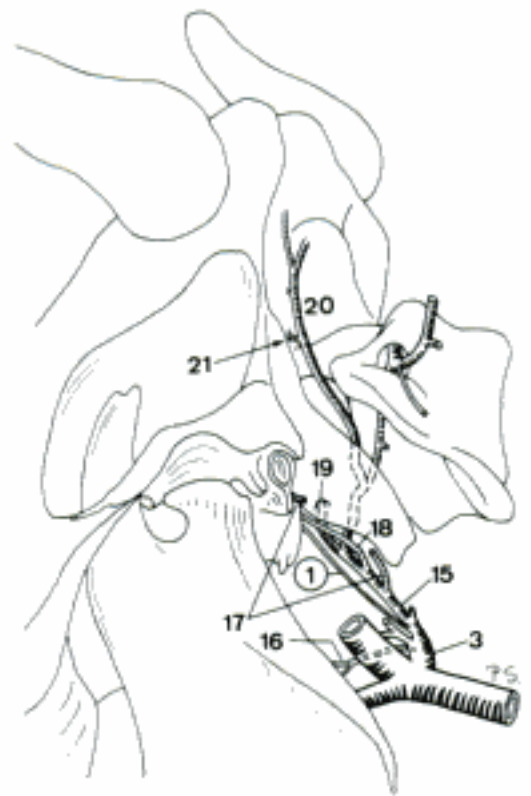
- 1 **ARTERIA CAROTIS INTERNA.** Arises from A. carotis communis, often together with A. occipitalis (esp. su, Ru). Enters Cavum cranii. The extracranial segment is regressed in the adult fe, su, Ru. A B C D E F
 - 2 *Glomus caroticum.* Small nodule containing epitheloid chemoreceptor cells, located at the division of A. carotis communis. B
 - 3 *Sinus caroticus.* Variably distinct enlargement at the origin of A. carotis interna. D E
 - 4 *A. caroticobasilaris (eq).* Inconstant caudomedially directed connection between A. carotis interna and A. basilaris. A
 - 5 *A. intercarotica caudalis (Car, eq).* Connects both Aa. carotides internae at the caudal aspect of hypophysis. May be slightly reticulated (esp. Car). A C
 - 6 *A. intercarotica rostralis (Car).* Connection between left and right A. carotis interna or A. cerebri rostralis (fe), located at the rostral aspect of hypophysis. C
- SUS
- 7 **A. occipitalis.** Dorsal branch of A. carotis interna. B F
 - 8 *Ramus occipitalis.* Continuation of A. occipitalis beyond the contact with Ramus communicans cum a. occipitali from A. vertebralis. Runs towards Crista nuchae. B F
 - 9 *A. meningea caudalis.* Enters Cavum cranii via Meatus temporalis and ramifies in dura. B
 - 10 **A. condylaris.** Reaches Fossa condylaris ventralis and enters Cavum cranii through Canalis n. hypoglossi and Foramen jugulare. B F
 - 11 *A. stylomastoidea.* Pierces through Foramen stylomastoideum and traverses Canalis facialis in order to reach Auris media. B
 - 12 *Rete mirabile epidurale caudale.* Epidurally located arterial network at the level of atlas. Formed by the terminal segment of A. vertebralis, its Ramus spinalis that enters between atlas and axis, and A. condylaris. F
 - 13 *Ramus ad rete mirabile epidurale rostrale.* Large branch that courses to Foramen lacerum where it joins Rete mirabile epidurale rostrale. B F
 - 14 *Rete mirabile epidurale rostrale.* Network of small arteries formed by branches of A. carotis interna, A. meningea media, A. meningea rostralis, and A. maxillaris. Consists of an extracranial and an intracranial part. F
- RUMINANTIA
- 15 **A. occipitalis.** Arises with the vestigial A. carotis interna at the level of transition between A. carotis communis and A. carotis externa. D E
 - 16 *A. palatina ascendens (bo).* Crosses the pharyngeal wall and supplies Palatum molle. D E
 - 17 *A. stylomastoidea profunda (bo).* Passes through Foramen stylomastoideum into Auris media. D E
 - 18 *A. meningea media.* Enters Cavum cranii via Foramen jugulare. D E
 - 19 *A. condylaris.* Runs into Fossa condylaris ventralis and, frequently double, enters Cavum cranii through the likewise double Canalis n. hypoglossi. Joins A. vertebralis and Rete mirabile epidurale caudale (bo). D E
 - 20 *Ramus occipitalis.* Continuation of A. occipitalis beyond the contact with Ramus anastomoticus cum a. occipitali from A. vertebralis or A. condylaris. Ramifies on the nuchal aspect of Os occipitale. D E
 - 21 *A. meningea caudalis.* Reaches meninges via the openings near Margo mastoideus of Squama occipitalis. May be absent (bo). D
 - 22 **Rete mirabile epidurale rostrale.** Anastomotic arterial network located in Sinus cavernosus. Developed in the intracranial course of A. carotis interna, supplied by branches of A. maxillaris. Continuous with Rete mirabile epidurale caudale (bo). E
 - 23 *Rete chiasmaticum (bo).* Reticular extension of Rete mirabile epidurale rostrale to Chiasma opticum. E
 - 24 *A. ophthalmica interna.* Accompanies N. opticus through Canalis opticus to the Orbita, where it anastomoses with A. ophthalmica externa. E



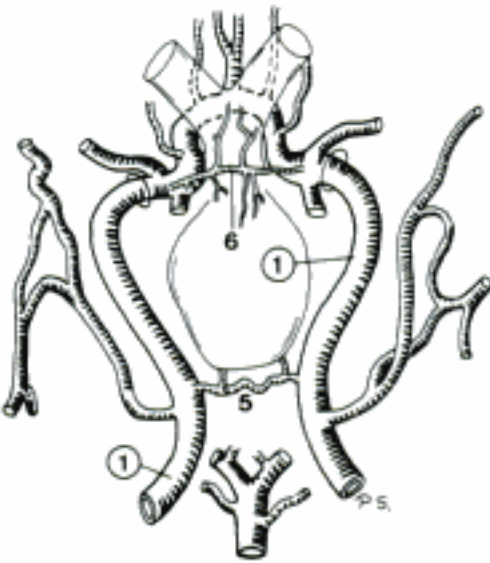
A Aa. carotides internae, ventral aspect (eq)



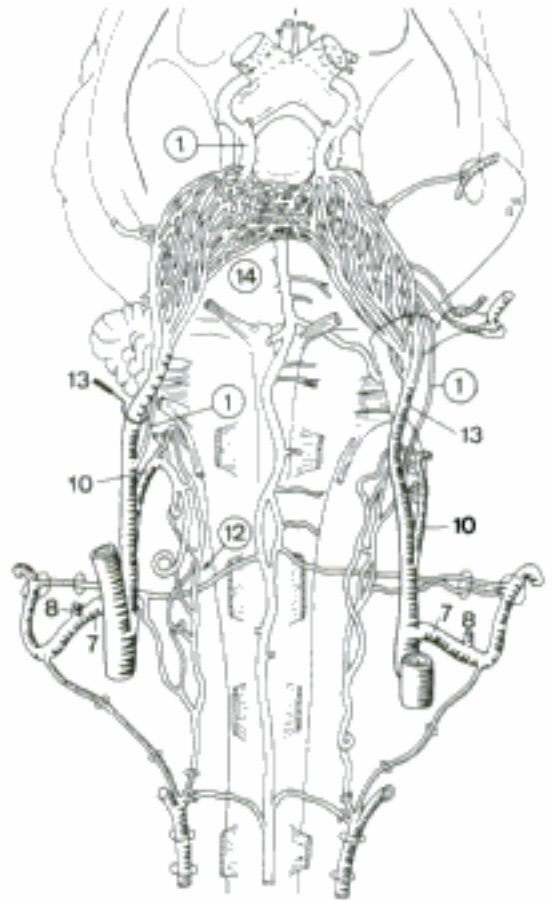
B A. carotis interna, lateral aspect (su)



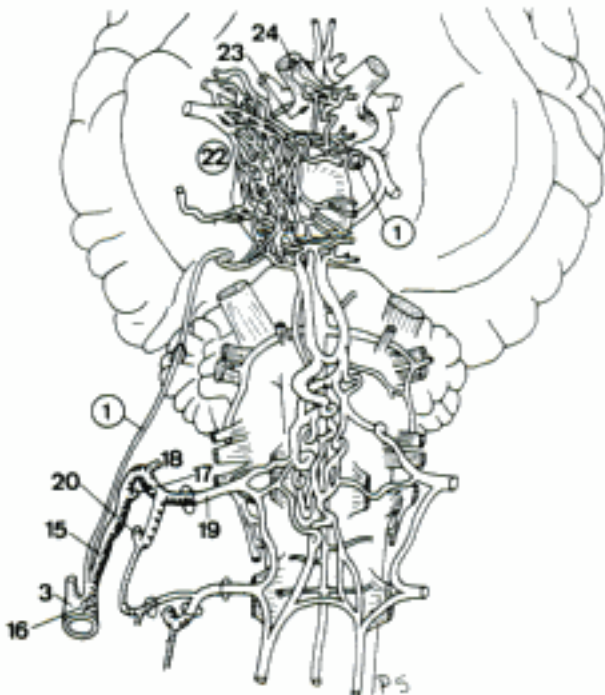
D A. carotis interna, lateral aspect (bo)



C Aa. carotides internae, ventral aspect (ca)



F Aa. carotides internae, ventral aspect (su)



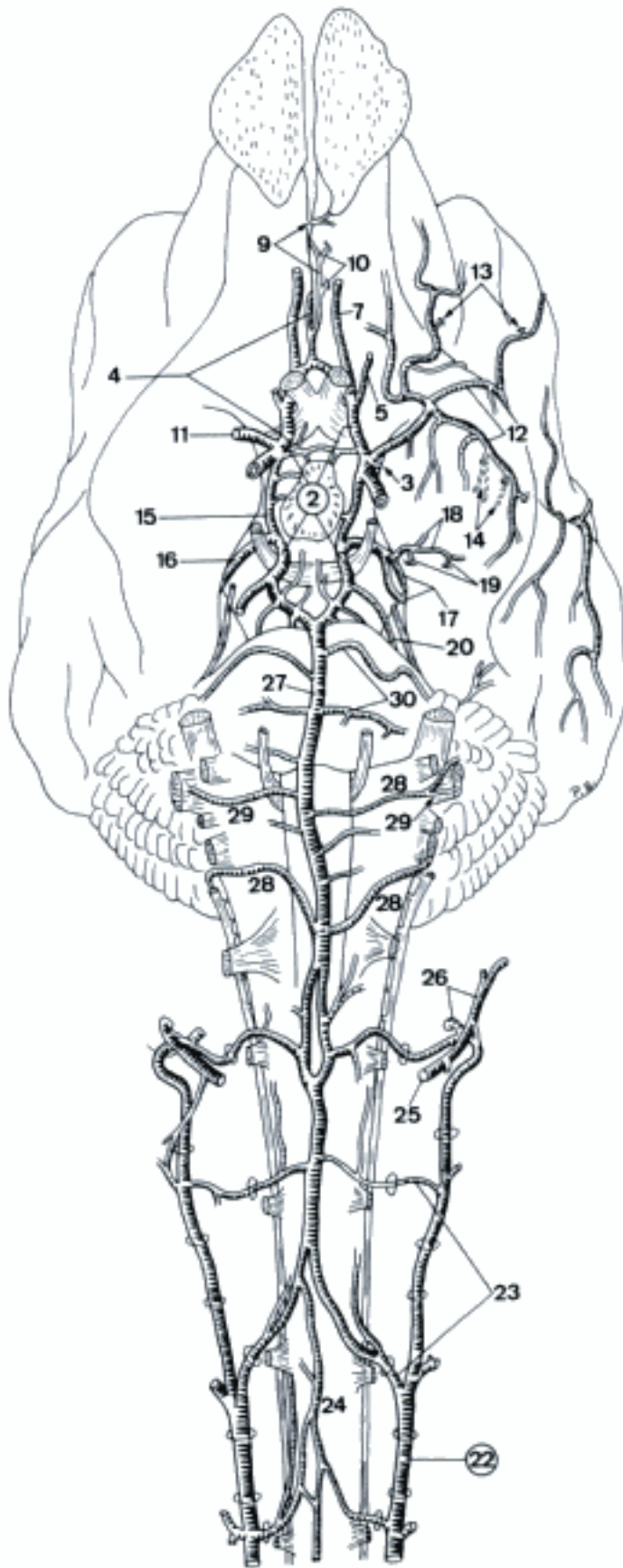
E Aa. carotides internae, ventral aspect (bo)

TERMINI COMMUNES

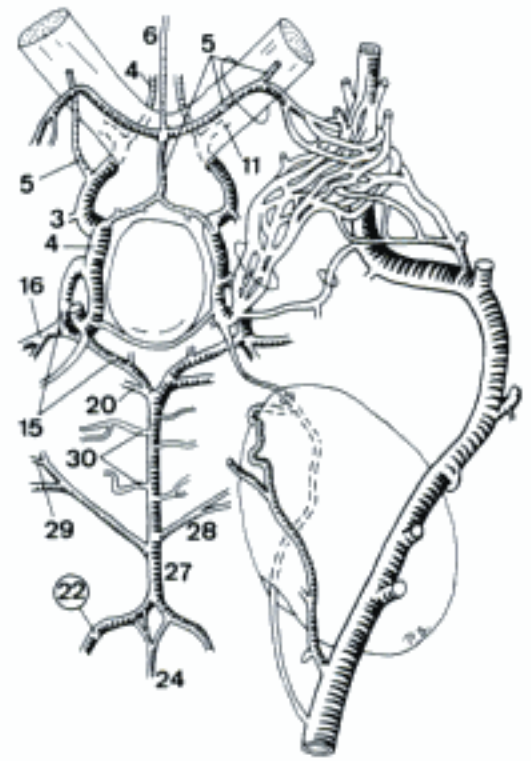
- 1 **ARTERIAE CEREBRI.** Supply the brain.
- 2 *Circulus arteriosus cerebri.* Willis' arterial circle, surrounds Hypophysis and Chiasma opticum. Formed by A. communicans rostralis, Aa. cerebri rostrales, and Aa. communicantes caudales. A B
- 3 *A. choroidea [chorioidea] rostralis.* Mainly contributes to Plexus choroideus ventriculi lateralis. A B
- 4 **A. cerebri rostralis.** Originates directly from A. carotis interna, forms the rostrolateral quadrant of Circulus arteriosus cerebri and continues curving on Facies medialis of Hemispherium. A B C
- 5 *A. ophthalmica interna.* Accompanies N. opticus through Canalis opticus, anastomoses with A. ophthalmica externa. Given off by Rete chiasmaticum in bo. A B C
- 6 *A. meningeae rostralis (fe).* Rostrally directed single branch to Dura mater encephali. Arises from the intracranial communication between both Aa. ophthalmica internae. B
- 7 *A. ethmoidalis interna.* Courses rostrally to Fossa ethmoidalis where it rami-fies. A C
- 8 *A. communicans rostralis.* Connection between right and left A. cerebri rostralis just rostral to Chiasma opticum. Constant in su, inconstant in Car and Ru, absent in eq. Occasionally plural in su and Ru. C
- 9 *Rami corticales.* Supply Cortex cerebri. A C
- 10 *Rami centrales.* Penetrate deeply into the brain. A
- 11 **A. cerebri media.** Arises from Circulus arteriosus cerebri, passes laterally to Lobus piriformis. Represented by two or three branches in su. A B C
- 12 *Rami corticales.* To Cortex cerebri. A C
- 13 *Rami centrales.* Penetrate into the brain. A
- 14 *Rami striati.* Supply Corpus striatum and associated structures. A
- 15 **A. communicans caudalis.** Connects A. carotis interna with A. basilaris and forms the caudolateral quadrant of Circulus arteriosus cerebri. A B C
- 16 *A. cerebri caudalis.* Courses dorsolaterally around Crus cerebri. Often double in eq, plural in ca. A B C
- 17 *Rami choroidei [chorioidei] caudales.* Reach Plexus choroideus ventriculi tertii. A
- 18 *Rami corticales.* To the cortex. A C
- 19 *Rami centrales.* Penetrate into the brain. A
- 20 *A. cerebelli rostralis.* Arises from A. communicans caudalis, occasionally (su, ov, eq) from A. basilaris. Crosses Crus cerebri and courses dorsocaudally to the lateral aspect of cerebellum. May be plural (fe, su, ov, eq). A B C
- 21 **ARTERIA SUBCLAVIA.** Intrathoracic portion of the artery to Membrum thoracicum. The left arises from Arcus aortae (Car, su) or Truncus brachiocephalicus (Ru, eq), the right is usually given off by Truncus brachiocephalicus. D

CARNIVORA

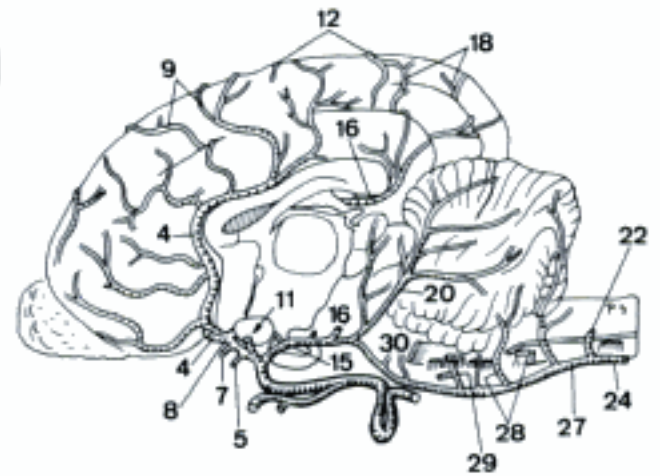
- 22 **A. vertebralis.** Passes cranially inside Foramina transversaria of Vertebrae cervicales VI–I, turns dorsally through Incisura alaris and enters Canalis vertebralis via Foramen vertebrale laterale of atlas. Then the right and left join to form A. basilaris. A B C D
- 23 *Rami spinales.* Enter Canalis vertebralis through the cervical Foramina intervertebralia. A D
- 24 *A. spinalis ventralis.* Unpaired vessel at Fissura mediana. A B C
- 25 *Ramus anastomoticus cum a. occipitali.* Joins A. occipitalis. May be partially absent in fe. A
- 26 *Ramus descendens.* Muscular branch, emerges dorsally through Incisura alaris. A
- 27 **A. basilaris.** Unpaired vessel on the ventral surface of rhombencephalon, formed by the union of both Aa. vertebrales. A B C
- 28 *A. cerebelli caudalis.* To the caudal aspect of cerebellum. May be plural. A B C
- 29 *A. labyrinthi.* Enters Meatus acusticus internus and supplies Auris interna. A B C
- 30 *Rami ad pontem.* Branches for pons. May be absent in ca. A B C



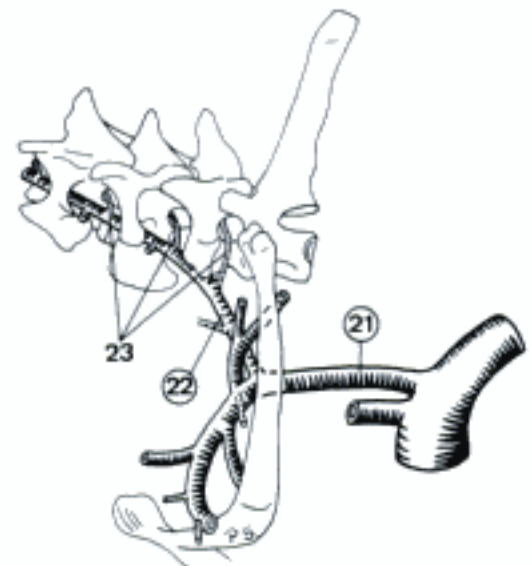
A Aa. cerebri and A. vertebralis, ventral aspect (ca)



B Circulus arteriosus cerebri, ventral aspect (fc)

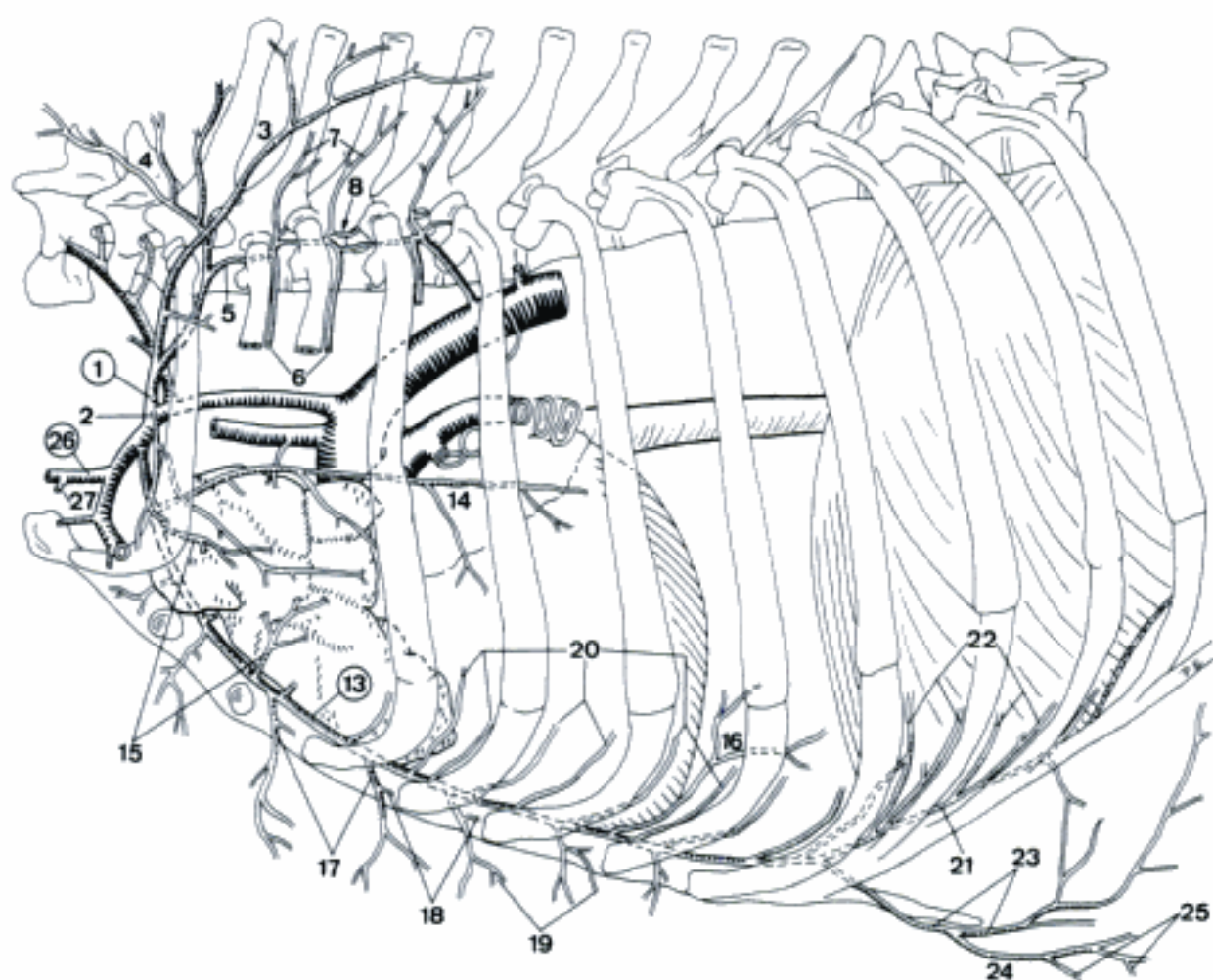


C Arteries of the brain (left hemisphere removed), left aspect (ca)

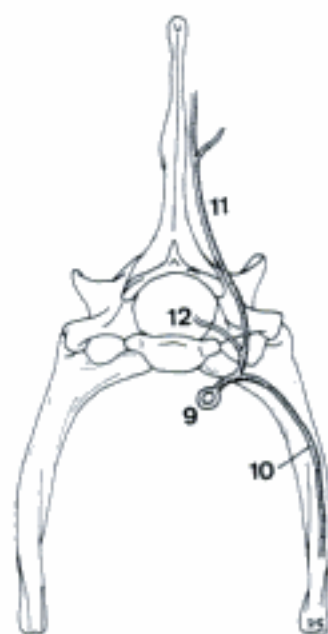


D A. subclavia sinistra, lateral aspect (ca)

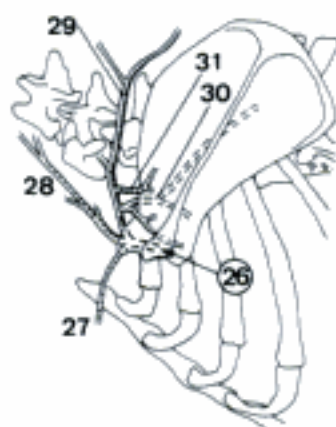
- 1 **Truncus costocervicalis.** Dorsally directed arterial trunk. Inconstant in fe. A
- 2 *A. intercostalis dorsalis I.* Supplies the first Spatium intercostale. A
- 3 *A. scapularis dorsalis.* Courses dorsally through the first Spatium intercostale or at the cranial aspect of Costa I. A
- 4 *A. cervicalis profunda.* Leaves Cavum thoracis through the first Spatium intercostale and curves dorsocranially into the cervical musculature. A
- 5 *A. vertebralis thoracica (ca).* Courses caudally on the dorsal aspect of the necks of 2nd and 3rd ribs. A
- 6 *Aa. intercostales dorsales II et III.* Course ventrally in the corresponding Spatium intercostale. A
- 7 *Rami dorsales.* Course dorsally to Mm. dorsi. A
- 8 *Ramus spinalis.* Enters Canalis vertebralis via the corresponding Foramen intervertebrale. A
- 9 *A. intercostalis suprema (fe).* Courses caudally on the ventral aspects of the necks of the 2nd and 3rd ribs. May be absent. B
- 10 *Aa. intercostales dorsales II et III.* Course ventrally in the respective Spatium intercostale. B
- 11 *Ramus dorsalis.* Courses dorsally to Mm. dorsi. B
- 12 *Ramus spinalis.* Enters Canalis vertebralis via the corresponding Foramen intervertebrale. B
- 13 **A. thoracica interna.** Curves caudoventrally and passes between sternum and M. transversus thoracis. A
- 14 *A. pericardiacophrenica.* Runs caudally with N. phrenicus to pericardium, and reaches occasionally Diaphragma. A
- 15 *Rami thymici.* Supply thymus. May be single (esp. fe). A
- 16 *Rami mediastinales.* Essentially to Mediastinum craniale. A
- 17 *Rami perforantes.* Leave Cavum thoracis via the ventral parts of Spatia intercostalia. A
- 18 *Rami sternales.* To the sternebrae. A
- 19 *Rami mammarii.* Supply the medial portions of the Mammæ thoracicae. A
- 20 *Rami intercostales ventrales.* Frequently double segmental branches which supply the ventral parts of Spatia intercostalia II–VIII, usually absent in the second in fe. A
- 21 *A. musculophrenica.* Courses caudo-dorsolaterally, perforates Diaphragma and continues subperitoneally. A
- 22 *Rami intercostales ventrales.* Often double segmental branches supplying the ventral parts of Spatia intercostalia VIII–X (XI). A
- 23 *A. epigastrica cranialis.* Leaves thorax caudally and continues on the dorsal aspect of M. rectus abdominis. A
- 24 *A. epigastrica cranialis superficialis.* Perforates M. rectus abdominis and continues subcutaneously. A
- 25 *Rami mammarii.* To the caudal thoracic and cranial abdominal mammae. A
- 26 **A. cervicalis superficialis.** Dorsocranially directed arterial stem. A C
- 27 *Ramus deltoideus.* Accompanies V. cephalica in Sulcus pectoralis lateralis. A C
- 28 *Ramus ascendens.* Cranially directed muscular branch at the medial aspect of M. cleidocephalicus. Frequently double. C
- 29 *Ramus prescapularis [prae-].* Continuation of A. cervicalis superficialis beyond the origin of A. suprascapularis. Runs parallel to Margo cranialis of scapula. C
- 30 *A. suprascapularis.* Accompanies N. suprascapularis and divides at the cranial aspect of Collum scapulae. C
- 31 *Ramus acromialis.* Courses on the lateral aspect of scapula. C



A A. subclavia sinistra (ca)



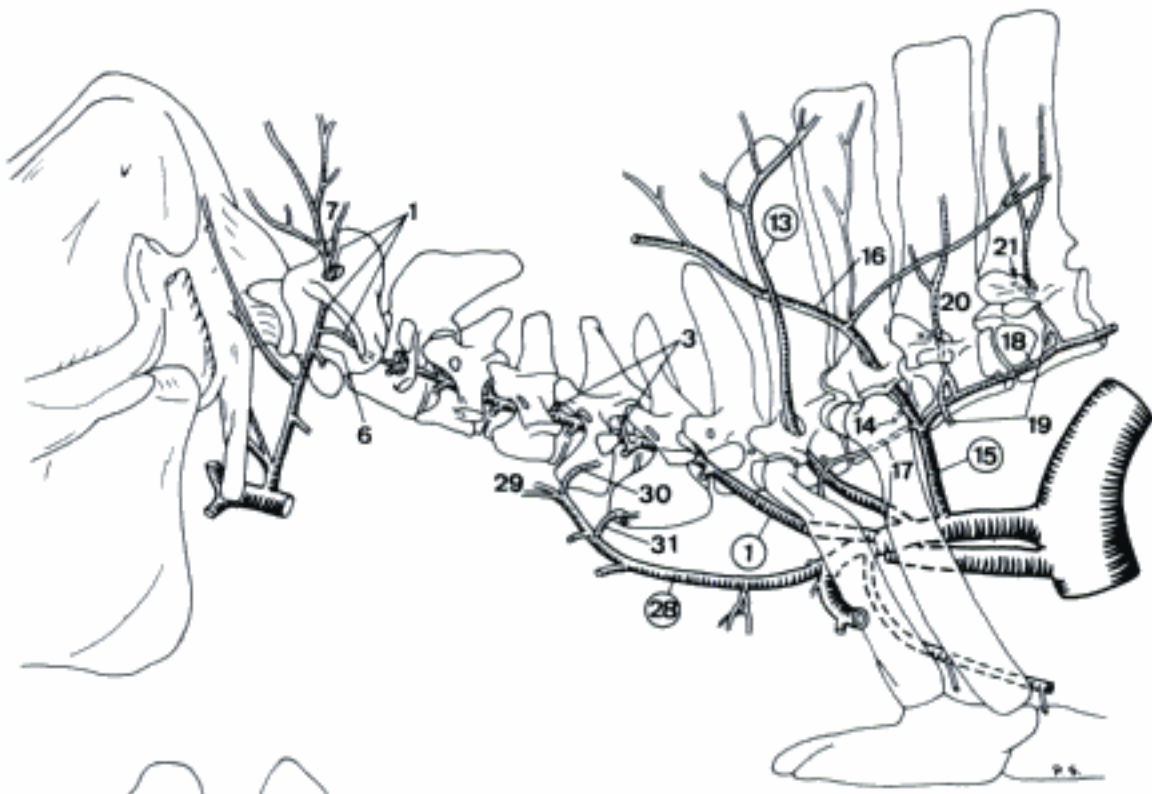
B Branches of A. intercostalis suprema, caudal aspect (fe)



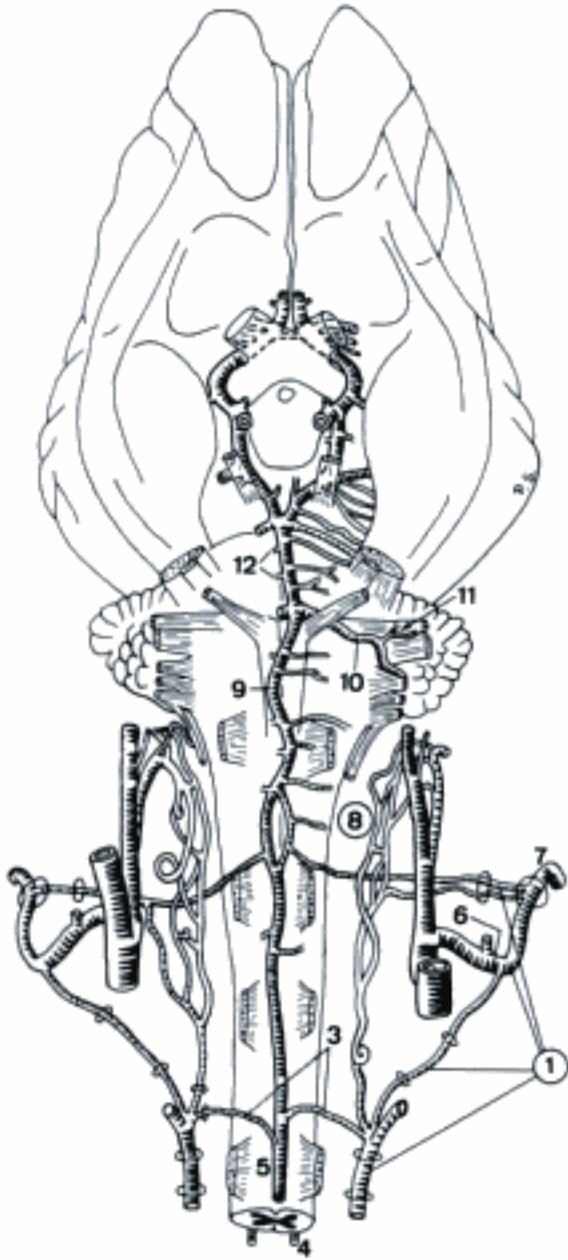
C A. cervicalis superficialis, lateral aspect (ca)

SUS

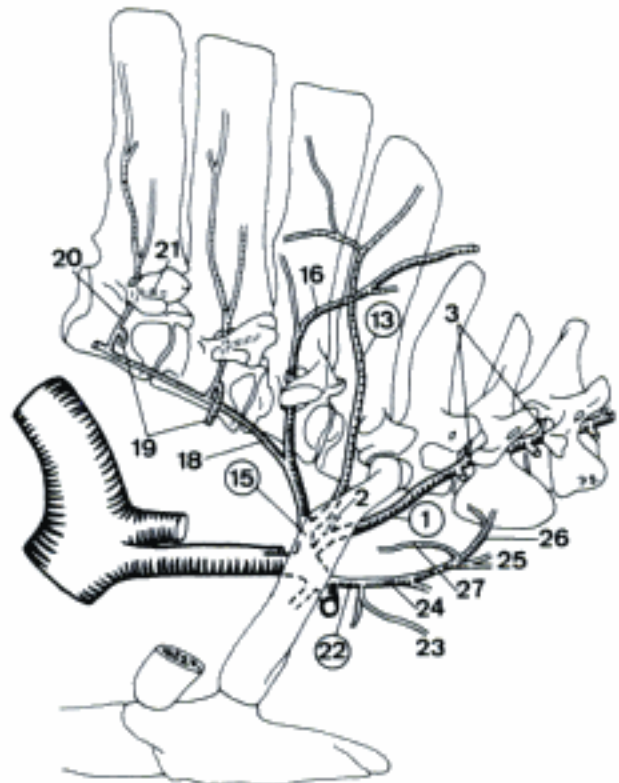
- 1 **A. vertebralis.** Courses cranially inside Foramina transversaria of Vertebrae cervicales (VI) V–I, continues through Fossa atlantis, Foramen alare, and Foramen vertebrale laterale of atlas. Then both join to A. basilaris. A B C
- 2 *A. intercostalis dorsalis I dextra.* Courses ventrally in the first Spatium intercostale. C
- 3 *Rami spinales.* Enter Canalis vertebralis through the cervical Foramina intervertebralia (VIII) VII–III and Foramen vertebrale laterale of axis. A B C
- 4 *A. spinalis dorsalis.* Small, near Radices dorsales of Nervi spinales. B
- 5 *A. spinalis ventralis.* Unpaired at Fissura mediana. B
- 6 *Ramus anastomoticus cum a. occipitali.* Arises in Fossa atlantis and joins A. occipitalis. A B
- 7 *Ramus descendens.* Muscular branch, emerges dorsally through Foramen alare. A B
- 8 *Rete mirabile epidurale caudale.* Arterial network near the beginning of canalis vertebralis. Supplied by A. vertebralis and A. condylaris. B
- 9 **A. basilaris.** Unpaired vessel on the ventral surface of rhombencephalon. Formed by the union of both Aa. vertebrales. B
- 10 *A. cerebelli caudalis.* Courses dorso-laterally to the caudal aspect of cerebellum. Exceptionally double. B
- 11 *A. labyrinthi.* Enters Meatus acusticus internus and supplies Auris interna. B
- 12 *Rami ad pontem.* Branches for pons. B
- 13 **A. scapularis dorsalis.** Leaves Cavum thoracis via the first Spatium intercostale and/or pierces through Foramen vertebrale laterale of Vertebra thoracica I. A C
- 14 *A. intercostalis dorsalis II.* Courses ventrally in the second Spatium intercostale. A
- 15 **Truncus costocervicalis.** Common stem for A. cervicalis profunda and A. intercostalis suprema. Occasionally absent. A C
- 16 *A. cervicalis profunda.* Passes through Foramen vertebrale laterale of Vertebra thoracica II. A C
- 17 *A. intercostalis dorsalis I sinistra.* Courses ventrally in the first Spatium intercostale. A
- 18 *A. intercostalis suprema.* Runs on the dorsolateral aspect of M. longus colli. A C
- 19 *Aa. intercostales dorsales III–V.* Course ventrally in the corresponding Spatium intercostale. A C
- 20 **Ramus dorsalis.** Courses dorsally and passes through Foramen vertebrale laterale of the corresponding vertebra. Frequently double. A C
- 21 **Ramus spinalis.** Passes through Foramen intervertebrale or Foramen vertebrale laterale. A C
- 22 **Truncus thyrocervicalis [thyreo-].** Trunk for A. cervicalis superficialis and A. thyroidea caudalis, usually only on the right side. C
- 23 *A. thyroidea [thyroidea] caudalis dextra.* Courses cranially to Gl. thyroidea. C
- 24 *A. cervicalis superficialis dextra.* Courses in craniodorsal direction. C
- 25 *Ramus ascendens.* Craniodorsally directed muscular branch. C
- 26 *Ramus prescapularis [prae-].* Continuation of A. cervicalis superficialis along the cranial border of M. subclavius. C
- 27 *Ramus acromialis.* Enters the lateral aspect of M. supraspinatus, crosses Collum scapulae laterally. C
- 28 **A. cervicalis superficialis sinistra.** Courses cranioventrally and continues craniodorsally. A
- 29 *Ramus ascendens.* Craniodorsally directed muscular branch along the medial aspect of M. cleidocephalicus. A
- 30 *Ramus prescapularis [prae-].* Courses along the cranial border of M. subclavius. A
- 31 *Ramus acromialis.* Enters the lateral aspect of M. supraspinatus and crosses Collum scapulae laterally. A



A A. subclavia sinistra, lateral aspect (su)

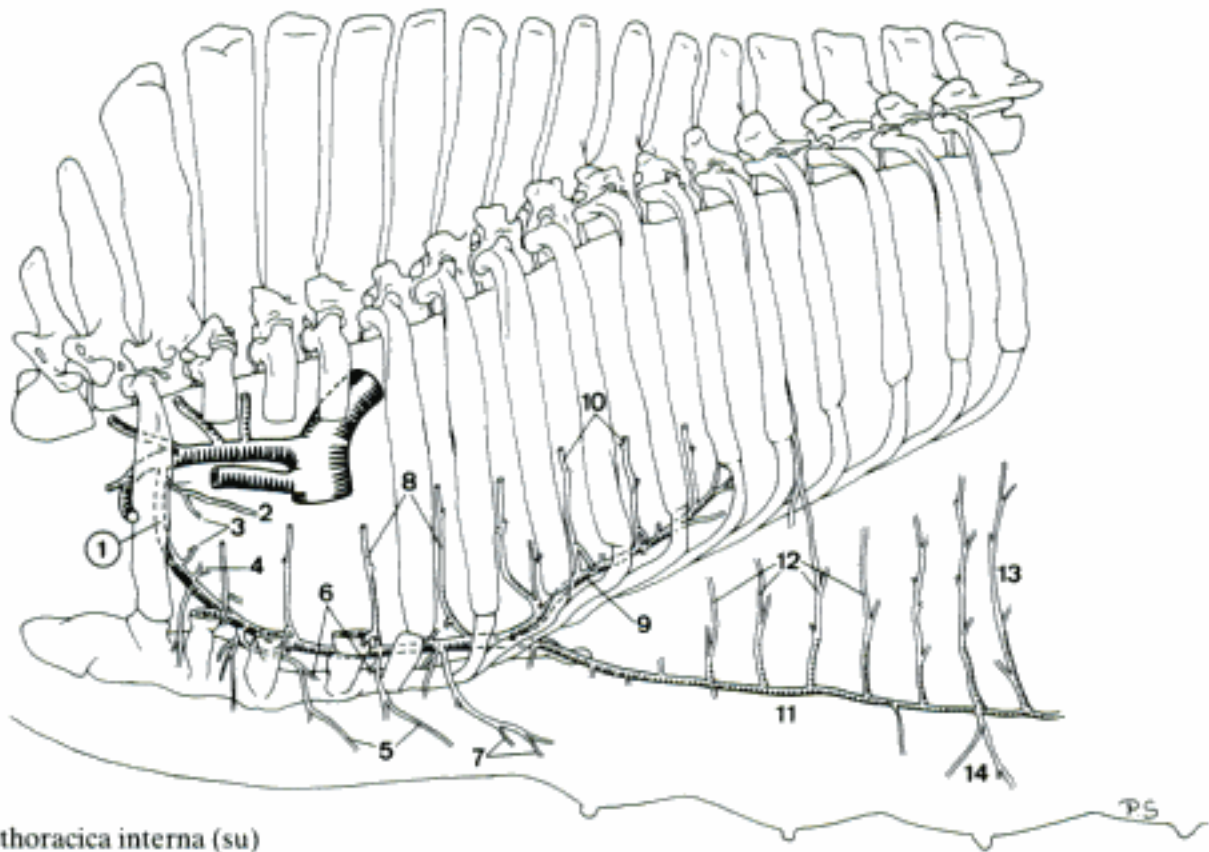


B A. vertebralis, ventral aspect (su)

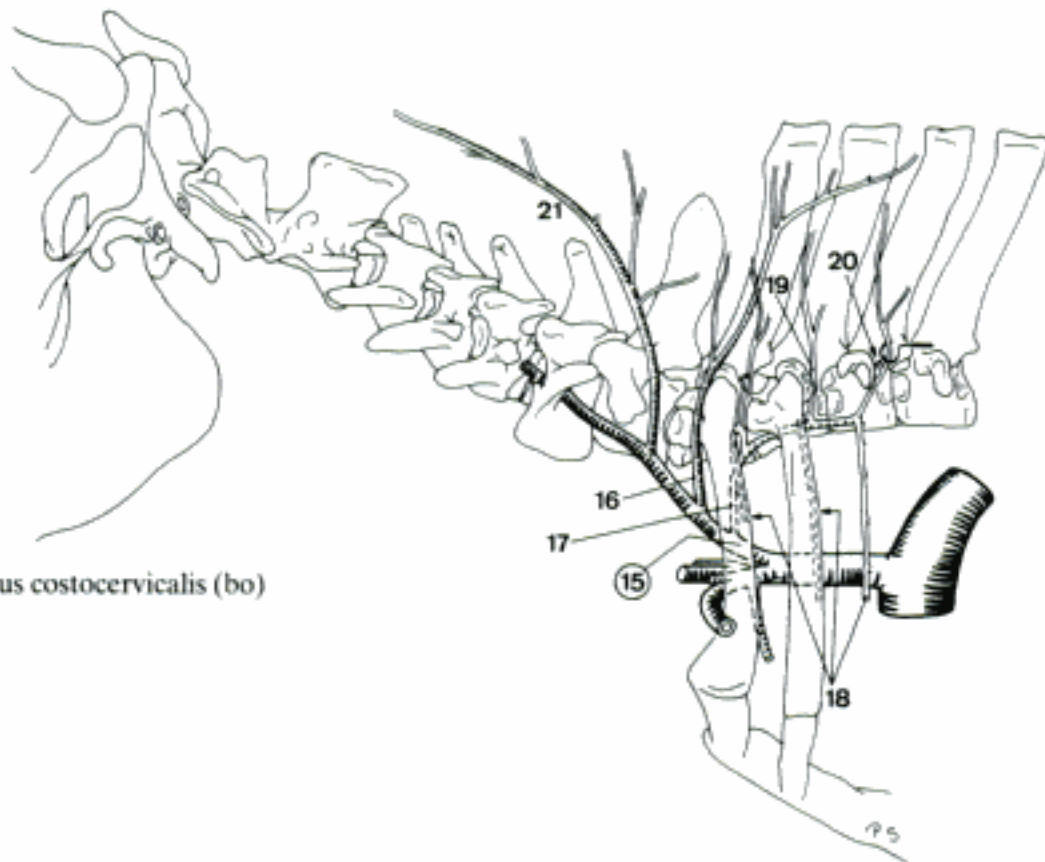


C Truncus brachiocephalicus, right aspect (su)

- 1 **A. thoracica interna.** Courses caudoventrally and continues caudally on the ventral aspect of *M. transversus thoracis*. A
 - 2 *A. pericardiophrenica.* Courses caudally to pericardium and may reach Diaphragma. Occasionally absent. A
 - 3 *Rami thymici.* To Thymus. A
 - 4 *Rami mediastinales.* Lie in Mediastinum craniale. A
 - 5 *Rami perforantes.* Perforate *Mm. intercostales* near sternum. A
 - 6 *Rami sternales.* To sternum. A
 - 7 *Rami mammarii.* Supply the *Mammae thoracicae*. A
 - 8 *Rami intercostales ventrales.* Supply the ventral parts of the first 6 or 7 *Spatia intercostalia*. May be absent or indistinct in some segments. A
 - 9 *A. musculophrenica.* Pierces through Diaphragma after coursing caudodorsally along the medial face of *Arcus costalis*. A
 - 10 *Rami intercostales ventrales.* Supply the ventral parts of *Spatia intercostalia* (VI) VII and VIII. A
 - 11 *A. epigastrica cranialis.* Courses caudally on the dorsal aspect of *M. rectus abdominis*. A
 - 12 *Rami intercostales ventrales.* Run dorsally to *Spatia intercostalia* IX–XII (XIII). May be absent in the caudal segments. A
 - 13 *Ramus costoabdominalis ventralis.* Courses dorsally to the caudal aspect of last rib. A
 - 14 *Rami mammarii.* To the first two *Mammae abdominales*. A
- RUMINATIA
- 15 **Truncus costocervicalis.** Craniodorsally directed, variably branching arterial trunk, given off by *A. subclavia*. B
 - 16 *A. scapularis dorsalis.* Crosses the vertebral end of the first rib cranially, and continues caudodorsally. B
 - 17 *A. intercostalis suprema.* Courses caudally on the ventral aspect of the necks of 1st, 2nd (3rd) rib, exceptionally on their dorsal aspect (cap, ov). B
 - 18 *Aa. intercostales dorsales I et II (III).* Course ventrally at the caudal margin of the corresponding rib. B
 - 19 *Ramus dorsalis.* Runs dorsally to *Mm. dorsi*. B
 - 20 *Ramus spinalis.* Given off by *Ramus dorsalis*, occasionally by *A. intercostalis dorsalis* (bo). Enters *Canalis vertebralis* via the corresponding *Foramen vertebrale laterale* (bo) or *Foramen intervertebrale* (ov, cap). B
 - 21 *A. cervicalis profunda.* Passes dorsally at the caudal (exceptionally cranial) aspect of *Processus transversus* of the seventh *Vertebra cervicalis*. Continues far cranially in the neck (bo). B

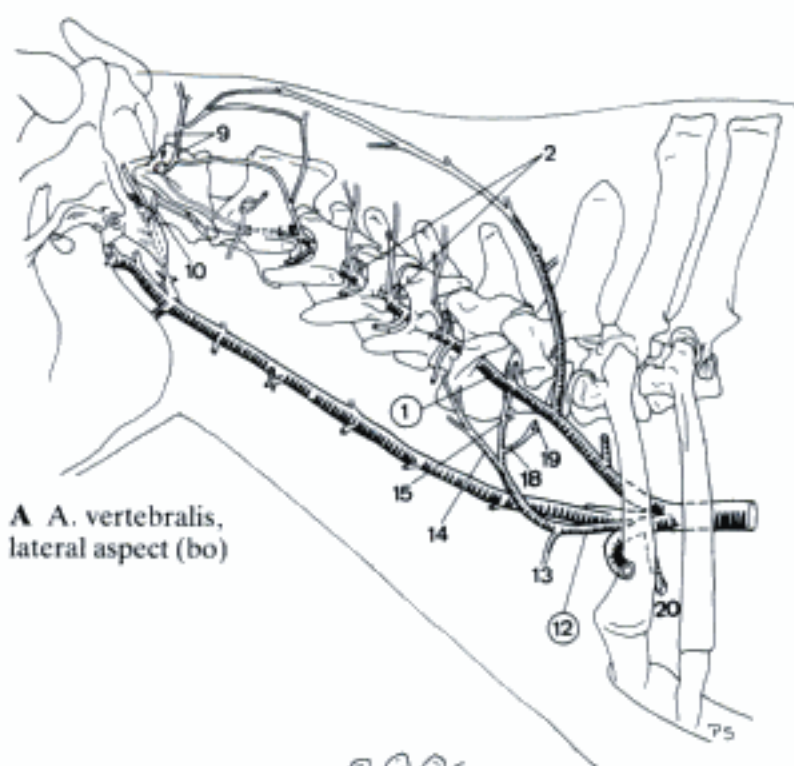


A A. thoracica interna (su)

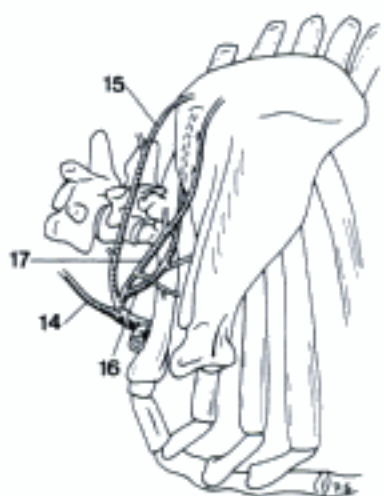


B Truncus costocervicalis (bo)

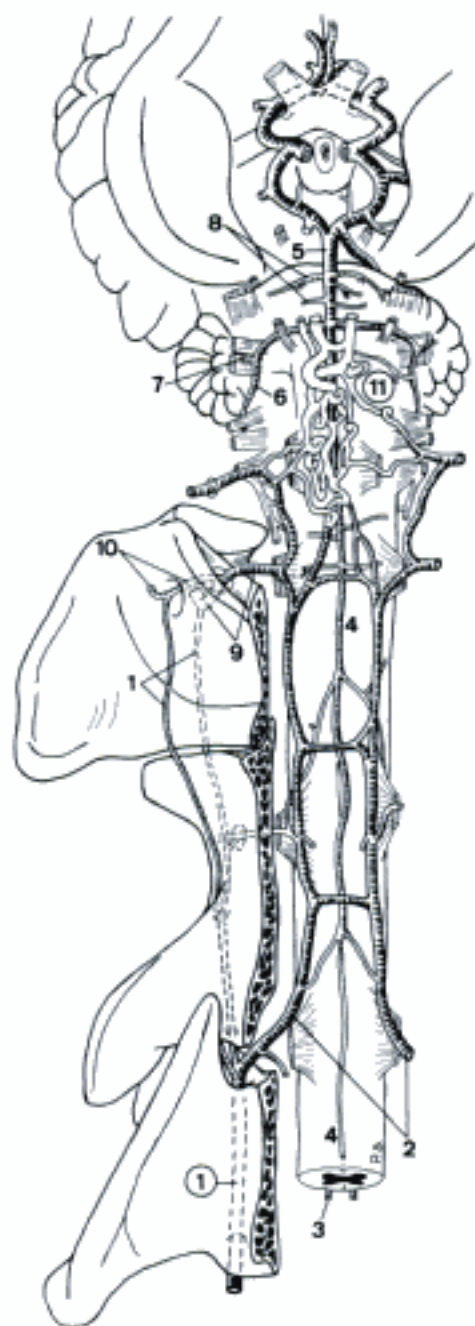
- 1 **A. vertebralis.** Continuation of Truncus costocervicalis that courses craniodorsally through Foramina transversaria of Vertebrae cervicales VI–III. Then most blood is conducted in Canalis vertebralis by the Ramus spinalis between Vertebrae cervicales II and III (exc. III and IV). The course, along the lateral aspect of atlas and axis, is represented by a branch which usually traverses the Foramen transversarium of axis and gives rise to small branches which join Ramus descendens and Ramus anastomoticus cum a occipitali. A B
- 2 *Rami spinales.* Enter the Foramina intervertebralia VII (except some ov), VI–III and Foramen vertebrale laterale of axis. A B
- 3 *A. spinalis dorsalis.* Irregular vessel along Radices dorsales of Nervi spinales. Absent at some levels. B
- 4 *A. spinalis ventralis.* Unpaired vessel at Fissura mediana. B
- 5 **A. basilaris.** Large unpaired vessel between the union of both Aa. communicantes caudales and A. spinalis ventralis. B
- 6 *A. cerebelli caudalis.* Courses dorsolaterally to the caudal aspect of cerebellum. B
- 7 *A. labyrinthi.* Enters Meatus acusticus internus and supplies Auris interna. B
- 8 *Rami ad pontem.* Branches for pons. B
- 9 *Ramus descendens.* Large muscular branch which emerges through Foramen vertebrale laterale of atlas. A B
- 10 *Ramus anastomoticus cum a. occipitali.* Passes through Foramen alare to join A. occipitalis. Sometimes absent in bo and ov. A B
- 11 *Rete mirabile epidurale caudale (bo).* Epidural arterial network at Os occipitale. Formed by A. vertebralis and A. condylaris. Continuous with the rostral rete. B
- 12 **A. cervicalis superficialis.** Cranially directed. A C D
- 13 *Ramus deltoideus.* Accompanies V. cephalica in Sulcus pectoralis lateralis. Inconstant. A
- 14 *Ramus ascendens.* Courses craniodorsally at the medial face of M. brachiocephalicus. A C
- 15 *Ramus prescapularis [prae-].* Courses at the cranial margin of M. supraspinatus. A C
- 16 *A. suprascapularis (ov, cap).* Extends across the craniomedial face of M. supraspinatus. C
- 17 *Ramus acromialis.* Courses laterally to the craniolateral aspect of M. supraspinatus. C
- 18 *Ramus suprascapularis (bo).* Small vessel accompanying N. suprascapularis. A
- 19 *Ramus acromialis.* Crosses M. supraspinatus cranially. A
- 20 **A. thoracica interna.** Curves caudoventrally and continues caudally on the ventral aspect of M. transversus thoracis. A D
- 21 *A. pericardiophrenica.* Courses caudally to pericardium and may reach Diaphragma. Occasionally absent. D
- 22 *Rami thymici.* To thymus. Usually singular or even absent. D
- 23 *Rami mediastinales.* To mediastinum. D
- 24 *Rami perforantes.* Pass through the ventral parts of Spatia intercostalia I–VI. D
- 25 *Rami sternales.* To the adjacent Sternebrae. D
- 26 *Rami intercostales ventrales.* Course dorsally at the caudal margin of Costae I–VI. D
- 27 *A. musculophrenica.* Courses caudo-dorsally, perforates Diaphragma and continues parallel to Arcus costalis. D
- 28 *Rami intercostales ventrales.* Course dorsally along the caudal margin of Costae VII–VIII (IX, X). D
- 29 *Ramus phrenicus.* Enters Pars sternalis of Diaphragma. D
- 30 *A. epigastrica cranialis.* Pierces between Arcus costalis and Processus xiphoideus (bo, ov) or passes through Spatium intercostale VII (cap). Continues caudally to the dorsal aspect of M. rectus abdominis and finally enters it. D
- 31 *A. epigastrica cranialis superficialis.* Becomes subcutaneous. D
- 32 *Rami intercostales ventrales.* Course dorsally to Costae (IX, X) XI–XII. D
- 33 *Ramus costoabdominalis ventralis.* Runs dorsally towards the caudal aspect of the last rib. D



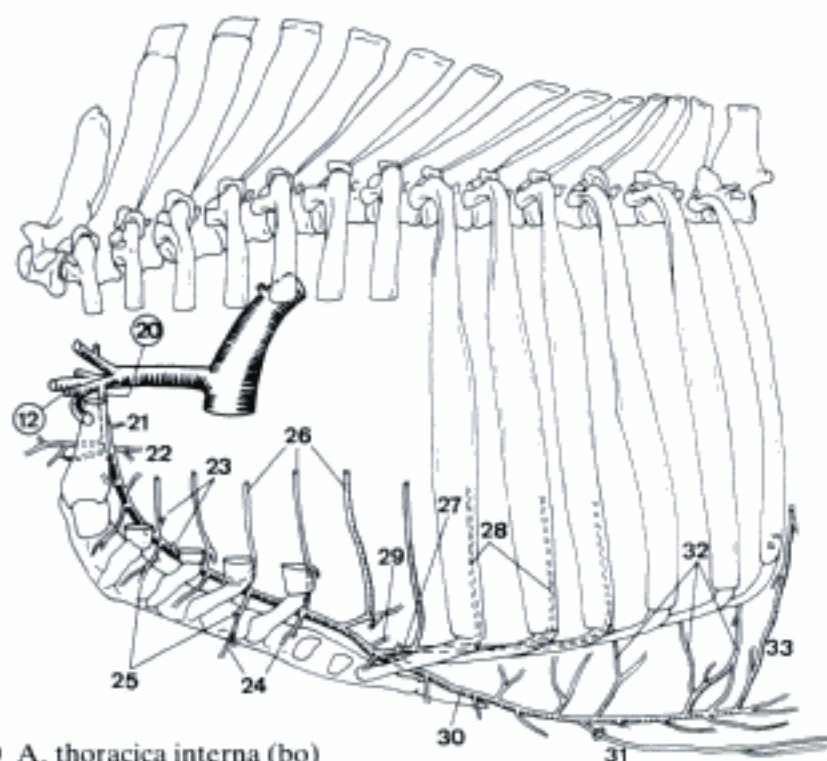
A A. vertebralis, lateral aspect (bo)



C Branches of A. cervicalis superficialis, lateral aspect (ov)



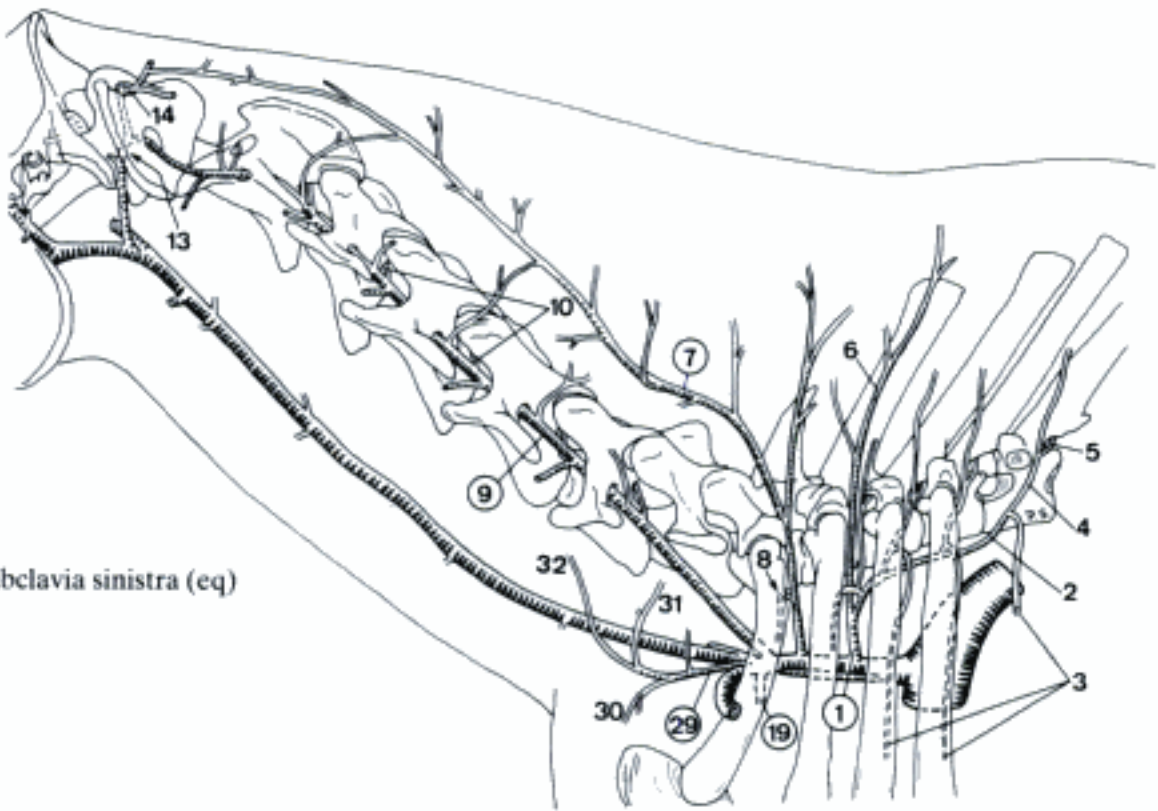
B A. vertebralis, ventral aspect (bo)



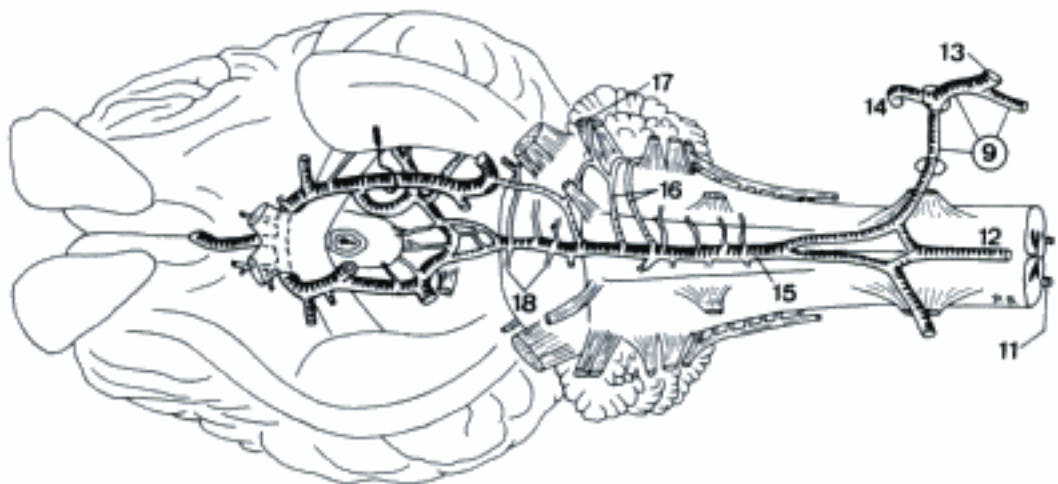
D A. thoracica interna (bo)

EQUUS

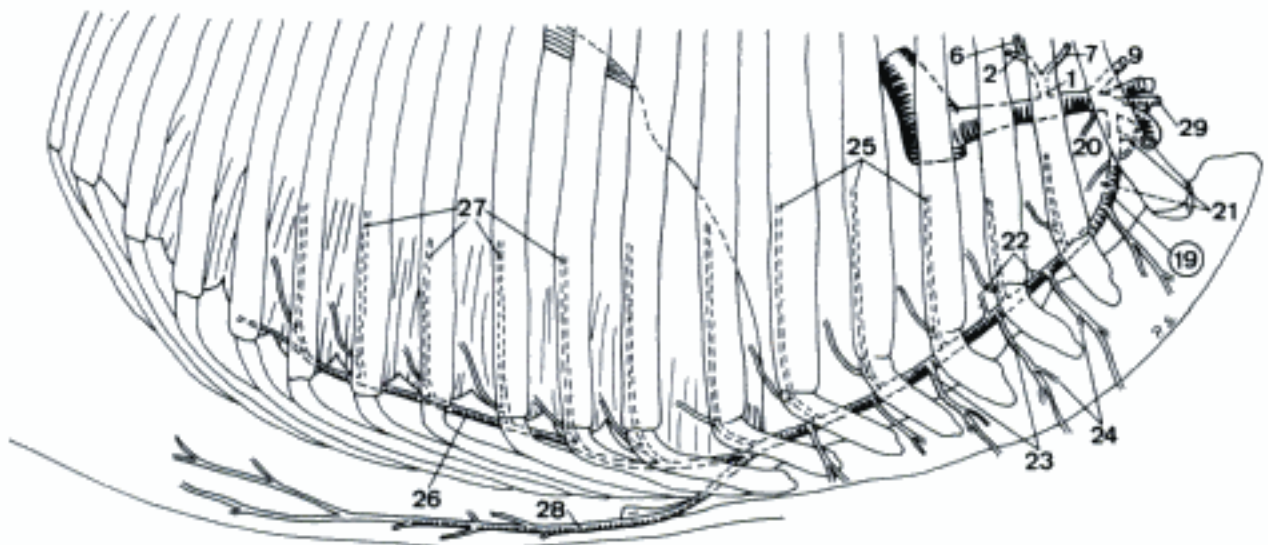
- 1 **Truncus costocervicalis.** Dorsally directed arterial trunk. May arise from Truncus brachiocephalicus (esp. on the right), exceptionally from aorta. A C
- 2 *A. intercostalis suprema.* Courses caudally on the lateral aspect of *M. longus colli*. A C
- 3 *Aa. intercostales dorsales II–V.* Course ventrally along the caudal margin of the corresponding rib. A
- 4 *Ramus dorsalis.* Courses dorsally to *Mm. dorsi*. A
- 5 *Ramus spinalis.* Through the corresponding Foramen intervertebrale in *Canalis vertebralis*. A
- 6 *A. scapularis dorsalis.* Emerges through *Spatium intercostale II* (exc. III). A C
- 7 **A. cervicalis profunda.** Passes through *Spatium intercostale I* or II. May arise from *Truncus costocervicalis*. A C
- 8 *A. intercostalis dorsalis I.* Runs ventrally in *Spatium intercostale I*. A
- 9 **A. vertebralis.** Courses through *Foramina transversaria* of *Vertebrae cervicales* (VII, VI), V–I, continues through *Fossa atlantis*, *Foramen alare*, and enters *Canalis vertebralis* via *Foramen vertebrale laterale* of atlas. Then both *Aa. vertebrales* join to *A. basilaris*. Given off from *Truncus brachiocephalicus* on the right. A B C
- 10 *Rami spinales.* Enter *Canalis vertebralis* via cervical *Foramina intervertebralia VIII–III* and *Foramen vertebrale laterale* of axis. A
- 11 *A. spinalis dorsalis.* On the dorsolateral aspect of *Medulla spinalis*. B
- 12 *A. spinalis ventralis.* Unpaired at *Fissura mediana*. B
- 13 *Ramus anastomoticus cum a. occipitali.* Anastomosis with *A. occipitalis*. A B
- 14 *Ramus descendens.* Muscular branch, emerges dorsally through *Foramen alare*. A B
- 15 **A. basilaris.** Unpaired, formed by the union of both *Aa. vertebrales*. Runs rostrally on the ventral surface of rhombencephalon. B
- 16 *Aa. cerebelli caudales.* Course laterally to the caudal aspect of cerebellum. Frequently singular. B
- 17 *A. labyrinthi.* Passes to *Auris interna* via *Meatus acusticus internus*. Usually given off by one of the *Aa. cerebelli caudales*. B
- 18 *Rami ad pontem.* Branches for pons. B
- 19 **A. thoracica interna.** Curves ventrocaudally and passes on the ventral aspect of *M. transversus thoracis*. A C
- 20 *A. pericardiacophrenica.* Supplies pericardium and accompanies *N. phrenicus* to *Diaphragma*. C
- 21 *Rami thymici.* To thymus. C
- 22 *Rami mediastinales.* Supply *mediastinum craniale*. C
- 23 *Rami perforantes.* Perforate *Mm. intercostales* near sternum. C
- 24 *Rami sternales.* To sternum. C
- 25 *Rami intercostales ventrales.* Course dorsally at the caudal margin of the first (6) 7 ribs. C
- 26 *A. musculophrenica.* Runs caudodorsally, perforates *Diaphragma* and continues parallel to the costal arch. C
- 27 *Rami intercostales ventrales.* Course dorsally in *Spatia intercostalia* (VII) VIII–XI(–XVI). C
- 28 *A. epigastrica cranialis.* Emerges between *Cartilago costalis IX* and *Cartilago xiphoidea* and passes into the abdominal wall. C
- 29 **A. cervicalis superficialis.** Cranioventrally directed. A C
- 30 *Ramus deltoideus.* Accompanies *V. cephalica* in *Sulcus pectoralis lateralis*. A
- 31 *Ramus prescapularis [prae-].* Runs parallel to the cranial border of *M. subclavius*. A
- 32 *Ramus ascendens.* Courses craniodorsally at the medial side of *M. brachiocephalicus*. A



A A. subclavia sinistra (eq)



B A. basilaris, ventral aspect (eq)



C A. thoracica interna, lateral aspect (eq)

TERMINUS COMMUNIS

- 1 **ARTERIA AXILLARIS.** Continuation of A. subclavia beyond the origin of A. cervicalis superficialis. A B

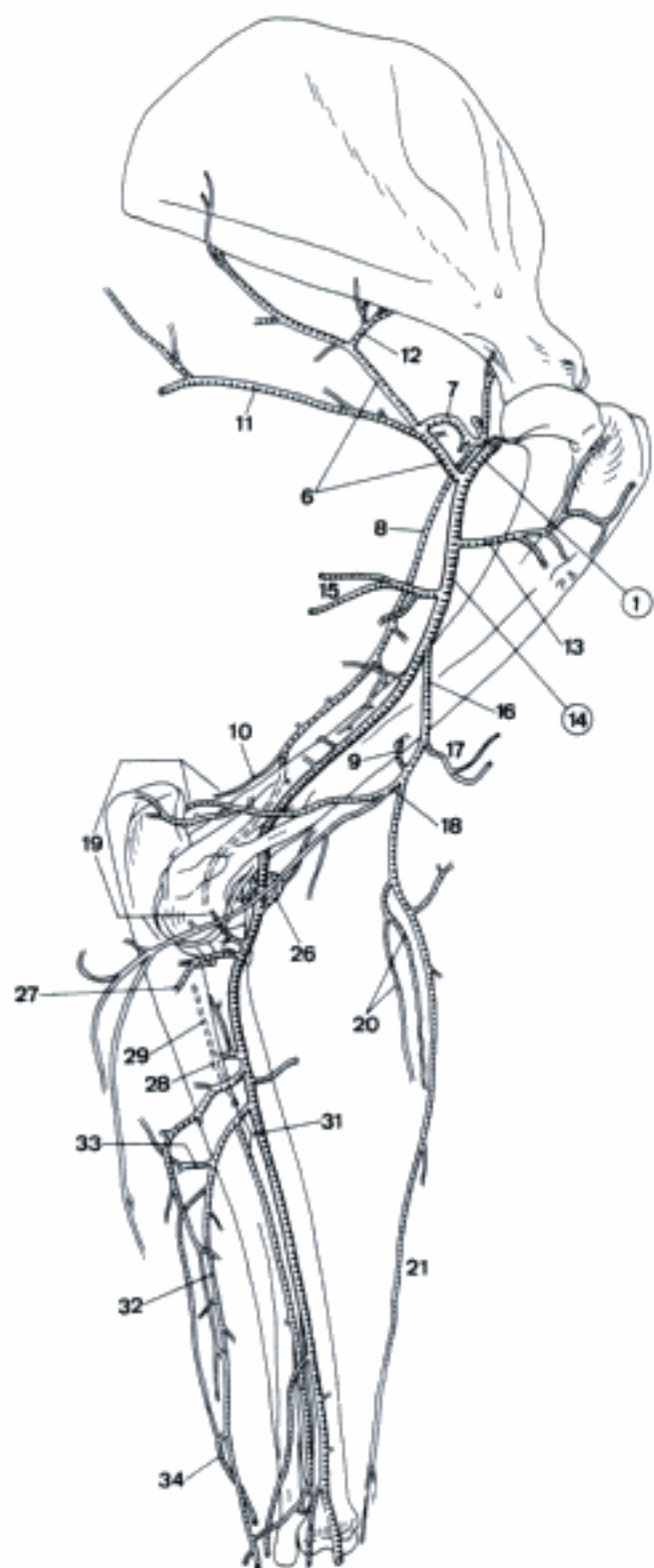
CARNIVORA

- 2 *Ramus deltoideus (ca).* Accompanies V. cephalica in Sulcus pectoralis lateralis. B
- 3 *A. thoracica externa.* Courses across the cranial border of M. pectoralis profundus, supplies the pectoral muscles. B
- 4 *A. thoracica lateralis.* Runs caudally toward the ventral thoracic wall. B
- 5 *Rami mammarii laterales.* Supply the Mammae thoracicae. B
- 6 *A. subscapularis.* Courses along the caudal border of scapula. A B
- 7 *A. circumflexa humeri caudalis.* Courses across the caudal aspect of Articulatio humeri. A B
- 8 *A. collateralis radialis.* Accompanies N. radialis onto the surface of M. brachialis. A B
- 9 *A. nutricia humeri.* Variable origin. A B
- 10 *A. collateralis media.* Branch of A. collateralis radialis to Rete articulare cubiti. May be absent (ca). A B
- 11 *A. thoracodorsalis.* Passes across the medial surface of M. teres major to M. latissimus dorsi. A B
- 12 *A. circumflexa scapulae.* Passes craniodorsally across the lateral and medial aspects of scapula. A B
- 13 *A. circumflexa humeri cranialis.* Curves cranially along the medial aspect of humerus. A B

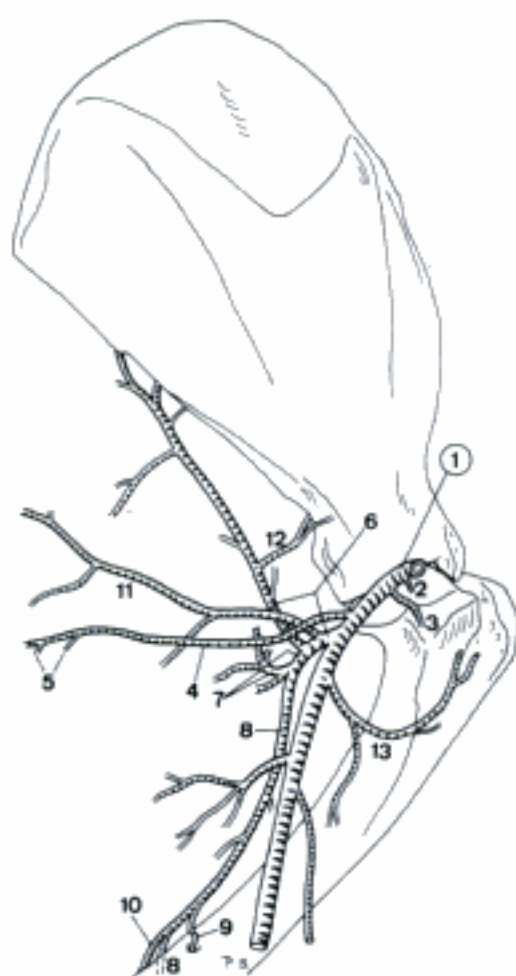
FELIS

- 14 **A. brachialis.** Runs distally with N. medianus, traverses Foramen supracondylare. A
- 15 *A. profunda brachii.* To the muscles of the caudal side of brachium. A
- 16 *A. brachialis superficialis.* Courses along M. biceps brachii to the cranial aspect to Articulatio cubiti. A
- 17 *A. bicipitalis.* Enters M. biceps brachii. A
- 18 *A. collateralis ulnaris.* Ramifies at olecranon. A

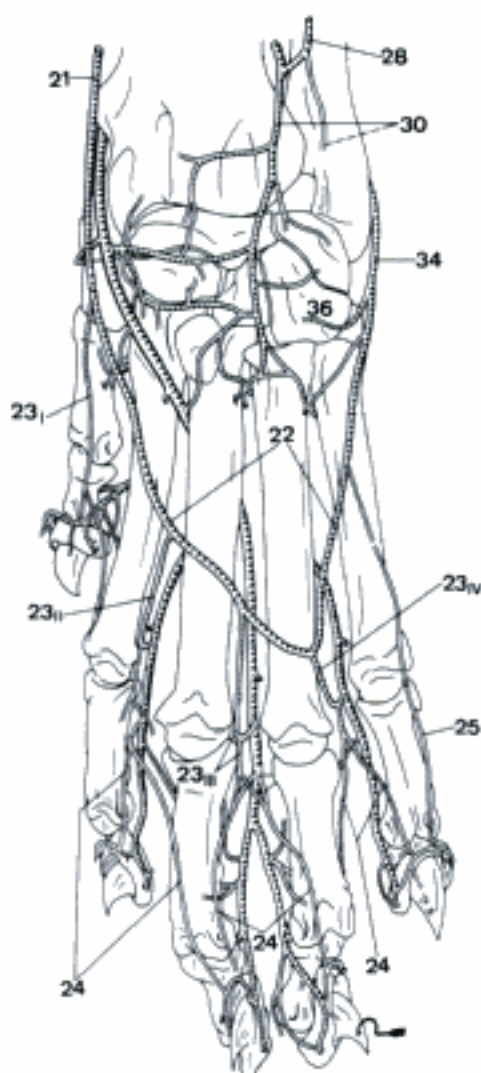
- 19 *Rete articulare cubiti.* Network at the caudal aspect of Articulatio cubiti. A
- 20 *Aa. radiales superficiales.* Accompany N. cutaneus antebrachii medialis. A
- 21 *A. antebrachialis superficialis cranialis.* Courses along the craniomedial aspect of antebrachium. A C
- 22 *Arcus dorsalis superficialis.* Subcutaneous communication to Ramus dorsalis of A. ulnaris in Regio metacarpi dorsalis. C
- 23 *Aa. digitales dorsales communes I–IV.* Superficial branches of Arcus dorsalis superficialis. C
- 24 *Aa. digitales dorsales propriae.* A rise from the bifurcation of Aa. digitales dorsales communes. C
- 25 *A. digitalis dorsalis V. abaxialis.* Arises from Arcus dorsalis superficialis. C
- 26 *A. transversa cubiti.* Curves laterally across the cranial surface of Articulatio cubiti. A
- 27 *A. profunda antebrachii.* Plural and variable, to caudal muscles of antebrachium.
- 28 *A. interossea cranialis.* Pierces the Spatium interosseum, continues on the cranial aspect of Membrana interossea. A C
- 29 *A. recurrens interossea.* Passes proximally to the lateral aspect of Articulatio cubiti. A
- 30 *Ramus carpeus dorsalis.* Often double contribution to Rete carpi dorsale. C
- 31 *A. interossea caudalis.* Courses between Membrana interossea and M. pronator quadratus. A
- 32 *A. ulnaris.* Accompanies N. ulnaris in Sulcus antebrachii caudalis. A
- 33 *A. recurrens ulnaris.* Courses proximally at the medial aspect of olecranon, anastomoses with A. collateralis ulnaris. A
- 34 *Ramus dorsalis.* To Arcus dorsalis superficialis. A C
- 35 *Ramus carpeus palmaris.*
- 36 *Ramus carpeus dorsalis.* Branch of Ramus dorsalis to Rete carpi dorsale. C



A Arteries of left thoracic limb, medial aspect (fc)

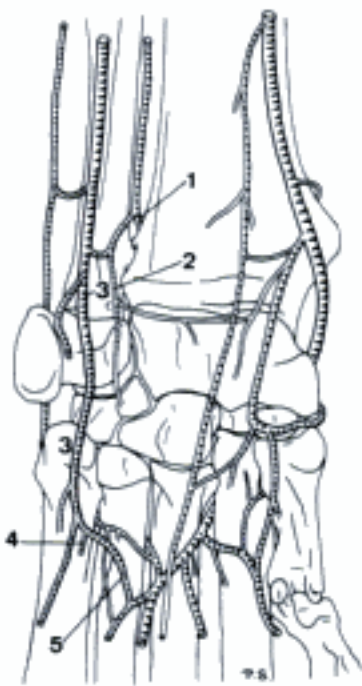


B Arteries of left axilla, medial aspect (ca)

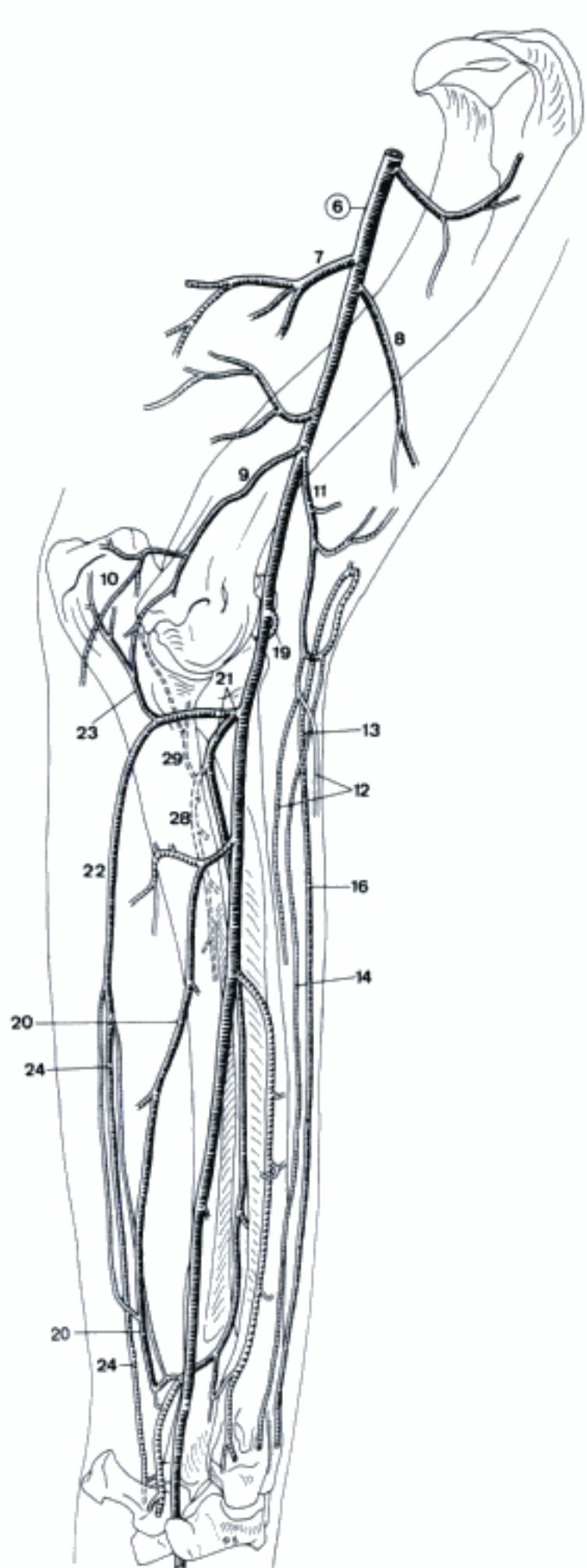


C Arteries of left manus, dorsal aspect (fc)

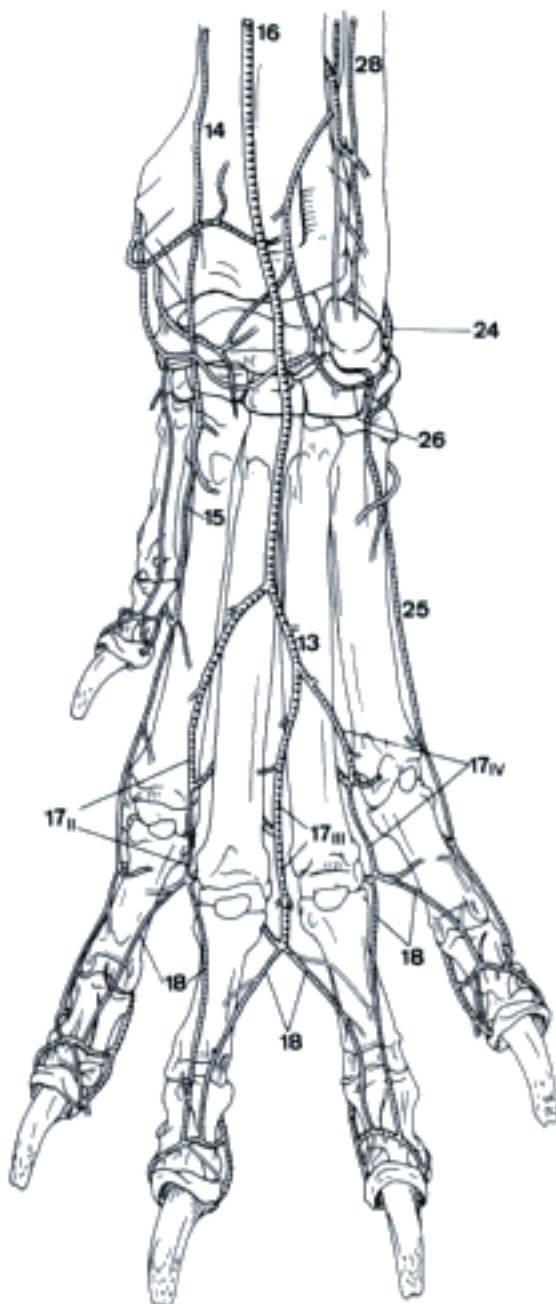
- 1 *Ramus interosseus*. Branch of *A. interossea caudalis*, passes through the distal part of *Spatium interosseum antebrachii*, joins *A. interossea cranialis*. A
 - 2 *Ramus carpeus palmaris*. Branch to the palmar aspect of carpus. A
 - 3 *Ramus palmaris*. Continuation of *A. interossea caudalis* beyond the origin of *Ramus carpeus palmaris*. Joins *A. ulnaris*. A
 - 4 *Ramus superficialis*. Courses at the lateropalmar aspect of metacarpus. Joins *Arcus palmaris superficialis* and/or continues as *A. digitalis palmaris communis IV* and *A. digitalis palmaris V abaxialis*. A
 - 5 *Ramus profundus*. Passes to *Mm. interossei*, forming the lateral contribution to *Arcus palmaris profundus*. A
- CANIS
- 6 ***A. brachialis***. Continuation of *A. axillaris*. Runs distally across the medial aspect of humerus. B
 - 7 *A. profunda brachii*. To the caudal musculature of brachium. B
 - 8 *A. bicipitalis*. Supply for *M. biceps brachii*. B
 - 9 *A. collateralis ulnaris*. Courses caudally and, near *N. ulnaris*, ramifies at olecranon. B
 - 10 *Rete articulare cubiti*. Arterial network at the caudal aspect of *Articulatio cubiti*. B
 - 11 *A. brachialis superficialis*. Courses craniodistally across the distal part of *M. biceps brachii*. B
 - 12 *Aa. radiales superficiales*. Pair of small superficial vessels that accompany *N. cutaneus antebrachii medialis*. B
 - 13 *A. antebrachialis superficialis cranialis*. Continuation of *A. brachialis superficialis* in the antebrachium. Immediately bifurcated. B
 - 14 *Ramus medialis*. Runs along the cranio-medial border of *M. extensor carpi radialis* and on the dorsomedial aspect of carpus. B C
 - 15 *A. digitalis dorsalis communis I*. Continuation of *Ramus medialis* of *A. antebrachialis superficialis cranialis*. C
 - 16 *Ramus lateralis*. Runs on the cranial aspect of antebrachium and the dorsal of carpus. B C
 - 17 *Aa. digitales dorsales communes II–IV*. Run on the superficial surface of the extensor tendons. C
 - 18 *Aa. digitales dorsales propriae*. Three pairs of vessels, arisen from the bifurcation of *Aa. digitales dorsales communes II–IV*. Run along the dorsal parts of the adjacent surface of digits. C
 - 19 *A. transversa cubiti*. Curves laterally across *Articulatio cubiti*. B
 - 20 *A. profunda antebrachii*. Variable supply for the muscles on the caudal side of antebrachium. B
 - 21 *A. interossea communis*. Proceeds to the *Spatium interosseum antebrachii*. B
 - 22 *A. ulnaris*. Runs caudally across the medial aspect of ulna, where it joins *N. ulnaris*. Continues along the lateral surface of *M. flexor carpi ulnaris*. B
 - 23 *A. recurrens ulnaris*. Courses proximally along the medial aspect of olecranon and joins *Rete articulare cubiti*. B
 - 24 *Ramus dorsalis*. Courses along the lateral border of *M. flexor carpi ulnaris* to *Regio carpi lateralis*. B C
 - 25 *A. digitalis dorsalis V abaxialis*. Runs along the dorsolateral surface of metacarpus and digit V. C
 - 26 *Ramus carpeus dorsalis*. To *rete carpi dorsale*. C
 - 27 *Ramus carpeus palmaris*.
 - 28 *A. interossea cranialis*. Passes cranially through the proximal part of *Spatium interosseum antebrachii* and continues distally along the cranial aspect of *Membrana interossea antebrachii*. B C
 - 29 *A. recurrens interossea*. Courses proximally to the lateral aspect of *Articulatio cubiti* and contributes to *Rete articulare cubiti*. B



A Arteries of left carpus, palmar aspect (fe)

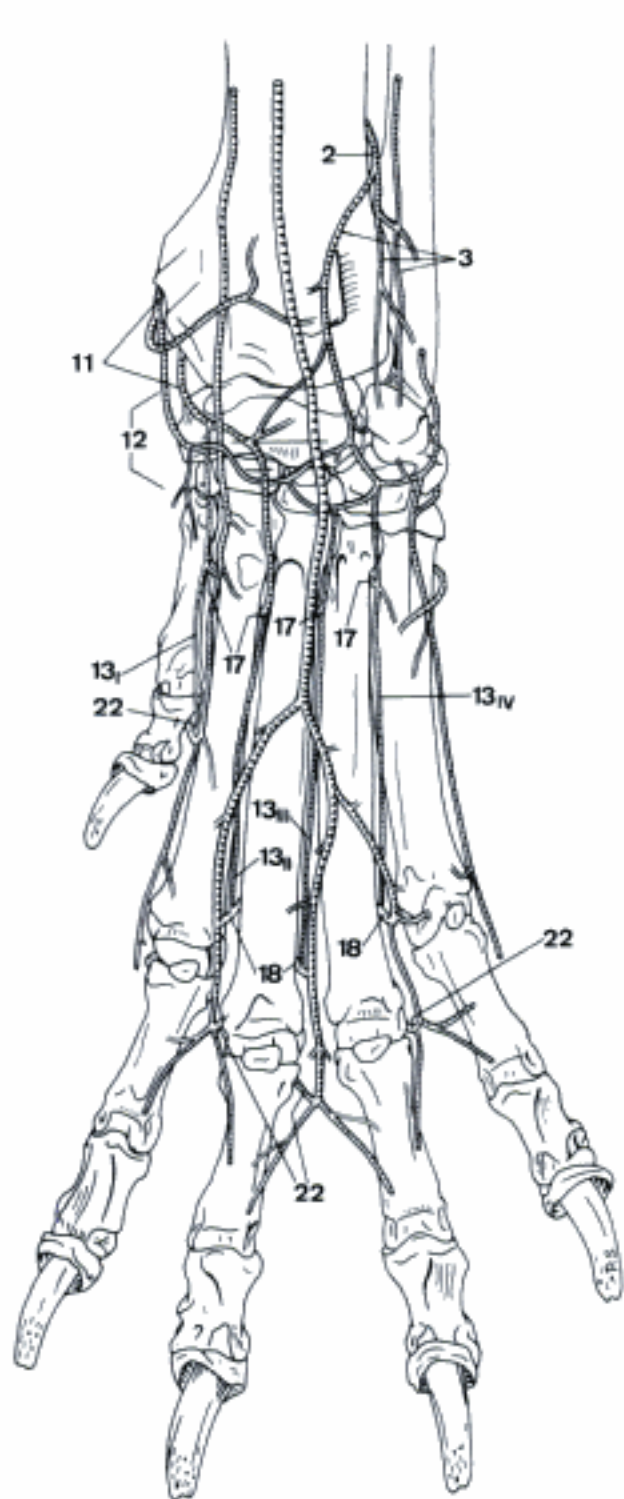


C Arteries of left manus, dorsal aspect (ca)

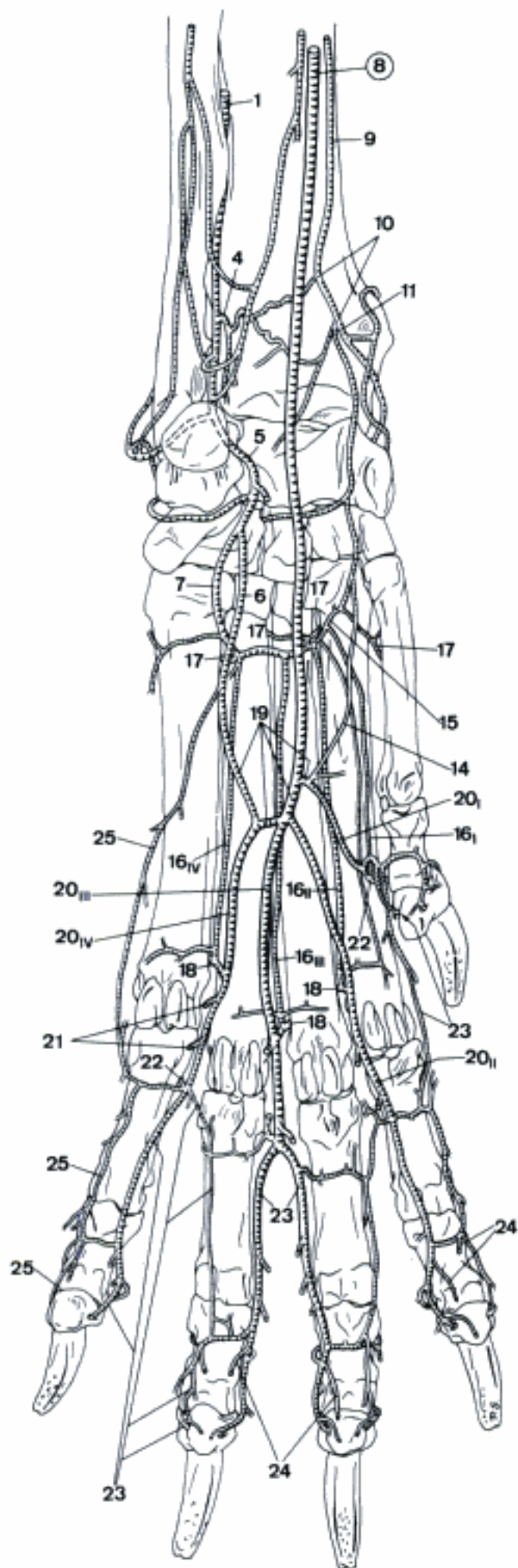


B Arteries of left thoracic limb, medial aspect (ca)

- 1 *A. interossea caudalis*. Courses between Membrana interossea antebrachii and M. pronator quadratus. B
 - 2 Ramus interosseus. Passes cranially through the distal part of Spatium interosseum antebrachii. A
 - 3 Ramus carpeus dorsalis. To Rete carpi dorsale. A
 - 4 Ramus carpeus palmaris. Small branch to the palmar aspect of carpus. B
 - 5 Ramus palmaris. Continuation of A. interossea caudalis. Joins A. ulnaris and/or A. profunda antebrachii. B
 - 6 Ramus superficialis. Lateral contribution to Arcus palmaris superficialis. B
 - 7 Ramus profundus. Lateral contribution to Arcus palmaris profundus. B
- CARNIVORA
- 8 **A. mediana**. Continuation of A. brachialis beyond the origin of A. interossea communis (ca) s. caudalis (fe). Courses along the caudomedial aspect of antebrachium, passes through Canalis carpi to Regio metacarpi palmaris. Distal to the origin of A. radialis it is much diminished in size in fe. B
 - 9 *A. radialis*. Courses along the caudomedial border of radius and in Retinaculum flexorum to the mediopalmar aspect of carpus. B
 - 10 *Ramus carpeus palmaris*. Courses to the palmar aspect of carpus. B
 - 11 *Ramus carpeus dorsalis*. Runs dorsodistally across the medial aspect of carpus. Usually plural. A B
 - 12 Rete carpi dorsale. Network on the dorsal aspect of carpus. A
 - 13 Aa. metacarpeae dorsales I–IV. Join A. interdigitalis (I) s. Ramus perforans distalis (II–IV). A
 - 14 *Ramus palmaris superficialis*. Joins Arcus palmaris superficialis, or may continue as A. digitalis palmaris communis II (most fe). B
 - 15 *Arcus palmaris profundus*. Lies across the palmar aspect of Mm. interossei. May be incomplete, or be complemented by a supplementary arch on the dorsal aspect of Mm. interossei (ca). In fe mainly supplied via Ramus carpeus dorsalis of A. radialis. B
 - 16 Aa. metacarpeae palmares I–IV. B
 - 17 Ramus perforans proximalis. Connects each of the Aa. metacarpeae palmares with its dorsal counterpart by piercing through the proximal part of the corresponding Spatium interosseum metacarpi. A B
 - 18 Ramus perforans distalis. Connects each of the Aa. metacarpeae palmares II–IV with its dorsal counterpart by traversing the distal part of the corresponding Spatium interosseum metacarpi. Also connected with Aa. digitales dorsales et palmares communes II–IV. A B
 - 19 *Arcus palmaris superficialis*. Situated between M. flexor digitorum profundus and M. flexor digitorum superficialis. Usually absent in fe. B
 - 20 Aa. digitales palmares communes I–IV (ca), II–IV (fe). B
 - 21 Ramus tori metacarpei. Usually double branch, supplies Torus metacarpeus. B
 - 22 A. interdigitalis. Connects each of the Aa. digitales palmares communes with the corresponding A. digitalis dorsalis communis (Car) or Aa. digitales dorsales propriae (fe). A B
 - 23 Aa. digitales palmares propriae. 3 (fe) or 4 (ca) pairs of arteries which course distally along the adjacent palmar aspects of digits. Finally enter Foramen soleare axiale s. abaxiale of Phalanx distalis. B
 - 24 Ramus tori digitalis. Usually double branch, supplies the Torus digitalis. B
 - 25 *A. digitalis palmaris V abaxialis*. Finally enters Foramen soleare abaxiale of Phalanx distalis V. B



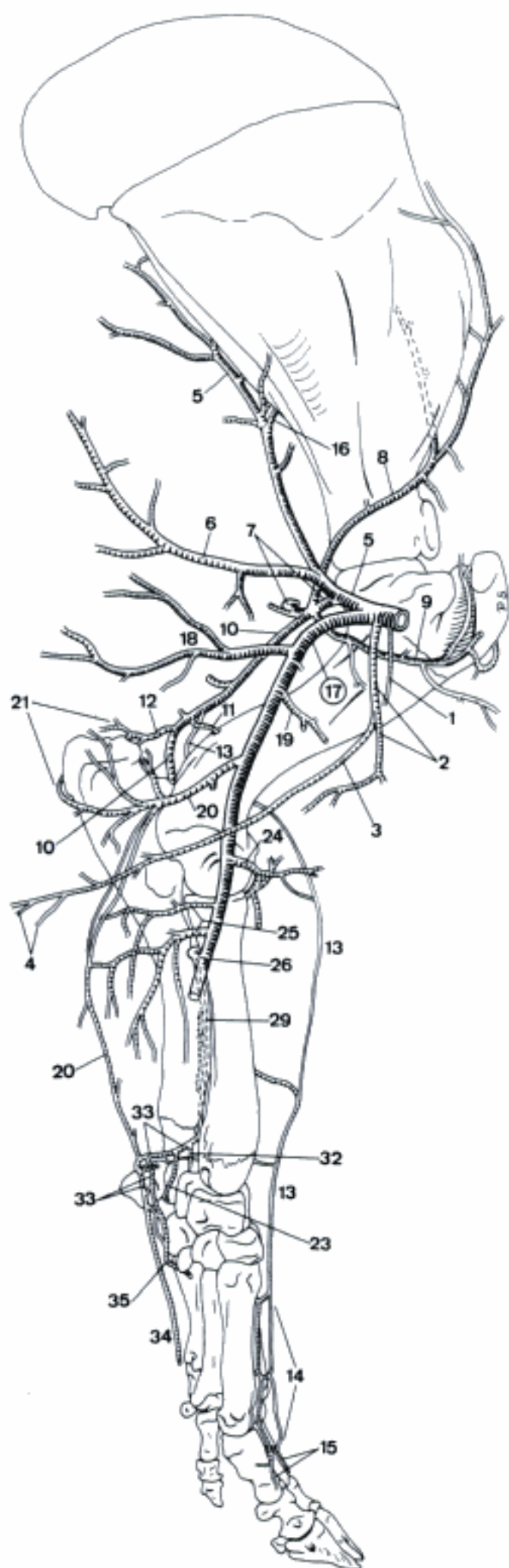
A Arteries of left manus, dorsal aspect (ca)



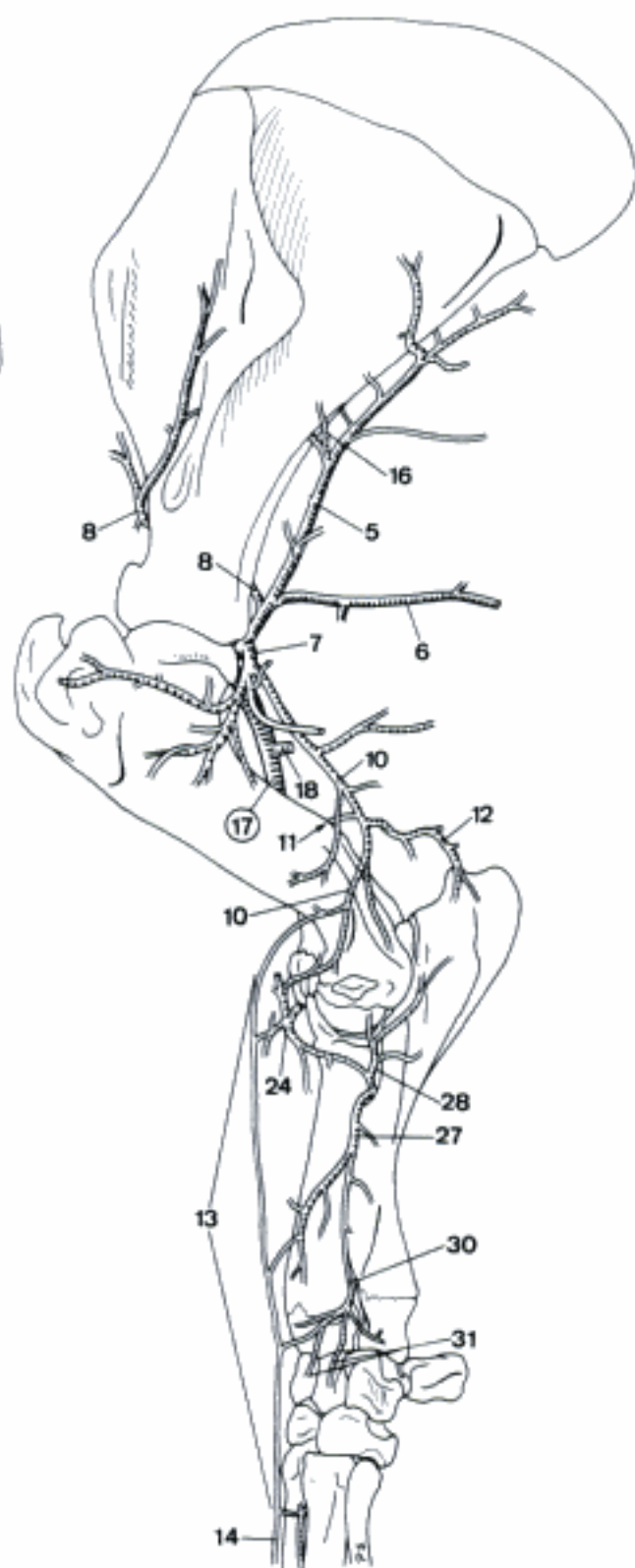
B Arteries of left manus, palmar aspect (ca)

SUS

- 1 *Ramus deltoideus*. Accompanies V. cephalica in Sulcus pectoralis lateralis. A
- 2 *A. thoracica externa*. Arises at the medial aspect of the first rib, emerges from Apertura thoracis cranialis and supplies the pectoral muscles. A
- 3 *A. thoracica lateralis*. Accompanies N. thoracicus lateralis, coursing caudally along the medial aspect of M. pectoralis profundus. A
- 4 Rami mammarii. Supply the first (ev. second) Mamma thoracica. A
- 5 *A. subscapularis*. Courses dorsocaudally along Margo caudalis of scapula. A B
- 6 *A. thoracodorsalis*. Runs across the medial surface of M. teres major and M. latissimus dorsi. A B
- 7 *A. circumflexa humeri caudalis*. Courses along the caudal aspect of Articulatio humeri. A B
- 8 *A. suprascapularis*. Runs dorsocranially across the medial aspect of Collum scapulae and continues along Margo cranialis of scapula. A B
- 9 *A. circumflexa humeri cranialis*. Courses craniodistally through or lateral to M. coracobrachialis. A
- 10 *A. collateralis radialis*. Accompanies N. radialis upon M. brachialis. A B
- 11 *A. nutricia humeri*. Branch of *A. collateralis radialis* to For. nutricium. A B
- 12 *A. collateralis media*. Caudodistal branch of *A. collateralis radialis* towards Rete articulare cubiti. A B
- 13 *A. antebrachialis superficialis cranialis*. Continuation of *A. collateralis radialis* along M. extensor carpi radialis. A B
- 14 *A. digitalis dorsalis communis III*. Superficial continuation of *A. antebrachialis superficialis cranialis*. A B
- 15 Aa. digitales dorsales propriae. Continuations of *A. digitalis dorsalis communis III*. A
- 16 *A. circumflexa scapulae*. Courses toward Margo caudalis and mainly Facies lateralis scapulae. A B
- 17 **A. brachialis**. Continuation of *A. axillaris*, runs across the medial aspect of brachium. A B
- 18 *A. profunda brachii*. To M. triceps brachii. A B
- 19 *A. bicipitalis*. To M. biceps brachii. A
- 20 *A. collateralis ulnaris*. Accompanies N. ulnaris. Usually reinforced by branches of *A. profunda antebrachii*. A
- 21 *Rete articulare cubiti*. Network supplying the elbow joint. A
- 22 *Ramus carpeus palmaris*.
- 23 *Ramus carpeus dorsalis*. To the dorsal aspect of carpus. A
- 24 *A. transversa cubiti*. Courses laterally across the cranial aspect of humerus. A B
- 25 *A. profunda antebrachii*. Usually plural, to the caudal musculature of antebrachium. A
- 26 *A. interossea communis*. Runs laterally to the proximal part of Spatium interosseum antebrachii. A
- 27 *A. interossea cranialis*. Passes laterally through the proximal part of Spatium interosseum antebrachii and continues distally. B
- 28 *A. recurrens interossea*. Runs proximally to Rete articulare cubiti. B
- 29 *A. interossea caudalis*. Courses between radius und ulna. Enveloped in a fine arterial network. A
- 30 *Ramus interosseus*. Passes through the distal part of Spatium interosseum antebrachii and joins *A. interossea cranialis*. B
- 31 *Ramus carpeus dorsalis*. Branch of *Ramus interosseus* to Rete carpi dorsale. B
- 32 *Ramus carpeus palmaris*. Deep branch to the palmar aspect of carpus. A
- 33 *Ramus palmaris*. Continuation of *A. interossea caudalis*. Receives *A. collateralis ulnaris*, continues distally along the medial aspect of Os accessorium. A
- 34 *Ramus superficialis*. Branch of *Ramus palmaris*, courses distally along the lateropalmar border of metacarpus, joins Arcus palmaris superficialis. A
- 35 *Ramus profundus*. Inconstant deep branch of *Ramus palmaris* to Arcus palmaris profundus. A

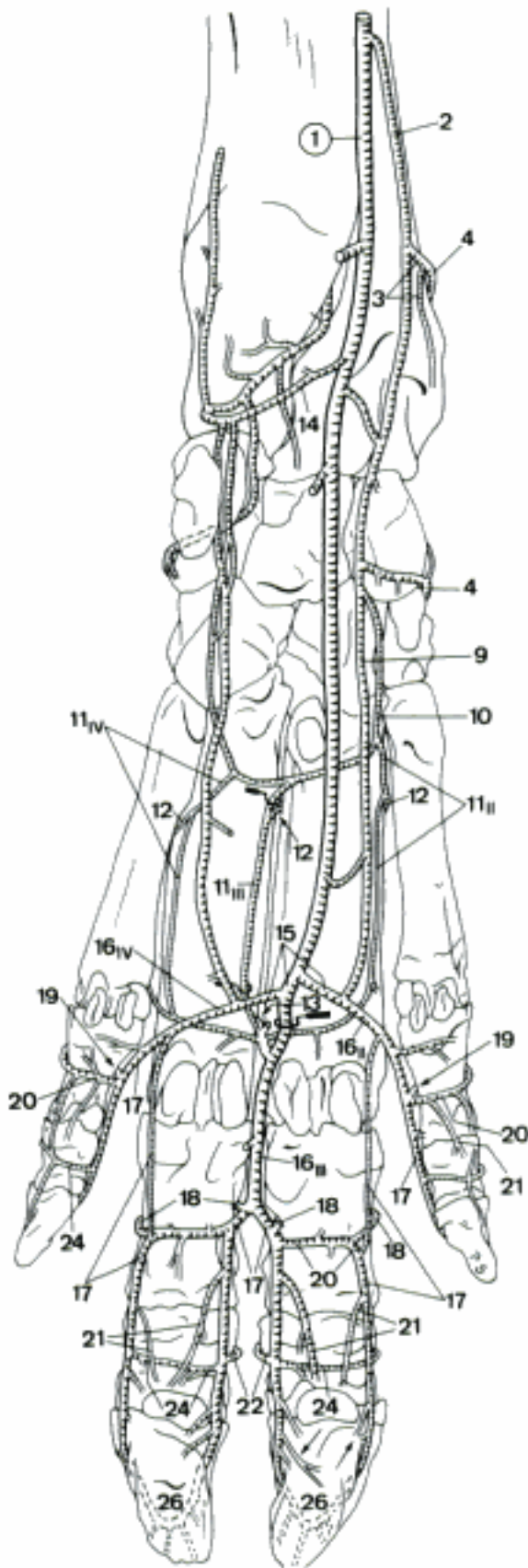


A Arteries of left thoracic limb, medial aspect (su)

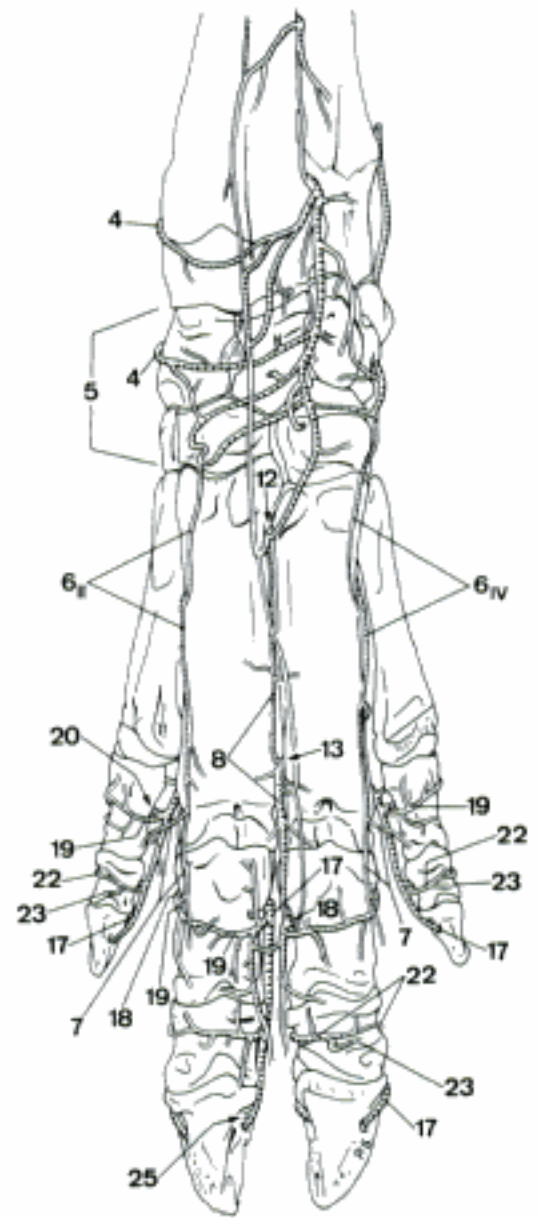


B Arteries of left thoracic limb, lateral aspect (su)

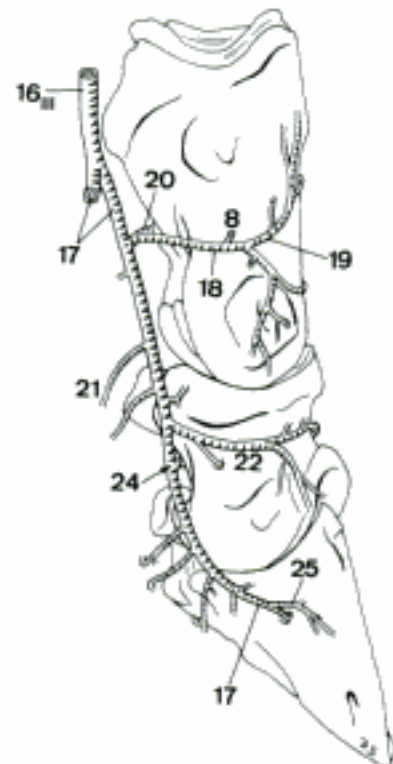
- 1 **A. mediana.** Continuation of A. brachialis distal to the origin of A. interossea communis. Runs distally, medial to the digital flexor tendons surrounded by a fine arterial network, and continues through Canalis carpi. A
- 2 **A. radialis.** Courses along the caudomedial aspect of radius, surrounded by a fine arterial network, continues superficially on the mediopalmar aspect of carpus. A
- 3 **Ramus carpeus palmaris.** Small branch to the palmar aspect of carpus. A
- 4 **Ramus carpeus dorsalis.** Courses dorsally across the medial aspect of carpus. A B
- 5 **Rete carpi dorsale.** Arterial network on the dorsal aspect of carpus. B
- 6 **Aa. metacarpeae dorsales II et IV.** Small branches of Rete carpi dorsale which are reinforced is by Rami perforantes proximales IV. B
- 7 **Aa. digitales dorsales propriae.** Slender superficial continuations of A. metacarpea dorsalis II s. IV along the adjacent sides of Digiti II and III s. IV and V. B
- 8 **A. metacarpea dorsalis III.** Arises from Rete carpi dorsale, reinforcement by Ramus perforans proximalis. B C
- 9 **Ramus palmaris superficialis.** Courses distally along the medial aspect of the flexor tendons of the third digit and joins Arcus palmaris superficialis. A
- 10 **Arcus palmaris profundus.** Transverse connection between A. radialis and Ramus profundus of Ramus palmaris of A. interossea caudalis across the dorsal aspect of Mm. interossei, often complemented by an arch on the palmar aspect. A
- 11 **Aa. metacarpeae palmares II–IV.** Join Ramus perforans distalis. A
- 12 **Ramus perforans proximalis.** Connects each of Aa. metacarpeae palmares II–IV with its dorsal counterpart through the proximal part of Spatium interosseum metacarpi. A B
- 13 **Ramus perforans distalis III.** Connects A. metacarpea palmaris III with its dorsal counterpart, by traversing the distal part of the space between Ossa metacarpalia III et IV. A B
- 14 **Ramus ulnaris.** Transverse connection between A. mediana and Ramus palmaris of A. interossea caudalis. A
- 15 **Arcus palmaris superficialis.** Variable, subfascial connection between Ramus palmaris superficialis of A. radialis, A. mediana, and Ramus superficialis of Ramus palmaris of A. interossea caudalis. A
- 16 **Aa. digitales palmares communes II–IV.** A C
- 17 **Aa. digitales palmares propriae.** Enter Foramen axiale of the corresponding Phalanx distalis. A B C
- 18 **A. interdigitalis.** Each of the four arteries which traverse Spatia interdigitalia, connecting the axial and abaxial Aa. digitales palmares propriae III et IV with their dorsal analogues. A B C
- 19 **Ramus dorsalis phalangis proximalis.** Each of the six vessels which arise usually from A. interdigitalis (Digiti III et IV) or Ramus palmaris phalangis proximalis (Digiti II et V) and ramify on the dorsal side of the corresponding Phalanx proximalis. B
- 20 **Ramus palmaris phalangis proximalis.** Transverse branch of each A. digitalis palmaris propria which courses across the palmar surface of the corresponding Phalanx proximalis. A B C
- 21 **Ramus tori digitalis.** Branch of Aa. digitales palmares propriae III et IV and Rami palmares phalangis proximalis II et V, supplying the corresponding Torus ungulae. A C
- 22 **Ramus dorsalis phalangis mediae.** Transverse branch of each A. digitalis palmaris propria across the dorsal aspect of the corresponding Phalanx media. A B C
- 23 **A. coronalis.** Superficial branch of each axial Ramus dorsalis phalangis mediae (II–V), which courses abaxially towards the corresponding Corona ungulae. B
- 24 **Ramus palmaris phalangis mediae.** Transverse branch of each A. digitalis palmaris propria which runs across the palmar aspect of the corresponding Phalanx media. A C
- 25 **Ramus dorsalis phalangis distalis.** Slender branch of each axial A. digitalis palmaris propria which courses dorsally along Facies axialis of the corresponding Phalanx distalis. B C
- 26 **Arcus terminalis.** Arterial arch inside Phalanx distalis. A



A Arteries of left manus, palmar aspect (su)



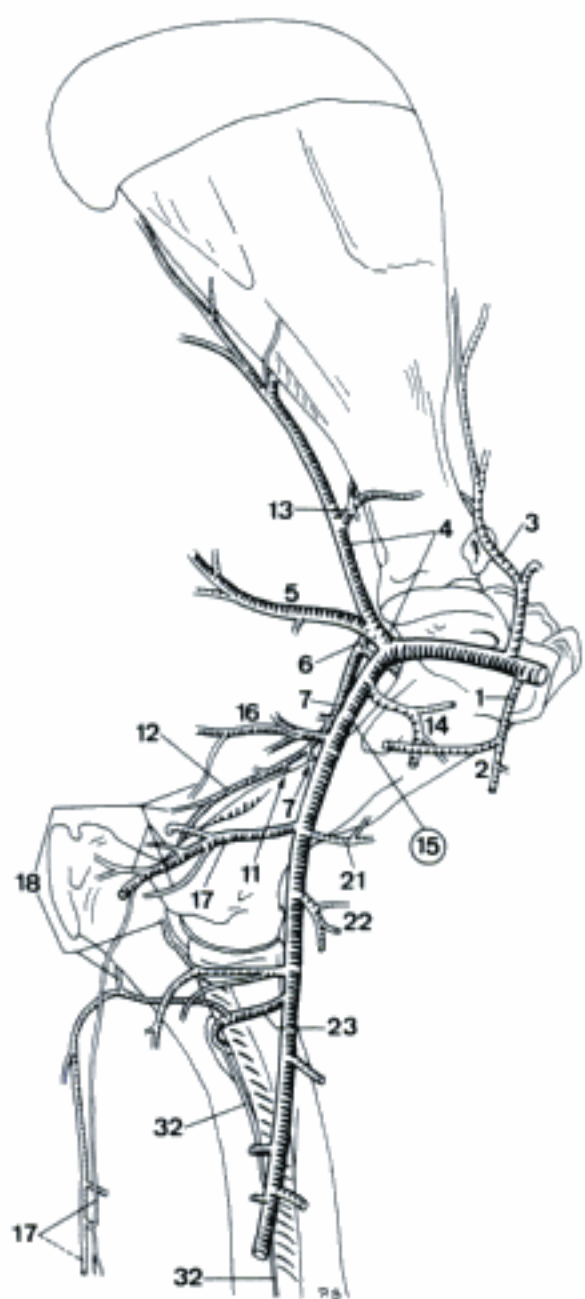
B Arteries of left manus, dorsal aspect (su)



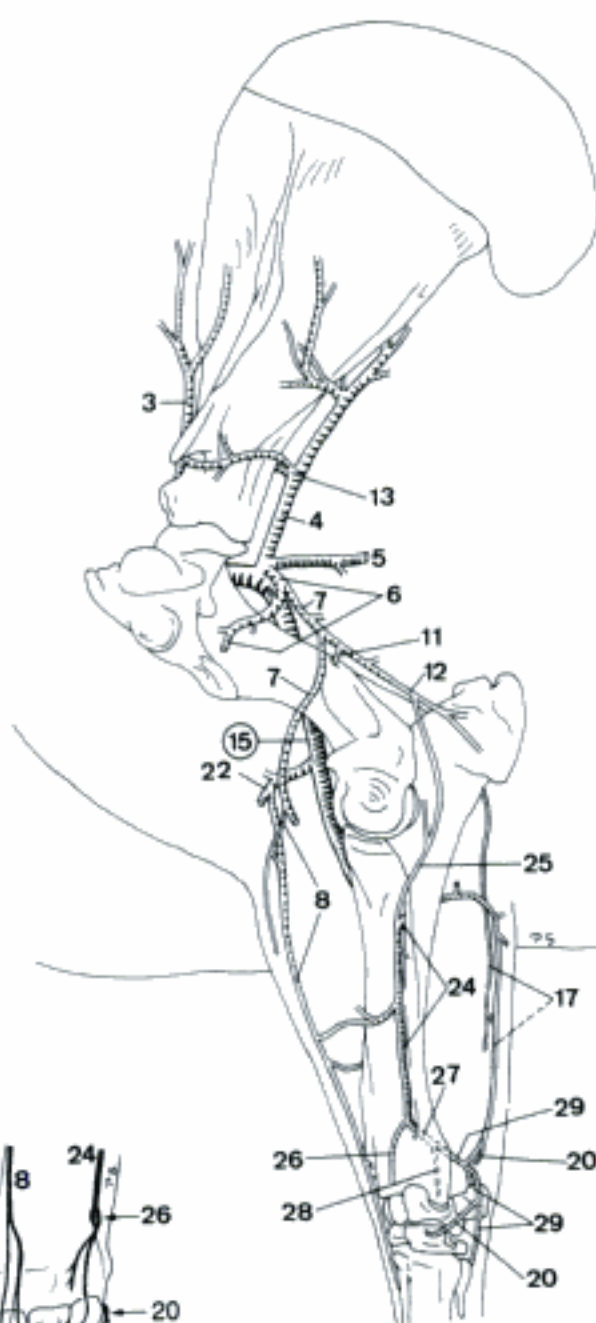
C Arteries of fourth digit, left manus, axial aspect (su)

RUMINANTIA

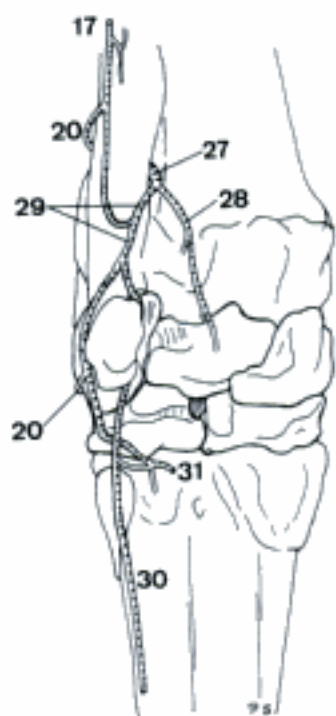
- 1 *A. thoracica externa*. Supplies mainly Mm. pectorales. A
- 2 *Ramus deltoideus (bo)*. Accompanies V. cephalica in Sulcus pectoralis lateralis. A
- 3 *A. suprascapularis (bo)*. Principal vessel accompanying N. suprascapularis. A B
- 4 *A. subscapularis*. Passes dorsocaudally along Margo caudalis of scapula. A B
- 5 *A. thoracodorsalis*. Caudodorsally directed muscular vessel. A B
- 6 *A. circumflexa humeri caudalis*. Runs laterally passing the flexor angle of Articulatio humeri. A B
- 7 *A. collateralis radialis*. Runs distocaudally, accompanying N. radialis. A B
- 8 *A. antebrachialis superficialis cranialis*. Small branch of *A. collateralis radialis*, accompanies *Ramus superficialis* of N. radialis. Reinforced by *A. transversa cubiti* and *A. interossea cranialis*. B D
- 9 Aa. *digitales dorsales communes II et III*. Very small branches given off by *A. antebrachialis superficialis cranialis*. D
- 10 Aa. *digitales dorsales propriae*. The medial one forms the continuation of *A. digitalis dorsalis communis II*, both axial originate from the bifurcation of *A. digitalis dorsalis communis III*. D
- 11 *A. nutricia humeri*. Branch of *A. collateralis radialis*. A B
- 12 *A. collateralis media*. Arises from *A. collateralis radialis* and proceeds caudally towards Articulatio cubiti. A B
- 13 *A. circumflexa scapulae*. Courses dorsocranially to the caudal border of scapula and continues across its lateral and medial aspects. A B
- 14 *A. circumflexa humeri cranialis*. Courses cranially across the medial aspect of humerus. A
- 15 **A. brachialis**. Continuation of *A. axillaris*. Courses across the medial aspect of brachium. A B
- 16 *A. profunda brachii*. Caudally directed trunk which soon divides in muscular branches. A
- 17 *A. collateralis ulnaris*. Courses caudally, and usually gives off a distal continuation between Mm. extensor and flexor carpi ulnaris. A B C
- 18 *Rete articulare cubiti*. Arterial network which supplies the elbow joint. A
- 19 *Ramus carpeus palmaris*.
- 20 *Ramus carpeus dorsalis*. Courses to Regio carpi dorsalis. B C D
- 21 *A. bicipitalis*. Short muscular branch, mainly for M. biceps brachii. A
- 22 *A. transversa cubiti*. Cranially directed trunk which ramifies into muscular branches on the flexor aspect of Articulatio cubiti. A B
- 23 *A. interossea communis*. Passes caudolaterally along the caudomedial aspect of radius, may enter Spatium interosseum antebrachii proximale (bo, cap). A
- 24 *A. interossea cranialis*. Continuation of *A. interossea communis*. Traverses Spatium interosseum antebrachii proximale, courses distally in the craniolateral groove between radius and ulna. B D
- 25 *A. recurrens interossea*. Courses proximally to the lateral aspect of olecranon. B
- 26 *Ramus carpeus dorsalis*. Courses distodorsally and ramifies on the dorsolateral aspect of carpus. B D
- 27 *Ramus interosseus*. Caudal continuation of *A. interossea cranialis* through Spatium interosseum antebrachii distale. B C
- 28 *Ramus carpeus palmaris*. Deep branch of *Ramus interosseus* to the palmar aspect of carpus. B C
- 29 *Ramus palmaris*. Continuation of *Ramus interosseus*. Receives *A. collateralis ulnaris*, and, usually split, continues along the lateropalmar aspect of carpus. B C
- 30 *Ramus superficialis*. Branch of *Ramus palmaris* which courses along the lateral aspect of the flexor tendons of the digits and usually joins *Arcus palmaris superficialis*. C
- 31 *Ramus profundus*. Deep branch of *Ramus palmaris* which pierces between metacarpus and M. interosseus into *Arcus palmaris profundus*. C
- 32 *A. interossea caudalis*. Along the medial groove between radius and ulna. A



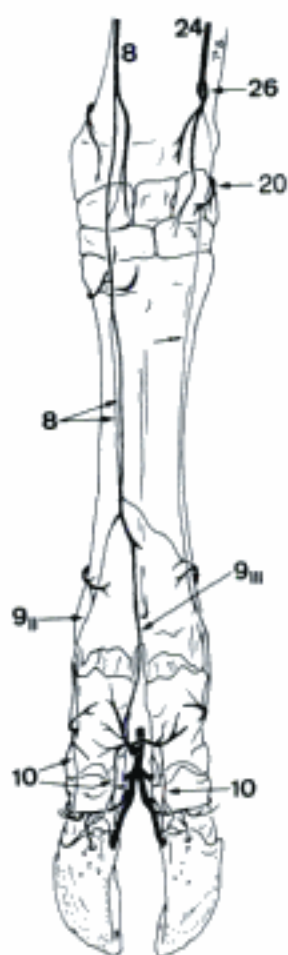
A Arteries of left thoracic limb, medial aspect (bo)



B Arteries of left thoracic limb, lateral aspect (bo)

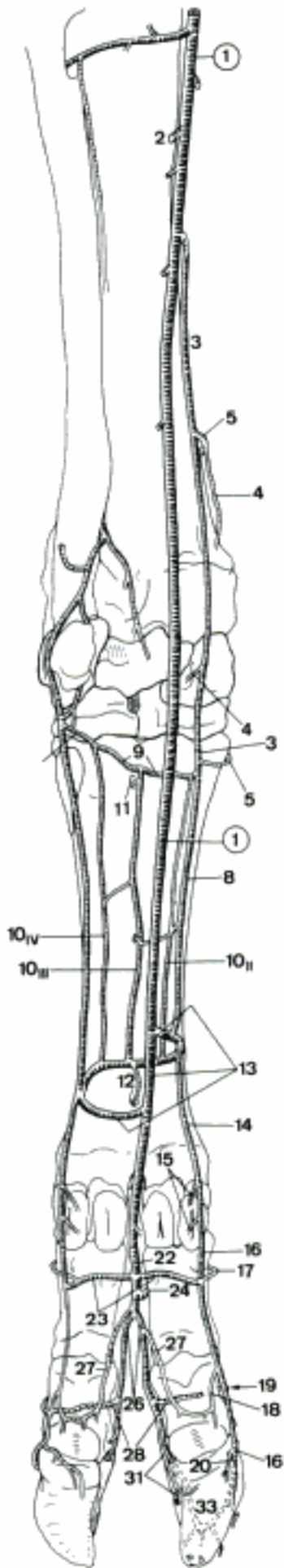


C Arteries of left carpus, palmar aspect (bo)

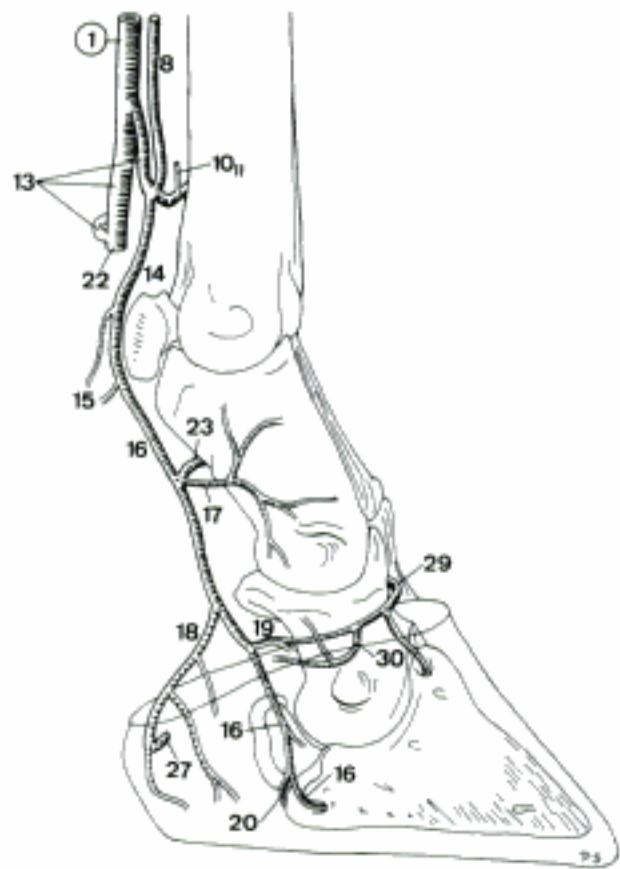


D Arteries of left manus, dorsal aspect (bo)

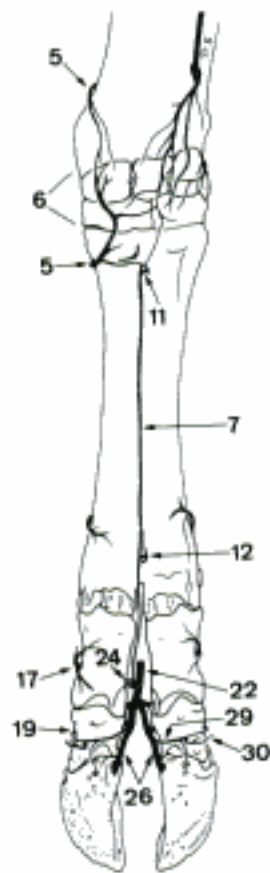
- 1 **A. mediana.** Continuation of A. brachialis distal to the origin of A. interossea communis. Passes through Sulcus carpi. A C D
- 2 *A. profunda antebrachii.* To the muscles on the caudal side of the forearm. A
- 3 *A. radialis.* Continues superficially on the mediopalmar aspect of carpus. A
- 4 *Ramus carpeus palmaris.* A
- 5 *Ramus carpeus dorsalis.* Usually double branch to the dorsal aspect of carpus. A B
- 6 **Rete carpi dorsale.** Network on the dorsal aspect of Carpus. B
- 7 *A. metacarpea dorsalis III.* Proceeds from Rete carpi dorsale in Sulcus longitudinalis dorsalis of Os metacarpale III et IV, joins A. interdigitalis. B D
- 8 *Ramus palmaris superficialis.* Courses underneath Fascia palmaris, joins Arcus palmaris superficialis, or continues in A. digitalis palmaris communis II. A C D
- 9 *Arcus palmaris profundus.* Connection between A. radialis and Ramus interosseus between Os metacarpale III et IV and M. interosseus. A
- 10 **Aa. metacarpeae palmares II–IV.** Interanastomosing arteries between Os metacarpale III et IV and M. interosseus. A C D
- 11 *Ramus perforans proximalis III.* Connects A. metacarpea palmaris III or Arcus palmaris profundus through Canalis metacarpi proximalis with A. metacarpea dorsalis III. A B
- 12 *Ramus perforans distalis III.* Connects A. metacarpea palmaris III with A. metacarpea dorsalis III through Canalis metacarpi distalis. A B D
- 13 *Arcus palmaris superficialis.* Subfascial arch connecting Ramus interosseus, via A. mediana, with Ramus palmaris superficialis of A. radialis. A C D
- 14 *A. digitalis palmaris communis II.* A C D
- 15 *A. digitalis palmaris propria II axialis.* Courses subfascially to the medial dew claw. A C
- 16 *A. digitalis palmaris propria III abaxialis.* A C
- 17 *Ramus dorsalis phalangis proximalis.* Branch of A. digitalis palmaris propria III abaxialis to the dorsal aspect of Phalanx proximalis. A B C
- 18 *Ramus tori digitalis.* Branch of A. digitalis palmaris propria III abaxialis to Torus unguulae. A C
- 19 *Ramus dorsalis phalangis mediae.* Branch of A. digitalis palmaris propria III abaxialis to the dorsal aspect of Phalanx media. A B C
- 20 *Ramus palmaris phalangis distalis.* A C
- 21 *Ramus dorsalis phalangis distalis.*
- 22 *A. digitalis palmaris communis III.* Continuation of A. mediana beyond Arcus palmaris superficialis. A B C D
- 23 **Rami palmares phalangium proximalium.** Course across the palmar surface of Phalanx proximalis, join A. digitalis palmaris propria abaxialis. A D
- 24 *A. interdigitalis.* Communication with A. metacarpea dorsalis III through Spatium interdigitale. A B D
- 25 **Rami dorsales phalangium proximalium.** Branches of A. interdigitalis to the dorsal aspect of Phalanx proximalis. D
- 26 **Aa. digitales palmares propriae III et IV axiales.** Course to the corresponding Foramen axiale, through which they enter Phalanx distalis. A B D
- 27 *Ramus tori digitalis.* Branch of A. digitalis palmaris propria axialis to Torus unguulae. A C D
- 28 *Ramus palmaris phalangis mediae.* Branch of A. digitalis palmaris propria III s. IV axialis which courses transversely across the palmar aspect of Phalanx media III s. IV. A D
- 29 *Ramus dorsalis phalangis mediae.* Branch of A. digitalis palmaris propria axialis to the dorsal aspect of Phalanx media. B C D
- 30 *A. coronalis.* Arises from the axial Ramus dorsalis phalangis mediae (bo) or A. digitalis palmaris propria axialis, courses into the abaxial part of Corona unguulae. B C D
- 31 *Ramus palmaris phalangis distalis.* Continuation of A. digitalis palmaris propria III s. IV axialis. A D
- 32 *Ramus dorsalis phalangis distalis.* Branch of Ramus palmaris phalangis distalis, courses dorsally along Facies axialis of Phalanx distalis. D
- 33 **Arcus terminalis.** Arterial arch inside Phalanx distalis. A D



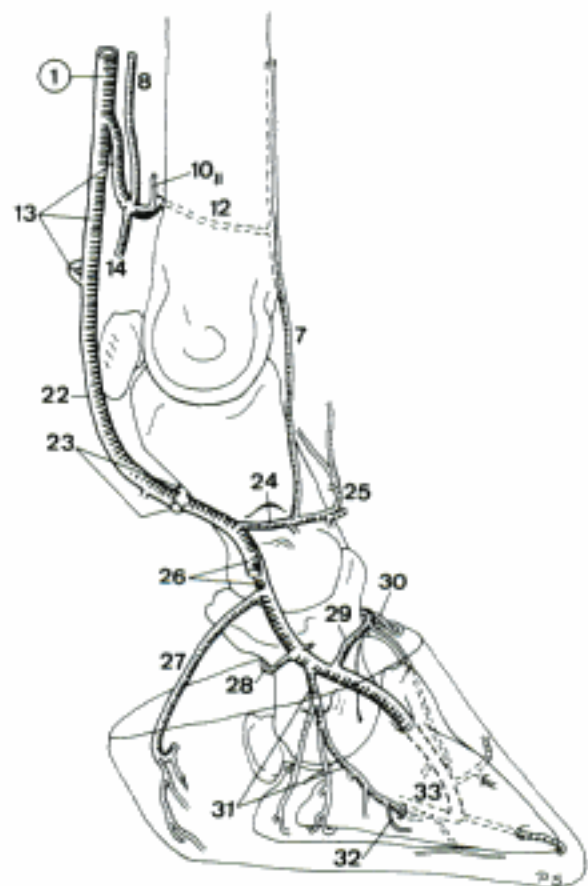
A Arteries of left thoracic limb, palmar aspect (bo)



C Arteries of left manus, medial aspect (bo)



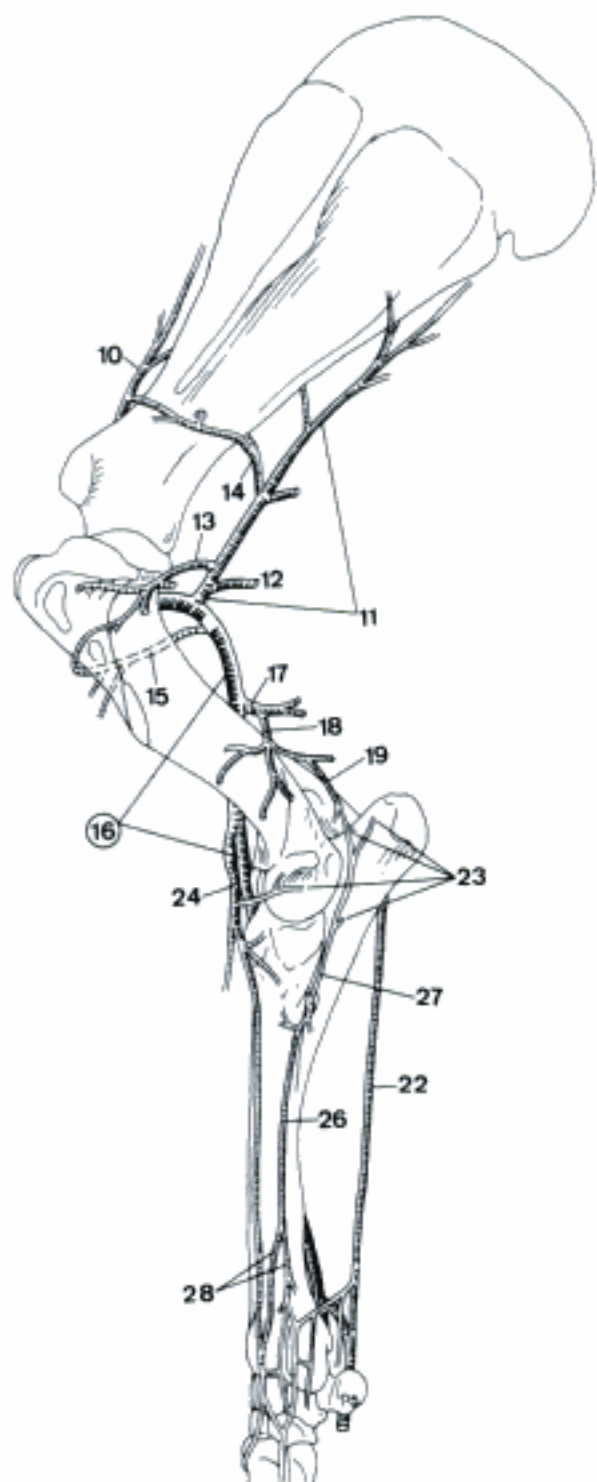
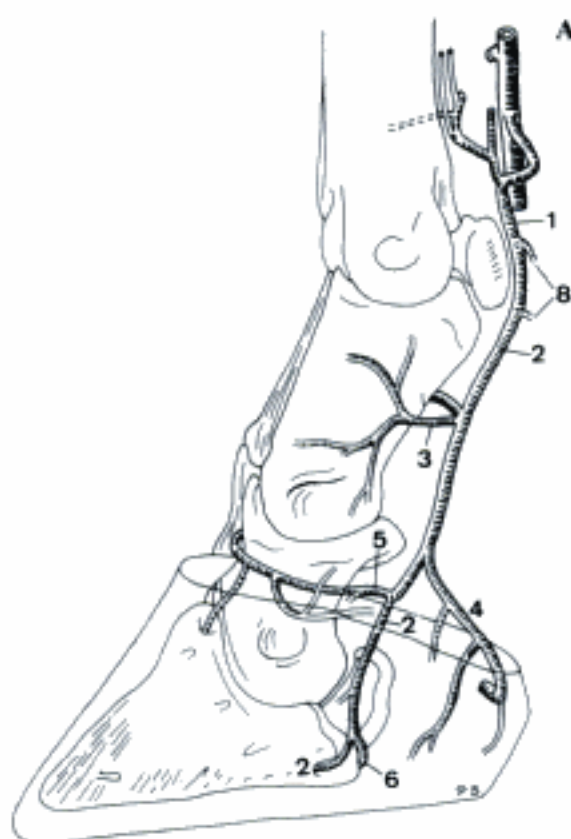
B Arteries of left manus, dorsal aspect (bo)



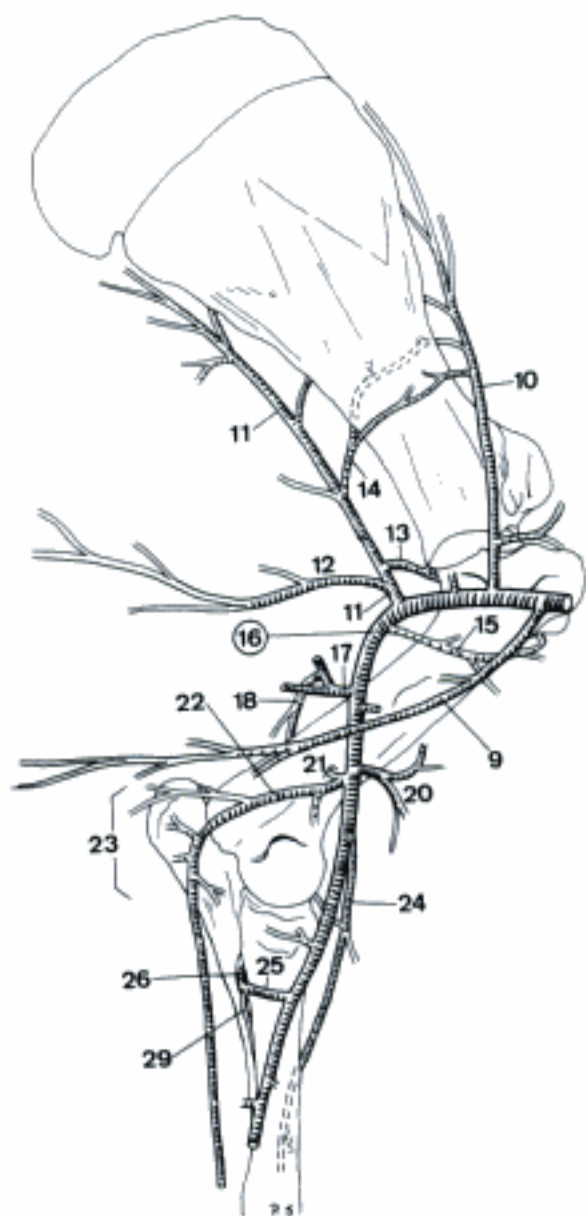
D Arteries of left manus (third digit removed), medial aspect (bo)

- 1 *A. digitalis palmaris communis IV*. A
 - 2 *A. digitalis palmaris propria IV abaxialis*. Runs along the lateropalmar side of the flexor tendons of the fourth digit. A
 - 3 *Ramus dorsalis phalangis proximalis*. Branch of *A. digitalis palmaris propria IV abaxialis*, to the dorsal aspect of *Phalanx proximalis IV*. A
 - 4 *Ramus tori digitalis*. Branch of *A. digitalis palmaris propria IV abaxialis*, enters *Torus unguulae IV* laterally. A
 - 5 *Ramus dorsalis phalangis mediae*. Branch of *A. digitalis palmaris propria IV abaxialis*, to the dorsal aspect of *Phalanx media IV*. A
 - 6 *Ramus palmaris phalangis distalis*. Branch of *A. digitalis palmaris propria IV abaxialis*, courses axially across the palmar aspect of *Phalanx distalis IV*. A
 - 7 *Ramus dorsalis phalangis distalis*.
 - 8 *A. digitalis palmaris propria V axialis*. Courses subfascially to the lateral dew claw. A
- EQUUS
- 9 *A. thoracica externa*. Courses caudoventrally to *Mm. pectorales*. Variable and inconstant. B
 - 10 *A. suprascapularis*. Runs dorsally to the furrow between *M. subscapularis* and *M. supraspinatus*, accompanying *N. suprascapularis*. Often double. B C
 - 11 *A. subscapularis*. Courses caudodorsally between *M. subscapularis* and *M. teres major* towards *Angulus caudalis* of scapula. B C
 - 12 *A. thoracodorsalis*. Crosses the medial face of *M. teres major* and continues caudodorsally on *M. latissimus dorsi*. B C
 - 13 *A. circumflexa humeri caudalis*. Passes laterally with *N. axillaris*, caudal to *Articulatio humeri*. B C
 - 14 *A. circumflexa scapulae*. Runs between *M. subscapularis* and *Caput longum* of *M. triceps brachii* and gives off cranial branches at each side of scapula. B C
 - 15 *A. circumflexa humeri cranialis*. Courses distocranially across the medial aspect of humerus. B C
 - 16 **A. brachialis**. Continuation of *A. axillaris* distal to the place where *A. circumflexa humeri cranialis* arises. Courses across the medial surface of humerus to the craniomedial aspect of *Articulatio cubiti*. B C
 - 17 *A. profunda brachii*. Caudally directed trunk which primarily supplies the musculature of the caudal side of brachium. B C
 - 18 *A. collateralis radialis*. Courses to the cranial aspect of *Articulatio cubiti*, accompanying *N. radialis* in *Sulcus m. brachialis*. B C
 - 19 *A. collateralis media*. Runs towards *Fossa olecrani* and contributes to *Rete articulare cubiti*. C
 - 20 *A. bicipitalis*. Cranially and slightly distally directed muscular trunk, mainly for *M. biceps brachii*. B
 - 21 *A. nutricia humeri*. Enters *Foramen nutricium* of humerus. B
 - 22 *A. collateralis ulnaris*. Passes caudodistally across the medial surface of humerus and continues distally between *Mm. extensor* and *flexor carpi ulnaris*. Joins *Ramus palmaris* of *A. mediana* just proximal to carpus. B C
 - 23 *Rete articulare cubiti*. Network around *Articulatio cubiti*. B C
 - 24 *A. transversa cubiti*. Passes distolaterally over the cranial aspect of *Articulatio cubiti* and continues on the cranial surface of radius towards carpus. B C
 - 25 *A. interossea communis*. Courses caudolaterally towards *Spatium interosseum antebrachii*. B
 - 26 *A. interossea cranialis*. Traverses *Spatium interosseum antebrachii* and courses distally on the lateral border of radius. B C
 - 27 *A. recurrens interossea*. Courses proximally along the lateral aspect of ulna. C
 - 28 *Rami carpei dorsales*. Concur to form the *Rete carpi dorsale*. C
 - 29 *A. interossea caudalis*. Very slender and inconstant, runs along the caudal surface of radius. B

A Arteries of left manus, lateral aspect (bo)

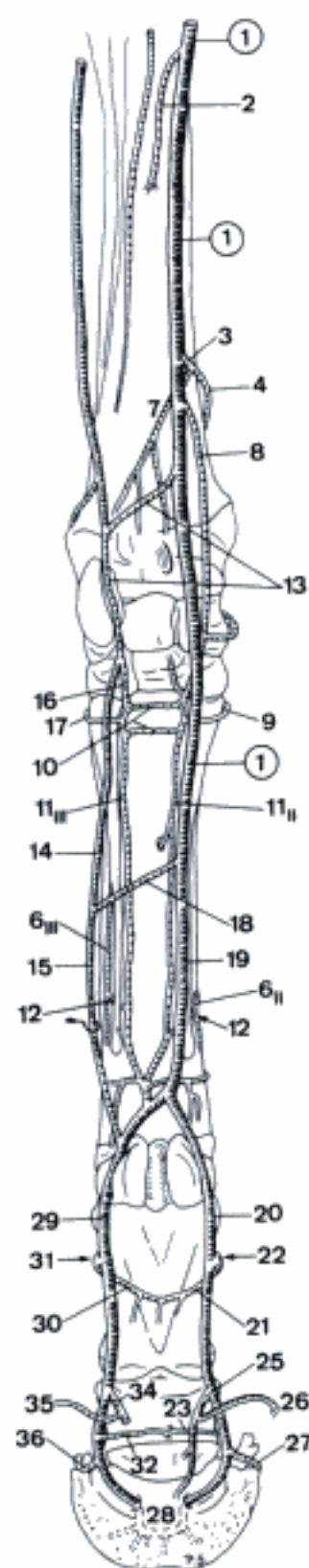


C Arteries of left thoracic limb, lateral aspect (eq)

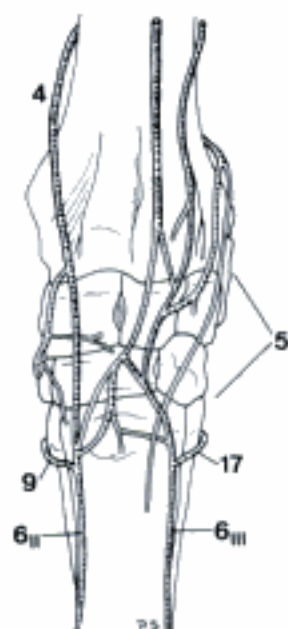


B Arteries of left thoracic limb, medial aspect (eq)

- 1 **A. mediana.** Continuation of A. brachialis distal to the origin of A. interossea communis. Passes through Canalis carpi and continues along the medial aspect of the digital flexor tendons. A
- 2 *A. profunda antebrachii.* Supplies the caudal muscles on antebrachium. A
- 3 *A. radialis proximalis.* Courses on the caudal surface of radius. A
- 4 *Ramus carpeus dorsalis.* Branch to Rete carpi dorsale. A B
- 5 Rete carpi dorsale. Network on the dorsal surface of carpus. B
- 6 Aa. metacarpeae dorsales II et III. Run in the dorsal grooves between Ossa metacarpalia II–III s. III–IV. B C D
- 7 *Ramus carpeus palmaris.* Supplies the palmar aspect of carpus. A
- 8 *A. radialis.* Courses on the palmar surface of carpus. A
- 9 *Ramus anastomoticus cum a. metacarpea dorsali II.* Courses around the Basis of Os metacarpale II. A B
- 10 *Arcus palmaris profundus.* Connection between A. radialis and Ramus palmaris of A. mediana. Usually represented on both surfaces of M. interosseus. A
- 11 Aa. metacarpeae palmares II et III. Run along the palmar groove between Ossa metacarpalia II–III s. III–IV. A C D
- 12 *Ramus perforans distalis.* Branch of A. metacarpea palmaris, penetrates between Ossa metacarpalia, joins A. metacarpea dorsalis. A C D
- 13 *Ramus palmaris.* Courses laterodistally, joins A. collateralis ulnaris and continues distally. A
- 14 *Ramus superficialis.* Concurs to Arcus palmaris superficialis. A
- 15 *A. digitalis palmaris communis III.* Continuation of Ramus superficialis distal to the point where it joins Arcus palmaris superficialis. A D
- 16 *Ramus profundus.* Concurs to Arcus palmaris profundus. A
- 17 *Ramus anastomoticus cum a. metacarpea dorsali III.* Courses around the lateral surface of Basis of Os metacarpale IV, joins A. metacarpea dorsalis III. A B
- 18 (*Arcus palmaris superficialis*). Subfascial connection of A. mediana and Ramus superficialis of Ramus palmaris. A
- 19 *A. digitalis palmaris communis II.* Continuation of A. mediana distal to the point where Arcus palmaris superficialis normally arises. A C D
- 20 *A. digitalis [palmaris propria III] medialis.* Passes medial to the medial Os sesamoideum proximale, reaches Sulcus solearis, enters Foramen soleare. A C D
- 21 *Ramus palmaris phalangis proximalis.* Courses laterally across the palmar aspect of Phalanx proximalis. A C
- 22 *Ramus dorsalis phalangis proximalis.* Dorsally directed branch, given off by Ramus palmaris phalangis proximalis. A C
- 23 *Ramus palmaris phalangis mediae.* Courses laterally across the palmar aspect of Phalanx media. A
- 24 *Ramus dorsalis phalangis mediae.* Passes on the lateral aspect of Cartilago unguaris medialis to the dorsal surface of Phalanx media. C
- 25 *Ramus tori digitalis.* Runs in a distopalmar direction and ramifies chiefly in Torus unguiae. A C
- 26 *A. coronalis.* Arises from Ramus tori digitalis, courses dorsally along the proximal border of Cartilago unguaris medialis and Capsula vugulae. A C
- 27 *Ramus dorsalis phalangis distalis.* Passes through Foramen or Incisura processus palmaris and continues dorsally in Sulcus parietalis medialis. A C
- 28 *Arcus terminalis.* Arch inside Canalis solearis, formed by the union of Aa. digitales medialis and lateralis. A
- 29 *A. digitalis [palmaris propria III] lateralis.* Courses laterally between M. interosseus and M. flexor digitorum profundus, takes up Aa. metacarpeae palmares and A. digitalis palmaris communis III. Continues lateral to the lateral Os sesamoideum proximale. Reaches Sulcus solearis, enters Foramen soleare. A C D
- 30 *Ramus palmaris phalangis proximalis.* See 21. A D
- 31 *Ramus dorsalis phalangis proximalis.* See 22. A D
- 32 *Ramus palmaris phalangis mediae.* See 23. A
- 33 *Ramus dorsalis phalangis mediae.* Counterpart of 24. D
- 34 *Ramus tori digitalis.* See 25. A D
- 35 *A. coronalis.* See 26. A D
- 36 *Ramus dorsalis phalangis distalis.* Counterpart of 27. A D

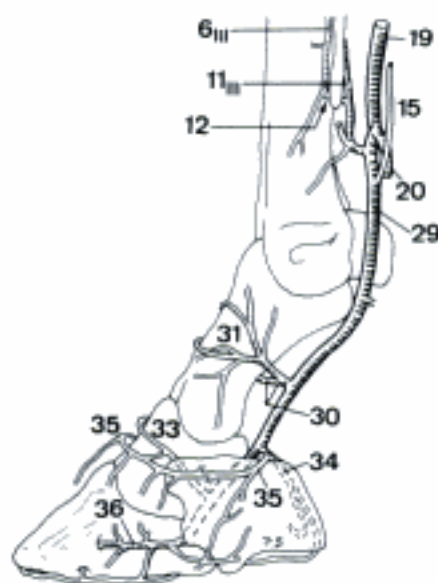
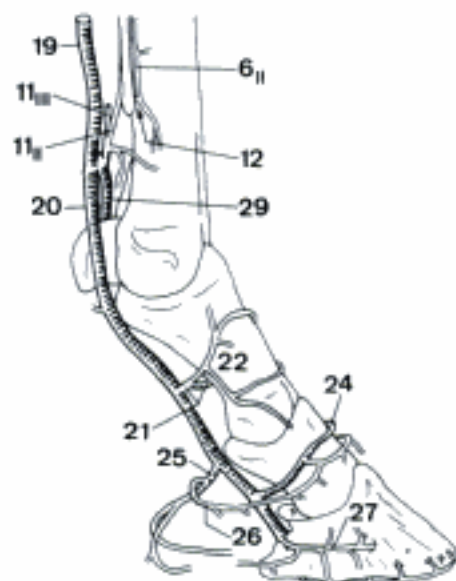


A Arteries of left thoracic limb, palmar aspect (eq)



B Arteries of left carpus, dorsal aspect (eq)

C Arteries of left manus, medial aspect (eq)



D Arteries of left manus, lateral aspect (eq)

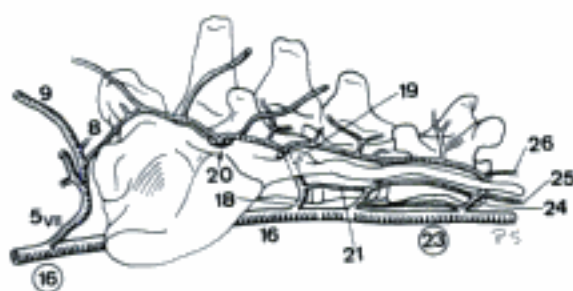
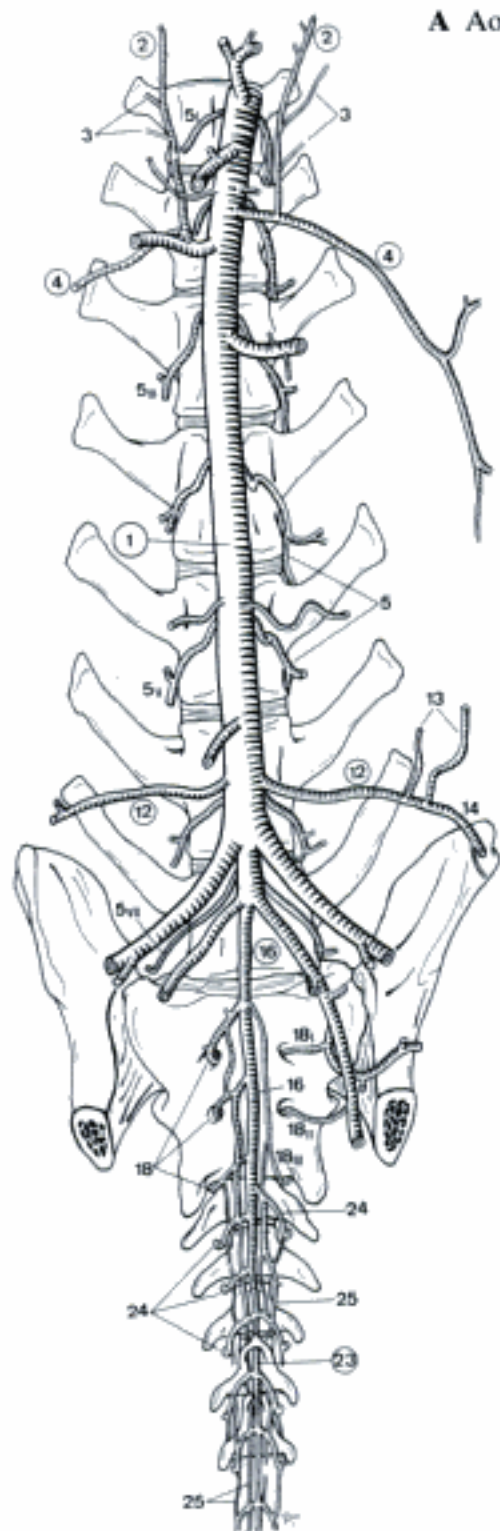
TERMINI COMMUNES

- 1 **AORTA DESCENDENS.** Caudal continuation of Arcus aortae. A C
- 2 **AORTA THORACIA.** Intrathoracic segment of Aorta descendens. Extends to Hiatus aorticus of the Diaphragma. A B C
- 3 *A. broncho-esophagea [-oesophagea].* Variable trunk for the supply of lungs and esophagus. A
- 4 *Ramus bronchalis.* Variably developed vessel which divides at Bifurcatio tracheae in left and right branches which enter the hilus of the corresponding lung along the bronchi. A
- 5 *Ramus esophageus [oesophageus].* Passes caudally along esophagus. A
- 6 *Rami esophagei [oesophagei].* Small branches to esophagus, in su and ov.
- 7 *Rami pericardiaci.* Variably arising branches to pericardium in ca. A
- 8 *Rami mediastinales.* Small branches to Mediastinum dorsale in ca. A
- 9 *A. phrenica cranialis (eq).* Intrathoracic branch to Pars lumbalis of the Diaphragma. Also described in su, ov, bo. C
- 10 *Aa. intercostales dorsales.* Pass across the Corpus vertebrae to the Spatium intercostale and continue along Sulcus costae. Often fuse the initial segments of adjacent fellow vessels. A B C
- 11 *Ramus dorsalis.* Courses dorsally to Mm. dorsi. Passes through Foramen vertebrale laterale in su. B C
- 12 *Ramus spinalis.* Enters Canalis vertebralis via Foramen intervertebrale, Foramen vertebrale laterale or both openings (su). Contributes to A. spinalis ventralis. B C
- 13 *Ramus cutaneus medialis.* Superficial continuation of Ramus dorsalis. Absent in su. B
- 14 *Ramus cutaneus lateralis.*
- 15 *Ramus collateralis (Car, su).* Courses across the medial aspect of the corresponding rib to the preceding Spatium intercostale. An analogous branch, but towards the cranial border of the following rib, is described in eq. B
- 16 *Rami cutanei laterales.* Perforating branches to the skin of the lateral thoracic wall. B
- 17 *Rami mammarii.* To the Mammae thoracicae (Car, su). B
- 18 *Rami phrenici.* Arise from the caudal Aa. intercostales dorsales and supply Pars costalis of Diaphragma.
- 19 *A. costoabdominalis dorsalis.* Courses along the caudal aspect of the last rib. Given off by Aorta abdominalis in eq. C
- 20 *Ramus dorsalis.* Runs dorsally to Mm. dorsi. Passes through Foramen vertebrale laterale of the last Vertebra thoracica in su. C
- 21 *Ramus spinalis.* Enters Canalis vertebralis via the thoracolumbar Foramen intervertebrale and (su)/or Foramen vertebrale laterale and joins A. spinalis ventralis. C
- 22 *Ramus cutaneus medialis.* Superficial continuation of Ramus dorsalis. C
- 23 *Ramus cutaneus lateralis.*
- 24 *Rami cutanei laterales.* Pass laterally to the adjacent skin segments. C

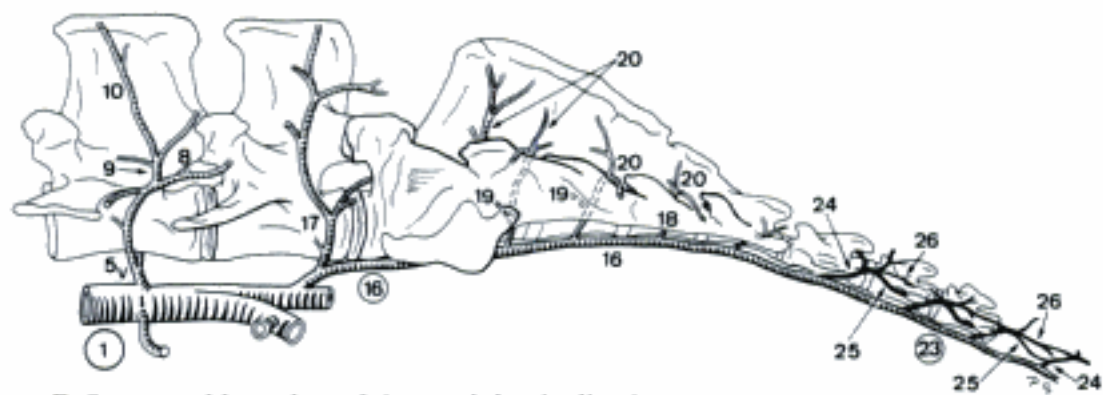
Hidden page

- 1 **AORTA ABDOMINALIS.** Intra-abdominal segment of Aorta descendens. A B
- 2 **A. phrenica caudalis.** Courses cranially into Pars lumbalis of Diaphragma. Usually absent in eq, ov, cap, may be unpaired (fe, su, Ru) or plural (Cap, ov, cap). Arises variably. A
- 3 *Rami adrenales [supra-] craniales.* Run caudally to Gl. suprarenalis. Arise variably. A
- 4 **A. abdominalis cranialis (Cap, su).** Passes to the lateral abdominal wall. A
- 5 **Aa. lumbales.** Often initially fused segmental vessels, pass across Corpus of the corresponding Vertebra lumbalis to the caudal border of its Processus costarius. The first 2 or 3 arise from Aorta thoracica in Car, the last arises variably. A B C
- 6 *Rami phrenici (su, Ru).* Arise from the cranial Aa. lumbales and course cranially to Pars lumbalis of Diaphragma. May be absent (esp. su).
- 7 *Rami adrenales [supra-] (Ru).* Arise from the cranial Aa. lumbales and supply Gl. suprarenalis. Also described in ca.
- 8 *Ramus spinalis.* Enters Canalis vertebralis through the corresponding Foramen intervertebrale or Foramen vertebrale laterale and joins A. spinalis ventralis. B C
- 9 *Ramus dorsalis.* Courses dorsally to the epaxial muscles. Passes through Foramen vertebrale laterale of the corresponding Vertebra lumbalis in su. B C
- 10 *Ramus cutaneus medialis.* Runs to the medial region of the skin of the dorsum. B
- 11 *Ramus cutaneus lateralis.* Superficial continuation of Ramus dorsalis into the skin of the Dorsum.
- 12 **A. circumflexa ilium profunda (Car).** Arises exceptionally from A. iliaca externa. A
- 13 *Rami craniales.* Course cranioventrally in the flank. A
- 14 *Rami caudales.* Ventrally or ventrocaudally directed branches to the flank and the thigh. A
- 15 **(A. sacralis mediana) (eg).** Continuation of the aorta along Facies pelvina of Os sacrum. Slender or absent.
- 16 **A. sacralis mediana.** Continuation of aorta along Facies pelvina of Os sacrum in Car, su, Ru. May be paired (ca, ov). A B C
- 17 *A. lumbalis VI (VII) (su, ov, cap).* Often initially fused, passes across the corpus of the corresponding Vertebra lumbalis to the caudal border of its Processus costarius. B
- 18 *Rami sacrales.* Often initially fused segmental arteries, course dorsally into the corresponding Foramen sacrale pelvinum. The last pair pierces between Os sacrum and Vertebra caudalis I. B C
- 19 *Ramus spinalis.* Joins A. spinalis ventralis. B C
- 20 *Ramus dorsalis.* Emerges through Foramen sacrale dorsale or between the last sacral and first caudal vertebrae resp., and supplies the epaxial musculature. B C
- 21 *A. sacralis lateralis (fe).* Anastomosis between Rami sacrales along the ventral aspect of Os sacrum. C
- 22 *(A. sacralis lateralis) (ca).* Anastomosis between Rami sacrales along the ventral aspect of Os sacrum.
- 23 **A. caudalis [coccygea] mediana.** Continuation of A. sacralis mediana (exc. eq) along the ventral surface of Vertebrae caudales. Locally enclosed by Processusemales or Arcusemales. In eq it usually arises from the left or right A. glutea caudalis. B C
- 24 *Rami caudales [coccygei].* Sometimes initially fused (ca, su) segmental branches, course dorsally across the corpus of the corresponding Vertebra caudalis. A B C
- 25 *A. caudalis [coccygea] ventrolateralis.* Chain of anastomoses between the Rami caudales, located along the ventrolateral aspect of Vertebrae caudales. A B C
- 26 *A. caudalis [coccygea] dorsolateralis.* Chain of anastomoses between the Rami caudales, located along the dorsolateral aspect of Vertebrae caudales. B C
- 27 *Corpora caudalia [coccygea].* Small nodules of arteriovenous anastomoses, located in the tail.

A Aorta abdominalis, ventral aspect (ca)



C Branches of *A. sacralis mediana* and *A. caudalis mediana* (fe)

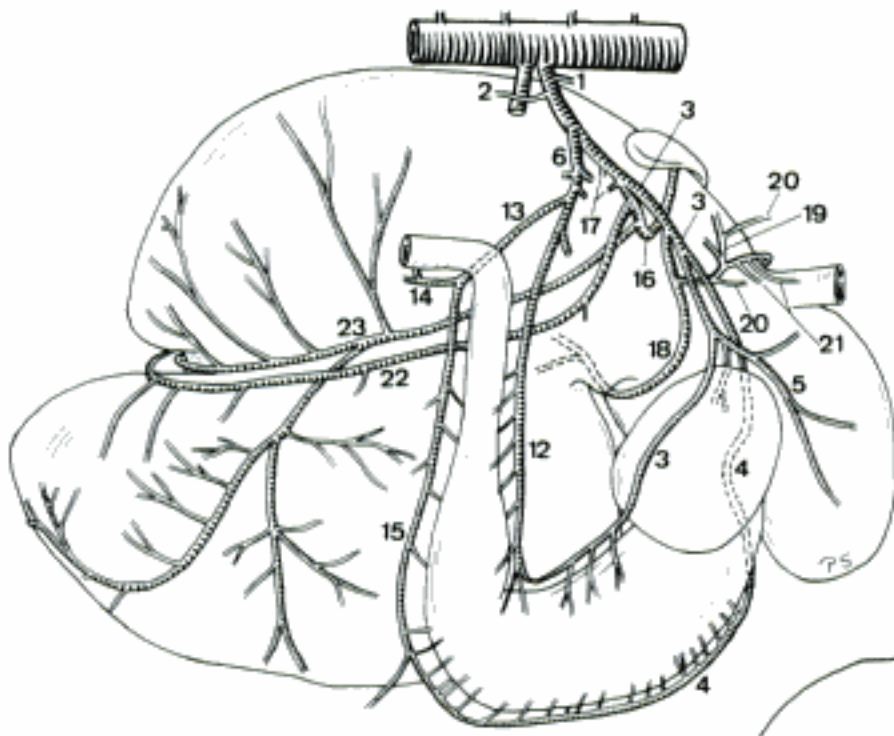


B Segmental branches of *Aorta abdominalis*, *A. sacralis mediana*, and *A. caudalis mediana* (cap)

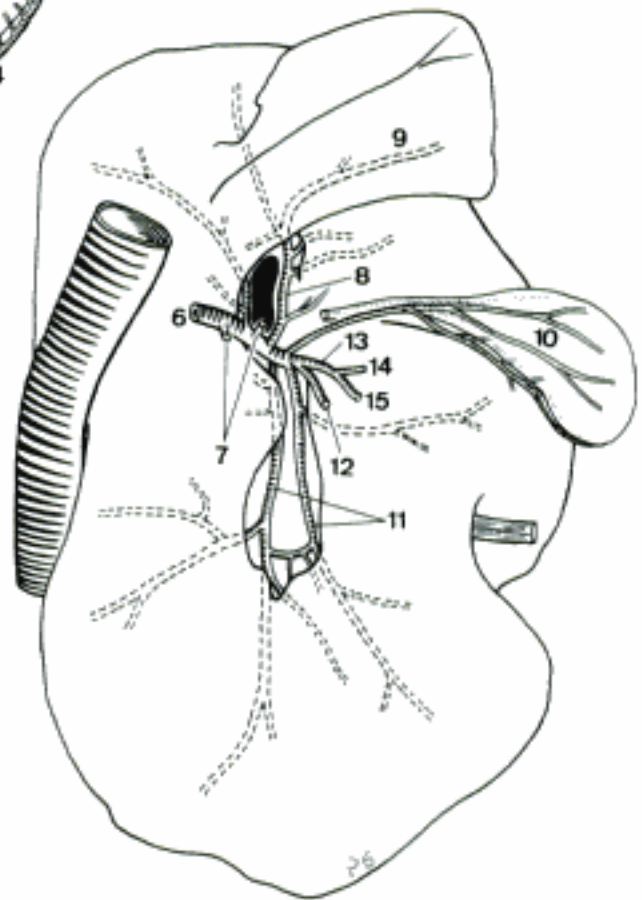
Hidden page

Hidden page

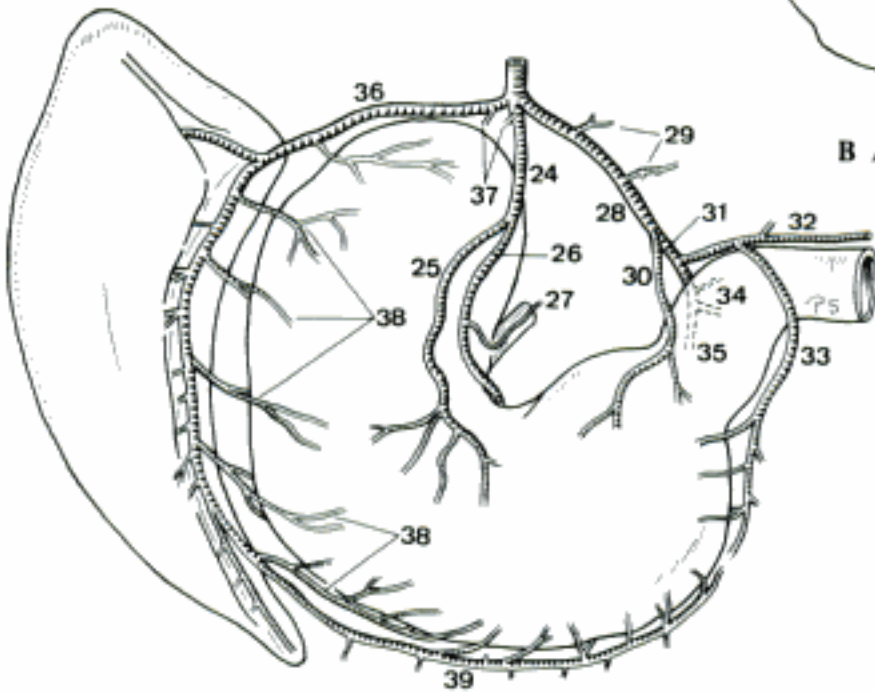
Hidden page



A Arteries of the stomach, right aspect (cap)

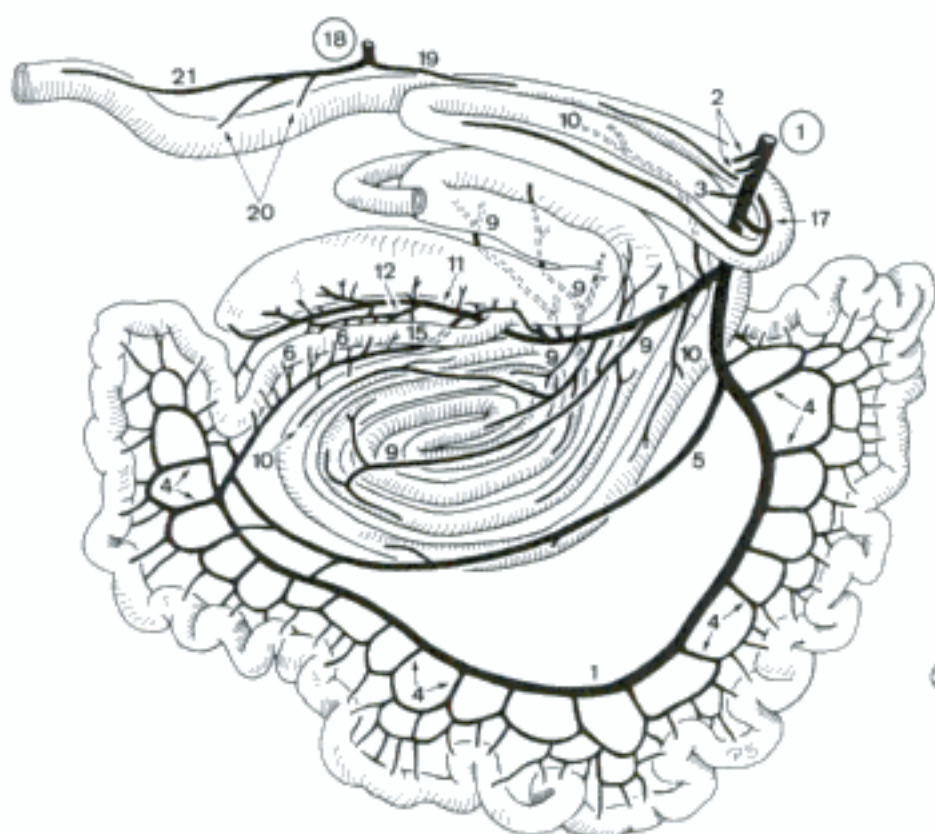


B Arteries of the liver, caudal aspect (bo)

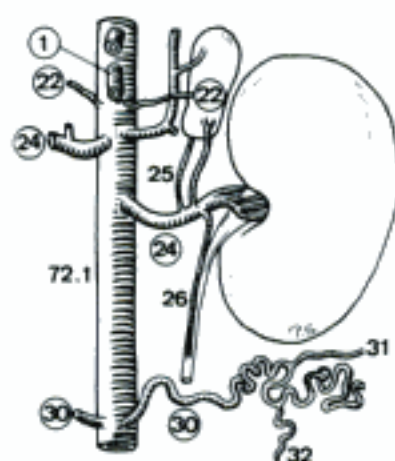


C Arteries of stomach and spleen, caudal aspect (eq)

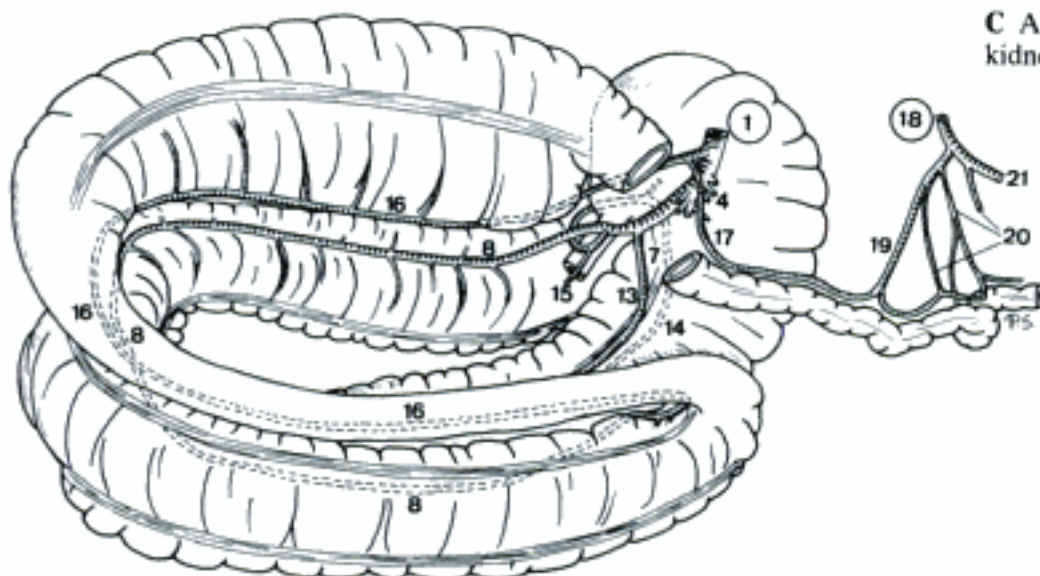
Hidden page



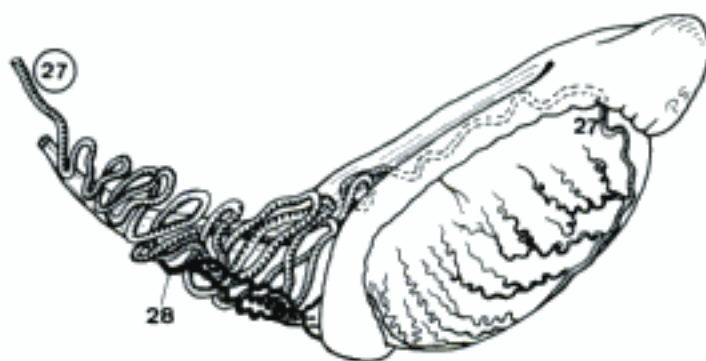
A Arteries of the intestinal tract, right aspect (bo)



C Aorta abdominalis and left kidney, ventral aspect (ca)



B Arteries of the large intestine, left aspect (eq)



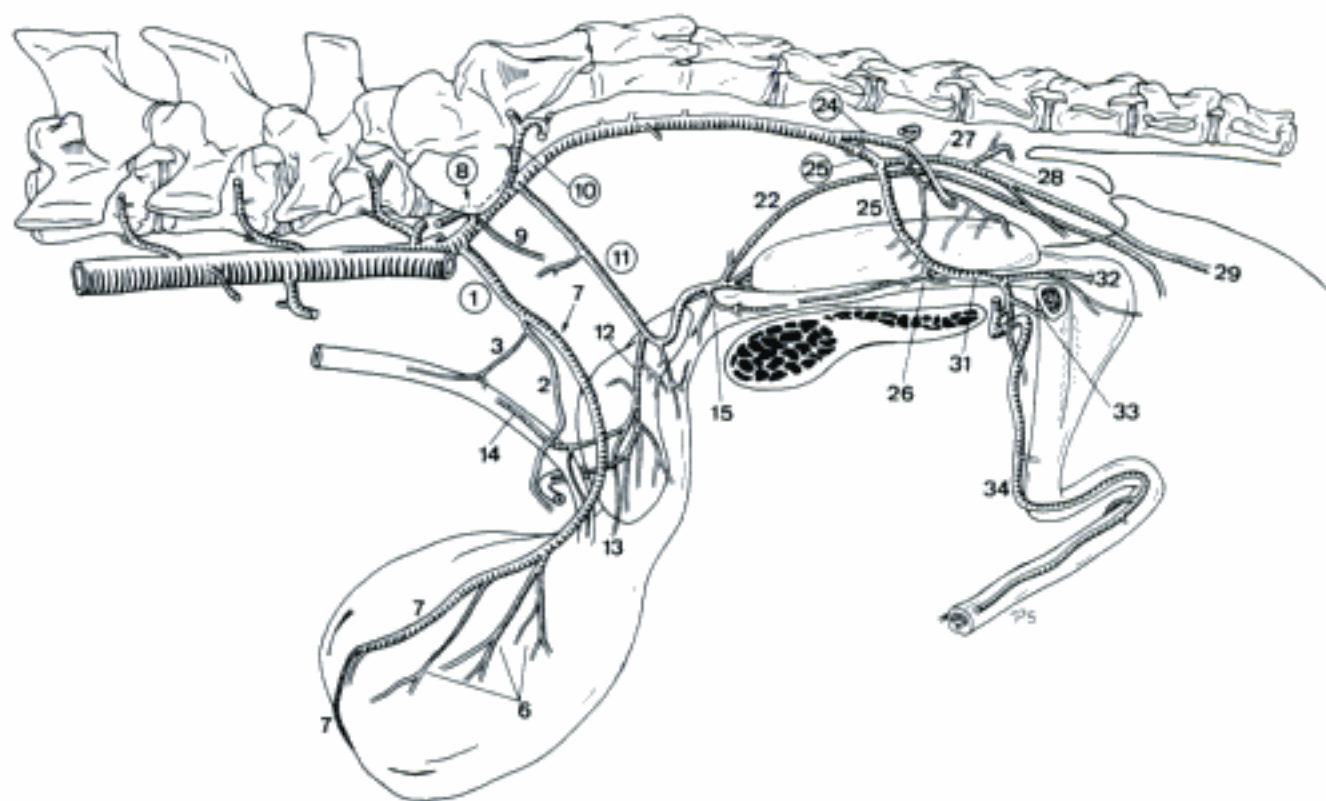
D Left A. testicularis, lateral aspect (su)

Hidden page

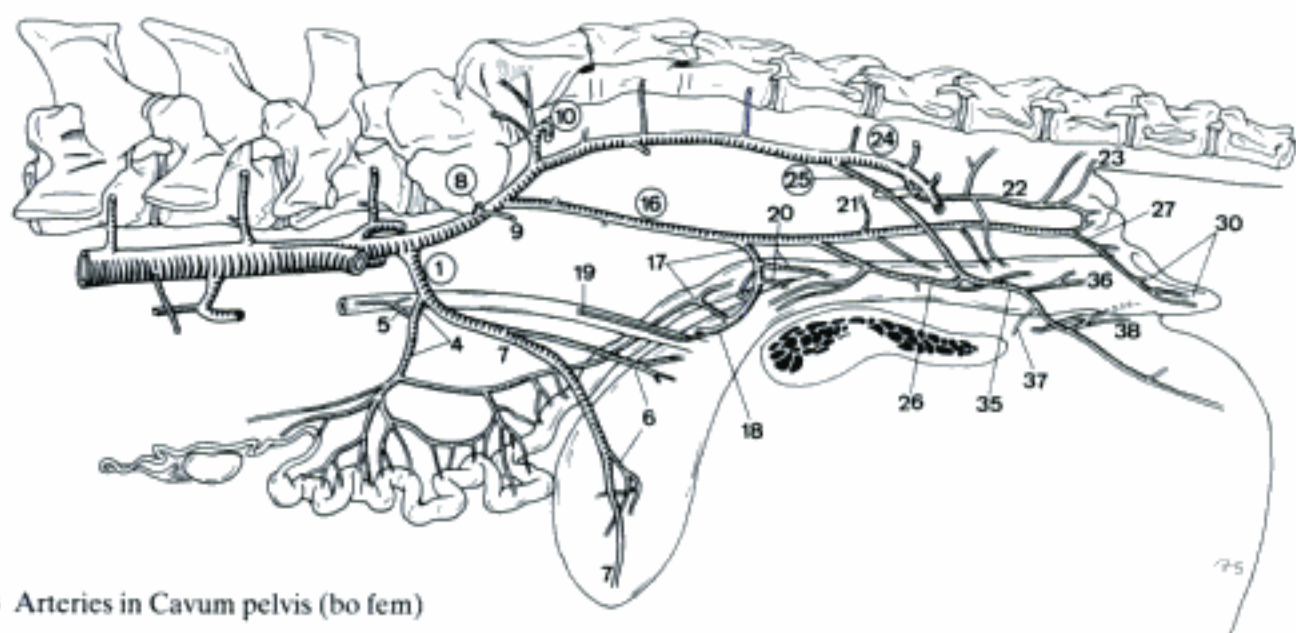
Hidden page

SUS

- 1 **A. umbilicalis.** Enters Lig. vesicae laterale. In the fetus it continues in Funiculus umbilicalis to the placenta. A B
- 2 *A. ductus deferentis.* Courses along Ductus deferens. A
- 3 *Ramus uretericus.* Ramifies along ureter. A
- 4 *A. uterina.* Courses in Lig. latum uteri, supplies Cervix, Corpus, and Cornu uteri. B
- 5 *Ramus uretericus.* Ramifies along ureter. B
- 6 *Aa. vesicales craniales.* Supply the cranial portion of Vesica urinaria. A B
- 7 *Ligamentum teres vesicae.* Vestige of *A. umbilicalis* near the cranial border of Lig. vesicae laterale. A B
- 8 **A. iliolumbalis.** To the lumbal musculature. A B
- 9 *A. obturatoria.* Passes with N. obturatorius towards Foramen obturatum. A B
- 10 **A. glutea [glutaea] cranialis.** Courses over Incisura ischiadica major. A B
- 11 **A. prostatica.** Runs over the lateral aspect of the rectum and Glandula vesicularis to prostata. A
- 12 *Ramus ductus deferentis.* Supplies the terminal segment of Dectus deferens. A
- 13 *A. vesicalis caudalis.* To the caudal part of Vesica urinaria. A
- 14 *Ramus uretericus.* Supplies the terminal segment of ureter. A
- 15 *Ramus urethralis.* Supplies the cranial segment of Pars pelvina of urethra. A
- 16 **A. vaginalis.** Courses along the lateral wall of the rectum to the vagina. B
- 17 *Ramus uterinus.* Runs along Cervix and Corpus uteri. B
- 18 *A. vesicalis caudalis.* Passes to the caudal part of Vesica urinaria. B
- 19 *Ramus uretericus.* Supplies the terminal segment of ureter. B
- 20 *Ramus urethralis.* Supplies the cranial segment of urethra. B
- 21 *A. rectalis media.* Inconstant, to rectum. B
- 22 *A. perinealis dorsalis.* Runs to perineum. Also described in su masc as branch of *A. prostatica* or *A. glutea caudalis*. A B
- 23 *A. rectalis caudalis.* Supplies Canalis analis. B
- 24 **A. glutea [glutaea] caudalis.** Courses laterally at Incisura ischiadica minor to the musculature at Regio clunis. A B
- 25 **A. pudenda interna.** Enters Cavum pelvis by piercing medially through Foramen ischiadicum minus and passes caudovertrally towards Arcus ischiadicus. A B
- 26 *A. urethralis.* Runs to the caudal portion of Urethra feminina s. Pars pelvina of Urethra masculina. May form a common initial trunk with its counterpart. A B
- 27 *A. perinealis ventralis.* Passes to perineum. A B
- 28 *A. rectalis caudalis.* Supplies Canalis analis. A
- 29 *Rami scrotales dorsales.* Ramify in the dorsal aspect of scrotum. A
- 30 *Rami labiales dorsales.* Ramify in Labium pudendi. B
- 31 *A. penis.* Courses towards Radix penis. A
- 32 *A. bulbi penis.* Enters Bulbus penis and ramifies in Corpus spongiosum penis. A
- 33 *A. profunda penis.* Enters Corpus cavernosum penis. A
- 34 *A. dorsalis penis.* Courses along Dorsum penis. Fuses with its counterpart or continues unilateally at Flexura sigmoidea penis. A
- 35 *A. clitoridis.* Courses to Crus clitoridis. B
- 36 *A. bulbi vestibuli.* Colurses to Bulbus vestibuli. B
- 37 *A. profunda clitoridis.* Enters Corpus cavernosum clitoridis. B
- 38 *A. dorsalis clitoridis.* Courses along the ventral aspect of Corpus clitoridis. The right may arise from its left counterpart. B



A Arteries in Cavum pelvis (bo masc)



B Arteries in Cavum pelvis (bo fem)

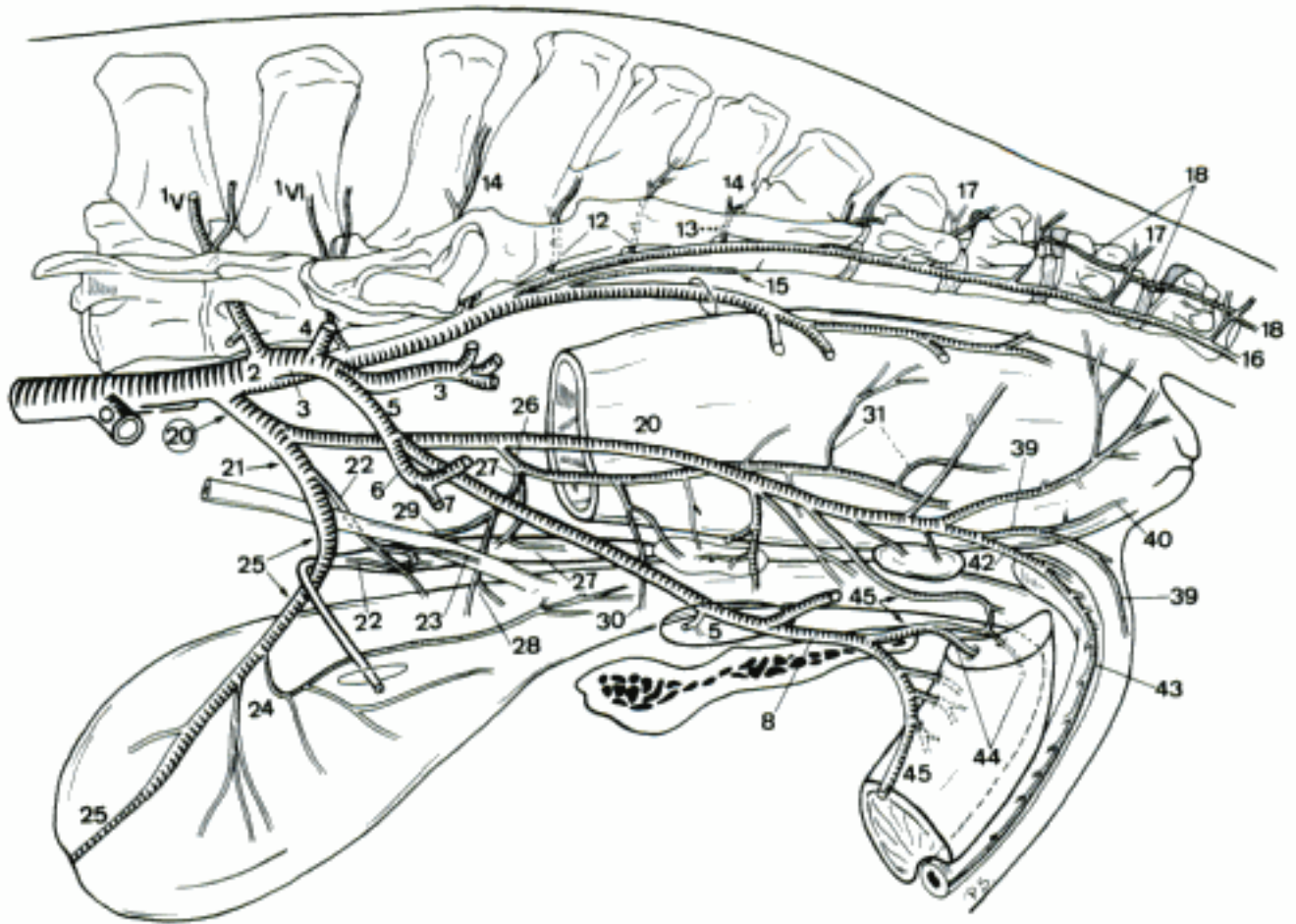
RUMINANTIA

- 1 **A. umbilicalis.** Curves in Lig. vesicae laterale. In the fetus it continues via Funiculus umbilicalis to the placenta. A B
- 2 *A. ductus deferentis.* Courses along Ductus deferens. A
- 3 *A. uterina.* Courses in Lig. latum uteri, supplies Cervix, Corpus, and Cornu uteri. B
- 4 *Ramus uretericus.* To the caudal segment of ureter. A B
- 5 *Aa. vesicales craniales.* Supply the cranial part of Vesica urinaria. A B
- 6 *Ligamentum teres vesicae.* Vestige of *A. umbilicalis* near cranial border of Lig. vesicae laterale. A B
- 7 **A. iliolumbalis.** Courses laterally between Os ilium and M. iliopsoas. A B
- 8 *A. lumbalis VI (bo).* A
- 9 **A. glutea [glutaea] cranialis.** Courses laterally through Foramen ischiadicum majus. Often plural. A B
- 10 *Rami sacrales I et II (bo).* Course dorsally into the corresponding Foramen sacrale pelvinum, leave as Ramus dorsalis the corresponding Foramen sacrale dorsale. A
- 11 **A. prostatica.** To Glandula vesicularis and prostata. A
- 12 *Ramus ductus deferentis.* Supplies the terminal segment of Ductus deferens. A
- 13 *A. vesicalis caudalis.* Supplies the caudal part of Vesica urinaria. A
- 14 *Ramus uretericus.* To the terminal segment of ureter. A
- 15 *Ramus urethralis.* Supplies the initial segment of Urethra masculina.
- 16 **A. vaginalis.** Courses to the vagina. B
- 17 *Ramus uterinus.* Courses along vagina and Cervix uteri. B
- 18 *A. vesicalis caudalis.* Supplies the caudal part of Vesica urinaria. B
- 19 *Ramus uretericus.* To the terminal segment of ureter. B
- 20 *Ramus urethralis.* Passes to the initial segment of urethra. B
- 21 *A. rectalis media.* To the rectum we. Also described in the male Ru, as branch of *A. prostatica*. B
- 22 *A. perinealis dorsalis.* Runs toward anus. Also described in the male, as branch of *A. prostatica*. B
- 23 *A. rectalis caudalis.* Supplies the caudal segment of rectum and the Canalis analis. B
- 24 *Ramus labialis dorsalis.* Enters the dorsal aspect of Labium pudendi. B
- 25 **A. glutea [glutaea] caudalis.** Leaves Cavum pelvis through Foramen ischiadicum minus. A B
- 26 **A. pudenda interna.** Runs toward Arcus ischiadicus. A B
- 27 *A. urethralis (bo).* Supplies the caudal segment of Urethra feminina s. Pars pelvina of Urethra masculina. A
- 28 *A. vestibularis (bo).* Courses ventrally to the lateral wall of Vestibulum vaginae.
- 29 *A. perinealis ventralis.* Courses to perineum. A B
- 30 *A. rectalis caudalis.* Supplies the caudal segment of rectum and the Canalis analis of the male. A
- 31 *Ramus labialis dorsalis et mammarius.* Ramifies in Labium pudendi and continues at Regio supramammaria. B
- 32 *A. urethralis (ov, cap).* Supplies the caudal segment of Urethra feminina s. Pars pelvina of Urethra masculina. B
- 33 *A. penis.* Courses to Radix penis. A
- 34 *A. bulbi penis.* Enters Bulbus penis and continues in Corpus spongiosum penis. A
- 35 *A. profunda penis.* Enters Crus penis and contributes to a vessel which runs in Corpus cavernosum penis. A
- 36 *A. dorsalis penis.* Courses along Dorsum penis towards glans and Preputium. Usual asymmetrical. A
- 37 *A. clitoridis.* To Crus clitoridis. B
- 38 *A. bulbi vestibuli (ov, cap).* Ramifies in Bulbus vestibuli. B
- 39 *A. profunda clitoridis.* Enters Corpus cavernosum clitoridis. B
- 40 *A. dorsalis clitoridis.* Courses along the ventral aspect of Corpus clitoridis. B

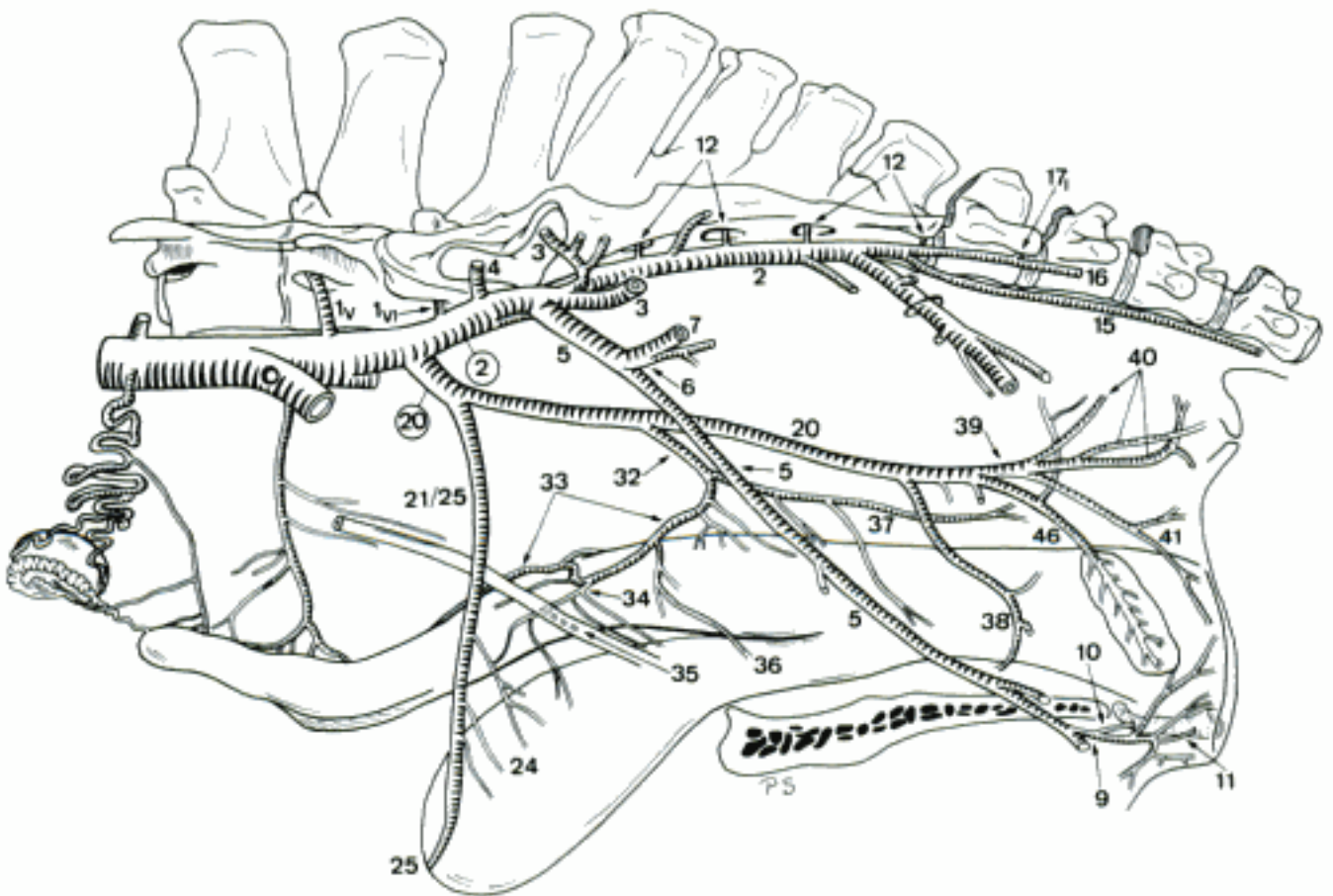
Hidden page

EQUUS

- 1 **Aa. lumbales V et VI.** A B
- 2 **A. glutea [glutaea] caudalis.** Passes through the dorsal part of Lig. sacrotuberale latum. A B
- 3 *A. glutea [glutaea] cranialis.* Curves caudoventrally at the medial aspect of Os ilium. Passes through Foramen ischiadicum majus. A B
- 4 *A. iliolumbalis.* Runs across the ventromedial aspect of Ala ossis ilium and continues craniodorsally at its craniolateral aspect. May arise from *A. glutea caudalis*. A B
- 5 *A. obturatoria.* Leaves Cavum pelvis through Foramen obturatum. A B
- 6 *A. iliocofemoralis.* Curves across the craniomedial aspect of Corpus ossis ilium. A B
- 7 *Ramus ascendens.* Courses along *M. tensor fasciae latae*. A B
- 8 *A. penis media.* To Dorsum penis, joins *A. dorsalis penis*. A
- 9 *A. clitoridis media.* To Crus clitoridis, the only artery of the clitoris in eq. B
- 10 *A. profunda clitoridis.* Supplies Corpus cavernosum clitoridis. B
- 11 *A. dorsalis clitoridis.* Courses along the ventral border of Corpus clitoridis towards glans. B
- 12 *Rami sacrales.* Course into the corresponding Foramen sacrale pelvinum. A B
- 13 *Ramus spinalis.* To *A. spinalis ventralis*. A
- 14 *Ramus dorsalis.* Emerges through Foramen sacrale dorsale. A
- 15 *A. caudalis [coccygea] mediana.* Arises from the left or right *A. glutea caudalis* or *A. caudalis ventrolateralis*, exceptionally from *A. sacralis mediana*. A B
- 16 *A. caudalis [coccygea] ventrolateralis.* Continues along the ventrolateral aspect of Vertebrae caudales. A B
- 17 *Rami caudales [coccygei].* Course dorsally to the caudal aspect of the corresponding Vertebra caudalis. A B
- 18 *A. caudalis [coccygea] dorsolateralis.* Chain of anastomoses between the Rami caudales at the dorsolateral aspect of Vertebrae caudales. A
- 19 *Corpora caudalia [coccygea].* Nodules of arteriovenous anastomoses in the tail.
- 20 **A. pudenda interna.** Continues along the Spina ischiadica. A B
- 21 *A. umbilicalis.* Curves in Lig. vesicae laterale. In the fetus it continues to the placenta. A B
- 22 *A. ductus deferentis.* Courses along Ductus deferens. A
- 23 *Ramus uretericus.* Supplies ureter. A
- 24 *Aa. vesicales craniales.* Supply Vesica urinaria. A B
- 25 *Ligamentum teres vesicae.* Vestige of *A. umbilicalis* near the cranial border of Lig. vesicae laterale. A B
- 26 *A. prostatica.* To Prostata. A
- 27 *Ramus ductus deferentis.* Supplies the terminal segment of Ductus deferens. A
- 28 *A. vesicalis caudalis.* To Vesica urinaria. A
- 29 *Ramus uretericus.* Supplies the terminal segment of ureter. A
- 30 *Ramus urethralis.* Supplies the cranial segment of Urethra masculina. A
- 31 *A. rectalis media.* Ramifies in the wall of rectum. A
- 32 *A. vaginalis.* Supply for the pelvic viscera, esp. vagina. B
- 33 *Ramus uterinus.* To Cervix and Corpus uteri. B
- 34 *A. vesicalis caudalis.* To the caudal segment of Vesica urinaria. B
- 35 *Ramus uretericus.* Supplies the terminal segment of ureter. B
- 36 *Ramus urethralis.* Supplies the cranial segment of Urethra feminina. B
- 37 *A. rectalis media.* To the rectum. B
- 38 *Ramus vestibularis.* Passes around the Vestibulum vaginae. B
- 39 *A. perinealis ventralis.* To perineum. A B
- 40 *A. rectalis caudalis.* To the caudal segment of rectum and Canalis analis. A B
- 41 *Ramus labialis dorsalis.* To Labium pudendi. B
- 42 *A. penis.* To Radix penis. A
- 43 *A. bulbi penis.* Enters Bulbus penis and continues in Corpus spongiosum penis. A
- 44 *A. profunda penis.* Enters Corpus cavernosum penis. A
- 45 *A. dorsalis penis.* Courses along Dorsum penis, is reinforced by *A. penis media*. A
- 46 *A. bulbi vestibuli.* To Bulbus vestibuli. B



A Arteries in Cavum pelvis (eq masc)



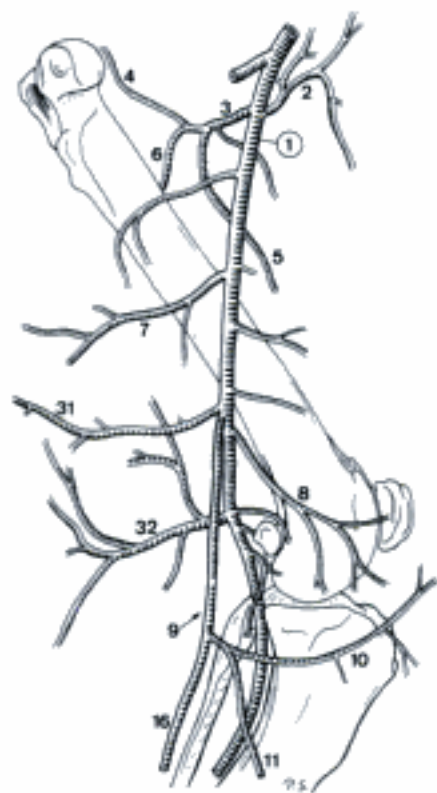
B Arteries in Cavum pelvis (eq fem)

Hidden page

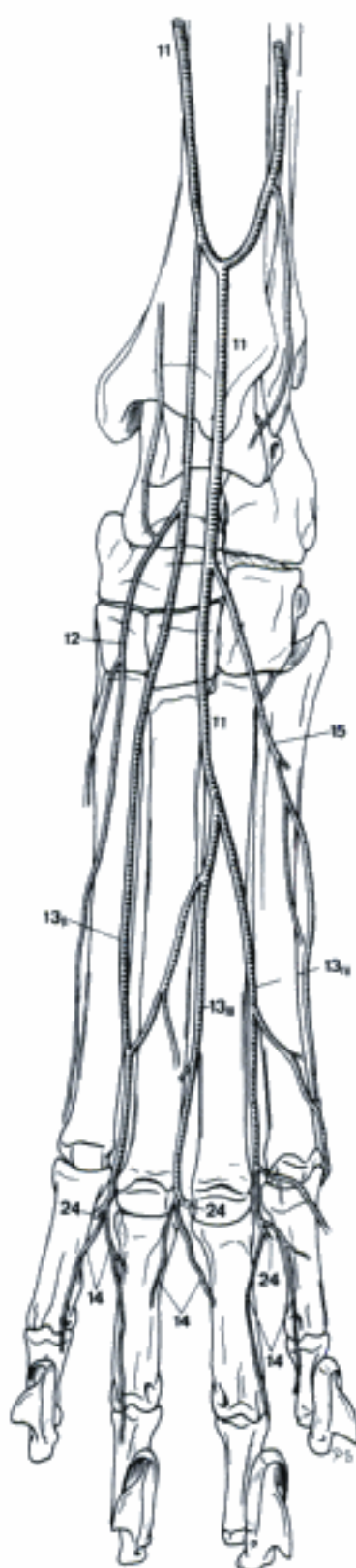
Hidden page

CARNIVORA

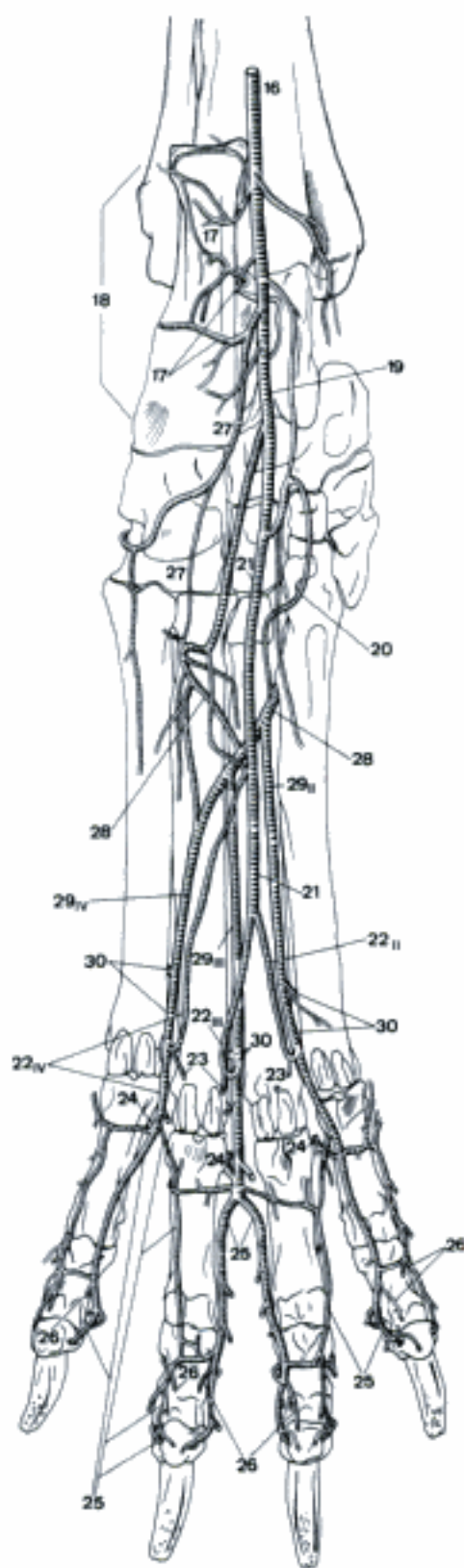
- 1 **A. femoralis.** Continuation of *A. iliaca externa*, courses through *Canalis femoralis*. A
- 2 *A. circumflexa ilium superficialis (ca)*. Also described in *fe* as branch of *A. circumflexa femoris lateralis*. A
- 3 *A. circumflexa femoris lateralis*. Courses laterally between *M. vastus medialis* and *M. rectus femoris*. A
- 4 *Ramus ascendens*. Courses proximally. A
- 5 *Ramus descendens*. Courses distolaterally inside *M. quadriceps femoris*. A
- 6 *Ramus transversus*. A
- 7 *A. caudalis femoris proximalis*. Muscular branch, usually coursing across the lateral surface of *M. gracilis*. A
- 8 *A. genus descendens*. To the medial aspect of *Articulatio genus*. A
- 9 *A. saphena*. Courses superficially to *Condylus medialis tibiae*. A
- 10 *Ramus articularis genus*. Courses over *M. sartorius* to *Articulatio genus*. A
- 11 *Ramus cranialis*. Runs over *Facies medialis* of *Corpus tibiae*, continues onto *Dorsum pedis*. A B
- 12 *A. digitalis dorsalis II abaxialis (fe)*. B
- 13 *Aa. digitales dorsales communes II–IV (fe)*, *I–IV (ca)*. Subcutaneous arteries, run to the *Articulationes metatarsophalangeae* where they bifurcate. B
- 14 *Aa. digitales dorsales propriae*. Arise from the bifurcation of *Aa. digitales dorsales communes*, run along the dorsal parts of the adjacent surfaces of the digits. B
- 15 *A. digitalis dorsalis V abaxialis (fe)*. Passes along the dorsolateral aspect of *Digitus V*. B
- 16 *Ramus caudalis*. Courses superficially along the medial border of *Corpus tibiae* to the medioplantar aspect of *tarsus*. A C
- 17 *Rami calcanei*. To *calcaneus*. C
- 18 *Rete calcaneum*. Network at *Tuber calcanei*. C
- 19 *A. plantaris medialis*. Larger terminal branch at the medial aspect of the *tarsus*. C
- 20 *Ramus profundus (ca)*. Passes along the medial border of the tendon of *M. flexor digitorum profundus*, lateral contribution to *Arcus plantaris profundus*. Also described in *fe*. C
- 21 *Ramus superficialis*. Runs along the medial border of the tendon of *M. flexor digitorum superficialis*. C
- 22 *Aa. digitales plantares communes II–IV*. Superficial branches of *Ramus superficialis* of *A. plantaris medialis*. C
- 23 *Ramus tori metatarsi*. Branch for *Torus metatarsus*, given off by each *A. digitalis plantaris communis*. C
- 24 *A. interdigitalis*. Connects each *A. digitalis plantaris communis* corresponding *A. digitalis dorsalis communis* or *Aa. digitales dorsales propriae (ca)*. B C
- 25 *Aa. digitales plantares propriae*. Arise from the bifurcation of *Aa. digitales plantares communes*, course along the plantar aspects of adjacent digits, enter *Foramen soleare axiale s. abaxiale* of *Phalanx distalis*. C
- 26 *Ramus tori gigitalis*. Supplies the *Torus digitalis*. C
- 27 *A. plantaris lateralis*. Runs between *Mm. flexores digitorum superficialis* and *profundus*, continues along the lateral aspect of the tendon of *M. flexor digitorum profundus*. C
- 28 *Arcus plantaris profundus*. Courses transversely across the plantar aspect of *Mm. interossei*, joins *Ramus profundus* of *A. plantaris medialis*. Receives most of its blood via *Ramus perforans proximalis II*. C
- 29 *Aa. metatarsae plantares II–IV*. Branches of *Arcus plantaris profundus* along the lateroplantar aspect of the corresponding *Os metatarsale*. C
- 30 *Ramus perforans distalis*. Connects each *A. metatarsae plantaris* with its dorsal counterpart by traversing the *Spatium interosseum metatarsi*. Also connected with *A. digitalis dorsalis* and *plantaris communis*. C
- 31 *A. caudalis femoris media*. Muscular branch for *M. adductor* and *M. semimembranosus*. A
- 32 *A. caudalis femoris distalis*. Large muscular branch in the poples. A



A Arteries of left femur, medial aspect (ca)



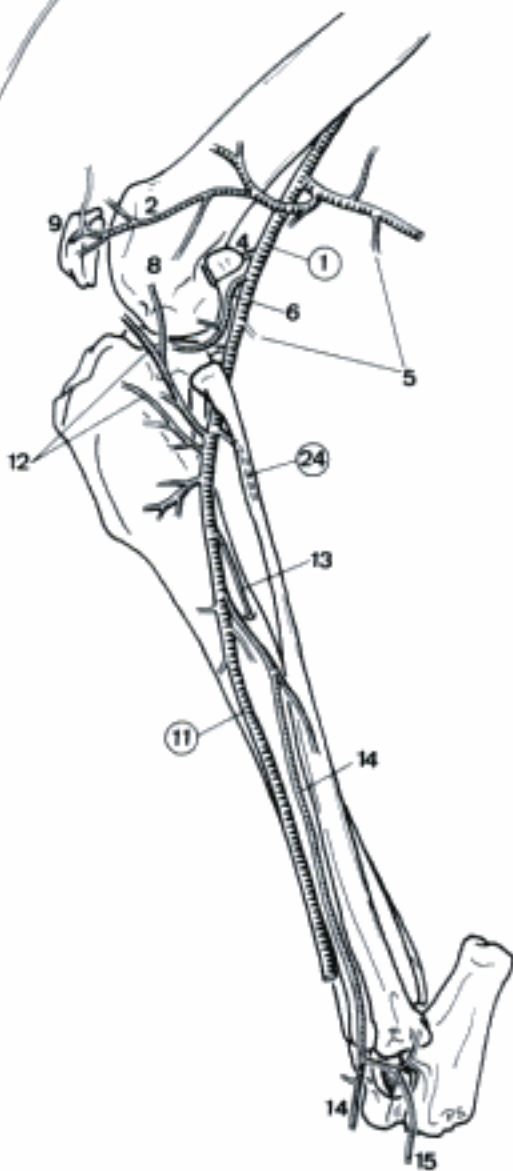
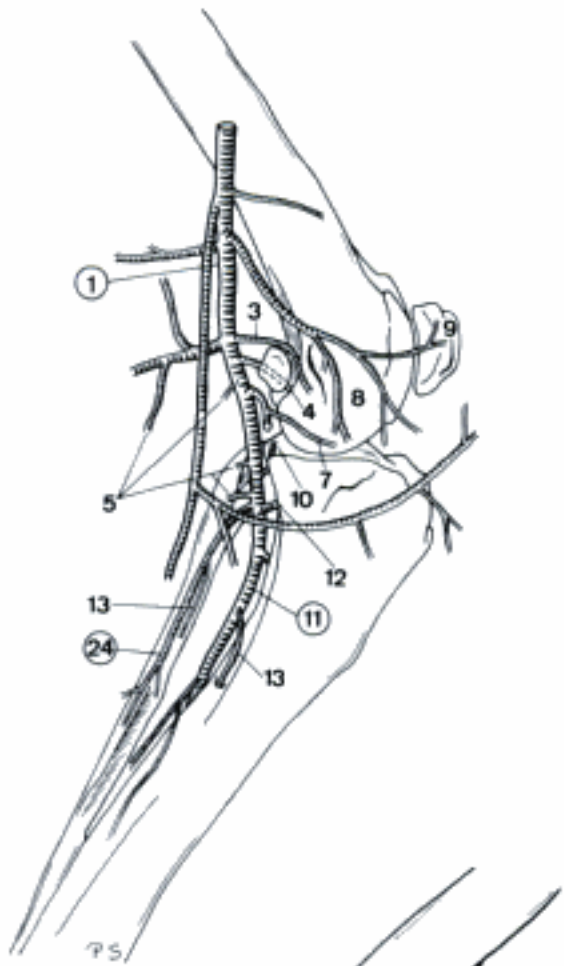
B Arteries of left pes, dorsal aspect (fe)



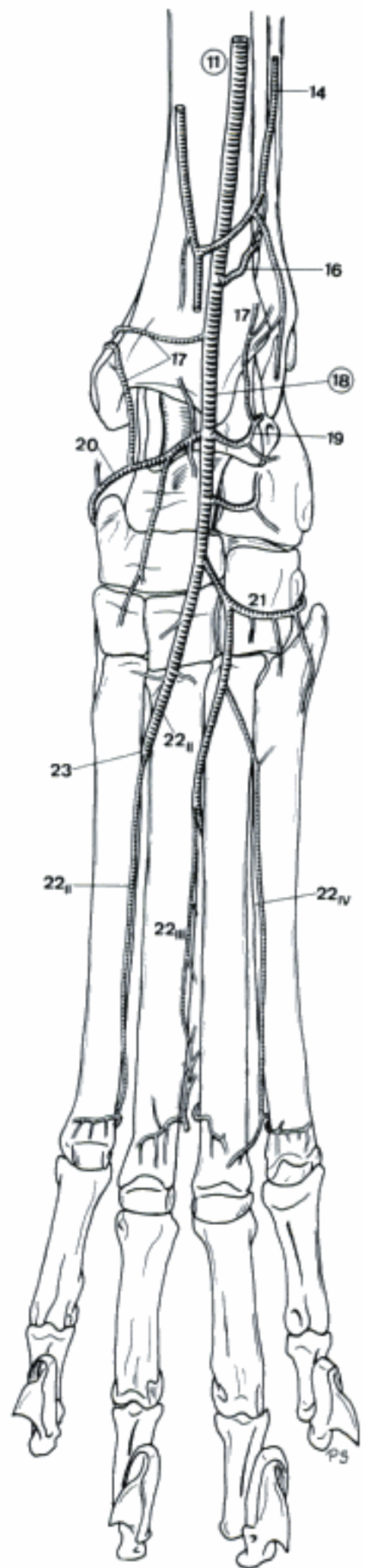
C Arteries of left pes, plantar aspect (ca)

- 1 **A. poplitea.** Continuation of A. femoralis beyond the origin of A. caudalis femoris distalis. Passes over the flexor surface of Articulatio femorotibialis. A B
- 2 *A. genus proximalis lateralis.* Ramifies in joint capsule along Condylus lateralis of Os femoris. B
- 3 *A. genus proximalis medialis.* Ramifies in joint capsule along Condylus medialis of Os femoris. A
- 4 *A. genus media.* Passes cranially to Fossa intercondylaris of Os femoris. A B
- 5 *Aa. surales.* Course to the muscles along the caudal aspect of crus. A B
- 6 *A. genus distalis lateralis (ca).* Courses over the medial surface of Ligamentum collaterale laterale of Articulatio femorotibialis to the lateral aspect of Articulatio genus. Also present in fe. B
- 7 *A. genus distalis medialis (ca).* Passes over the lateral surface of Ligamentum collaterale mediale of Articulatio femorotibialis to the medial aspect of Articulatio genus. Also present in fe. A
- 8 *Rete articulare genus.* Network around Articulatio genus. A B
- 9 *Rete patellae.* Network at the patella. A B
- 10 *A. recurrens tibialis caudalis (ca).* Courses proximally along the caudal aspect of tibia to Articulatio femorotibialis. Also described in fe as branch of A. tibialis cranialis. A
- 11 **A. tibialis cranialis.** Larger terminal branch of A. poplitea, courses craniodistally through the proximal part of Membrana interossea cruris and continues along the craniolateral aspect of tibia. A B C
- 12 *A. recurrens tibialis cranialis (ca).* Courses proximally over Facies lateralis of tibia toward Articulatio genus. Usually also present in fe. A B
- 13 *A. nutricia tibiae et fibulae.* Stem for the nutrient arteries for tibia and fibula. In many cases these two branches arise separately. A B
- 14 *Ramus superficialis.* Courses along Facies lateralis of Corpus tibiae and usually joins Ramus cranialis of A. saphena at the tarsus. B C
- 15 *A. digitalis dorsalis V abaxialis (ca).* Runs along the dorsolateral aspect of tarsus, metatarsus and Digitus V. B
- 16 *Ramus interosseus (fe).* Courses caudally through the distal part of Membrana interossea cruris, anastomoses with branches of A. caudalis femoris distalis. Also connected with Ramus cranialis (and Ramus caudalis) of A. saphena. C
- 17 *Rami malleolares.* Course to Malleolus medialis and Malleolus lateralis. C
- 18 **A. dorsalis pedis.** Extension of A. tibialis cranialis distal to Articulatio tarsocruralis on the dorsal aspect of the tarsus. C
- 19 *A. tarsea lateralis.* Courses to the lateral aspect of the tarsus. C
- 20 *A. tarsea medialis.* Courses to the medial aspect of the tarsus. C
- 21 *A. arcuata.* Courses laterally across the dorsal and lateral aspect of the tarsus. C
- 22 *Aa. metatarsae dorsales II–IV.* Run along the dorsolateral aspects of Ossa metatarsalis II–IV and join the corresponding Ramus perforans distalis. C
- 23 *Ramus perforans proximalis II.* Large branch of A. metatarsae dorsales II which courses to the plantar aspect of Metatarsus by passing between the proximal ends of Ossa metatarsalia II and III. Joins Arcus plantaris profundus. C
- 24 **A. tibialis caudalis.** Small terminal branch of A. poplitea at the caudal aspect of Skeleton cruris. A B

A Arteries of left stifle, medial aspect (ca)

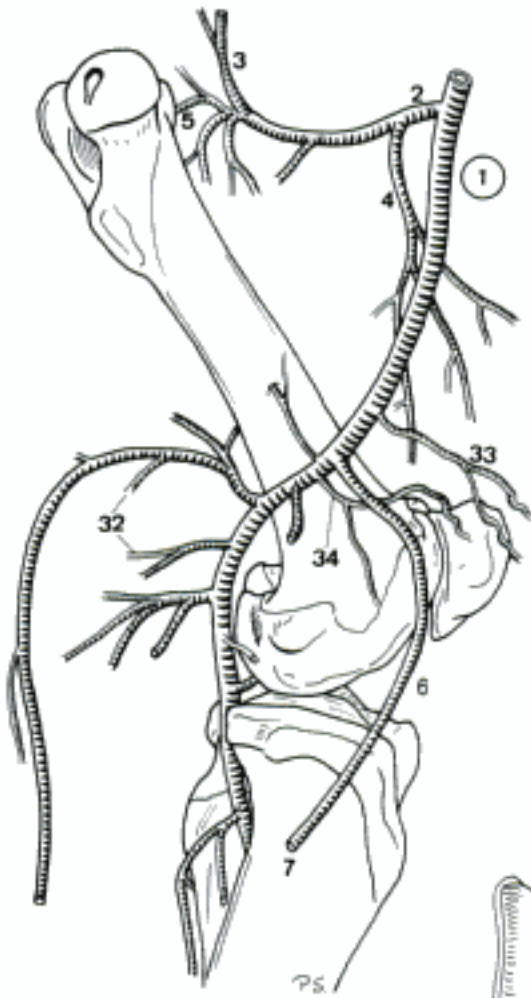


B Arteries of left stifle, lateral aspect (ca)

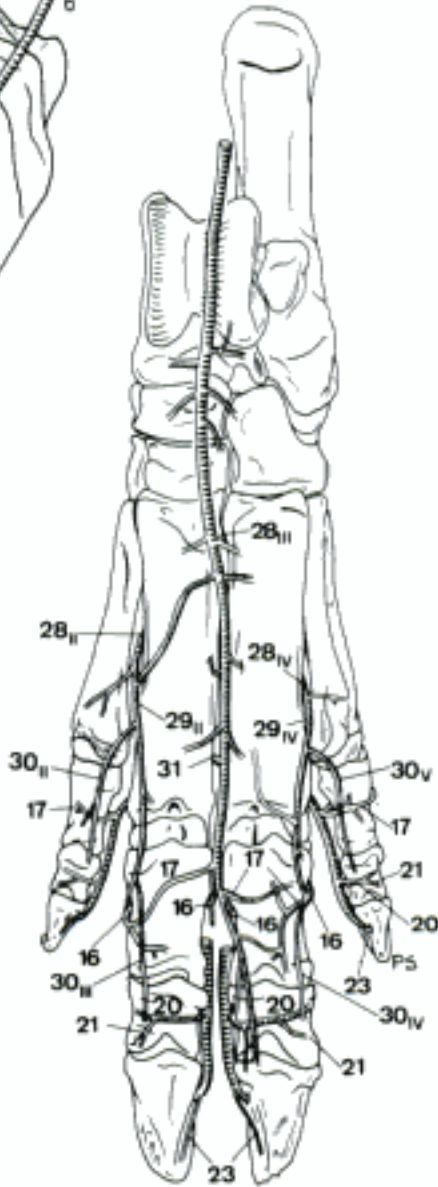


C Arteries of left pes, dorsal aspect (fe)

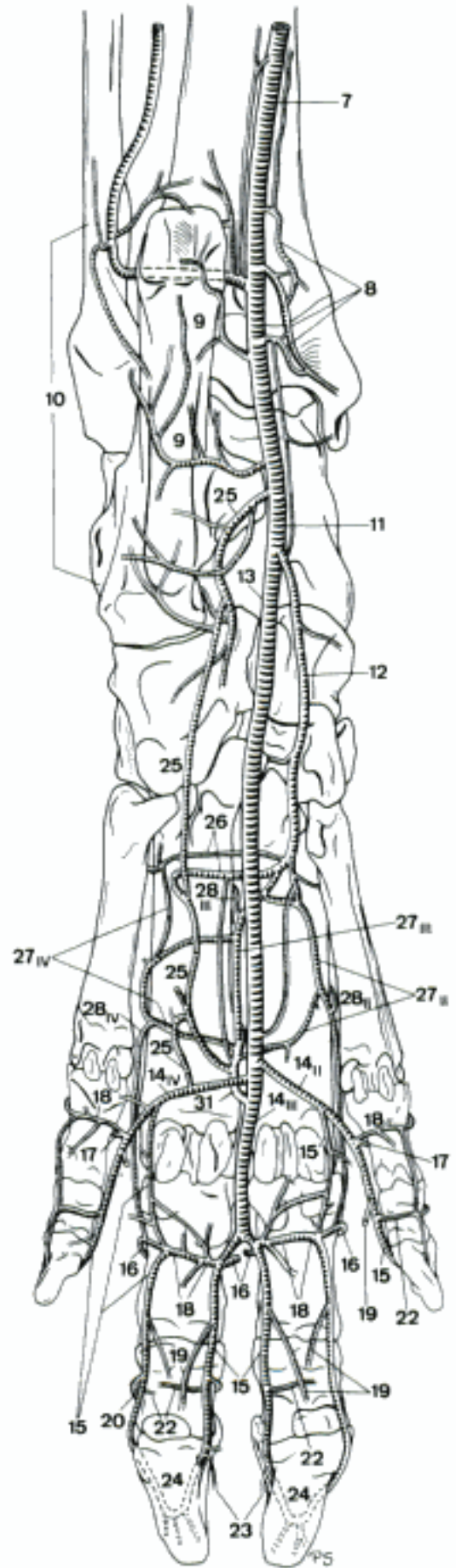
Hidden page



A Arteries of left femur, medial aspect (su)

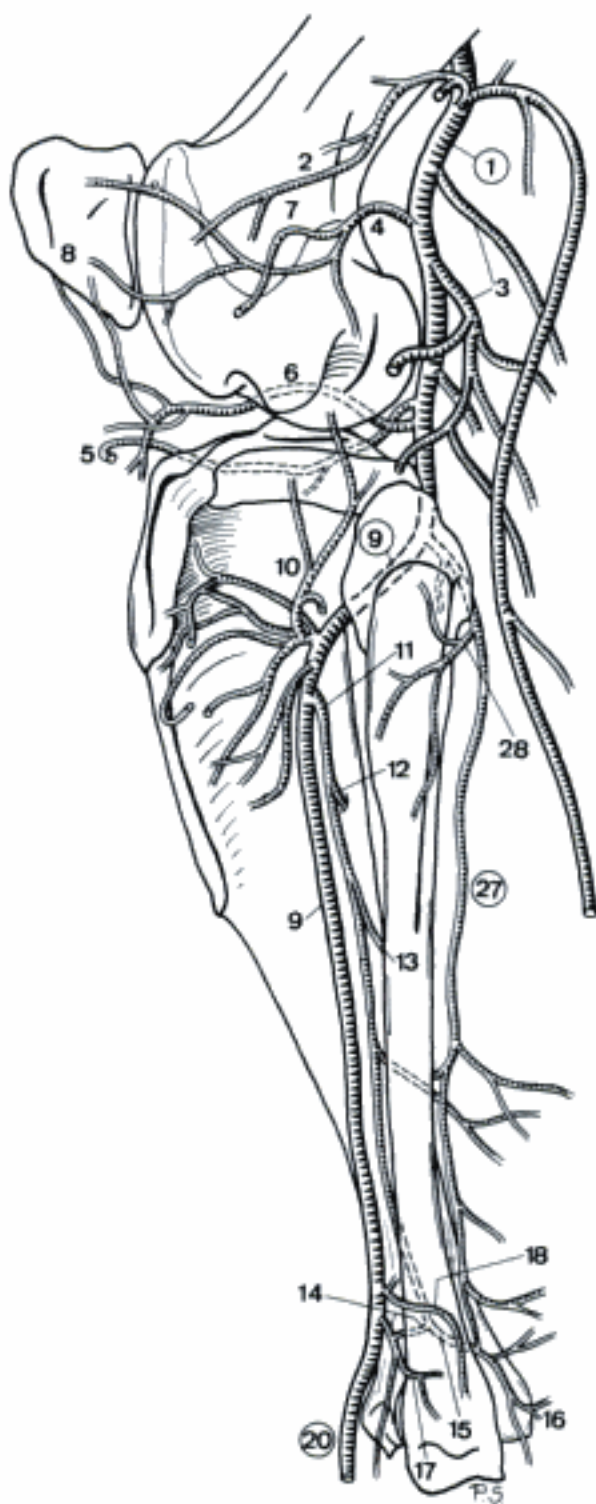


B Arteries of left pes, dorsal aspect (su)

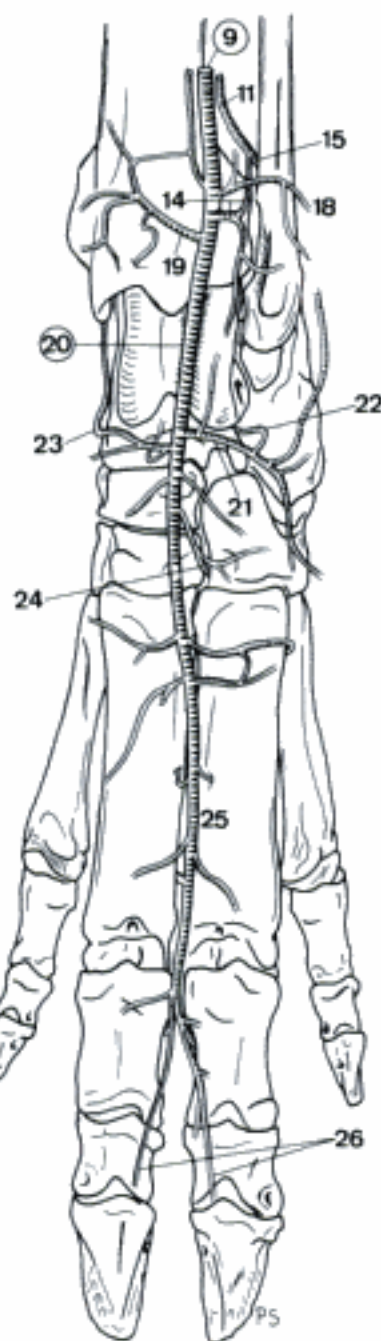


C Arteries of left pes, plantar aspect (su)

- 1 **A. poplitea.** Continuation of A. femoralis in poples, runs over the flexor surface of Articulatio femorotibialis. A
- 2 *A. genus proximalis lateralis.* Courses to the lateral aspect of Articulatio genus. A
- 3 *Aa. surales.* Caudodistal branches for the musculature at the caudal aspect of crus. A
- 4 *A. genus distalis lateralis.* Courses to the lateral aspect of Articulatio genus. A
- 5 *A. genus distalis medialis.* Courses to the medial aspect of Articulatio genus. A
- 6 *A. genus media.* Runs cranially between Condylus lateralis and Condylus medialis of Os femoris to the cranial aspect of Articulatio genus. A
- 7 *Rete articulare genus.* Arterial Network surrounding Articulatio genus. A
- 8 *Rete patellae.* Network at the patella. A
- 9 **A. tibialis cranialis.** Larger terminal branch of A. poplitea which courses through the proximal part of Membrana interossea cruris and continues along the lateral border of tibia. A B
- 10 *A. recurrens tibialis cranialis.* Courses proximally over Condylus lateralis of tibia towards Articulatio genus. A
- 11 *A. interossea cruris.* Runs at the caudal surface of Membrana interossea cruris. A B
- 12 *A. nutricia tibiae.* Enters Foramen nutricium of tibia. A
- 13 *A. nutricia fibulae.* Enters Foramen nutricium of fibula. A
- 14 *Ramus perforans.* Passes cranially through the distal part of Membrana interossea cruris and joins A. tibialis cranialis. A B
- 15 *Ramus anastomoticus cum a. tibiali caudali.* Passes caudomedially over the distal aspect of tibia, anastomoses with A. tibialis caudalis. A B
- 16 **Rami malleolares mediales.** Reach Malleolus medialis. A
- 17 *Rami malleolares laterales.* To Malleolus lateralis. A
- 18 *A. malleolaris cranialis lateralis.* Passes caudolaterally to Malleolus lateralis. In constant. A B
- 19 *A. malleolaris cranialis medialis.* Passes to Malleolus medialis. B
- 20 **A. dorsalis pedis.** Continuation of A. tibialis cranialis, distal to Articulatio tarsocruralis. Lies on the dorsal aspect of the tarsus. A B
- 21 *A. tarsea lateralis.* Courses laterally to the lateral aspect of the tarsus, divides in proximal and distal branches. B
- 22 *A. tarsea perforans proximalis.* Pierces between talus and calcaneus, joins A. plantaris lateralis. B
- 23 *A. tarsea medialis.* Courses to the medial aspect of the tarsus. B
- 24 *A. tarsea perforans distalis.* Pierces between Os tarsale III and IV, joins Ramus profundus of A. plantaris medialis. B
- 25 *A. metatarsea dorsalis III.* Continuation of A. dorsalis pedis, courses at the dorsal aspect of metatarsus. Joined by Ramus perforans distalis, finally reaches the paired A. interdigitalis III. B
- 26 *Aa. digitales dorsales propriae.* Dorsal vessels which course along the axial aspects of Digiti III and IV. B
- 27 **A. tibialis caudalis.** Smaller terminal branch of A. poplitea, coursing distally along the caudal aspect of crus. A
- 28 *Ramus circumflexus fibulae.* Passes laterally around the fibula. A

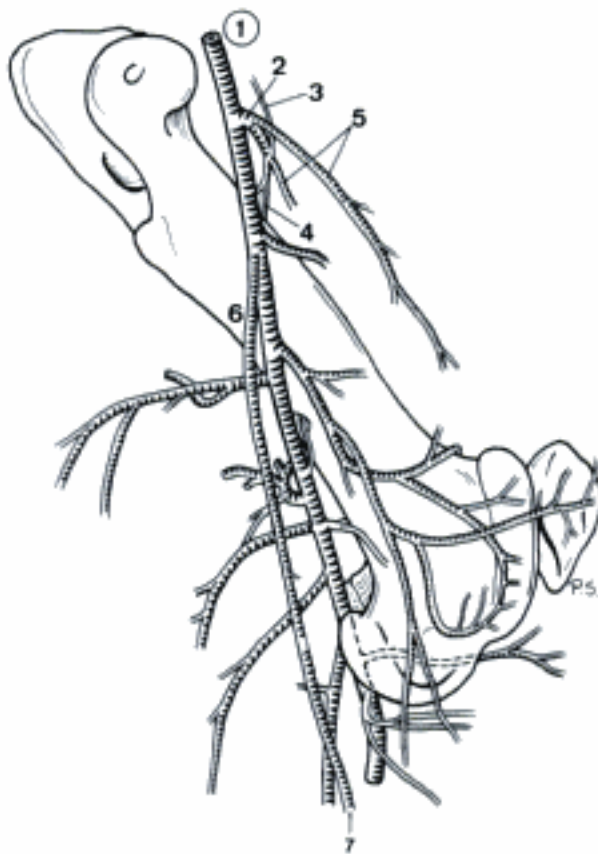


A Arteries of left stifle, lateral aspect (su)



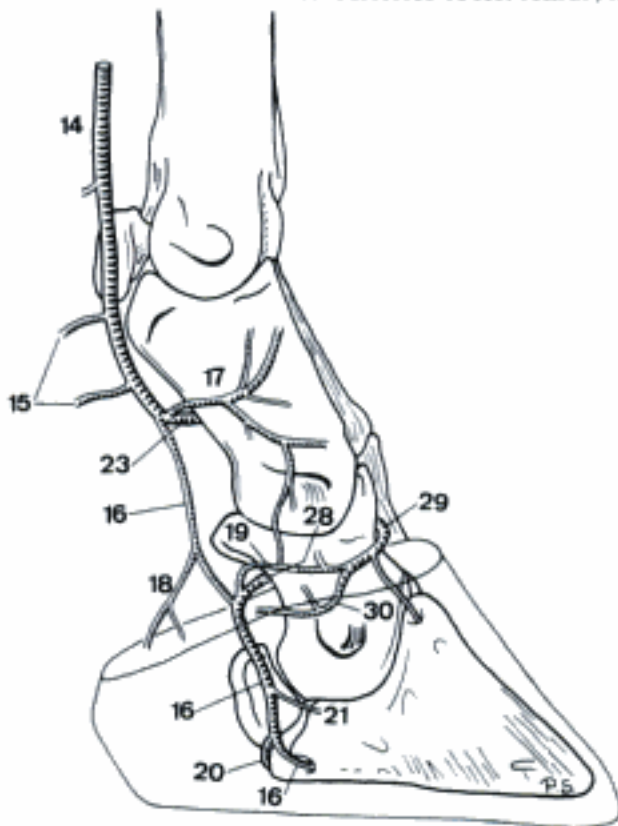
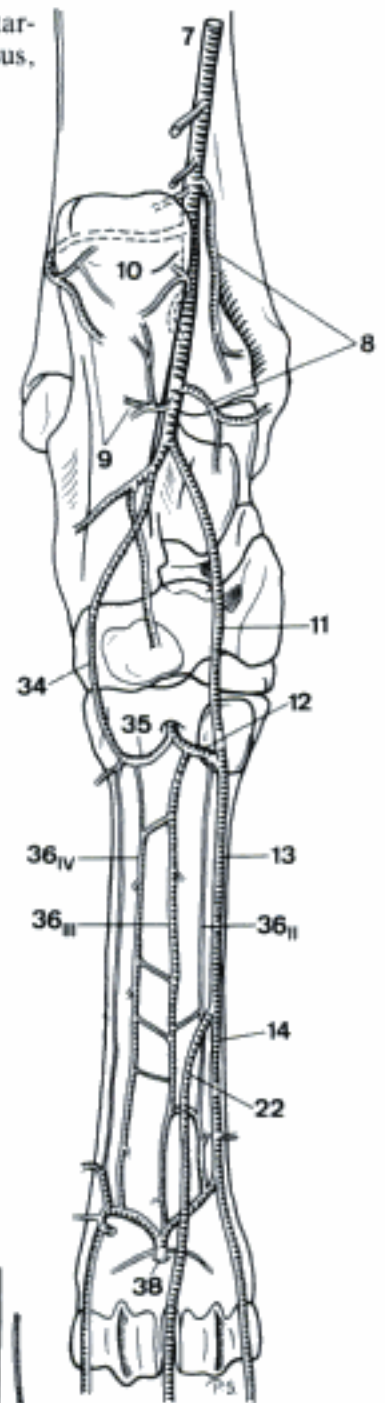
B Arteries of left pes, dorsal aspect (su)

Hidden page

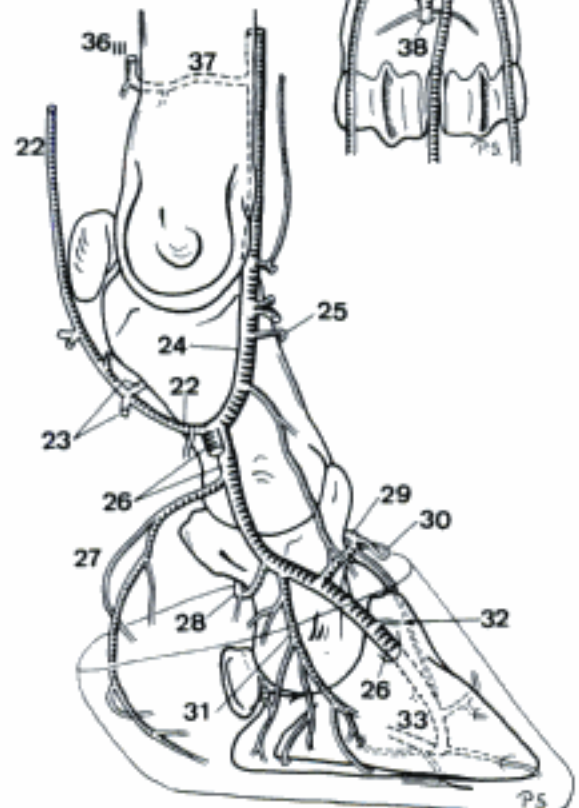


A Arteries of left femur, medial aspect (bo)

B Arteries of left tarsus and metatarsus, plantar aspect (bo)



C Arteries of left pes, medial aspect (bo)



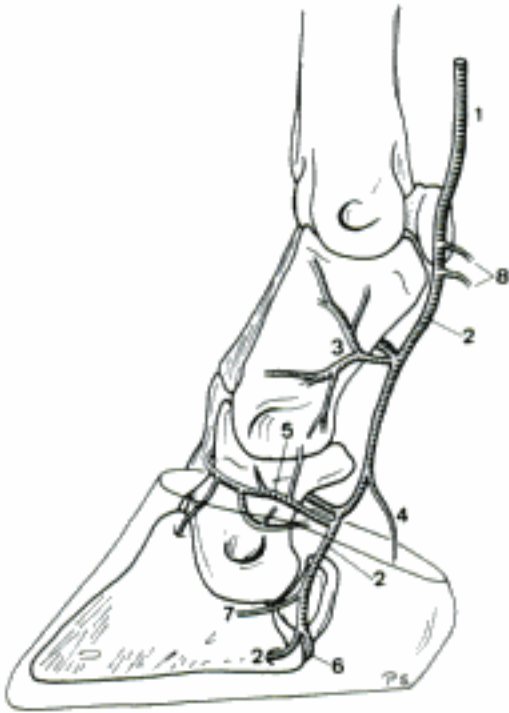
D Arteries of left pes (third digit removed), medial aspect (bo)

36 Aa. metatarsae plantares II-IV. Branches of Arcus plantaris profundus between Os metatarsale III et IV and M. interosseus. B D

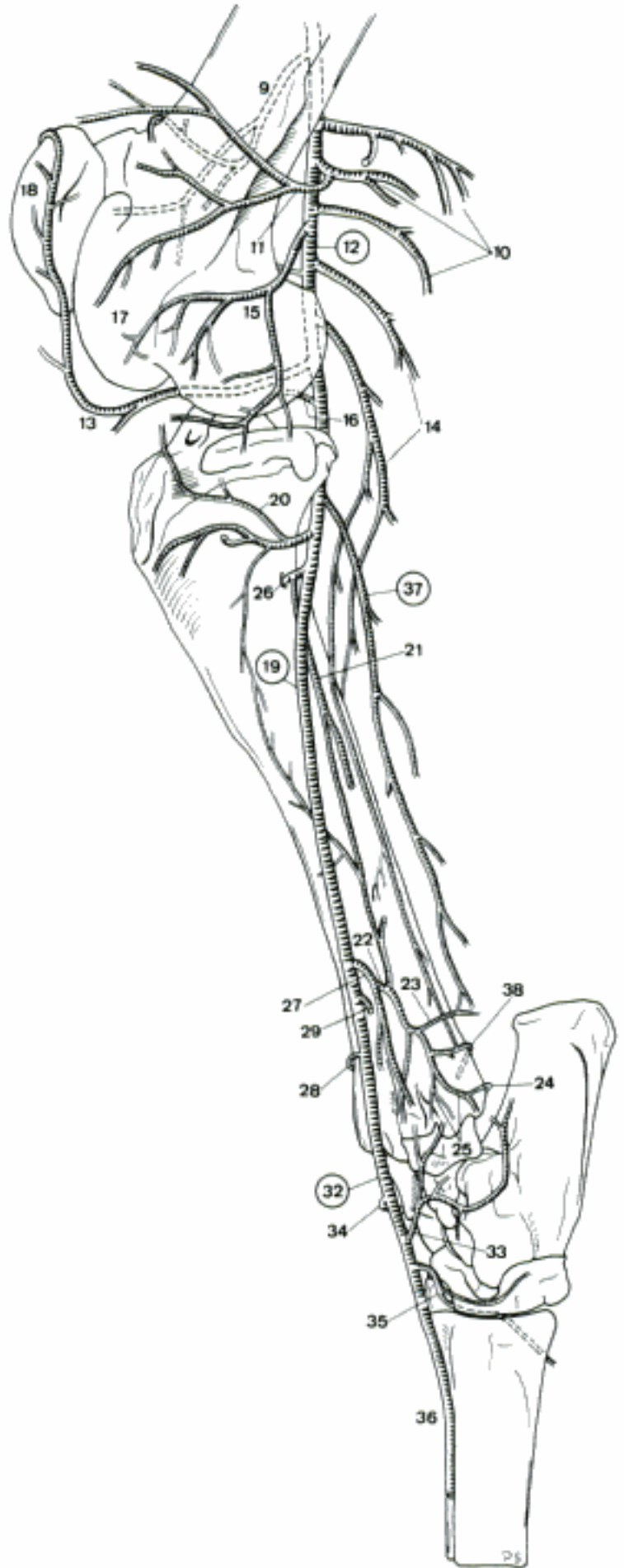
37 Ramus perforans proximalis III (bo). Small connection to A. metatarsae dorsalis III. D

38 Ramus perforans distalis III. Connects A. metatarsae plantaris III with its dorsal counterpart. B

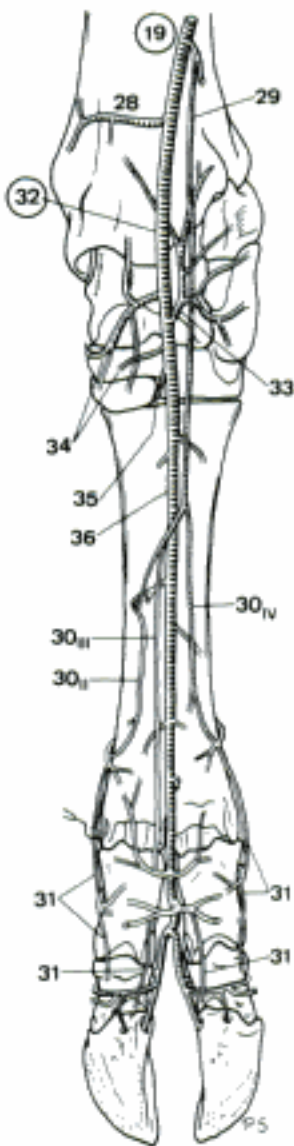
- 1 Ramus superficialis [A. digitalis plantaris communis IV]. Continuation of A. plantaris lateralis along the lateral border of the tendon of M. flexor digitorum profundus. A
- 2 A. digitalis plantaris propria IV abaxialis. Continuation of Ramus superficialis of A. plantaris lateralis. A
Ramus dorsalis phalangis proximalis. To the dorsal aspect of Phalanx proximalis IV. A
- 4 Ramus tori digitalis. Enters Torus ungulae. A
- 5 Ramus dorsalis phalangis mediae. To the dorsal aspect of Phalanx media. A
- 6 Ramus plantaris phalangis distalis. Courses axially across the plantar aspect of Phalanx distalis. A
- 7 Ramus dorsalis phalangis distalis. Courses dorsally along Facies parietalis of Phalanx distalis. A
- 8 A. digitalis plantaris propria V axialis. Branch of Ramus superficialis of A. plantaris lateralis which enters the base of the lateral dew claw. A
- 9 A. genus descendens. To the medial aspect of Articulatio genus. B
- 10 A. caudalis femoris. Supplies the musculature in the poples with proximal and distal branches. B
- 11 A. genus proximalis lateralis. Ramifies at the lateral aspect of Articulatio genus. B
- 12 **A. poplitea.** Continuation of A. femoralis. runs over the flexor surface of Articulatio femorotibialis. B
- 13 A. genus media. Courses between Ligamenta cruciata genus to the cranial aspect of Articulatio genus. B
- 14 Aa. surales. Branches for the musculature at the caudal aspect of crus. B
- 15 A. genus distalis lateralis. To the lateral side of Articulatio genus. B
- 16 A. genus distalis medialis. To the medial side of Articulatio genus. B
- 17 Rete articulare genus. Network surrounding Articulatio genus. B
- 18 Rete patellae. Network at the patella. B
- 19 **A. tibialis cranialis.** Larger terminal branch of A. poplitea along the cranio-lateral aspect of tibia. B C
- 20 A. recurrens tibialis cranialis (bo). Runs over Condylus lateralis tibiae towards Articulatio genus. B
- 21 A. interossea cruris. Runs along Margo lateralis of Corpus tibiae. B
- 22 Ramus perforans. Passes craniodistally. B
- 23 Ramus anastomoticus cum a tibiali caudali. Joins A. tibialis caudalis on the distal part of tibia. B
- 24 Rami malleolares mediales. To Malleolus medialis. B
- 25 Rami malleolares laterales. To Malleolus lateralis. B
- 26 A. nutricia tibiae. Enters Foramen nutricium of tibia. B
- 27 A. malleolaris cranialis lateralis. To Malleolus lateralis. B
- 28 A. malleolaris cranialis medialis. To Malleolus medialis. B C
- 29 Ramus superficialis. Superficial branch at the dorsal aspect of tarsus, together with N. peroneus superficialis. B C
- 30 A. digitalis dorsalis communis III (ov, cap), II-IV (bo). Continuation of Ramus superficialis of A. tibialis cranialis, III joins A. interdigitalis. C
- 31 Aa. digitales dorsales propriae. Superficial digital arteries on the dorsoaxial and dorsoabaxial (bo) aspect of digits. C
- 32 **A. dorsalis pedis.** Continuation of A. tibialis cranialis distal to Articulatio tarsocruralis. B C
- 33 A. tarsea lateralis. Ramifies at the dorso-lateral aspect of the tarsus. B C
- 34 A. tarsea medialis. Ramifies at the dorso-medial aspect of the tarsus. B C
- 35 A. tarsea perforans. Pierces between Os centroquartale and Os tarsale II et III and continues in Canalis metatarsi proximalis. Joins A. plantaris medialis (ov, cap), A. metatarsea plantaris III (bo), or Arcus plantaris profundus (bo). May be absent (bo). B C
- 36 A. metatarsea dorsalis III. Continuation of A. dorsalis pedis in Sulcus longitudinalis dorsalis of Os metatarsale III et IV. Joins A. interdigitalis III. B C
- 37 **A. tibialis caudalis.** Smaller terminal branch of A. poplitea, at the caudal aspect of tibia. B
- 38 Rami malleolares mediales (bo). To Malleolus medialis. B



A Arteries of left pes, lateral aspect (bo)



B Arteries of left crus, lateral aspect (bo)



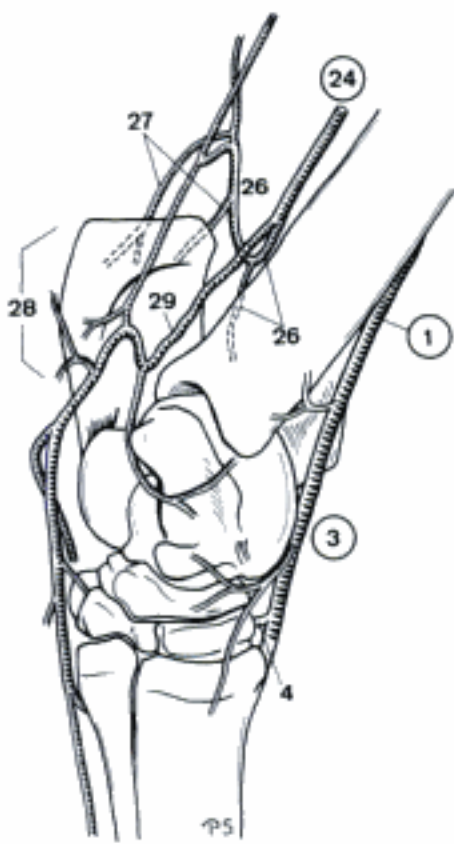
C Arteries of left pes, dorsal aspect (bo)

EQUUS

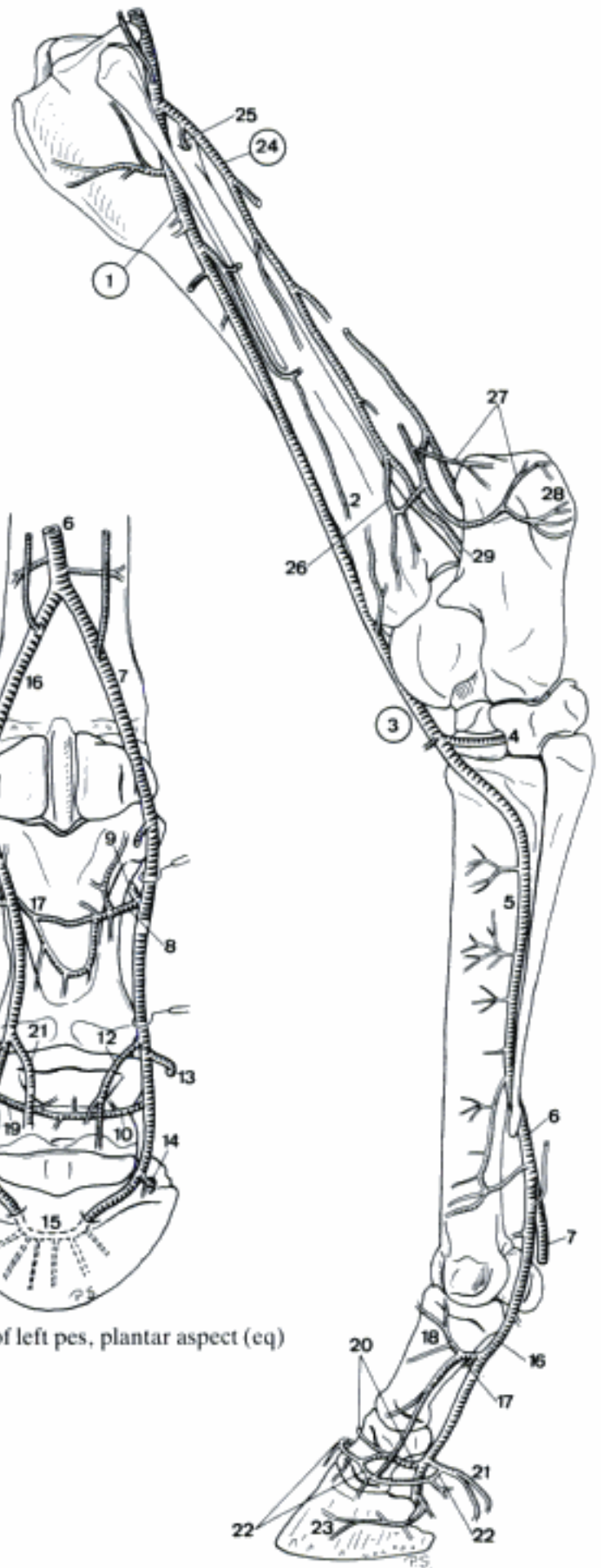
- 1 **A. femoralis.** Continuation of A. iliaca externa in Canalis femoralis. A
- 2 *A. circumflexa femoris lateralis.* Runs craniolaterally between M. rectus femoris and M. vastus medialis. A
- 3 *Ramus descendens.* Passes distally in M. quadriceps femoris. A
- 4 *A. saphena.* Leaves the distal end of Canalis femoralis medially, and pursues a caudodistally curved superficial course over the medial surface of the thigh. A
- 5 *Ramus cranialis.* Slender craniodistal branch, courses over Facies medialis of tibia. A
- 6 *Ramus caudalis.* Caudodistal continuation of A. saphena. Reinforced by a branch of A. caudalis femoris (usually), A. malleolaris caudalis lateralis (occasionally), and Ramus anastomoticus cum a. saphena of A. tibialis caudalis (usually). Continues distally over the medioplantar aspect of the tarsus to. A B
- 7 A. plantaris medialis. Courses distally along the medioplantar aspect of the tarsus. A B
- 8 Ramus profundus. Deep branch of A. plantaris medialis, pierces dorsolaterally into Arcus plantaris profundus. A B
- 9 Ramus superficialis [A. digitalis plantaris communis II]. Superficial continuation of A. plantaris medialis, courses along the medial border of the tendon of M. flexor digitorum profundus. Joins A. digitalis medialis, Ramus perforans distalis III or Ramus superficialis of A. plantaris lateralis. A B
- 10 A. plantaris lateralis. Passes laterodistally to the lateral aspect of the tendon of M. flexor digitorum profundus. A B
- 11 Arcus plantaris profundus. Connection between A. plantaris lateralis and Ramus profundus of A. plantaris medialis. Usually double, upon the dorsal and plantar surfaces of M. interosseus in the proximal part of metatarsus. B
- 12 Aa. metatarsae plantares II et III. Branches of Arcus plantaris profundus which run along the medial s. lateral border of the M. interosseus. Usually they join Ramus perforans distalis III. B
- 13 Ramus perforans distalis II. Slender branch of A. metatarsae plantaris II which courses dorsally between Ossa metatarsalia II and III, and joins the slender dorsomedial metatarsal artery. B
- 14 Ramus superficialis [A. digitalis plantaris communis III]. Superficial continuation of A. plantaris lateralis which courses along the lateral border of the tendon of M. flexor digitorum profundus. Joins A. digitalis lateralis, Ramus perforans distalis III, or Ramus superficialis of A. plantaris medialis. B
- 15 *A. genus descendens.* Courses craniodistally along the medial border of M. vastus medialis to the medial aspect of Articulatio genus. A
- 16 *A. caudalis femoris.* Large artery which supplies the musculature in the poples. A
- 17 **A. poplitea.** Continuation of A. femoralis beyond the origin of A. caudalis femoris. Runs over the flexor surface of Articulatio femorotibialis. A
- 18 *A. genus proximalis lateralis.* Runs craniolaterally to the lateral aspect of Articulatio genus. A
- 19 *A. genus proximalis medialis.* Runs craniomedially to the medial aspect of Articulatio genus. A
- 20 *A. genus media.* Runs cranially between Ligamenta cruciata genus to the cranial aspect of Articulatio genus. A
- 21 *A. genus distalis lateralis.* Courses over the medial surface of Ligamentum collaterale laterale of Articulatio femorotibialis to the lateral side of Articulatio genus. A
- 22 *A. genus distalis medialis.* Passes over the lateral surface of Ligamentum collaterale mediale of Articulatio femorotibialis to the medial side of Articulatio genus. A
- 23 *Rete articulare genus.* Network surrounding Articulatio genus. A
- 24 *Rete patellae.* Network at the patella. A

Hidden page

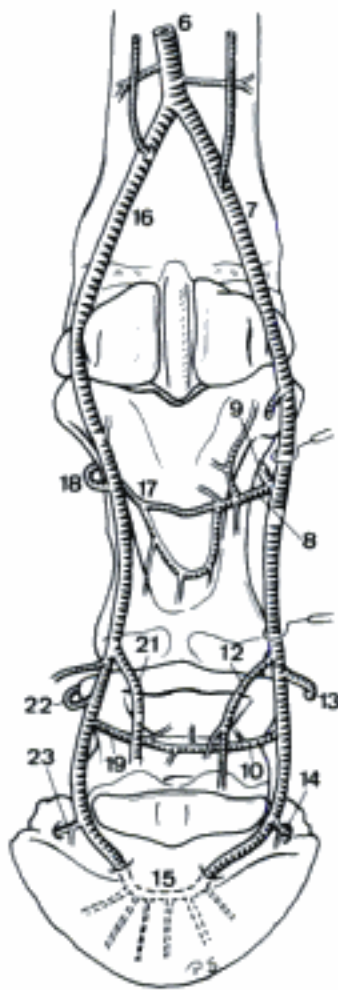
- 1 **A. tibialis cranialis.** Larger terminal branch of A. poplitea along the craniolateral aspect of tibia. A B
- 2 *Ramus superficialis.* Superficial branch, courses on the craniolateral aspect of the crus along N. peroneus superficialis. A
- 3 **A. dorsalis pedis.** Continuation of A. tibialis cranialis distal on the dorsal aspect of the tarsus. A B
- 4 *A. tarsea perforans.* Courses through Canalis tarsi, joins Arcus plantaris profundus, A. plantaris lateralis, or A. metatarsa plantaris II. A B
- 5 *A. metatarsa dorsalis III.* Continuation of A. dorsalis pedis, curves over the dorsolateral surface of Os metatarsale III, continues in the dorsal groove between Ossa metatarsalia III and IV. A
- 6 *Ramus perforans distalis.* Continuation of A. metatarsa dorsalis III, passes to the plantar surface of metatarsus by piercing between Ossa metatarsalia III and IV. A C D
- 7 A. digitalis [plantaris propria III] medialis. Medial terminal branch of Ramus perforans distalis III. Enters Foramen soleare mediale. A C D
- 8 Ramus plantaris phalangis proximalis. To the plantar aspect of Phalanx proximalis. C
- 9 Ramus dorsalis phalangis proximalis. To the dorsomedial surface of Phalanx proximalis. C D
- 10 Ramus plantaris phalangis mediae. To the plantar aspect of Phalanx media. C
- 11 Ramus dorsalis phalangis mediae. Branch of A. digitalis medialis which passes at the lateral aspect of Cartilago unguaris medialis to the dorsal surface of Phalanx media. D
- 12 Ramus tori digitalis. Ramifies in Torus unguis. C D
- 13 A. coronalis. Arises from Ramus tori digitalis or A. digitalis medialis, courses dorsally along the proximal border of Cartilago unguaris medialis. C D
- 14 Ramus dorsalis phalangis distalis. Passes through Foramen or Incisura of Processus plantaris medialis and continues dorsally in Sulcus parietalis medialis. C D
- 15 Arcus terminalis. Arch inside Canalis solearis, formed by the union of Aa. digitales medialis and lateralis. C
- 16 A. digitalis [plantaris propria III] lateralis. Lateral terminal branch of Ramus perforans distalis III. Enters Foramen soleare laterale. A C D
- 17 Ramus plantaris phalangis proximalis. To the plantar aspect of Phalanx proximalis. A C
- 18 Ramus dorsalis phalangis proximalis. Ramifies at the dorsolateral surface of Phalanx proximalis. A C
- 19 Ramus plantaris phalangis mediae. To the plantar aspect of Phalanx media. C
- 20 Ramus dorsalis phalangis mediae. Passes at the medial aspect of Cartilago unguaris lateralis to the dorsal surface of Phalanx media. A
- 21 Ramus tori digitalis. Ramifies in Torus unguis. A C
- 22 A. coronalis. Arises from Ramus tori digitalis or A. digitalis lateralis, courses along the proximal border of Cartilago unguaris lateralis. A C
- 23 Ramus dorsalis phalangis distalis. Passes through Foramen or Incisura of Processus plantaris lateralis, and continues in Sulcus parietalis lateralis. A C
- 24 **A. tibialis caudalis.** Smaller terminal branch of A. poplitea, courses at the caudal aspect of the tibia. A B
- 25 *A. nutricia tibiae.* Enters Foramen nutricium of tibia. A
- 26 *A. malleolaris caudalis lateralis.* Passes laterally between tibia and M. flexor digitorum profundus, branches to Malleolus lateralis. A B
- 27 *Rami calcanei.* To Tuber calcanei. A B
- 28 Rete calcaneum. Network at Tuber calcanei. A B
- 29 *Ramus anastomoticus cum a saphena.* Curved continuation of A. tibialis caudalis beyond the origin of A. malleolaris caudalis lateralis. Joins and reinforces Ramus caudalis of A. saphena. Exceptionally absent. A B



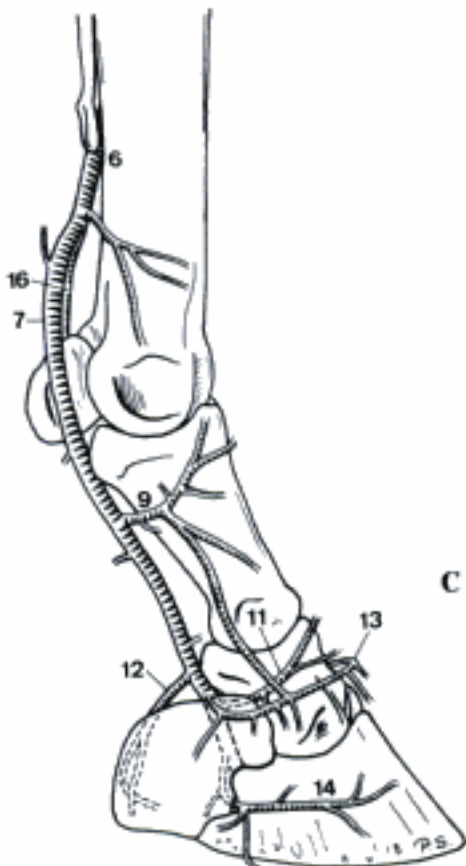
B Arteries of left tarsus, medial aspect (eq)



A Arteries of left pelvic limb, lateral aspect (eq)

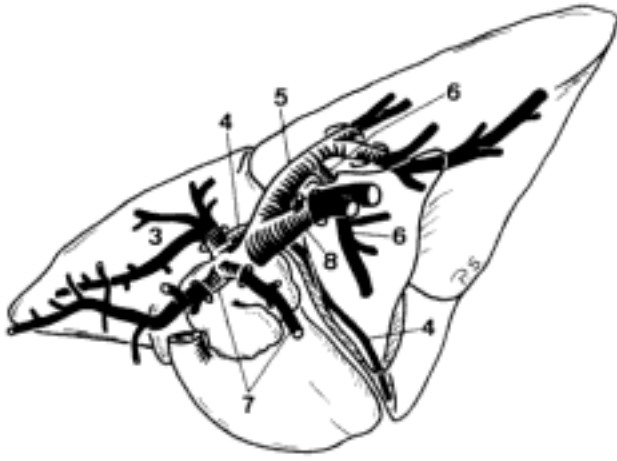


C Arteries of left pes, plantar aspect (eq)

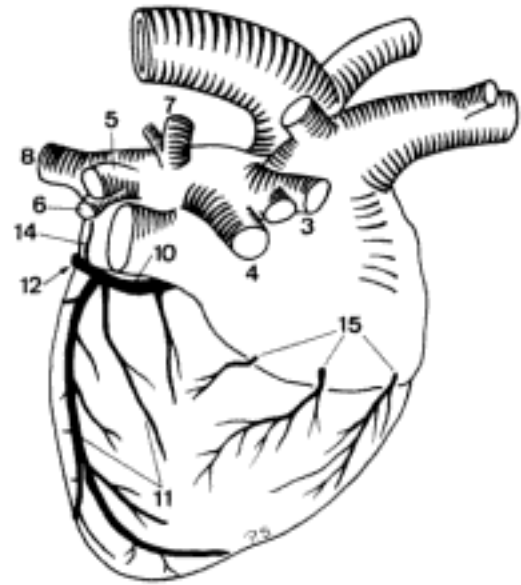


D Arteries of left pes, medial aspect (eq)

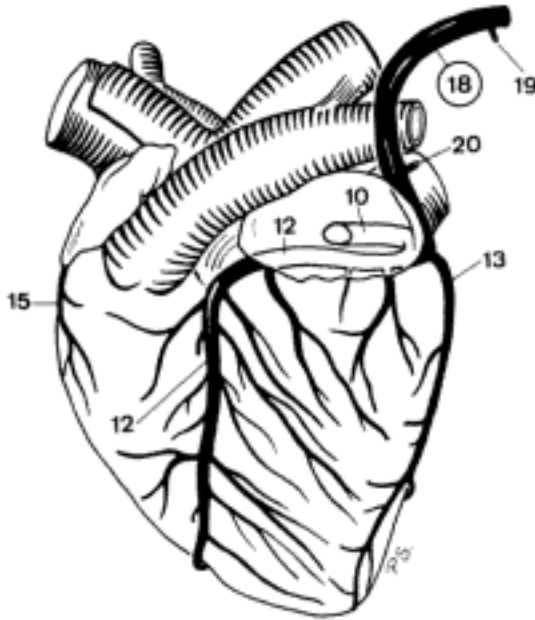
Hidden page



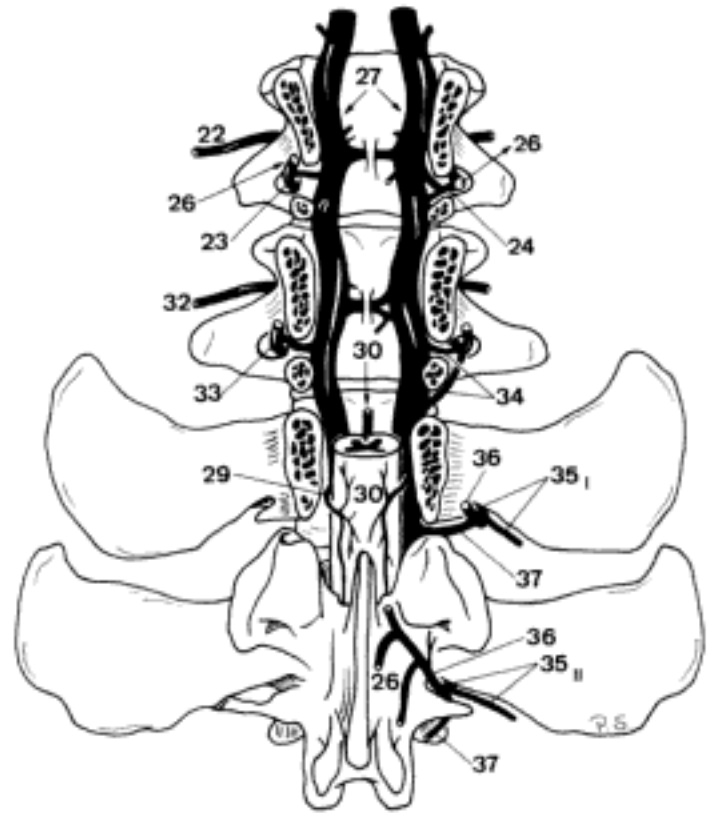
A Venae pulmonales (left lung removed) (fc)



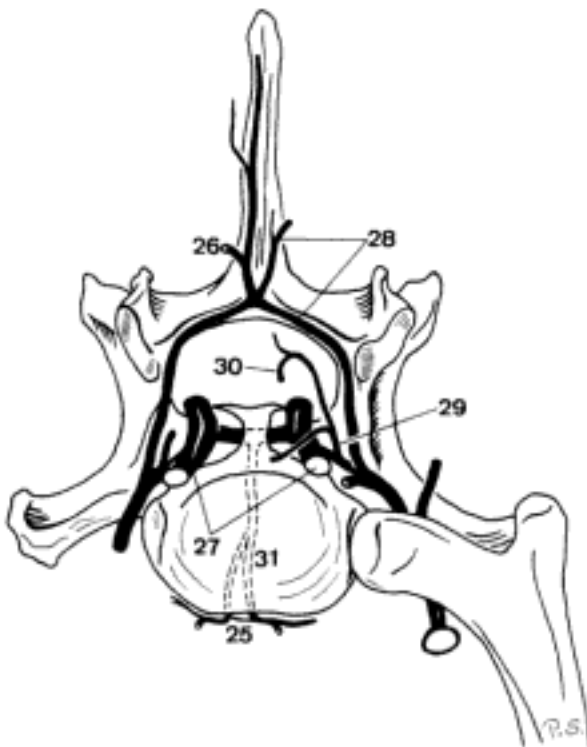
B Veins on Facies atrialis of the heart (ca)



C Veins on Facies auricularis of the heart (bo)

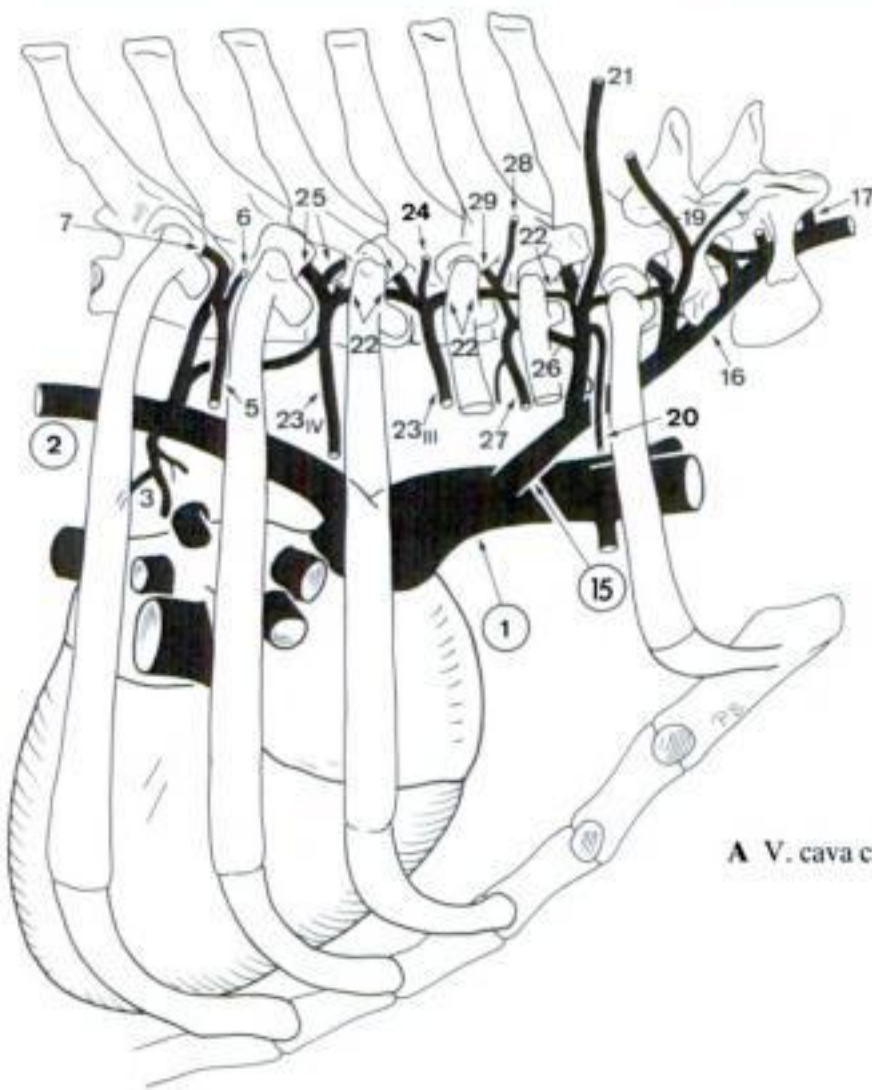


D Veins in relation to Vertebrae thoracicae and lumbales (Arcus partly removed) (su)

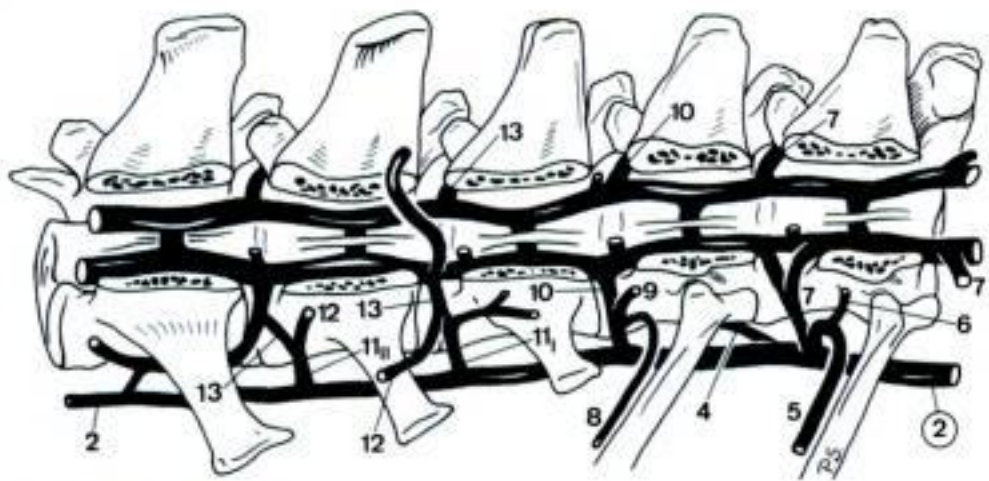


E Veins in relation to Vertebra cervicalis VII, caudal aspect (ca)

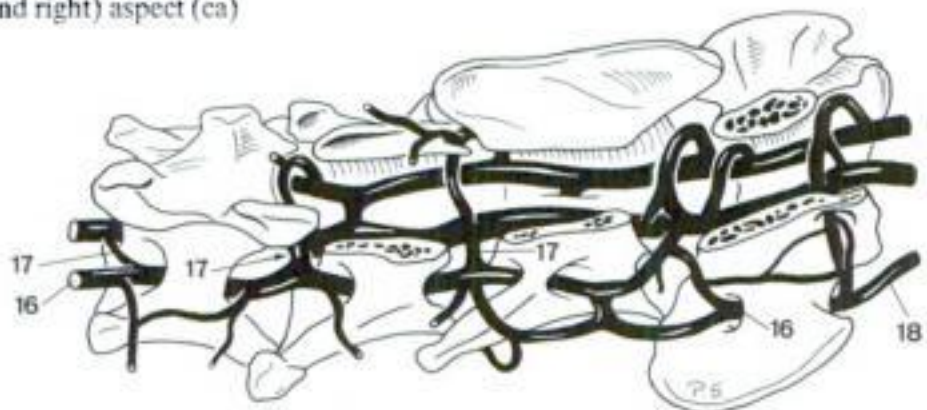
- 1 **VENA CAVA CRANIALIS.** Large unpaired vein which leaves Sinus venarum cavarum of Atrium dextrum, courses cranially in Mediastinum craniale towards Apertura thoracis cranialis. Bifurcates in the left and right Vv. brachiocephalicae (Car, su, sometime cap) or gives rise to the left and right Vv. subclaviae and Truncus bijugularis (Ru, eq). A
 - 2 **V. azygos dextra.** Occurs in Car, Ru, eq, and sometimes su. Unpaired vein, curves across the right aspect of trachea and esophagus, continues along the right-dorsal surface of Aorta thoracica. A B
 - 3 *V. broncho-esophagea [-oesophagea] (ca, eq).* Bilateral (ca) s. unpaired (eq) vein which gives rise to bronchal and esophageal branches. A
 - 4 (*V. hemiazygos sinistra*) (ca, eq). Unpaired complement or replacement of the caudal portion of V. azygos dextra. Arises from the latter vein in the caudal half on the thorax, crosses Columna vertebralis ventrally and continues along the left surface of aorta. B
 - 5 *Vv. intercostales dorsales.* Accompany corresponding arteries. A B
 - 6 *Ramus dorsalis.* To Plexus vertebralis externus dorsalis. A B
 - 7 *V. intervertebralis.* Passes through the Foramen intervertebrale, connects Plexus vertebrales externi and internus. A B
 - 8 *V. costoabdominalis dorsalis.* Accompanies corresponding artery. B
 - 9 *Ramus dorsalis.* To Plexus vertebralis externus dorsalis. B
 - 10 *V. intervertebralis.* Passes through Foramen intervertebrale, connects Plexus vertebrales externi and internus. B
 - 11 *Vv. lumbales I et II (III).* Bilateral, but often initially fused, accompany corresponding arteries. B
 - 12 *Ramus dorsalis.* To Plexus vertebralis externus dorsalis. B
 - 13 *V. intervertebralis.* Passes through Foramen intervertebrale, connects Plexus vertebrales externi and internus. B
 - 14 *V. broncho-esophagea [-oesophagea] (fe).*
 - 15 *V. costocervicalis.* V. costocervicalis sinistra originates from V. brachiocephalica sinistra in Car. A
- CARNIVORA**
- 16 *V. vertebralis.* Accompanies corresponding artery. A C
 - 17 *Vv. intervertebrales.* Pass through the Foramen intervertebrale s. Foramen vertebrale laterale of atlas and connect Plexus vertebrales externi and internus. A C
 - 18 *Ramus anastomoticus cum v. jugulari interna.* Originates in Fossa atlantis, courses across the ventrolateral surface of Articulatio atlantooccipitalis to V. jugularis interna. C
 - 19 *V. scapularis dorsalis.* Accompanies corresponding artery. A
 - 20 *V. intercostalis dorsalis I.* Accompanies corresponding artery. A
 - 21 *V. cervicalis profunda.* Accompanies corresponding artery. A
 - 22 *V. vertebralis thoracica.* Accompanies corresponding artery in ca. A
 - 23 *Vv. intercostales dorsales III et IV.* Accompany corresponding arteries. A
 - 24 *Rami dorsales.* To Plexus vertebralis externus dorsalis. A
 - 25 *V. intervertebralis.* Branch of Ramus dorsalis, passes through the Foramen intervertebrale, connects Plexus vertebrales externi and internus. A
 - 26 *V. intercostalis suprema.* Accompanies corresponding artery. May be absent in ca. A
 - 27 *V. intercostalis dorsalis II.* Accompanies corresponding artery. A
 - 28 *Ramus dorsalis.* To Plexus vertebralis externus dorsalis. A
 - 29 *V. intervertebralis.* Branch of Ramus dorsalis, passes through Foramen intervertebrale, connects Plexus vertebrales externi and internus. A



A V. cava cranialis (ca)



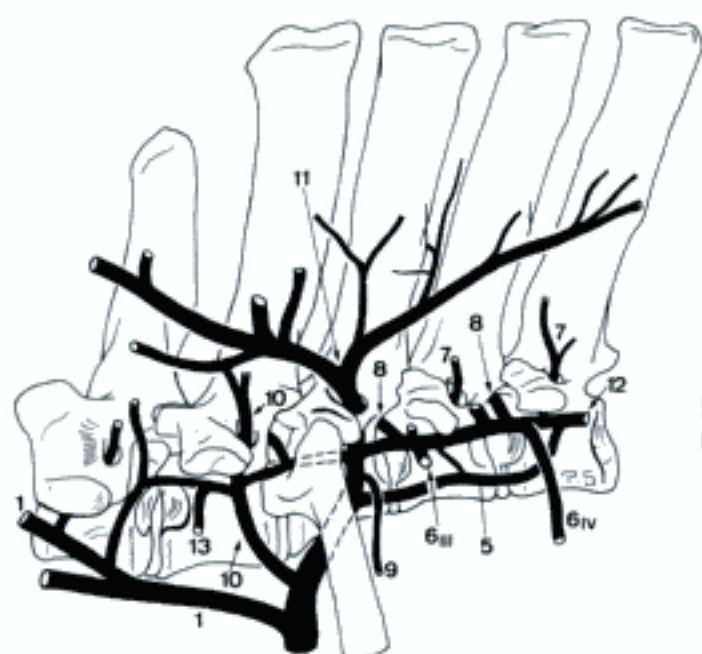B Veins in relation to Vertebrae thoracicae and lumbales (Arcus removed), dorsal (and right) aspect (ca)



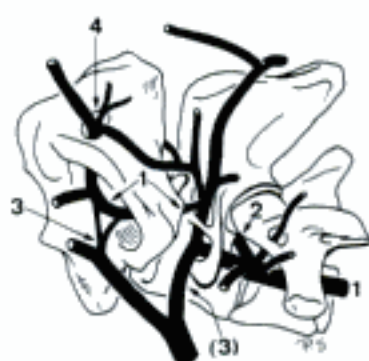C Veins in relation to Vertebrae cervicales I-IV, (Arcus partly removed), right dorsal aspect (ca)

SUS

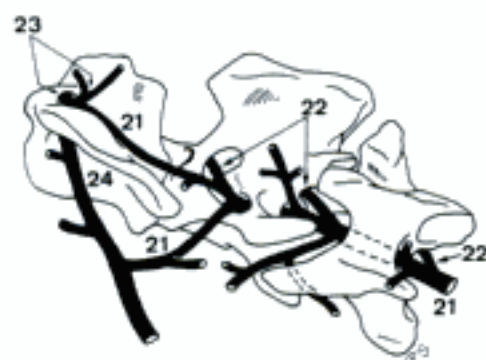
- 1 *V. vertebralis*. Accompanies corresponding artery. A B
 - 2 *Vv. intervertebrales*. Pass through Foramen intervertebrale s. Foramen vertebrale laterale of axis or atlas, connect Plexus vertebrales externi and internus. B
 - 3 *Ramus anastomoticus cum v. occipitali*. Connection to *V. occipitalis* in Fossa atlantis. Accompanied by a similar branch at the level of the axis. B
 - 4 *Ramus descendens*. Emerges dorsally from Foramen alare and joins Plexus vertebralis externus dorsalis. B
 - 5 *V. intercostalis suprema*. Accompanies corresponding artery. A
 - 6 *Vv. intercostales dorsales III et IV (V)*. Accompany corresponding arteries. A
 - 7 *Ramus dorsalis*. Courses dorsally through Foramen vertebrale laterale, joins Plexus vertebralis externus dorsalis. A
 - 8 *V. intervertebralis*. Foramen intervertebrale, connects Plexus vertebrales externi and internus. A
 - 9 *V. intercostalis dorsalis II*. Accompanies corresponding artery. A
 - 10 *V. scapularis dorsalis*. Courses through Foramen vertebrale laterale of Vertebra thoracica I and contributes to Plexus vertebralis externus dorsalis. A
 - 11 *V. cervicalis profunda*. Courses through Foramen vertebrale laterale of Vertebra thoracica II (seldom I) and ramifies in branches which contribute to Plexus vertebralis externus dorsalis. A
 - 12 *V. vertebralis thoracica*. Runs caudally upon the dorsal aspect of Colla costarum. A
 - 13 *V. intercostalis dorsalis I*. Accompanies corresponding artery. A
- RUMINANTIA
- 14 *V. intercostalis suprema*. Accompanies corresponding artery. C
 - 15 *Vv. intercostales dorsales*. Course distally in Spatium intercostale I–III (IV) at the left side and, inconstantly present, in the right Spatium intercostale I. C
 - 16 *Ramus dorsalis*. Contributes to Plexus vertebralis externus dorsalis. C
 - 17 *V. intervertebralis*. Branch of *Ramus dorsalis*, passes through Foramen intervertebrale, connects Plexus vertebrales externi and internus. C
 - 18 *V. scapularis dorsalis*. Accompanies corresponding artery. C
 - 19 *V. cervicalis profunda*. Accompanies corresponding artery. C
 - 20 *V. vertebralis thoracica*. Courses caudally over the dorsal surface of Colla costarum. Inconstant in ov and cap. C
 - 21 *V. vertebralis*. Accompanies corresponding artery. C
 - 22 *Vv. intervertebrales*. Enter Foramen intervertebrale s. Foramen vertebrale laterale of axis, connect Plexus vertebrales externi and internus. D
 - 23 *Ramus descendens*. Branch of the intravertebral segment of *V. vertebralis*, leaves Canalis vertebralis through Foramen vertebrale laterale of atlas, and joins Plexus vertebralis externus dorsalis. D
 - 24 *Ramus anastomoticus cum v. occipitali*. Passes through Foramen alare of atlas, joins *V. occipitalis*. D
- EQUUS
- 25 *V. cervicalis profunda*. Accompanies corresponding artery. E
 - 26 *V. intercostalis dorsalis I*. Accompanies corresponding artery. E
 - 27 *V. intercostalis suprema*. Accompanies corresponding artery. E
 - 28 *Vv. intercostales dorsales II–VI (sin), II–IV (dext)*. Accompany corresponding artery. E
 - 29 *Ramus dorsalis*. Contributes to Plexus vertebralis externus dorsalis. E
 - 30 *V. intervertebralis*. Branch of *Ramus dorsalis*, enters Foramen intervertebrale, connects Plexus vertebrales externi and internus. E
 - 31 *V. scapularis dorsalis*. Contributes to Plexus vertebralis externus dorsalis. E
 - 32 *V. vertebralis*. Accompanies corresponding artery. E F
 - 33 *Vv. intervertebrales*. Pass through Foramen intervertebrale s. Foramen vertebrale laterale of axis s. atlas, connect Plexus vertebrales externi and internus. F
 - 34 *Ramus anastomoticus cum v. occipitali*. Connection to *V. occipitalis* in Fossa atlantis. A similar anastomosis may arise at the level of the axis. F
 - 35 *Ramus descendens*. Emerges dorsally from Foramen alare and ramifies. F



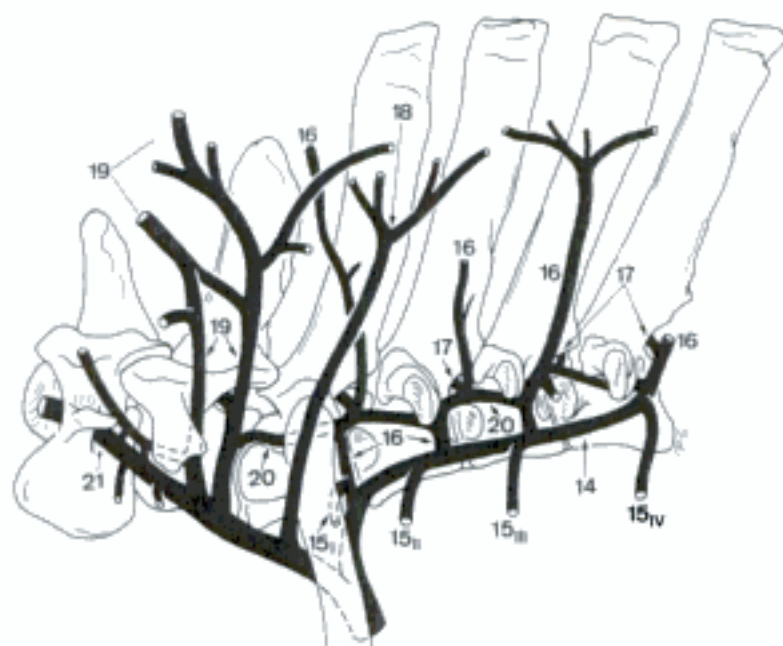A Veins in relation to Vertebrae cervicalis VII–thoracica IV (su)



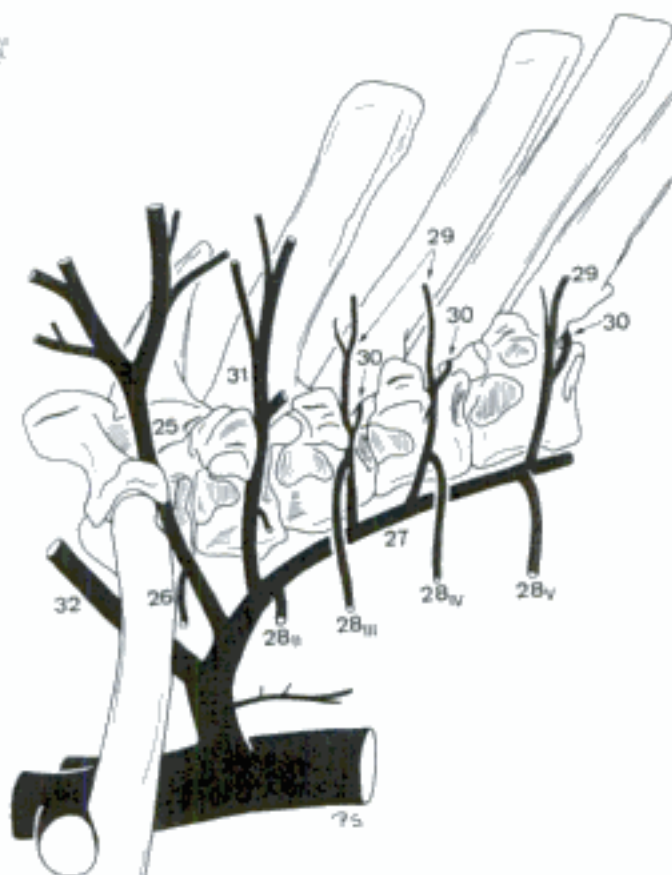
B Veins in relation to Vertebrae cervicales I–III (su)



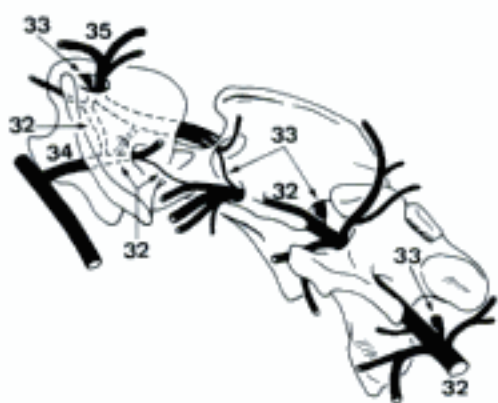
D Veins in relation to Vertebrae cervicales I–III (bo)



C Veins in relation to Vertebrae cervicalis VI–thoracica IV (bo)

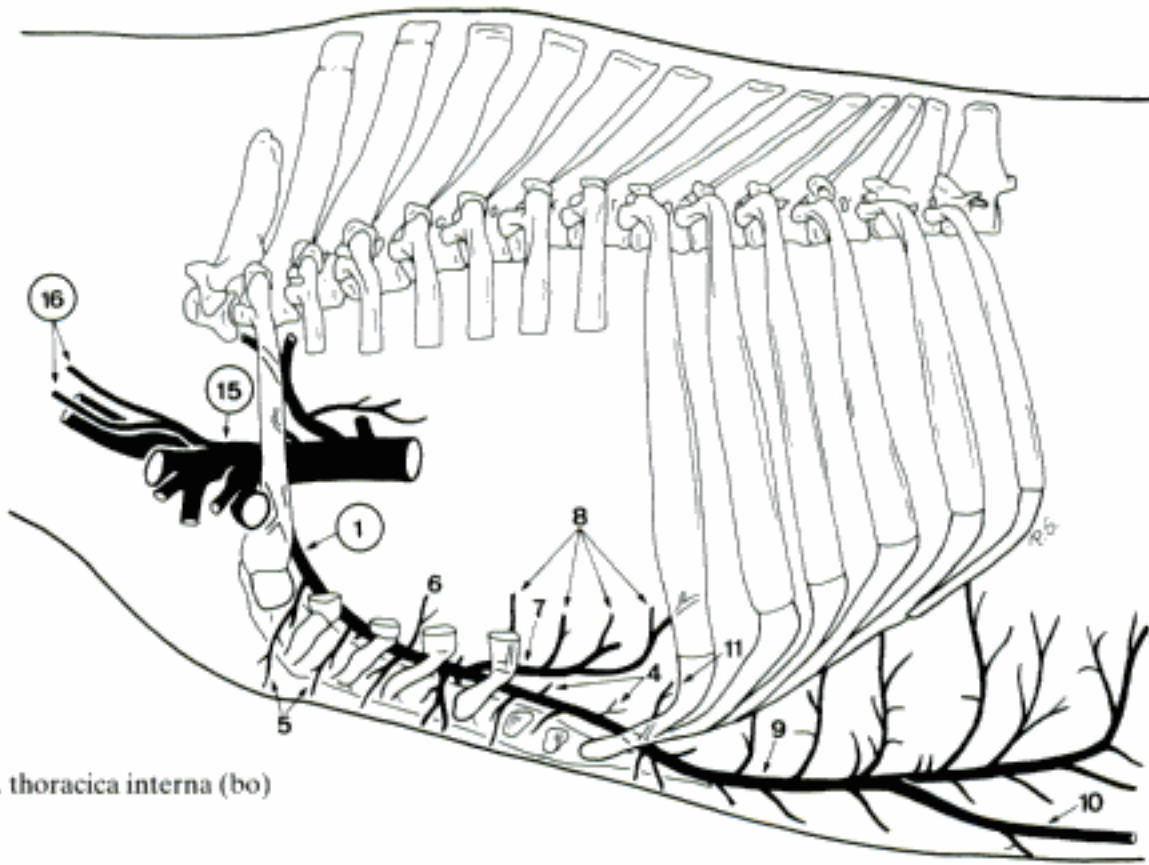


E Veins in relation to Vertebrae thoracicae I–V (eq)

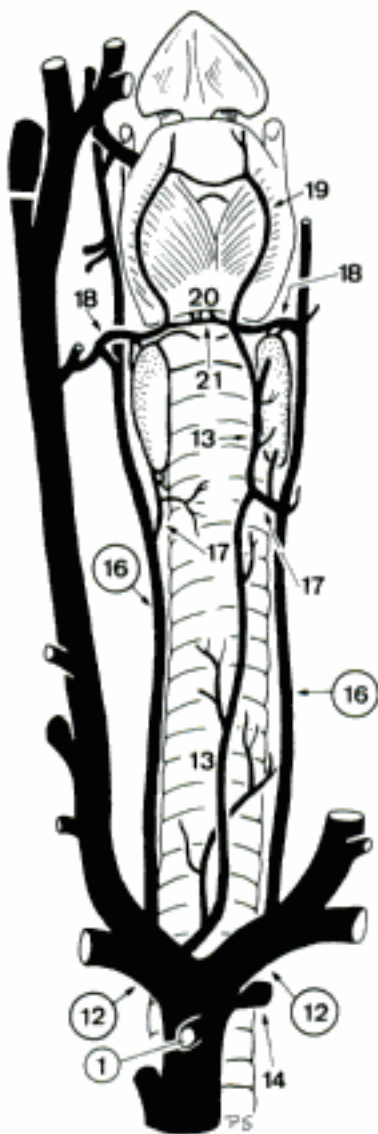


F Veins in relation to Vertebrae cervicales I–III (eq)

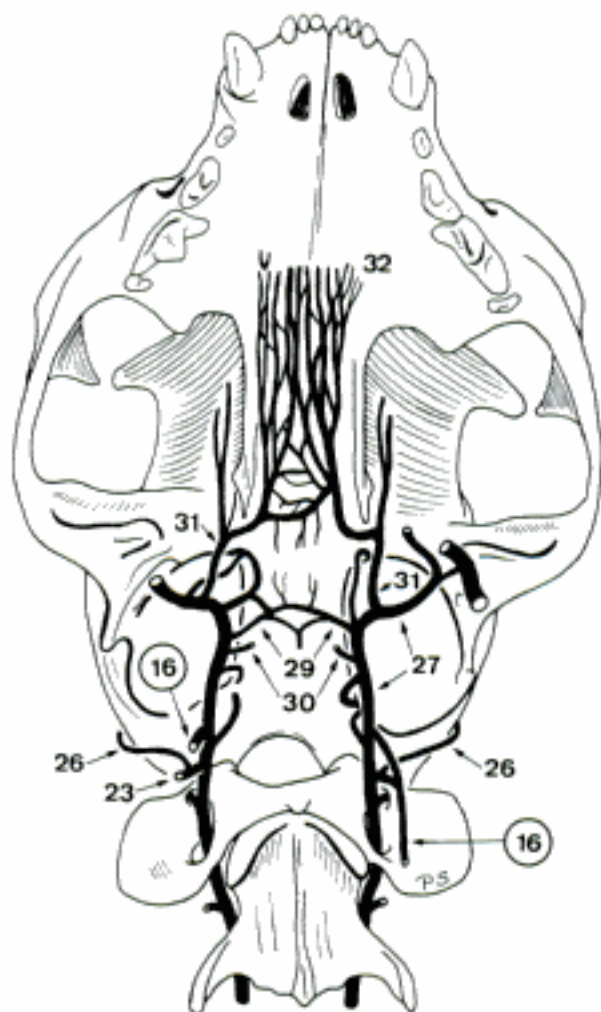
Hidden page



A *V. thoracica interna* (bo)

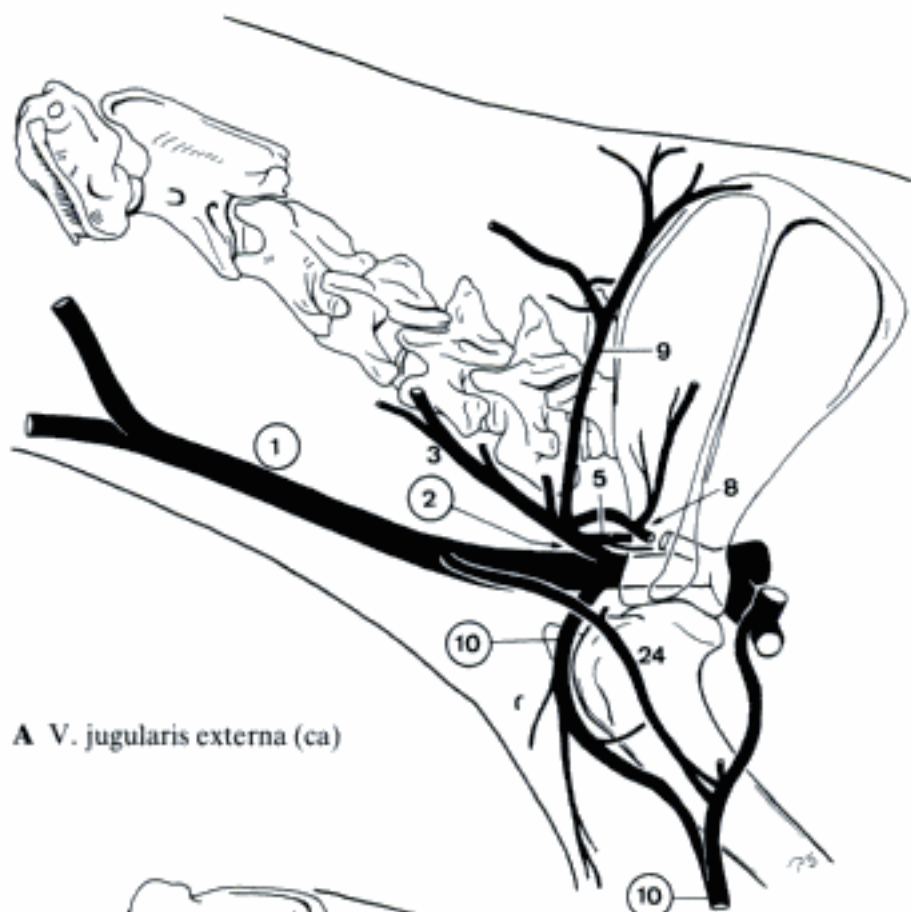


B Veins of larynx and trachea, ventral aspect (ca)

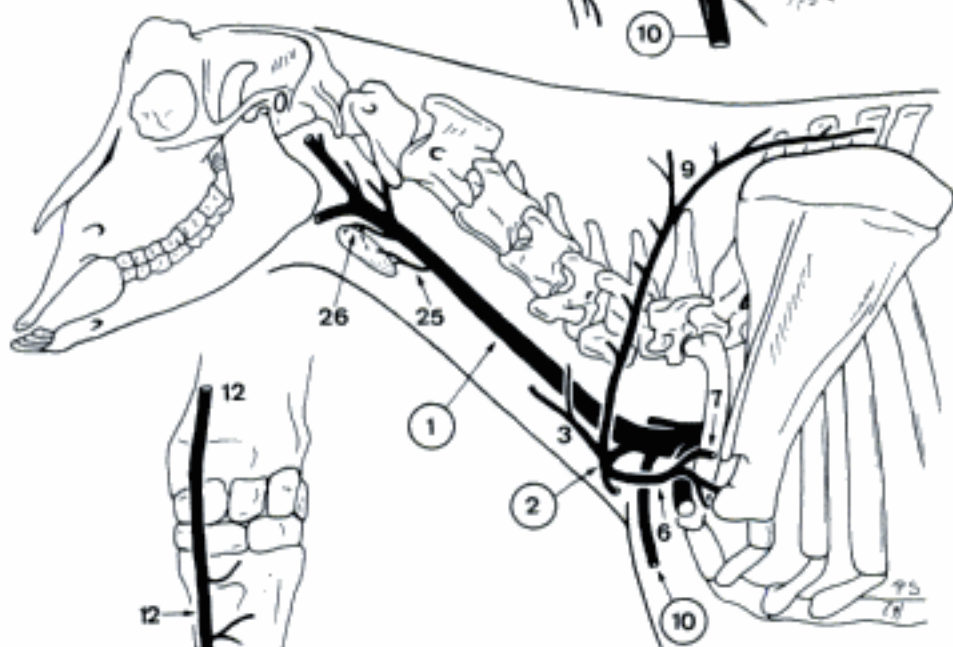


C *V. jugularis interna* (Mandibula removed), ventral aspect (fe)

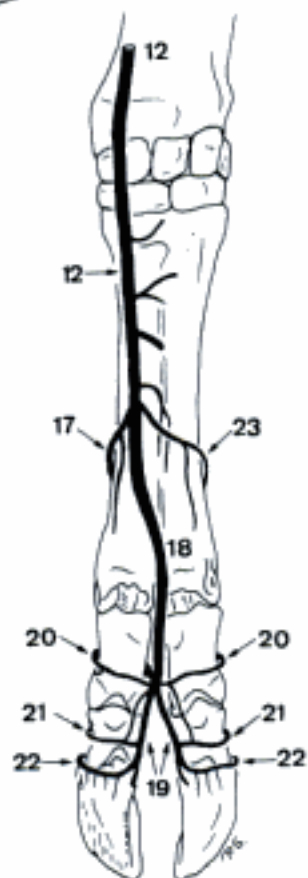
- 1 **V. JUGULARIS EXTERNA.** Superficial and principal vein of the neck, arises from V. brachiocephalica in Car (su, cap), V. cava cranialis (ov), or Truncus bijugularis in Un (except sometimes su, ov, cap), courses in Sulcus jugularis and bifurcates into V. linguofacialis and V. maxillaris. A B
 - 2 **V. cervicalis superficialis.** Accompanies corresponding artery. A B
 - 3 *Ramus ascendens.* Accompanies corresponding artery. A B
 - 4 *Ramus auricularis (su).* Anastomoses with V. auricularis caudalis.
 - 5 *V. suprascapularis (Car).* Accompanies N. suprascapularis. A
 - 6 *Ramus suprascapularis (Ru).* Accompanies corresponding artery. B
 - 7 *Ramus acromialis.* Accompanies corresponding artery. B
 - 8 *Ramus acromialis (Car, su).* Accompanies corresponding artery. A
 - 9 *Ramus prescapularis [prae-].* Accompanies corresponding artery. A B
 - 10 **V. cephalica.** Branch of V. jugularis externa (ca, Un), V. cervicalis superficialis (fe), courses in Sulcus pectoralis lateralis (and caudomedial to M. brachiocephalicus in ca). Continues superficially along the medial border of M. extensor carpi radialis. Ends at the medioplantar aspect of carpus by joining V. radialis. A B D
 - 11 *V. mediana cubiti.* Caudodistal (Car, su, Ru) or caudoproximal (eq) connection to V. brachialis, V. mediana (bo, cap) and/or V. brachialis superficialis (Car) at the cranial aspect of Regio cubiti. D
 - 12 *V. cephalica accessoria.* Subcutaneous branch, arising halfway Regio brachialis (su: first root), in the proximal (eq), lower middle (Car) or distal (su: second root, Ru) segment of antebrachium. Courses over the dorsomedial aspect of carpus and metacarpus. C D
- CARNIVORA, SUS
- 13 *Ramus carpeus dorsalis (Car.)* Branch to the Rete carpi dorsale, often plural. D
 - 14 *Vv. digitales dorsales communes I-IV (Car), II-IV (su).* Run over the superficial surface of the digital extensor tendons towards the lateral aspect of the corresponding Articulatio metacarpophalangea, where they bifurcate. D
 - 15 *Vv. digitales dorsales propriae.* Three (su) s. four (Car) pairs of dorsal veins, arising from the bifurcation of Vv. digitales dorsales communes. D
 - 16 *V. digitalis dorsalis V abaxialis (ca).* Accompanies corresponding artery. D
- RUMINANTIA
- 17 *V. digitalis dorsalis communis II.* Courses mediolaterally across the middle segment of metacarpus and joins Arcus palmaris profundus distalis or V. digitalis palmaris communis II (bo). C
 - 18 *V. digitalis dorsalis communis III.* Continuation of V. cephalica accessoria. C
 - 19 *Vv. digitales dorsales propriae.* Pair of superficial dorsal axial veins, course along tendons of M. extensor digitorum communis. C
 - 20 *Ramus dorsalis phalangis proximalis.* Branch of V. digitalis dorsalis communis III (bo), courses abaxially across the dorsal surface of Phalanx proximalis. C
 - 21 *Ramus dorsalis phalangis mediae.* Branch of V. digitalis dorsalis propria, courses abaxially across the dorsal surface of Phalanx media. C
 - 22 *V. coronalis.* Superficial branch of V. digitalis dorsalis propria, courses abaxially in Sulcus coronalis of Ungula. C
 - 23 *V. digitalis dorsalis communis IV.* Inconstant, courses laterodistally across the middle segment of metacarpus, joins Arcus palmaris profundus distalis or V. digitalis palmaris communis IV (bo). C
- TERMINI COMMUNES
- 24 **V. omobrachialis (ca).** Courses caudodistally across the lateral surface of M. brachiocephalicus and M. deltoideus, joins V. axillobrachialis. A
 - 25 **V. thyroidea [thyreoidea] media (ov, cap).** Courses cranially to the caudal pole of Gl. thyroidea where it ramifies. B
 - 26 **V. thyroidea [thyreoidea] cranialis (ov, cap).** Ramifies at the rostral pole of Gl. thyroidea. B



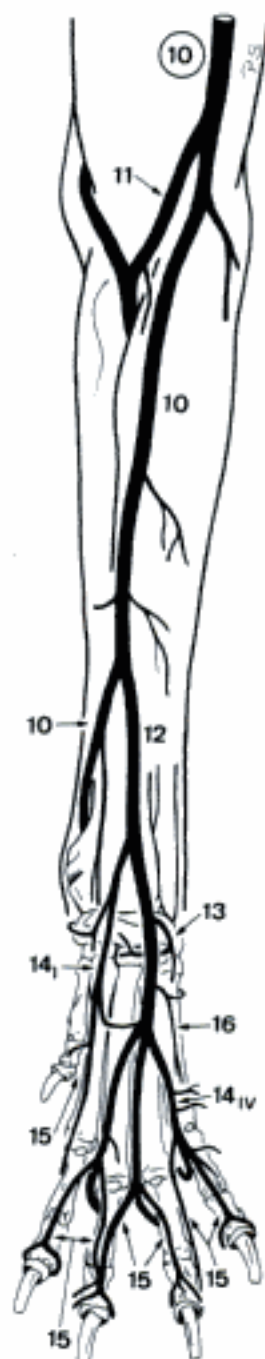
A V. jugularis externa (ca)



B V. jugularis externa (cap)

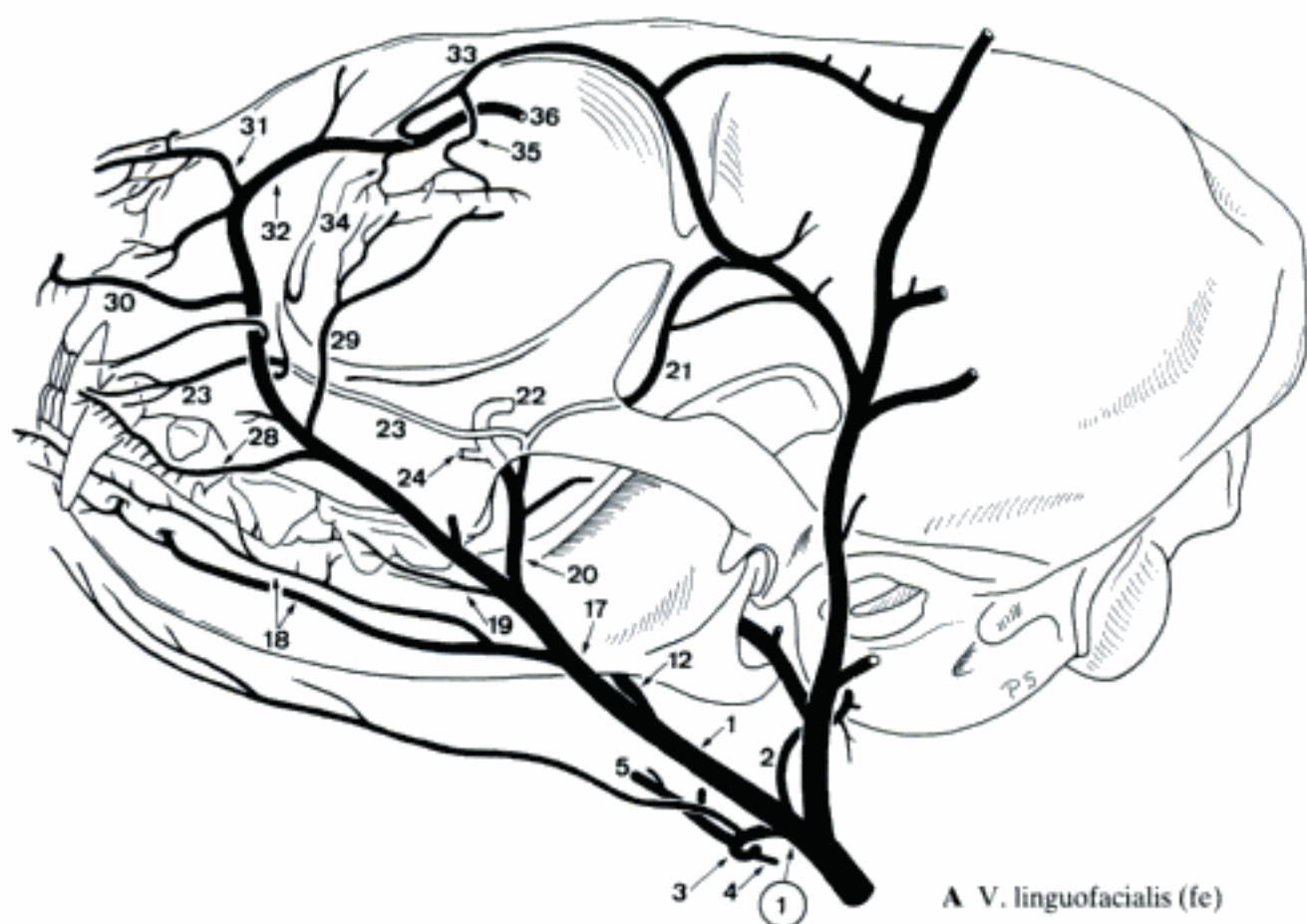


C Left V. cephalica accessoria, dorsal aspect (bo)

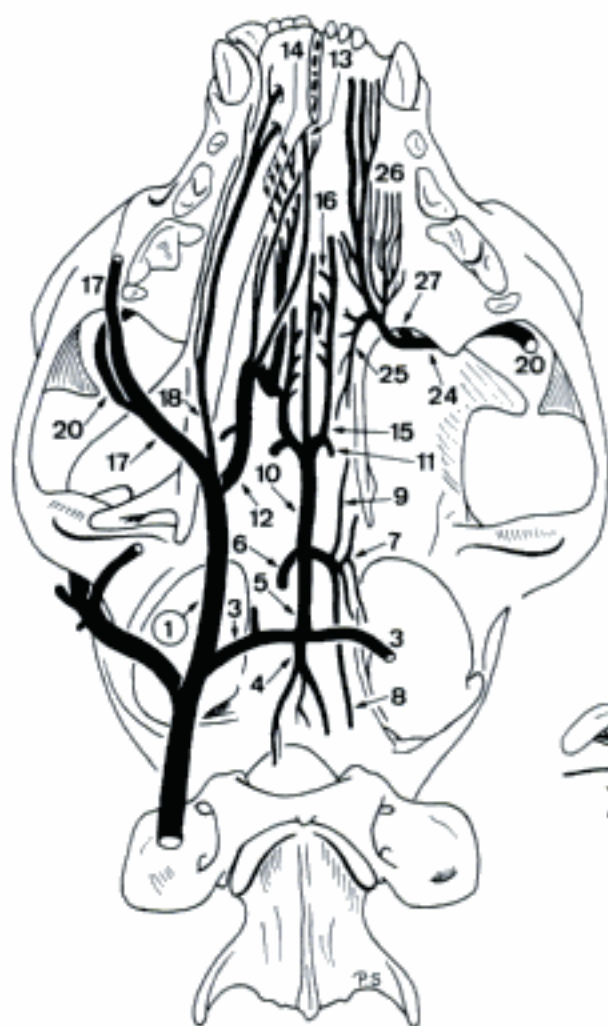

D Left V. cephalica, cranial aspect (ca)

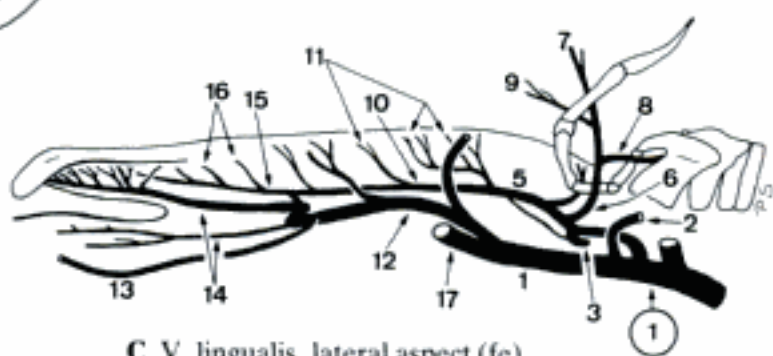
Hidden page



A V. linguofacialis (fe)



B V. linguofacialis (right) and V. palatina descendens (left), ventral aspect (fe)



C V. lingualis, lateral aspect (fe)

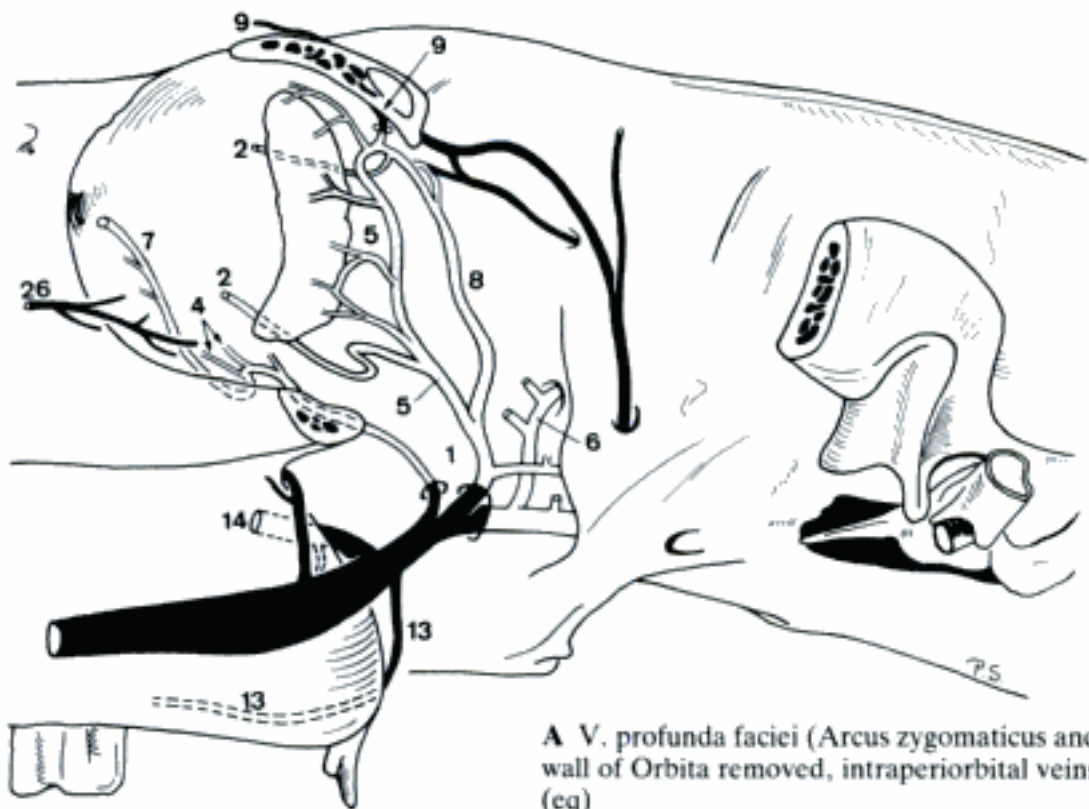
- CANIS
- 1 *V. lingualis*. Into the tongue. A B C D
 - 2 *V. glandularis*. To Gl. mandibularis. A
 - 3 *V. pharyngea ascendens*. To the pharyngeal wall. A B C
 - 4 Plexus pharyngeus. Network in the pharyngeal wall. A B
 - 5 *V. laryngea cranialis*. Enters larynx through Fissura thyroidea. A B C
 - 6 *V. palatina ascendens*. Joins Plexus palatinus. A B C
 - 7 *Arcus hyoideus*. Connection of both Vv. linguales. Often (partly) double or plural. A B C
 - 8 *V. laryngea impar*. Unpaired. B C
 - 9 Ramus submentalis. Variably developed unpaired branch, courses over the ventral aspect of Mm. mylohyoidei. A B C
 - 10 *V. sublingualis*. To the floor of the mouth. A B C
 - 11 *V. superficialis ventralis linguae*. Ramifies in the ventral mucosa of Apex linguae. B
 - 12 *V. profunda linguae*. Accompanies corresponding artery. B C
 - 13 *Arcus hyoideus profundus*. Arch between the initial segments of the Vv. profundae linguae, deep in the tongue. B C
 - 14 Vv. dorsales linguae. Ramify at Dorsum linguae. B C
 - 15 *V. facialis*. Runs over the lateral surface of Mandibula and over Facies towards Angulus oculi medialis. A C D
 - 16 *V. submentalis*. Courses along the ventromedial border of Corpus mandibulae. A C
 - 17 *V. labialis inferior*. Passes into Labium inferius. A C
 - 18 *V. angularis oris*. Runs to Angulus oris. A
 - 19 *V. profunda faciei*. Courses dorsomedially to the medial aspect of Processus temporalis of Os zygomaticum. A D
 - 20 Ramus anastomoticus cum v. temporali superficiali. To V. temporalis superficialis. A D
 - 21 Rami glandulares zygomatici. Branches of Ramus anastomoticus cum v. temporali superficiali or V. profunda faciei, supply Gl. zygomatica. A
 - 22 Rami dentales. Arise from Ramus anastomoticus cum v. temporali superficiali, usually by one common trunk. Pierce through small openings in Tuber maxillae to the upper Dentes molares. A D
 - 23 Ramus anastomoticus cum v. ophthalmica externa ventrali. Courses dorsomedially and pierces periorbita, joins V. ophthalmica externa ventralis. A D
 - 24 *V. infraorbitalis*. Accompanies corresponding artery. A D
 - 25 *V. malaris*. Branch of V. infraorbitalis or Ramus anastomoticus cum v. ophthalmica externa ventrali to the ventromedial border of Orbita. A
 - 26 *V. palatina descendens*. Ramifies in Fossa pterygopalatina. A D
 - 27 *V. palatina minor*. To Palatum molle. A D
 - 28 *V. palatina major*. Joins Plexus palatinus. A D
 - 29 *V. sphenopalatina*. Accompanies corresponding artery. A D
 - 30 *V. labialis superior*. Accompanies corresponding artery. A D
 - 31 *V. palpebralis inferior*. To Palpebra inferior. A D
 - 32 *V. lateralis nasi*. To Regio lateralis nasi. A D
 - 33 *V. dorsalis nasi*. To Dorsum nasi. A D
 - 34 *V. angularis oculi*. Continuation of V. facialis across the dorsomedial border of Orbita. A D
 - 35 Ramus anastomoticus cum v. ophthalmica externa dorsali. Pierces periorbita, continues as V. ophthalmica externa dorsalis. A D
 - 36 *V. palpebralis superior medialis*. Ramifies in Palpebra superior. A

Hidden page

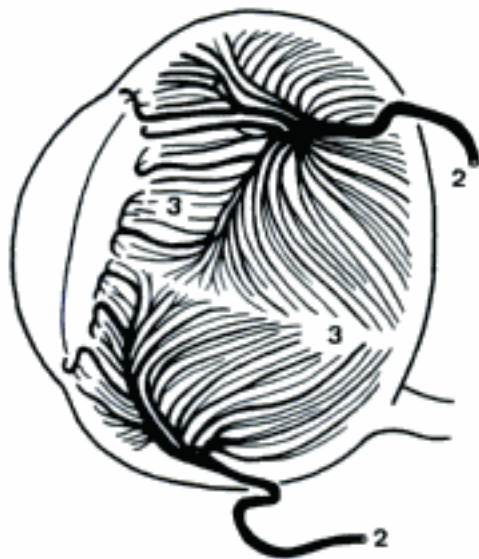Hidden page

Hidden page

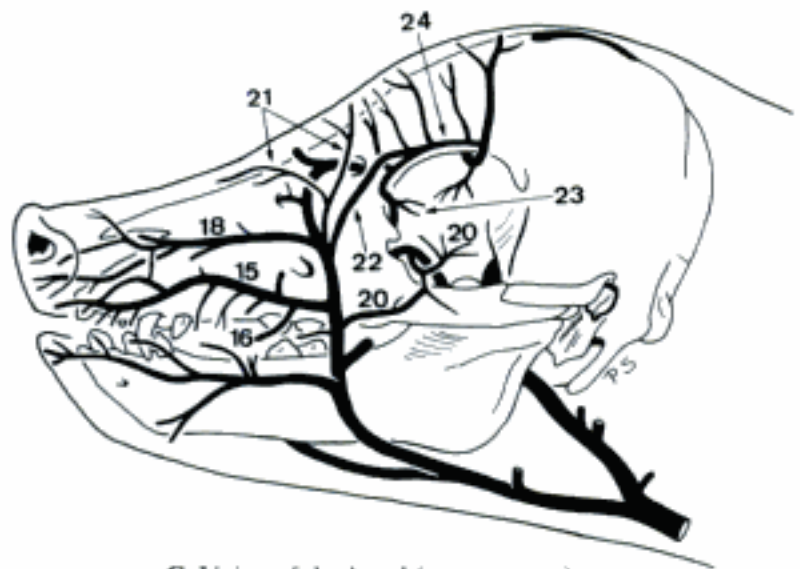
- 1 Sinus ophthalmicus (su), Plexus ophthalmicus (eq). Venous enlargement, resp. network in Orbita. A
- 2 Vv. vorticosae. Four veins which ramify in choroidea. A B
- 3 Vv. ciliares. Anterior branches of Vv. vorticosae to Corpus ciliare. B
- 4 Vv. conjunctivales. To Tunica conjunctiva. A
- 5 V. lacrimalis. To Gl. lacrimalis. A
- 6 V. ethmoidalis externa. Enters Foramen ethmoidale. A
- 7 V. malaris. Arises from Plexus ophthalmicus (eq), V. ophthalmica externa ventralis (su), courses to Angulus oculi medialis. A
- 8 V. ophthalmica externa dorsalis. Courses between M. obliquus dorsalis and M. levator palpebrae superioris. A
- 9 V. supraorbitalis. Lies dorsomedially in the Orbita, leaves through Foramen supraorbitale. Anastomoses with V. facialis in su. A
- 10 V. infraorbitalis. Passes through Canalis infraorbitalis. Originates from V. palatina descendens in Ru. 353 A B
- 11 V. palatina descendens. Continuation of V. profunda faciei in Fossa pterygopalatina. D
- 12 V. palatina minor. Inconstant branch to Palatum molle.
- 13 V. palatina major. Branch of V. palatina descendens, curves over Facies pterygopalatina of Corpus maxillae (su, bo, eq) or through Canalis palatinus major (ov, cap) to Palatum durum. A
- 14 V. sphenopalatina. Branch of V. palatina descendens, enters Cavum nasi through Foramen sphenopalatinum. A
- 15 V. labialis superior (su). Into Labium superius. C
- 16 V. angularis oris. To Angulus oris. Complemented by one or two branches of V. labialis inferior. C
- 17 Vv. labiales superiores (Ru). Superficial and deep veins into Labium superius. D
- 18 V. lateralis nasi. Variably developed vein in Regio lateralis nasi. C D
- 19 Vv. dorsales nasi (Ru). Variable branches in Regio dorsalis nasi. D
- 20 V. palpebralis inferior medialis (su, Ru). Enters the medial part of Palpebra inferior. Arises usually from V. angularis oculi in bo. C D
- 21 V. dorsalis nasi (su, eq). Ramifies in Regio dorsalis nasi. C
- 22 V. angularis oculi. Continuation of V. facialis along Angulus oculi medialis. C D
- 23 V. palpebralis superior medialis. To the medial part of Palpebra superior. C D
- 24 Ramus anastomoticus cum v. ophthalmica externa dorsali (su). Anastomoses with V. ophthalmica externa dorsalis. C
- 25 V. frontalis [supratrochlearis] (Ru). Courses along Margo supraorbitalis, ramifies in Regio frontalis. D
- 26 V. palpebralis inferior medialis (eq). To the medial part of Palpebra inferior. A



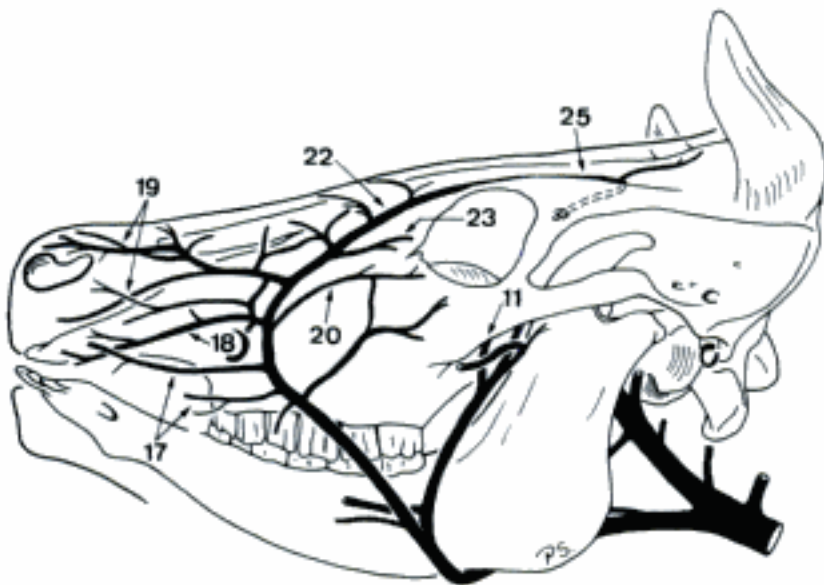
A V. profunda faciei (Arcus zygomaticus and lateral wall of Orbita removed, intraperiorbital veins white) (eq)



B Veins of the left eyeball, lateral aspect (eq)

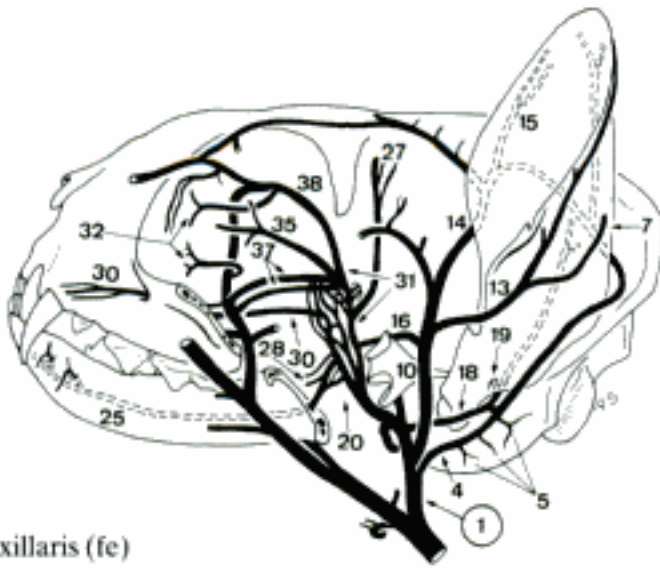


C Veins of the head (su, neonate)

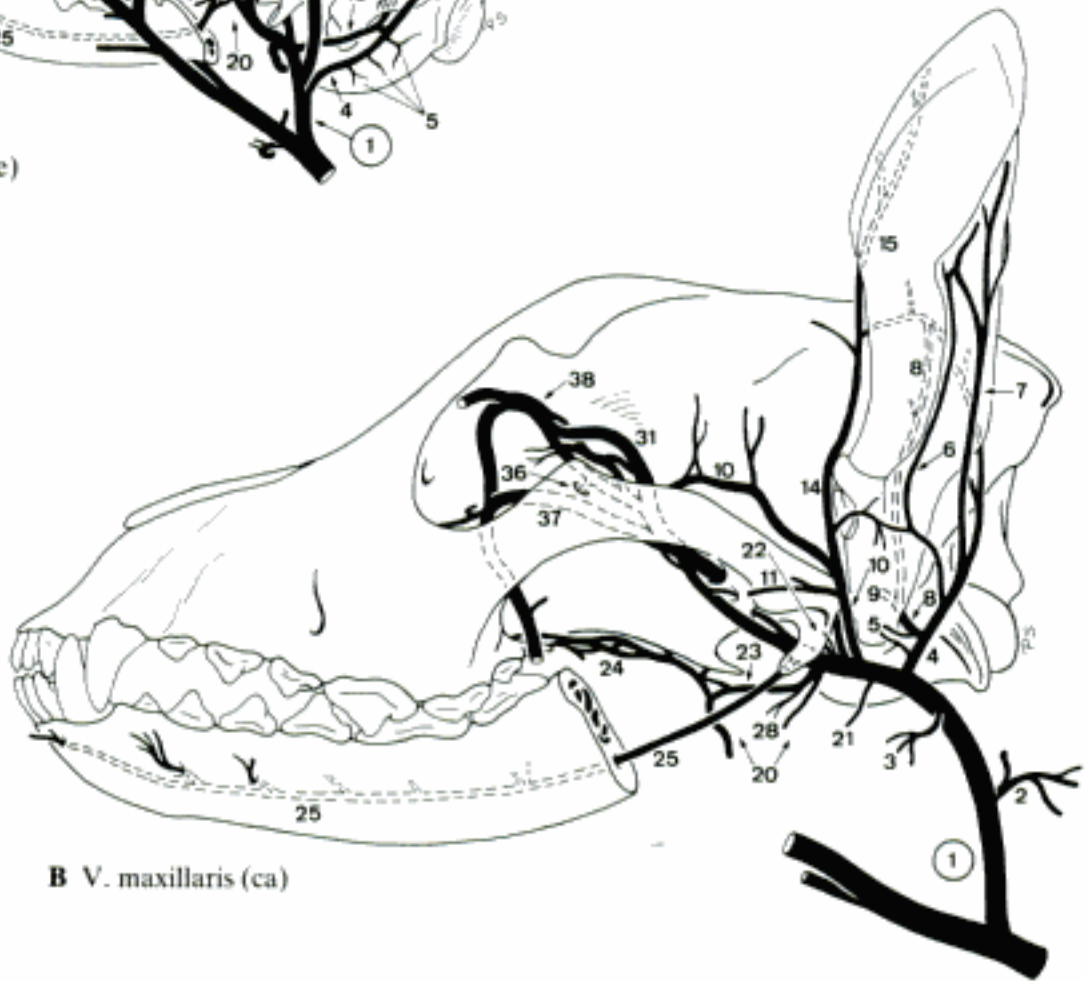

D V. facialis (bo)

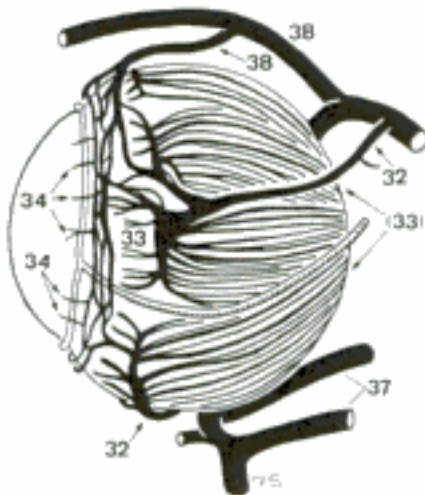
Hidden page



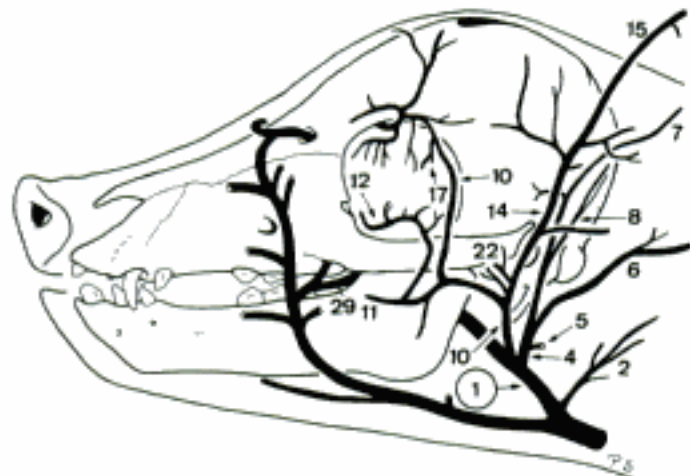
A *V. maxillaris* (fe)



B *V. maxillaris* (ca)



C Veins of the left eyeball, lateral aspect (fe)



D *V. maxillaris*, lateral aspect (su, neonate)

RUMINANTIA

- 1 *V. auricularis caudalis*. Passes towards the base of the ear. A
- 2 *Vv. glandulares*. To Gl. parotis (Ru) and Gl. mandibularis (bo). A
- 3 *V. stylomastoidea*. Enters Foramen stylomastoideum. A
- 4 *V. auricularis lateralis*. On Dorsum auriculae along Margo antitragicus. A
- 5 *V. auricularis intermedia*. In the middle of Dorsum auriculae. A
- 6 *V. auricularis profunda*. Ramifies in muscular branches. A
- 7 *V. masseterica ventralis*. Into M. masseter. A B
- 8 *V. temporalis superficialis*. Runs across the Arcus zygomaticus into M. temporalis. A B
- 9 *V. auricularis rostralis*. Runs over Cartilago scutiformis to Regio occipitalis. A
- 10 *V. auricularis medialis*. On Dorsum auriculae along Margo tragicus. A
- 11 *V. transversa faciei*. Accompanies corresponding artery. A
- 12 *V. palpebralis inferior lateralis*. To the lateral part of Palpebra inferior. Replaced or accompanied by a branch of *V. masseterica* (bo). A
- 13 *V. palpebralis superior lateralis*. Enters Palpebra superior laterally. A
- 14 *V. cornualis*. Along Linea temporalis to Basis cornus. A
- 15 *V. ophthalmica externa dorsalis*. Perforates periorbita, continues along the dorsal border of M. rectus lateralis. A B
- 16 Plexus ophthalmicus. Network inside periorbita. B
- 17 *Vv. vorticosae*. Four veins which arise from Plexus ophthalmicus, perforate sclera, ramify in Choroidea. B C
- 18 *Vv. ciliares*. Anterior branches of *Vv. vorticosae* to Corpus ciliare. C
- 19 *Vv. conjunctivales*. Branches of Plexus ophthalmicus to Tunica conjunctiva.
- 20 *V. lacrimalis*. Branch of Plexus ophthalmicus to Gl. lacrimalis. B
- 21 *V. ethmoidalis externa*. Through Foramen ethmoidale, continues through Lamina cribrosa into Cavum nasi. B
- 22 *V. supraorbitalis*. Branch of Plexus ophthalmicus, traverses Canalis supraorbitalis, anastomoses with *V. frontalis*. B
- 23 *V. malaris*. Branch of Plexus ophthalmicus to Angulus oculi medialis. B
- 24 *V. palpebrae tertiae*. Branch of *V. malaris* into Palpebra III. Usually plural B
- 25 *Plexus pterygoideus*. Network at the caudolateral aspect of Mm. pterygoidei. B
- 26 *Vv. palatinae*. To Palatum molle. B
- 27 Plexus palatinus. Network around Tonsilla palatina and in Palatum molle. B
- 28 *Vv. pharyngeae*. Ramify in the pharyngeal wall. B
- 29 *V. alveolaris inferior*. Enters Canalis mandibulae. B
- 30 *V. mentalis*. Emerges from Foramen mentale, ramifies in the chin. A
- 31 *V. temporalis profunda*. Courses across the rostral aspect of Articulatio temporomandibularis into M. temporalis. B
- 32 *V. masseterica*. Through Incisura mandibulae into M. masseter. A B
- 33 *Vv. articulares temporomandibulares*. To Articulatio temporomandibularis. A B
- 34 *V. buccalis*. Vein to the cheek. B
- 35 *Vv. pterygoideae*. To Mm. pterygoidei. B

Hidden page

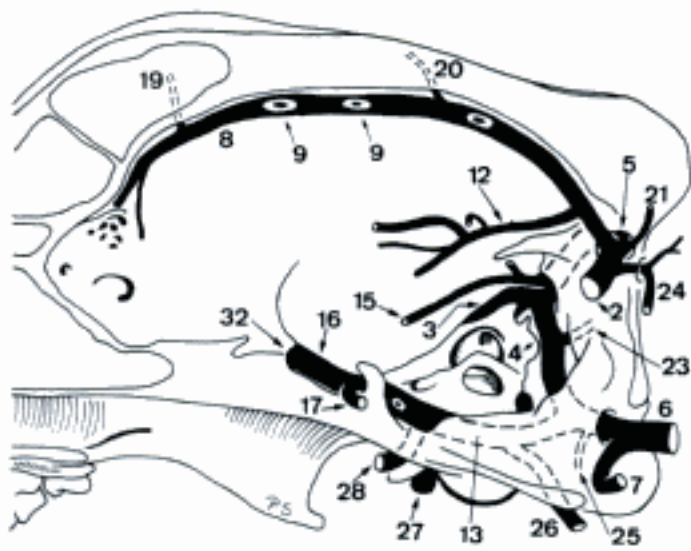
EQUUS

- 1 *V. thyroidea [thyroidea] cranialis*. Curves around the cranial pole of Gl. thyroidea. B
- 2 (*V. thyroidea [thyroidea] media*). Inconstant, enters the middle segment of Gl. thyroidea. B
- 3 *V. pharyngea ascendens*. Into the pharyngeal musculature. B
- 4 Plexus pharyngeus. Network around Pharynx. B
- 5 *V. cricothyroidea [-thyroidea]*. To M. cricothyroideus. B
- 6 *Ramus laryngeus caudalis*. Enters larynx between Cartilago thyroidea and Cartilago cricoidea. B
- 7 *V. occipitalis*. To Fossa atlantis, receives a Ramus anastomoticus from V. vertebralis, continues along the medial aspect of Processus paracondylaris, joins the extracranial segment of Sinus petrosus ventralis. A
- 8 *V. stylomastoidea*. To Foramen stylomastoideum.
- 9 *Ramus occipitalis*. Extends towards Crista nuchae. Usually replaced by a slender branch of V. vertebralis. A
- 10 *V. auricularis caudalis*. To the base of the ear. A B
- 11 *Rami parotidei*. To Gl. parotis. B
- 12 *V. auricularis lateralis*. On Dorsum auriculae along Margo antitragicus. B
- 13 *V. auricularis intermedia*. In the middle of Dorsum auriculae. B
- 14 *V. auricularis medialis*. On Dorsum auriculae along Margo tragicus. B
- 15 *V. masseterica ventralis*. Into M. masseter. A B
- 16 *V. temporalis superficialis*. Passes between Auris externa and Articulatio temporomandibularis, ramifies in M. temporalis. A B
- 17 *V. transversa faciei*. Courses along the ventral border of Crista facialis, joins V. facialis. A B
- 18 Sinus v. transversae faciei. Long enlargement of V. transversa faciei. A
- 19 *V. auricularis rostralis*. To the rostral part of the base of the ear. A B
- 20 *V. auricularis profunda*. Ramifies into muscular branches. B
- 21 *Plexus pterygoideus*. Network at the caudolateral aspect of Mm. pterygoidei. B
- 22 *Vv. pharyngeae*. Form a network in the pharyngeal wall. B
- 23 *Vv. palatinae*. Into Palatum molle. B
- 24 Plexus palatinus. Network in Palatum molle and Palatum durum. B
- 25 *V. alveolaris inferior*. Into Canalis mandibulae. A B
- 26 *V. mentalis*. Emerges from Foramen mentale. A
- 27 *Ramus sublingualis*. Into the tongue. A B
- 28 *V. temporalis profunda*. Into M. temporalis. B
- 29 *Vv. articulares temporomandibulares*. To Articulatio temporomandibularis. B
- 30 *Vv. pterygoideae*. Ramify in Mm. pterygoidei. A B
- 31 *V. buccalis*. Courses along the medial surface of M. masseter, joins V. facialis. A B
- 32 Sinus v. buccalis. Large spindle-shaped dilatation of V. buccalis. A

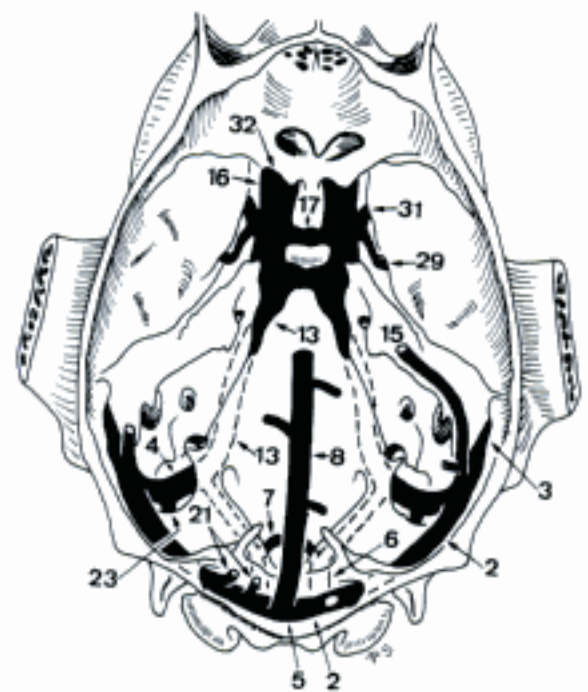
Hidden page

TERMINI COMMUNES

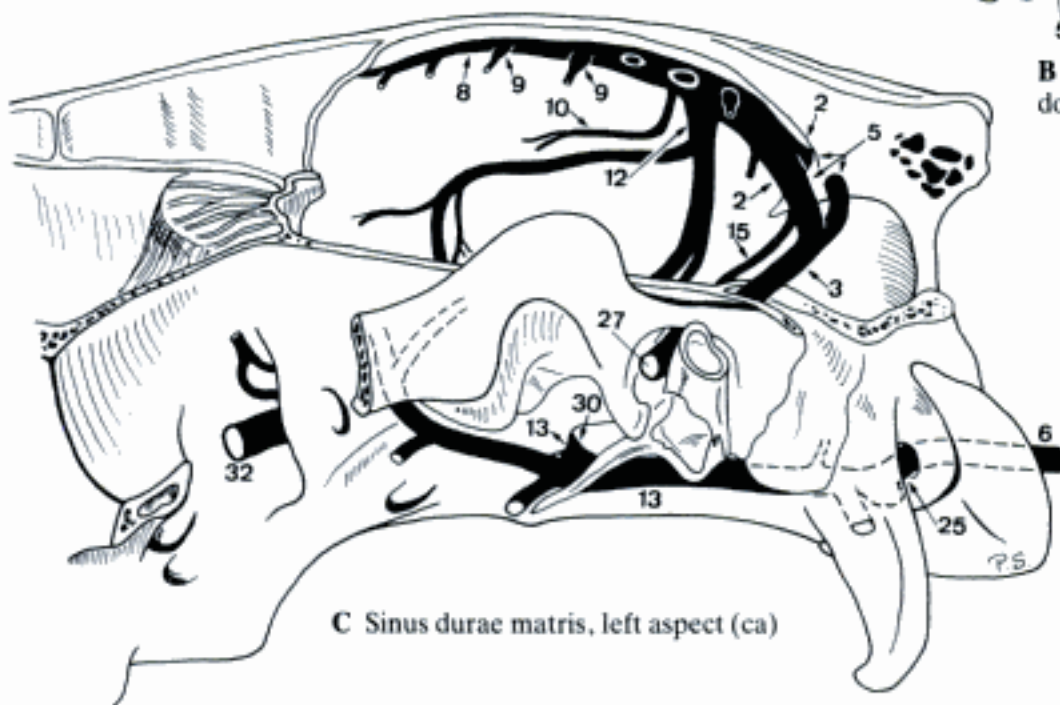
- 1 **SINUS DURAE MATRIS.** Channels within dura. Receive blood from Encephalon and Calvaria, drain into Vv. emissariae and Plexus vertebralis internus ventralis.
- 2 *Sinus transversus.* Located within Tentorium cerebelli osseum (Car, eq) s. membranaceum (su, Ru). A B C D
- 3 *Sinus temporalis (Car, Ru, eq).* Continuation of Sinus transversus through Meatus temporalis. A B C D
- 4 *Sinus sigmoideus (Car, su, Ru).* Continuation of Sinus transversus along the caudal aspect of Pars petrosa. A B D E
- 5 *Confluens sinuum.* Triangular (eq, often fe), plexiform (su, Ru), or asymmetrical (Car) confluence of sinus. A B C D
- 6 *Sinus basilaris.* Continuation of Plexus vertebralis internus ventralis upon clivus. Contains in bo the Rete mirabile epidurale caudale. A B C D E
- 7 *Sinus interbasilaris.* Ventral connection of left and right Sinus basilaris. May be complemented dorsally (Car). A E
- 8 *Sinus sagittalis dorsalis.* In the rim of Falx cerebri along Crista sagittalis interna. A B C D
- 9 *Lacunae laterales.* Enlargements into which the Vv. cerebri dorsales discharge. C
- 10 *Sinus sagittalis ventralis (eq).* In the free margin of Falx cerebri. C
- 11 (*Sinus sagittalis ventralis*) (Car).
- 12 *Sinus rectus.* Unpaired continuation of V. cerebri magna inside Falx cerebri. A C
- 13 *Sinus petrosus ventralis.* Caudal extension of Sinus cavernosus, intracranial in Car, leaves Cavum cranii through Foramen lacerum in eq, Fissura petrooccipitalis in Ru. A B C E
- 14 *Vv. labyrinthi.* Enter Meatus acusticus internus.
- 15 *Sinus petrosus dorsalis (Car, eq).* Courses in Tentorium cerebelli membranaceum along Pars petrosa to Sinus transversus. Described also in Ru. A B C D
- 16 *Sinus cavernosus.* Located at the lateral aspect of hypophysis. Encloses A. carotis interna (Car, eq) or Rete mirabile epidurale rostrale (su, Ru). A B E
- 17 *Sinus intercavernosi.* Connections between left and right Sinus cavernosi, rostral and caudal to hypophysis. A B E
- 18 **Vv. diploicae.** Conduct blood from Diploë of Calvaria into Sinus durae matris.
- 19 *V. diploica frontalis.* Ramifies in Diploë of Os frontale, discharges into Sinus sagittalis dorsalis. A
- 20 *V. diploica parietalis.* Ramifies in Os parietale, discharges into Sinus transversus (Ru) or Sinus sagittalis dorsalis. A
- 21 *V. diploica occipitalis.* Ramifies in Os occipitale, discharges in Confluens sinuum or Sinus transversus (ca). A B
- 22 **Vv. emissariae.** Connections between Sinus durae matris and veins of skull.
- 23 *V. emissaria mastoidea (ca, bo).* Leaves Sinus sigmoideus, perforates through Foramen mastoideum. Joins V. emissaria occipitalis in ca. A B
- 24 *V. emissaria occipitalis (ca).* Leaves Sinus transversus, perforates Os occipitale near Crista nuchae, joins V. emissaria mastoidea. A
- 25 *V. emissaria canalis n. hypoglossi.* Connects Sinus basilaris via Canalis n. hypoglossi with various veins. A C E
- 26 *V. emissaria foraminis jugularis.* Connects Sinus sigmoideus (Car, su, cap) s. Sinus basilaris (ca, su, Ru) through Foramen jugulare with various veins. A E
- 27 *V. emissaria foraminis retroarticularis (Car, Ru, eq).* Connects Sinus temporalis with V. maxillaris (Car, Ru) or V. temporalis superficialis (eq). A C D
- 28 *V. emissaria canalis carotici (Car).* Leaves Sinus petrosus ventralis, emerges at the rostral aspect of Bulla tympanica, joins V. maxillaris. A
- 29 *V. emissaria foraminis ovalis (Car, Ru).* Connects Sinus cavernosus through Foramen ovale with V. maxillaris. B E
- 30 *V. emissaria foraminis lacerti (su, eq).* Connects Sinus cavernosus with V. jugularis interna (su) or extracranial segments of Sinus petrosus ventralis (eq). C
- 31 *V. emissaria foraminis rotundi (Car).* Connects Sinus cavernosus with V. maxillaris or Plexus ophthalmicus. B
- 32 *V. emissaria fissurae orbitalis (Car, eq).* Connects Sinus cavernosus via Fissura orbitalis with Plexus ophthalmicus. A B C
- 33 *V. emissaria foraminis orbitorotundi (su, Ru).* Connects Sinus cavernosus with Sinus s. Plexus ophthalmicus. E



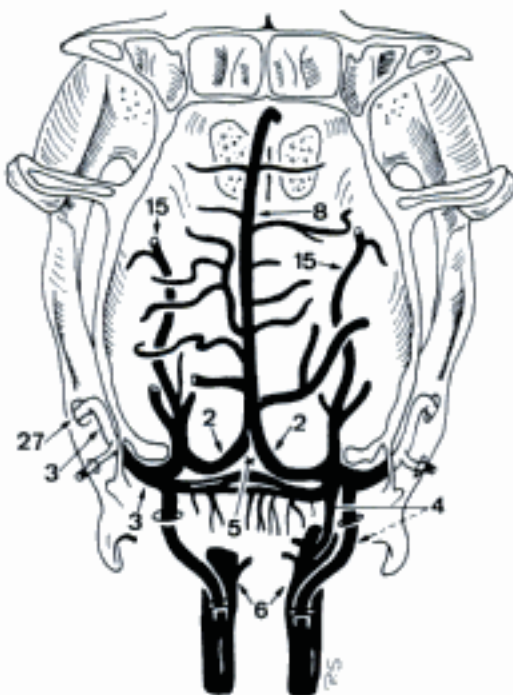
A Sinus durae matris, medial aspect (ca)



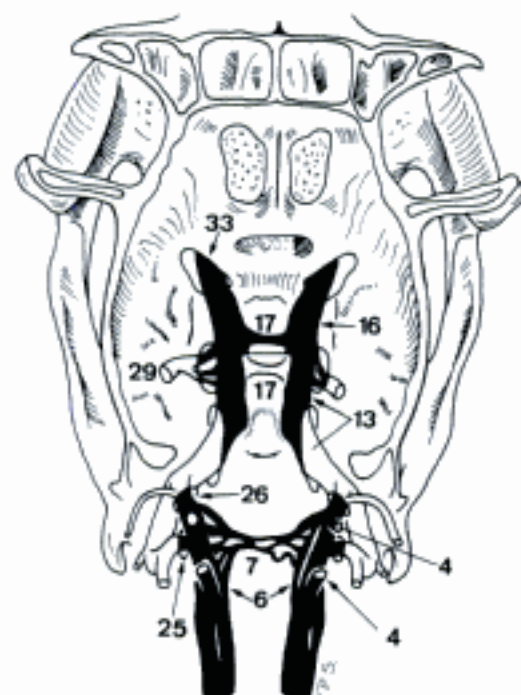
B Sinus durae matris, dorsal aspect (ca)



C Sinus durae matris, left aspect (ca)



D Dorsal Sinus durae matris, dorsal aspect (cap)

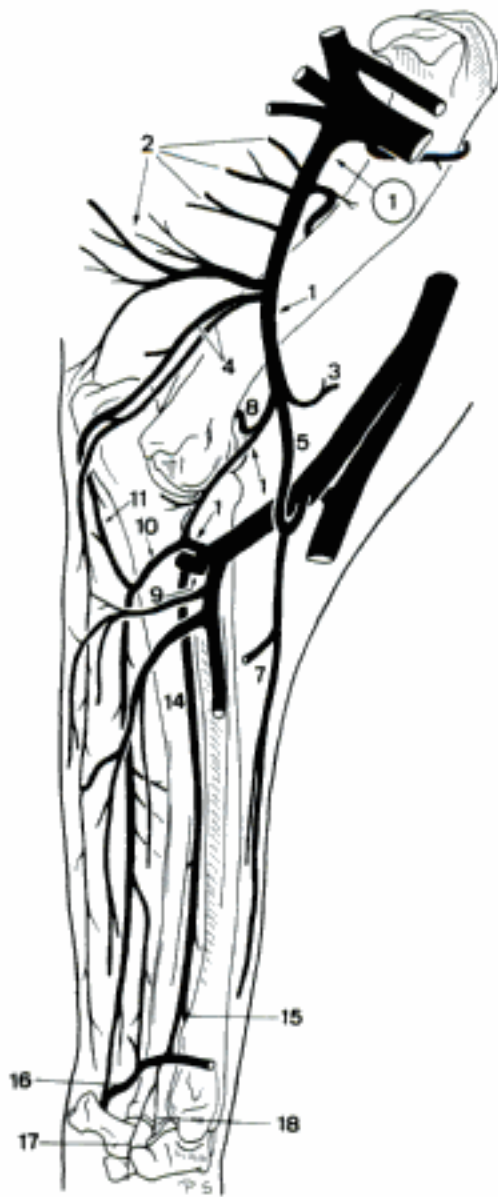

E Basal Sinus durae matris, dorsal aspect (cap)

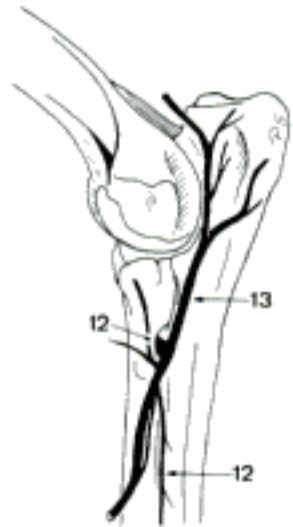
- 1 **Vv. cerebri.** Valveless veins of cerebrum. Discharge into Sinus durae matris.
- 2 *Vv. cerebri dorsales.* Ramify on Facies convexa and medialis of Hemispheria cerebri. A B C
- 3 *Vv. cerebri ventrales.* Ramify on Facies basilaris of Hemispheria cerebri, and Pars basalis rhinencephali. A B C
- 4 *V. cerebri magna.* Unpaired trunk formed by left and right Vv. cerebri internae in Tela choroidea ventriculi tertii, continues inside Falx cerebri as Sinus rectus. B D
- 5 (*V. corporis callosi*). Unpaired, courses caudally along the dorsal surface of Corpus callosum. B
- 6 *Vv. cerebri internae.* Bilateral venous trunks in Tela choroidea ventriculi tertii, collect blood from V. choroidea and V. thalamostriata. B D
- 7 *V. choroidea* [chorioidea]. Collects blood from Plexus choroideus ventriculi lateralis (et tertii). D
- 8 *V. thalamostriata.* Curves along the medial border of Nucleus caudatus, drains Corpus striatum and thalamus. D
- 9 *Vv. cerebelli dorsales.* Ramify on the dorsal surface of Vermis and Hemispheria cerebelli. A
- 10 *Vv. cerebelli ventrales.* Collect blood from the ventral surface of cerebellum and adjacent segments of Rhombencephalon incl. Plexus choroideus ventriculi quarti. C
- 11 **V. ophthalmica interna.** Branch of Plexus s. Sinus ophthalmicus along N. opticus, receives Venulae retinae and Vv. ciliares.
- 12 **V. SUBCLAVIA.** Arises from V. brachiocephalica (Car, su, sometimes cap) or V. cava cranialis (Ru, eq), curves laterally to the cranial border of the first rib. Very short and double in su. G
- 13 **V. axillaris.** Continuation of V. subclavia beyond the cranial border of Costa I. Courses into axilla. Double in su. E F G
- 14 *V. thoracica externa.* Double (bo, sometimes eq) or plural (Car, su) vein, courses into Mm. pectorales. G
- 15 *V. thoracica superficialis (Ru).* Courses over M. serratus ventralis thoracis, continues subcutaneously.
- 16 *V. thoracica lateralis (Car, su).* Courses along the dorsal border of M. pectoralis profundus.
- 17 *V. suprascapularis (Un).* Accompanies corresponding artery. F G
- 18 *V. subscapularis.* Accompanies corresponding artery. E F G
- 19 *V. circumflexa humeri cranialis (Ru).* Accompanies corresponding artery.
- 20 *V. circumflexa humeri caudalis.* Accompanies corresponding artery. E F G
- 21 *V. collateralis radialis (Car, su, cap).* Accompanies corresponding artery. Arises from V. circumflexa humeri cranialis or V. brachialis in su. E F
- 22 *V. collateralis media.* Accompanies corresponding artery. E F
- 23 *Ramus suprascapularis (su).* Courses craniodorsally between scapula and M. subscapularis, joins V. suprascapularis. F
- 24 *V. circumflexa scapulae.* Accompanies corresponding artery. E F G
- 25 *V. circumflexa humeri cranialis (su).* Accompanies corresponding artery. F
- 26 *V. thoracodorsalis.* Accompanies corresponding artery. E F G
- 27 *V. thoracica superficialis (eq).* Courses over M. serratus ventralis thoracis, drains the lateral thoracic wall. G
- 28 *V. epigastrica cranialis superficialis* [V. subcutanea abdominis]. Subcutaneous continuation of V. thoracica superficialis, towards Regio inguinalis. G
- 29 *V. axillobrachialis (Car).* Branch of V. axillaris (ca) or V. circumflexa humeri caudalis (Car), receives V. omobrachialis (ca), joins V. cephalica. E
- 30 *V. circumflexa humeri cranialis (Car, eq).* Accompanies corresponding artery. G

Hidden page

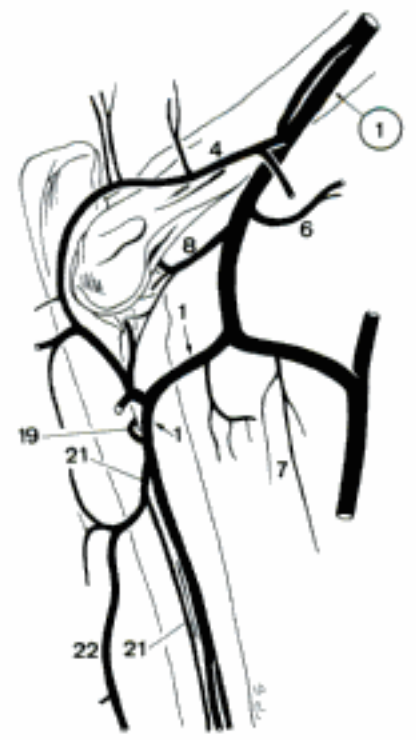Hidden page



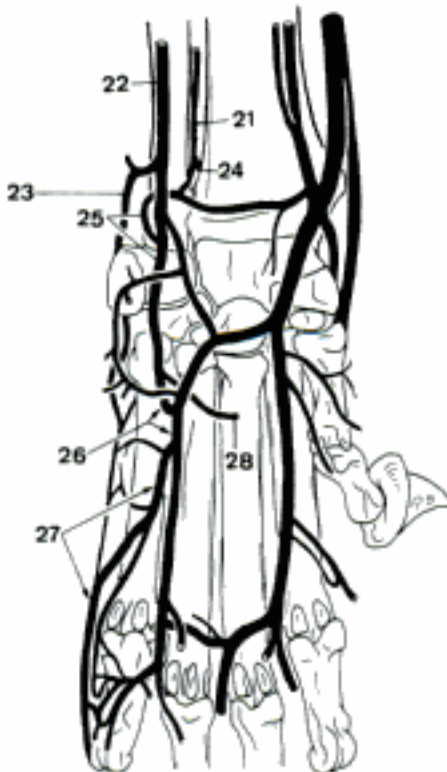
A Veins of left thoracic limb, medial aspect (ca)



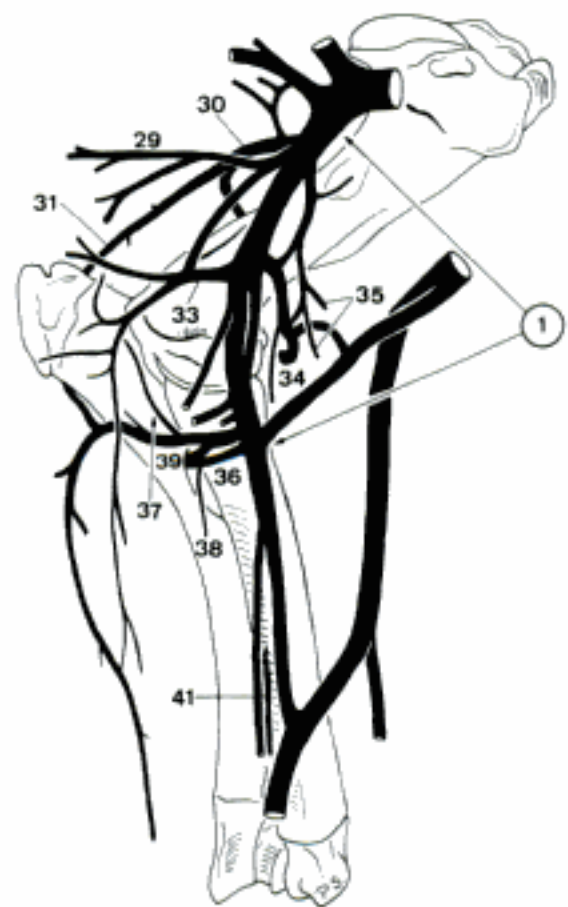
B Veins of left elbow, lateral aspect (ca)



C Veins of left elbow, medial aspect (fe)



D Veins of left manus, palmar aspect (fe)



E Veins of left thoracic limb, medial aspect (bo)

TERMINUS COMMUNIS

- 1 **V. mediana.** Accompanies corresponding artery. A C

CARNIVORA

- 2 *V. profunda antebrachii.* Accompanies corresponding artery.
- 3 *V. radialis.* Courses along the caudomedial border of radius, receives *V. cephalica*, continues superficially over the mediopalmar surface of carpus. Double in fe. Forms the major continuation of *V. mediana* in fe. A
- 4 *Ramus carpeus dorsalis.* Accompanies corresponding artery. Plural in ca. A B
- 5 *Rete carpi dorsale.* Network on the dorsal aspect of carpus. Mainly supplied by branches of *V. radialis*, *Vv. interossea cranialis* and *caudalis*, and *V. cephalica accessoria*. B
- 6 *Vv. metacarpeae dorsales I–IV.* Accompany corresponding arteries. Join *V. digitalis propria* I axiali s. *V. digitalis dorsalis communis* (II–IV) (ca). B
- 7 *Arcus palmaris profundus.* Lies across the palmar aspect of *Ossa metacarpalia*. Reinforced by *Ramus carpeus dorsalis* of *V. radialis* in fe. A
- 8 *Vv. metacarpeae palmares I–IV.* Accompany corresponding arteries. A
- 9 *Arcus palmaris superficialis.* Usually double, across the palmar aspect of the flexor tendons at *Torus metacarpeus*. Complementary superficial (fe) s. intermediate (ca) arch in the proximal half of metacarpus, receives *V. mediana* in ca. A
- 10 *Vv. digitales palmares communes I–IV.* May be absent, as their *Vv. digitales palmares propriae* may arise directly from *Arcus palmaris superficialis*. A
- 11 *V. interdigitalis.* Accompanies corresponding artery. A
- 12 *Vv. digitales palmares propriae.* Accompany corresponding arteries. A

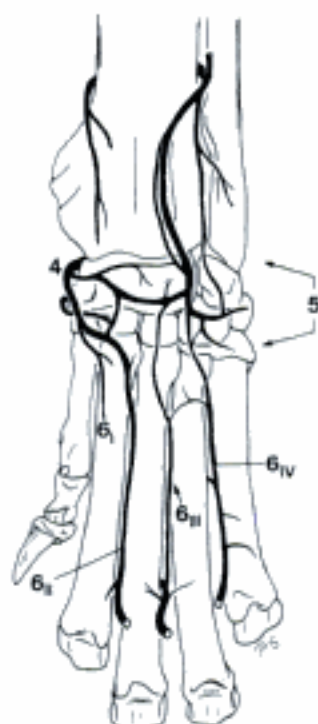SUS

- 13 *V. radialis.* Accompanies corresponding artery. C D

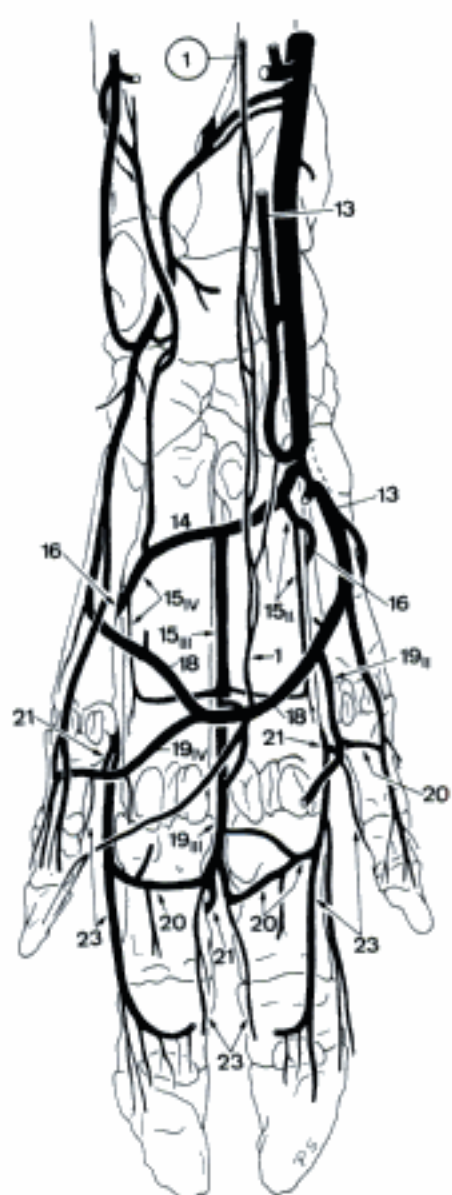
- 14 *Arcus palmaris profundus.* Lies between *Ossa metacarpalia* and *Mm. interossei*. C
- 15 *Vv. metacarpeae palmares II–IV.* Accompany corresponding arteries. End in the distal half of metacarpus by a transverse anastomosis which joins *Arcus palmaris superficialis*. C
- 16 *Ramus perforans proximalis.* Branch of *V. metacarpea palmaris*, pierces through the proximal half of the *Spatium interosseum metacarpi*. C D
- 17 *V. metacarpea dorsalis.* Slender continuation of *Ramus perforans proximalis*. Joins *V. digitalis dorsalis communis*. D
- 18 *Arcus palmaris superficialis.* Connection between *V. radialis* and *Ramus superficialis* of *Ramus palmaris* of *V. interossea caudalis* across the palmar aspect of the flexor tendons. C D
- 19 *Vv. digitales palmares communes II–IV.* Accompany corresponding arteries. C
- 20 *Rami palmares phalangium proximalium.* Transverse branches of each *V. digitalis palmaris communis* and/or *propria* across the palmar surface of the corresponding *Phalanx proximalis*. C D
- 21 *V. interdigitalis.* Branch of *V. digitalis palmaris communis* to the corresponding *V. digitalis dorsalis communis* or *propria*. C D
- 22 *Rami dorsales phalangium proximalium.* Branches of *V. interdigitalis* (II, III, IV) which ramify on the adjacent dorsal aspect of *Phalanges proximales*. D
- 23 *Vv. digitales palmares propriae.* Three pairs of veins, arisen by the bifurcation of *Vv. digitales palmares communes*. *Vv. digitales palmares propriae* III and IV abaxiales originate from the corresponding *Vv. digitales dorsales propriae*. C D



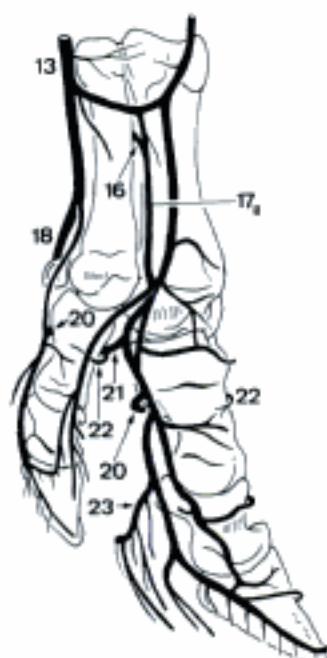
A Veins of left manus, palmar aspect (ca)



B Deep dorsal veins of the left manus (ca)



C Veins of left manus, palmar aspect (su)



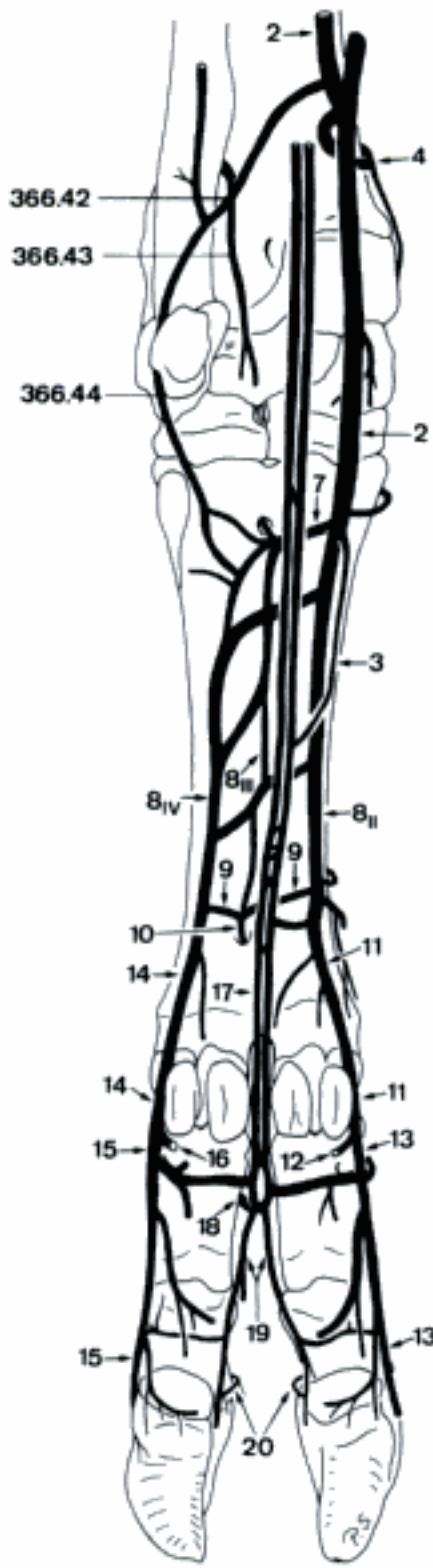
D Veins of left manus, medial aspect (su)

RUMINANTIA

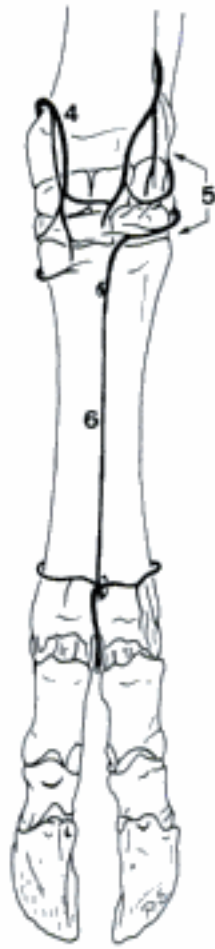
- 1 *V. profunda antebrachii*. Accompanies corresponding artery.
- 2 *V. radialis*. Accompanies corresponding artery. A
- 3 *Ramus superficialis*. Variable superficial branch, joins *V. mediana* in the middle third of metacarpus (bo, sometimes cap). A
- 4 *Ramus carpeus dorsalis*. Accompanies corresponding artery. A B
- 5 Rete carpi dorsale. Network on the dorsal aspect of carpus. B
- 6 *V. metacarpea dorsalis III*. Inconstant branch of Rete carpi dorsale, accompanies corresponding artery. B
- 7 *Arcus palmaris profundus*. Connection between *V. radialis* and *Ramus palmaris* of *V. interossea cranialis*. A
- 8 *Vv. metacarpeae palmares II–IV*. Accompany corresponding arteries. Generally, *V. metacarpea palmaris II*, the continuation of *V. radialis*, is prominent. A
- 9 *Arcus palmaris profundus distalis*. Distal connection of *Vv. metacarpeae palmares II–IV* under *M. interosseus*. A
- 10 *Ramus perforans distalis III*. Branch of *Arcus palmaris profundus distalis* through *Canalis metacarpi distalis*, joins *V. metacarpea dorsalis III* (bo). A
- 11 *V. digitalis palmaris communis II*. Superficial branch of *Arcus palmaris profundus distalis*. A
- 12 *V. digitalis palmaris propria II axialis*. To the medial dew claw. A
- 13 *V. digitalis palmaris propria III abaxialis*. Continuation of *V. digitalis palmaris communis II*. A
- 14 *V. digitalis palmaris communis IV*. Superficial branch of *Arcus palmaris profundus distalis*. A
- 15 *V. digitalis palmaris IV abaxialis*. Continuation of *V. digitalis palmaris communis IV*. A
- 16 *V. digitalis palmaris propria V axialis*. To the lateral dew claw. A
- 17 *V. digitalis palmaris communis III*. Continuation of *V. mediana* distal to the connection with *V. digitalis palmaris communis II* (Ru) s. *IV* (ov, cap). Double in bo. A
- 18 *V. interdigitalis*. Accompanies corresponding artery, joins *V. digitalis dorsalis communis III* (bo), arises in ov from *Vv. digitales palmares propriae III* resp. *IV axiales* and is double. A
- 19 *Vv. digitales palmares propriae III et IV axiales*. Accompany corresponding arteries. A
- 20 *V. coronalis*. Superficial connection of *Vv. digitales palmares propriae axialis* and *abaxialis* in the Corona unguulae. A

EQUUS

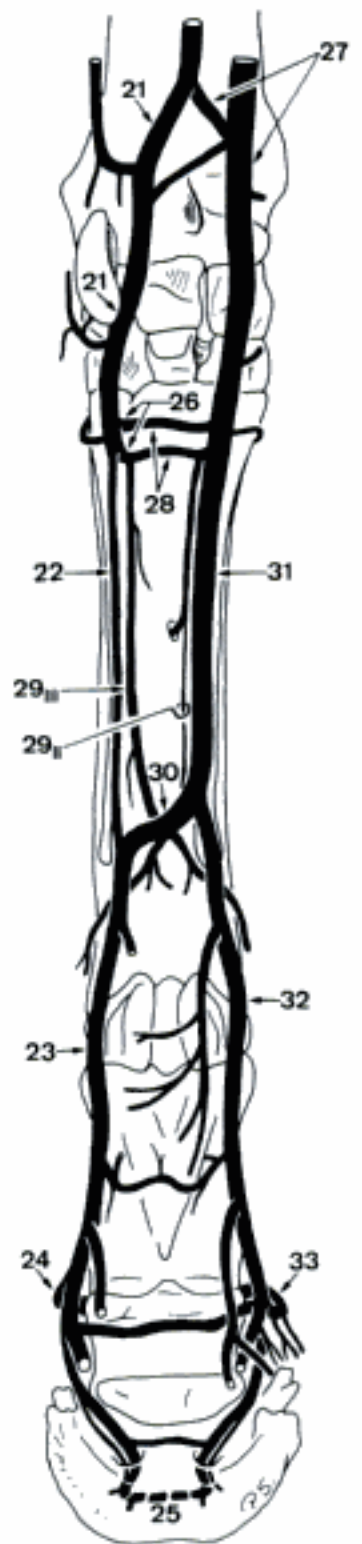
- 21 *Ramus palmaris*. Accompanies corresponding artery. C
- 22 *Ramus superficialis [V. digitalis palmaris communis III]*. Runs along the lateral surface of the deep flexor tendon. C
- 23 *V. digitalis [palmaris propria III] lateralis*. Continuation of *Ramus superficialis* of *Ramus palmaris* of *V. mediana* distal to *Arcus palmaris profundus distalis*. Accompanies corresponding artery dorsally. C
- 24 *V. coronalis*. Superficial branch of *V. digitalis lateralis*, curves dorsally, proximal to Corona unguulae. Its distal branches form the network in the corium of the hoof. C
- 25 *Arcus terminalis*. Accompanies corresponding artery. C
- 26 *Ramus profundus*. Accompanies corresponding artery. C
- 27 *V. radialis*. Receives *V. cephalica*, accompanies corresponding artery. C
- 28 *Arcus palmaris profundus*. Accompanies corresponding artery. C
- 29 *Vv. metacarpeae palmares II et III*. Accompany corresponding arteries. Pierce between the branches of *M. interosseus*, join *Arcus palmaris profundus distalis*. C
- 30 *Arcus palmaris profundus distalis*. Connection between *Ramus superficialis* of *Ramus palmaris* of *V. mediana* and *Ramus palmaris superficialis* of *V. radialis* in the distal third of metacarpus, between *M. interosseus* and the deep flexor tendon. C
- 31 *Ramus palmaris superficialis [V. digitalis palmaris communis II]*. Accompanies corresponding artery. C
- 32 *V. digitalis [palmaris propria III] medialis*. Continuation of *Ramus palmaris superficialis* of *V. radialis* distal to *Arcus palmaris profundus distalis*. Accompanies corresponding artery dorsally. C D
- 33 *V. coronalis*. Superficial branch of *V. digitalis medialis*, curves dorsally, proximal to Corona unguulae. Its distal branches form the network in the corium of the hoof. C D



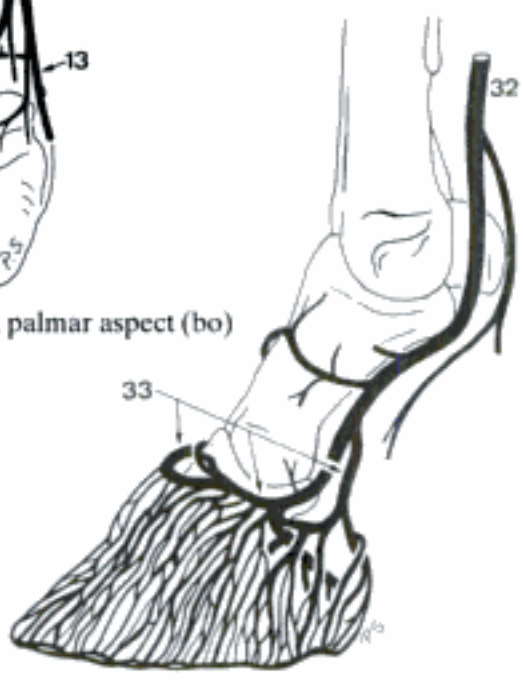
A Veins of left thoracic limb, palmar aspect (bo)



B Veins of left manus, dorsal aspect (bo)



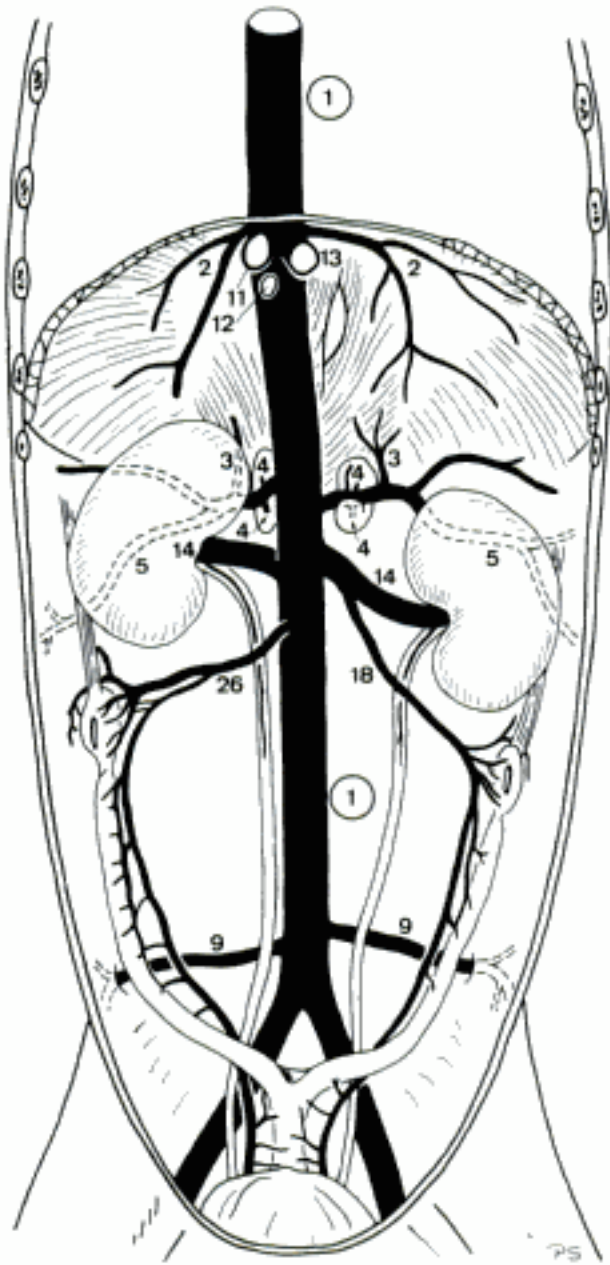
C Veins of left thoracic limb, palmar aspect (eq)



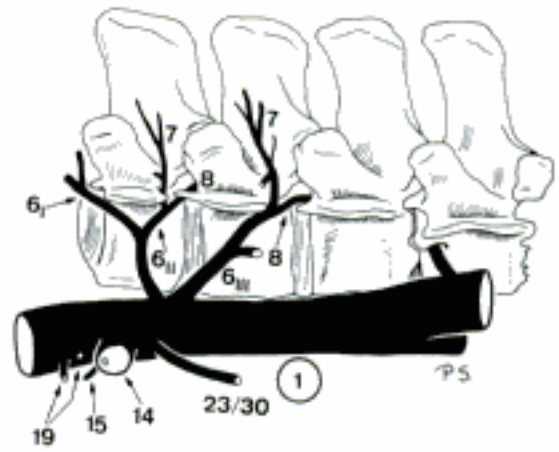
D Veins of right digit, medial aspect (eq)

TERMINI COMMUNES

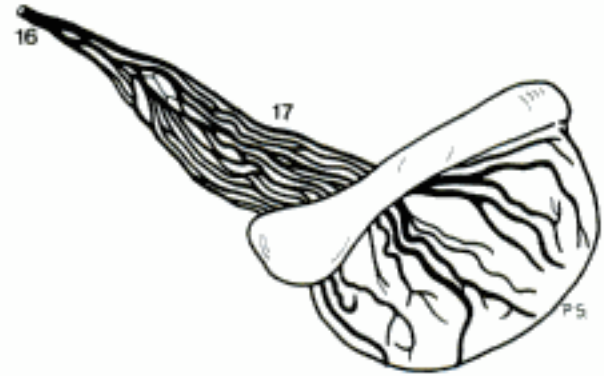
- 1 **VENA CAVA CAUDALIS.** Leaves Sinus venarum cavarum of Atrium dextrum, courses in Plica venae cavae and pierces through Foramen venae cavae of Diaphragma into Cavum abdominis, courses along Sulcus venae cavae of the liver and continues right to Aorta abdominalis. A B F
- 2 *Vv. phrenicae craniales.* Left and right, course laterally in Centrum tendineum towards Partes (lumbalis), costalis, and sternalis of Diaphragma. A
- 3 *V. phrenica caudalis.* Bilateral, arises with *V. abdominalis cranialis* (Car) or from *V. azygos sinistra* in (su). A
- 4 *Rami adrenales [supra-] craniales* (Car). Into Gl. suprarenalis. A
- 5 *V. abdominalis cranialis* (Car, su). Bilateral, arises with *V. phrenica caudalis* (Car) from *V. cava caudalis* (su: right side) s. *V. renalis sinistra* (su: left side), ramifies in the cranial-lateral abdominal wall. Double in su. A
- 6 *Vv. lumbales.* Often initially fused, segmental, accompany corresponding arteries. B
- 7 *Ramus dorsalis.* To Plexus vertebralis externus dorsalis. B
- 8 *V. intervertebralis.* Through Foramen intervertebrale, connects Plexus vertebrales externi and interni. B
- 9 *V. circumflexa ilium profunda* (Car). Accompanies corresponding artery. A
- 10 *Vv. hepaticae.* Intrahepatic, join *V. cava caudalis* in Sulcus venae cavae of the liver. A
- 11 *V. hepatica dextra.* In the right part of the liver. A
- 12 *V. hepatica media.* In the central segments, esp. Lobus quadratus, of the liver. A
- 13 *V. hepatica sinistra.* In the left part of the liver. A
- 14 *V. renalis.* To the Hilus renalis, the left crosses Aorta abdominalis ventrally. A B
- 15 *Ramus adrenalis [supra-] caudalis* (Ru, eq). To Gl. suprarenalis. B
- 16 *V. testicularis sinistra.* (Car). Accompanies corresponding artery. C
- 17 Plexus pampiniformis. Network around A. testicularis. C
- 18 *V. ovarica sinistra* (Car). Accompanies corresponding artery. A
- 19 *Vv. adrenales [supra-]* (bo, eq). To Gl. suprarenalis. B
- 20 *V. testicularis dextra.* Accompanies corresponding artery. D F
- 21 *V. vesicalis cranialis* (cap). In Ligamentum vesicae laterale to Vesica urinaria. F
- 22 Plexus pampiniformis. Network around A. testicularis. D
- 23 *V. testicularis sinistra* (su, cap, eq). Accompanies corresponding artery. B E F
- 24 *V. vesicalis cranialis* (cap). In Ligamentum vesicae laterale to Vesica urinaria. F
- 25 Plexus pampiniformis. Network around A. testicularis. E
- 26 *V. ovarica dextra.* Accompanies corresponding artery. A
- 27 *V. uterina* (su). Main vein of the uterus. 389 B
- 28 *V. vesicalis cranialis.* To Vesica urinaria. 389 B
- 29 *V. vesicalis cranialis* (cap). To Vesica urinaria.
- 30 *V. ovarica sinistra* (su, ov, eq). Courses in Mesovarium to the right Ovarium, Tuba uterina and Cornu uteri. B
- 31 *V. uterina* (su). See 27
- 32 *V. vesicalis cranialis.* See 28



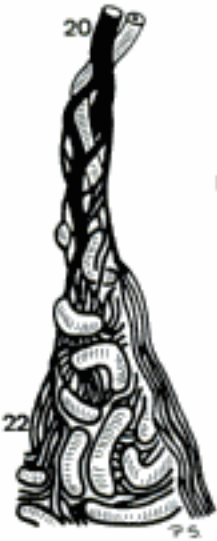A V. cava caudalis, ventral aspect (ca fem)



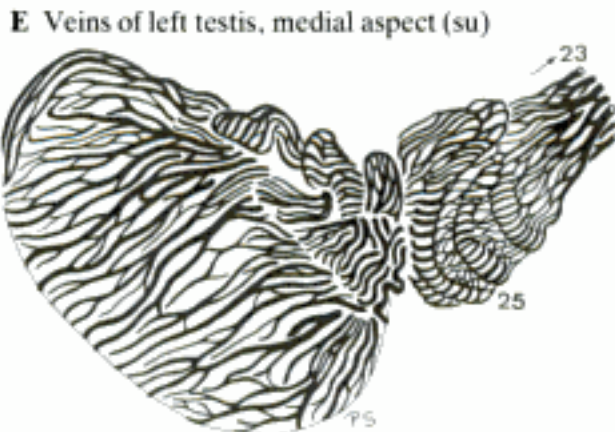
B Veins in relation to Vertebrae lumbales II-V, left aspect (cq)



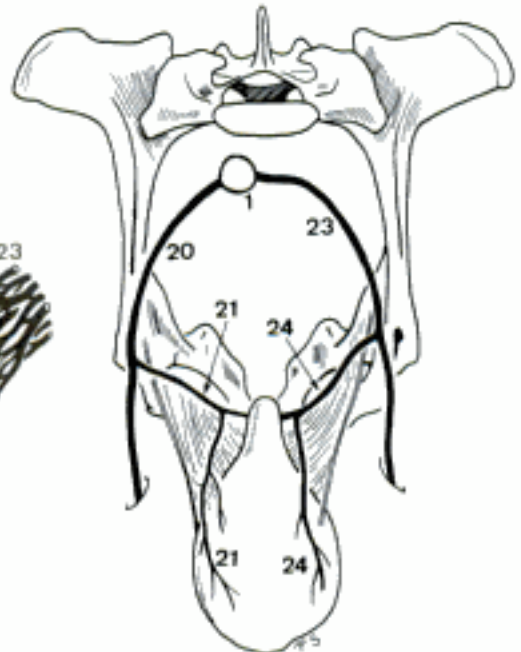
C Veins of the left testis, lateral aspect (ca)



D Right Plexus pampiniformis, lateral aspect (bo)



E Veins of left testis, medial aspect (su)



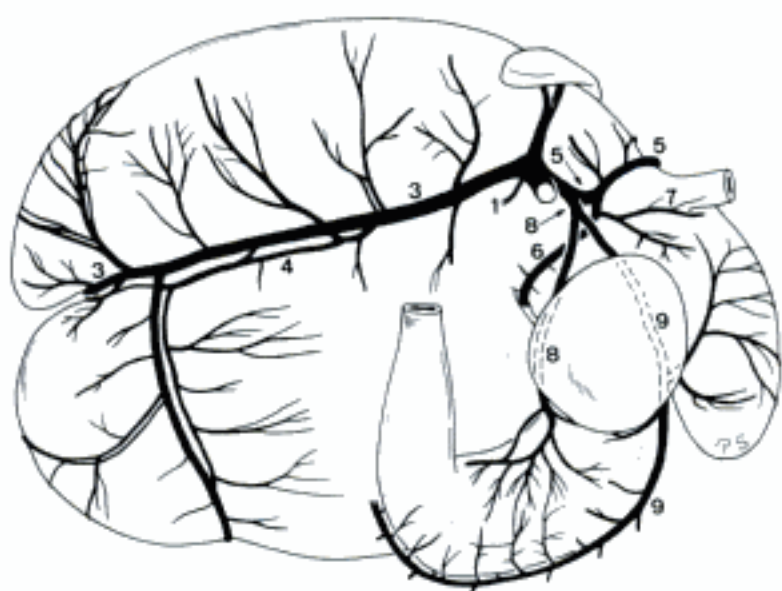
F Veins of pelvis and urinary bladder, cranial aspect (cap masc)

- 1 **V. PORTAE.** Unpaired, transports blood from the gastrointestinal tract (except the caudal segment of rectum and the Canalis analis), the pancreas, and the spleen into the liver. Extends from Porta hepatis in the Omentum minus, pierces through Incisura (Car, Ru) s. Anulus (su, eq) pancreatis to the right surface of A. mesenterica cranialis. A B C D
- 2 *Ramus dexter.* In Lobus hepatis dexter (lateralis) and Processus caudatus. A B
- 3 *Ramus sinister.* In the left and central hepatic segments, including Lobus hepatis dexter medialis (Car, su, eq) s. the central segment of Lobus hepatis dexter (Ru). A B
- 4 *Pars transversa.* Initial segment of Ramus sinister, coursing transversely to the left (Car, su, eq) s. ventrally (Ru) in Porta hepatis. A
- 5 *Pars umbilicalis.* Sagittal (Car, su, eq) s. transversal (Ru) continuation of Ramus sinister in Lobus hepatis sinister (medialis) towards Fissura lig. teretis. Derived from the intrahepatic segment of V. umbilicalis. A
- 6 **Ductus venosus (ont).** Intrahepatic shunt connecting V. umbilicalis with V. cava caudalis. Perinatally still present in Car and Ru. A
- 7 **V. umbilicalis (ont).** Unpaired, conveys blood from the Placenta via Funiculus umbilicalis (where it is paired in Car and Ru), into the liver. Discharges into V. cava caudalis via Ductus venosus or via the hepatic portal venous system. A
- 8 **Ligamentum teres hepatis.** Fibrous remnant of V. umbilicalis in Ligamentum falciforme hepatis. D
- 9 *Vv. cysticae.* Drain the wall of Vesica fellea (and adjacent hepatic segments). A B
- 10 *V. gastrica dextra (ca).* Accompanies corresponding artery. B
- 11 *V. gastrica sinistra parietalis (eq).* To Facies parietalis of the stomach. D
- 12 *Rami pancreatici (eq).* Into pancreas. D
- 13 **V. gastroduodenalis.** Unpaired affluent to V. portae, except in bo, where it joins one of its intrahepatic rami. Courses towards Flexura duodeni cranialis. B C D
- 14 *V. gastrica dextra (fe, Un).* Accompanies corresponding artery. C D
- 15 *V. gastroepiploica dextra.* Accompanies corresponding artery. B C D
- 16 *V. pancreaticoduodenalis cranialis.* Accompanies corresponding artery. B C D
- 17 **V. lienalis.** Unpaired affluent to V. portae. Accompanies corresponding artery. B C D
CARNIVORA, SUS, EQUUS
- 18 *Vv. pancreaticae.* Accompany corresponding arteries. B C D
- 19 *V. gastrica sinistra (Car, su).* Accompanies corresponding artery. B C
- 20 *Vv. diverticuli (su).* Ramify at Diverticulum ventriculi. C
- 21 *V. gastrica sinistra visceralis (eq).* To Facies visceralis of the stomach. D
- 22 *Rami pancreatici.* Drain Lobus pancreatis sinister. D
- 23 *Vv. gastricae breves.* Accompany corresponding arteries. B C D
- 24 *V. gastroepiploica sinistra.* Accompanies corresponding artery. B C D

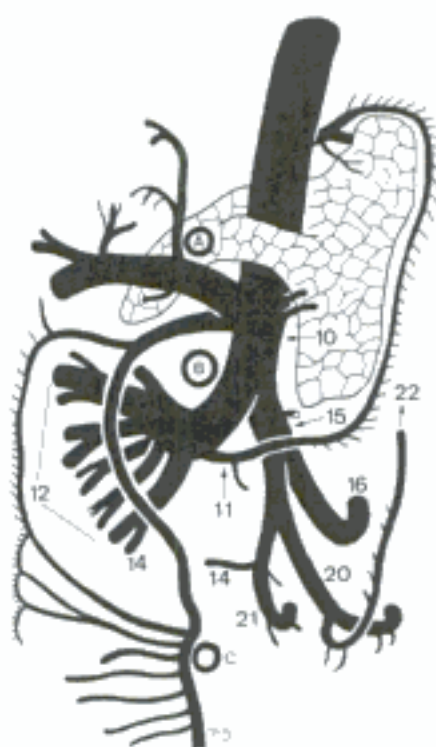
Hidden page

RUMINANTIA

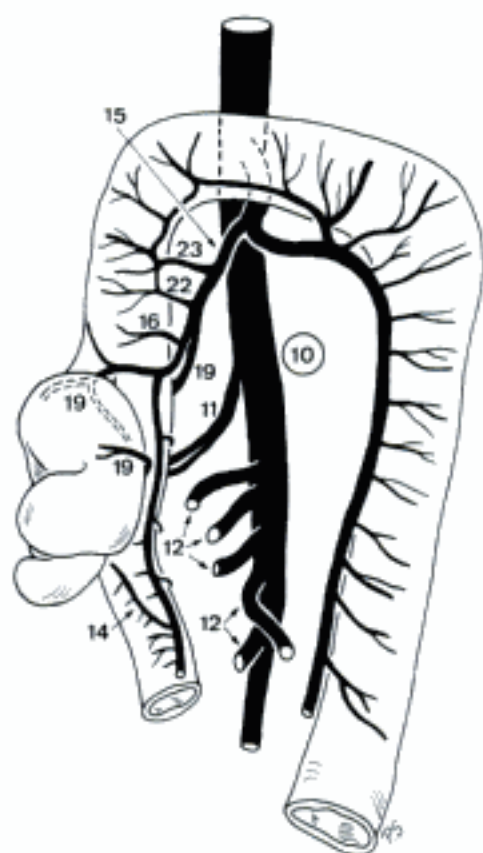
- 1 *Vv. pancreaticae*. Into Lobus pancreatis sinister. A
 - 2 *Ramus epiploicus*. Accompanies corresponding artery.
 - 3 *V. ruimalis dextra*. Accompanies corresponding artery. A
 - 4 *Ramus collateralis*. Courses parallel to *V. ruminalis dextra*. A
 - 5 *V. reticularis*. Accompanies corresponding artery. A
 - 6 *V. ruminalis sinistra*. Accompanies corresponding artery. A
 - 7 *V. esophagea [oesophagea] caudalis*. Drains the caudal segment of Esophagus. A
 - 8 *V. gastrica sinistra*. Accompanies corresponding artery. A
 - 9 *V. gastroepiploica sinistra*. Accompanies corresponding artery. A
- TERMINI COMMUNES
- 10 **V. mesenterica cranialis**. Unpaired, major terminal tributary to *V. portae*. Drains most of the intestinal tract: from Pars descendens of duodenum to colon transversum. Courses in mesenterium at the right aspect of *A. mesenterica cranialis*. B C D
 - 11 *V. pancreaticoduodenalis caudalis*. Accompanies corresponding artery. B C D
 - 12 *Vv. jejunales*. Accompany corresponding arteries. B C D
 - 13 *Ramus collateralis (bo)*. Courses caudoventrally in mesojejunum, parallel to the terminal segment of *V. mesenterica cranialis*, gives rise to *Vv. jejunales*. Contributes to the jejunal venous arcades. D
 - 14 *Vv. ilei*. Variably arising branches (from *V. mesenterica cranialis*, *V. ileocolica*, and *V. cecalis*) for ileum. B C D
 - 15 *V. ileocolica*. Accompanies corresponding artery. B C D
 - 16 *Ramus colicus (Car, su, eq)*. Accompanies corresponding artery. B C
 - 17 *Rami colici (Ru)*. Accompany corresponding arteries. D
 - 18 *Vv. colicae dextrae (Ru)*. Accompany corresponding arteries. D
 - 19 *V. cecalis [caecalis] (Car, su, Ru)*. Accompanies corresponding artery. C D
 - 20 *V. cecalis [caecalis] medialis (eq)*. Accompanies corresponding artery. B
 - 21 *V. cecalis [caecalis] lateralis (eq)*. Accompanies corresponding artery. B
 - 22 *V. colica dextra (Car, su, eq)*. Branch of *V. ileocolica (Car, su)* or *Ramus colicus (eq)*. Accompanies corresponding artery. B C
 - 23 *V. colica media (Car, su)*. Arises from *V. ileocolica*, accompanies corresponding artery, joins *V. mesenterica caudalis*. C



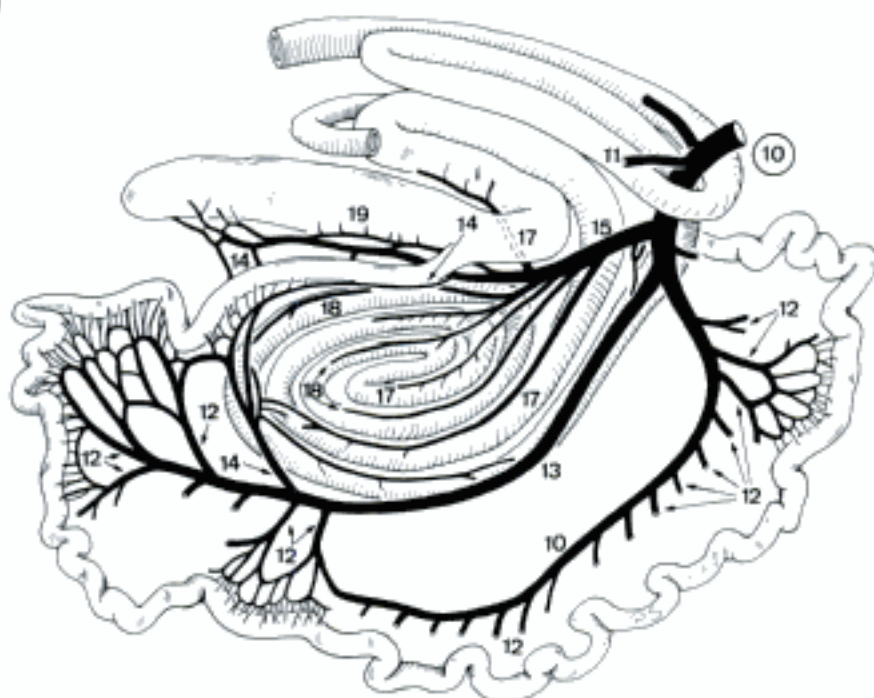
A Veins of the stomach, right aspect (bo)



B V. portae in relation to pancreas and A. celiaca (A), A. mesenterica cranialis (B) and A. mesenterica caudalis (C), dorsal aspect (eq)

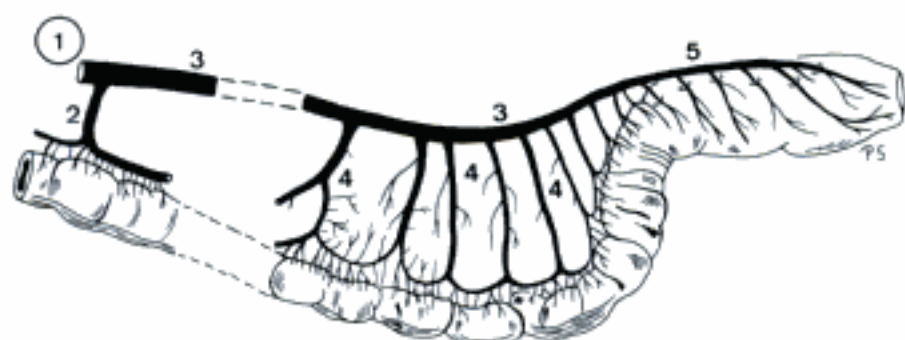


C Veins of cecum and colon, ventral aspect (ca)

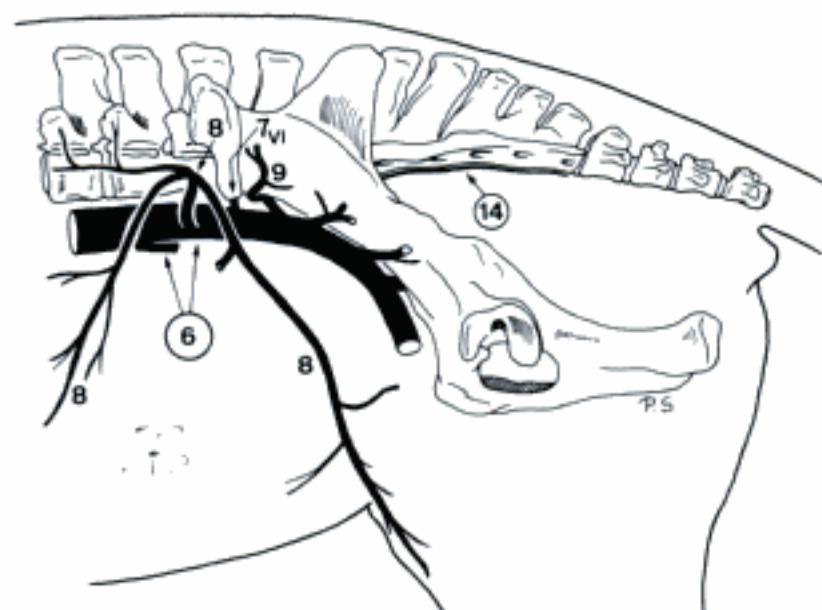


D Veins of the intestinal tract (half-schematic), right aspect (bo)

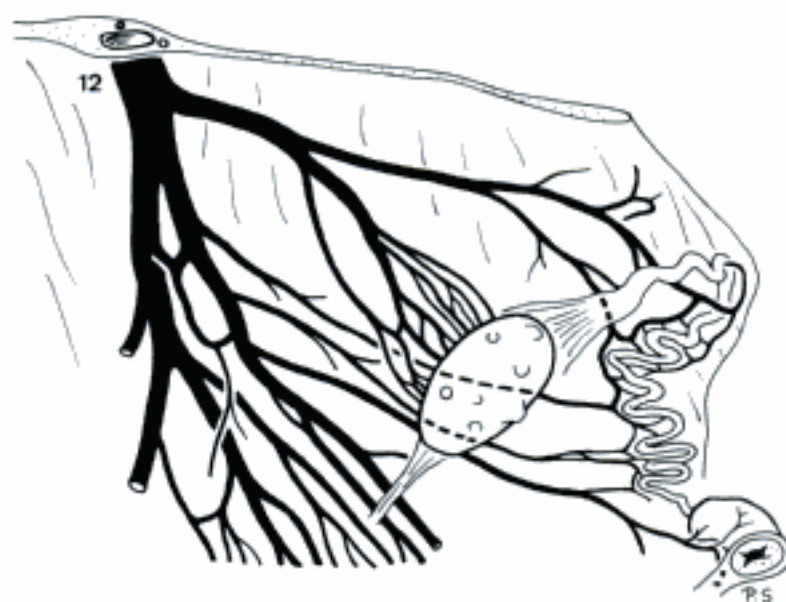
- 1 **V. mesenterica caudalis.** Unpaired, smaller terminal tributary to V. portae. Courses in mesenterium towards Colon descendens. A
- 2 *V. colica media (Ru, eq).* Drains Colon transversum and courses in Mesocolon transversum to the right in order to join V. colica dextra. A
- 3 *V. colica sinistra.* Continuation of V. mesenterica caudalis in Mesocolon descendens, close to Colon descendens, except in eq where it continues caudally in the dorsal part of mesocolon. A
- 4 *Vv. sigmoideae.* Accompany corresponding arteries. A
- 5 *V. rectalis cranialis.* Continuation of V. colica sinistra along the dorsal surface of the rectum. Anastomoses with V. rectalis (media and) caudalis. A
- 6 **V. ILIACA COMMUNIS.** Terminal branch of V. cava caudalis, courses caudolaterally to the medial aspect of Osa ilium, splits in V. iliaca externa and V. iliaca interna. Exceptionally, V. iliaca communis sinistra is absent in cap. B E
- 7 *V. lumbalis V (eq), VI (Un), VII (Car, su, ov).* Variably fused segmental veins. Accompany corresponding arteries. B E
- 8 *V. circumflexa ilium profunda (Un).* Accompanies corresponding artery. B E
- 9 *V. iliolumbalis (eq).* Accompanies corresponding artery. B
- 10 *V. testicularis sinistra (bo, ov).* Accompanies corresponding artery. D E
- 11 *Plexus pampiniformis.* Network around A. testicularis. D
- 12 *V. ovarica sinistra (bo, cap).* Courses across the dorsal aspect of aorta (bo) into mesovarium, accompanies corresponding artery. C E
- 13 *V. vesicalis cranialis (cap).* To Vesica urinaria.
- 14 **(V. sacralis mediana) (eq).** Accompanies corresponding artery. B
- 15 **V. sacralis mediana.** Variably developed in Car, su, Ru, courses along Facies pelvina of Os sacrum. Usually paired in su, sometimes (locally) in Car, cap, bo. E
- 16 *Rami sacrales.* Often initially fused, course into the corresponding Foramen sacrale pelvinum, emerge from the Foramen sacrale dorsale, joining Plexus vertebralis externus dorsalis. The last pair pierces between Os sacrum and Vertebra caudalis. I. E
- 17 *V. intervertebralis.* Connects the Ramus sacralis with Plexus vertebralis internus ventralis. E
- 18 **V. caudalis [coccygea] mediana.** Variably developed continuation of V. sacralis mediana (except eq), accompanies corresponding artery. Paired in Car, su, and sometimes cap. E
- 19 *Rami caudales [coccygei].* Accompany corresponding arteries. E
- 20 *V. intervertebralis.* Passes medially between Vertebrae caudales and connects Plexus vertebrales externi (and internus). E
- 21 *V. caudalis [coccygea] ventrolateralis.* Accompanies corresponding artery. Contributes to Plexus vertebralis externus ventralis. E
- 22 *V. caudalis [coccygea] dorsolateralis.* Accompanies corresponding artery. Contributes to Plexus vertebralis externus dorsalis. E



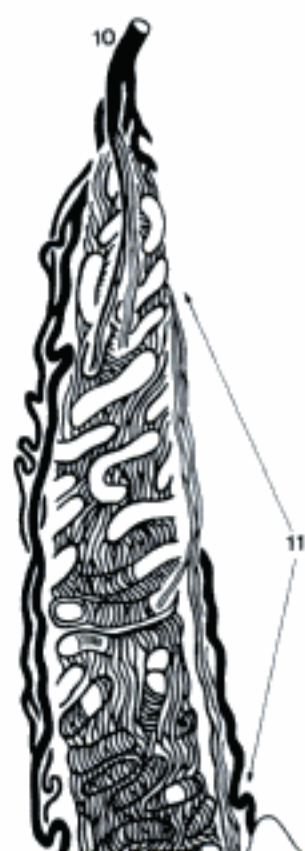
A Veins of Colon tenue and Rectum, left aspect (eq)



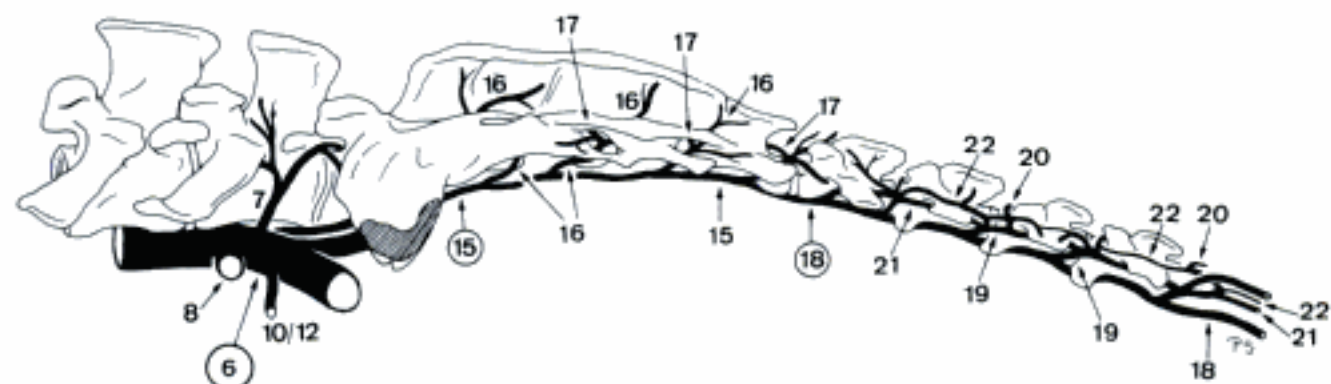
B Branches of V. iliaca communis (eq)



C Veins of left Ovarium, tuba uterina, and Cornu uteri, medial aspect (bo)

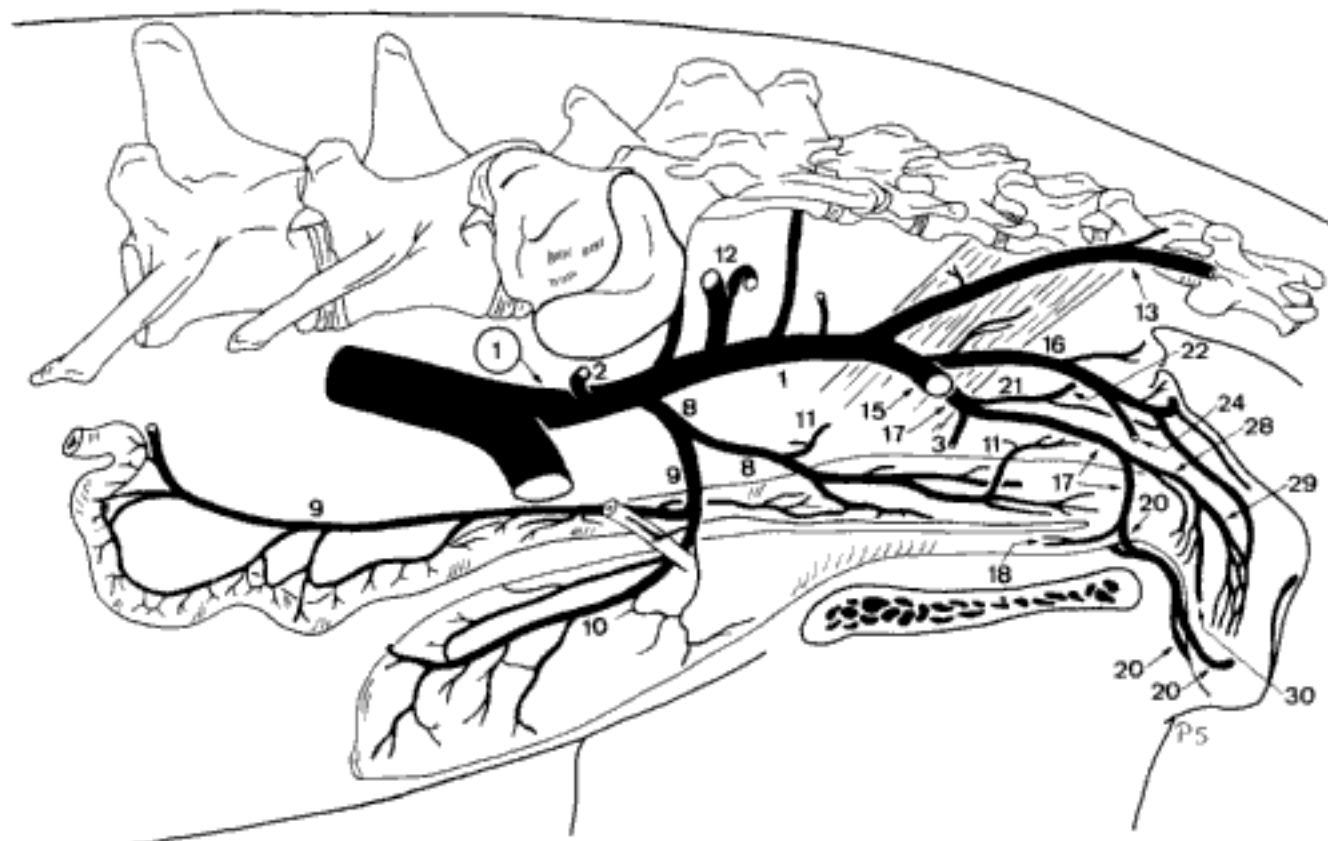


D Corrosion cast of the left V. testicularis, craniomedial aspect (bo)

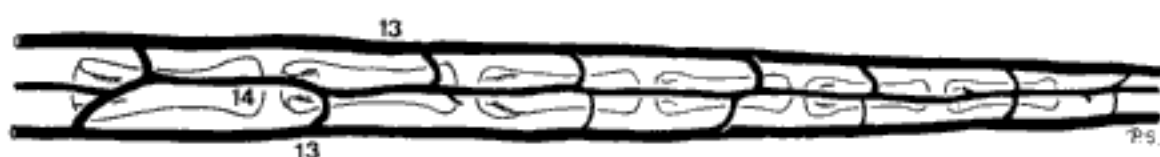

E Veins in relation to Vertebrae lumbalis V-caudalis IV, left aspect (bo)

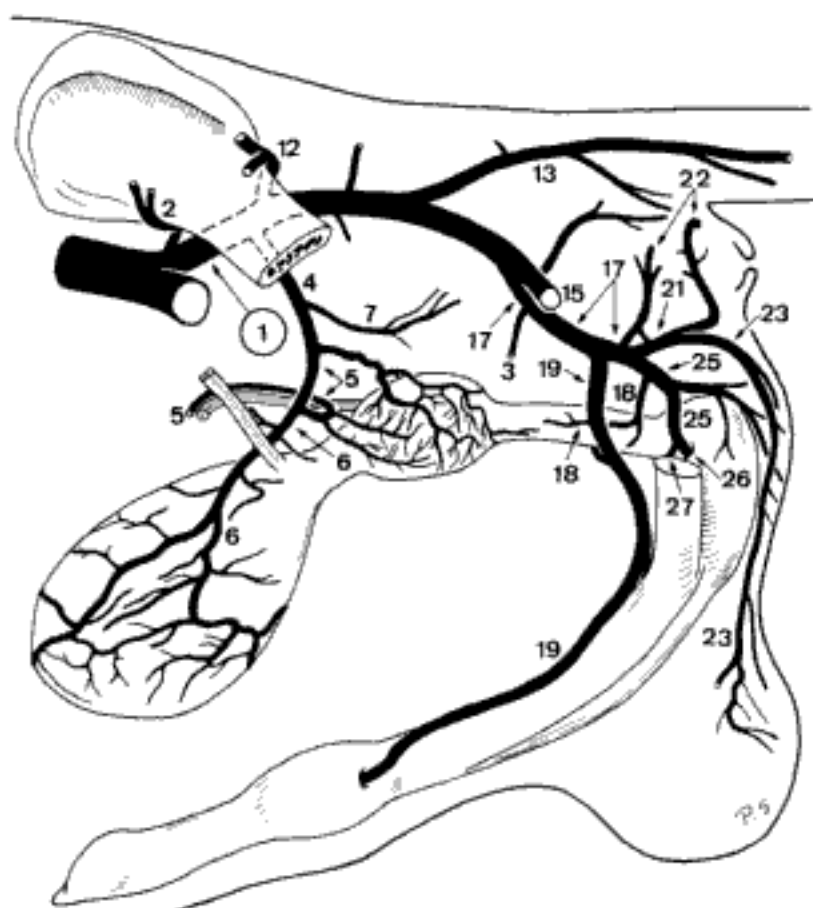
- 1 **V. ILIACA INTERNA.** Medial terminal branch of V. iliaca communis, courses into Cavum pelvis. Accompanies corresponding artery. A C
- CARNIVORA
- 2 *V. iliolumbalis.* Accompanies corresponding artery. A C
- 3 *V. obturatoria.* Branch of V. iliaca interna (fe) s. V. glutea caudalis (ca) towards Foramen obturatum. A C
- 4 *V. prostatica.* To Prostata. C
- 5 *V. ductus deferentis.* To Ductus deferens. C
- 6 *V. vesicalis caudalis.* Drains the venous plexus of Vesica urinaria. C
- 7 *V. rectalis media.* To rectum. C
- 8 *V. vaginalis.* To the lateral wall of the vagina. A
- 9 *V. uterina.* Accompanies corresponding artery. A
- 10 *V. vesicalis caudalis.* Drains the venous plexus of Vesica urinaria. A
- 11 *V. rectalis media.* To rectum. A
- 12 *V. glutea [glutaea] cranialis.* Accompanies corresponding artery. A C
- 13 *V. caudalis [coccygea] lateralis.* Accompanies corresponding artery. A B C
- 14 *V. caudalis [coccygea] dorsalis (fe).* Unpaired, formed by tributaries from the left and right Vv. caudales laterales, located at the dorsal surface of the tail. B
- 15 *V. glutea [glutaea] caudalis.* Accompanies corresponding artery. A C
- 16 *V. perinealis dorsalis.* Drains the dorsal part of perineum. A
- 17 *V. pudenda interna.* Accompanies corresponding artery. A C
- 18 *V. urethralis.* Drains the pelvic part of the urethra. A C
- 19 *V. dorsalis penis.* Accompanies corresponding artery. The left and right are united for a short distance at Arcus ischiadicus. C
- 20 *V. dorsalis clitoridis.* Accompanies corresponding artery. The left and right are fused for a short distance at Arcus ischiadicus. A
- 21 *V. perinealis ventralis.* To perineum and anus. A C
- 22 *V. rectalis caudalis.* Accompanies corresponding artery, often accompanied by a branch of V. pudenda interna (ca). A C
- 23 *V. scrotalis dorsalis.* Often accompanied by branches of V. penis. C
- 24 *V. labialis dorsalis.* Accompanies corresponding artery (ca). A
- 25 *V. penis.* Accompanies corresponding artery. Common trunk for V. bulbi penis and V. profunda penis. C
- 26 *V. bulbi penis.* Accompanies corresponding artery. C
- 27 *V. profunda penis.* Accompanies corresponding artery. C
- 28 *V. clitoridis.* Accompanies corresponding artery. Common trunk for V. bulbi vestibuli and V. profunda clitoridis. A
- 29 *V. bulbi vestibuli.* Drains Bulbus vestibuli. A
- 30 *V. profunda clitoridis.* Fuses with its counterpart (ca), drains Corpus cavernosum clitoridis with several branches. A



A Veins in Cavum pelvis, left aspect (ca fem)



B Veins in relation to Vertebrae caudales XII–XVII, dorsal aspect (fe)



C Veins of genital organs, left aspect (ca masc)

SUS

- 1 *V. iliolumbalis*. Accompanies corresponding artery. A B
- 2 *V. glutea [glutaea] cranialis*. Accompanies corresponding artery. A B
- 3 *V. prostatica*. Accompanies corresponding artery. A
- 4 *V. vesicalis caudalis*. Accompanies corresponding artery. A
- 5 *V. vaginalis*. Accompanies corresponding artery. B
- 6 *Ramus uterinus*. Accompanies corresponding artery. B
- 7 *V. vesicalis caudalis*. Accompanies corresponding artery. B
- 8 *V. obturatoria*. Accompanies corresponding artery. Usually connected with *V. profunda femoris* and *V. penis s. clitoridis*. A B
- 9 *V. glutea [glutaea] caudalis*. Accompanies corresponding artery. A B
- 10 *V. perinealis dorsalis*. Branch of *V. iliaca interna* and/or *V. caudalis dorsolateralis* to perineum. A B
- 11 *V. rectalis caudalis*. Drains *Canalis analis*. A B
- 12 *V. pudenda interna*. Accompanies corresponding artery. A B
- 13 *V. perinealis ventralis*. Passes to perineum. A B
- 14 *V. scrotalis dorsalis*. Drains the dorsal segment of scrotum. Accompanied by branches of *V. bulbi penis*. A
- 15 *V. labialis dorsalis*. Drains *Labium pudendi*. Accompanied or replaced by branches of *V. perinealis dorsalis*. B
- 16 *V. penis*. At *Arcus ischiadicus* connected with its counterpart by a large cranial branch, which continues into *V. obturatoria* and *V. profunda femoris*. A
- 17 *V. bulbi penis*. Drains *Corpus spongiosum penis*. A
- 18 *V. profunda penis*. Drains *Corpus cavernosum penis*. A
- 19 *V. dorsalis penis*. Accompanies corresponding artery. Usually bilaterally asymmetrical or only unilaterally represented in its initial segment. A
- 20 *V. clitoridis*. Accompanies corresponding artery. At *Arcus ischiadicus* connected with its counterpart by a large cranial branch, which continues into *V. obturatoria* and *V. profunda femoris*. B
- 21 *V. bulbi vestibuli*. Courses to *Bulbus vestibuli*. B
- 22 *V. profunda clitoridis*. Drains *Corpus cavernosum clitoridis*. B
- 23 *V. dorsalis clitoridis*. Variably developed, along the ventral surface of *Corpus clitoridis*. B

Hidden page

RUMINANTIA

- 1 *V. uterina (bo)*. Slender, inconstant, accompanies A. uterina into the uterine venous network. B
- 2 *V. iliolumbalis*. Accompanies corresponding artery. A B
- 3 *V. glutea [glutaea] cranialis*. Accompanies corresponding artery. A B
- 4 *V. obturatoria*. Courses to Foramen obturatum. May be double and arise from *V. pudenda interna (bo)*. A B
- 5 *V. vaginalis accessoria (bo)*. Often double, to vagina. B
- 6 *V. prostatica*. Accompanies corresponding artery. A
- 7 *V. ductus deferentis*. Accompanies corresponding artery. A
- 8 *V. vesicalis caudalis*. Drains the venous plexus of Vesica urinaria. A
- 9 *V. vaginalis*. Accompanies corresponding artery. B
- 10 *Ramus uterinus*. Accompanies corresponding artery, contributes to the uterine venous network. Plexiform in bo. B
- 11 *V. vesicalis caudalis*. Drains the venous plexus of Vesica urinaria. B
- 12 *V. rectalis media*. To the rectum (bo, cap) (branch of *V. prostatica*, in the male). Often unilaterally absent. B
- 13 *V. perinealis dorsalis*. To perineum (branch of *V. prostatica* in the male). B
- 14 *V. rectalis caudalis*. Accompanies corresponding artery. Variable in shape and origin. B
- 15 *V. labialis dorsalis*. Accompanies corresponding artery. B
- 16 *V. glutea [glutaea] caudalis*. Accompanies corresponding artery. A B
- 17 *V. pudenda interna*. Accompanies corresponding artery. Connected with its counterpart at Arcus ischiadicus in the female. A B
- 18 *V. rectalis caudalis (bo masc, ov)*. Accompanies corresponding artery. Variable in shape and origin. A
- 19 *V. vestibularis (bo)*. Accompanies corresponding artery. B
- 20 *V. perinealis ventralis*. To perineum. A B
- 21 *V. labialis dorsalis et mammaria*. Accompanies corresponding artery, joins *V. labialis ventralis [mammaria caudalis]*. May fuse with its counterpart, or be absent unilaterally (bo). B
- 22 *V. penis*. Accompanies corresponding artery. Joins or anastomoses with its counterpart at Arcus ischiadicus. A
- 23 *V. bulbi penis*. Drains Corpus spongiosum penis. A
- 24 *V. profunda penis*. Drains Corpus cavernosum penis. A
- 25 *V. dorsalis penis*. Unpaired, on Dorsum penis. Especially in ov and cap reinforced at Flexura sigmoidea penis by a large unpaired branch of *V. pudenda externa*. The unpaired caudal portion of *V. dorsalis penis* may be lacking (cap). A
- 26 *V. clitoridis*. Accompanies corresponding artery. B
- 27 *V. bulbi vestibuli (ov, cap)*. Drains Bulbus vestibuli.
- 28 *V. profunda clitoridis*. Drains Corpus cavernosum clitoridis. B
- 29 *V. dorsalis clitoridis*. Along the ventral border of Corpus clitoridis. B

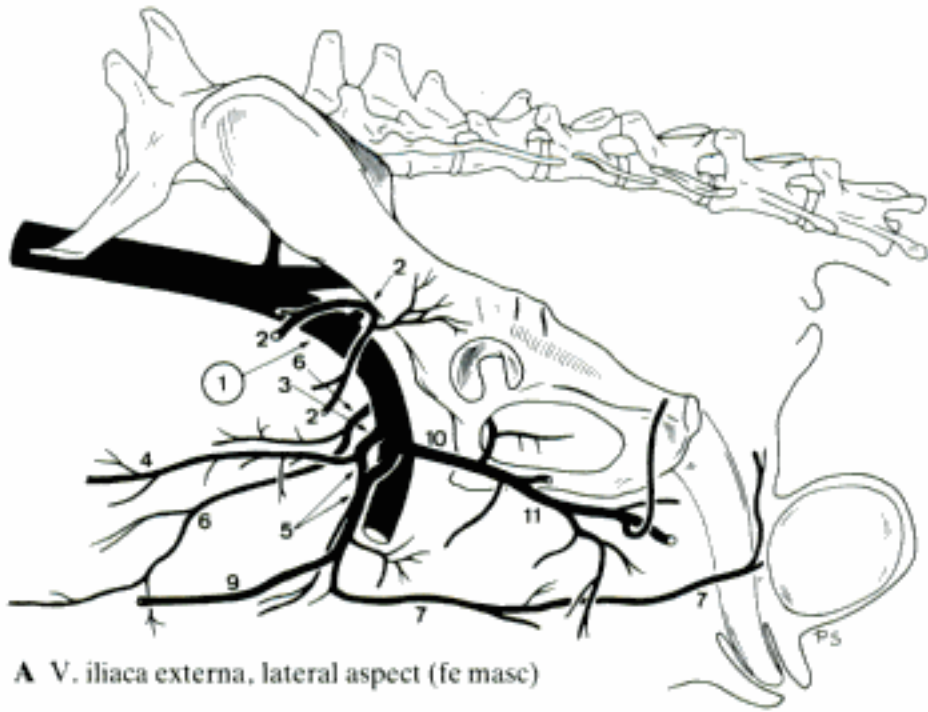
Hidden page

EQUUS

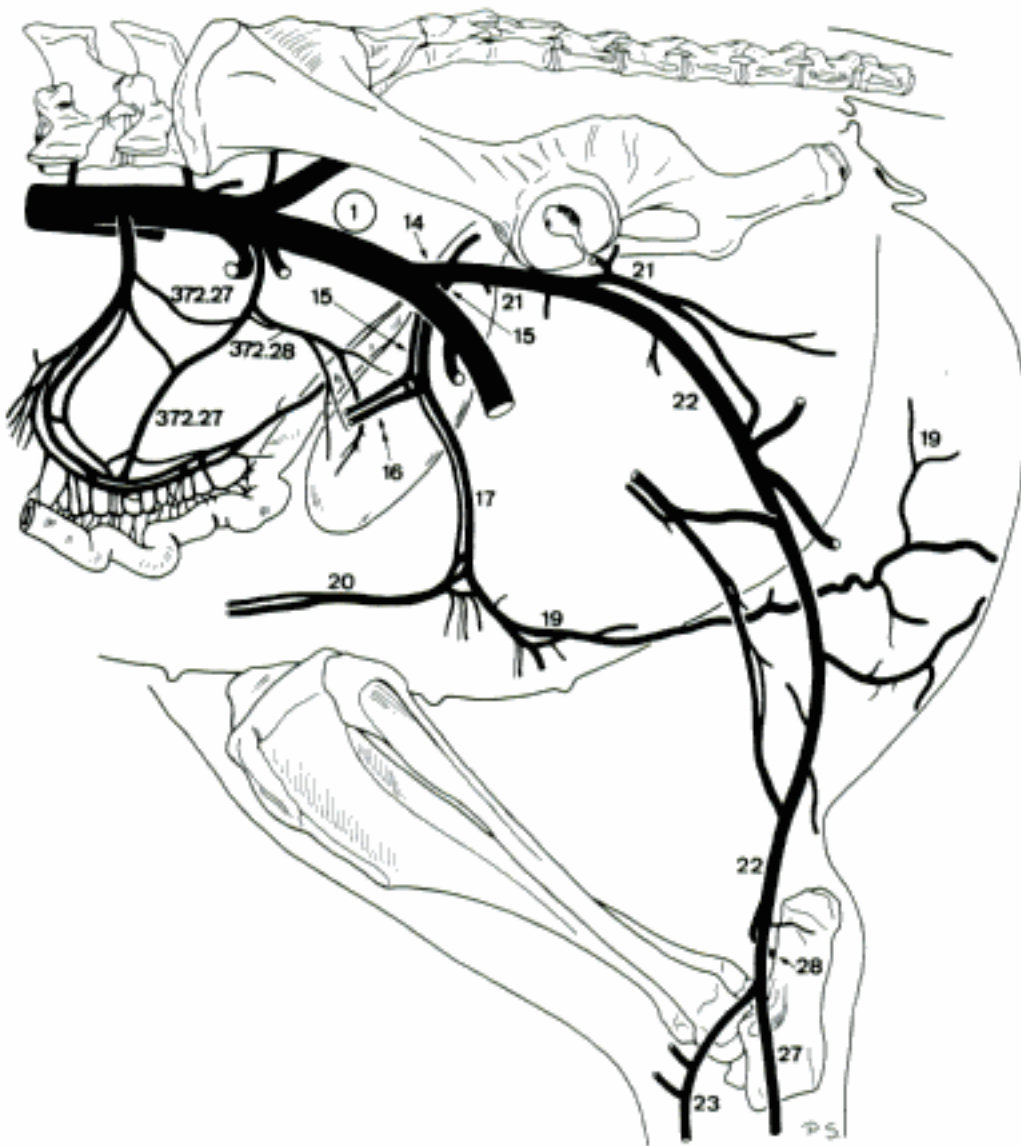
- 1 *V. glutea [glutaea] caudalis*. Accompanies corresponding artery. A B
- 2 *V. glutea [glutaea] cranialis*. Accompanies corresponding artery. A B
- 3 *Rami sacrales*. Course into Foramen sacrale pelvinum, emerge from Foramen sacrale dorsale, joining Plexus vertebralis externus dorsalis. Ramus sacralis I arises from *V. iliaca interna*. A B
- 4 *V. intervertebralis*. Arises in Canalis sacralis, connects Ramus sacralis with Plexus vertebralis internus ventralis. A
- 5 *V. caudalis [coccygea] mediana*. Unpaired, arises from the left or right *V. glutea caudalis* or is formed by the fusion of asymmetrical branches of both *Vv. gluteae caudales*. Seldom given off by *V. sacralis mediana*. A
- 6 *V. caudalis [coccygea] ventrolateralis*. Accompanies corresponding artery. Contributes to Plexus vertebralis externus ventralis. A B
- 7 *Rami caudales [coccygei]*. Accompany corresponding arteries. A
- 8 *V. intervertebralis*. Medial branch of Ramus caudalis, passes between Vertebrae caudales, connects the Plexus vertebrales externi with internus ventralis. A
- 9 *V. caudalis [coccygea] dorsolateralis*. Accompanies corresponding artery. Contributes to Plexus vertebralis externus dorsalis. A
- 10 *V. pudenda interna*. Accompanies corresponding artery. The caudal segment is usually accompanied by a parallel vein which courses along the lateral surface of Ligamentum sacrotuberale latum and joins the main vein again at Foramen ischiadicum minus. A B
- 11 *V. prostatica*. To Prostata. A
- 12 *Ramus ductus deferentis*. Accompanies corresponding artery. A
- 13 *V. vesicalis caudalis*. Arises from Ramus ductus deferentis and drains the venous plexus of Vesica urinaria. A
- 14 *V. rectalis media*. To the rectum. A
- 15 *V. vaginalis*. Accompanies corresponding artery. B
- 16 *Ramus uterinus*. To Cervix et Corpus uteri. B
- 17 *V. vesicalis caudalis*. Arises from Ramus uterinus, drains the venous plexus of Vesica urinaria. B
- 18 *V. rectalis media*. Arises from *V. vesicalis caudalis* or *V. vaginalis*, to the rectum. B
- 19 *V. perinealis ventralis*. To perineum. A B
- 20 *V. rectalis caudalis*. To the rectum. A B
- 21 *V. penis*. To Radix penis. A
- 22 *V. bulbi penis*. Enters Bulbus penis, drains Corpus spongiosum penis. A
- 23 *V. profunda penis*. Drains Corpus cavernosum penis. A
- 24 *V. dorsalis penis*. Very slender, along the caudal segment of Dorsum penis. Reinforced by *V. penis media*, continues upon Dorsum penis, and, receiving the multiple *V. penis cranialis*, forms a complex of large coiled veins that drain Corpora spongiosa penis and glandis and Corpus cavernosum penis. A
- 25 *V. clitoridis*. Continuation of *V. pudenda interna*. B
- 26 *V. bulbi vestibuli*. Drains Bulbus vestibuli. B
- 27 *V. profunda clitoridis*. Drains Corpus cavernosum clitoridis. B
- 28 *V. dorsalis clitoridis*. Curves along the ventral border of Corpus clitoridis. B

Hidden page

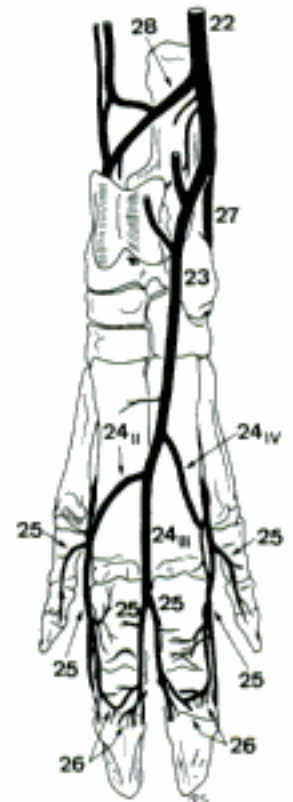
- 1 **V. ILIACA EXTERNA.** Lateral terminal branch of V. iliaca communis, courses to Lacuna vasorum along the cranial aspect of Corpus ossis ilium. A B
- CARNIVORA
- 2 *V. abdominalis caudalis.* Courses into the caudolateral abdominal wall. A
 - 3 *V. pudendoepigastrica.* Trunk for V. pudenda externa and V. epigastrica caudalis. A
 - 4 *V. epigastrica caudalis.* Accompanies corresponding artery. A
 - 5 *V. pudenda externa.* Accompanies corresponding artery. A
 - 6 *V. vesicalis media (fe).* Courses in Ligamentum vesicae laterale to Vesica urinaria. May arise from V. epigastrica caudalis or from a muscular branch of V. iliaca externa. A
 - 7 *V. scrotalis ventralis.* Drains scrotum. A
 - 8 *V. labialis ventralis.* To Labium pudendi, drains also the inguinal mamma.
 - 9 *V. epigastrica caudalis superficialis.* Accompanies corresponding artery, joins V. epigastrica cranialis superficialis. Drains Mammae abdominales and inguinalis. A
 - 10 *V. profunda femoris.* Courses along the medial surface of M. iliopsoas. A
 - 11 *V. circumflexa femoris medialis.* Continuation of V. profunda femoris. Accompanies corresponding artery. A
- SUS
- 12 *V. ductus deferentis.* Drains the terminal segment of Ductus deferens.
 - 13 *V. vesicalis cranialis.* To Vesica urinaria.
 - 14 *V. profunda femoris.* Trunk for V. pudendoepigastrica and V. circumflexa femoris medialis. B
 - 15 *V. pudendoepigastrica.* Double trunk for V. pudenda externa and V. epigastrica caudalis. B
 - 16 *V. epigastrica caudalis.* Accompanies corresponding artery. B
 - 17 *V. pudenda externa.* Accompanies corresponding artery. B
 - 18 *V. scrotalis ventralis.* Double branch of V. pudenda externa along the corresponding artery.
 - 19 *V. labialis ventralis.* Branch of V. pudenda externa along the corresponding artery. B
 - 20 *V. epigastrica caudalis superficialis.* Subcutaneous branch of V. pudenda externa, accompanies corresponding artery. Drains the caudal mammae s. preputium. B
 - 21 *V. circumflexa femoris medialis.* Double continuation of V. profunda femoris. Accompanies corresponding artery. B
 - 22 *V. saphena lateralis [parva].* Courses between M. biceps femoris and M. semitendinosus, along the caudal aspect of M. gastrocnemius to the craniolateral surface of Tendo calcaneus communis. B C
 - 23 *Ramus cranialis.* Superficial branch of V. saphena lateralis, courses across the lateral aspect of tarsus, joins the branches of Ramus cranialis of V. saphena medialis at Collum tali, continues along the dorsal surface of tarsus and the proximal half of metatarsus. B C
 - 24 *Vv. digitales dorsales communes II–IV.* Superficial branches of Ramus cranialis of V. saphena lateralis. Connected with the respective V. metatarsae dorsalis. C
 - 25 *Vv. digitales dorsales propriae.* Arise from the bifurcation of Vv. digitales dorsales communes II–IV. Accompany corresponding arteries. C
 - 26 *V. coronalis.* Branch of Vv. digitales dorsales propriae III et IV (axiales et abaxiales), course in the dorsal segment of Corona unguulae. C
 - 27 *Ramus caudalis.* Continuation of V. saphena lateralis along the lateroplantar aspect of tarsus, joins V. plantaris lateralis. B C
 - 28 *Ramus anastomoticus cum v. saphena mediali [magna].* Branch of V. saphena lateralis or Ramus caudalis, courses across the plantar aspect of M. flexor digitorum profundus, joins Ramus caudalis of V. saphena medialis at Sustentaculum tali. B C



A V. iliaca externa, lateral aspect (fe masc)



B V. iliaca externa, lateral aspect (su fem)



C Veins of left pes, dorsal aspect (su)

RUMINANTIA

- 1 *V. profunda femoris*. Accompanies corresponding artery. A
- 2 *V. pudendoepigastrica*. Trunk for *V. pudenda externa* and *V. epigastrica caudalis*. A
- 3 *V. abdominalis caudalis*. Accompanies corresponding artery. A
- 4 *V. epigastrica caudalis*. Accompanies corresponding artery. A
- 5 *V. cremasterica*. Arises variably, accompanies corresponding artery. A
- 6 *V. pudenda externa*. Accompanies corresponding artery. A C
- 7 *V. scrotalis ventralis*. To scrotum. A
- 8 *V. labialis ventralis* [mammaria caudalis]. Branch of *V. pudenda externa* on the lateral surface of the udder, continues in Regio supramammaria towards Labium pudendi. C
- 9 *V. epigastrica caudalis superficialis* [mammaria cranialis]. Branch of *V. pudenda externa* on the craniolateral aspect of the udder in the female, continues in the ventral abdominal wall, joins *V. epigastrica cranialis superficialis*. A C
- 10 *V. circumflexa femoris medialis*. Accompanies corresponding artery. A
- 11 *V. saphena lateralis* [parva]. Courses between *M. gluteobiceps* and *M. semitendinosus* along the caudal aspect of *M. gastrocnemius* to the craniolateral surface of *Tendo calcaneus communis*. A
- 12 *Ramus cranialis*. Branch of *V. saphena lateralis* across the lateral aspect of tarsus, receives a branch of *V. tibialis cranialis*, continues along the dorsal surface of tarsus and metatarsus. B
- 13 *Vv. digitales dorsales communes* III et IV (ov, cap), II–IV (bo). Branches of *Ramus cranialis* of *V. saphena lateralis*. II and IV join *Arcus plantaris profundus distalis*, III joins *V. metatarsea dorsalis III* and *V. interdigitalis*. B
- 14 *Vv. digitales dorsales propriae*. Arise from the bifurcation of *V. digitalis dorsalis communis III*, course along the axial tendons of *M. extensor digitorum longus*. B
- 15 *V. coronalis*. Branch of *V. digitalis dorsalis propria*, courses in *Sulcus coronalis* of ungula. B
- 16 *Ramus caudalis*. Continuation of *V. saphena lateralis* over the lateroplantar surface of tarsus, joins *V. plantaris lateralis*. B
- 17 *Ramus anastomoticus cum V. saphena mediali* [magna]. Branch of *Ramus caudalis* of *V. saphena lateralis*, courses across the dorsal aspect of *Tuber calcanei*, joins *V. saphena medialis*. B

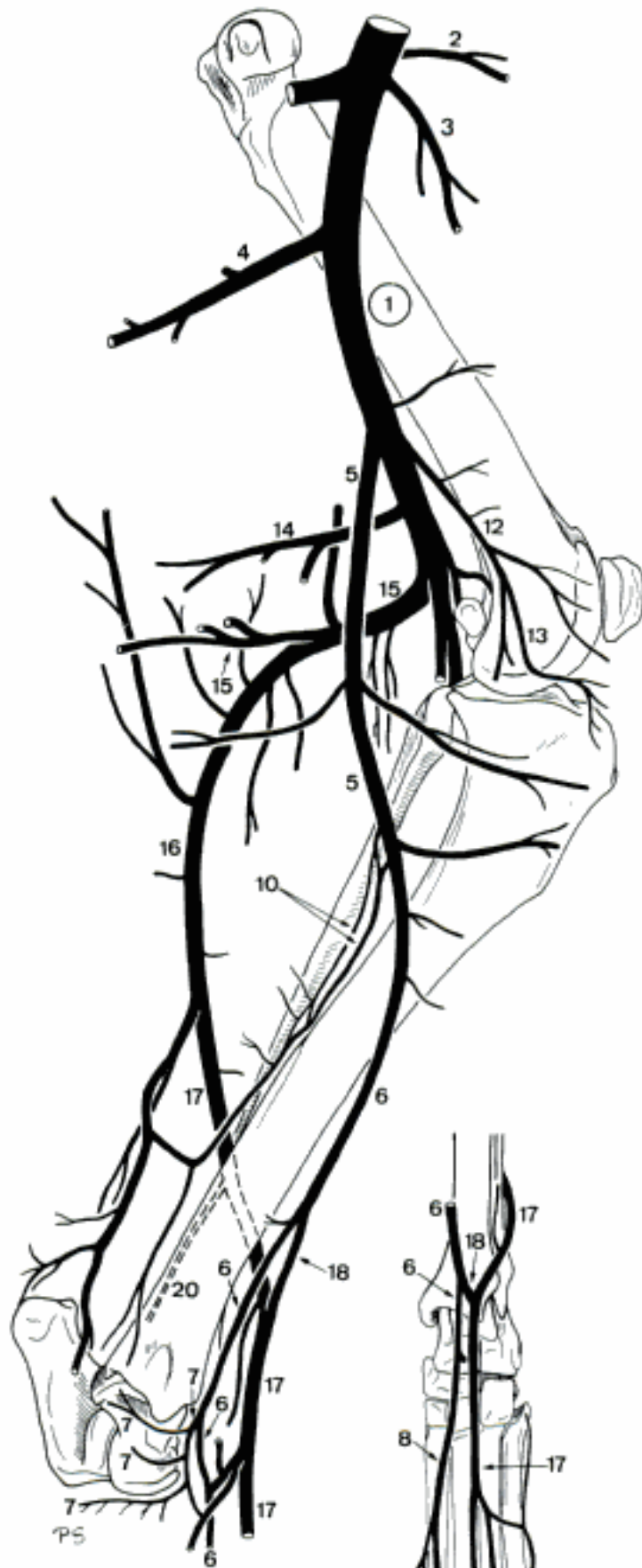
EQUUS

- 18 *V. ductus deferentis*. To the abdominal part of *Ductus deferens*.
- 19 *V. uterina*. Accompanies *A. uterina*.
- 20 *V. iliocofemoralis*. Courses along the cranial aspect of *Corpus ossis ilium*. Usually double. D E
- 21 *V. obturatoria*. Courses along the medial aspect of *Corpus ossis ilium*, passes through *Foramen obturatum*. D E
- 22 *V. penis media*. To the caudal part of *Dorsum penis*, joins *V. dorsalis penis*. E
- 23 *V. clitoridis media*. Anastomoses with its counterpart at the ventral aspect of *Arcus ischiadicus*, pierces between *Crura clitoridis*, drains *Corpus cavernosum clitoridis*. D
- 24 *V. profunda femoris*. Accompanies corresponding artery. D E
- 25 *V. pudendoepigastrica*. Inconstant. Trunk for *V. pudenda externa* and *V. epigastrica caudalis*. D E
- 26 *V. epigastrica caudalis*. Double. Accompanies corresponding artery. D E
- 27 *V. pudenda externa*. Accompanies corresponding artery. Generally complemented by a branch of *V. profunda femoris*, which perforates the cranial segment of *M. gracilis* and forms a large network at the dorsal aspect of the penis s. uber. D E
- 28 *V. scrotalis ventralis*. Branch of *V. pudenda externa* or its inguinal network to the scrotum. E
- 29 *V. penis cranialis*. Branches of *V. pudenda externa* and its complementary vein to *Dorsum penis*. E
- 30 *V. labialis ventralis* [mammaria caudalis]. Branch of *V. pudenda externa* and the complementary vein, to Regio supramammaria and Labium pudendi. D
- 31 *V. epigastrica caudalis superficialis* [mammaria cranialis]. Branch of *V. pudenda externa* to Regio abdominis caudalis, anastomoses with *V. epigastrica cranialis superficialis*. D E
- 32 *V. circumflexa femoris medialis*. Accompanies corresponding artery. D E

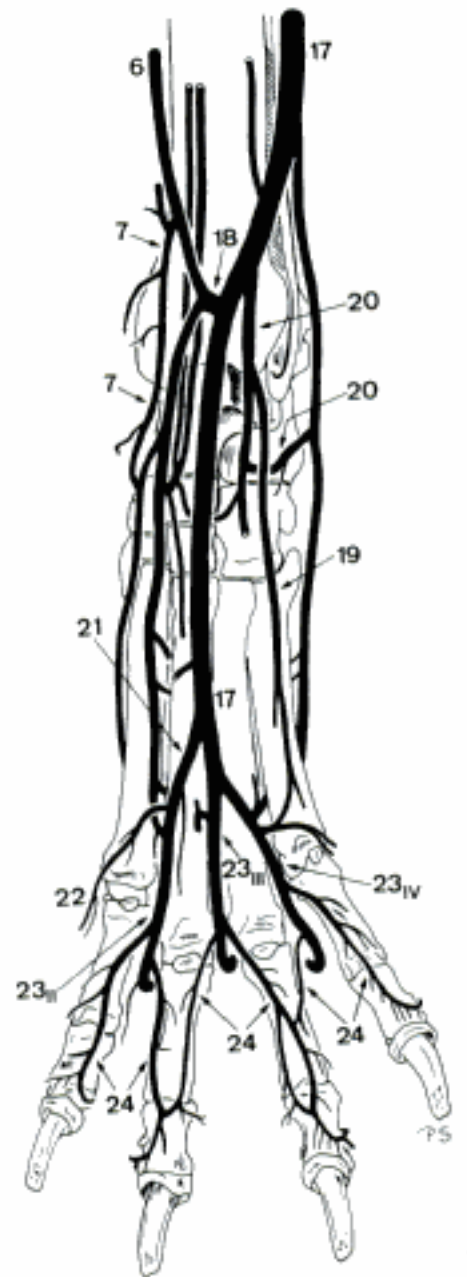
Hidden page

CARNIVORA

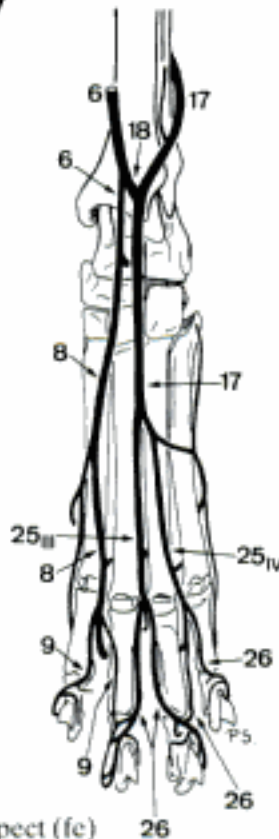
- 1 **V. femoralis.** Continuation of V. iliaca externa beyond Lacuna vasorum. Courses caudal to A. femoralis. A
- 2 *V. circumflexa ilium superficialis (ca).* Accompanies corresponding artery. A
- 3 *V. circumflexa femoris lateralis.* Accompanies corresponding artery. A
- 4 *V. caudalis femoris proximalis.* Accompanies corresponding artery. A
- 5 *V. saphena medialis [magna].* Accompanies A. saphena. A
- 6 *Ramus cranialis.* Accompanies corresponding artery, joins Ramus cranialis of V. saphena lateralis or its Ramus anastomoticus, continues at the dorsomedial surface of the tarsus, anastomoses with V. dorsalis pedis. Continues dorsal to Os metatarsale II as V. digitalis dorsalis communis II (fe), as the medial root of Arcus dorsalis superficialis (ca). A B C
- 7 *V. tarsea medialis (ca).* Curves to the medial and plantar aspect of the tarsus, where it ramifies. Sends a branch along the medioplantar surface of the metatarsus to Arcus plantaris superficialis. A B
- 8 *V. digitalis dorsalis communis II (fe).* C
- 9 *Vv. digitales dorsales propriae.* Arise from the bifurcation of V. digitalis dorsalis communis II. C
- 10 *Ramus caudalis.* Accompanies corresponding artery. Ramifies at the medioplantar aspect of the tarsus. A D
- 11 *V. plantaris medialis (fe).* Courses along the medioplantar surface of metatarsus into Arcus plantaris superficialis. D
- 12 *V. genus descendens.* Accompanies corresponding artery. A
- 13 *Ramus articularis genus.* Drains Articulatio genus and Corpus adiposum infrapatellare. A
- 14 *V. caudalis femoris media.* Accompanies corresponding artery. A
- 15 *V. caudalis femoris distalis.* Accompanies corresponding artery. A
- 16 *V. saphena lateralis [parva].* Courses along the M. gastrocnemius, becomes subcutaneous by piercing between M. biceps femoris and M. semitendinosus, continues in Regio cruris lateralis. A
- 17 *Ramus cranialis.* Courses across Regio cruris lateralis and the dorsal surface of the tarsus and metatarsus. A B C
- 18 *Ramus anastomoticus cum v. saphena mediali [magna].* Branch of Ramus cranialis of V. saphena lateralis, joins Ramus cranialis of V. saphena medialis. A B C
- 19 *V. digitalis dorsalis V abaxialis (ca).* Branch of Ramus cranialis of V. saphena lateralis along the abaxial border of Os metatarsale V. B
- 20 *V. tarsea lateralis (ca).* Branch of Ramus cranialis of V. saphena lateralis to the lateral and plantar aspect of the tarsus, anastomoses with Ramus caudalis of V. saphena lateralis. A B
- 21 *Arcus dorsalis superficialis (ca).* Variably shaped connection between Ramus cranialis of Vv. saphenae lateralis and medialis. B
- 22 *V. digitalis dorsalis II abaxialis.* Branch of Arcus dorsalis superficialis. B
- 23 *Vv. digitales dorsales communes II-IV.* Branches of Arcus dorsalis superficialis, accompany corresponding arteries. B
- 24 *Vv. digitales dorsales propriae.* Accompany corresponding arteries. B
- 25 *Vv. digitales dorsales communes III et IV (fe).* Branches of Ramus cranialis of V. saphena lateralis. Accompany corresponding arteries. C
- 26 *Vv. digitales dorsales propriae.* Arise from the bifurcation of Vv. digitales dorsales communes III et IV. Accompany corresponding arteries. C



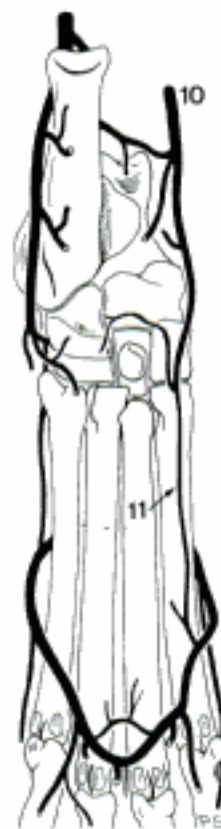
A Veins of left pelvic limb, medial aspect (ca)



B Veins of left pes, dorsal aspect (ca)

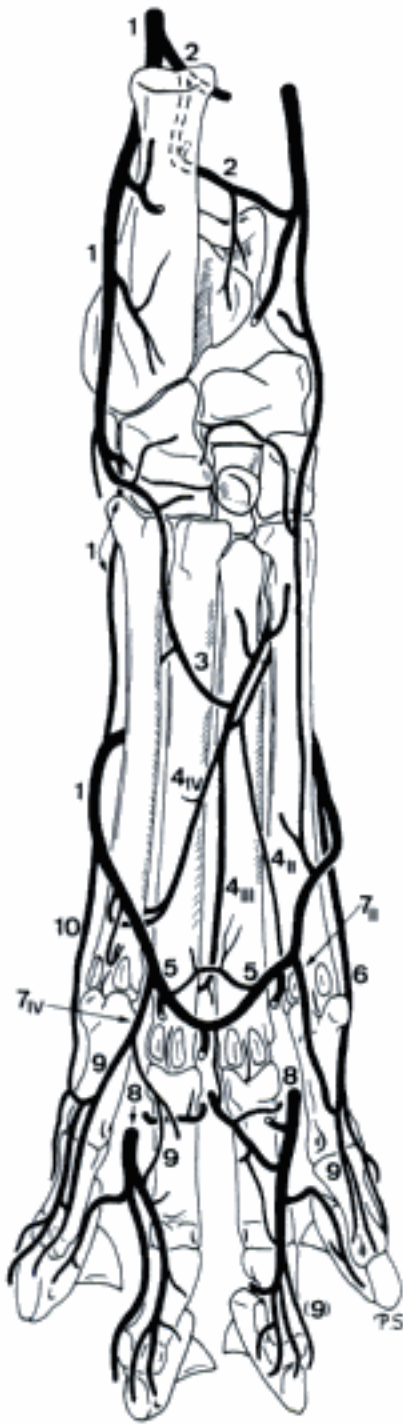

C Veins of left pes, dorsal aspect (fe)

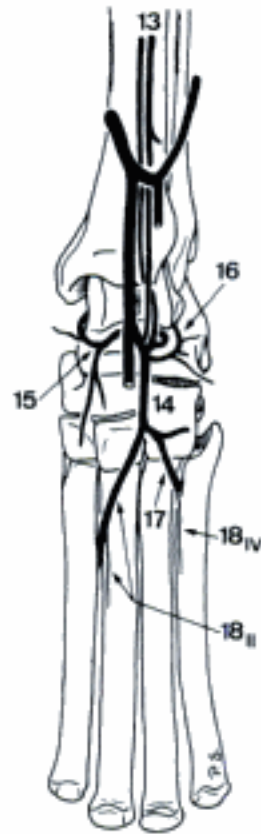


D Veins of left pes, plantar aspect (fe)

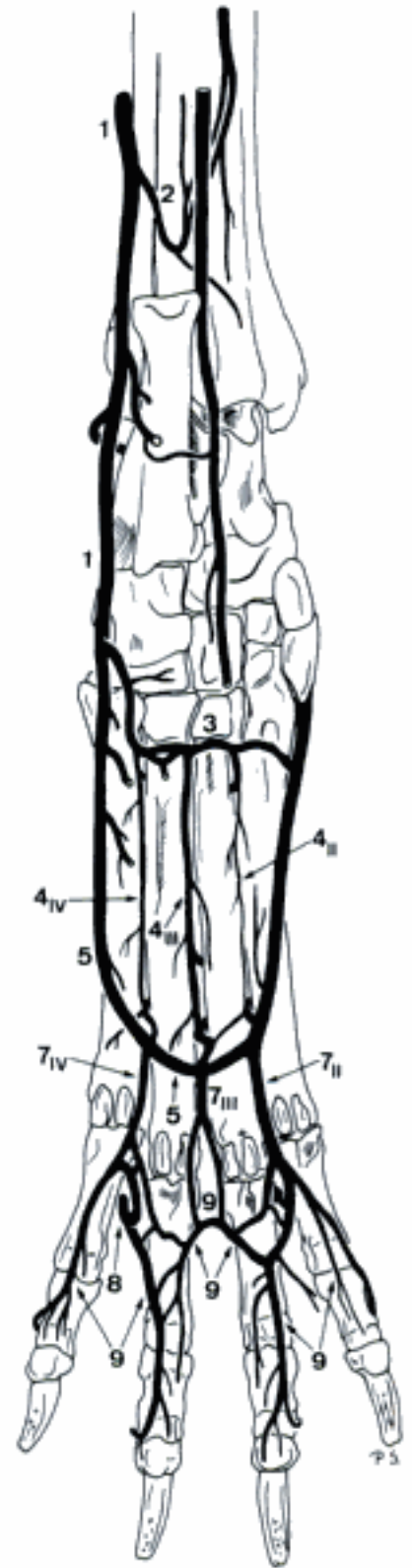
Hidden page



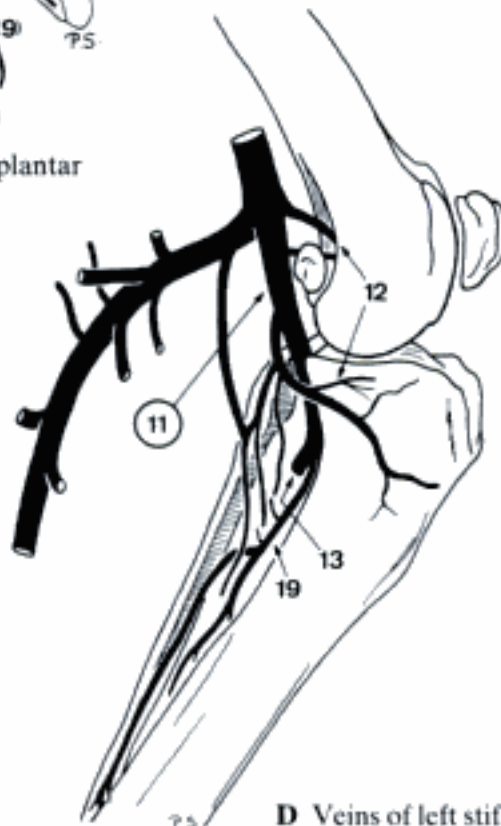
A Veins of left pes, plantar aspect (fe)



B Veins of left tarsus and metatarsus, dorsal aspect (fe)

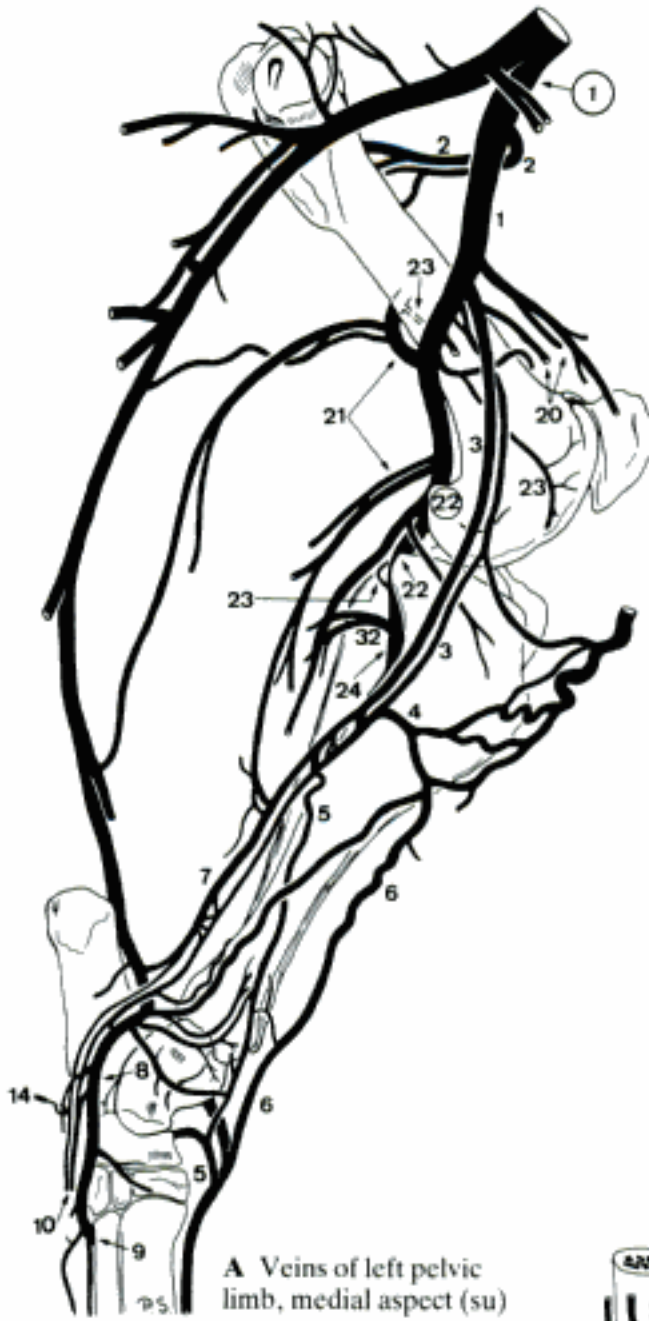

C Veins of left pes, plantar aspect (ca)

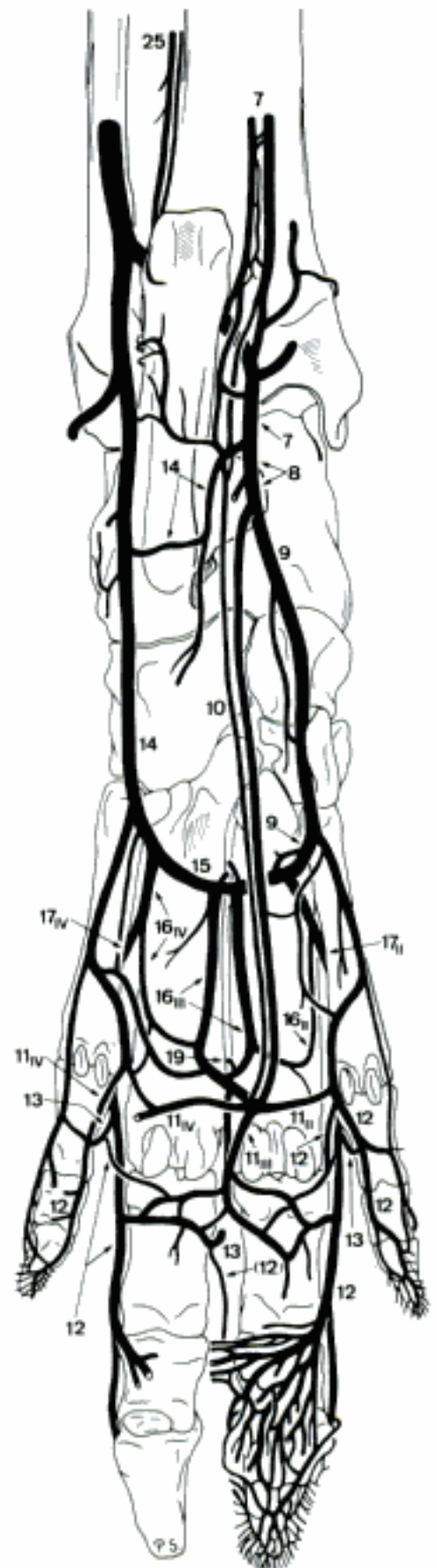


D Veins of left stifle, medial aspect (ca)

Hidden page



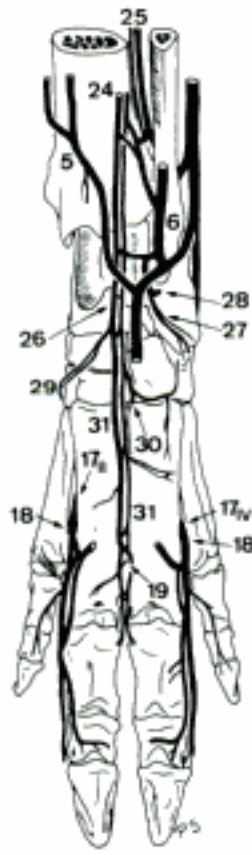
A Veins of left pelvic limb, medial aspect (su)



B Veins of left pes, plantar aspect (su)



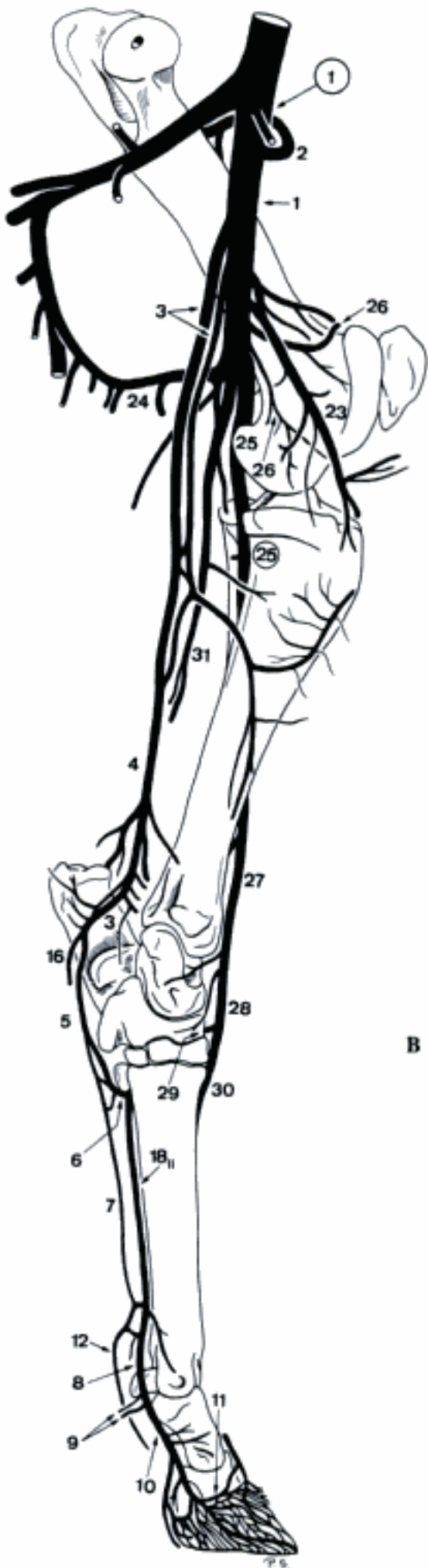
D Veins of left pes, lateral aspect (su)



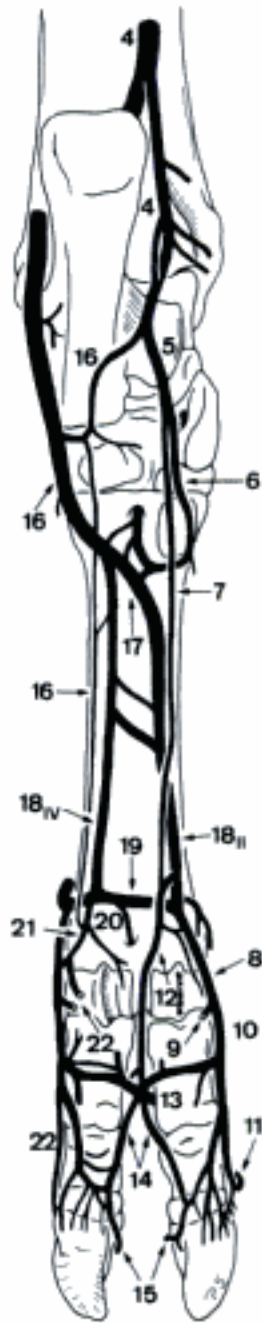
C Veins of left pes, dorsal aspect (su)

RUMINANTIA

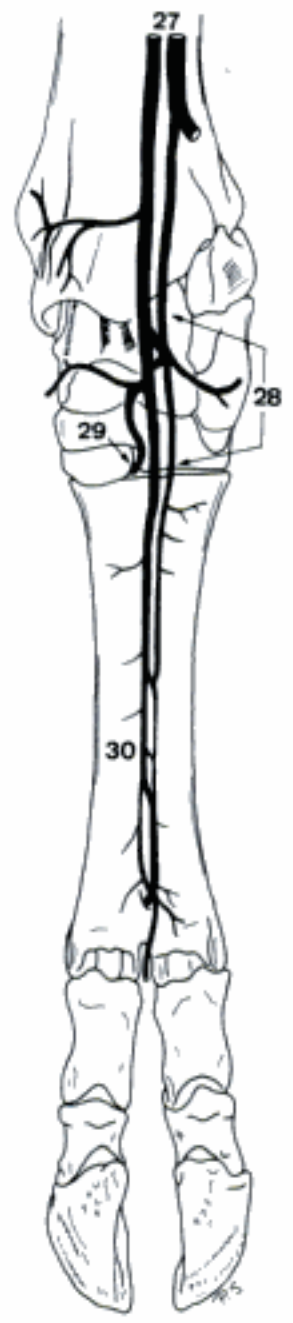
- 1 **V. femoralis**. Continuation of V. iliaca externa, accompanies corresponding artery. A
- 2 *V. circumflexa femoris lateralis*. Accompanies corresponding artery. A
- 3 *V. saphena medialis [magna]*. Pierces between M. sartorius and M. gracilis, courses superficially towards Articulatio genus. A
- 4 *Ramus caudalis*. Continuation to the medioplantar aspect of tarsus. A B
- 5 V. plantaris medialis. Accompanies corresponding artery. A B
- 6 Ramus profundus. Accompanies corresponding artery. A B
- 7 Ramus superficialis (bo). Accompanies corresponding artery. A B D
- 8 V. digitalis plantaris communis II. Medial continuation of Ramus superficialis of V. plantaris medialis, reinforced by a large connection with Arcus plantaris profundus distalis. Accompanies corresponding artery. A B D
- 9 V. digitalis plantaris propria II axialis. Accompanies corresponding artery. A B
- 10 V. digitalis plantaris propria III abaxialis. Continuation of V. digitalis plantaris communis II. Accompanies corresponding artery. A B D
- 11 V. coronalis. Branch of V. digitalis plantaris propria III abaxialis, curves dorsally in the abaxial segment of Corona unguiae. A B
- 12 V. digitalis plantaris communis III. Lateral continuation of Ramus superficialis of V. plantaris medialis. Accompanies corresponding artery. A B D
- 13 V. interdigitalis. Connects V. digitalis plantaris communis III and its dorsal counterpart. B D
- 14 Vv. digitales plantares propriae III et IV axiales. Arise from the bifurcation of V. digitalis plantaris communis III, accompany corresponding arteries. B D
- 15 V. coronalis. Branch of V. digitalis plantaris propria in the axial segment of Corona unguiae. B D
- 16 V. plantaris lateralis. Accompanies corresponding artery. A B
- 17 Arcus plantaris profundus. Connection between V. plantaris lateralis and Ramus profundus of V. plantaris medialis. Accompanies corresponding artery. B
- 18 Vv. metatarsae plantares II–IV. Branches of Arcus plantaris profundus. Accompany corresponding arteries. A B D
- 19 Arcus plantaris profundus distalis. Variably shaped connection between Vv. metatarsae plantares II–IV, located distally between Os metatarsale III et IV and M. interosseus. B D
- 20 Ramus perforans distalis III. Branch of Arcus plantaris profundus distalis through Canalis metatarsi distalis, joins V. metatarsae dorsalis III. B
- 21 Vv. digitales plantares communes IV (bo), II–IV (ov, cap). Arise usually from Arcus plantaris profundus distalis, accompany corresponding arteries in the distal third of metatarsus. B D
- 22 Vv. digitales plantares propriae. Arise from the bifurcation of Vv. digitales plantares communes. Accompany corresponding arteries. B
- 23 *V. genus descendens*. Accompanies corresponding artery. A
- 24 *Vv. caudales femoris*. Variably arising, to the musculature in the poples. A
- 25 **V. poplitea**. Continuation of V. femoralis, accompanies corresponding artery. A
- 26 *Vv. genus*. Variably developed, drain Articulatio genus. A
- 27 *V. tibialis cranialis*. Continuation of V. poplitea. Usually represented by two anastomosing veins bordering A. tibialis cranialis. A C
- 28 *V. dorsalis pedis*. Continuation of V. tibialis cranialis distal to Articulatio tarsocruralis. A C
- 29 V. tarsea perforans. Accompanies corresponding artery, joins Arcus plantaris profundus. A C
- 30 V. metatarsae dorsalis III. Continuation of V. dorsalis pedis, accompanies corresponding artery. A C
- 31 *V. tibialis caudalis*. To the musculature at the caudal aspect of crus. Actually replaced by a branch of a V. caudalis femoris. A



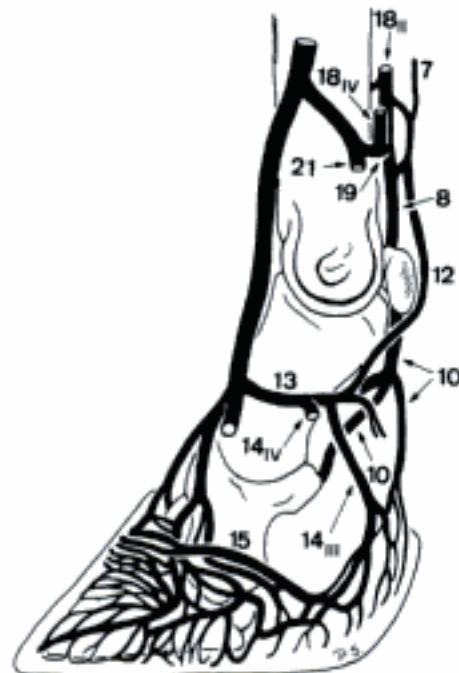
A Veins of left pelvic limb, medial aspect (bo)



B Veins of left pes, plantar aspect (bo)



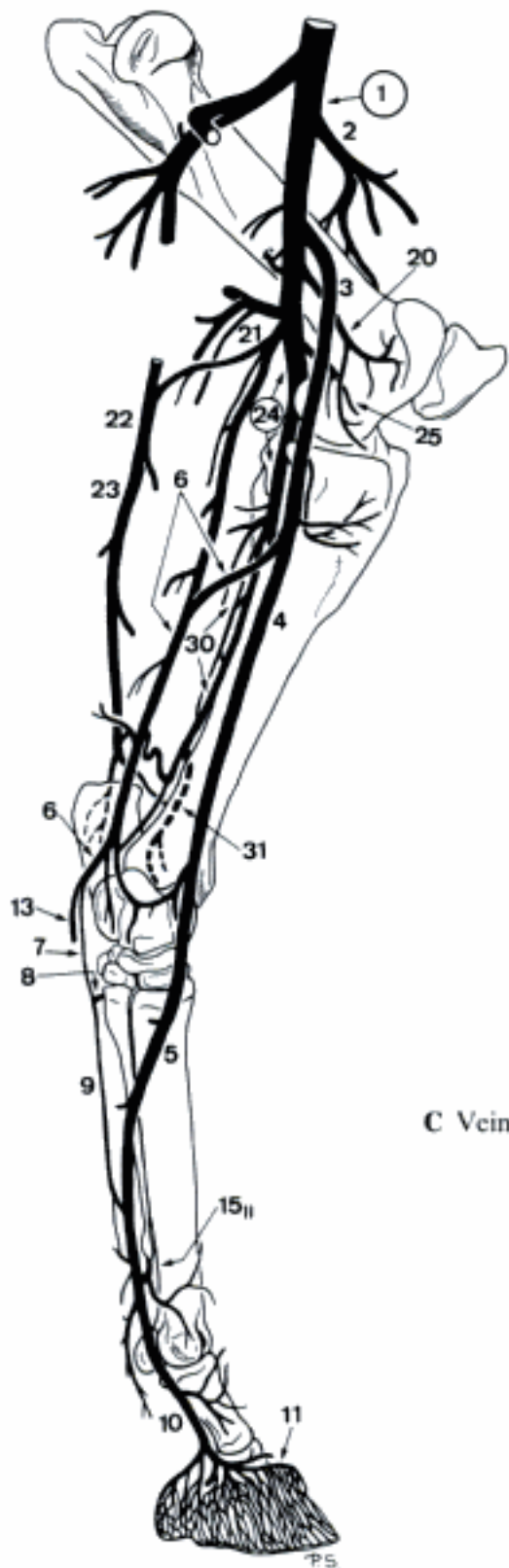
C Veins of left pes, dorsal aspect (bo)



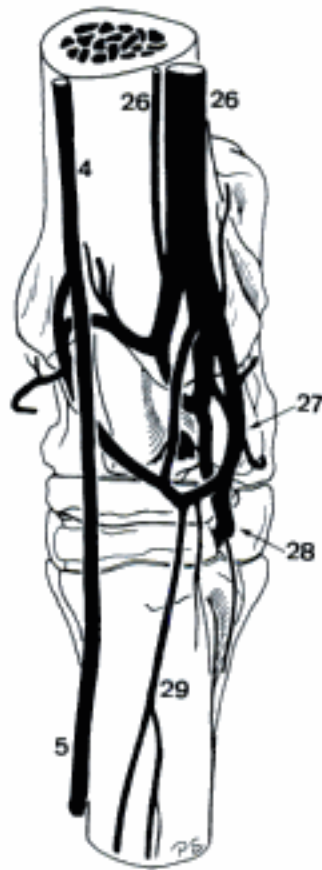
D Veins of left pes (fourth digit removed), lateral aspect (bo)

EQUUS

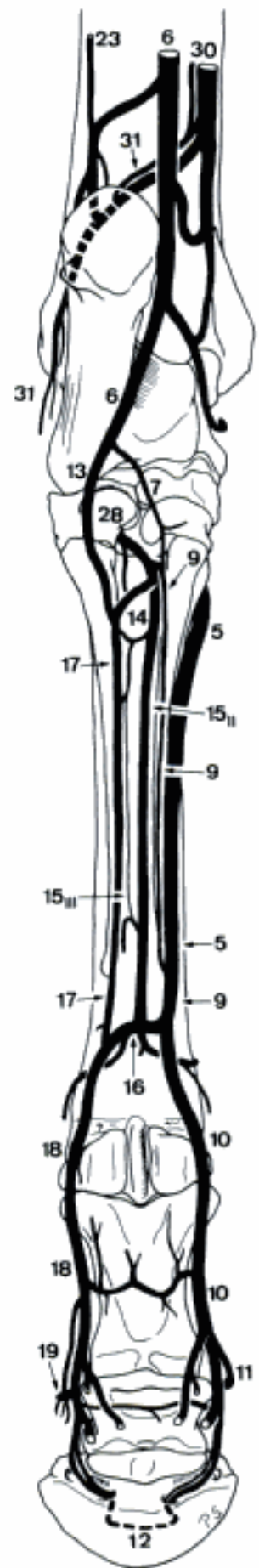
- 1 **V. femoralis.** Continuation of V. iliaca externa. Accompanies corresponding artery. A
- 2 *V. circumflexa femoris lateralis.* Accompanies corresponding artery. A
- 3 *V. saphena medialis [magna].* Courses superficially over the medial surface of the thigh, bifurcates in the proximal segment of Regio cruris medialis. A
- 4 *Ramus cranialis.* Courses to Facies medialis of Corpus tibiae, continues to the dorsomedial surface of the tarsus, where it is connected with V. dorsalis pedis by a large anastomosis. A C
- 5 *V. digitalis dorsalis communis II.* Continuation of Ramus cranialis of V. saphena medialis, curves to the plantar aspect of the metatarsus, joins Ramus superficialis of V. plantaris medialis. Largest vein of the equine metatarsus. A B C
- 6 *Ramus caudalis.* Accompanies corresponding artery, receives a large anastomosis from V. tibialis caudalis, bifurcates into Vv. plantares medialis and lateralis. A B
- 7 *V. plantaris medialis.* Accompanies corresponding artery. A B
- 8 *Ramus profundus.* Deep branch of V. plantaris medialis, accompanies corresponding artery. A
- 9 *Ramus superficialis [V. digitalis plantaris communis II].* Continuation of V. plantaris medialis, accompanies corresponding artery, joins Arcus plantaris profundus distalis. A B
- 10 *V. digitalis [plantaris propria III] medialis.* Continuation of Ramus superficialis of V. plantaris medialis. Accompanies corresponding artery. A B
- 11 *V. coronalis.* Branch of V. digitalis medialis, curves proximal to Corona unguulae, and joins its counterpart. Its distal branches form the venous network of the corium of the hoof. A B
- 12 *Arcus terminalis.* Arch inside Canalis solearis, formed by the union of Vv. digitales lateralis and medialis. B
- 13 *V. plantaris lateralis.* Accompanies corresponding artery. A B
- 14 *Arcus plantaris profundus.* Connection between V. plantaris lateralis and Ramus profundus of V. plantaris medialis. Accompanies corresponding artery. B
- 15 *Vv. metatarsae plantares II et III.* Branches of Arcus plantaris profundus. Accompany corresponding arteries. A B
- 16 *Arcus plantaris profundus distalis.* Connection between Rami superficiales of Vv. plantares lateralis and medialis plantaris to M. interosseus in the distal third of metatarsus. Receives Vv. metatarsae plantares II and III. B D
- 17 *Ramus superficialis [V. digitalis plantaris communis III].* Continuation of V. plantaris lateralis, accompanies corresponding artery along the lateral border of the tendon of M. flexor digitorum profundus and joins Arcus plantaris profundus distalis. B D
- 18 *V. digitalis [plantaris propria III] lateralis.* Continuation of Ramus superficialis of V. plantaris lateralis. Accompanies corresponding artery. B D
- 19 *V. coronalis.* Branch of V. digitalis lateralis, curves proximal to Corona unguulae, joins its medial counterpart. Its distal branches form the network of the corium of the hoof. B D
- 20 *V. genus descendens.* Accompanies corresponding artery. A
- 21 *V. caudalis femoris.* Accompanies corresponding artery. A
- 22 *V. saphena lateralis [parva].* Courses along the M. gastrocnemius. A
- 23 *Ramus caudalis.* Continuation along the cranio-lateral border of Tendo calcaneus communis. A B
- 24 **V. poplitea.** Continuation of V. femoralis. Accompanies corresponding artery. A
- 25 *Vv. genus.* Drain Articulatio genus. A
- 26 *V. tibialis cranialis.* Continuation of V. poplitea, accompanies corresponding artery. C
- 27 *V. dorsalis pedis.* Variably developed continuation of V. tibialis cranialis distal to Articulatio tarsocruralis. C
- 28 *V. tarsea perforans.* Accompanies corresponding artery, joins Arcus plantaris profundus. B C
- 29 *V. metatarsa dorsalis II.* Continuation of V. dorsalis pedis over Facies dorsalis of Os metatarsale III. C
- 30 *V. tibialis caudalis.* Accompanies corresponding artery, anastomoses with Ramus caudalis of V. saphena medialis. A B
- 31 *V. malleolaris caudalis lateralis.* Accompanies corresponding artery. A B



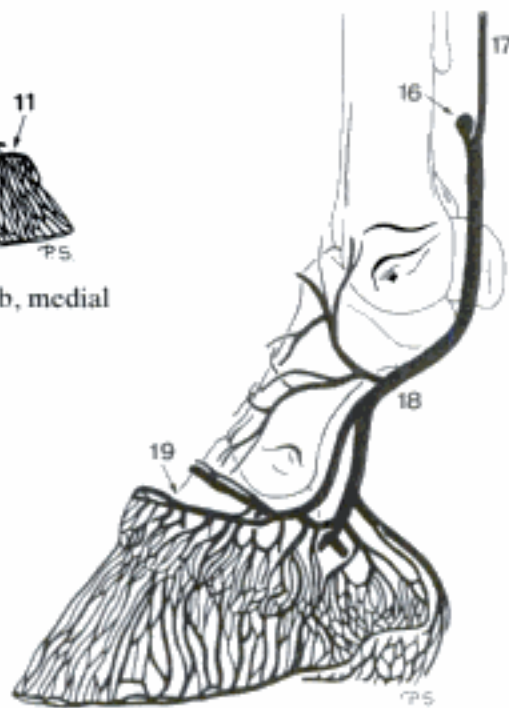
A Veins of left pelvic limb, medial aspect (eq)



C Veins of left tarsus, dorsal aspect (eq)

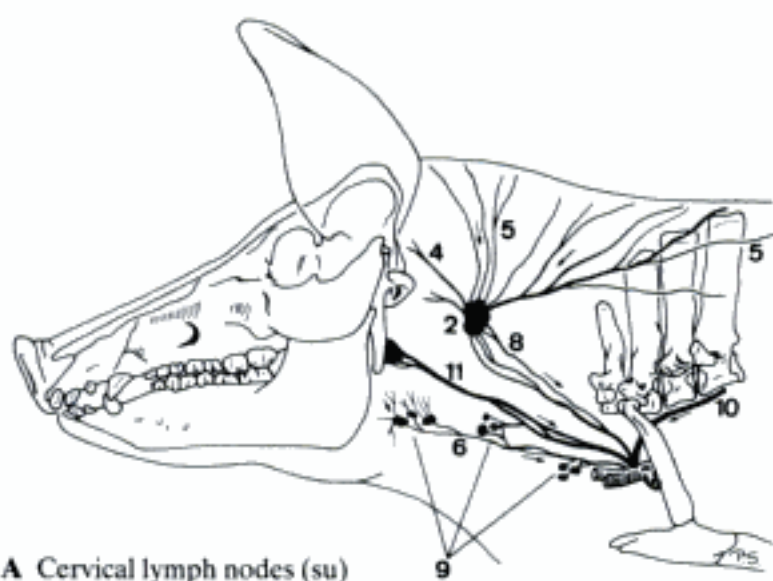


B Veins of left pes, plantar aspect (eq)

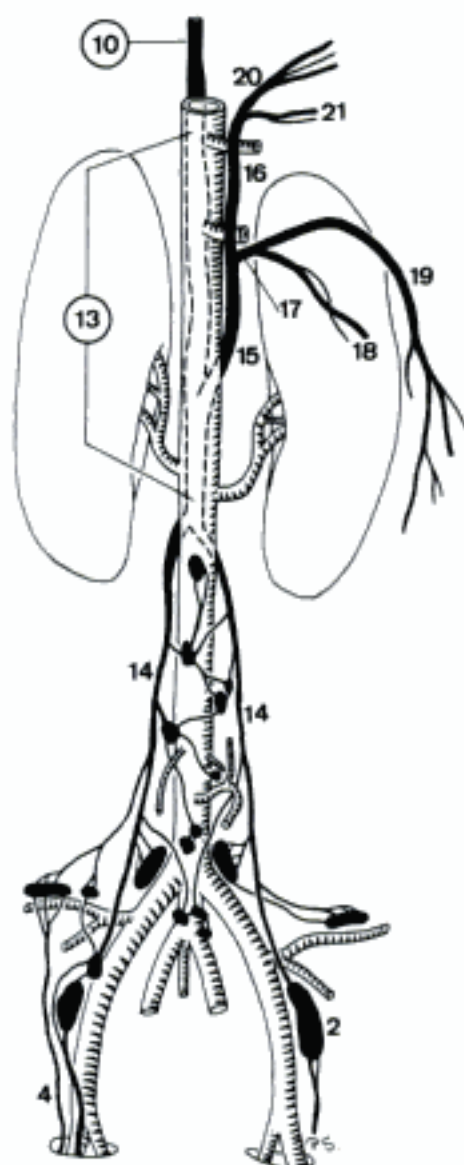

D Veins of left pes, lateral aspect (eq)

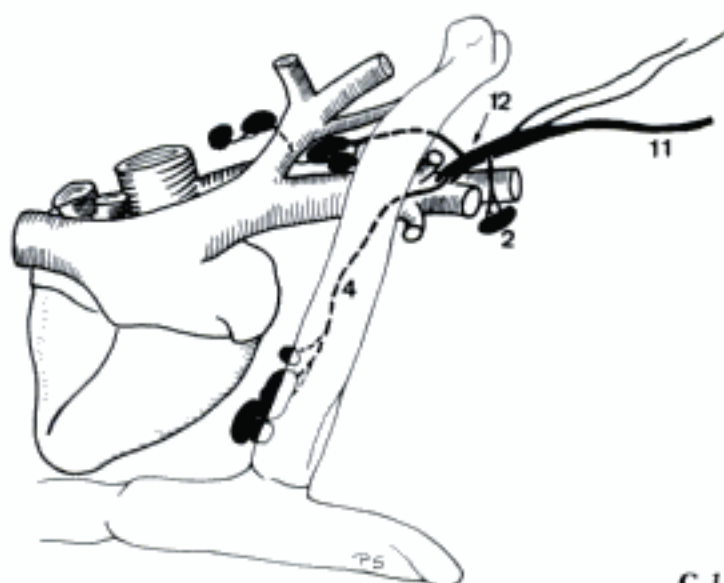
- 1 **SYSTEMA LYMPHATICUM.** System of lymphatic organs (Lymphonodi, Lymphonoduli, Tonsillae, Lien, and Thy-mus) and lymphatic vessels.
- 2 *Lymphonodus [Nodus lymphaticus]*. Organized lymphatic organ provided with a capsule. A B C D
- 3 *Lymphonodus hemalis [haemalis] (Ru)*. Spleen-like organization, contains lymphatic tissue with blood circulating in the sinuses.
- 4 *Vas lymphaticum*. Thin-walled vessel with valves which contains lymph. A B C D
- 5 *Vas lymphatica superficialia*. Cutaneous and subcutaneous lymphatic vessels. A
- 6 *Vasa lymphatica profunda*. Lymphatic vessels beneath the fasciae. A
- 7 *Valvula lymphatica*. Valve of one or two leaflets in lymphatic vessels. D
- 8 *Plexus lymphaticus*. Network of lymphatic vessels.
- 9 *Lymphocentrum*. A lymph node or a group of lymph nodes that occurs constantly in the same region and receives vessels from the same region in all species. A
- 10 **DUCTUS THORACICUS.** Starts near (Ru) or in Hiatus aorticus, courses along the right-dorsal (occasionally: left-dorsal) side of Aorta thoracica, then to the left in Mediastinum craniale, joins V. cava cranialis or one of its branches at Apertura thoracis cranialis. May locally be plural. A C
- 11 *Truncus trachealis [Truncus jugularis]*. Bilateral lymphatic duct along the trachea. Conveys lymph from head and neck. Usually the right duct ends in Ductus lymphaticus dexter (except cap), the left in Ductus thoracicus. A B
- 12 *Ductus lymphaticus dexter*. Lymphatic vessel in the right-caudal part of the neck, collecting lymph from cervical, thoracic and axillary lymph nodes and Truncus trachealis dexter. Joins V. cava cranialis or one of its branches. May be absent. B
- 13 **CISTERNA CHYLI.** Lymphatic sac dorsal to Aorta abdominalis. Collects lymph from Truncus visceralis (or Truncus celiacus and Truncus intestinalis) and Trunci lumbales. Discharges into Ductus thoracicus. C
- 14 *Trunci lumbales*. Paired, collect lymph from pelvic limbs and pelvis to Cisterna chyli. May be plexiform (ca, su). C
- 15 *Truncus visceralis*. Unpaired, collects lymph from Truncus celiacus and Truncus intestinalis. May be absent (eq, sometimes cap) or plexiform (Car). C
- 16 *Truncus celiacus [coeliacus]*. Collects lymph from Lymphocentrum celiacum, empties in Truncus visceralis (Car, su, Ru) or Cisterna chyli (eq). C
- 17 *Truncus intestinalis*. Collects lymph from Lymphocentrum mesentericum craniale, empties in Truncus visceralis (Car, su, Ru) or Cisterna chyli (eq, sometimes cap). May be plexiform (Car). C
- 18 *Truncus colicus*. Collects lymph from Lymphonodi colici, empties in Truncus intestinalis or Truncus visceralis (sometimes bo). May be plural (Car, su). C
- 19 *Truncus jejunalis*. Collects lymph from Lymphonodi jejunales, empties in Truncus intestinalis. May be plural (Car). C
- 20 *Truncus gastricus*. Collects lymph from the gastric lymph nodes, empties in Truncus celiacus or Cisterna chyli (Ru), sometimes Truncus intestinalis (cap). C
- 21 *Truncus hepaticus*. Collects lymph from Lymphonodi hepatici and hepatici accessorii. Joins Truncus celiacus or Truncus intestinalis (Ru).
- 22 **LYMPHONODI [NODI LYMPHATICI].** See 2
- 23 *Vasa lymphatica afferentia*. Lymphatic vessels which enter the convex surface (Car, Ru, eq) or the Hilus (su). D
- 24 *Sinus lymphaticus*. Subcapsular and medullary network of spaces. D
- 25 *Vasa lymphatica efferentia*. Leave the Lymphonodus through the Hilus (Car, Ru, eq) or at the periphery (su). D
- 26 *Capsula*. Capsule, contains some elastic and smooth muscle fibers. D
- 27 *Cortex*. Peripheral (Car, Ru, eq) or central (su) zone containing Lymphonoduli. D
- 28 *Trabecula*. Connective tissue cord. D
- 29 *Medulla*. Central (Car, Ru, eq) or peripheral (su) zone with lymphatic tissue organized in medullary cords. D
- 30 *Hilus*. Indentation for the entry of arteries, nerves, and Vasa afferentia (su) and the exit of veins and the Vasa efferentia (Car, Ru, eq). D
- 31 *Lobulus*. Segment incompletely separated by Trabeculae. D
- 32 *Lymphonodulus [Nodus lymphaticus]*. Small cell-rich mass of lymphatic tissue in the cortex. D



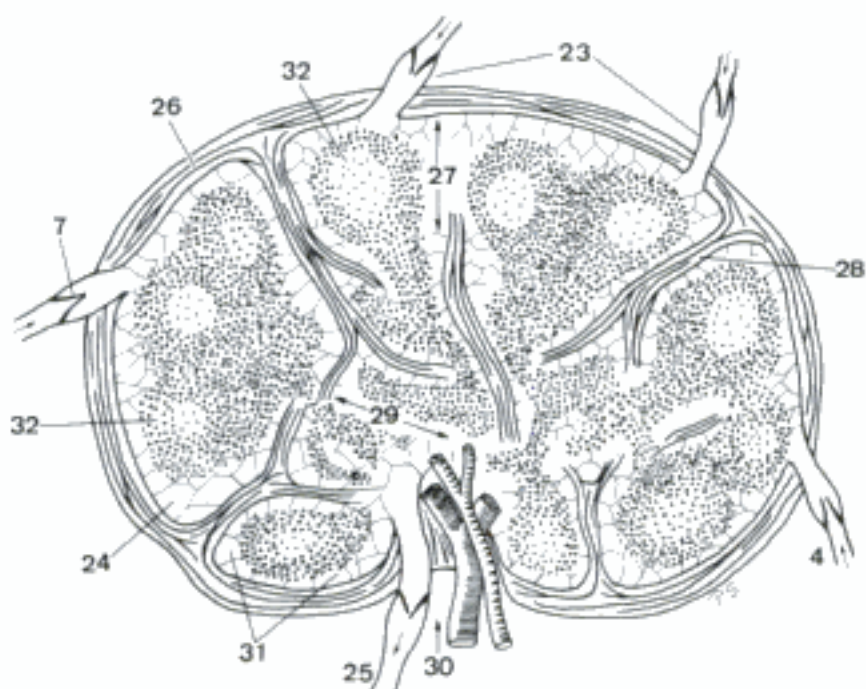
A Cervical lymph nodes (su)



C Lymph vessels in relation to Aorta abdominalis, ventral aspect (su)



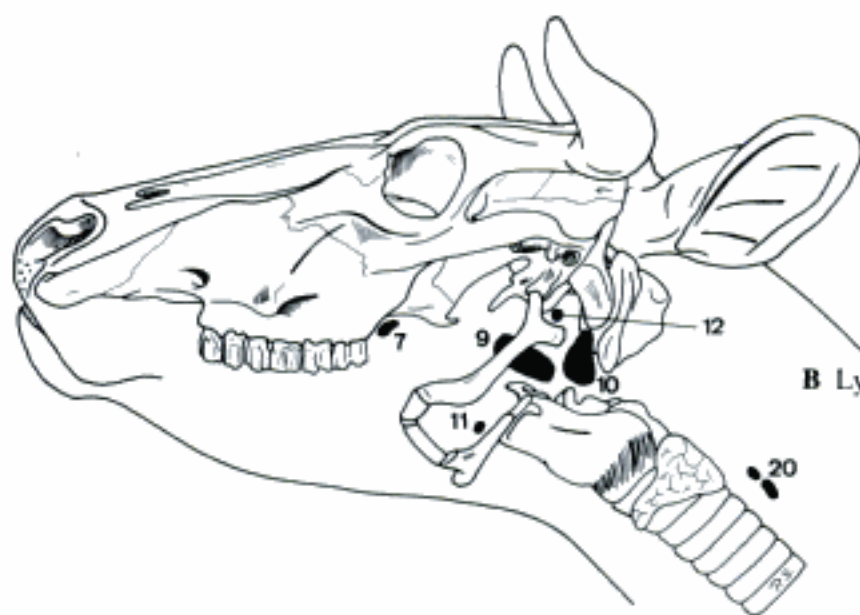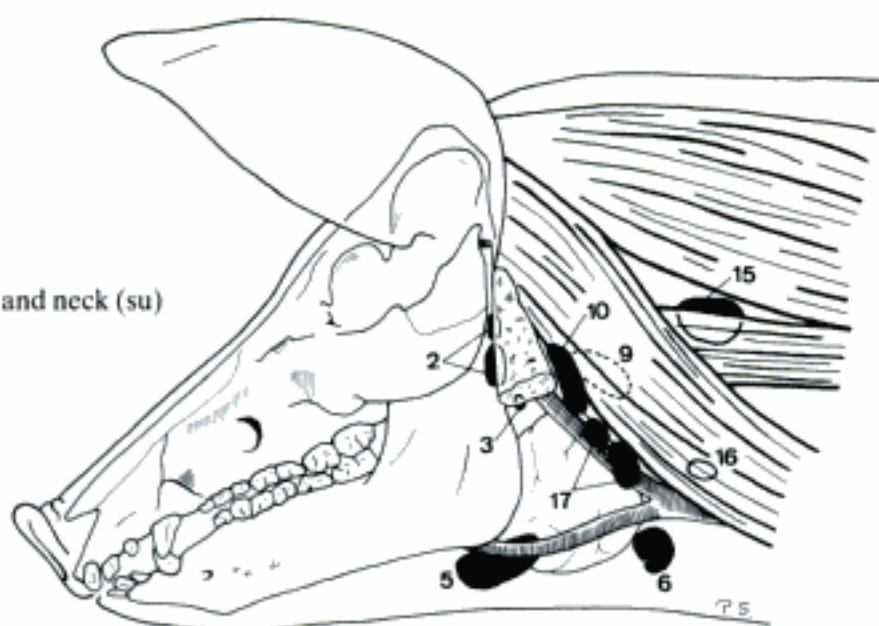
B Ductus lymphaticus dexter (su)



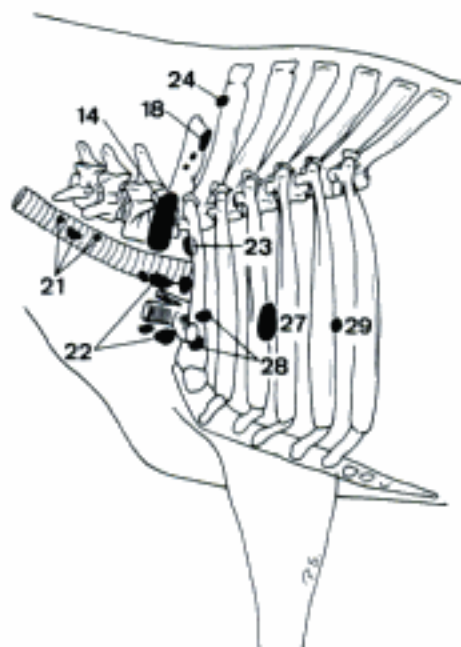
D Section of a lymph node (schematic)

Hidden page

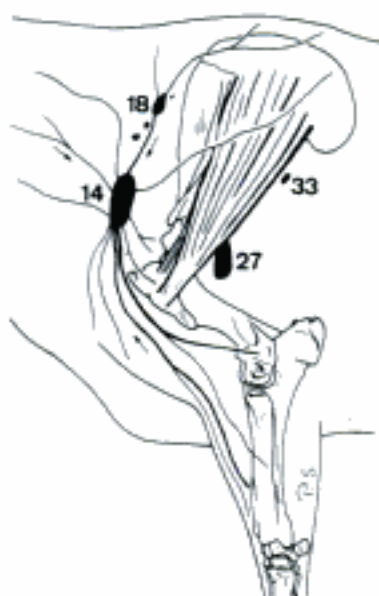
A Lymphocentres of head and neck (su)



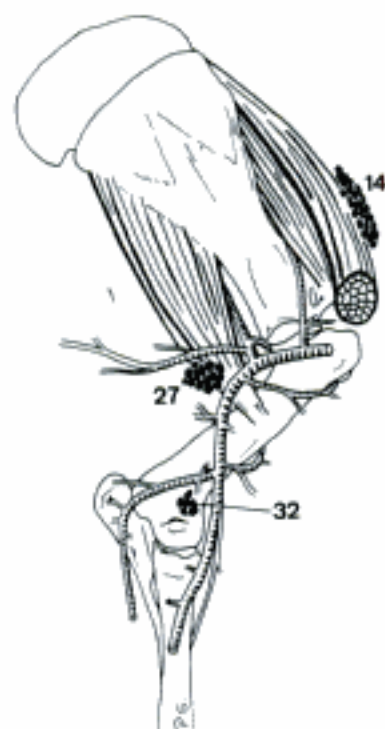
B Lymphocentrum retropharyngeum (bo)



C Cervical and axillary lymphocentres (bo)

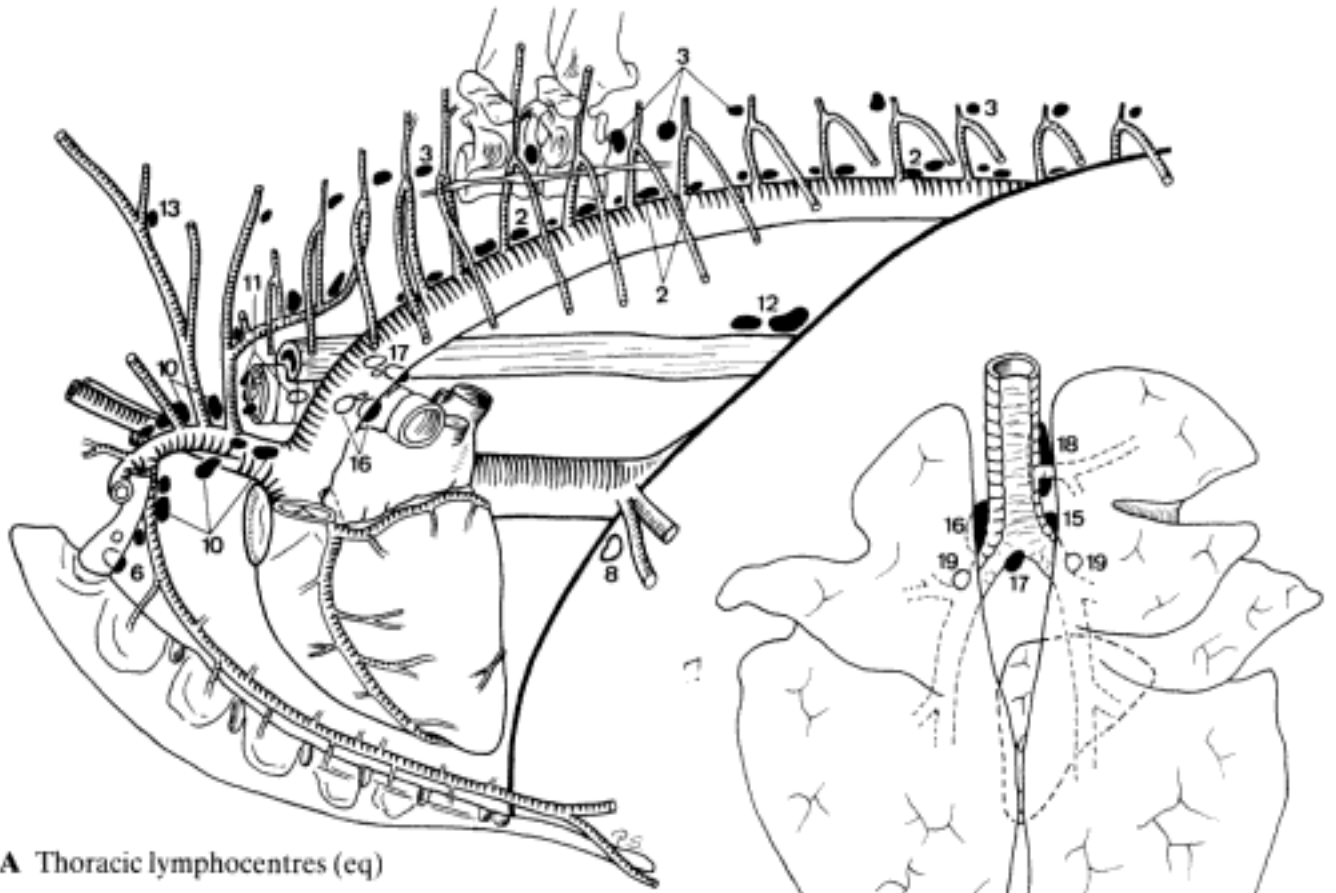


D Cervical and axillary lymph nodes (bo)



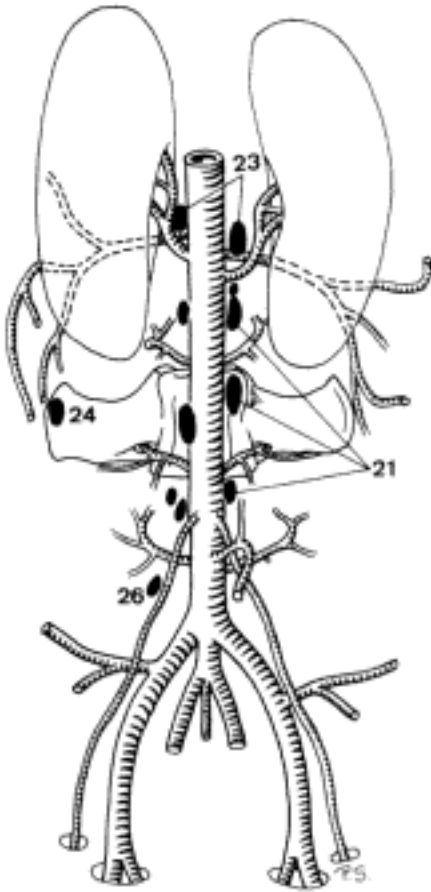
E Cervical and axillary lymph nodes (eq)

Hidden page

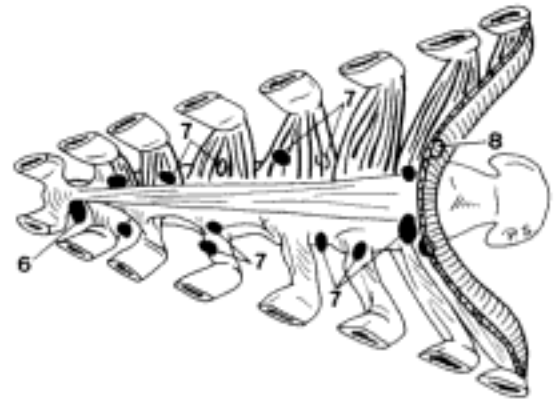


A Thoracic lymphocentres (eq)

B Lymphocentrum bronchiale, dorsal aspect (cap)

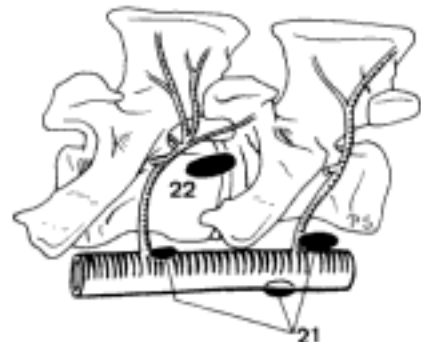


C Lymphocentrum thoracicum ventrale, dorsal aspect (bo)

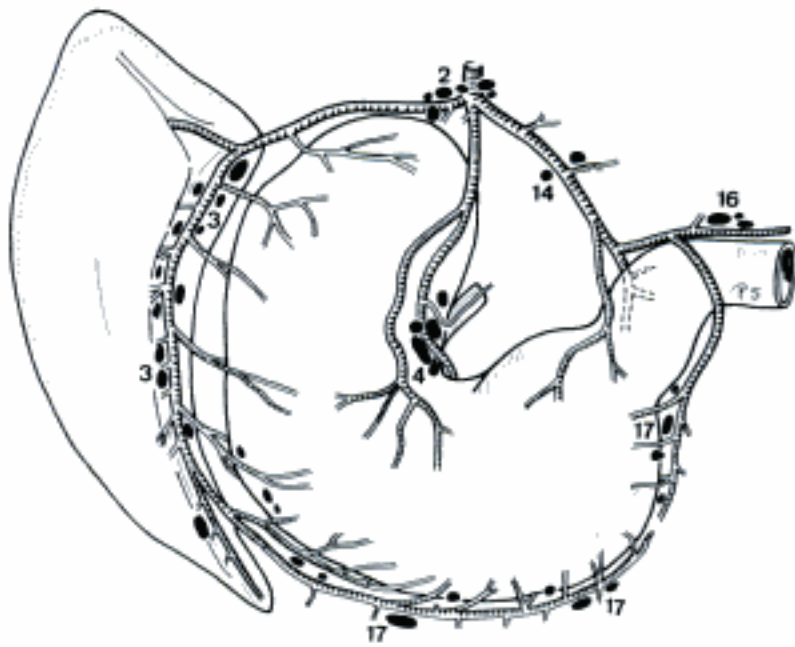


D Lymphocentrum lumbale, ventral aspect (su)

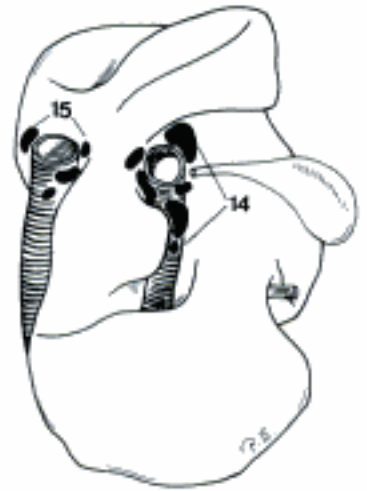
E Lymph nodes in relation to lumbar vertebrae IV and V, left aspect (bo)



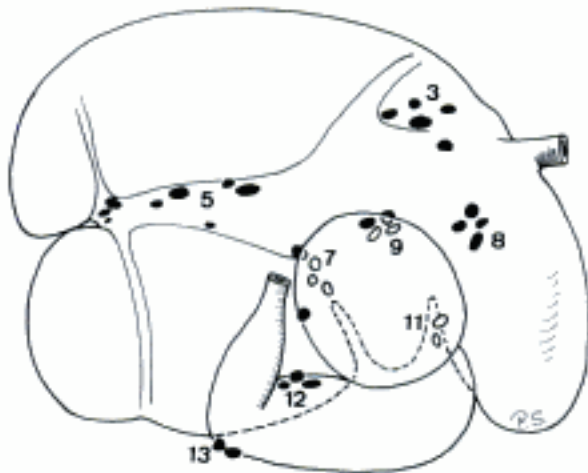
- 1 *Lymphocentrum celiacum [coeliacum]*. Along A. celiaca and its branches. Drains the intrathoracally located abdominal organs. Receives lymph also from thoracic organs (ca, su, eq).
- 2 *Lymphonodi celiaci [coeliaci]*. Along A. celiaca. May be absent (Car, some cap) or single (ov). Hard to differentiate from the adjacent lymph nodes, esp. in Ru. Their efferent lymphatic vessels form the Truncus celiacus. A
- 3 *Lymphonodi lienales*. Along A. and V. lienalis near Hilus lienis (Car, su, eq) or upon Atrium ruminis near cardia (Ru). May absent (fe). A C
- 4 *Lymphonodi gastrici*. At A. gastrica sinistra near Curvatura ventriculi minor. May be absent (Car) or single (Car, su), in Ru divided into specific groups. A
- 5 *Lymphonodi ruminales dextri*. In Sulcus longitudinalis dexter of rumen. May be absent or single (cap). C
- 6 *Lymphonodi ruminales sinistri*. In Sulcus longitudinalis sinister of rumen. May be absent. D
- 7 *Lymphonodi ruminales craniales*. Deep in Sulcus cranialis of the rumen. Usually absent in ov, cap. C
- 8 *Lymphonodi reticulares*. On reticulum. May be absent. C
- 9 *Lymphonodi omasiales*. Along A. and V. gastrica sinistra near Curvatura omasi. C
- 10 *Lymphonodi ruminoabomasiales (ov, bo)*. Between the cranioventral border of rumen and the initial segment of abomasum. May be absent (ov). D
- 11 *Lymphonodi reticuloabomasiales*. In the angle between rumen, reticulum, omasum, and abomasum. May be absent (ov, cap). C D
- 12 *Lymphonodi abomasiales dorsales*. Along Curvatura minor of abomasum. C
- 13 *Lymphonodi abomasiales ventrales*. Along the caudal part of Curvatura major of abomasum. May be absent.
- 14 *Lymphonodi hepatici [portales]*. Near Porta hepatis. A B
- 15 *Lymphonodi hepatici accessorii (bo)*. Along Margo dorsalis of the liver near V. cava caudalis. B
- 16 *Lymphonodi pancreaticoduodenales*. At Pars descendens of duodenum and pancreas. A
- 17 *Lymphonodi omentales (eq)*. In Omentum majus near Curvatura ventriculi major. A
- 18 *Lymphocentrum mesentericum craniale*. Along A. mesenterica cranialis and its branches. Drains the intestinal organs supplied by those arteries.
- 19 *Lymphonodi mesenterici craniales*. At A. mesenterica cranialis. Absent in Car, inconstant in su, cap. Hard to differentiate from the adjacent lymph nodes (esp. Ru). E
- 20 *Lymphonodi jejunaes*. In mesenterium near Aa. and Vv. jejunaes. More or less concentrated near the root (Car, eq) or near the intestinal border (su, Ru) of mesenterium. E
- 21 *Lymphonodi cecales [caecales] (bo, eq)*. In Plica ileocecalis (bo, eq) and along Teniae medialis, lateralis and dorsalis of cecum (eq). May be absent (bo). Described also in fe, ov, cap. E
- 22 *Lymphonodi ileocolici (su)*. Near Ostium ileale in mesoileum and Plica ileocecalis. Described also in cap.
- 23 *Lymphonodi colici*. In Mesocolon ascendens and transversum (Car), in the axis of Ansa spiralis coli (su) or along the loops (Ru) or segments (eq) of Colon ascendens. E
- 24 *Lymphocentrum mesentericum caudale*. At A. mesenterica caudalis and its branches, draining Colon descendens and rectum.
- 25 *Lymphonodi mesenterici caudales*. In Mesocolon descendens and sigmoideum and Mesorectum near A. mesenterica caudalis and its branches. E
- 26 *Lymphonodi vesicales (eq)*. Occasionally single, in Ligamentum vesicae laterale. Drain Vesica urinaria (and Prostata).



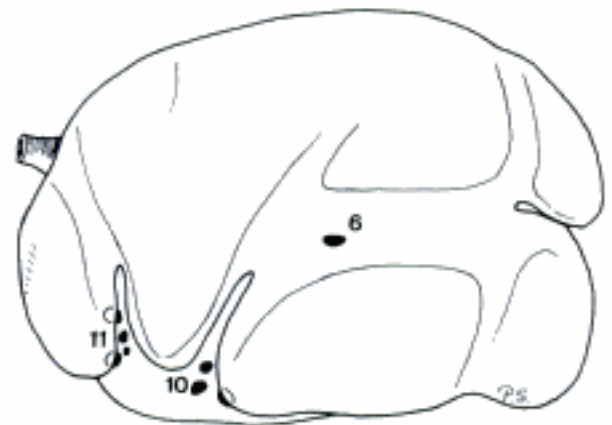A Lymphocentrum celiacum, caudal aspect (eq)



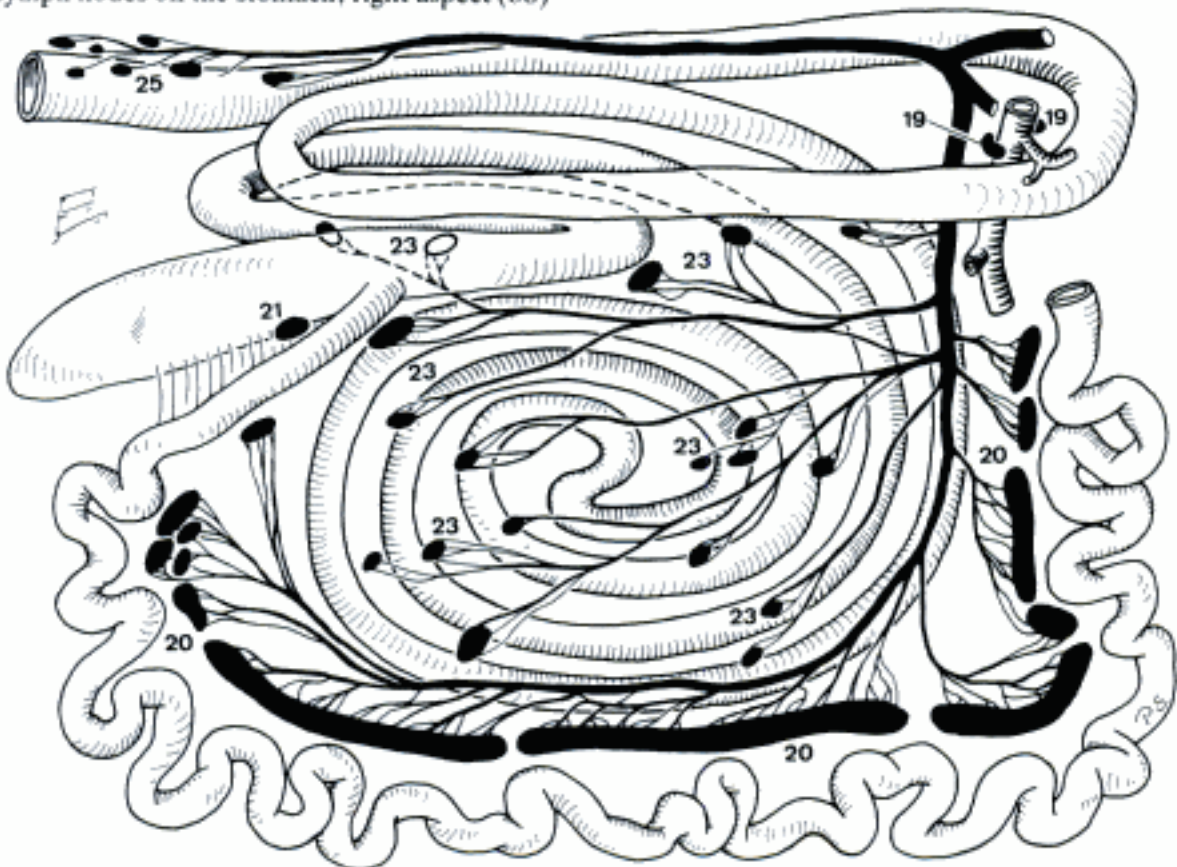
B Lymph nodes on the visceral surface of the liver (bo)



C Lymph nodes on the stomach, right aspect (bo)

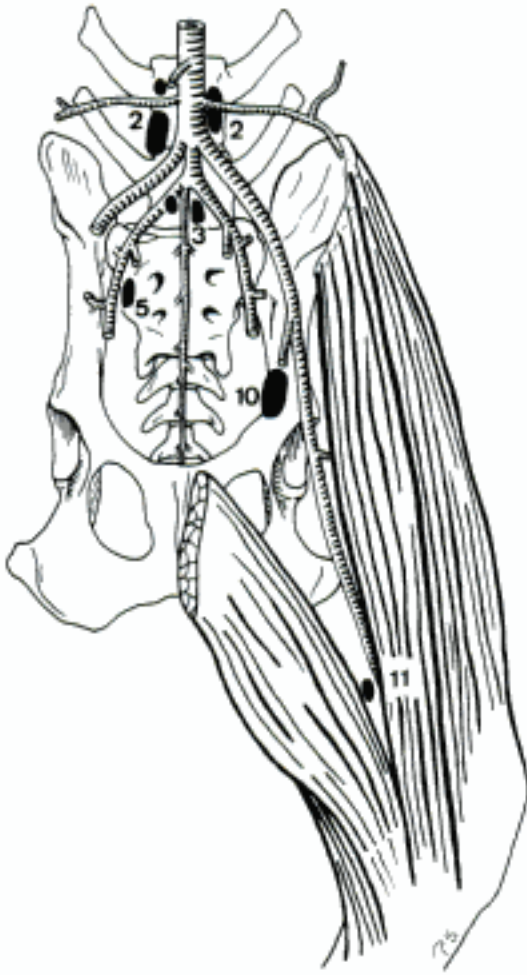


D Lymph nodes on the stomach, left aspect (bo)

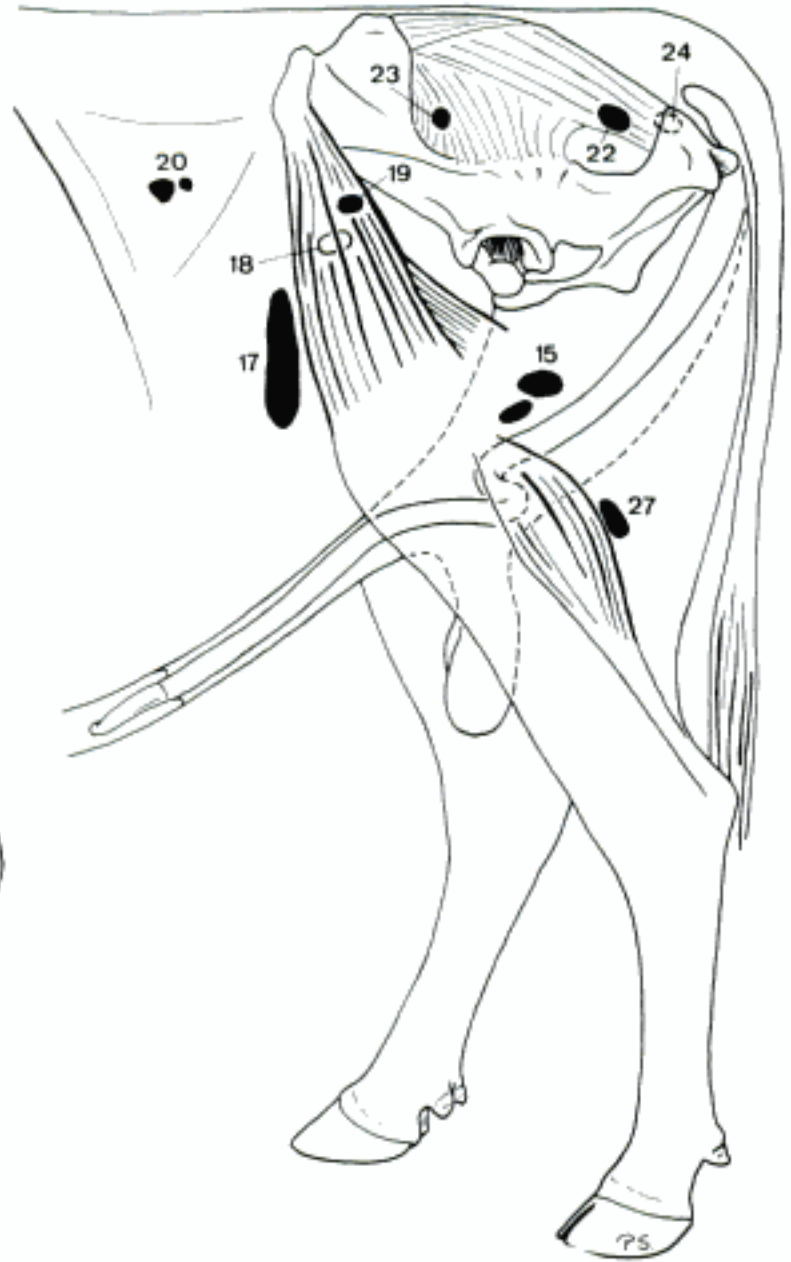

E Lymph nodes of the intestinal tract (semischematic), right aspect (bo)

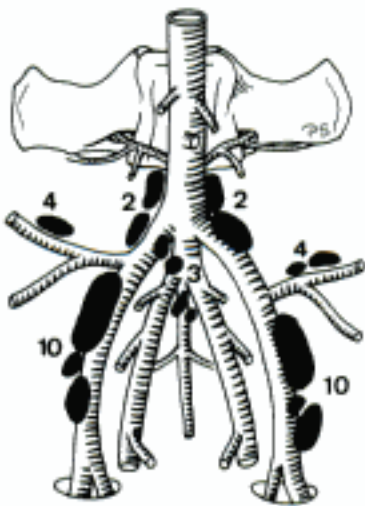
- 1 *Lymphocentrum iliosacrale*. At Facies pelvina of Os sacrum and the terminal segments of aorta and V. cava caudalis. Drains the pelvic wall, pelvic organs and Lymphocentra iliofemorale, inguinofemorale, ischiadicum and popliteum.
- 2 *Lymphonodi iliaci mediales*. Along the terminal segment of aorta and the initial segment of A. iliaca externa. A B D
- 3 Lymphonodi sacrales. Unpaired, variably developed, at the origin of A. sacralis mediana. A B
- 4 *Lymphonodi iliaci laterales*. At the bifurcation of A. circumflexa ilium profunda into Ramus cranialis and Ramus caudalis. Absent in Car, cap, sometimes in su, ov, bo. B
- 5 *Lymphonodi hypogastrici*. Near A. iliaca interna and variably its branches. A D
- 6 *Lymphonodi anorectales*. Retroperitoneally upon the dorsolateral surface of rectum (su, Ru, eq) and Canalis analis (bo, eq). Absent in Car, sometimes in su, ov. D
- 7 *Lymphonodus uterinus* (su, eq). In Ligamentum latum uteri. Often absent (su, eq) or plural (su). D
- 8 *Lymphonodus obturatorius* (eq). Occasional, at the initial segment of A. and V. obturatoria. D
- 9 *Lymphocentrum iliofemorale [inguinale profundum]*. Along A. iliaca externa or A. femoralis at the cranial aspect of Corpus ossis ilii or in Canalis femoralis, respectively. Drains the thigh and receives lymphatic vessels from Lymphocentrum popliteum.
- 10 *Lymphonodi iliofemorales [inguinales profundi]*. At the cranial aspect of Corpus ossis ilii along A. iliaca externa (Car, su, Ru) or in Canalis femoralis along A. femoralis (eq). A B
- 11 Lymphonodus femoralis (Car). In the distal part of Canalis femoralis. Usually absent. A
- 12 Lymphonodus epigastricus (bo). Inconstant. On A. epigastica caudalis near Pecten ossis pubis. Drains the ventral abdominal wall.
- 13 *Lymphocentrum inguinofemorale [inguinale superficiale]*. In Regiones abdominalis lateralis and caudalis. Drains the abdominal and ventral pelvic walls, the superficial parts of thigh and the external genital organs.
- 14 *Lymphonodi inguinales superficiales*. Superficially in Regio pubica.
- 15 Lymphonodi scrotales. Along the dorsolateral aspect of penis (except fe) cranial (Car, su, eq) and/or caudal (su, Ru, eq) to Funiculus spermaticus. Drain penis and scrotum. C
- 16 Lymphonodi mammarii. At the caudo-dorsal (Car, su, Ru) or dorsal (eq) aspect of the inguinal mammae. Often accompanied by intramammary lymph nodes in bo. Drain mammae and Pudendum femininum. D
- 17 *Lymphonodi subiliaci*. Located in Plica lateralis halfway between Tuber coxae and patella. Usually absent in Car. C
- 18 *Lymphonodus coxalis* (bo, ov, eq). Near the ventral aspect of Tuber coxae, medial to M. tensor fasciae latae. May be absent (esp. eq). C
- 19 *Lymphonodus coxalis accessorius* (bo). Inconstant, inside or lateral of M. tensor fasciae latae. C
- 20 *Lymphonodi fossae paralumbalis* (bo). Inconstant, often single, subcutaneous, in the centre of Fossa paralumbalis. C
- 21 *Lymphocentrum ischiadicum*. In Regiones glutea, clunis and tuberis ischiadici at the lateral aspect of Ligamentum sacrotuberale latum. Drains the regional musculature and skin.
- 22 *Lymphonodi ischiadici*. At Incisura ischiadica minor, lateral to the Ligamentum sacrotuberale latum, near A. and V. glutea caudalis. Absent in ca, sometimes in su, ov, cap. C
- 23 *Lymphonodus gluteus [glutaeus]* (su, bo). Near Incisura ischiadica major, lateral to Ligamentum sacrotuberale latum. Described also in ov. C
- 24 *Lymphonodus tuberalis* (bo, ov). Inconstant, subcutaneous, dorsomedial to Tuber ischiadicum. Described also in cap. C
- 25 *Lymphocentrum popliteum*. In Regio poplitea, drains the distal parts of the pelvic limb.
- 26 *Lymphonodi poplitei*. In poples.
- 27 Lymphonodi poplitei profundi (su, Ru, eq). Deep in poples, caudoproximal to M. gastrocnemius. May be absent (su). C
- 28 Lymphonodi poplitei superficiales (Car, su). Superficially in Fossa poplitea, exceptionally absent in su.



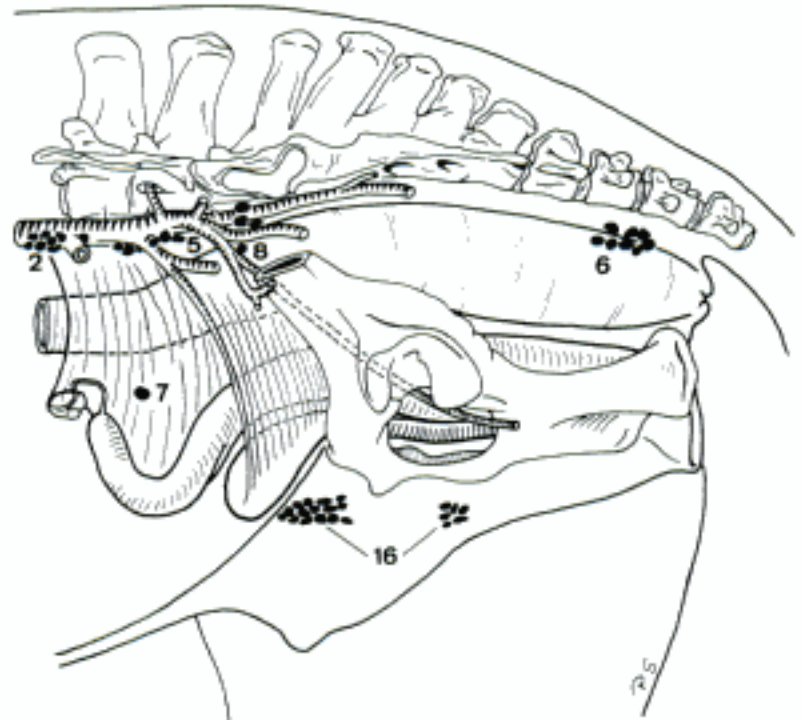
A Iliosacral and -femoral lymphocentres, ventral aspect (ca)



C Inguinal, ischiadic, and popliteal lymphocentres (bo masc)

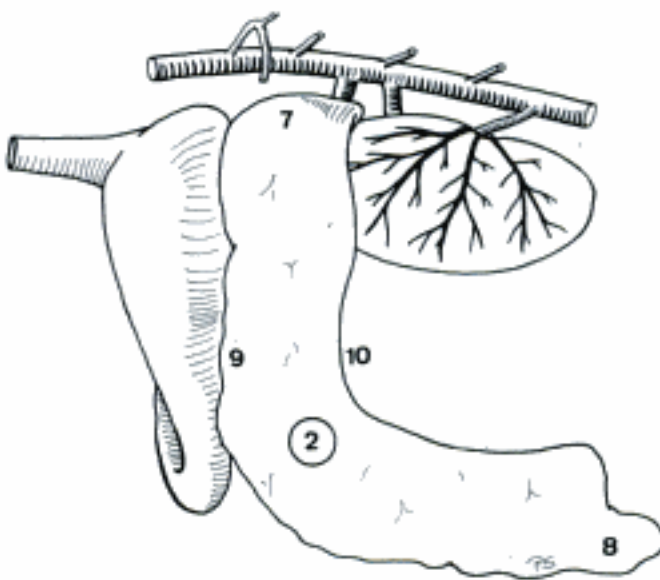


B Lymph nodes in relation to the terminal branches of Aorta abdominalis, ventral aspect (bo)

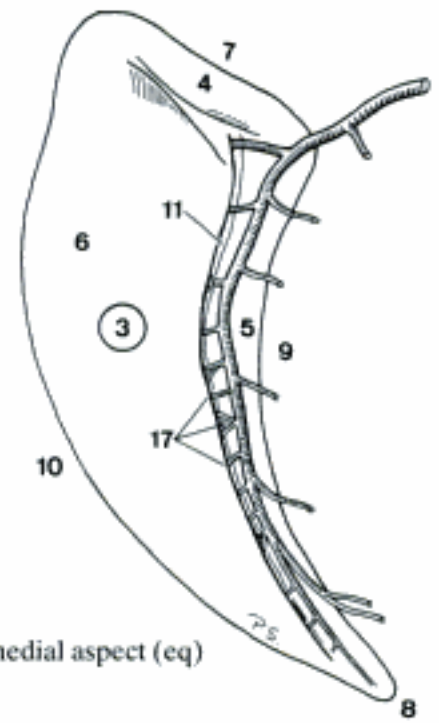


D Iliosacral and inguinal lymphocentres (eq fem)

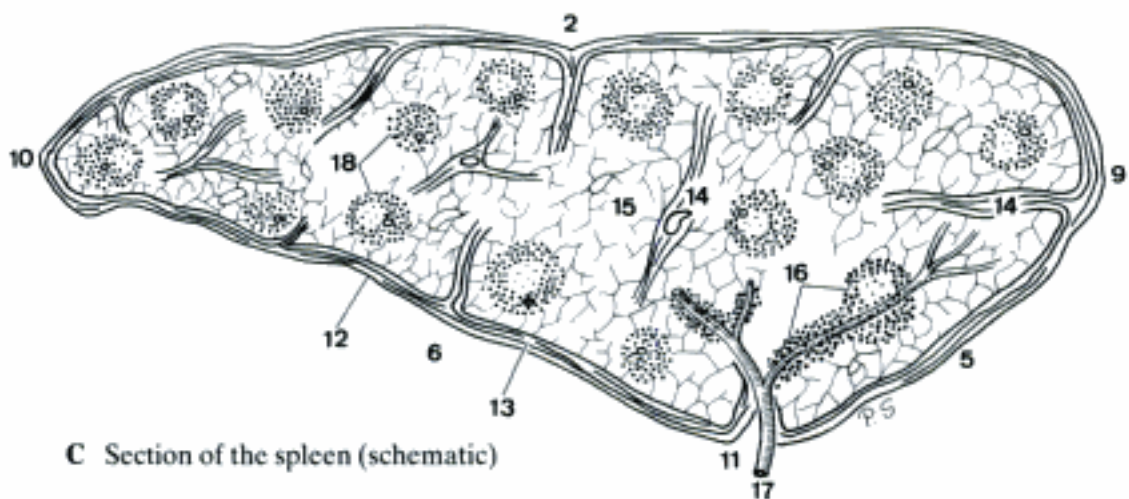
- 1 **LIEN.** Spleen. Large abdominal lymphatic organ incorporated into the circulatory system. Variably shaped: falciform (Car, eq), elongated elliptical (su, bo) or triangular (ov, cap). A B C
- 2 *Facies parietalis [diaphragmatica]*. Convex lateral surface, facing Diaphragma (Ru, eq) and the left-cranial abdominal wall. A C
- 3 *Facies visceralis*. Concave medial surface. Contains hilus. Largely free of Tunica serosa in Ru. B
- 4 *Facies renalis*. Dorsal part of Facies visceralis facing the left kidney. Absent in Ru. B
- 5 *Facies gastrica*. Cranial part of Facies visceralis, faces the stomach. In Ru the entire Facies visceralis. B C
- 6 *Facies intestinalis*. Caudal segment of Facies visceralis, faces portions of jejunum and colon. Absent in Ru. B C
- 7 *Extremitas dorsalis*. Dorsal extremity. A B
- 8 *Extremitas ventralis*. Ventral extremity. A B
- 9 *Margo cranialis*. Cranial border. A B C
- 10 *Margo caudalis*. Caudal border. A B C
- 11 *Hilus lienis*. Longitudinal ridge (Car, su, eq) or round depression (Ru) at Facies visceralis for entrance of nerves and arteries, for exit of veins and lymphatic vessels. B C
- 12 *Tunica serosa*. Peritoneal layer covering the spleen, except at the Hilus and the larger portion of Facies visceralis (Ru). C
- 13 *Capsula*. Thick capsule. Consists of collagen, elastic and smooth muscle fibers. C
- 14 *Trabeculae lienis*. Centripetal cords of collagen, elastic and smooth muscle fibers which leave the capsule. Contain arteries, veins, nerves, and lymph vessels. C
- 15 *Pulpa lienis rubra*. Red pulp. System of sinuses formed by reticular connective tissue, filled with blood cells. C
- 16 *Pulpa lienis alba*. White pulp. Accumulations of cell-rich lymphatic tissue which surround the initial segments of the intraparenchymatous Rami lienales arteriae lienalis, forming periarterial lymphatic sheaths or larger Lymphonoduli. C
- 17 *Rami lienales [arteriae lienalis]*. Branches of A. lienalis, enter capsule and trabeculae, continue in Pulpa lienis alba and then through Pulpa lienis rubra, and finally ramify brush-like into pulp arterioles. B C
- 18 *Lymphonoduli [Noduli lymphatici] lienales*. Spherical accumulations of cell-rich lymphatic tissue, surround the intraparenchymatous Rami lienales arteriae lienalis locally. C
- 19 (*Lien accessorius*). Occasional small island of additional splenic tissue, described a. o. in Ligamentum gastrolienale of su.
- 20 **THYMUS.** Variably shaped primary lymphatic organ which undergoes involution in the postfetal life. D
- 21 *Lobus cervicalis [dexter et sinister]*. Cervical portion of thymus extending cranially along both sides of trachea. Volume in young animals: large (su, Ru), variably but usually small (fe, eq), absent (ca). D
- 22 *Lobus intermedius*. Bridge of thymic tissue through Apertura thoracis cranialis, connecting Lobi cervicales with Lobus thoracicus. Bilateral in su. D
- 23 *Lobus thoracicus [dexter et sinister]*. Intrathoracic portion of thymus, located in the ventral (Car, su, eq) or dorsal (Ru) part of Mediastinum craniale. Left and right lobe are apparently fused. D
- 24 *Lobuli thymici*. Lobules of thymus, incompletely separated by thin strands of connective tissue. D
- 25 *Cortex*. Peripheral part of the lobule.
- 26 *Medulla*. Central part of the lobule.
- 27 (*Noduli thymici accessorii*). Occasional clusters of additional thymic tissue, described a. o. in bo.



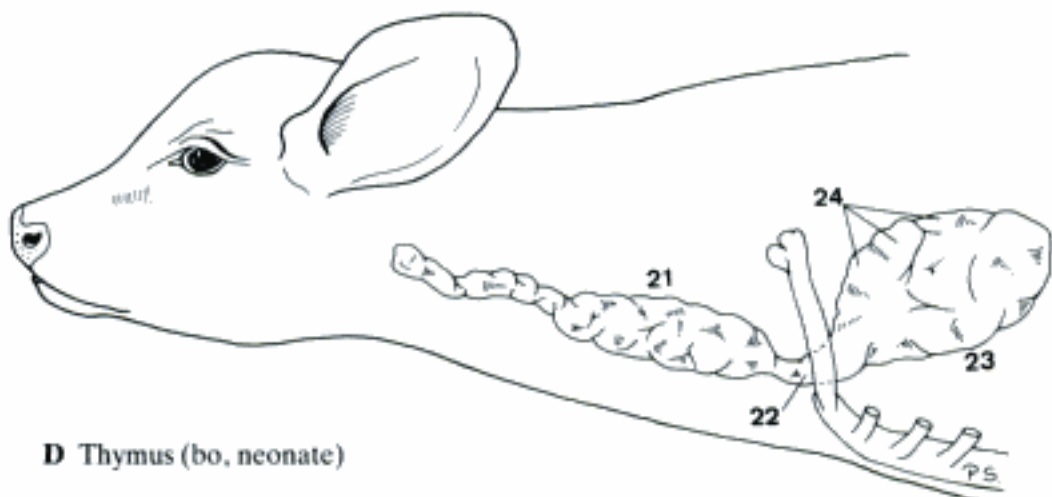
A Topography of the spleen, left aspect (fe)



B Spleen, medial aspect (eq)

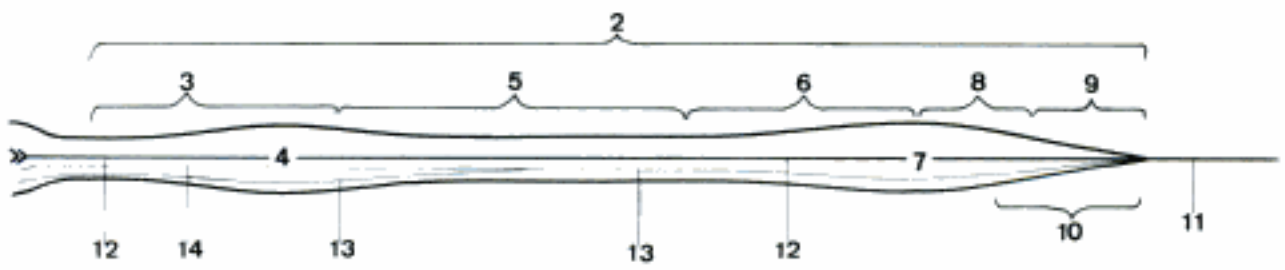


C Section of the spleen (schematic)

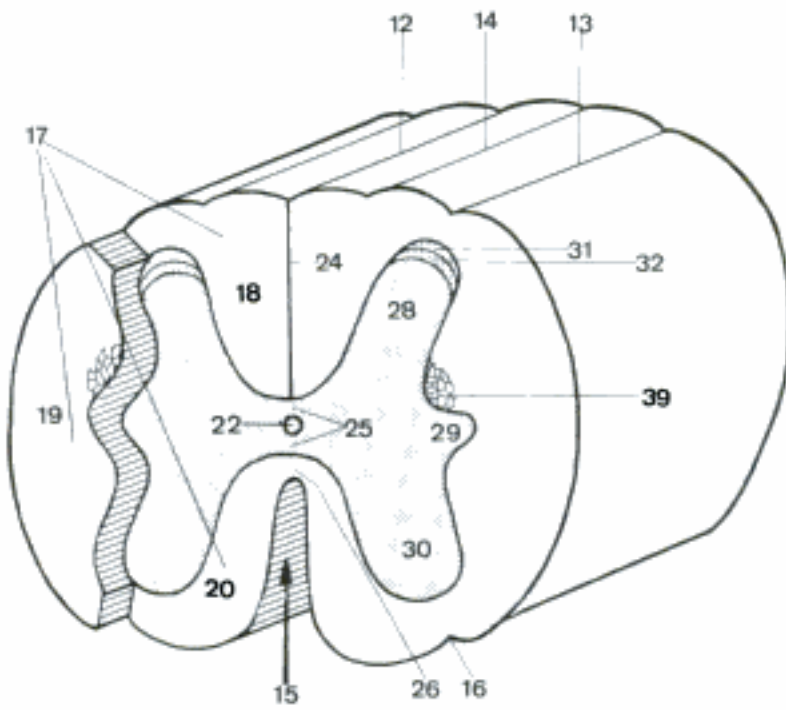


D Thymus (bo, neonate)

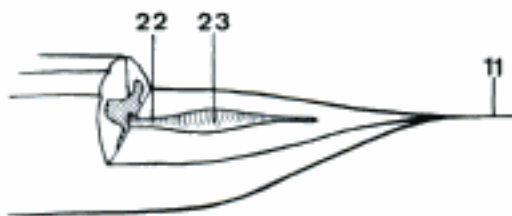
- 1 **SYSTEMA NERVOSUM CENTRALE.** Central nervous system.
- 2 **MEDULLA SPINALIS.** Spinal cord, extends from the first Nervi cervicales to the end of the Filum terminale. A
- 3 *Pars cervicalis.* Cervical part, corresponds to Nn. cervicales. A
- 4 *Intumescentia cervicalis.* Cervical enlargement between C6 and T2. A
- 5 *Pars thoracica.* Thoracic part, corresponds to Nn. thoracici. A
- 6 *Pars lumbalis.* Lumbar part, corresponds to Nn. lumbales. A
- 7 *Intumescentia lumbalis.* Lumbar enlargement, within Vertebrae lumbales. A
- 8 *Pars sacralis.* Sacral part, corresponds to Nn. sacrales. A
- 9 *Pars caudalis.* Caudal part, corresponds to Nn. caudales. A
- 10 *Conus medullaris.* Medullary cone, the end of Medulla spinalis, that continues as the Filum terminale. A
- 11 *Filum terminale.* Thin filament of glial and ependymal cells. A C
- 12 *Sulcus medianus [dorsalis].* Groove between the Funiculi dorsales. B
- 13 *Sulcus lateralis dorsalis.* Groove between Funiculus dorsalis and lateralis. B
- 14 *Sulcus intermedius dorsalis.* Groove in the middle of the Funiculus dorsalis. B
- 15 *Fissura mediana [ventralis].* Median (ventral) fissure, deep longitudinal groove between the Funiculi ventrales. B
- 16 *Sulcus lateralis ventralis.* Groove between Funiculus ventralis and lateralis. B
- 17 *Funiculi medullae spinalis.* Funiculi of spinal cord, three paired columns of white matter, surrounding gray matter. B
- 18 *Funiculus dorsalis.* Column between Cornu dorsale and Septum medianum dorsale. B
- 19 *Funiculus lateralis.* Column between Cornu dorsale and Cornu ventrale. B
- 20 *Funiculus ventralis.* Column between Fissura mediana and Cornu ventrale. B
- 21 **Sectiones medullae spinalis.** Sections of the spinal cord.
- 22 *Canalis centralis.* Central canal. B C D
- 23 *Ventriculus terminalis.* Terminal ventricle, enlargement of Canalis centralis in the Conus medullaris. C
- 24 *Septum medianum dorsale.* Separates the Funiculi dorsales. B
- 25 *Commissura grisea.* Gray commissure, numerous non-myelinated fibers passing in the Substantia grisea, particularly dorsal to Canalis centralis. B
- 26 *Commissura alba.* White commissure, fibers passing between Fissura mediana and Substantia grisea. B
- 27 *Substantia grisea.* Gray matter, H- or butterfly-shaped central substance. D
- 28 *Cornu dorsale.* Dorsal horn. B D
- 29 *Cornu laterale.* Lateral horn. B D
- 30 *Cornu ventrale.* Ventral horn. B D
- 31 *Apex cornus dorsalis.* Apex or tip of dorsal horn. B D
- 32 *Substantia gelatinosa.* Rolando's substance. B D
- 33 *Nucleus thoracicus.* Stilling-Clarke nucleus in C8–L2–3. D
- 34 *Substantia intermedia centralis.* Substantia grisea that surrounds the Canalis centralis. D
- 35 *Substantia intermedia lateralis.* Substantia grisea between Cornu dorsale, ventrale, and laterale and Substantia intermedia centralis. D
- 36 *Nucleus cervicalis lateralis.* Lateral to Cornu dorsale, in C1–C3. D
- 37 *Nucleus motorius n. accessorii.* In the dorsal region of Cornu ventrale in C1–C6–7. D
- 38 *Nucleus tractus spinalis n. trigemini.* Continuation with Substantia gelatinosa, in many species in C1–C5–6. D
- 39 *Formatio reticularis.* Mixture of white and gray matter between Cornu dorsale and laterale. B



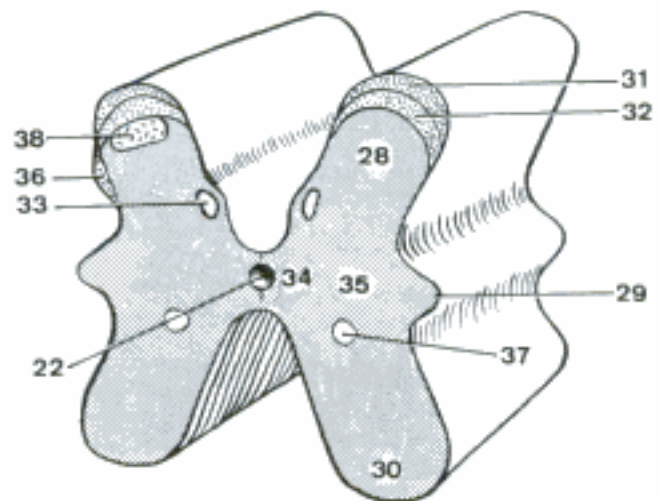
A Spinal cord, schematic dorsal aspect



B Spinal cord, schemati transverse section

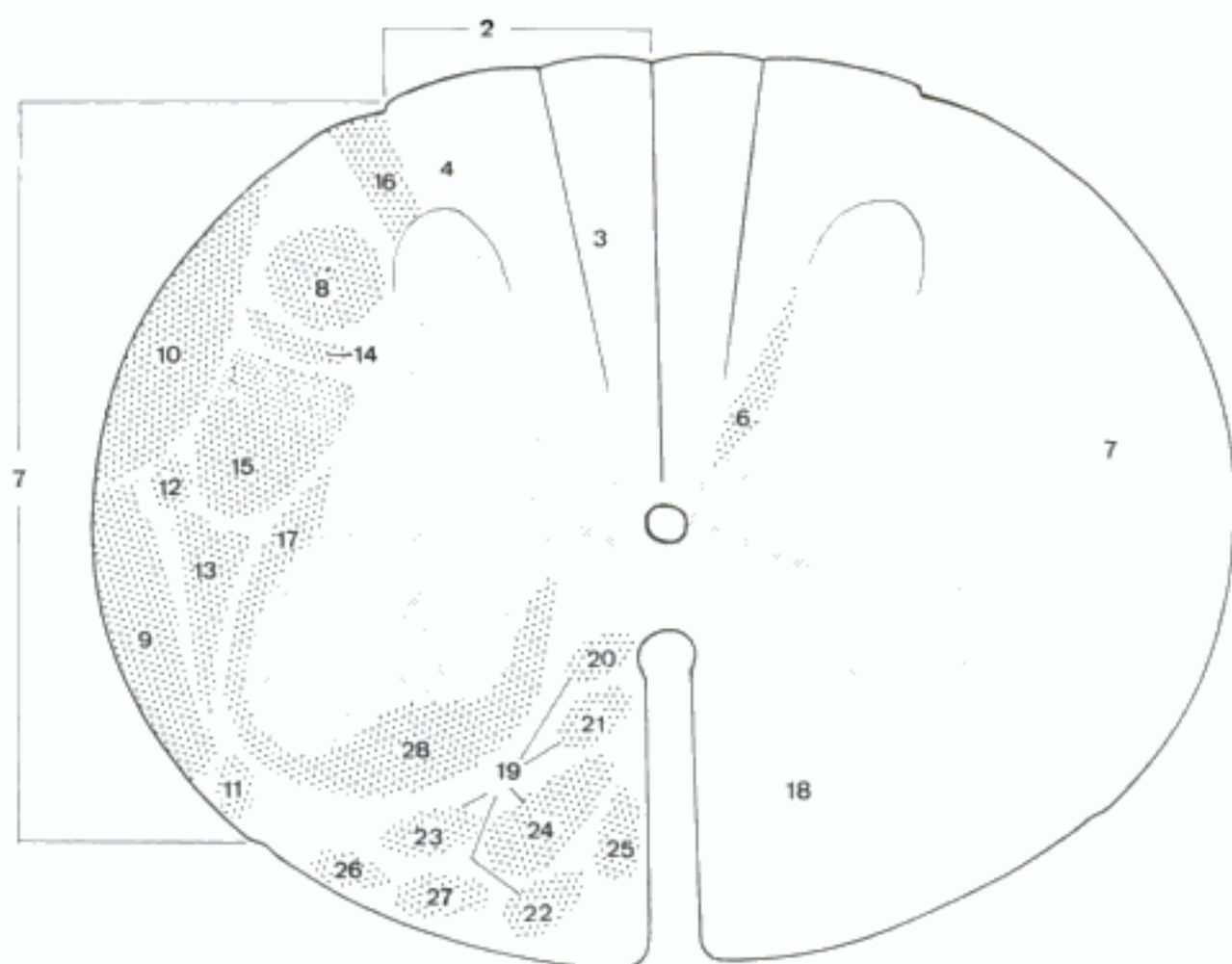


C Spinal cord, ventral half of caudal end

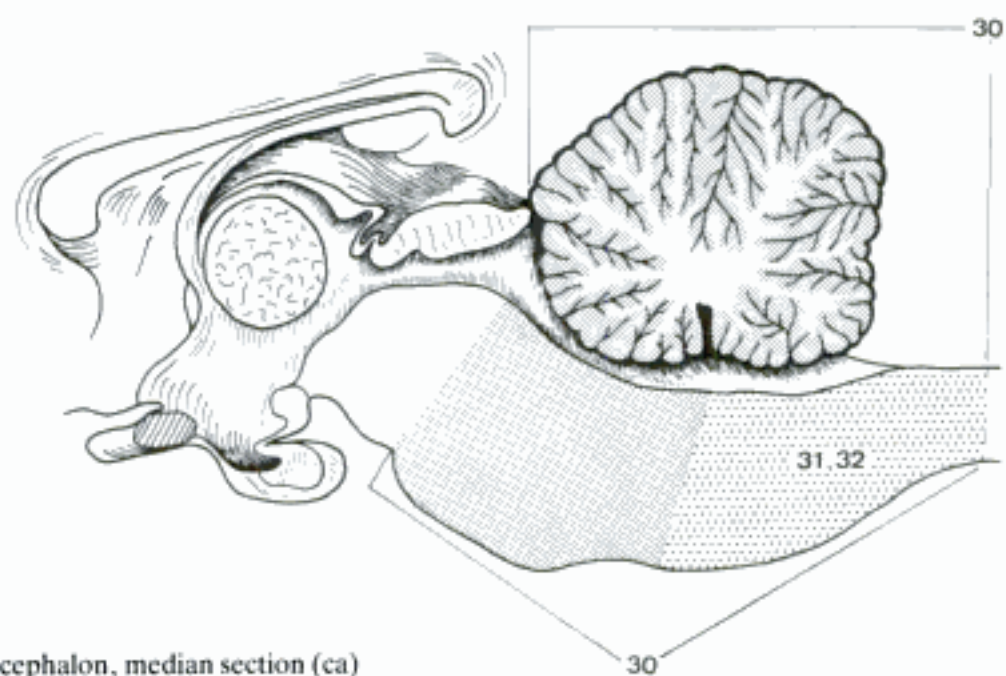


D Spinal cord, gray substance, schematic transverse section of cervical part (ca)

- 1 *Substantia alba*. White matter, represented by three paired peripheral funiculi.
- 2 **Funiculus dorsalis**. Conducts ascending pathways. A
- 3 *Fasciculus gracilis*. Goll's tract, medial segment of Funiculus dorsalis. A
- 4 *Fasciculus cuneatus*. Burdach's tract, lateral segment of Funiculus dorsalis. A
- 5 *Tractus pyramidalis [corticospinalis] dorsalis*. Dorsal pyramidal (corticospinal) tract. A trace of it appears in Un in the cranial cervical segments.
- 6 *Fasciuli proprii*. Proper fascicles, connect adjacent segments. A
- 7 **Funiculus lateralis**. Conducts descending and ascending pathways. A
- 8 *Tractus pyramidalis [corticospinalis] lateralis*. Lateral pyramidal (corticospinal) tract. A
- 9 *Tractus spinocerebellaris ventralis*. Ventral spinocerebellar or Gower's tract, on the lateroventral aspect of Funiculus lateralis. A
- 10 *Tractus spinocerebellaris dorsalis*. Dorsal spinocerebellar or Flechsig's tract, on the laterodorsal aspect of Funiculus lateralis. A
- 11 *Tractus spinotectalis*. Spinotectal tract. A
- 12 *Fibrae tectospinales laterales*. Lateral tectospinal fibers. There are also tectospinal fibers in the Funiculus ventralis. A
- 13 *Tractus spinothalamicus*. Spinothalamic tract. Although direct spinothalamic fibers may be too rare to justify their designation as a tract, there does exist a polynuclear system between Medulla spinalis and thalamus for which is useful a collective term. A
- 14 *Tractus reticulospinalis lateralis*. Lateral reticulospinal tract. A
- 15 *Tractus rubrospinalis*. Rubrospinal or Monakow's tract, connects Nucleus ruber to Cornu ventrale. A
- 16 *Tractus dorsolateralis*. Dorsolateral or Lissauer's tract, short fibers between Substantia gelatinosa and surface of the Medulla spinalis. A
- 17 *Fasciculi proprii*. Proper fascicles, connect adjacent segments. A
- 18 **Funiculus ventralis**. Conducts descending pathways. A
- 19 *Fasciculus longitudinalis medialis*. Medial longitudinal fascicle, particularly well-developed in Un. It is in part a continuation of Fasciculus longitudinalis medialis encephali and is made up of a mixture in variable proportions of several types of fibers. A
- 20 *Pars commissurospinalis*. Starting from Nucleus prethalamicus, formerly Nucleus commissurae posterioris. A
- 21 *Pars interstitiospinalis*. Origin in Nucleus interstitialis of mesencephalon. A
- 22 *Pars tectospinalis*. Starting from Tectum mesencephali. A
- 23 *Pars vestibulospinalis*. Starting from Nuclei vestibulares. A
- 24 *Pars reticulospinalis*. Origin in Formatio reticularis of Tegmentum mesencephali. A
- 25 *Tractus pyramidalis [corticospinalis] ventralis*. Ventral pyramidal (corticospinal) tract, homolateral fibers extending to Pars thoracica. A
- 26 *Tractus spinoolivaris*. Termination in Nucleus olivaris. A
- 27 *Tractus spinothalamicus*. Spinothalamic tract, see 13. A
- 28 *Fasciculi proprii*. Proper fascicles, connect adjacent segments. A
- 29 **ENCEPHALON**. Brain, consisting of myelencephalon, metencephalon, mesencephalon, diencephalon and telencephalon.
- 30 **RHOMBENCEPHALON**. Hindbrain, consists of myelencephalon and metencephalon. B
- 31 **Myelencephalon**. Medulla oblongata, extends from the first pair of Nervi cervicales to pons. B
- 32 **Medulla oblongata**. Same as myelencephalon. B



A Spinal cord, schematic section



B Rhombencephalon, median section (ca)

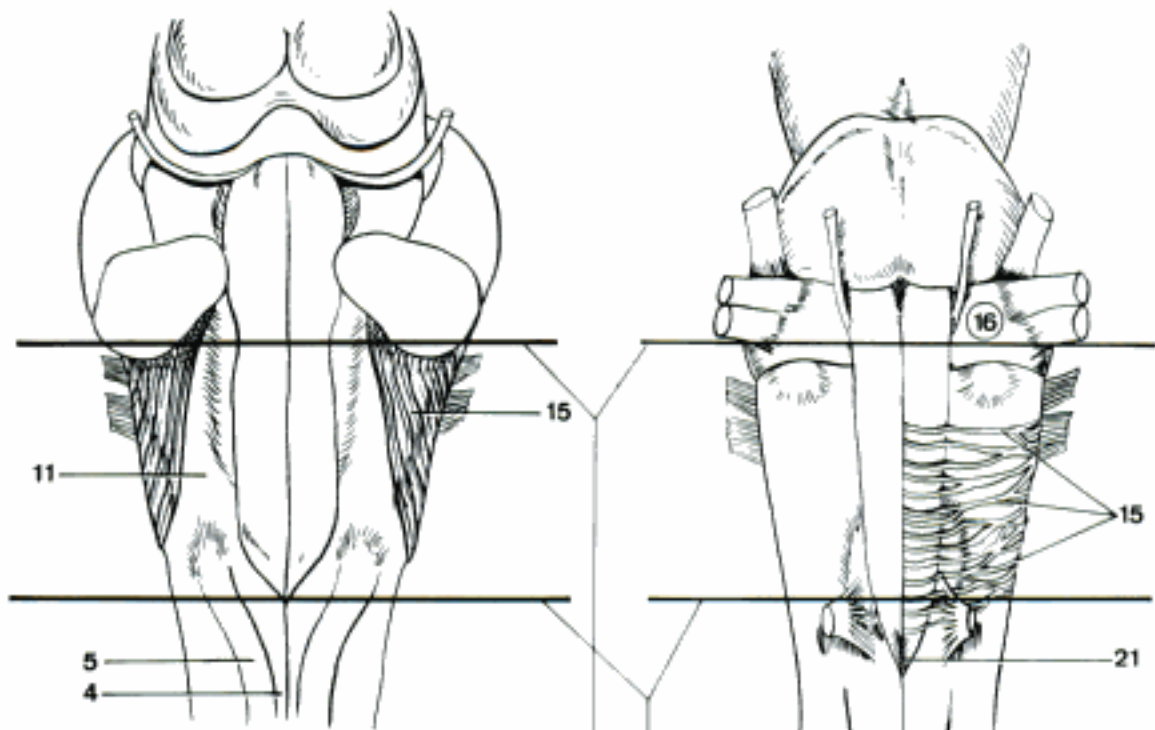
- 1 *Fissura mediana [ventralis]*. Median (ventral) fissure, groove continuing Fissura mediana [ventralis] of Medulla spinalis. A
- 2 *Pyramis [medullae oblongatae]*. Pyramid of medulla oblongata, longitudinal paired prominence. A
- 3 *Decussatio pyramidum*. Pyramidal decussation, visible on the ventral surface of the Medulla oblongata, can also be seen in sections. A
- 4 *Sulcus lateralis ventralis*. Ventral lateral sulcus, groove lateral to the pyramid, exit of Nn. hypoglossus and abducens. A
- 5 *Sulcus lateralis dorsalis*. Dorsal lateral sulcus, extends along the dorsal aspect of Medulla oblongata toward the Recessus lateralis ventriculi quarti. B
- 6 *Sulcus intermedius dorsalis*. Dorsal intermediate sulcus, separates Fasciculus gracilis from Fasciculus cuneatus. B
- 7 *Oliva*. Olive, does not exist as external prominence in many species. A
- 8 *Pedunculus cerebellaris caudalis*. Caudal cerebellar peduncle, connection of medulla oblongata to cerebellum. B
- 9 *Corpus restiforme*. Restiform body, lateral main part of Pedunculus cerebellaris caudalis, contains largely tracts of afferent fibers. B
- 10 *Corpus juxtarestiforme*. Juxtarestiform body, medial smaller part of Pedunculus cerebellaris caudalis, contains Tractus vestibulocerebellaris and cerebellovestibularis. B
- 11 *Funiculus lateralis*. Continuation of Funiculus lateralis medullae spinalis. A B
- 12 *Fasciculus cuneatus*. Burdach's tract, continuation of the corresponding tract of Medulla spinalis. B
- 13 *Tuberculum nuclei cuneati*. Cuneate tubercle, prominence at the level of Nucleus cuneatus. B
- 14 *Fasciculus gracilis*. Goll's tract, continuation of the corresponding tract of Medulla spinalis. B
- 15 *Tuberculum nuclei gracilis*. Gracilis tubercle or clava, prominence at the level of Nucleus gracilis. B
- 16 *Fibrae arcuatae superficiales*. Superficial arcuate fibers from Nuclei cuneatus lateralis and arcuatus to cerebellum. B
- 17 *Sulcus medianus [dorsalis]*. Groove continuing Sulcus medianus of Medulla spinalis up to obex. B
- 18 **Sectiones medullae oblongatae**. Sections through medulla oblongata.
- 19 *Raphe [Rhaphe]*. Suture-like median wall, mainly by crossing fibers. D
- 20 *Tegmentum rhombencephali*. Area ventral to Canalis centralis and Ventriculus quartus, dorsal to olives and pyramids, contains nuclei of V–XII. D
- 21 *Nucleus motorius n. hypoglossi*. C D
- 22 *Nucleus intercalatus*. Staderini's nucleus, probably provides reflex connections to Nucleus motorius n. hypoglossi. C D
- 23 *Nucleus prepositus [prae-] n. hypoglossi*. Marburg's nucleus, probably provides reflex connections to Nucleus motorius n. hypoglossi. C
- 24 *Nucleus ambiguus [Nucleus motorius nn. vagi et glossopharyngei]*. C D
- 25 *Nucleus parasympathicus n. vagi*. C D
- 26 *Nucleus parasympathicus n. glossopharyngei*. C
- 27 *Nucleus motorius n. accessorii*. C
- 28 *Tractus solitarius*. Gustatory fibers of nn. VII and IX, sensory fibers of nn. IX and X, ending in Nucleus tractus solitarii. C D
- 29 *Nucleus tractus solitarii*. Condensation of nervous cell bodies, associated with Tractus solitarius. C D

Hidden page

Hidden page

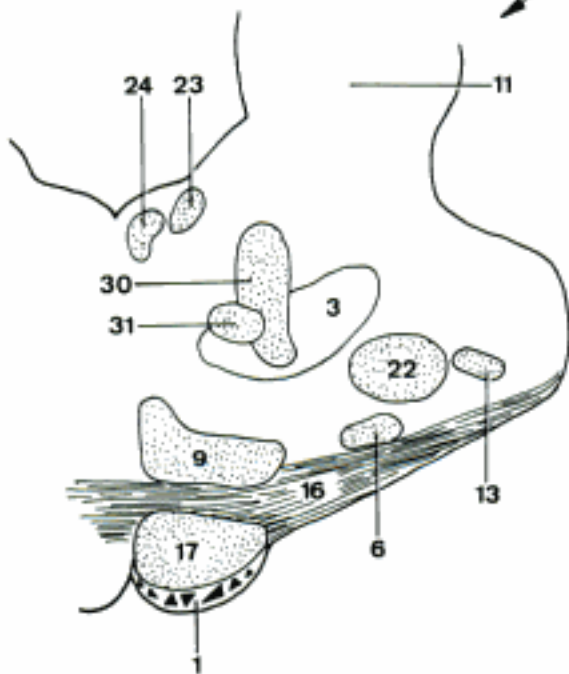
Hidden page

Hidden page

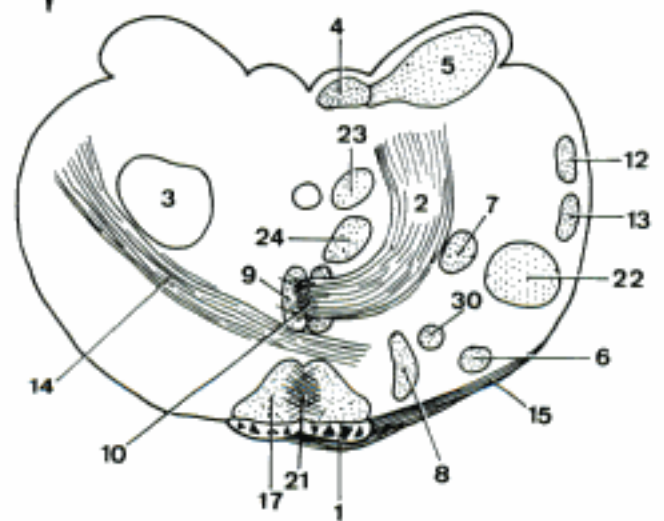


A Medulla oblongata and pons, dorsal aspect (ca)

B Medulla oblongata and pons, ventral aspect (ca)



C Medulla oblongata, rostral transverse section (ca)

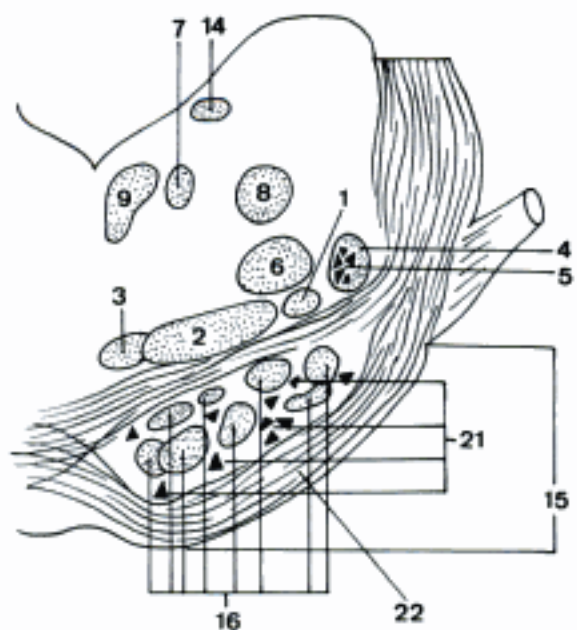


D Medulla oblongata, caudal transverse section (ca)

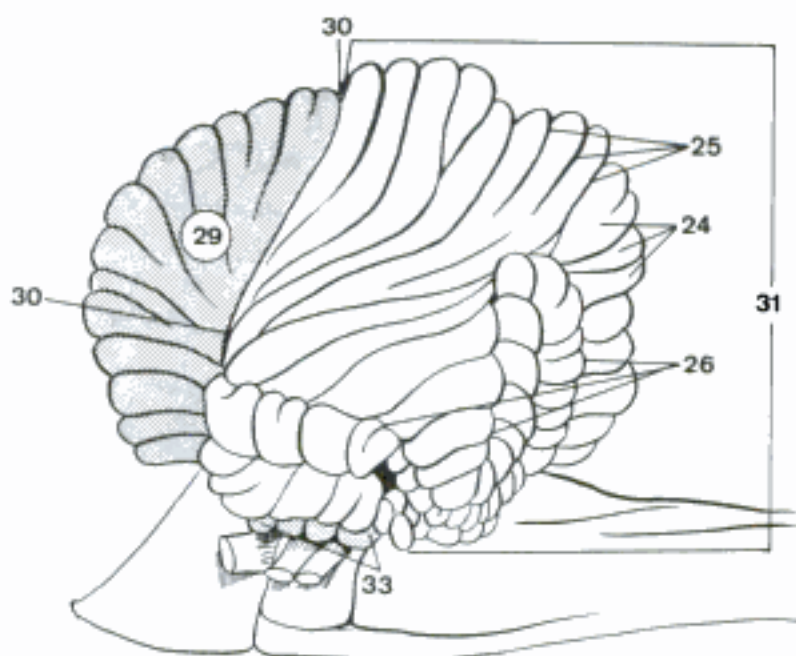
- 1 **Metencephalon.** Rostal part of Rhombencephalon, consisting of pons and cerebellum. A
- 2 **Pons.** Bridge, between mesencephalon and medulla oblongata. Consists of transverse fibers and cell groups of cerebrocerebellar pathways and rostral part of Tegmentum rhombencephali. A B
- 3 *Sulcus basilaris.* Median groove, produced by right and left pyramidal tracts. B
- 4 *Pedunculus cerebellaris medius [Brachium pontis].* Middle cerebellar peduncle, communication between pons and cerebellum. A B D
- 5 **Sectiones pontis.** Sections through pons. D E
- 6 **Pars dorsalis pontis [Tegmentum pontis].** Floor of the rostral half of Ventriculus quartus and deep adjacent structures. D E
- 7 *Raphe [Rhaphe].* Median suture-like structure, mainly crossing fibers. D E
- 8 *Formatio reticularis.* Similar to Formatio reticularis medullae oblongatae. D E
- 9 *Nucleus motorius n. abducentis.* In some species located in medulla oblongata. C E
- 10 *Nucleus motorius n. facialis.* In some species located in medulla oblongata. C E
- 11 *Genu n. facialis.* Loop of fibers from Nucleus motorius n. facialis, dorsal to Nucleus motorius n. abducentis. C E
- 12 *Nucleus motorius n. trigemini.* C D
- 13 *Nucleus sensibilis pontinus n. trigemini.* Origin of fibers forming after decussation the Lemniscus trigeminalis. C D
- 14 *Tractus mesencephalicus n. trigemini.* Fibers to Nucleus tractus mesencephalicus n. trigemini. C
- 15 *Nucleus tr. mesencephalici n. trigemini.* Rostral sensory trigeminal nucleus. C
- 16 *Nucleus ceruleus [caeruleus].* Bluish columnar cell group. D
- 17 *Tractus spinalis n. trigemini.* Tract descending into the Medulla spinalis, contains pain and temperature fibers of N. trigeminus. C E
- 18 *Nucleus tractus spinalis n. trigemini.* Nucleus for the fibers of Tractus spinalis n. trigemini. E
- 19 *Nuclei n. vestibulocochlearis.* In some species some of them located in medulla oblongata. C
- 20 *Nucleus cochlearis ventralis.* Ventral nucleus of the cochlear part of N. vestibulocochlearis. In some species located in medulla oblongata. C E
- 21 *Nucleus cochlearis dorsalis [Tuberculum acusticum].* Dorsal nucleus of the cochlear part of N. vestibulocochlearis. In some species located in medulla oblongata. C E
- 22 *Nucleus vestibularis rostralis.* Bechterew's nucleus. C
- 23 *Nucleus vestibularis medialis.* Triangular or Schwalbe's nucleus. C E
- 24 *Nucleus vestibularis lateralis.* Deiter's nucleus. C E
- 25 *Nucleus vestibularis caudalis. [descendens].* Spinal or Roller's nucleus. C
- 26 *Stria acustica.* Fibers from Nucleus cochlearis dorsalis which pass over Pedunculus cerebellaris caudalis and course medially into the floor of Ventriculus quartus. C
- 27 *Corpus trapezoideum.* Trapezoid body. Sheet of transversely running fibers from the Nuclei cochleares, part of auditory pathway. B E
- 28 *Nucleus dorsalis corporis trapezoidei.* Formerly Nucleus olivaris superior. Origin of a part of Lemniscus lateralis. C E
- 29 *Nuclei ventrales corporis trapezoidei.* Origin of a part of Lemniscus lateralis. C E
- 30 *Pedunculus cerebellaris rostralis [Brachium conjunctivum].* Connects mesencephalon to cerebellum. C D

Hidden page

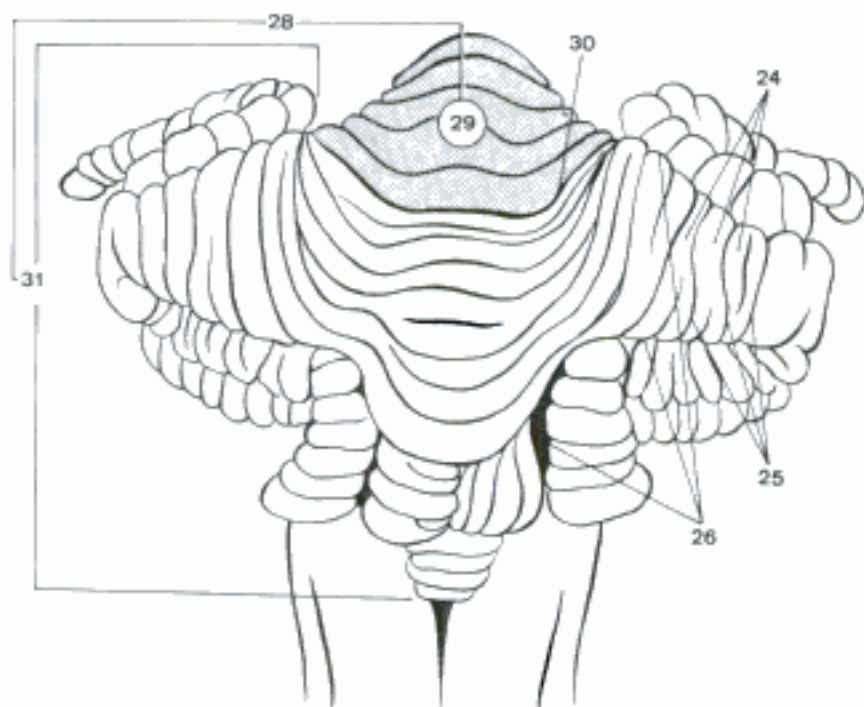
- 1 *Tractus spinothalamici*. See 416. 13. A
- 2 *Lemniscus medialis*. Crossed fibers connecting Nuclei gracilis and cuneatus medialis to thalamus. A
- 3 *Lemniscus trigeminalis*. Crossed fibers connecting Nucleus sensibilis pontinus n. trigemini to thalamus. A
- 4 *Lemniscus lateralis*. Partially crossed fibers connecting Nuclei cochleares to Colliculus caudalis and Corpus geniculatum mediale. A
- 5 *Nucleus lemnisci lateralis*. Synapses of some fibers in the Lemniscus lateralis. A
- 6 *Tractus rubrospinalis*. Monakow's tract, connects Nucleus ruber with Medulla spinalis. A
- 7 *Tractus tectospinalis*. Connects Tectum mesencephali with Medulla spinalis. A
- 8 *Tractus tegmenti centralis*. Connects Pallidum, Zona incerta subthalami, and Nucleus ruber to Nucleus olivaris (Car). A
- 9 *Fasciculus longitudinalis medialis*. A
- 10 *Pars commissurospinalis*. Starting from Nucleus prethalamicus, formerly Nucleus commissurae posterioris.
- 11 *Pars interstitiospinalis*. Origin in Nucleus interstitialis of mesencephalon.
- 12 *Pars tectospinalis*. Starting from Tectum mesencephali.
- 13 *Pars reticulospinalis*. Origin in Formatio reticularis of Tegmentum mesencephali.
- 14 *Fasciculus longitudinalis dorsalis*. Schütz's bundle, starts from Nucleus periventricularis caudalis hypothalami, to Substantia grisea centralis mesencephali and Medulla spinalis. A
- 15 *Pars ventralis pontis*. A
- 16 *Tractus pyramidalis*. A
- 17 *Fibrae corticonucleares*. Fibers from Cortex cerebri to Nuclei nervorum cranialium.
- 18 *Fibrae corticospinales*. Fibers from Cortex cerebri to Medulla spinalis.
- 19 *Fibrae corticoreticulares*. Fibers from Cortex cerebri to Formatio reticularis of Medulla oblongata and Medulla spinalis.
- 20 *Tractus corticopontinus*. Connects Cortex frontalis, temporalis, and occipitalis to Nuclei pontis.
- 21 *Nuclei pontis*. Pontine nuclei, related to Tractus corticopontinus. A
- 22 *Fibrae pontis transversae*. Transverse pontine fibers, from Nuclei pontis to cerebellum. A
- 23 **Cerebellum**. Part of metencephalon dorsal to Fossa rhomboidea. For the nomenclature the subdivisions established by Larsell have been adapted, however the classical names of the lobules have been retained. B C D
- 24 *Folia cerebelli*. Cerebellar folia, gracile gyri separated by fissures. B C
- 25 *Fissurae cerebelli*. Cerebellar fissures, deep and narrow grooves between Folia cerebelli. B C
- 26 *Sulci cerebelli*. Cerebellar sulci, grooves between Vermis and Hemispherium and between parts of the Hemispherium. B C
- 27 *Vallecula cerebelli*. Large ventral groove. D
- 28 *Corpus cerebelli*. Cerebellar body, made up of Lobus rostralis and caudalis, separated from Lobus flocculonodularis by Fissura uvulonodularis (Fiss. posterolateralis of N. A.). B D
- 29 *Lobus rostralis*. B C D
- 30 *Fissura prima*. B C
- 31 *Lobus caudalis*. B C D
- 32 *Fissura uvulonodularis*. Separates Uvula from Nodus and corresponding parts of Hemispherium. D
- 33 *Lobus flocculonodularis*. Fusion of Flocculi of hemispheres and Nodus vermis. C D



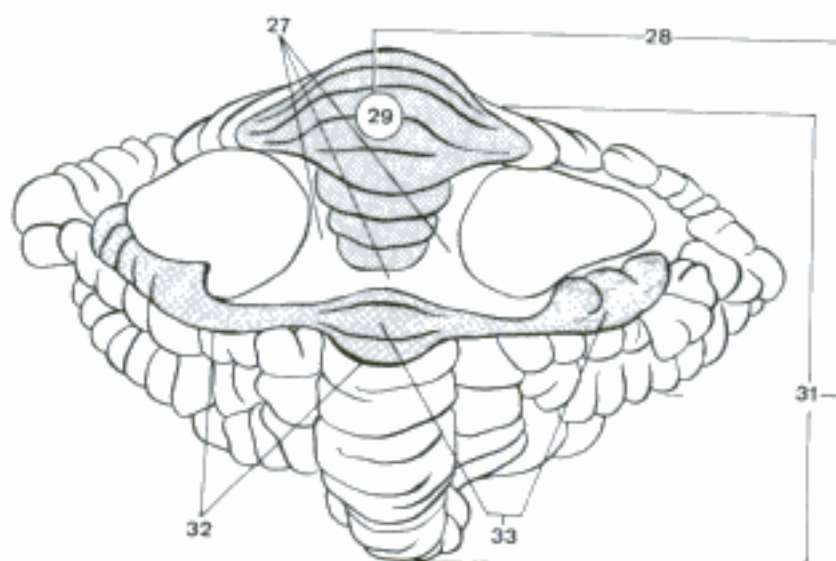
A Pons, transverse section (ca)



C Rhombencephalon, lateral aspect (ca)

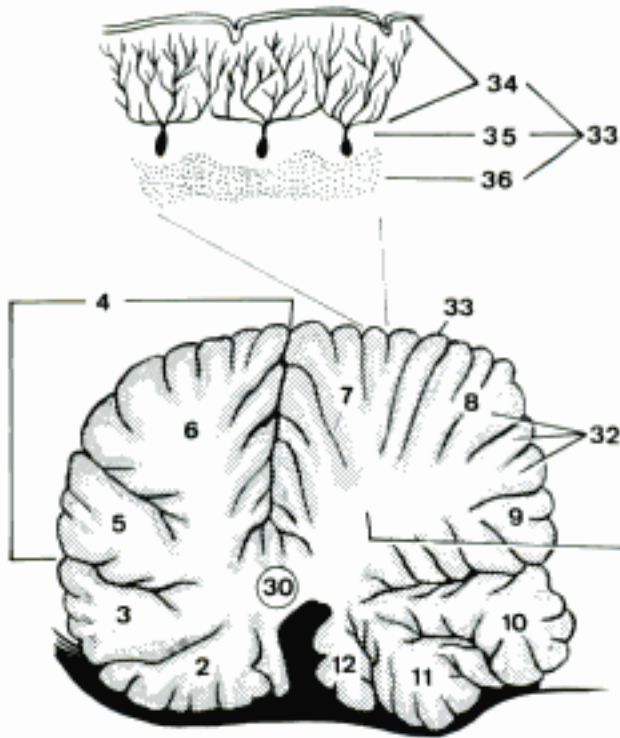


B Cerebellum, caudodorsal aspect (ca)

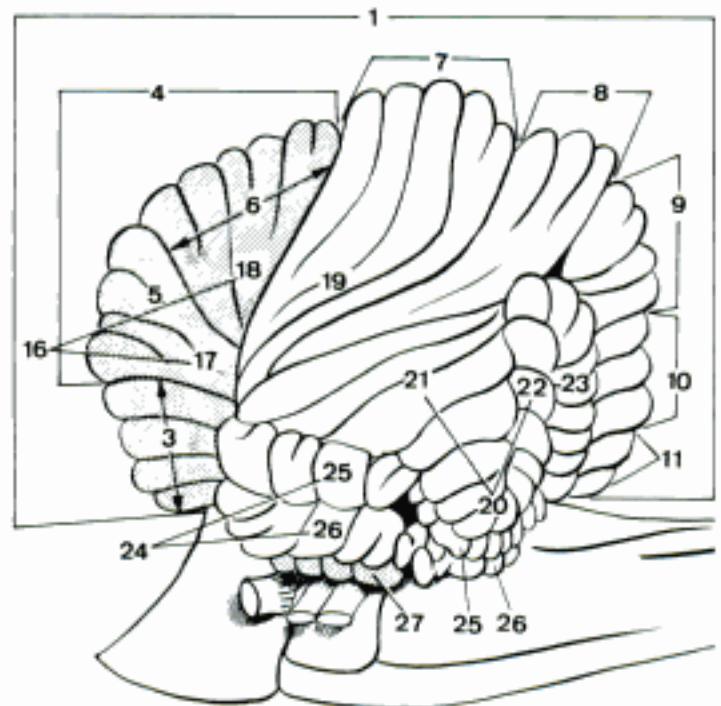


D Cerebellum, ventral aspect (ca)

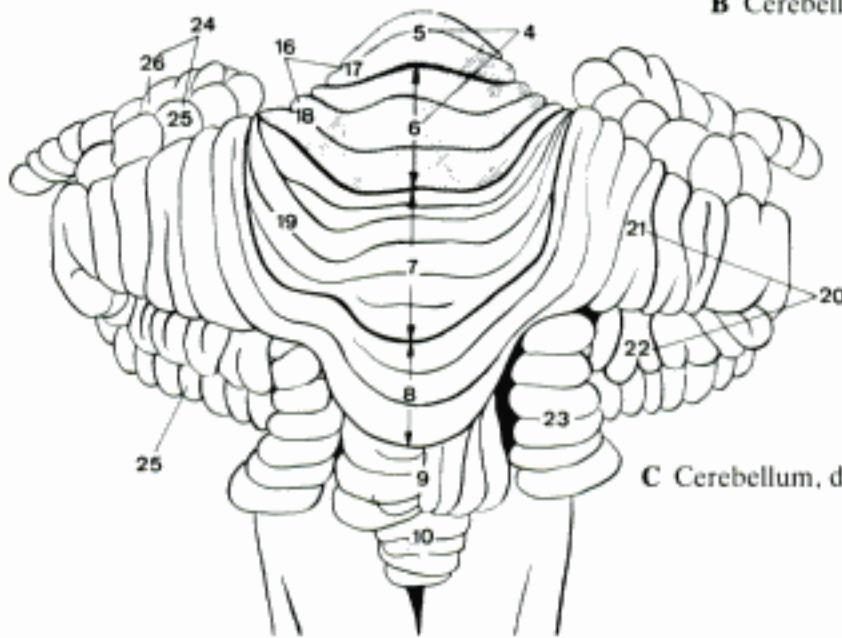
- 1 *Vermis*. Unpaired major component of cerebellum. A B D
- 2 *Lingula cerebelli*. Corresponds to Vinculum lingulae hemispherii. A D
- 3 *Lobulus centralis*. Corresponds to Ala lobuli centralis hemispherii. A B D
- 4 *Culmen*. Corresponds to Lobulus quadrangularis hemispherii. A B C
- 5 Pars rostralis. A B C
- 6 Pars caudalis. A B C
- 7 *Declive*. Corresponds to Lobulus simplex hemispherii. A B C
- 8 *Folium vermis*. Corresponds to Crus rostrale lobuli ansiformis hemispherii. A B C
- 9 *Tuber vermis*. Corresponds to Crus caudale lobuli ansiformis hemispherii. A B C
- 10 *Pyramis [vermis]*. Corresponds to Lobulus paramedianus and Paraflocculus dorsalis hemispherii. A B C D
- 11 *Uvula [vermis]*. Corresponds to Paraflocculus ventralis hemispherii. A B D
- 12 *Nodus*. Corresponds to Flocculus hemispherii. A D
- 13 *Hemisphaerium [Hemisphaerium] cerebelli*. D
- 14 *Vinculum lingulae*. Corresponds to Lingula cerebelli. D
- 15 *Ala lobuli centralis [Prolatio aliformis]*. Corresponds to Lobulus centralis vermis. D
- 16 *Lobulus quadrangularis*. Corresponds to Culmen vermis. B C
- 17 Pars rostralis. B C
- 18 Pars caudalis. B C
- 19 *Lobulus simplex*. Corresponds to Declive vermis. B C
- 20 *Lobulus ansiformis*. Corresponds to Folium vermis and Tuber vermis. B C
- 21 *Crus rostrale*. Corresponds to Folium vermis. B C D
- 22 *Crus caudale*. Corresponds to Tuber vermis. B C D
- 23 *Lobulus paramedianus*. Corresponds to a part of Pyramis vermis. B C D
- 24 *Paraflocculus*. B C D
- 25 *Paraflocculus dorsalis*. Corresponds to a part of Pyramis vermis. B C D
- 26 *Paraflocculus ventralis*. Corresponds to Uvula vermis. B C D
- 27 *Flocculus*. Corresponds to Nodus vermis. B D
- 28 *Pedunculus flocculi*. Connecting bridge to Nodus. D
- 29 **Sectiones cerebelli**. A
- 30 *Corpus medullare*. Central white matter, with myelinated fibers. A
- 31 *Arbor vitae*. Branching of white matter, resembling "tree of life". A
- 32 *Laminae albae*. White laminae, penetrating as digitations into Folia cerebelli. A
- 33 *Cortex cerebelli*. Cerebellar cortex. A
- 34 *Stratum moleculare*. Molecular layer, external cortical layer consisting of dendrites of Purkinje cells and basket-like cells with their axons and dendrites. A
- 35 *Stratum neuronorum piriformium*. Layer of piriform neurons, new term that identifies the layer of Purkinje cells. A
- 36 *Stratum granulosum*. Granular layer, deepest cortical layer with abundant cells, axons, and dendrites of granular neurons.



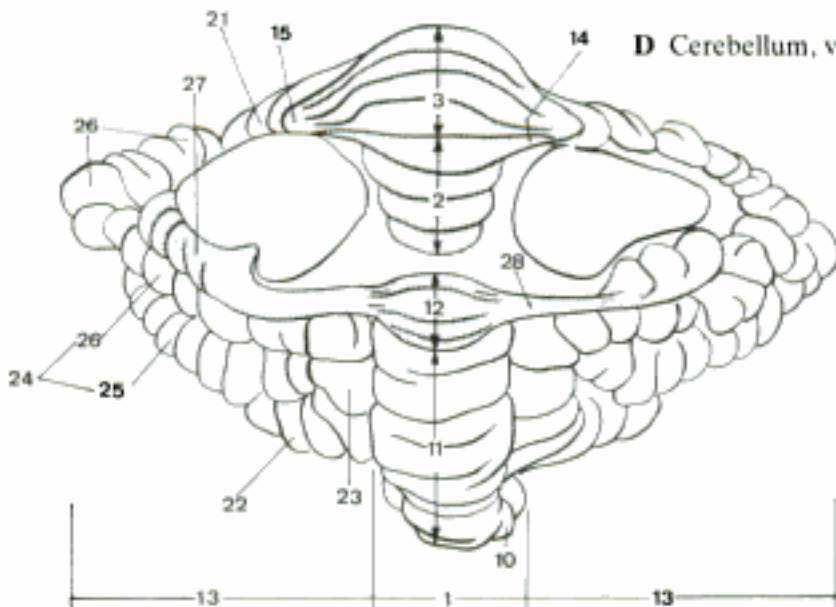
A Cerebellum, median section through vermis (ca)



B Cerebellum, lateral aspect (ca)

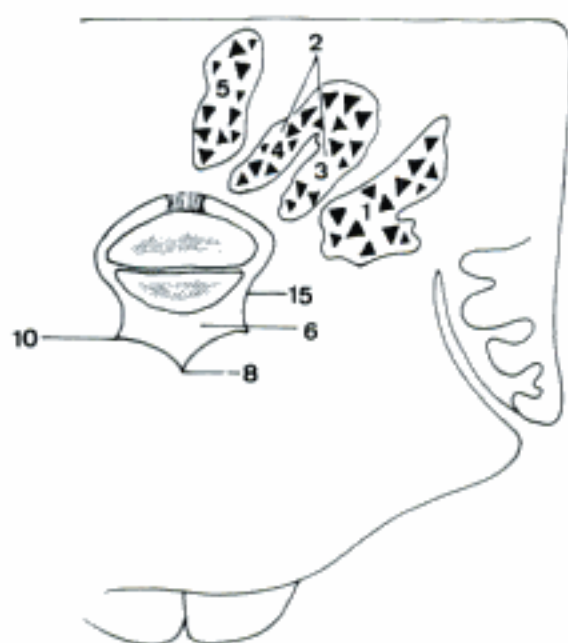


C Cerebellum, dorsal aspect (ca)

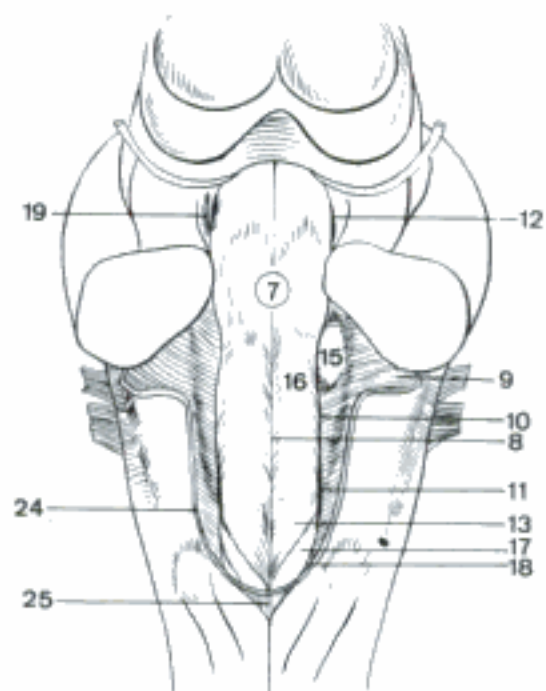


D Cerebellum, ventral aspect (ca)

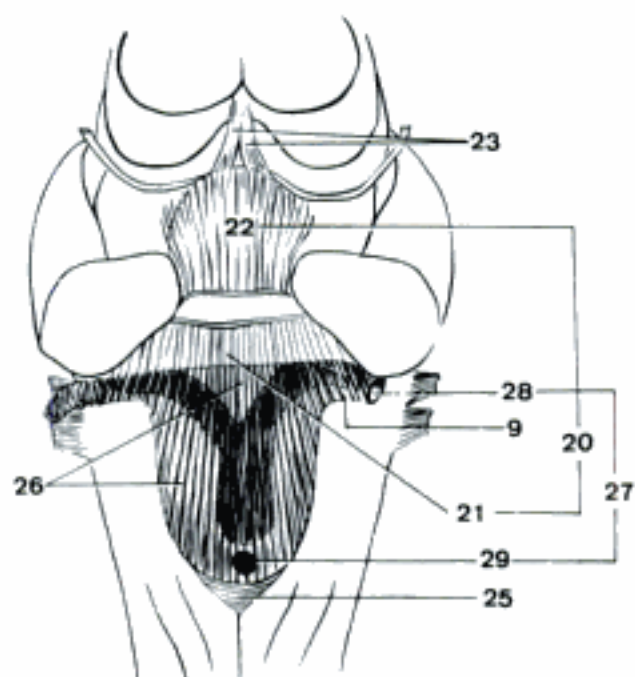
- 1 *Nucleus lateralis cerebelli* [*Nucleus dentatus*]. Lateral nucleus of cerebellum, the largest, located lateroventrally within Corpus medullare. A
- 2 *Nuclei interpositi cerebelli*. Intercalated cerebellar nuclei, between Nucleus lateralis cerebelli and Nucleus fastigii. A
- 3 *Nucleus interpositus lateralis cerebelli* [*Nucleus emboliformis*]. A
- 4 *Nucleus interpositus medialis cerebelli* [*Nucleus globosus*]. A
- 5 *Nucleus fastigii*. Fastigial nucleus, most medial within Corpus medullare. A
- 6 **Ventriculus quartus**. Fourth ventricle, belongs to rhombencephalon as a whole. A
- 7 *Fossa rhomboidea*. Floor of Ventriculus quartus, becomes visible after removal of cerebellum and Tegmen ventriculi quarti. B
- 8 *Sulcus medianus*. Longitudinal median groove. A B
- 9 *Recessus lateralis ventriculi quarti*. Lateral recess of fourth ventricle, ends at Apertura lateralis ventriculi quarti. B C
- 10 *Sulcus limitans*. Groove parallel to Sulcus medianus, separating Eminentia medialis from the rest of Fossa rhomboidea. A B
- 11 *Fovea caudalis*. Shallow groove at the rostral tip of Trigonum n. vagi. B
- 12 *Fovea rostralis*. Rostral depression of Sulcus limitans. B
- 13 *Trigonum n. hypoglossi*. Medial and caudal to Trigonum n. vagi, covering Nucleus motorius n. hypoglossi. B
- 14 *Striae medullares ventriculi quarti*. Medullary striae of fourth ventricle, not discernible in most mammals. The same structure is also listed as Stria acustica (424.26).
- 15 *Eminentia nuclei vestibularis medialis*. Rostral to Recessus lateralis ventriculi quarti, on the lateral side of Fossa rhomboidea. A B
- 16 *Eminentia medialis*. Between Sulcus medianus and Sulcus limitans. B
- 17 *Trigonum n. vagi*. Vagal trigone, lateral to Trigonum n. hypoglossi. B
- 18 *Area postrema*. Area with a specific histologic structure. B
- 19 *Locus ceruleus* [*caeruleus*]. Bluish columnar cell group in lateral wall of Ventriculus quartus. B
- 20 *Tegmen ventriculi quarti*. Roof of fourth ventricle. C
- 21 *Velum medullare caudale*. Lamella between right and left Pedunculus cerebellaris caudalis, Nodus and Tela choroidea ventriculi IV. C
- 22 *Velum medullare rostrale*. Lamella between right and left Pedunculus cerebellaris rostralis and Lingula cerebelli. C
- 23 *Frenulum veli medullaris rostralis*. Thin band-like structure connecting Velum medullare rostrale to Lamina tecti mesencephali. C
- 24 *Tenia* [*Taenia*] *ventriculi quarti*. Tenia of fourth ventricle, cut edge of roof of the caudal part of Ventriculus quartus. B
- 25 *Obex*. Unpaired transverse structure at the caudal extent of the roof of Ventriculus quartus that ends Sulcus medianus medullae oblongatae. B C
- 26 *Tela choroidea* [*choroidea*] *ventriculi quarti*. Layer of pia mater and ependyma between Velum medullare caudale and Tenia ventriculi quarti. C
- 27 *Aperturæ ventriculi quarti*. Openings of fourth ventricle. C
- 28 *Aperturæ laterales ventriculi quarti*. Luschka's foramina, correspond to Recessus laterales ventriculi quarti. C
- 29 (*Apertura mediana ventriculi quarti*). Magendie's foramen, unpaired opening rostral to obex. C



A Cerebellum, transverse section (ca)



B Fossa rhomboidea (ca)



C Tegmen ventriculi quarti (ca)

Hidden page

Hidden page

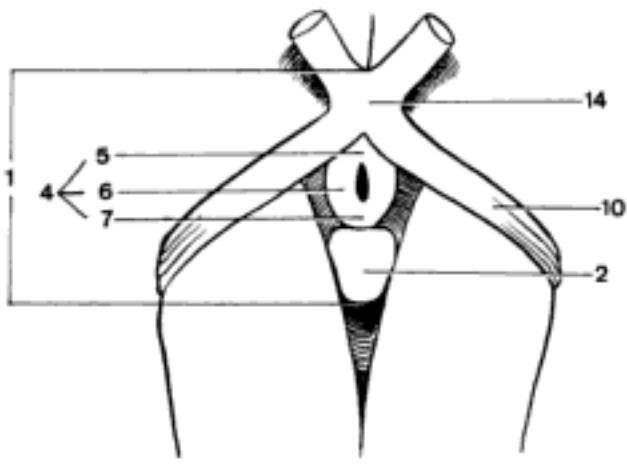
- 1 *Nucleus motorius n. oculomotorii*. A
- 2 *Nucleus motorius n. trochlearis*. Caudal to Nucleus motorius n. oculomotorii. B
- 3 *Nuclei parasympathici n. oculomotorii*. Edinger-Westphal's nucleus, dorso-medial to Nucleus motorius n. oculomotorii. A
- 4 *Nucleus interpeduncularis*. Related to the olfactory pathway. A
- 5 *Nuclei tegmenti*. Tegmental (Gudden's) nuclei, located in *Formatio reticularis*, give fibers to the *Fasciculus longitudinalis medialis*. A
- 6 *Nucleus interstitialis*. Cajal's nucleus, fibers from Nuclei vestibulares, Pallidum, and *Stratum griseum colliculi rostralis*. A
- 7 *Nucleus prestitialis [prae-]*. Former Nucleus commissurae posterioris.
- 8 *Nucleus precommissuralis [prae-]*.
- 9 *Nucleus ruber*. Red (Stilling's) nucleus, afferent fibers from *Cerebellum* and cortex, origin of *Tractus rubrospinalis*. A
- 10 *Pars magnocellularis*. Phylogenetically older caudal and middle parts, predominant in domestic mammals.
- 11 *Pars parvocellularis*. Phylogenetically younger rostral part, predominant in man.
- 12 *Decussationes tegmenti*. Tegmental decussations. In certain cases the two decussations are intermingled and difficult to distinguish. A
- 13 *Decussatio dorsalis*. Meynert's decussation of *Tractus tectospinalis*. A
- 14 *Decussatio ventralis*. Forel's decussation of *Tractus rubrospinales* and *Fibrae rubroreticulares*. A
- 15 *Pedunculus cerebellaris rostralis [Brachium conjunctivum]*. Paired arm, anchoring *Cerebellum* to mesencephalon. B
- 16 *Decussatio pedunculorum cerebellarium rostraliuum*. In the caudal segment of *Tegmentum*, ventral to *Fasciculus longitudinalis medialis*. B
- 17 *Decussatio nervorum trochlearium*. Within the *Velum medullare rostrale*.
- 18 *Lemniscus trigeminalis*. Built up of crossed fibers connecting the sensory trigeminal nuclei to thalamus. B
- 19 *Lemniscus medialis*. Crossed fibers connecting Nuclei gracilis and cuneatus medialis to thalamus. B
- 20 *Lemniscus lateralis*. Partially crossed fibers of auditory pathway corresponding to *Trigonum lemnisci*. B
- 21 *Nuclei lemnisci lateralis*. B
- 22 *Tractus spinothalamicus*. Accompanies the acoustic fibers of *Lemniscus lateralis*. See 416.13. B
- 23 *Fasciculi tegmenti*. Tegmental fascicles, large in Un, because they contain a wide secondary dorsal tract of Wallenberg, arising from *Nucleus sensibilis pontinus n. trigemini*. C
- 24 *Substantia nigra*. Black (Soemmering's) substance, separating *Crus cerebri* from *Tegmentum*, pigmented nuclear mass belonging to the extrapyramidal system. B
- 25 *Pars compacta*. B
- 26 *Pars reticulata*. B
- 27 *Crus cerebri*. See 432.3. B
- 28 *Tractus pyramidalis*. Contains fibers which end in mesencephalon or rhombencephalon, three kinds are observed. B
- 29 *Fibrae corticonucleares*. Connect the motor *Cortex cerebri* to Nuclei motorii nn. oculomotorii, trochlearis, and trigemini.
- 30 *Fibrae corticospinales*. End in *Medulla spinalis*.
- 31 *Fibrae corticoreticulares*. Connect *Cortex cerebri* to *Foramtio reticularis*.
- 32 *Tractus corticopontinus*. Variable location within *Crus cerebri*, but basically lateral to *Tractus pyramidalis*. In certain species two parts. B
- 33 *Pars frontopontina*. On the medial side of *Tractus pyramidalis*, greatly reduced or absent in domestic mammals. Besides, many fibers end in mesencephalon.
- 34 *Pars parietopontina*. On the lateral side of *Tractus pyramidalis*.

Hidden page

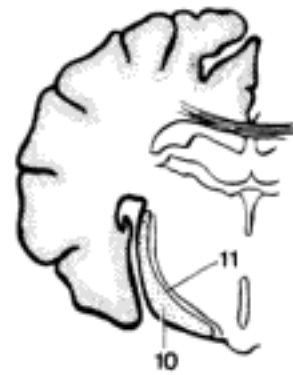Hidden page

Hidden page

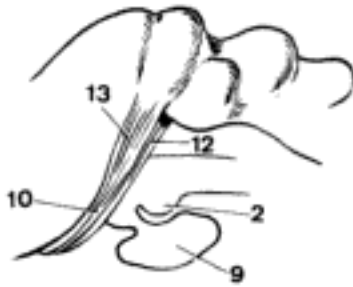
- 1 **Hypothalamus.** The most ventral component of diencephalon, separated from thalamus by Sulcus hypothalamicus. A
- 2 *Corpus mamillare.* Mamillary body, rostral to Fossa interpeduncularis, caudal to Tuber cinereum, between the two Crura cerebri. A C D
- 3 *Recessus inframamillaris.* Rostral recess of Fossa interpeduncularis. D
- 4 *Tuber cinereum.* Gray tubercle, between Chiasma opticum and Corpus mamillare. A D
- 5 *Pars rostralis tuberis.* Rostral to infundibulum. A
- 6 *Pars parainfundibularis tuberis.* On both sides of infundibulum. A
- 7 *Pars caudalis tuberis.* Caudal to infundibulum. A
- 8 *Sulcus tuberoinfundibularis.* Tuberoinfundibular groove. D
- 9 *Hypophysis [Glandula pituitaria]* (vide p. 232). C
- 10 *Tractus opticus.* Part of visual pathway between Chiasma opticum and Corpus geniculatum laterale. A B C
- 11 *Fasciculus paraopticus.* Small bundle of nerve fibers that course along the medial border of Tractus opticus of ov. It contains the contralateral retinal projections of the accessory optic system. B
- 12 *Radix medialis.* Medial root, disappears beneath Corpus geniculatum mediale, terminates in Colliculus rostralis. C
- 13 *Radix lateralis.* Lateral root, connects Tractus opticus to Corpus geniculatum laterale. C
- 14 *Chiasma opticum.* Crossing of medial fibers of Nn. optici. A F
- 15 *Lamina terminalis grisea.* Gray terminal lamina, plate of gray matter closing Ventriculus tertius rostrally, dorsal to Chiasma opticum. D
- 16 *Organum vasculosum laminae terminalis griseae.* Very small structure within Ventriculus tertius, dorsal to Recessus opticus. D
- 17 *Organum vasculosum hypothalami.* Ependymal organ with folded surface within Ventriculus tertius, ventral to Adhesio interthalamica, dorsal to Recessus neurohypophysialis. D
- 18 **Sectiones hypothalami.** Sections through hypothalamus.
- 19 *Stratum periventriculare.* Periventricular layer, around Ventriculus tertius, collective term for the following groups of nuclei.
- 20 **Regio hypothalamica rostralis cum Reg. preoptica [prae-].**
- 21 *Nucleus supraopticus.* Neurosecretory fibers extend to Neurohypophysis. E
- 22 *Pars suprachiasmatica.* Dorsal to Chiasma opticum. E
- 23 *Pars postchiasmatica.* Dorsal to Tractus opticus. E
- 24 *Nucleus suprachiasmaticus.* F
- 25 *Nucleus paraventricularis.* Between Commissura rostralis and Lamina terminalis grisea rostrally, and Adhesio interthalamica caudally. Neurosecretory fibers extend to Neurohypophysis. E
- 26 *Pars accessoria.* Represented by neurosecretory cells between Nuclei paraventricularis and supraopticus. E
- 27 *Nucleus paraventricularis parvocellularis.* Lateral to Nucleus paraventricularis.
- 28 *Nucleus hypothalamicus rostralis.* Between Commissura rostralis and Pars postchiasmatica nuclei supraoptici, lateral to Nucleus paraventricularis and Columna fornicis. F
- 29 *Nucleus preopticus [prae-] medianus.* Between Chiasma opticum and Commissura rostralis. F
- 30 *Nucleus preopticus [prae-] medialis.* F
- 31 *Nucleus preopticus [prae-] lateralis.* F
- 32 *Nucleus preopticus [prae-] periventricularis.* Between Nuclei preopticus medianus and paraventricularis. F
- 33 *Nucleus periventricularis rostralis.* Between Nuclei paraventricularis and hypothalamicus dorsomedialis. E



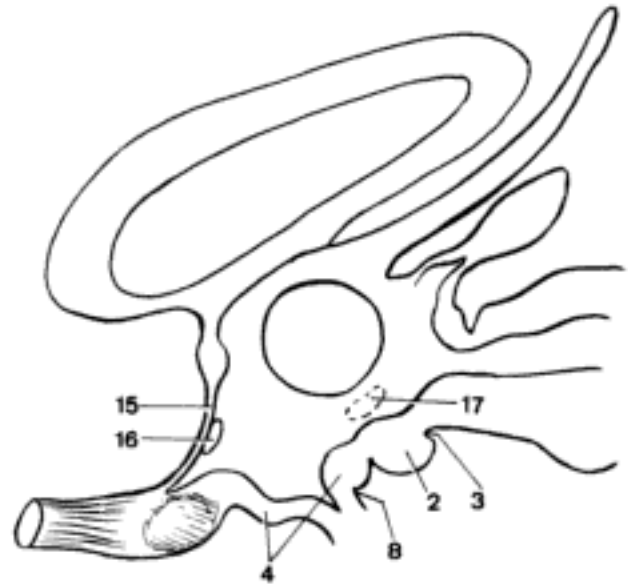
A Hypothalamus, ventral aspect (eq)



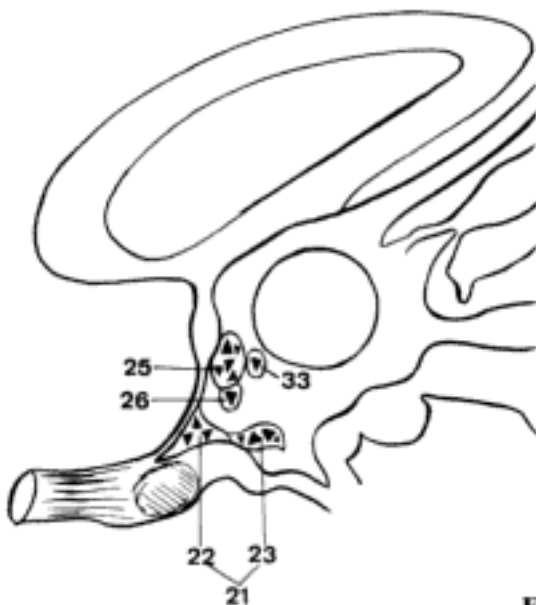
B Prosencephalon, transverse section (ov)



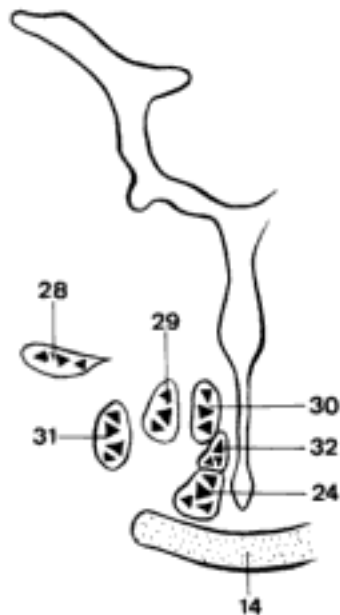
C Tractus opticus, lateral aspect (eq)



D Diencephalon, median section (ov)

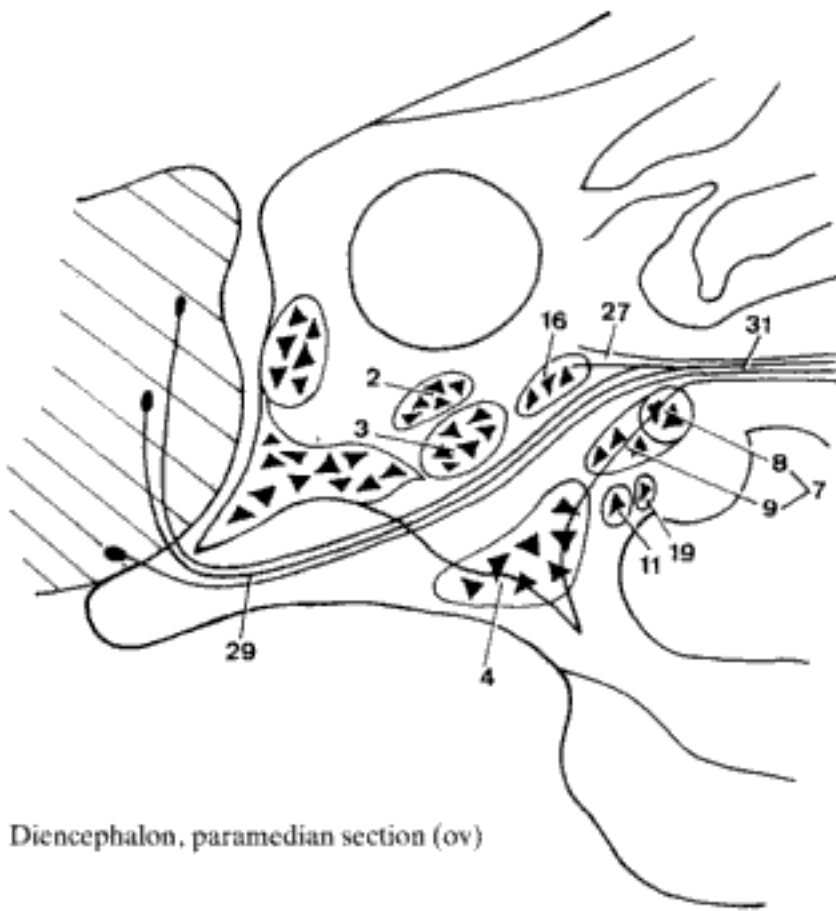


E Diencephalon, paramedian section, schematic representation of nuclei (ov)

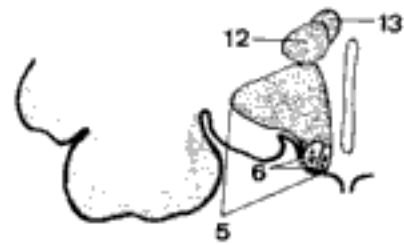


F Diencephalon, transverse section, schematic representation of nuclei (fe)

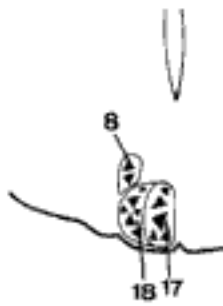
- 1 **Regio hypothalamica intermedia [tuber-
alis]**.
- 2 *Nucleus hypothalamicus dorsome-
dialis*. Between Nuclei paraventricularis
and hypothalamicus ventromedialis. A
- 3 *Nucleus hypothalamicus ventrome-
dialis*. Cajal's nucleus, between Nuclei
hypothalamicus dorsomedialis and peri-
ventricularis caudalis. A
- 4 *Nucleus infundibularis*. At the origin
of Infundibulum neurohypophysis. A
- 5 *Area hypothalamica lateralis*. In-
cludes the following groups of nuclei. B
- 6 *Nuclei tuberis laterales*. Lateral nuclei of
gray tubercle, dorsolateral to Nucleus in-
fundibularis, in Pars parainfundibularis tu-
beris. B
- 7 *Nucleus tuberomamillaris*. In Pars caudalis
tuberis and dorsal to Corpus mamillare. A
- 8 Pars caudalis [Nucleus intercala-
tus]. Caudal extension between Corpus
mamillare and Crus cerebri. A C
- 9 Pars supramamillaris. Main part of
Nucleus tuberomamillaris. A
- 10 **Regio hypothalamica caudalis**. Includes
Corpus mamillare.
- 11 *Nucleus premamillaris [prae-]*. Be-
tween Nucleus infundibularis and Nuclei
mamillares. A
- 12 *Area hypothalamica dorsalis*. B
- 13 *Area hypothalamica dorsocaudalis*.
B
- 14 *Nucleus hypothalamicus lateralis*.
Located within the dorsolateral part of hy-
pothalamus, between Ansa lenticularis and
fornix. It is not related to Area hypothala-
mica lateralis. D
- 15 *Nucleus hypothalamicus periforni-
calis*. Hypothalamic nucleus around for-
nix. D
- 16 *Nucleus periventricularis caudalis*.
Origin of a part of Fibrae periventriculares.
A
- 17 *Nucleus mamillaris medialis*. Medial
nucleus of mamillary body. C
- 18 *Nucleus mamillaris lateralis*. Lateral
nucleus of mamillary body. C
- 19 *Nucleus mamillaris cinereus*. Gray
mamillary nucleus, between Tuber ciner-
eum and Corpus mamillare. A
- 20 **Commissurae**. Commissures of white mat-
ter connecting right and left structures. D
- 21 *Commissurae supraopticae*. Trans-
verse fiber connections dorsal to Tractus
opticus and Chiasma opticum. D
- 22 *Commissura supraoptica dorsalis*. Ganser's
commissure. D
- 23 *Commissura supraoptica ventralis*. Mey-
nert's and Gudden's commissures. D
- 24 *Commissura supramamillaris*. Dor-
sal to Corpus mamillare.
- 25 *Commissurae intrahypothalamicae*.
- 26 **Tractus nervosi projectionis**. Projection fi-
bers, connecting segments of Encephalon
with each other and with Medulla spinalis,
descending or ascending.
- 27 *Fibrae periventriculares*. Periventi-
cular fibers, from Stratum periventriculare
hypothalami to Fasciculus longitudinalis
dorsalis. A
- 28 *Fornix*. Arcuate fibers connecting Hippo-
campus to Corpus mamillare, running in
both directions. D
- 29 *Fasciculus medialis telencephali*.
Medial fascicle of endbrain, connecting
rhinencephalon, hypothalamus and Forma-
tio reticularis. A
- 30 *Stria terminalis*. Bundle of myelinated
fibers connecting Corpus amygdaloideum
to Pars septalis rhinencephali, Nuclei habe-
nulares, and rostral region of hypothala-
mus, partially crossed through Commissura
rostralis. See 452.17
- 31 *Fasciculus longitudinalis dorsalis*.
Connects hypothalamus to mesencephalon,
rhombencephalon, and Medulla spinalis. A
- 32 *Fibrae hypothalamoretinales*.



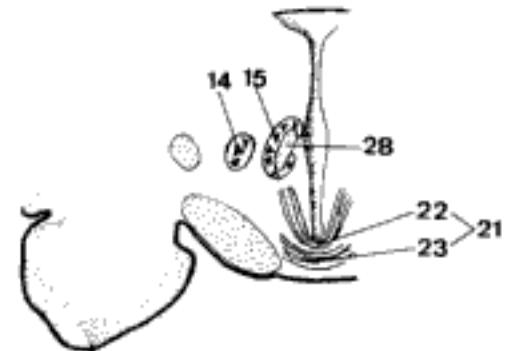
A Diencephalon, paramedian section (ov)



B Hypothalamus, transverse section through Tuber cinereum (fc)



C Hypothalamus, transverse section through Corpus mamillare (fc)

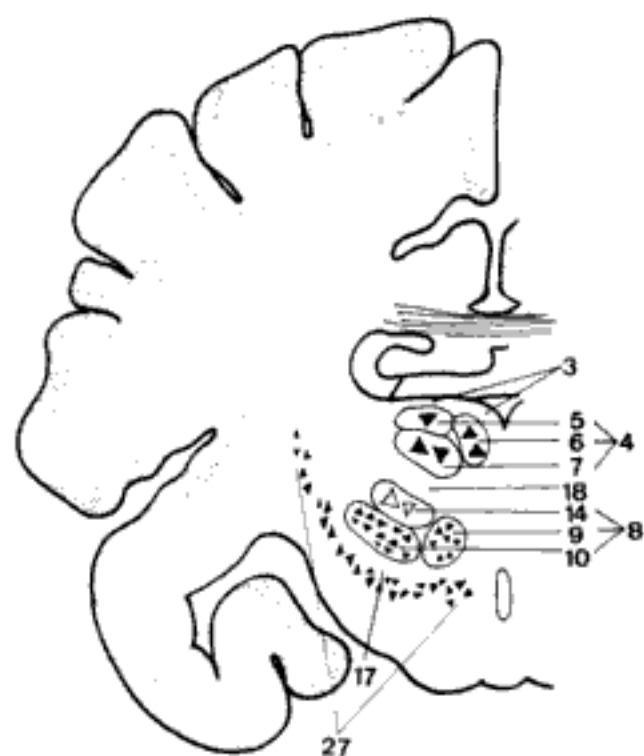


D Hypothalamus, transverse section through Commissurae hypothalami (fc)

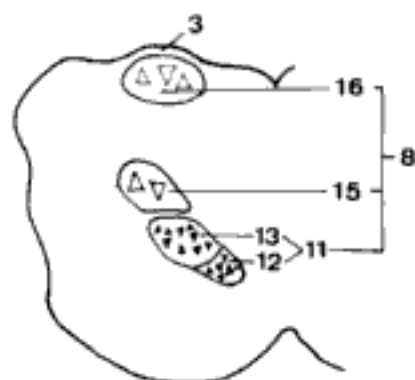
- 1 *Tractus supraopticohypophysialis*. Fibers from Nucleus supraopticus to Lobus nervosus neurohypophysis, neurosecretory. D
- 2 *Tractus paraventriculohypophysialis*. Fibers from Nucleus paraventricularis to Lobus nervosus neurohypophysis, neurosecretory. D
- 3 *Tractus tuberohypophysialis*. Former Tr. tuberoinfundibularis. Fibers from the parvocellular hypothalamic nuclei (Nuclei infundibularis, ventromedialis, dorsomedialis), ending around the capillary loops in the infundibulum. D
- 4 *Pedunculus mamillaris*. Fibers lateral to Fossa interpeduncularis between Corpus mamillare and mesencephalon. D
- 5 *Tractus mamillotegmentalis*. Connects Corpus mamillare and nuclei in the tegmentum.
- 6 *Faciculus mamillohypothalamicus*.
- 7 *Tractus mamillothalamicus*. In the lateral wall of Ventriculus tertius, connects Corpus mamillare and Nuclei rostrales thalami. First short segment runs together with Tractus mamillotegmentalis as Vicq d'Azyr's bundle. A D
- 8 **Subthalamus**. Between Thalamus and Substantia nigra. A
- 9 *Corpus subthalamicum*. Subthalamic body, the Nucleus subthalamicus and related structures lateral to it. A
- 10 *Zona incerta*. Uncertain zone, between Tractus mamillothalamicus and Ansa lenticularis. A
- 11 **Sectiones subthalami**. Sections through subthalamus. A B
- 12 *Zona incerta*. Uncertain zone. See 10. A
- 13 *Nucleus subthalamicus*. Luys's nucleus, between Tractus mamillothalamicus, Nucleus reticulatus thalami, and Substantia nigra. A
- 14 *Nucleus endopeduncularis*. Corresponds to medial portion of pallidum of primates. B
- 15 *Ansa peduncularis*. Bundle of fibers ventral to Nucleus lentiformis, connecting thalamus to insula and claustrum. B
- 16 *Ansa lenticularis*. Bundle of fibers connecting pallidum to thalamus, Nucleus subthalamicus, and mesencephalon. A
- 17 *Pedunculus ventralis thalami*. Connecting bridge between thalamus and hypothalamus, contains also connections to telencephalon. B
- 18 **Thalamencephalon**. Thalamus and associated structures. C
- 19 **Thalamus**. On both sides of Ventriculus tertius, dorsal to Sulcus hypothalamicus. A C
- 20 *Tuberculum rostrale thalami*. Rostral tubercle of thalamus. C
- 21 *Tenia [Taenia] thalami*. Thalamic tenia, attachment of Tela choroidea ventriculi tertii along Stria habenularis. C
- 22 *Pulvinar*. Not distinct in most domestic mammals. C
- 23 **Metathalamus**. Represented by Corpora geniculata. C
- 24 *Corpus geniculatum mediale*. Medial geniculate body, connected to Colliculus caudalis. Part of auditory pathway. C
- 25 *Corpus geniculatum laterale*. Lateral geniculate body, connected to Colliculus rostralis, end of Radix lateralis of Tractus opticus. C
- 26 **Epithalamus**. Consists of Glandula pinealis, Habenula and related structures. C D
- 27 *Glandula pinealis*. Pineal gland, or epiphysis. C D
- 28 *Corpus [glandulae pinealis]*. Body [of epiphysis]. D
- 29 *Pedunculus [glandulae pinealis]*. Rostral part, connected with right and left Habenula. D
- 30 *Recessus pinealis*. Extension of Ventriculus tertius into Glandula pinealis. D
- 31 *Recessus suprapinealis*. Caudodorsal extension of Ventriculus tertius dorsal to Glandula pinealis. D
- 32 *Habenula*. White matter anchoring Glandula pinealis to thalamus. C
- 33 *Commissura habenularum*. Decussation of fibers connecting the symmetrical Nuclei habenulares. C
- 34 *Stria habenularis thalami*. Habenular or medullary stria, band of white matter, rostral continuation of Habenula. C

Hidden page

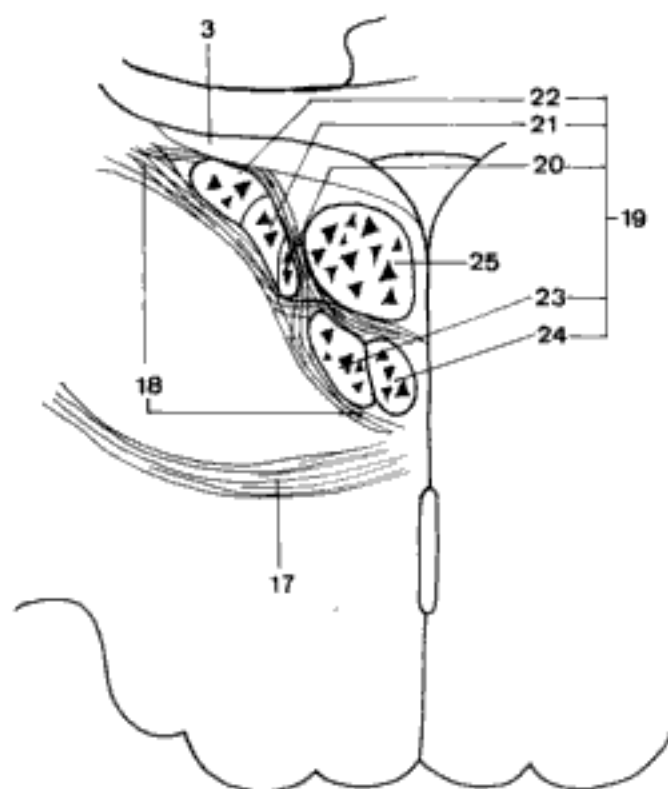
- 1 **Sectiones thalamencephali.** Sections through thalamus and associated structures. A B C
- 2 **Sectiones thalami.** Sections through thalamus. A B C
- 3 *Stratum zonale.* Zonal layer, layer of white matter covering thalamus on the dorsal aspect. A B C
- 4 *Nuclei rostrales thalami.* Rostral (anterior) thalamic nuclei, in Tuberculum rostrale thalami, at the dorsal aspect of thalamus, between Stria habenularis and Stria terminalis. Termination of Tractus mamillothalamicus, fibers from Fasciculus medialis telencephali, connections to Nuclei habenulares, Gyrus cinguli and Cortex frontalis. A
- 5 *Nucleus rostralis dorsalis.* A
- 6 *Nucleus rostralis medialis.* A
- 7 *Nucleus rostralis ventralis.* A
- 8 *Nuclei laterales thalami.* Lateral thalamic nuclei, group of six nuclei lateral to Lamina medullaris thalami interna. A B
- 9 *Nucleus ventralis rostralis.* Fibers from pallidum, cerebellum, and Nucleus interstitialis, connections to motor cortex. A
- 10 *Nucleus ventralis lateralis.* Fibers from Nuclei vestibulares and cerebellum, connections to Cortex parietalis. A
- 11 *Nucleus ventralis caudalis.* B
- 12 *Pars medialis.* Medial part. Synapse between Lemniscus trigeminalis and sensory cortex. B
- 13 *Pars lateralis.* Lateral part. Synapse between Lemniscus medialis and sensory cortex. B
- 14 *Nucleus lateralis dorsalis.* Connections with other thalamic nuclei and Cortex temporalis. A
- 15 *Nucleus lateralis caudalis.* Connections with other thalamic nuclei and Cortex temporalis. B
- 16 *Nucleus pulvinaris.* Fibers from other thalamic nuclei and Nuclei pretectales, connections to sensory cortex. B
- 17 *Lamina medullaris thalami externa.* External thalamic medullary lamina, thin layer of white matter separating Nucleus reticulatus from Nuclei laterales thalami. A C
- 18 *Lamina medullaris thalami interna.* Internal thalamic medullary lamina, thin layer of white matter separating Nuclei laterales thalami from Nuclei rostrales thalami. A C
- 19 *Nuclei intralaminares thalami.* Thalamic intralaminar nuclei, within Lamina medullaris thalami interna. Fibers from cerebellum and Lemniscus medialis, connections to Corpus striatum and Nucleus dorsomedialis thalami. C
- 20 *Nucleus centralis medialis.* C
- 21 *Nucleus paracentralis.* C
- 22 *Nucleus centralis lateralis.* C
- 23 *Nucleus centralis thalami [Centrum medianum].* Thalamic central (centromedian) nucleus, morphologically not strictly intralaminar, more developed in primates, easily visible also in Un. C
- 24 *Nucleus parafascicularis.* Morphologically not strictly interlaminar. C
- 25 *Nucleus dorsomedialis thalami.* Thalamic dorsomedial nucleus. Caudal to Nucleus paraventricularis. Termination of Pedunculus ventralis thalami, connections with thalamic and hypothalamic nuclei and Cortex frontalis. C
- 26 *Nuclei paraventriculares thalami.* Thalamic paraventricular nuclei, sometimes referred to as "midline nuclei", near the median plane. They are sometimes confused with Nuclei intralaminares thalami.
- 27 *Nucleus reticulatus thalami.* Between Lamina medullaris thalami externa and Capsula interna. A



A Thalamencephalon, transverse section through Corpus mamillare (eq)



B Thalamencephalon, transverse section through Corpora geniculata and Pedunculi cerebri (eq)

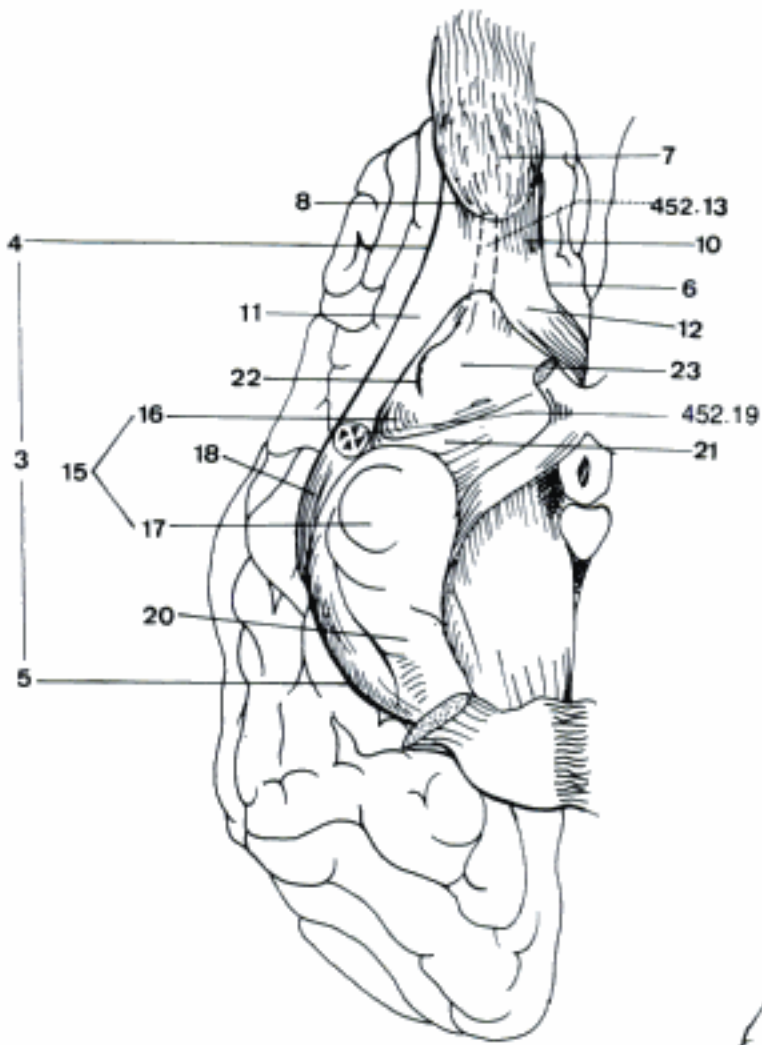


C Thalamus, transverse section, schematic representation of Nuclei intralaminares

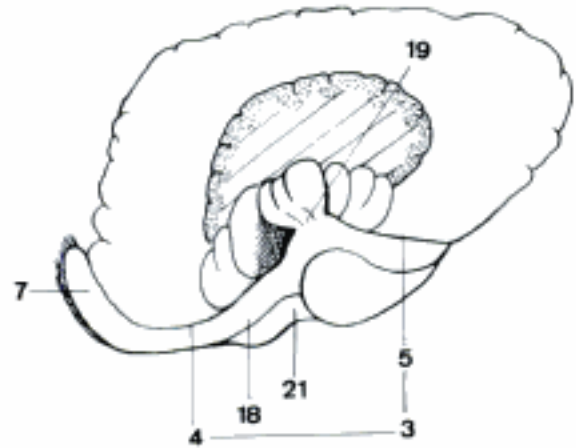
- 1 **Sectiones metathalami.** Sections through metathalamus. A
- 2 *Nucleus geniculatus medialis.* Cell group in Corpus geniculatum mediale, synapse in the auditory pathway. A
- 3 *Nucleus geniculatus lateralis.* Related to Corpus geniculatum laterale, in the visual pathway. A
- 4 *Pars dorsalis.* Dorsal (main) part. End of Radix lateralis of Tractus opticus, start of Radiatio optica to Area striata of Lobus occipitalis. A
- 5 *Pars ventralis.* Ventral part. A
- 6 **Sectiones epithalami.** Sections through epithalamus. B
- 7 *Nuclei habenulares.* Related to habenula. Synapses between Stria habenularis thalami and mesencephalon. B
- 8 *Nucleus habenularis medialis.* B
- 9 *Nucleus habenularis lateralis.* B
- 10 *Commissura habenularum.* Connects right and left Nuclei habenulares. B
- 11 *Fasciculus retroflexus.* Meynert's fascicle, from Nuclei habenulares to Nucleus interpeduncularis. B
- 12 **Telencephalon.** Endbrain, the most developed segment of Prosencephalon, its principal components are Neopallium, Rhinencephalon and Corpus striatum.
- 13 **Cerebrum.** The two hemispheres connected by commissures. C
- 14 *Fissura longitudinalis cerebri.* Cerebral longitudinal fissure, separating the two hemispheres. The Falx cerebri is located within it. A C D
- 15 *Fissura transversa cerebri.* Cerebral transverse fissure, between the two hemispheres and cerebellum. C
- 16 *Basis cerebri.* Cerebral basis, corresponds to the ventral aspect of cerebrum. D
- 17 **Hemispherium [Hemisphaerium].** The two symmetrical and biggest segments of cerebrum. C
- 18 *Facies convexa [F. dorsolateralis].* Convex (dorsolateral) surface of each hemisphere. E
- 19 *Facies medialis.* Medial surface, separated from its fellow by Fissura longitudinalis cerebri. F
- 20 *Facies basilaris.* Basal or ventral surface. D
- 21 *Margo dorsalis [dorsomedialis].* Dorsal (dorsomedial) border, separates Facies convexa and medialis. A E F
- 22 *Polus rostralis [frontalis].* Rostral (frontal) pole. E F
- 23 *Polus caudalis [occipitalis].* Caudal (ocipital) pole. E F
- 24 *Pallium.* Cloake- or mantle-like part of the hemisphere enveloping the brainstem. D
- 25 *Paleopallium [Palaeo-].* Oldest part of pallium, part of the Rhinencephalon on the ventral aspect of the hemisphere between Sulcus rhinalis lateralis and Sulcus endorhinalis, includes Lobus piriformis. D
- 26 *Archipallium.* On the medial aspect of the hemisphere, represented by Hippocampus and associated structures (ammonic complex). A
- 27 *Neopallium.* Youngest part of pallium, located dorsolaterally between the two previous structures. A D
- 28 *Cortex cerebri.* Cerebral cortex, gray matter overlapping the hemispheres. A
- 29 *Sulci cerebri.* Cerebral sulci, grooves separating gyri. A E F
- 30 *Gyri cerebri.* Cerebral gyri, convolutions of cerebral surface, separated by sulci. A E F

Hidden page

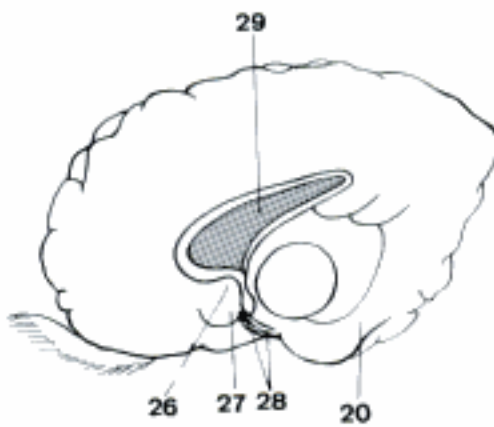
- 1 **Rhinencephalon.** Olfactory brain, consisting of basal Telencephalon, Hippocampus and associated structures. The function is not wholly related to olfaction.
- 2 **Pars basalis rhinencephali.** Basal part of olfactory brain. A
- 3 *Sulcus rhinalis lateralis.* Lateral olfactory groove, separates Neopallium from Rhinencephalon. A B
- 4 *Pars rostralis.* Rostral part. A B
- 5 *Pars caudalis.* Caudal part, separated from Pars rostralis by Limen insulae. A B
- 6 *Sulcus rhinalis medialis.* Medial olfactory groove, separates Pedunculus olfactorius from Neopallium. A
- 7 *Bulbus olfactorius.* Olfactory bulb, the most rostral part of the Rhinencephalon containing the mitral cells with their many dendrites. A B
- 8 *Sulcus limitans bulbi olfactorii.* Limiting groove of olfactory bulb, separates Bulbus olfactorius from Pedunculus olfactorius. A
- 9 *Bulbus olfactorius accessorius.* Accessory olfactory bulb, medial to Bulbus olfactorius, associated with the vomeronasal system. 465 A
- 10 *Pedunculus olfactorius.* Olfactory peduncle, joins Bulbus olfactorius to Hemisphere. A
- 11 *Tractus olfactorius lateralis.* Lateral olfactory tract. A
- 12 *Tractus olfactorius medialis.* Medial olfactory tract. A
- 13 *Trigonum olfactorium.* Olfactory trigone, term applies to microsmatic mammals.
- 14 *Sulcus limitans trigoni olfactorii.* Term applies to microsmatic mammals.
- 15 *Lobus piriformis.* Piriform lobe, caudal to Pedunculus olfactorius, extends from Tuberculum olfactorium to Tuberculum hippocampi, caudally not clearly delimited from Neocortex. A
- 16 *Pars rostralis.* Rostral part. A
- 17 *Pars caudalis.* Caudal part, separated from Pars rostralis by Vallecule lateralis cerebri. A
- 18 *Gyrus olfactorius lateralis.* Lateral olfactory gyrus, borders on Pars rostralis and the rostral part of Pars caudalis of Lobus piriformis. A B
- 19 *Limen insulae.* Limen (pole) of insula, between Pars rostralis and Pars caudalis of Sulcus rhinalis lateralis. B
- 20 *Gyrus parahippocampalis.* Caudal continuation of Lobus piriformis, located lateral to Sulcus hippocampi. A C
- 21 *Vallecule [Fossa] lateralis cerebri.* Lateral cerebral depression (fossa), separates the two parts of Lobus piriformis. A B
- 22 *Sulcus endorhinalis.* Endorhinal groove, the lateral limit of Tuberculum olfactorium. A
- 23 *Tuberculum olfactorium.* Olfactory tubercle, bordered by Tractus olfactorius medialis and Sulcus endorhinalis. A
- 24 *Substantia perforata rostralis.* In general, it is only found in higher and microsmatic mammals.
- 25 **Pars septalis rhinencephali.** Septal part of olfactory brain, located on the medial aspect of the hemisphere. C
- 26 *Area subcallosa.* Ventral to Genu and Rostrum corporis callosi. C
- 27 *Gyrus paraterminalis.* Grossly visible only in microsmatic mammals. C
- 28 *Gyrus diagonalis.* Ventral part of Gyrus paraterminalis. C
- 29 *Septum telencephali [cellulare, verum].* Septum of endbrain. Septum telencephali is applied to all species, it connects Corpus callosum and Fornix and separates the Ventriculi laterales. The synonyms "cellulare" and "verum" are applied to lower mammals in which the thick septum contains many nerve cells. C
- 30 *Septum telencephali [pellucidum].* Septum of endbrain (pellucid septum). Term applies to microsmatic mammals.
- 31 *Cavum septi telencephali [pellucidi].*
- 32 *Lamina septi telencephali [pellucidi].*



A Pars basalis rhinencephali (eq)



B Insula, opercula removed (eq)



C Pars septalis rhinencephali

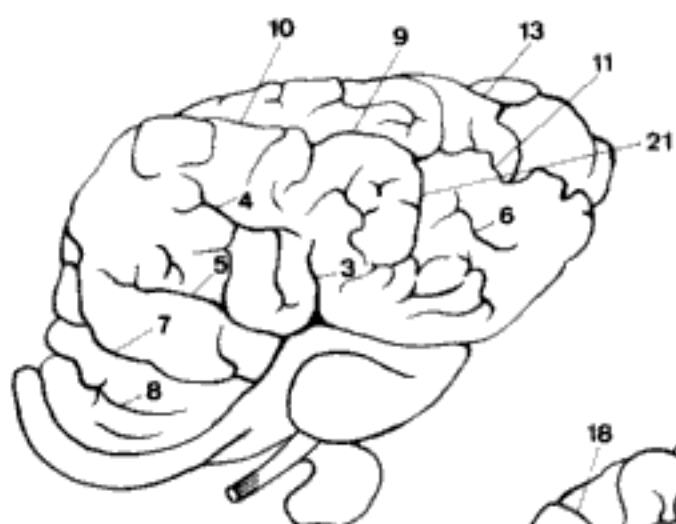
- 1 **Pars limbica rhinencephali.** Limbic (marginal) part of olfactory brain.
- 2 *Hippocampus.* The Pars retrocommissuralis is the hippocampus proper, the two other parts are not so well developed.
- 3 *Pars precommissuralis [prae-].* Extends rostral to Genu corporis callosi as far as the root of Pedunculus olfactorius, seldom macroscopically distinct. B
- 4 *Pars supracommissuralis [Indusium griseum].* On Corpus callosum as a thin layer of gray matter and in Sulcus corporis callosi. B C
- 5 *Pars retrocommissuralis.* Hippocampus proper, elongated prominence in Pars centralis and Cornu temporale of lateral ventricle. A B C
- 6 *Gyrus geniculi.* Genicular gyrus, continuation of Gyrus supracallosus below the Genu corporis callosi. B
- 7 *Gyrus supracallosus.* If the Sulcus corporis callosi is not directly adjacent to the Corpus callosum, there appears a small Gyrus supracallosus. B C
- 8 *Sulcus corporis callosi.* Separates Corpus callosum or Gyrus corporis callosi from Gyrus cinguli. B C
- 9 *Striae longitudinales.* Longitudinal white bands on Corpus callosum. C
- 10 *Stria longitudinalis lateralis.* C
- 11 *Stria longitudinalis medialis.* Lacisii stria. C
- 12 *Pes hippocampi [Cornu ammonis].* Ventral end of hippocampus, in man paw-shaped. C
- 13 *Alveus hippocampi.* Thin layer of white matter covering the internal surface of the hippocampus. A C
- 14 *Fimbria hippocampi.* Free border of alveus, traveling along the border of the hippocampus parallel to Gyrus dentatus. Continues as Crus fornicis. A B C
- 15 *Cornu ammonis inversum.* Inverse ammon's horn, part of ammonic complex on the extraventricular surface. In man vestiges which remain superficially form the Gyrus fasciolaris. B
- 16 *Gyrus dentatus [Fascia dentata].* Dentaculated by virtue of numerous crenations, between Sulcus hippocampi and Sulcus fimbriodentatus. C
- 17 *Sulcus hippocampi.* Ammon's horn groove, between Gyrus parahippocampalis and Gyrus dentatus. B C
- 18 *Sulcus fimbriodentatus.* Groove between Fimbria hippocampi and Gyrus dentatus. B C
- 19 *Sulcus dentatoammonis.* Groove between Gyrus dentatus and Cornu ammonis inversum. B
- 20 *Sulcus fimbriammonis.* Groove between Fimbria hippocampi and Cornu ammonis inversum. B
- 21 *Tuberculum hippocampi.* Ammon's horn tubercle, medial to the rostral end of Gyrus parahippocampalis, corresponds to uncus of primates. B
- 22 *Fornix.* Arcuate fibers connecting Hippocampus to Corpus mamillare, running in both directions. A B
- 23 *Crus fornicis.* Paired convergent structure, arises from hippocampus, fuses with the contralateral to form the Corpus fornicis. B
- 24 *Corpus fornicis.* Body of fornix, unpaired structure formed by fusion of the crura. B
- 25 *Tenia [Taenia] fornicis.* Border of fornix to which the tela choroidea is attached. A B C
- 26 *Columna fornicis.* Paired structure starting from Corpus fornicis, surrounds Foramen interventriculare rostrally, runs in the wall of Ventriculus III to Corpus mamillare. B
- 27 *Commissura fornicis [hippocampi] ventralis [Psalterium ventrale].* Rostroventral connection, relation to a Nucleus septi. 437 C
- 28 *Commissura fornicis [hippocampi] dorsalis [Psalterium dorsale].* Caudodorsal connection of Crura fornicis, difficult to distinguish from Corpus callosum. B
- 29 *Organum vasculosum subfornicale.* See 436. 15.

Hidden page

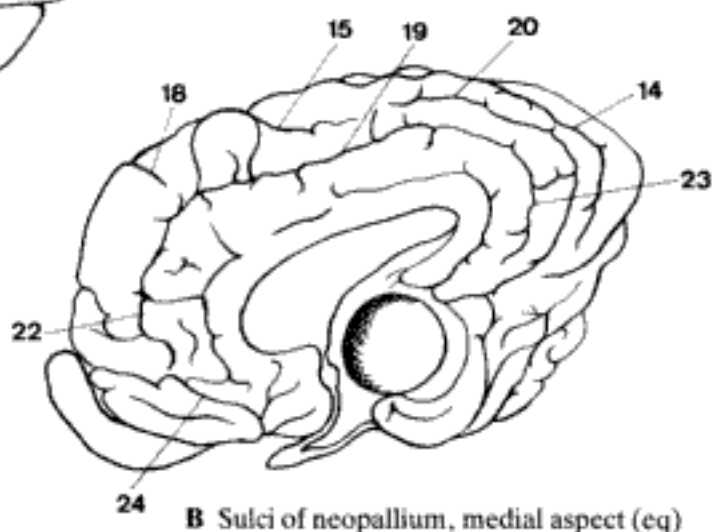
Hidden page

Hidden page

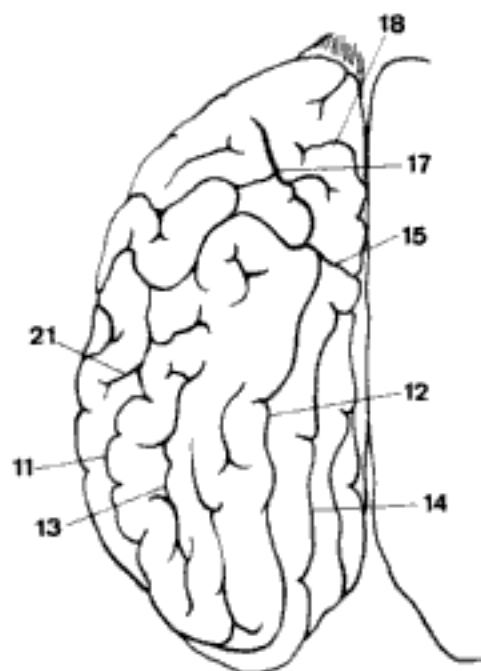
- 1 **Neopallium.** Phylogenetically the youngest part of pallium.
- 2 *Fissura pseudosylvia.* Pseudosylvian fissure, occurs in Car and is primitive. It is located lateral and dorsal to Lobus piriformis and joins Sulcus rhinalis lateralis at the junction of its Pars rostralis and Pars caudalis. D
- 3 *Fissura sylvia [lateralis cerebri].* Sylvian [lateral cerebral] fissure, appears in Un as a result of a process of opercularisation. Similar topographical position as *Fissura pseudosylvia*, but deeper. A
- 4 *Sulcus ectosylvius rostralis.* Rostral ectosylvian groove, rostral and dorsal to the previous two fissures. A D
- 5 *Sulcus diagonalis (Un).* Diagonal groove, ventral to the previous. A
- 6 *Sulcus ectosylvius caudalis.* Caudal ectosylvian groove. A D
- 7 *Sulcus presylvius [prae-].* Presylvian groove, ventral to Sulcus diagonalis. A D E
- 8 *Sulcus proreus [orbitalis] (Un).* Prorean groove, ventral to Sulcus presylvius. A
- 9 *Sulcus suprasylvius medius.* Middle suprasylvian groove, dorsal to Gyrus ectosylvius medius. A D E
- 10 *Sulcus suprasylvius rostralis.* Rostral suprasylvian groove, the rostral continuation of the previous, dorsal to Gyrus ectosylvius rostralis. A D E
- 11 *Sulcus suprasylvius caudalis.* Caudal suprasylvian groove, the caudal continuation of Sulcus suprasylvius medius, dorsal or caudal to Gyrus ectosylvius caudalis. A C D E
- 12 *Sulcus marginalis [sagittalis].* Marginal [sagittal] groove. Appears on the dorsolateral aspect of the hemisphere. C D E
- 13 *Sulcus ectomarginalis [ectosagittalis].* Ectomarginal [ectosagittal] groove, on the dorsolateral aspect. A C D E
- 14 *Sulcus endomarginalis [endosagittalis].* Endomarginal [endosagittal] groove, on the dorsal aspect. May be absent in Car. B C D E
- 15 *Sulcus ansatus.* Ansiform groove, in Un on both sides over the dorsal border of the hemisphere. B C D E
- 16 *Sulcus postcruciatu[s] [postcentralis] (Car).* Postcruciate [postcentral] groove on the dorsolateral surface, between Sulcus ansatus and Sulcus cruciatus. D E
- 17 *Sulcus coronalis.* Coronal groove, in Car located on the lateral aspect ventral to Gyrus precruciatu[s] and Gyrus postcruciatu[s]. C D E
- 18 *Sulcus cruciatus [centralis].* Cruciate [central] groove. In Car analogous to Sulcus centralis of primates and located on both sides of the hemisphere. In the other domestic mammals visible only on the medial aspect rostral to sulcus ansatus. B C D E F
- 19 *Sulcus splenialis.* Splenial groove, on the medial aspect midway between Corpus callosum and the dorsal border of the hemisphere. B F
- 20 *Sulcus suprasplenialis.* Suprasplenial groove, midway between Sulcus splenialis and the dorsal border of the hemisphere. B F
- 21 *Sulcus obliquus.* Oblique groove, caudal to *Fissura sylvia* and to Gyrus obliquus rostralis, present in most Un, best developed in eq. A C
- 22 *Sulcus genualis.* Genual groove, well developed in Un, poorly in ca, and absent in fe. Rostral continuation of Sulcus splenialis. B F
- 23 *Sulcus calcarinus (Un).* Calcarine groove, caudal continuation of Sulcus splenialis. B
- 24 *Sulcus rostralis internus (Un).* Rostral internal groove, dorsal to and parallel to Sulcus rhinalis medialis. B



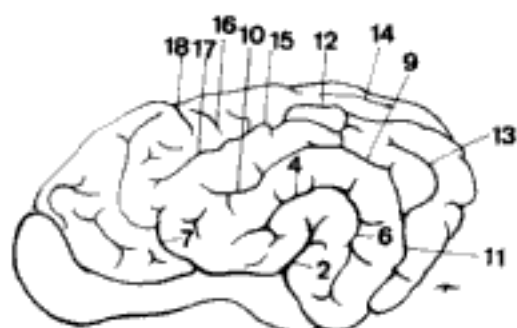
A Sulci of neopallium, lateral aspect (eq)



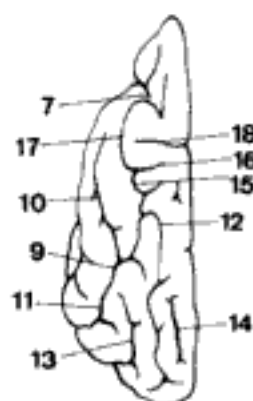
B Sulci of neopallium, medial aspect (eq)



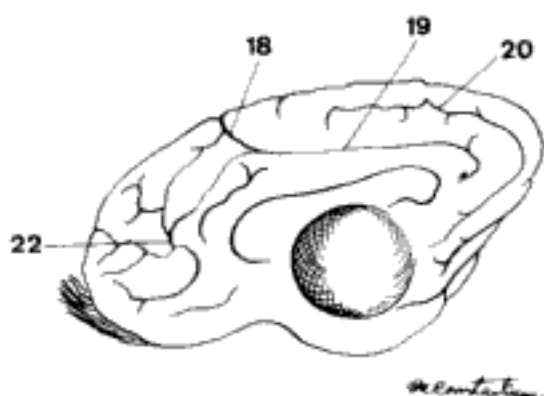
C Sulci of neopallium, dorsal aspect (eq)



D Sulci of neopallium, lateral aspect (ca)

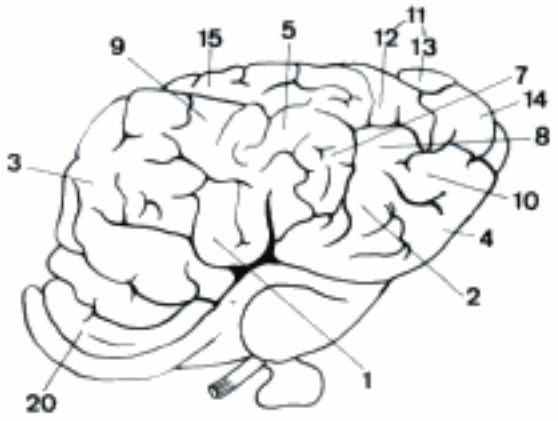


E Sulci of neopallium, dorsal aspect (ca)

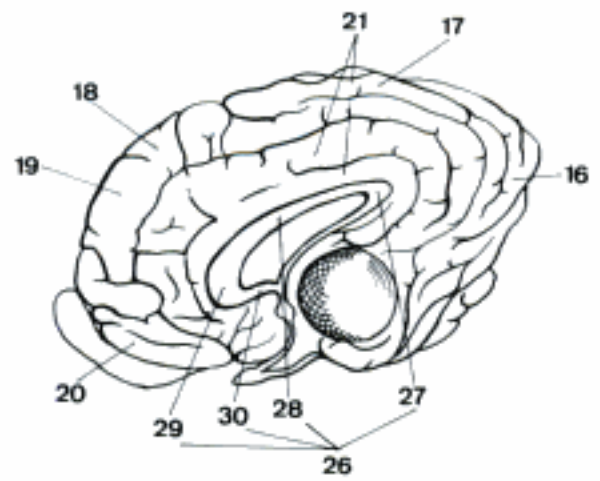


F Sulci of neopallium, medial aspect (ca)

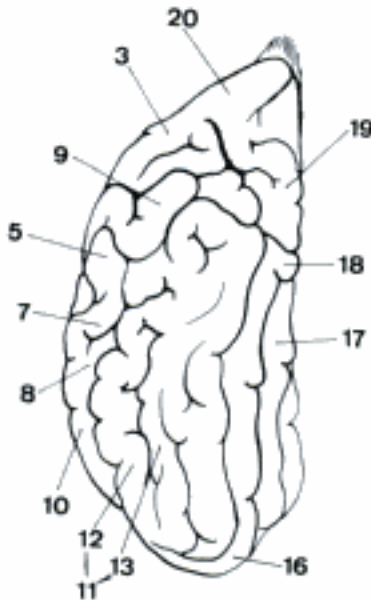
Hidden page



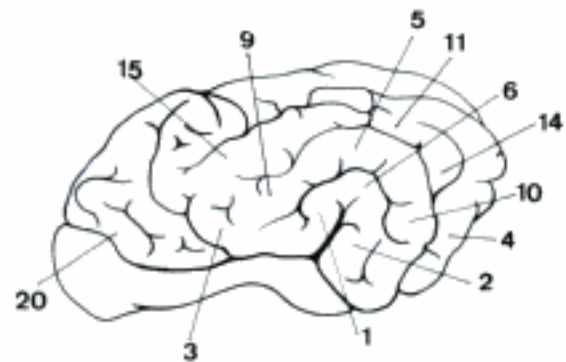
A Gyri of neopallium, lateral aspect (eq)



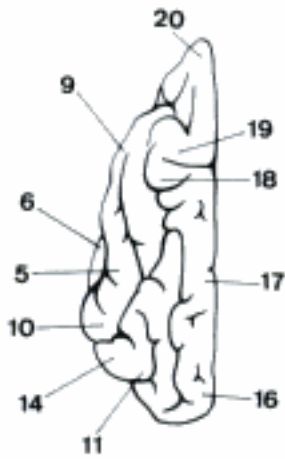
B Gyri of neopallium, medial aspect (eq)



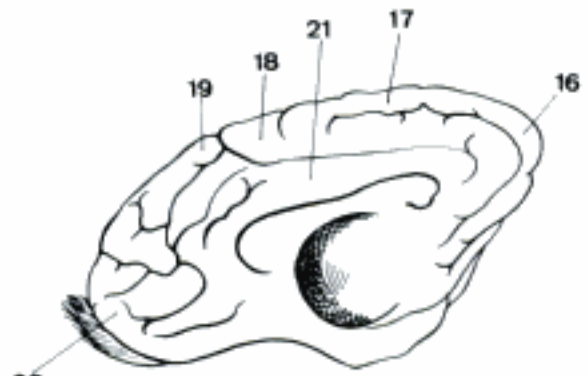
C Gyri of neopallium, dorsal aspect (eq)



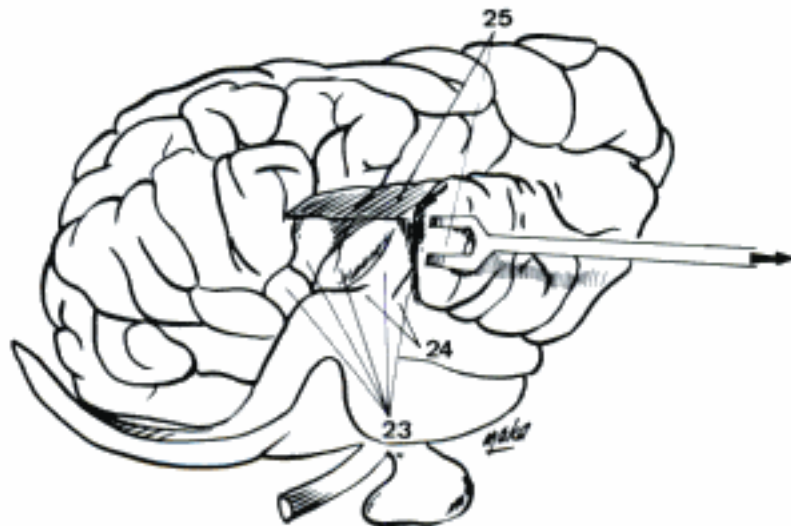
D Gyri of neopallium, lateral aspect (ca)



E Gyri of neopallium, dorsal aspect (ca)



F Gyri of neopallium, medial aspect (ca)

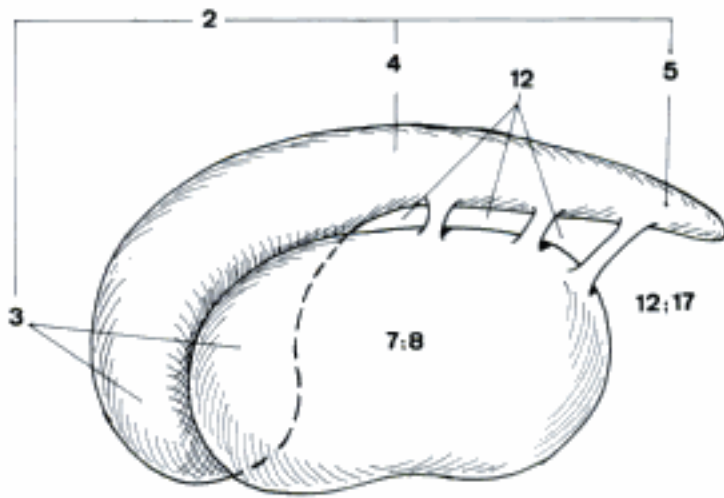


G Insula, opercula partly removed (eq)

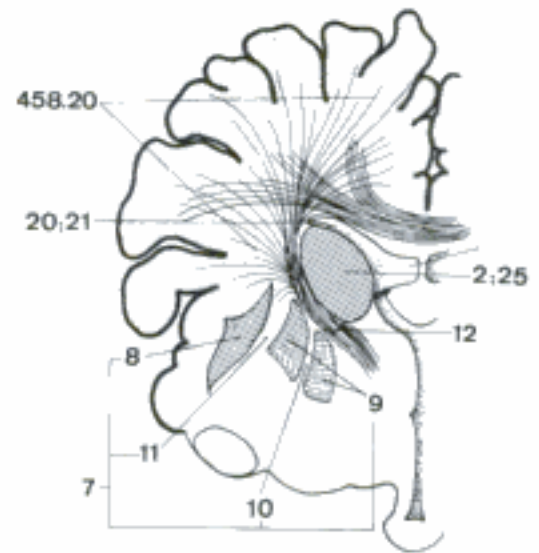
Hidden page

Hidden page

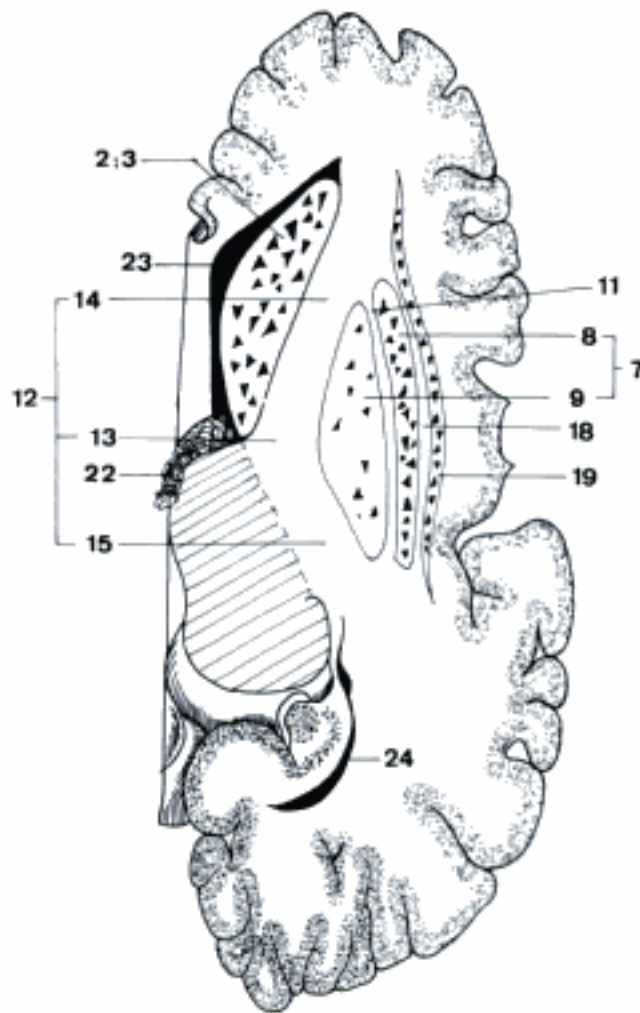
Hidden page



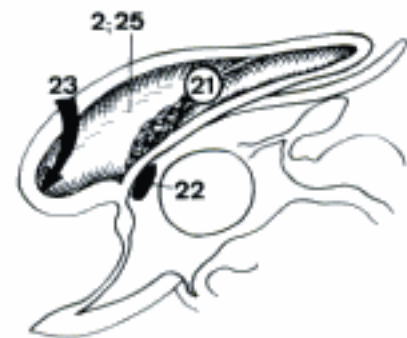
A Left Corpus striatum, lateral aspect



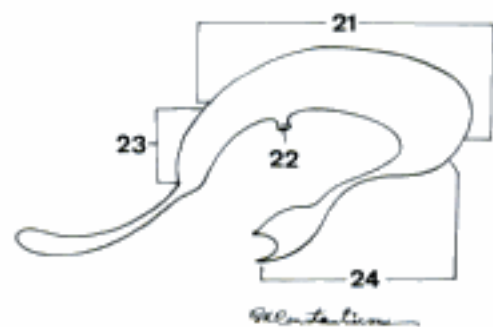
C Corpus striatum, transverse section



B Corpus striatum, horizontal section

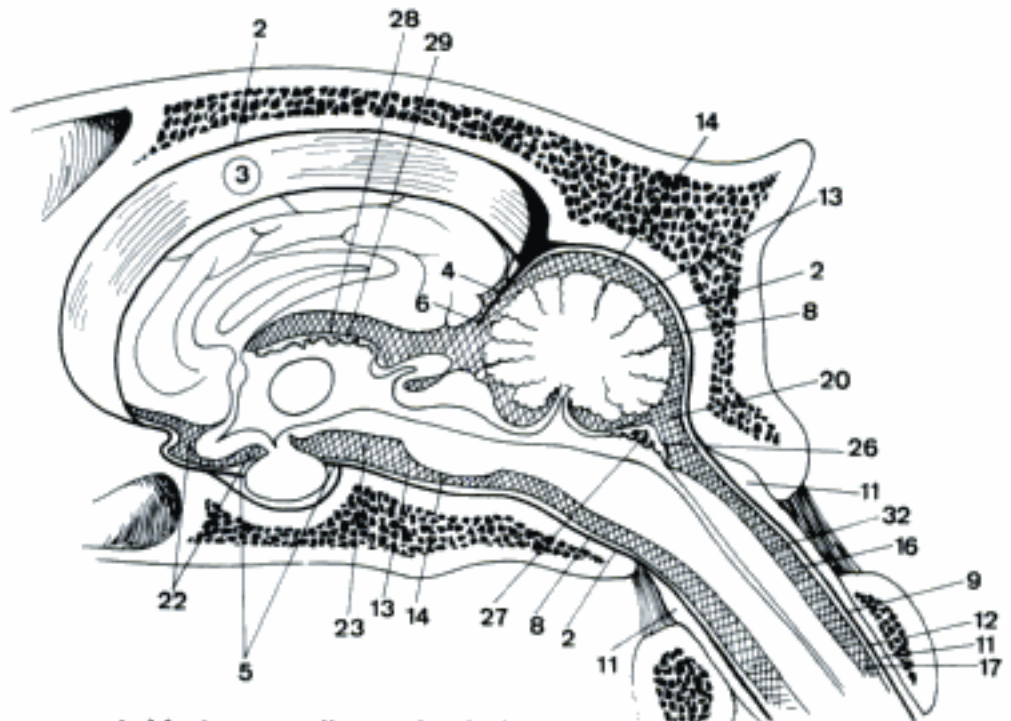


D Right Ventriculus lateralis, medial aspect

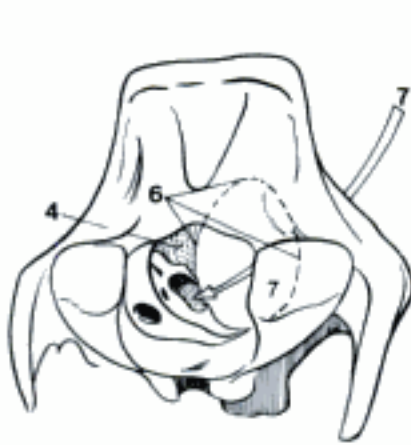

E Cast of the right Ventriculus lateralis, medial aspect (eq)

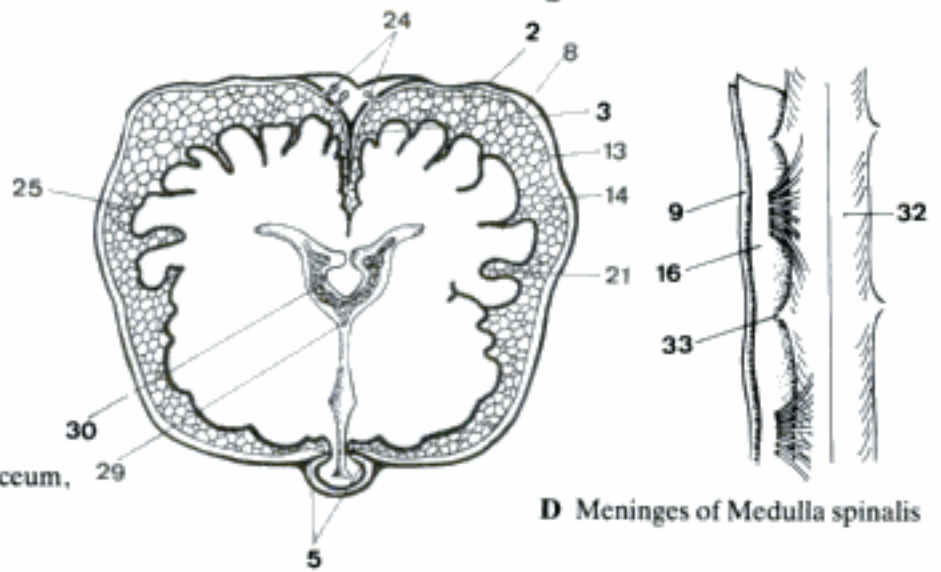
Hidden page



A Meninges, median section (eq)

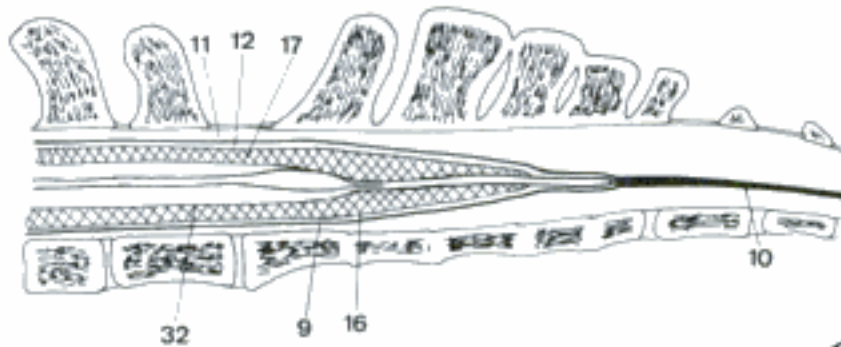


B Tentorium cerebelli membranaceum, right-caudal aspect (eq)

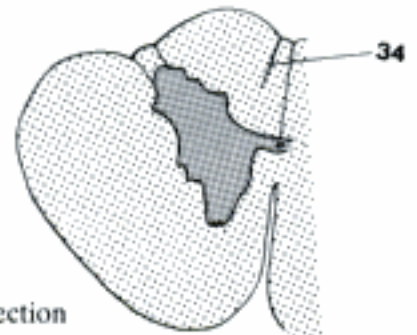

C Meninges of brain, transverse section (eq)

D Meninges of Medulla spinalis



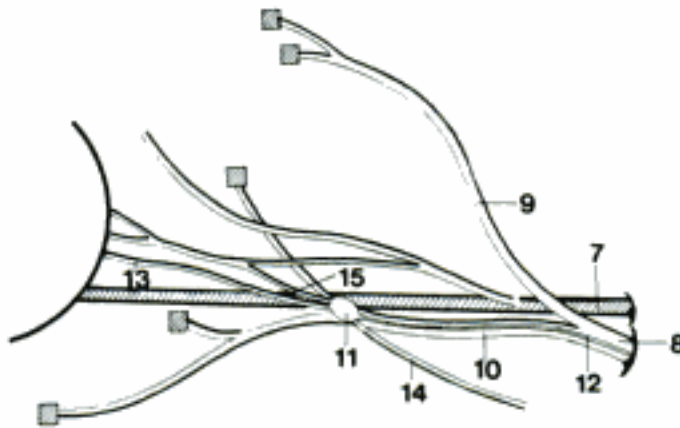
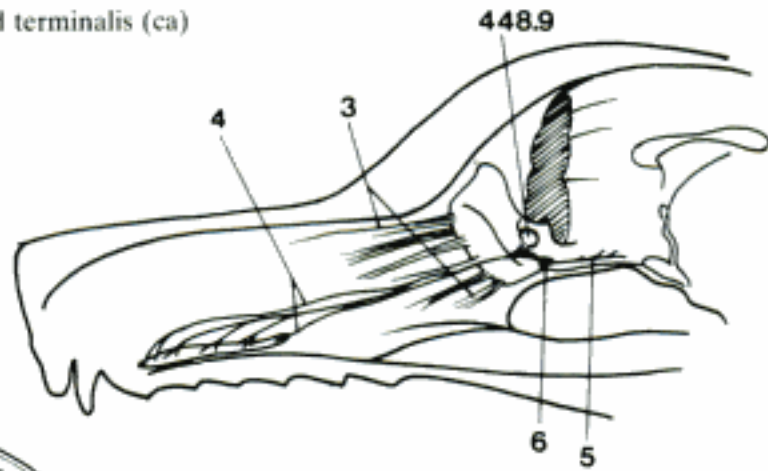
E Meninges of Medulla spinalis, median section (eq)



F Medulla spinalis, transverse section

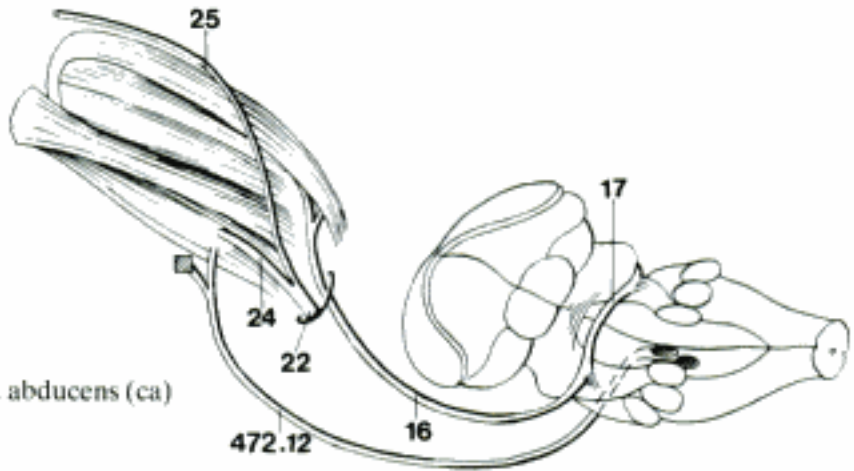
- 1 **SYSTEMA NERVOSUM PERIPHERICUM.** Peripheral nervous system.
- 2 **NERVI CRANIALES.** Cranial nerves, 12 pairs.
- 3 **Nn. olfactorii.** Olfactory nerves, Fila olfactoria, carry sense of smell from olfactory cells through Lamina cribrosa ossis ethmoidalis into Bulbus olfactorius. A
- 4 *N. vomeronasalis.* Vomeronasal nerve, starts from Organum vomeronasale, ends in Bulbus olfactorius accessorius. A
- 5 *N. terminalis.* Terminal nerve, starts from Organum vomeronasale, ends in or near Pedunculus olfactorius, postfetally described in Car. A
- 6 *Ganglion terminale.* Terminal ganglion, sensory. A
- 7 **N. opticus.** Optic nerve, carries optic fibers from retina through Canalis opticus, meets with its fellow in Chiasma opticum. B
- 8 **N. oculomotorius.** Oculomotor nerve, somatomotor and parasympathetic, emerges from Sulcus medialis cruris cerebri, passes through Fissura orbitalis, together with VI and V₁. B
- 9 *Ramus dorsalis.* Dorsal branch, supplies Mm. rectus dorsalis and levator palpebrae superioris. B
- 10 *Ramus ventralis.* Ventral branch, supplies Mm. rectus medialis, rectus ventralis and obliquus ventralis. B
- 11 **Ganglion ciliare.** Ciliary ganglion, at the origin of the branch of III that supplies M. obliquus ventralis. Synapses between pre- and postganglionic parasympathetic fibers. B
- 12 *Radix oculomotoria.* Oculomotor root, the preganglionic parasympathetic branch of III. B
- 13 *Nn. ciliaris breves.* Short ciliary nerves, represent the postganglionic parasympathetic and sympathetic fibers supplying posterior structures of the eye. B
- 14 (*Ramus sympathicus ad ganglion ciliare*). Slender postganglionic fibers from Plexus caroticus (sympathetic component), without synapse in ganglion. B
- 15 *Ramus communicans cum n. nasociliari.* Branch communicating with nasociliary nerve (Ru, eq), or ophthalmic nerve (Car, su). B
- 16 **N. trochlearis.** Trochlear nerve, emerges dorsocaudally from Lamina tecti, supplies M. obliquus dorsalis. C
- 17 *Decussatio nervorum trochlearium.* Crossing of trochlear nerves in Velum medullare rostrale. C
- 18 **N. trigeminus.** Trigeminal nerve. Somatosensitive fibers from skin and mucous membranes of the head and somatomotor fibers to masticatory muscles, except Venter caudalis m. digastrici. D
- 19 *Radix sensoria.* Sensory root, between pons and Ganglion trigeminale. D
- 20 *Ganglion trigeminale.* Trigeminal ganglion, in Cavum trigeminale of dura mater. D
- 21 *Radix motoria.* Motor root, origin in pons in Nucleus motorius n. trigemini. D
- 22 **N. ophthalmicus.** Ophthalmic nerve, first and smallest branch of N. trigeminus, through Fissura orbitalis, sensory for eye, lids, conjunctiva, skin of forehead, and part of nasal mucosa. C D
- 23 *Ramus meningeus.* Recurrent meningeal branch, sensory, to meninges. D
- 24 *N. lacrimalis.* Lacrimal nerve, ramifies in Glandula lacrimalis and Palpebra superior. C D
- 25 *N. frontalis.* Frontal nerve, leaves Orbita (through Foramen supraorbitale in eq), continues as N. supraorbitalis. C D
- 26 *N. sinuum frontaliium.* Frontal sinus nerve, runs dorsally between Mm. recti lateralis and dorsalis to a small foramen in the medial wall of the orbit, entering the Sinus frontalis; may originate from Ramus zygomaticotemporalis n. zygomatici (bo). D
- 27 *N. supraorbitalis.* Supraorbital nerve, direct continuation of N. frontalis, sensitive for upper eyelid and skin of the forehead. D
- 28 *N. supratrochlearis.* Supratrochlear nerve, ends in Palpebra superior at Angulus oculi medialis. D

A Nn. olfactorii, vomeronasalis, and terminalis (ca)
(Mc Cotter)

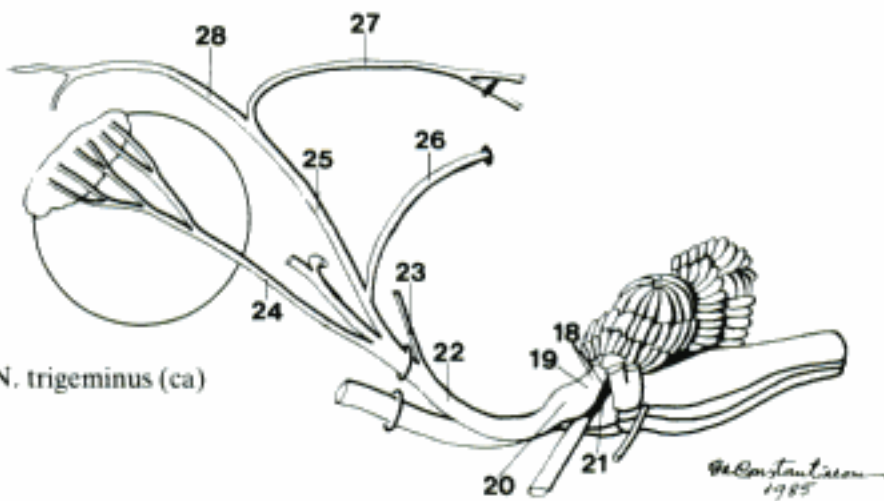


B Nerves in the Orbita, schematic

C Nn. trochlearis, ophthalmicus, and abducens (ca)

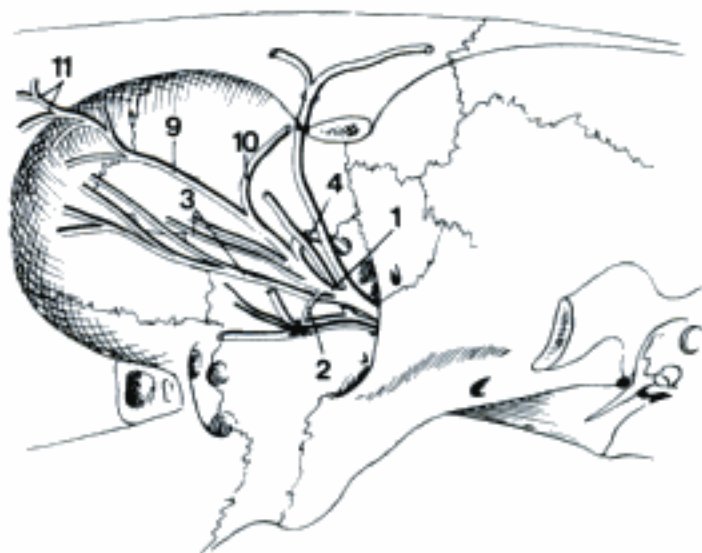


D N. trigeminus (ca)

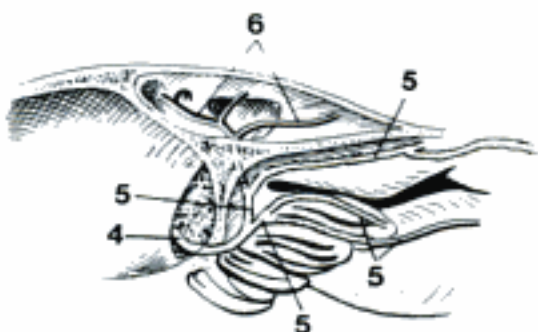


- 1 *N. nasociliaris*. Nasociliary nerve, between M. rectus medialis and M. obliquus dorsalis. A
- 2 *Ramus communicans cum ganglio ciliari*. Branch communicating with Ganglion ciliare. A
- 3 *Nn. ciliares longi*. Long ciliary nerves, supply the anterior structures of the eyeball. A
- 4 *N. ethmoidalis*. Ethmoidal nerve, enters the skull through Foramen ethmoidale, then pierces Os ethmoidale reaching Cavum nasi. A B C
- 5 *Ramus nasalis lateralis*. Lateral nasal branch, supplies Conchae nasales. B
- 6 *Rami sinus frontalis (eq)*. Frontal sinus branches, distribution to Sinus frontalis. B
- 7 *Ramus nasalis medialis*. Medial nasal branch, distribution to Septum nasi. C
- 8 *Rami nasales externi (Car)*. External nasal branches, to the skin rostral to the nasal bone. C
- 9 *N. infratrochlearis*. Infratrochlear nerve, to lacrimal caruncle, ducts and sac, and third eyelid. A
- 10 *Rami sinus frontalis (eq)*. Frontal sinus branches. A
- 11 *Rami palpebrales*. Palpebral branches to Palpebra superior. A
- 12 *Rami cornuales (cap)*. Cornual branches.
- 13 **N. maxillaris**. Maxillary nerve, second branch of N. trigeminus, passes through Foramen rotundum (orbitorotundum). D E F
- 14 *Ramus meningeus*. Meningeal branch, innervates a small area of Dura mater encephali. E
- 15 *N. zygomaticus*. Zygomatic nerve. D E
- 16 *Ramus zygomaticotemporalis*. Zygomaticotemporal branch, communicates with a branch of the N. lacrimalis, runs caudodorsally to the skin of the temporal region, and the lacrimal gland. D
- 17 *Ramus cornualis (Ru)*. Cornual branch.
- 18 *Ramus communicans cum n. lacrimali*. Branch communicating with N. lacrimalis. D
- 19 *Ramus zygomaticofacialis*. Zygomaticofacial branch, supplies the Palpebra inferior and the neighbouring skin. D
- 20 *Ramus zygomaticofacialis accessorius*. Accessory zygomaticofacial branch. D
- 21 *N. pterygopalatinus*. Pterygopalatine nerve, divides after a short course into three nerves. D F
- 22 *N. palatinus minor*. Lesser palatine nerve, innervates the Palatum molle. D F
- 23 *N. palatinus major*. Greater palatine nerve, traverses Canalis palatinus, supplies Palatum durum. D F
- 24 *N. palatinus accessorius*. Accessory palatine nerve, parallels N. palatinus major. D F
- 25 *Rami nasales caudales ventrales (eq)*. Ventral caudal nasal branches, perforate Palatum durum. F
- 26 *N. nasalis caudalis*. Caudal nasal nerve, enters the Cavum nasi through Foramen sphenopalatinum. C D F
- 27 *N. nasopalatinus*. Nasopalatine nerve, continuation of the septal branch, through Fissura palatina to the muscosa of the palate. C

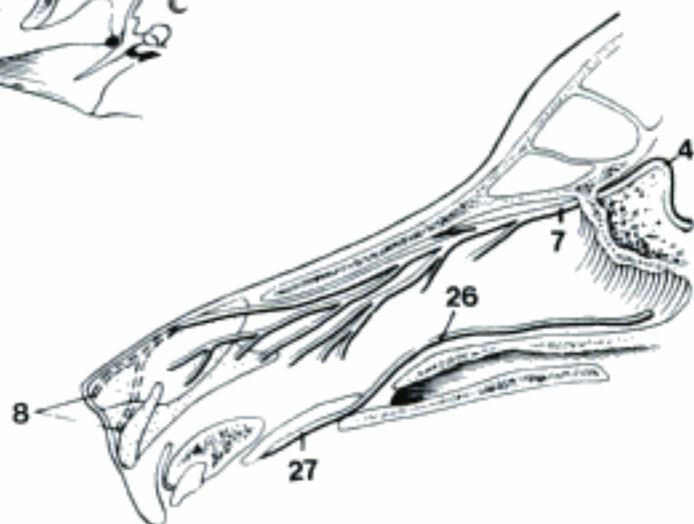
A N. nasociliaris (eq)



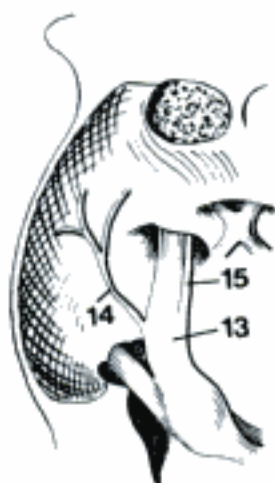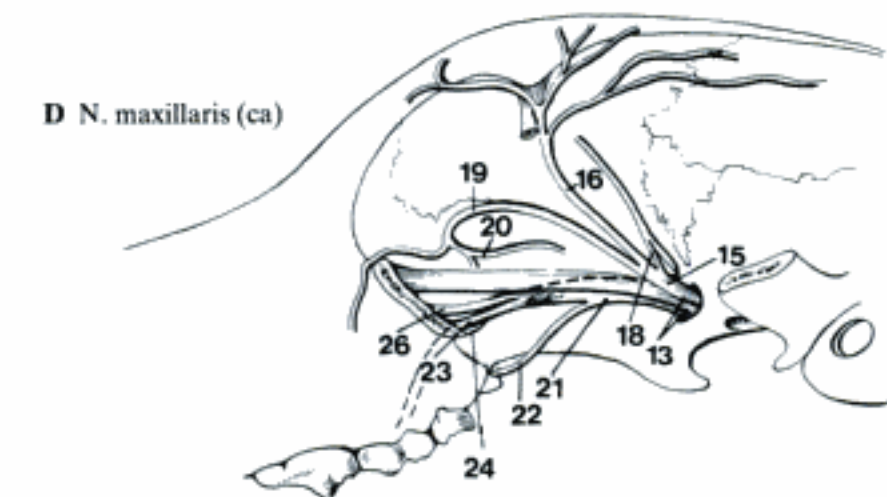
B N. ethmoidalis (eq)



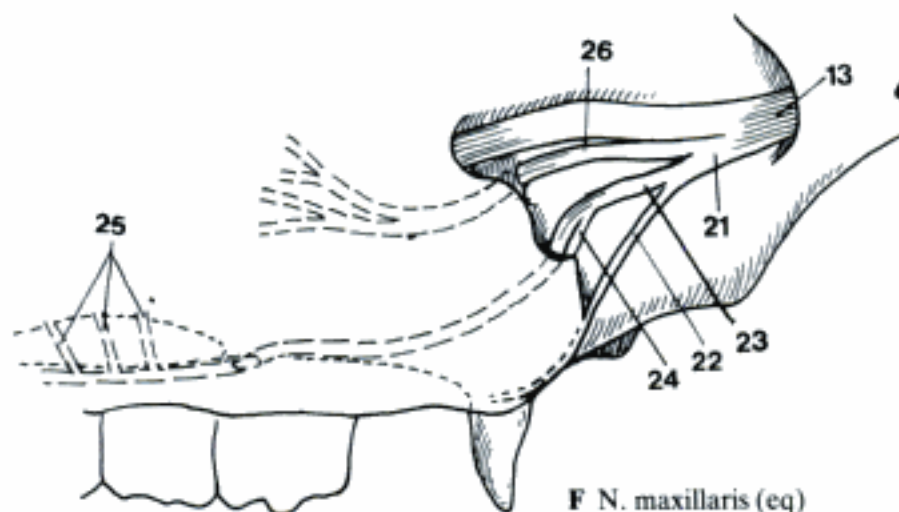
C Nerves in Cavum nasi (ca)



D N. maxillaris (ca)



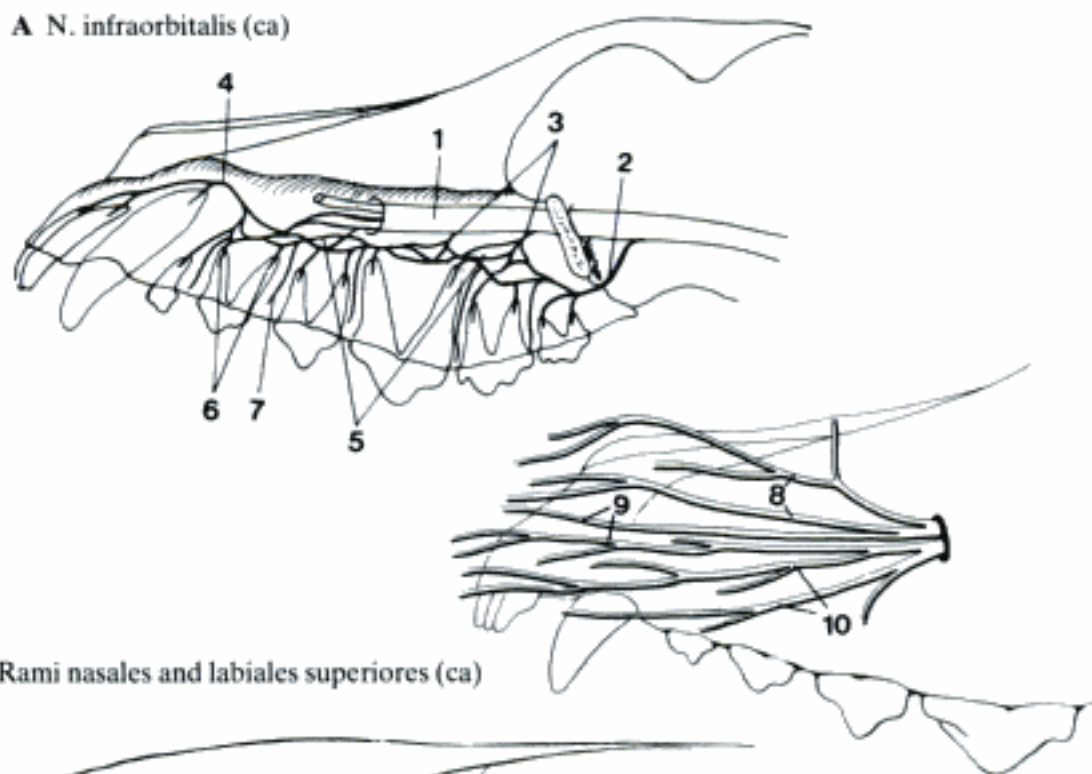
E N. maxillaris within the cranial cavity (eq)



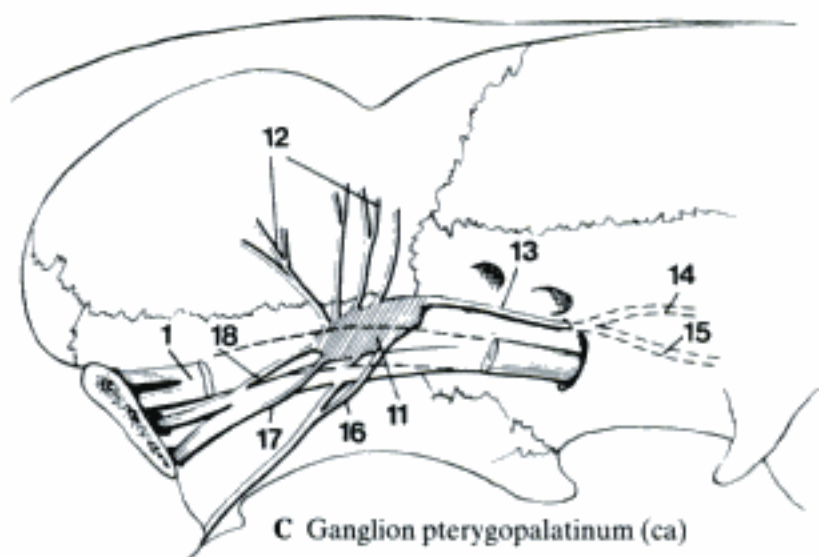
F N. maxillaris (eq)

Hidden page

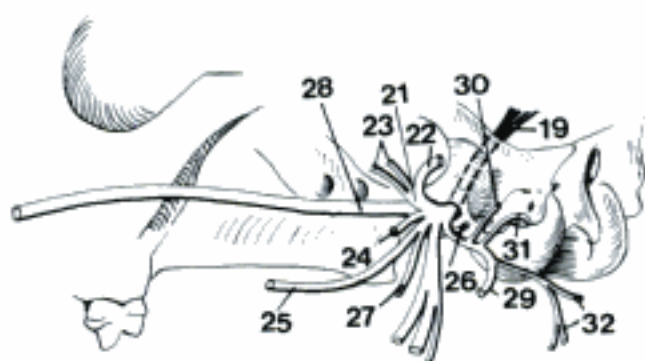
A N. infraorbitalis (ca)



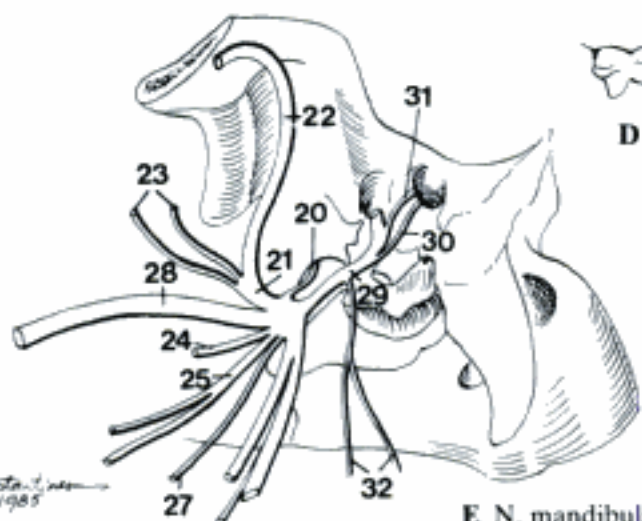
B Rami nasales and labiales superiores (ca)



C Ganglion pterygopalatinum (ca)



D N. mandibularis (ca)

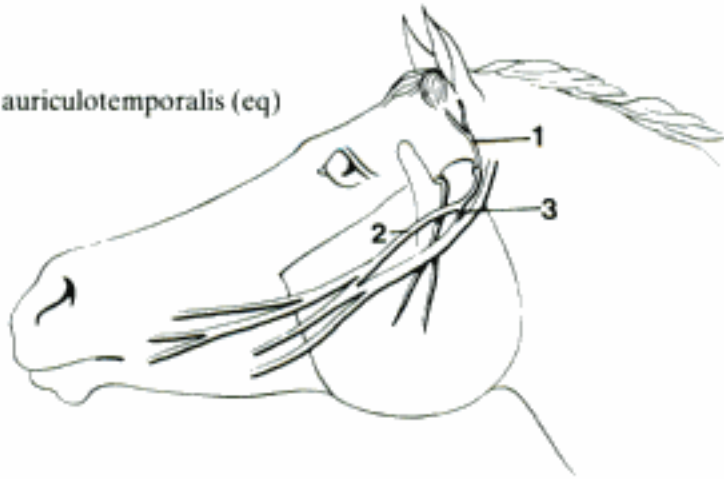


E N. mandibularis (cq)

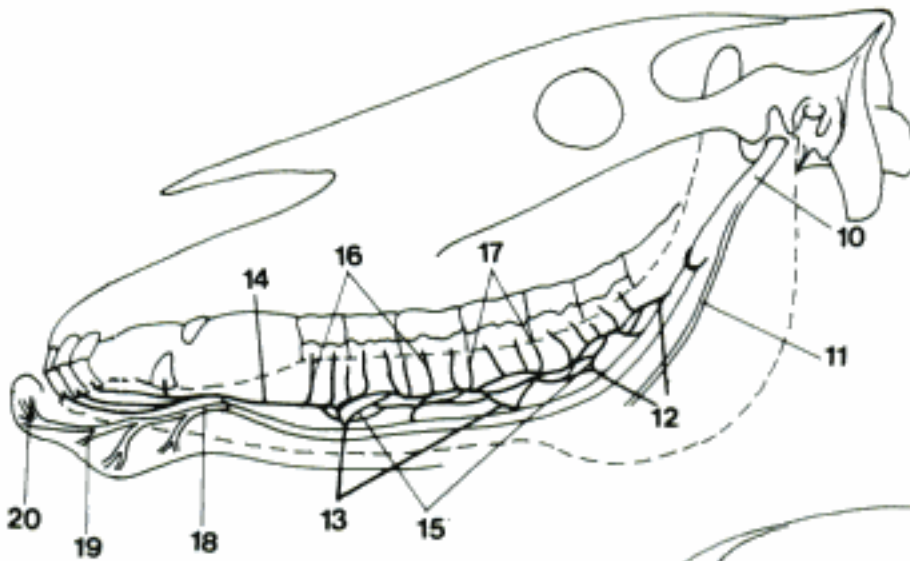
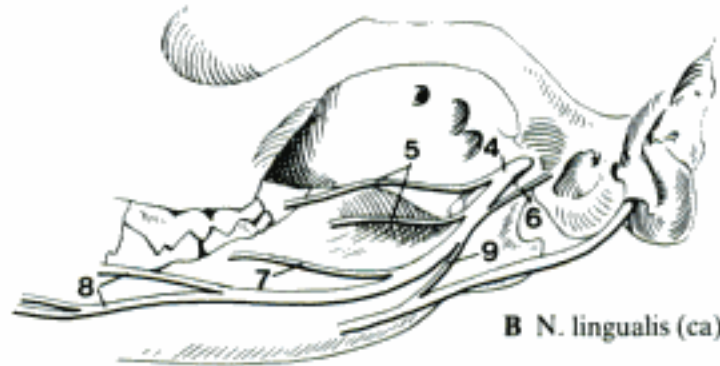
Schäfer, 1985

Hidden page

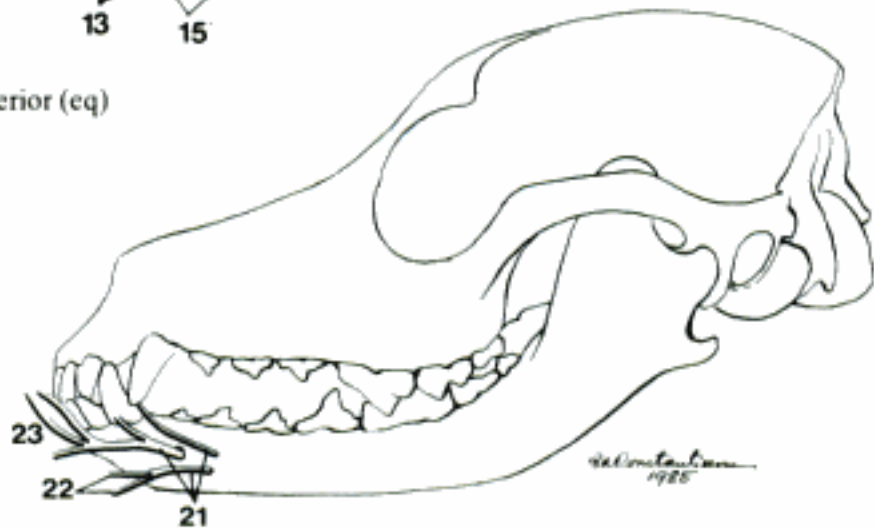
A N. auriculotemporalis (eq)



B N. lingualis (ca)



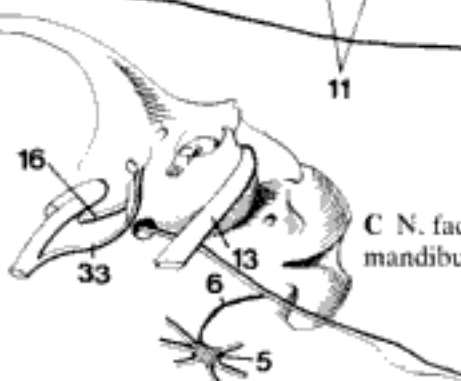
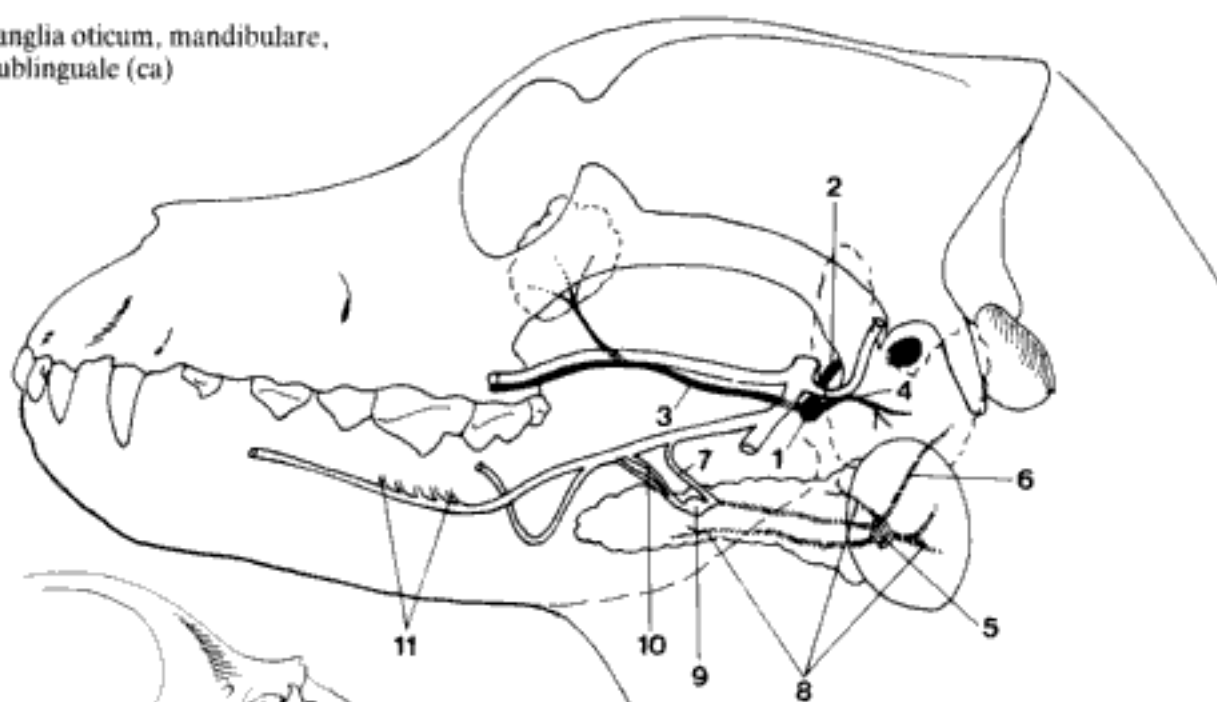
C N. alveolaris inferior (eq)



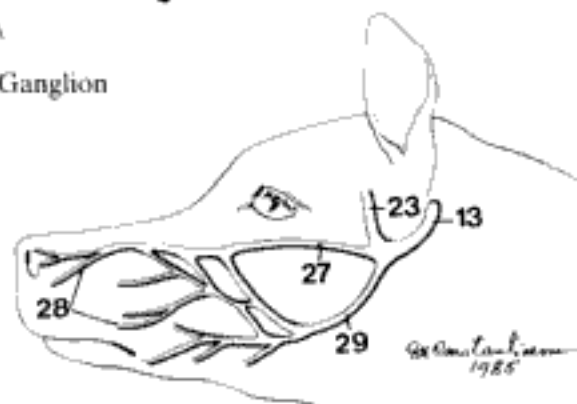
D Nn. mentales (ca)

- 1 **Ganglion oticum.** Otic ganglion, parasympathetic, at the origin of N. buccalis, gives off secretory fibers to Gl. parotis, Gll. buccales, and Gl. zygomatica (Car). A
- 2 *N. petrosus minor.* Lesser petrosal nerve, preganglionic fibers. A
- 3 *Rami communicantes cum n. buccali.* Communicating branches to the buccal nerve, carry parasympathetic fibers to buccal glands and Gl. zygomatica (Car). A
- 4 *Rami communicantes cum n. auriculotemporalis.* Communicating branches to the auriculotemporal nerve. A
- 5 **Ganglion mandibulare.** Mandibular ganglion, at the origin of N. sublingualis, but in Car at the hilus of Gl. mandibularis. The preganglionic fibers proceed from Chorda tympani. A C
- 6 (*Ramus sympathicus ad ganglion mandibulare*). Sympathetic branch to mandibular ganglion from Plexus caroticus internus, without synapses in Ganglion mandibulare. A C
- 7 *Rami communicantes cum n. lingualli.* Communicating branches to lingual nerve. A
- 8 *Rami glandulares.* Glandular branches to the Gll. sublinguales and mandibularis. A
- 9 **Ganglion sublinguale** (Car). Sublingual ganglion, in the angle between N. lingualis and the communicating branches of Ganglion mandibulare to N. lingualis. A
- 10 *Rami communicantes cum n. lingualli.* Communicating branches to the lingual nerve. A
- 11 *Rami glandulares.* To Gll. sublinguales. A
- 12 **N. abducens.** Abducent nerve, supplies Mm. retractor bulbi and rectus lateralis. 465 C
- 13 **N. facialis [N. intermediofacialis].** Facial [intermediofacial] nerve, carries motor, parasympathetic and taste fibers, passes through Meatus acusticus internus and Canalis facialis, exits through Foramen stylomastoideum. B C D
- 14 *Geniculum n. facialis.* Genu of facial nerve, a bend in the intraosseous course. B
- 15 *Ganglion geniculi.* Genuiculate ganglion (see 32). B
- 16 *N. petrosus major.* Greater petrosal nerve, emerges at the genu, parasympathetic, and joins with N. petrosus profundus. B C
- 17 *N. stapedius.* Nerve to M. stapedius. B
- 18 *Ramus auricularis internus.* Internal auricular branch, pierces the pinna and supplies the skin of the inner surface. Receives Ramus auricularis n. vagi before leaving the Canalis facialis. B
- 19 *N. auricularis caudalis.* Caudal auricular nerve, supplies the caudal muscles of the ear. B
- 20 *Ramus digastricus.* Digastric branch, for Venter caudalis m. digastrici. D
- 21 *Ramus stylohyoideus.* To M. stylohyoideus. D
- 22 *Plexus parotideus.* Parotid plexus. D
- 23 *N. auriculopalpebralis.* Auriculopalpebral nerve. D E
- 24 *Rami auriculares rostrales.* Rostral auricular branches, for rostral auricular muscles. D
- 25 *Ramus zygomaticus.* Zygomatic branch. D
- 26 *Rami palpebrales.* Palpebral branches, supply M. orbicularis oculi. D
- 27 *Rami buccales.* Buccal branches, supply the muscles of cheek, lips, and nose. D E
- 28 *Rami buccolabiales.* Buccolabial branches. E
- 29 *Ramus marginalis mandibulae.* Mandibular marginal branch (except eq). E
- 30 *Ramus colli.* Cervical branch, for Mm. parotidoauricularis and cutaneus colli. D
- 31 **N. intermedius.** Intermediate nerve, parasympathetic and sensory component of N. intermediofacialis. B
- 32 *Ganglion geniculi.* Genuiculate ganglion, similar to a spinal ganglion, located within Canalis facialis at Geniculum n. facialis. B
- 33 *Chorda tympani.* Passes through Fissura petrotympanica to join N. lingualis. B C

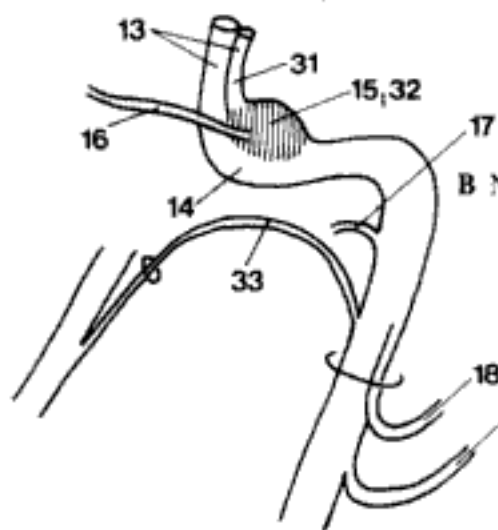
A Ganglia oticum, mandibulare, and sublinguale (ca)



C N. facialis and Ganglion mandibulare (ca)

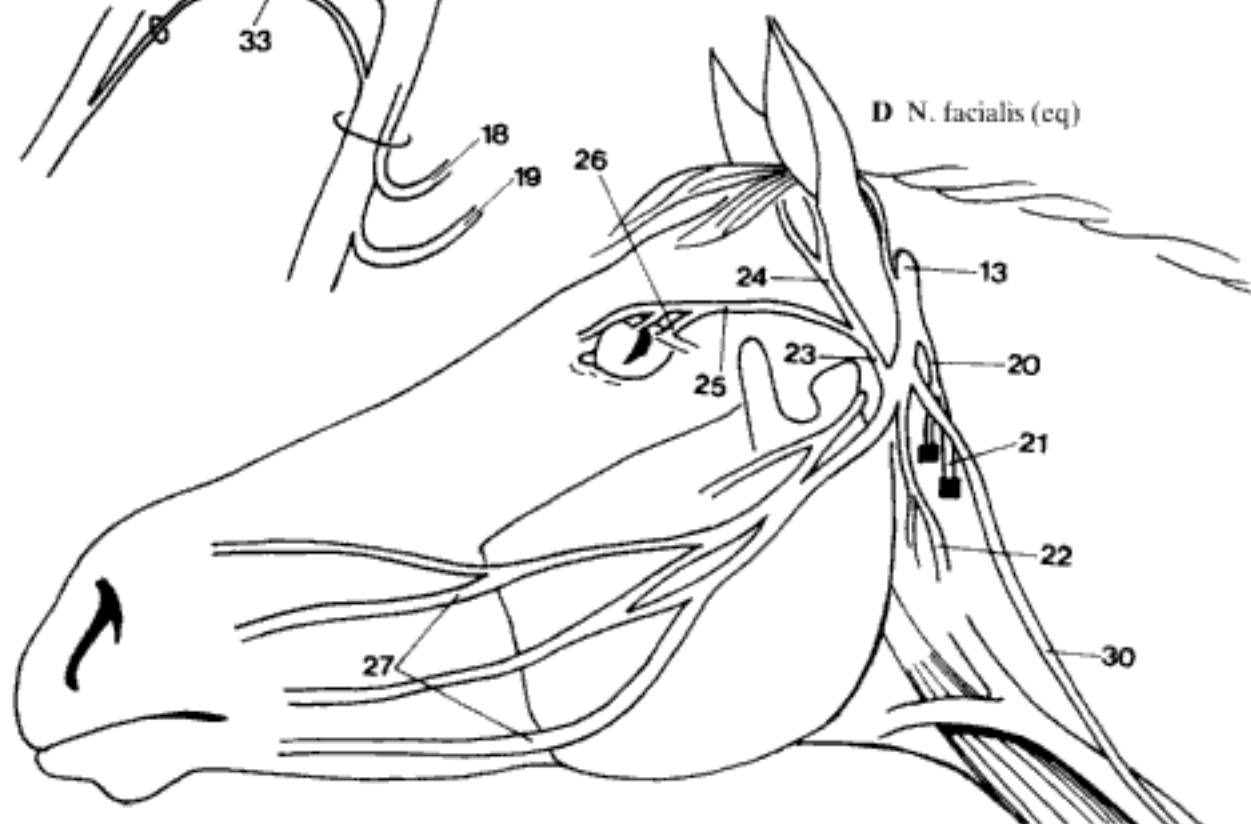


E N. facialis (ca)



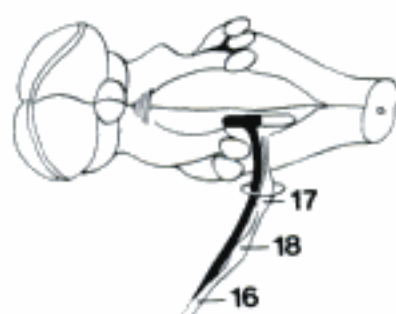
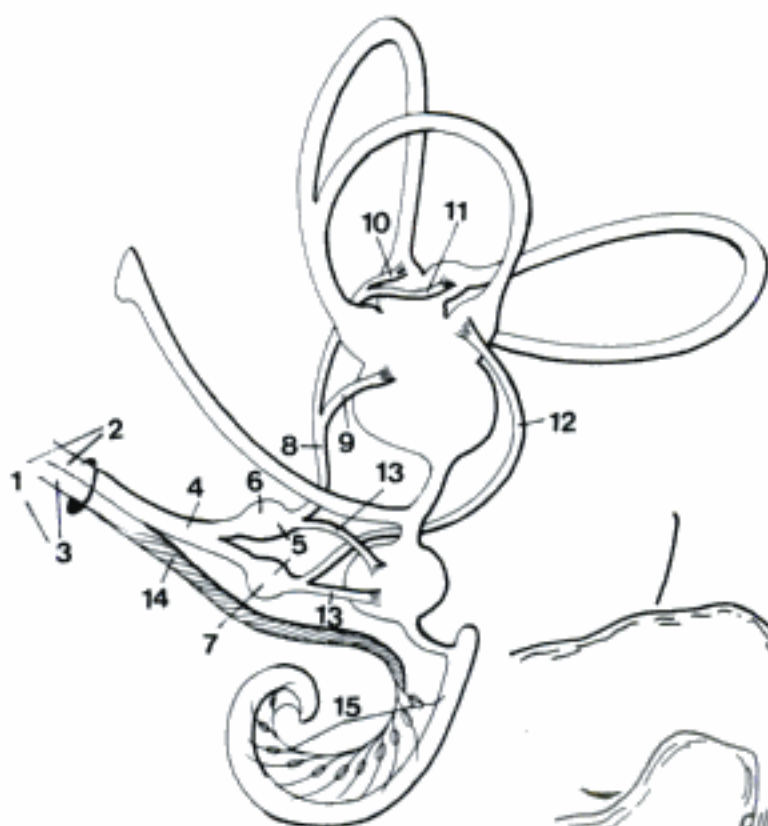
B N. intermediofacialis

D N. facialis (eq)



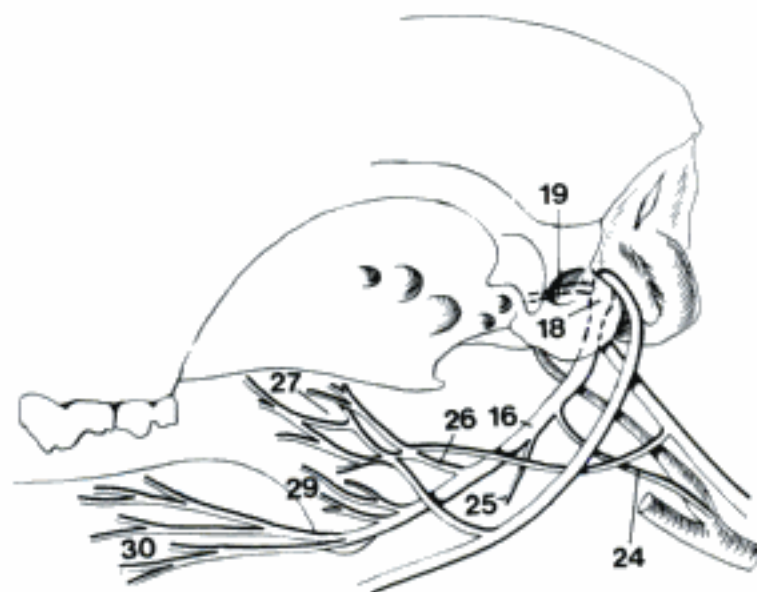
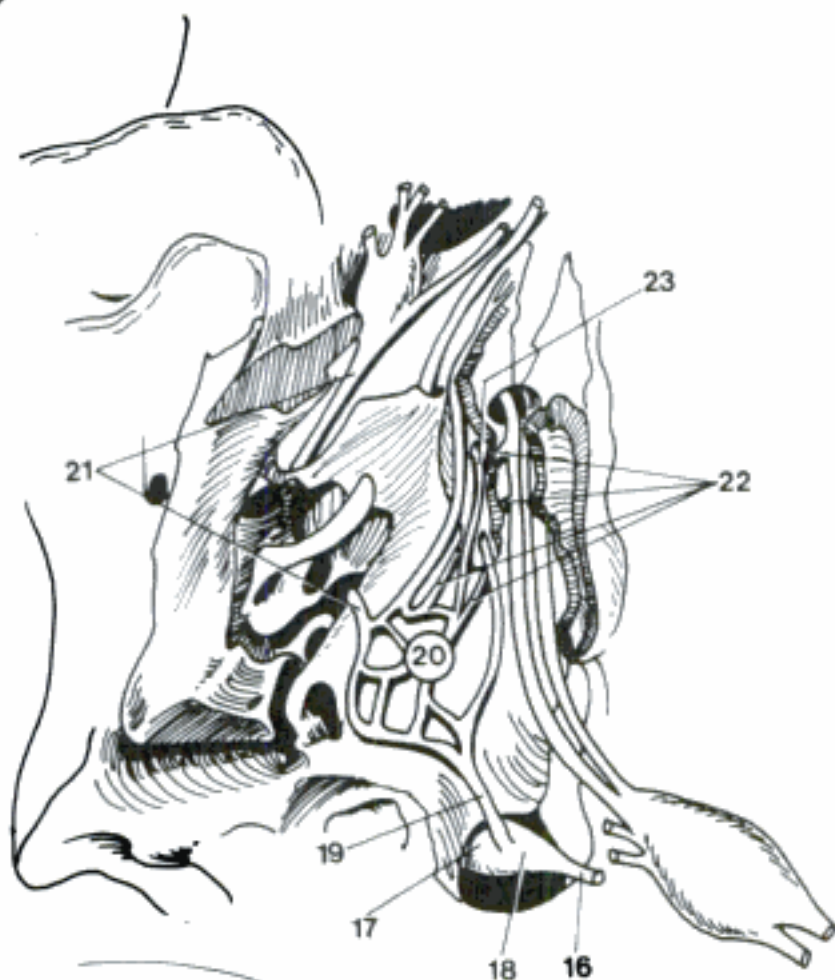
Hidden page

A Right N. vestibulocochlearis, caudal aspect



B Origin of N. glossopharyngeus

C N. glossopharyngeus, Ganglia pterygopalatinum and oticum (Cavum tympani opened), ventral aspect (ca)



D N. glossopharyngeus (ca)

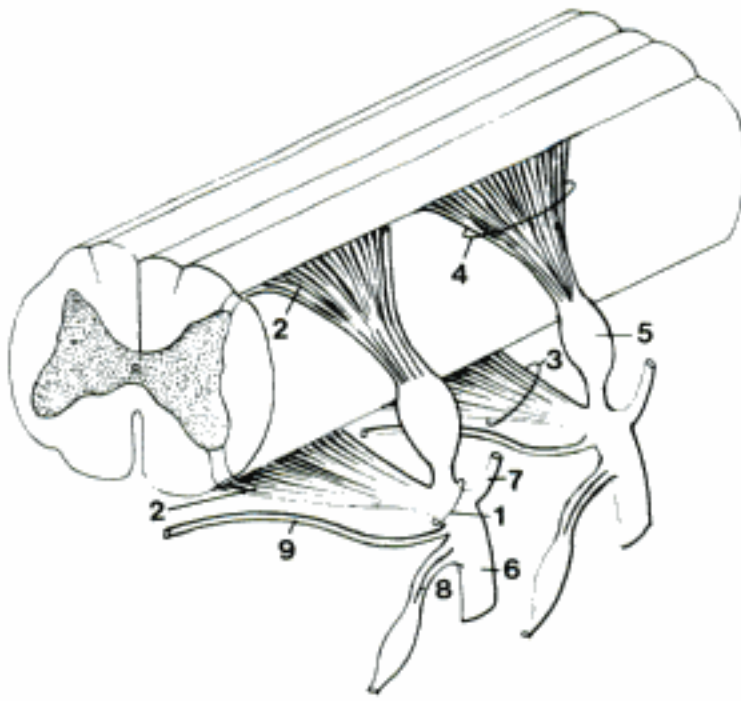
- 1 **N. vagus.** Vagus nerve, carrying motor, sensory, and parasympathetic fibers, passes through Foramen jugulare. A B C D
- 2 *Ganglion proximale.* Proximal ganglion, located in Foramen jugulare, was formerly named Ganglion jugulare. A B
- 3 *Ganglion distale.* Distal ganglion, located caudal to A. carotis interna and Ggl. cervicale craniale, formerly named Ganglion nodosum. A
- 4 *Ramus meningeus.* Meningeal branch, arises from Ganglion proximale. A
- 5 *Ramus communicans cum n. glossopharyngeo.* Branch communicating with glossopharyngeal n. A
- 6 *Ramus auricularis.* Auricular branch, communicates with N. facialis within Canalis facialis, supplies an area on the inner surface of the pinna. B
- 7 *Rami pharyngei.* Pharyngeal branches, supply the pharynx together with Ramus pharyngeus of N. glossopharyngeus. A
- 8 *Plexus pharyngeus.* Pharyngeal plexus, result of the joining of Rami pharyngei nn. glossopharyngei and vagi, and sympathetic fibers. A
- 9 *Ramus esophageus [oesophageus].* Esophageal branch. A
- 10 *N. laryngeus cranialis.* Cranial laryngeal nerve. A
- 11 *Ramus externus.* External branch, supplies M. cricothyroideus. A
- 12 *Ramus internus.* Internal branch, supplies the mucosa. A
- 13 *Ramus communicans cum n. laryngeo caudali.* Branch communicating with caudal laryngeal n., inside the larynx. A
- 14 *N. depressor.* Arises from N. vagus or N. laryngeus cranialis, enters the N. vagus again, distributed to pressoreceptors in aorta. A
- 15 *Truncus vago-sympathicus.* Vago-sympathetic trunk, common course of Truncus sympathicus and N. vagus in the neck. A
- 16 *Rami cardiaci.* Cardiac branches, parasympathetic fibers to the heart. C
- 17 *N. laryngeus recurrens.* Recurrent laryngeal nerve: the left loops around the aorta, the right the Truncus costocervicalis. Both run along trachea to the larynx. C D
- 18 *Rami tracheales.* Tracheal branches. D
- 19 *Rami esophagei [oesophagei].* Esophageal branches. D
- 20 *N. laryngeus caudalis.* Caudal laryngeal nerve, end of N. laryngeus recurrens, supplies all laryngeal muscles, except M. cricothyroideus. A C D
- 21 *Rami bronchiales.* Bronchial branches. C D
- 22 *Plexus pulmonalis.* Pulmonary plexus. C D
- 23 *Rami esophagei [oesophagei] [Plexus esophageus, oesophageus].* Esophageal branches [plexus]. C D
- 24 *Truncus vagalis ventralis.* Ventral vagal trunk, composed of the ventral branches of right and left N. vagus. C D E
- 25 *Rami gastrici parietales.* Parietal gastric branches, on Facies parietalis ventriculi (except Ru). C
- 26 *Ramus communicans.* Communicating branch (Ru), connects Trunci vagales, usually to left of esophagus, inclined caudodorsally or caudoventrally. E
- 27 *Rami atriales ruminis.* Branches to Atrium ruminis. E
- 28 *Rami reticulares craniales.* Branches to Facies diaphragmatica reticuli. E
- 29 *Ramus pyloricus.* Pyloric branch. C
- 30 *Rami hepatici.* Hepatic branches. One of these may arise from Truncus vagalis dorsalis in Ru. C
- 31 *Rami duodenales.* Branches to duodenum and pancreas. C
- 32 *Rami ad sulcum ventriculi.* Branches to ventricular groove in Ru. E
- 33 *Rami omasiales.* Omasal branches. E
- 34 *Rami abomasiales parietales.* Branches to Facies parietalis abomasi. E

Hidden page

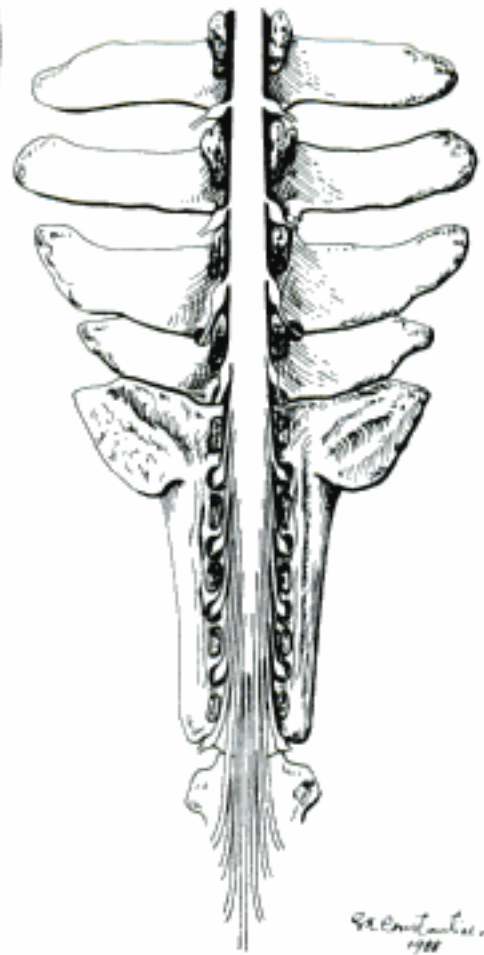
- 1 *Truncus vagalis dorsalis*. Dorsal vagal trunk, composed of the dorsal branches of left and predominantly right N. vagus. A, 477 C D E
- 2 *Rami gastrici viscerales*. Visceral gastric branches to Facies visceralis ventriculi. 477 C
- 3 *Rami atriales ruminis*. Branches to Atrium ruminis. A
- 4 *Rami celiaci [coeliaci]*. Celiac branches, to Plexus celiacus. A
- 5 *Rami ruminales dorsales*. Dorsal ruminal branches, continuations of Truncus vagalis dorsalis to rumen, except its atrium. A
- 6 *Ramus ruminalis dexter*. Right ruminal branch, is the main branch of Truncus vagalis dorsalis, on the Facies visceralis ruminis. A
- 7 *Ramus ad sulcum cranialem*. Branch to cranial groove of rumen. A
- 8 *Rami ad sulcum ventriculi*. Branches to ventricular groove. A
- 9 *Rami reticulares caudales*. Caudal reticular branches, supply Facies visceralis reticuli. A
- 10 *Ramus ad curvaturam majorem abomasi*. Branch to greater abomasal curvature. A
- 11 *Rami omasiales*. Omasal branches.
- 12 *Rami abomasiales viscerales*. Visceral abomasal branches, supply Facies visceralis abomasi. A
- 13 *Rami renales*. Renal branches, supply kidneys and adrenal glands. 477 C
- 14 **N. accessorius**. Accessory nerve, exclusively motor, passes through Foramen jugulare. B C
- 15 *Radices craniales*. Cranial roots, origin in medulla oblongata. C
- 16 *Radices spinales*. Spinal roots, origin in the spinal cord. C
- 17 *Ramus internus*. Internal branch, communicates with N. vagus. C
- 18 *Ramus externus*. External branch, continuation of N. accessorius which courses caudoventrally to supply muscles. B C
- 19 *Ramus dorsalis*. Dorsal branch, supplies the Mm. trapezius and cleidocephalicus. B
- 20 *Ramus ventralis*. Ventral branch, innervates M. sternocephalicus. B
- 21 **N. hypoglossus**. Hypoglossal nerve, exclusively motor, supplies the musculature of the tongue and the Mm. thyrohyoideus and geniohyoideus. Passes through Canalis n. hypoglossi. D
- 22 *Rami linguales*. Lingual branches, supply the muscles of the tongue. D

Hidden page

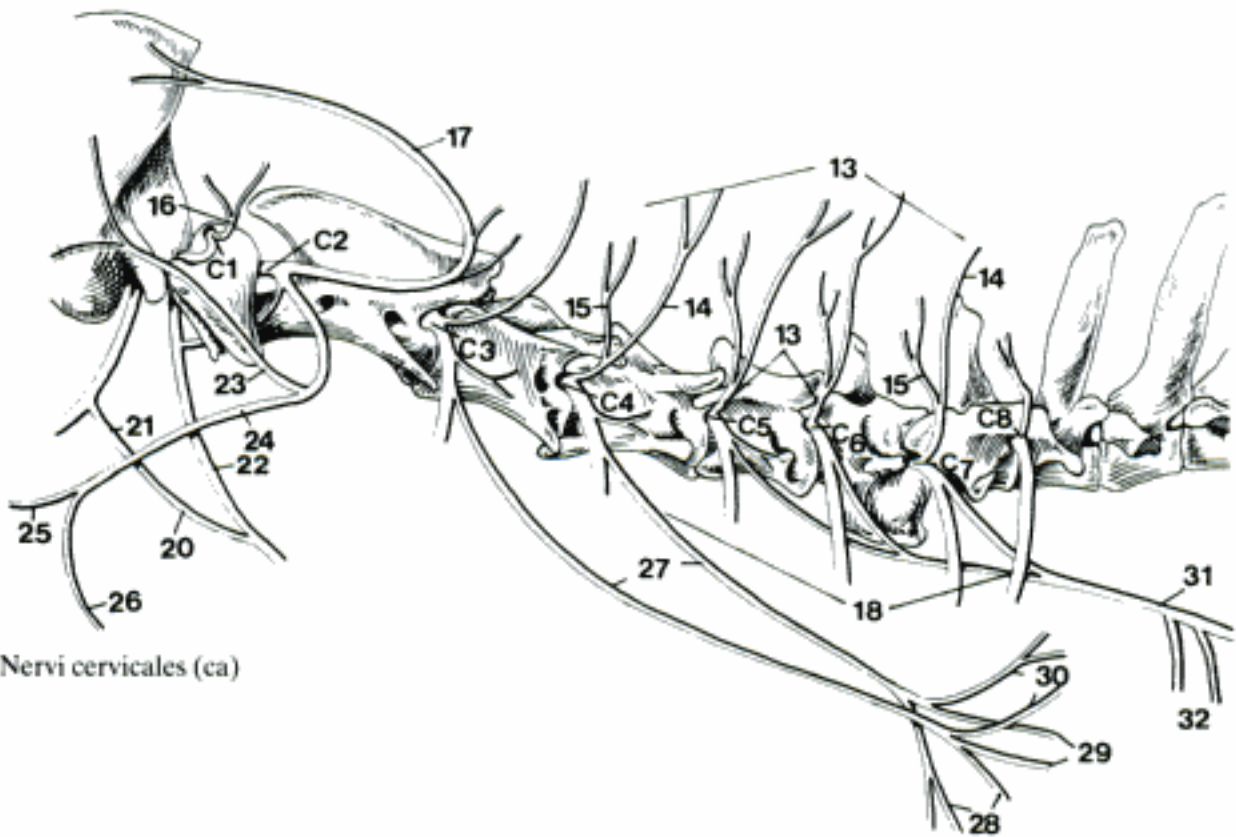
- 1 **NERVI SPINALES.** Spinal nerves, mixed and metameric, with a ventral and a dorsal root starting from Medulla spinalis. Exit through Foramina intervertebralia. A
- 2 *Fila radicularia.* Root filaments, represent the origin of Radix ventralis and Radix dorsalis. A
- 3 *Radix ventralis.* Ventral, motor root. A
- 4 *Radix dorsalis.* Dorsal, sensory root. A
- 5 *Ganglion spinale.* Spinal ganglion, located in Radix dorsalis, immediately before it joins the Radix ventralis in Canalis vertebralis. A
- 6 *Ramus ventralis.* Ventral branch, larger than dorsal branch. A
- 7 *Ramus dorsalis.* Dorsal branch, smaller than ventral branch. A
- 8 *Rami communicantes.* Communicating branches between N. spinalis and Truncus sympathicus. A
- 9 *Ramus meningeus.* Meningeal branch, reenters the Canalis vertebralis. A
- 10 *Cauda equina.* Horse tail-shaped structure, represented by the sacral and caudal spinal nerves, surrounding the Filum terminale. B
- 11 *Ansaes.* Loops, connecting neighbouring nerves.
- 12 **Nervi cervicales.** Cervical nerves. 8 spinal nerves originating from the cervical part of Medulla spinalis. C
- 13 *Rami dorsales.* Dorsal branches, supply muscles and skin in the dorsal part of the neck. C
- 14 *Ramus medialis.* Medial branch, motor and mainly sensory fibers (except C 8). C
- 15 *Ramus lateralis.* Lateral branch, contains only motor fibers. C
- 16 *N. suboccipitalis.* Suboccipital nerve, dorsal branch of the first N. cervicalis. C
- 17 *N. occipitalis major.* Greater occipital nerve, dorsal branch of the second N. cervicalis. C
- 18 *Rami ventrales.* Ventral branches, larger and more diverse than Rami dorsales. Their fibers intermingle resulting Plexus cervicalis. C
- 19 **Plexus cervicalis.** Cervical plexus. Network formed by Rami ventrales of Nn. cervicales I–V.
- 20 *Ansa cervicalis.* Cervical loop, between N. hypoglossus and Ramus ventralis of C1 (esp. ca). Rami ventr. of C1 and C2 and sometimes C3 (esp. Un). Supplies Mm. sterno- and omohyoideus and sternohyoideus C, 479 D
- 21 *Radix cranialis.* Cranial root, from N. hypoglossus or Ramus ventralis of C1. C
- 22 *Radix caudalis.* Caudal root, from Rami ventralis of C1 or C2 (sometimes additionally C3). C
- 23 *N. auricularis magnus.* Great auricular nerve, from Ramus ventralis of C2. C
- 24 *N. transversus colli.* Transverse cervical nerve, from Ramus ventralis of C2, was formerly designated Nervus cutaneus colli, but there are many cutaneous nerves of the neck, therefore the cleaner N. A. term was adopted. C
- 25 *Rami craniales.* Cranial branches. C
- 26 *Rami caudales.* Caudal branches. C
- 27 *Nn. supraclaviculares.* Supraclavicular nerves, arise from Rami ventrales of Nn. cervicales III–IV (Car), IV–V (su, Ru), V–VI (eq). C
- 28 *Nn. supraclaviculares ventrales.* Ventral supraclavicular nerves. C
- 29 *Nn. supraclaviculares intermedii.* Intermediate supraclavicular nerves. C
- 30 *Nn. supraclaviculares dorsales.* Dorsal supraclavicular nerves. C
- 31 **N. phrenicus.** Phrenic nerve, arises from Rami ventrales of Nn. cervicales V–VII and sometimes IV, to the diaphragm. C, 483 B
- 32 *Rami pericardiaci.* Pericardiac branches. C



A Nervi spinales, roots and branches



B Cauda equina (eq)



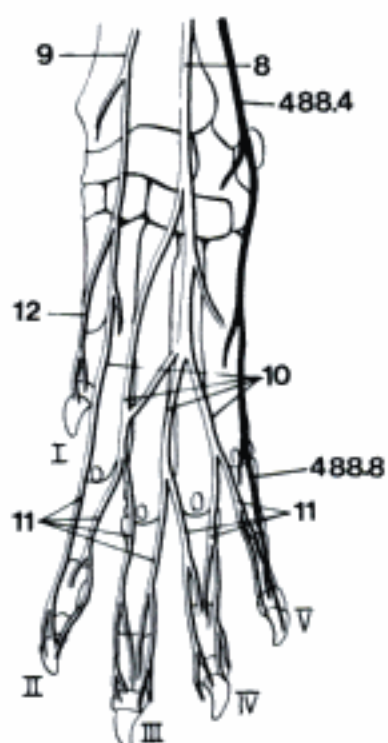
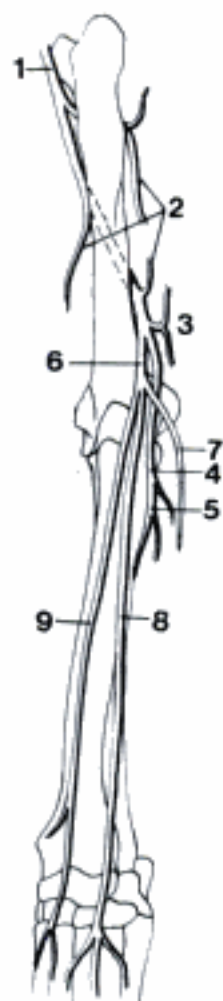
C Nervi cervicales (ca)

- 1 **Plexus brachialis.** Brachial plexus, network of Rami ventrales of Nn. cervicales V (su), VI–VIII and thoracici I, II (ca, Ru, eq), runs to the axilla, supplies the forelimb and partially the shoulder girdle. A B
- 2 **Radices plexus.** Roots of plexus, branches of the Rami ventrales that form the plexus. A
- 3 **Trunci plexus.** Trunks of plexus, some roots unite to form Trunci plexus. A B
- 4 *N. dorsalis scapulae.* Dorsal scapular nerve, small branch (usually not described in veterinary textbooks) to Mm. serratus ventralis cervicis and rhomboidei. A B
- 5 *N. subclavius.* Subclavian nerve, innervates M. subclavius in Un. B
- 6 *N. suprascapularis.* Suprascapular nerve, arising from C6–C7 (eq C8), supplies the Mm. supraspinatus and infraspinatus. A B
- 7 *Nn. subscapulares.* Subscapular nerves, originating from C6–C8, supply the M. subscapularis. A B
- 8 **N. musculocutaneus.** Musculocutaneous nerve, arises from C6 (Un), C7, C8 (Car, eq), descends medial to shoulder joint to join the N. medianus in Un. A B
- 9 *Ramus muscularis proximalis.* Proximal muscular branch, supplies Mm. coracobrachialis and biceps brachii. A B
- 10 *Ansa axillaris.* Axillary loop, formed by the junction of Nn. musculocutaneus and medianus, around distal surface of the A. axillaris in Un. The communication between Nn. musculocutaneus and medianus near the elbow in Car is not homologous to the Ansa axillaris. B
- 11 *Ramus muscularis distalis.* Distal muscular branch. Arises, together with N. cutaneus antebrachii medialis from N. medianus in the distal part of the brachium (Un). A B
- 12 *N. cutaneus antebrachii medialis.* Medial cutaneous antebrachial nerve, descends on the medial side of the antebrachium, carpus, and metacarpus. A B, 491 A B
- 13 **N. axillaris.** Axillary nerve, arises from C6–C7 (C7–C8 eq), supplies shoulder muscles and an area of the skin of brachium and antebrachium. A B
- 14 *Rami musculares.* Muscular branches, innervate the Mm. cleidobrachialis, deltoideus, teres minor, teres major, capsularis, and the caudal part of M. subscapularis. A B
- 15 *N. cutaneus brachii lateralis cranialis.* Cranial lateral cutaneous brachial nerve, arises between Caput longum and Caput laterale of M. triceps brachii, supplies the skin on the lateral surface of the brachium, cranial to the territory of N. intercostobrachialis. A B
- 16 *N. cutaneus antebrachii cranialis.* Cranial cutaneous antebrachial nerve, supplies the skin over the muscular part of M. extensor carpi radialis. A B
- 17 **Nn. pectorales craniales.** Cranial pectoral nerves, supply Mm. pectorales superficiales. A B
- 18 **N. thoracicus longus.** Long thoracic nerve, from C7 and (or) C8, runs caudally supplying the M. serratus ventralis thoracis. B
- 19 **N. thoracodorsalis.** Thoracodorsal nerve, originates mainly from C8, innervates the M. latissimus dorsi. A B
- 20 **N. thoracicus lateralis.** Lateral thoracic nerve, arises mainly from C8 and T1, supplies the M. cutaneus trunci. Some of its fibers join in Un the N. intercostobrachialis. A B
- 21 **Nn. pectorales caudales.** Caudal pectoral nerves, innervate the M. pectoralis ascendens. A B

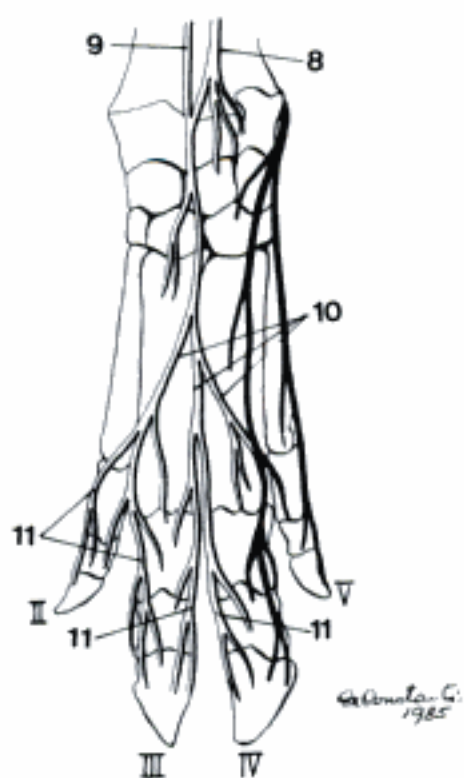
Hidden page

Hidden page

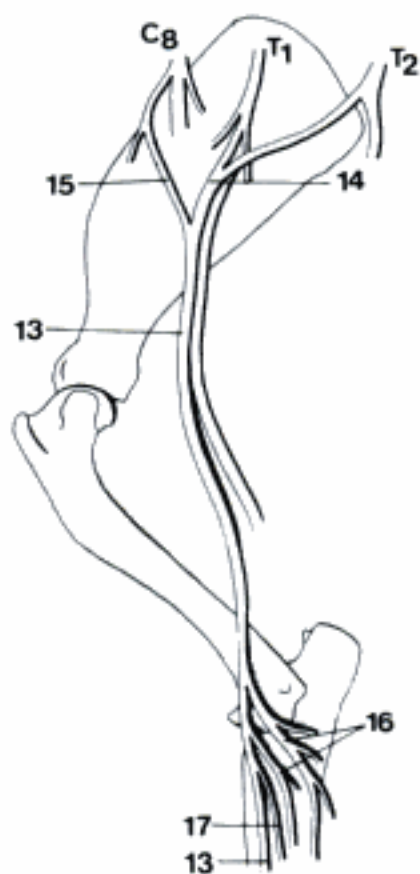
A N. radialis - left brachium and antebrachium, cranial aspect (ca)



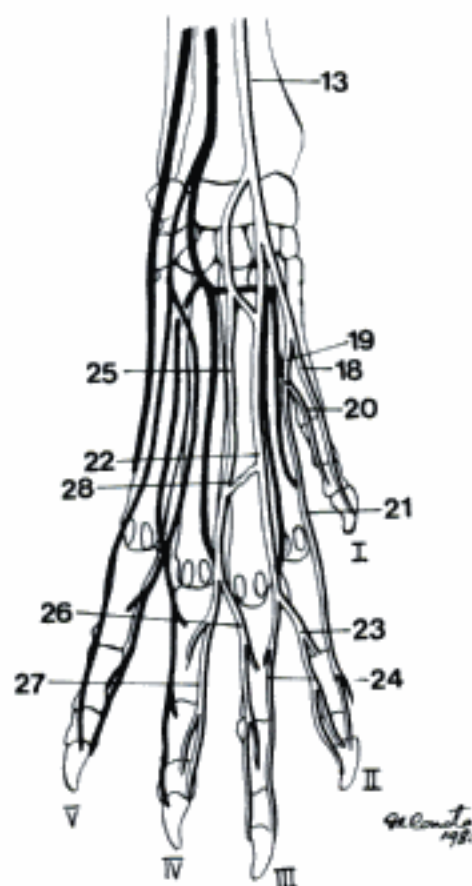
B Nn. radialis and ulnaris - left manus, dorsal aspect (ca)



C Nn. radialis and ulnaris - left manus, dorsal aspect (su)



D N. medianus - right shoulder, brachium, elbow, medial aspect (ca)



E N. medianus - left manus, palmar aspect (fe)

SUS

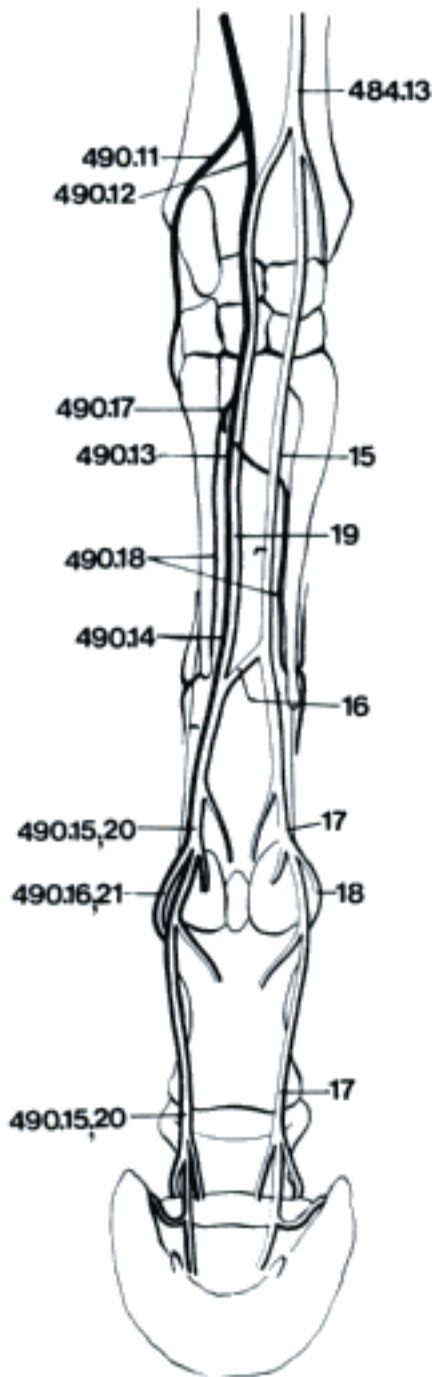
- 1 *N. digitalis palmaris II abaxialis*. Palmar abaxial digital nerve II, arises from the medial branch of N. medianus to supply the palmar aspect of the abaxial side of digit II. A
 - 2 *N. digitalis palmaris communis II*. Palmar common digital nerve II, arises from the medial branch of N. medianus. A
 - 3 *N. digitalis palmaris proprius II axialis*. Palmar axial proper digital nerve II. A
 - 4 *N. digitalis palmaris proprius III abaxialis*. Palmar abaxial proper digital nerve III. A
 - 5 *N. digitalis palmaris communis III*. Palmar common digital nerve III. A
 - 6 *N. digitalis palmaris proprius III axialis*. Palmar axial proper digital nerve III. A
 - 7 *N. digitalis palmaris proprius IV axialis*. Palmar axial proper digital nerve IV. A
 - 8 *Ramus communicans*. Communicating branch between N. digitalis palmaris communis III and N. digitalis palmaris communis IV (from N. ulnaris). A
- RAMINANTIA
- 9 *N. digitalis palmaris communis II*. Palmar common digital nerve II, arises from the medial branch of N. medianus. B
 - 10 *N. digitalis palmaris proprius II*. Palmar proper digital nerve II, a very short branch, in bo only. B
 - 11 *N. digitalis palmaris proprius III abaxialis*. Palmar abaxial proper digital nerve III, the continuation of N. digitalis communis II on the abaxial side of digit III. B
 - 12 *N. digitalis palmaris III axialis*. Palmar axial digital nerve III, arises from the medial branch of N. medianus and lies on the axial side of digit III (bo, ov). In cap there is a N. digitalis palmaris communis III continued by Nn. digitales palmares proprii III and IV axiales. B
 - 13 *N. digitalis palmaris IV axialis*. Palmar axial digital nerve IV, lateral branch of N. medianus, descends on the axial side of digit IV (bo, ov). In cap it arises from N. digitalis palmaris communis III. The Nn. digitales palmares III and IV axiales often reunite in bo for a short distance, forming a N. digitalis palmaris communis III. B

- 14 *Ramus communicans*. Communicating branch, connects the lateral branch of N. medianus with the palmar branch of N. ulnaris. B

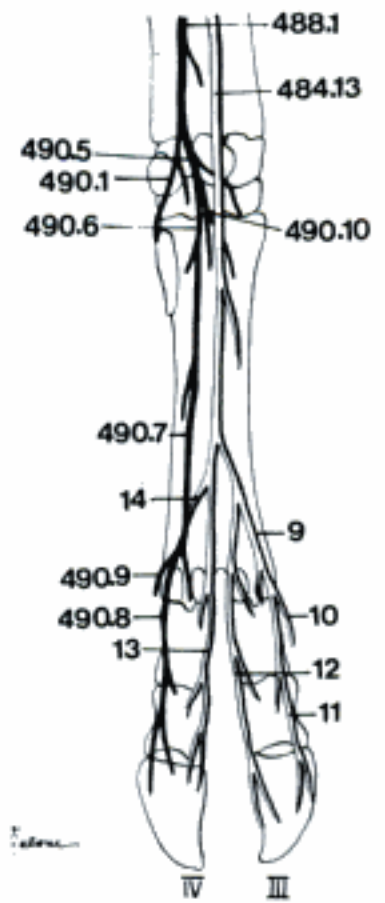
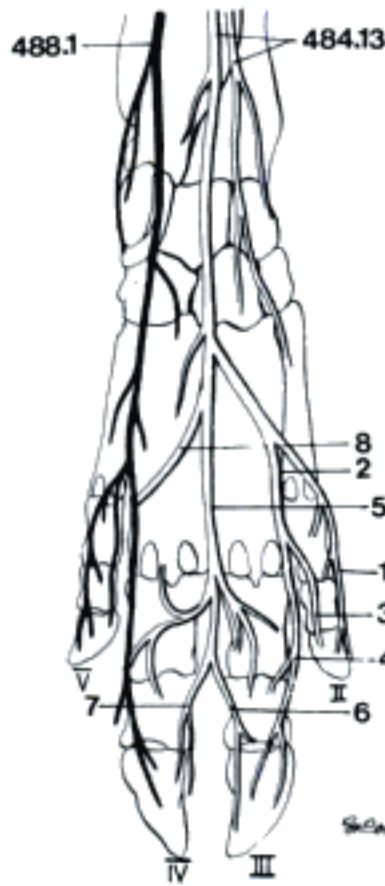
EQUUS

- 15 *N. palmaris medialis [N. digitalis palmaris communis II]*. Medial palmar nerve, descends through Canalis carpi and along the medial border of the tendon of M. flexor digitalis profundus. C D
- 16 *Ramus communicans*. Communicating branch between Nn. palmares in the middle of metacarpus, on the surface of the tendon of M. flexor digitalis superficialis. C D
- 17 *N. digitalis palmaris [proprius] medialis*. Palmar [proper] medial digital nerve, continuation of N. palmaris medialis in the digital area, along the tendons of the digital flexors. C D
- 18 *Ramus dorsalis*. Dorsal branch, arises at the level of Articulatio metacarpophalangea and runs obliquely towards the Facies dorsalis of the digit. In some specimens it gives off an intermediate branch. In others, N. digitalis palmaris medialis gives off the intermediate branch. C D
- 19 *N. palmaris lateralis [N. digitalis palmaris communis III]*. Lateral palmar nerve, accompanies the tendon of M. flexor digitalis profundus on the lateral side of the metacarpus after receiving the Ramus palmaris of N. ulnaris. C
- 20 *N. digitalis palmaris [proprius] lateralis*. Palmar (proper) lateral digital nerve, continuation of N. palmaris lateralis. C
- 21 *Ramus dorsalis*. Dorsal branch, arises at the level of Articulatio metacarpophalangea and runs obliquely towards the Facies dorsalis of the digit. C

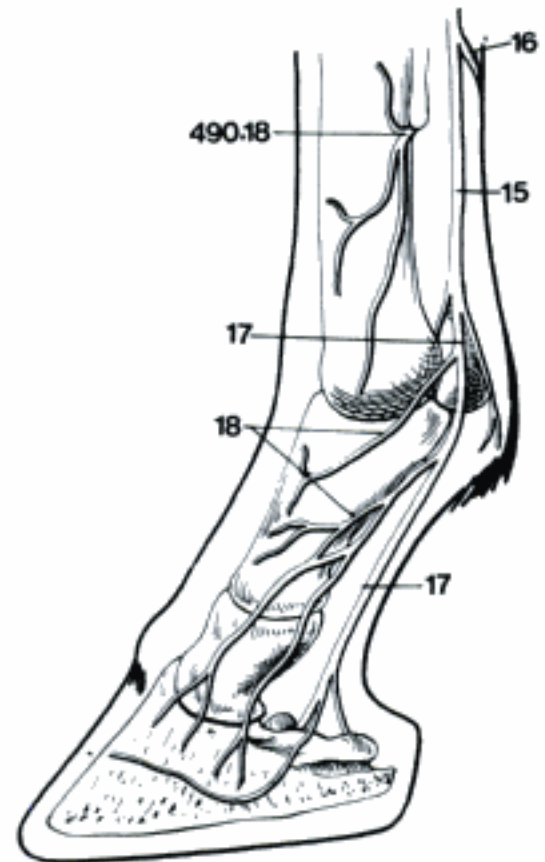
A Nn. medianus and ulnaris – left manus, palmar aspect (su)



C Nn. medianus and ulnaris – left manus, palmar aspect (eq)



B Nn. medianus and ulnaris – left manus, palmar aspect (bo)

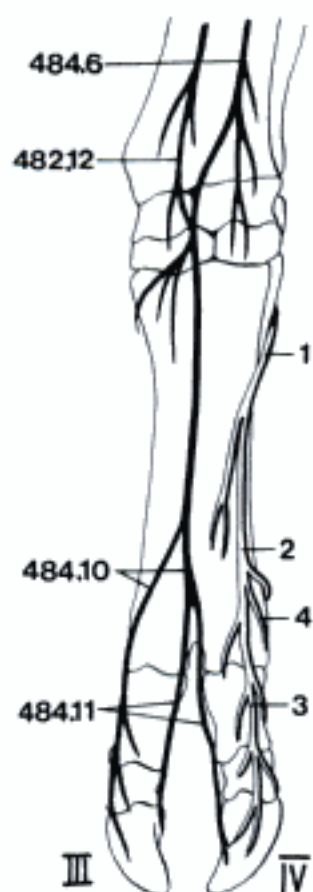


D N. medianus, right digit, medial aspect (eq)

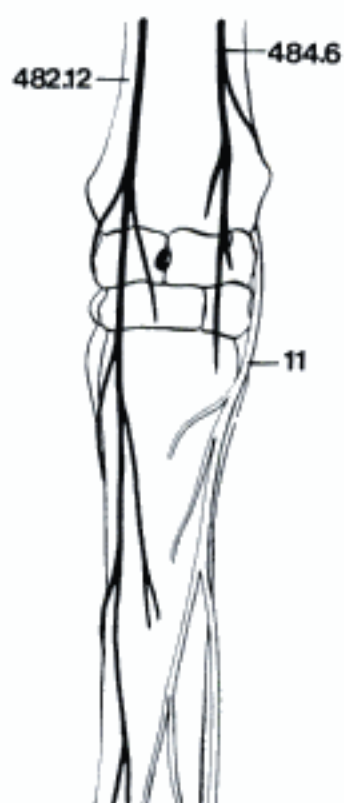Hidden page

Hidden page

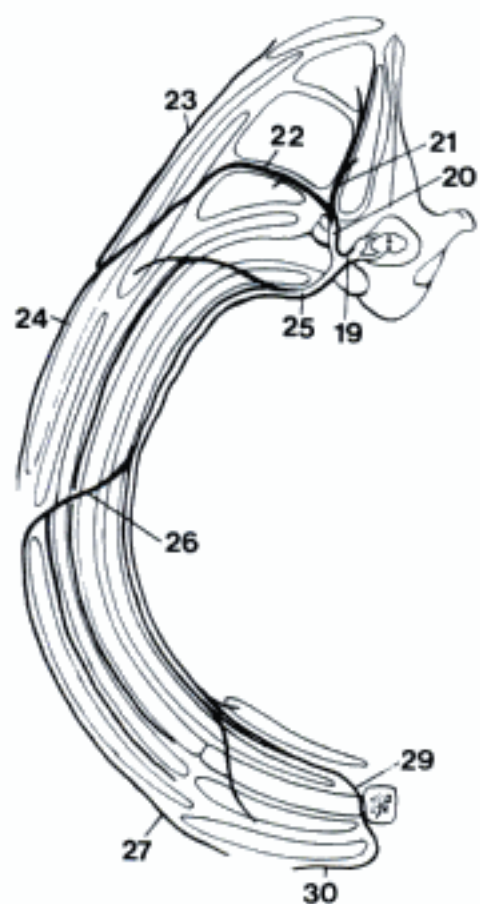
Hidden page



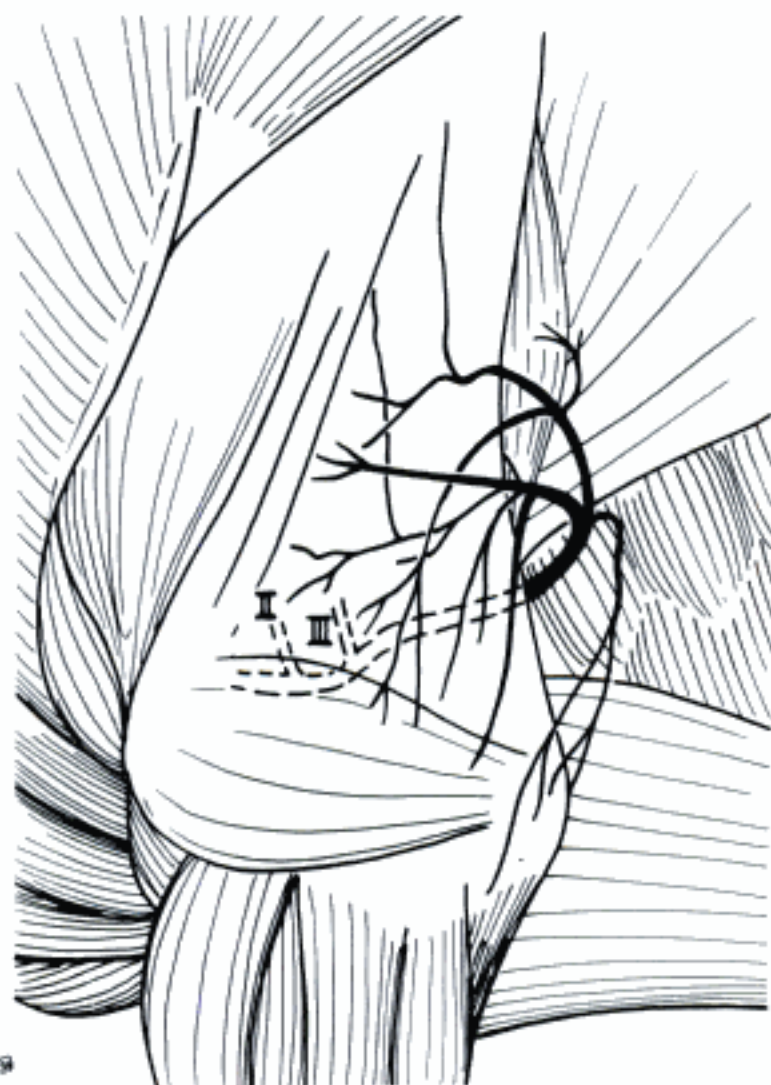
A Nerves of left manus, dorsal aspect (bo)



B Nerves of left metacarpus, dorsal aspect (eq)

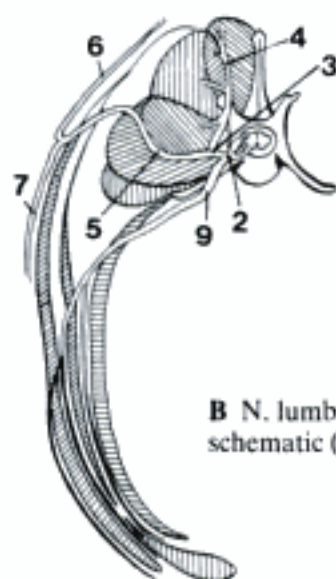
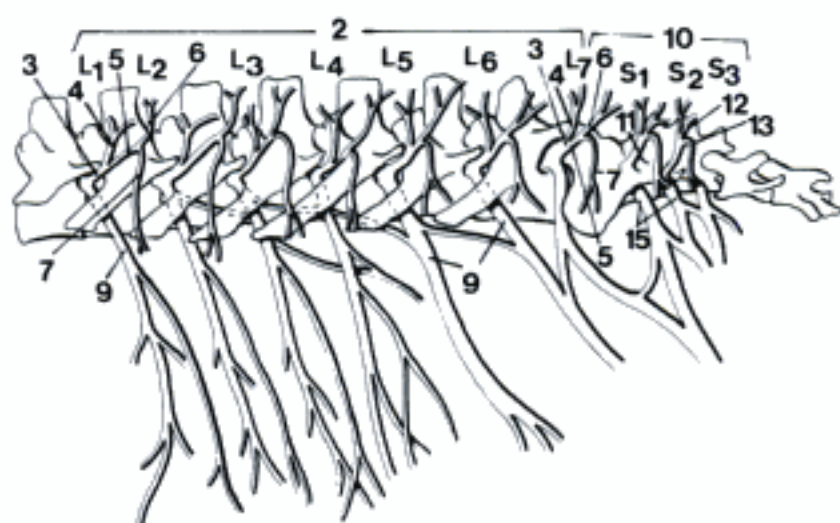


C N. thoracicus VIII - transverse section of thorax (ca)



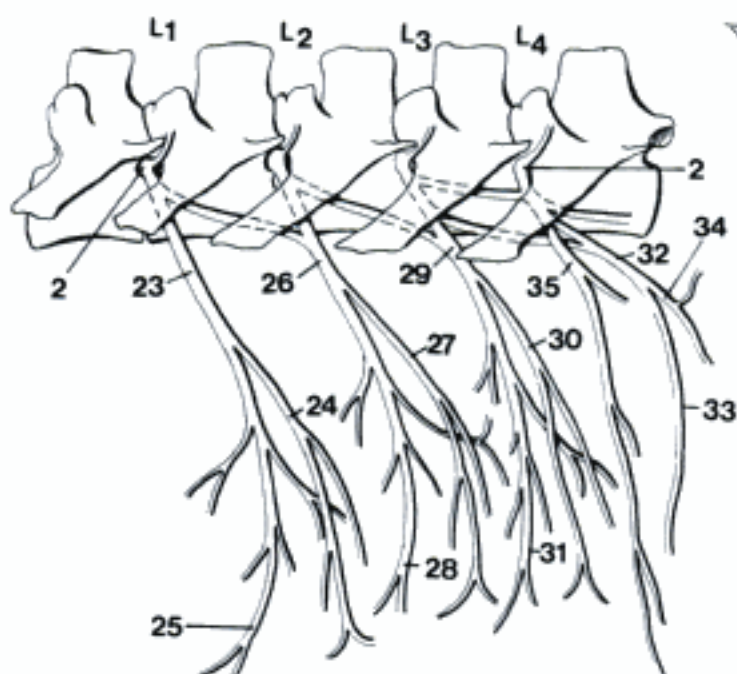
D Left N. intercostobrachialis (bo) (Schaller)

- 1 **Nn. lumbales, sacrales et caudales [coccygei]**. Lumbar, sacral and caudal [coccygeal] nerves.
- 2 **Nn. lumbales**. Lumbar nerves, number depends on species. A B D E
- 3 **Rami dorsales**. Dorsal branches, supply the epaxial musculature and the skin of the lumbar and the gluteal regions. A B E
- 4 **Ramus medialis**. Medial branch, motor for the epaxial musculature. A B
- 5 **Ramus lateralis**. Lateral branch, passes between Mm. longissimus and iliocostalis becomes subcutaneous and bifurcates immediately. A B E
- 6 **Ramus cutaneus medialis**. Medial cutaneous branch. A B E
- 7 **Ramus cutaneus lateralis**. Lateral cutaneous branch. A B E
- 8 **Nn. clunium craniales**. Cranial clunial nerves, innervate the skin of the gluteal region and over M. tensor fasciae latae (esp. Ru and eq). C
- 9 **Rami ventrales**. Ventral branches, contribute to form the Plexus lumbalis. A B E
- 10 **Nn. sacrales**. Sacral nerves. A
- 11 **Rami dorsales**. Dorsal branches. A
- 12 **Ramus medialis**. Medial branch, innervates the epaxial musculature. A
- 13 **Ramus lateralis**. Lateral branch, mainly cutaneous. A
- 14 **Nn. clunium medii**. Middle clunial nerves, supply the skin over M. gluteus superficialis and the cranial part of M. biceps femoris. C
- 15 **Rami ventrales**. Ventral branches contribute to form the Plexus sacralis. A
- 16 **Plexus lumbosacralis**. Lumbosacral plexus, includes lumbar and sacral plexuses, and Truncus lumbosacralis.
- 17 **Radices plexus**. Roots of the plexus, parts of the Rami ventrales that form the plexus. E
- 18 **Trunci plexus**. Trunks of the plexus, formed by the union of the roots. E
- 19 **Plexus lumbalis**. Lumbar plexus, supplies the cranial and medial muscles of the thigh and the skin on the medial aspect of thigh, crus, tarsus, and metatarsus. D E
- 20 **N. iliohypogastricus**. Iliohypogastric nerve, Ramus ventralis of L1 in species with six lumbar vertebrae, supplies abdominal muscles and skin. E
- 21 **Ramus cutaneus lateralis**. Lateral cutaneous branch. E
- 22 **Ramus cutaneus ventralis**. Ventral cutaneous branch.
- 23 **N. iliohypogastricus cranialis**. Cranial iliohypogastric nerve, Ramus ventralis of L1 in species with seven lumbar vertebrae. D
- 24 **Ramus cutaneus lateralis**. Lateral cutaneous branch. D
- 25 **Ramus cutaneus ventralis**. Ventral cutaneous branch. D
- 26 **N. iliohypogastricus caudalis**. Caudal iliohypogastric nerve, Ramus ventralis of L2 in species with seven lumbar vertebrae. D
- 27 **Ramus cutaneus lateralis**. Lateral cutaneous branch. D
- 28 **Ramus cutaneus ventralis**. Ventral cutaneous branch. D
- 29 **N. ilioinguinalis**. Ilioinguinal nerve, Ramus ventralis L2 or L3 depending on species. D E
- 30 **Ramus cutaneus lateralis**. Lateral cutaneous branch. D E
- 31 **Ramus cutaneus ventralis**. Ventral cutaneous branch. D E
- 32 **N. genitofemoralis**. Genitofemoral nerve, arises from L2 (Ru, eq), L3 and L4. D E
- 33 **Ramus genitalis**. Genital branch, passes through Canalis inguinalis, supplies M. cremaster, Preputium, Scrotum, Mammae. D E
- 34 **Ramus femoralis**. Femoral branch. D E
- 35 **N. cutaneus femoris lateralis**. Lateral cutaneous femoral nerve, arises from L3, L4 (L5), supplies the skin on the craniomedial aspect of the thigh. D E

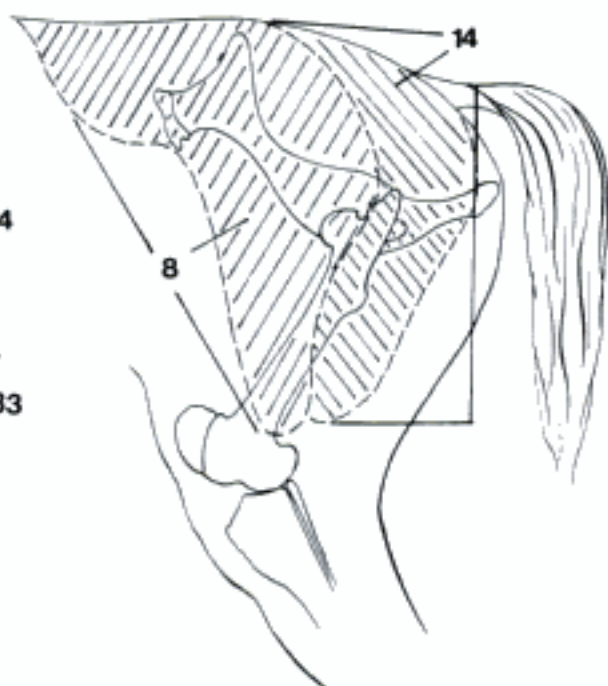


B N. lumbalis IV, schematic (ca)

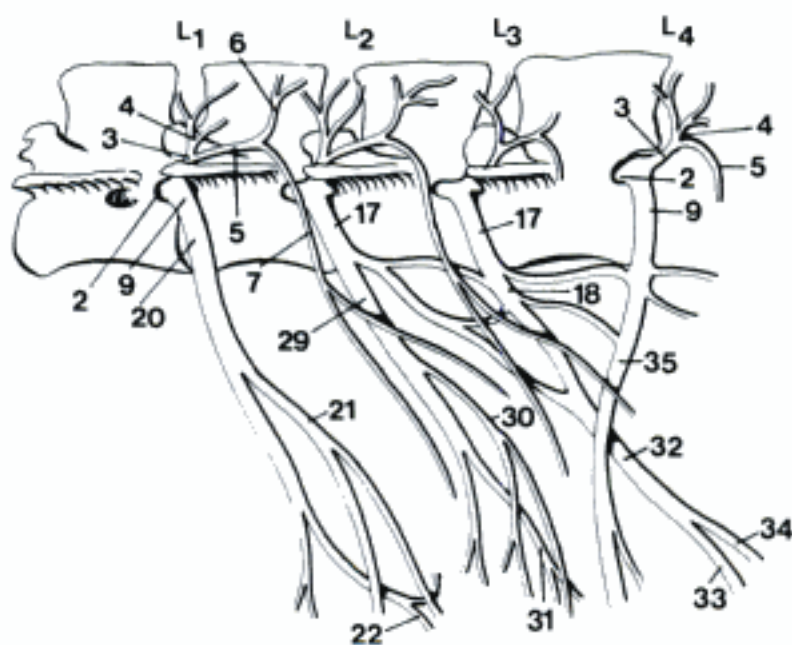
A Plexus lumbosacralis, left side (ca)



D Plexus lumbalis, left side (ca)

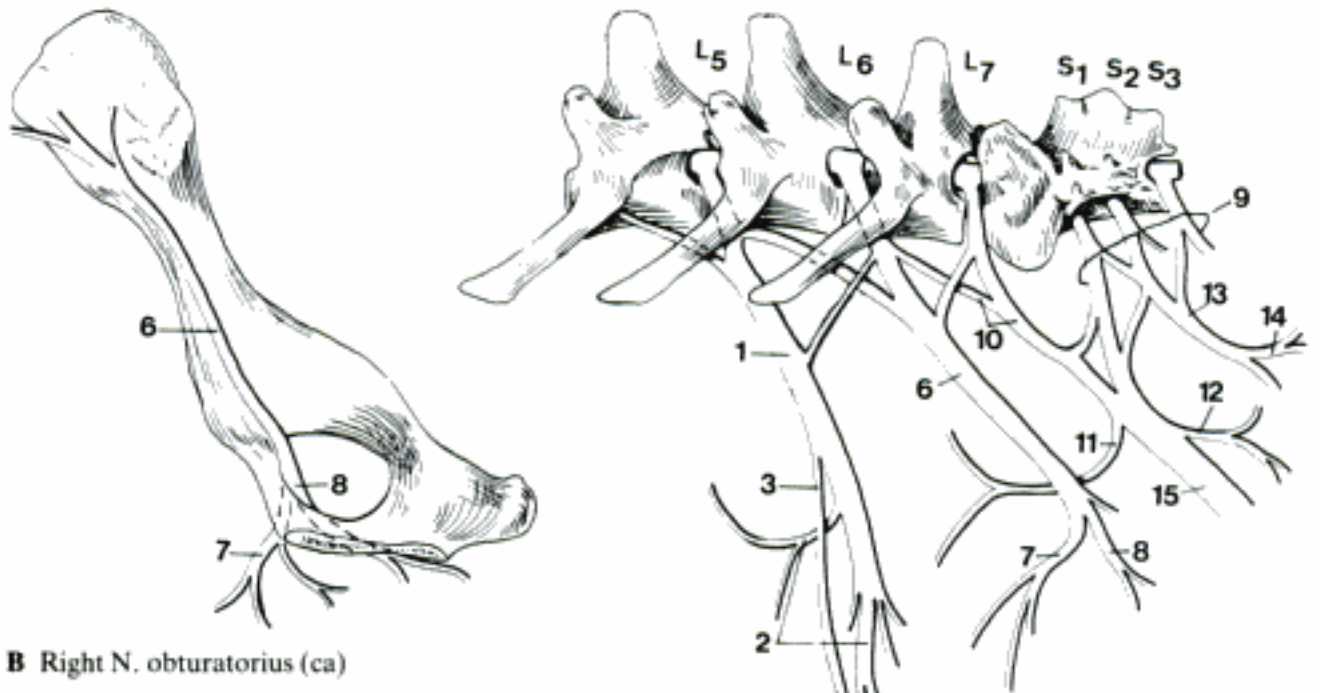


C Nn. clunium craniales and medii, left side (cq)



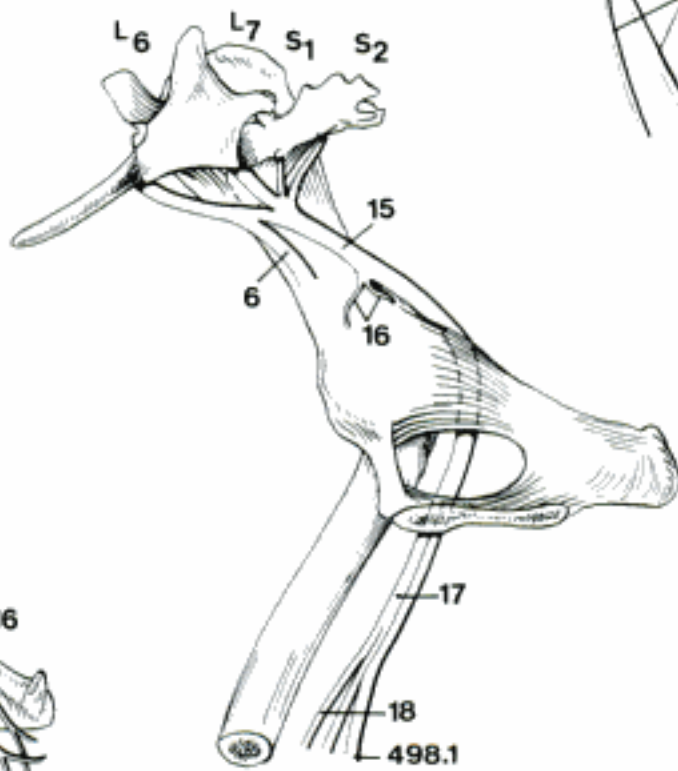
E Plexus lumbalis, left side (bo)

Hidden page

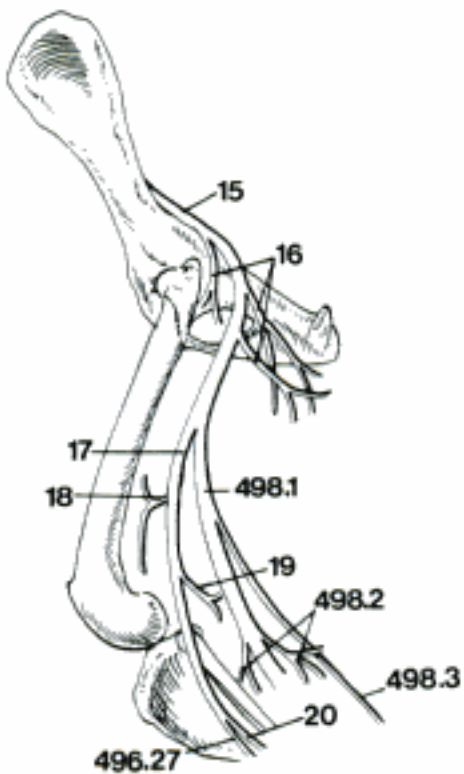


B Right N. obturatorius (ca)

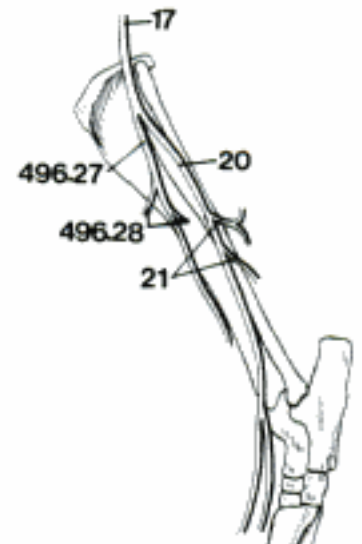
A Plexus lumbosacralis, left side (ca)



C Right N. ischiadicus (ca)



D Left Nn. ischiadicus, peroneus, and tibialis (ca)



E Left N. peroneus (ca)

CARNIVORA, SUS

- 1 *N. digitalis dorsalis II abaxialis*. Abaxial dorsal digital nerve II. A B
- 2 *N. digitalis dorsalis communis II*. Dorsal common digital nerve II. A B
- 3 *N. digitalis dorsalis proprius II axialis*. Axial dorsal proper digital nerve II. A B
- 4 *N. digitalis dorsalis proprius III abaxialis*. Abaxial dorsal proper digital nerve III. A B
- 5 *N. digitalis dorsalis communis III*. Dorsal common digital nerve III. A B
- 6 *N. digitalis dorsalis proprius III axialis*. Axial dorsal proper digital nerve III. A B
- 7 *N. digitalis dorsalis proprius IV axialis*. Axial dorsal proper digital nerve IV. A B
- 8 *N. digitalis dorsalis communis IV*. Dorsal common digital nerve IV. A B
- 9 *N. digitalis dorsalis proprius IV abaxialis*. Abaxial dorsal proper digital nerve IV. A B
- 10 *N. digitalis dorsalis proprius V axialis*. Axial dorsal proper digital nerve V. A B
- 11 *N. digitalis dorsalis V abaxialis*. Abaxial dorsal digital nerve V. A B

RUMINANTIA

- 12 *N. digitalis dorsalis communis II*. C
- 13 *Rami cutanei*. Cutaneous branches. C
- 14 *N. digitalis dorsalis proprius II axialis*. C
- 15 *N. digitalis dorsalis proprius III abaxialis*. C
- 16 *N. digitalis dorsalis communis III*. C
- 17 *Rami cutanei*. Cutaneous branches. C
- 18 *Ramus communicans cum n. metatarseo dorsali III*. Branch communicating with the dorsal metatarsal nerve III. C
- 19 *N. digitalis dorsalis proprius III axialis*. C
- 20 *N. digitalis dorsalis proprius IV axialis*. C
- 21 *N. digitalis dorsalis communis IV*. C

- 22 *Rami cutanei*. Cutaneous branches. C
- 23 *N. digitalis dorsalis proprius IV abaxialis*. C
- 24 *N. digitalis dorsalis proprius V axialis*. C

EQUUS

- 25 *Ramus dorsalis*. Dorsal branch. D
- 26 *Ramus lateralis*. Lateral branch. D

TERMINI COMMUNES

- 27 **N. peroneus [peronaeus, fibularis] profundus**. Deep peroneal nerve. A B C D, 495 D E

- 28 *Rami musculares*. Muscular branches to dorsolateral muscles of the crus. 495 E

CARNIVORA, SUS

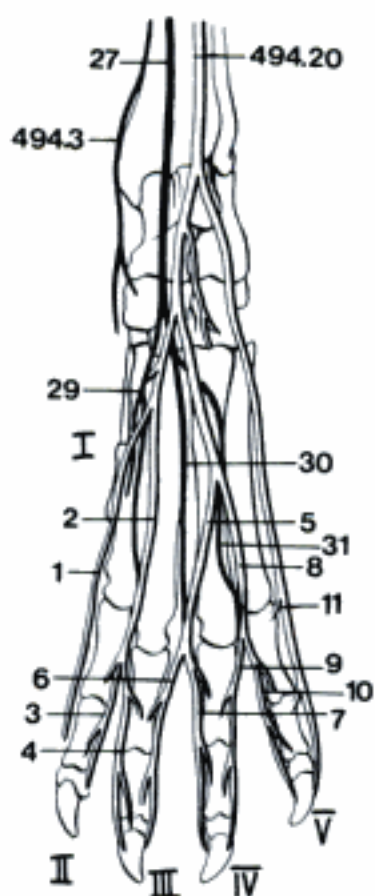
- 29 *N. metatarseus dorsalis II* (Car). Dorsal metatarsal nerve II. A
- 30 *N. metatarseus dorsalis III*. Dorsal metatarsal nerve III. A B
- 31 *N. metatarseus dorsalis IV* (Car). Dorsal metatarsal nerve IV. A

RUMINANTIA

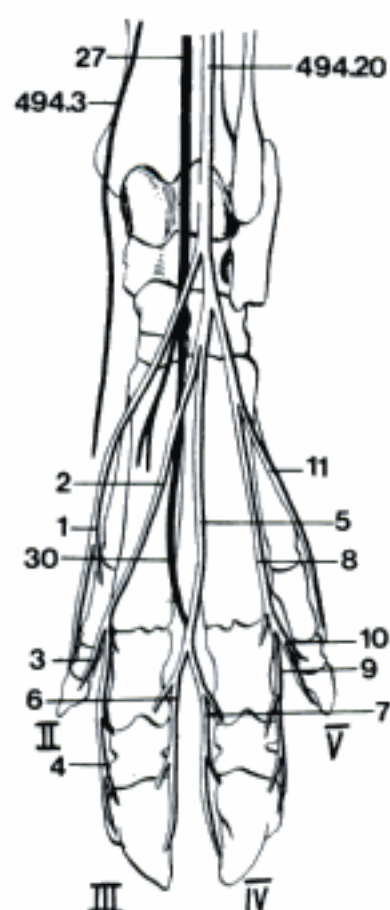
- 32 *N. metatarseus dorsalis III*. C
- 33 *Ramus communicans cum n. digitali plantari proprio III axiali*. Branch communicating with the axial plantar proper digital nerve III, traverses the interdigital space. C
- 34 *Ramus communicans cum n. digitali plantari proprio IV axiali*. Communicating branch to the axial plantar proper digital nerve IV, traverses the interdigital space. C

EQUUS

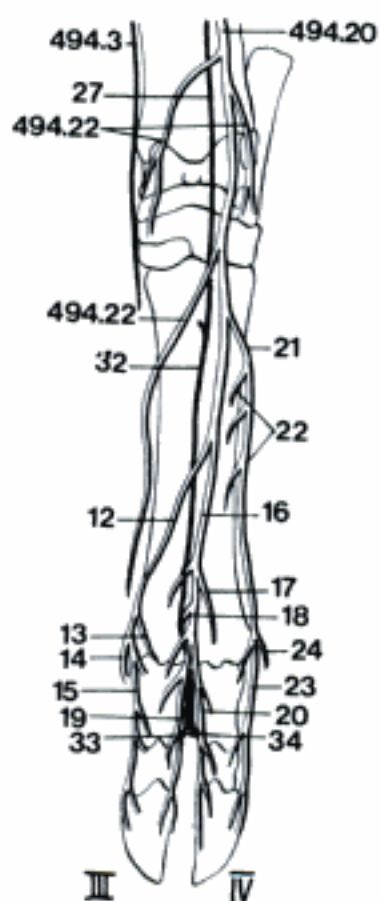
- 35 *N. metatarseus dorsalis II*. D
- 36 *N. digitalis dorsalis III medialis*. Medial dorsal digital nerve III. D
- 37 *N. metatarseus dorsalis III*. D
- 38 *N. digitalis dorsalis III lateralis*. Lateral dorsal digital nerve III. D



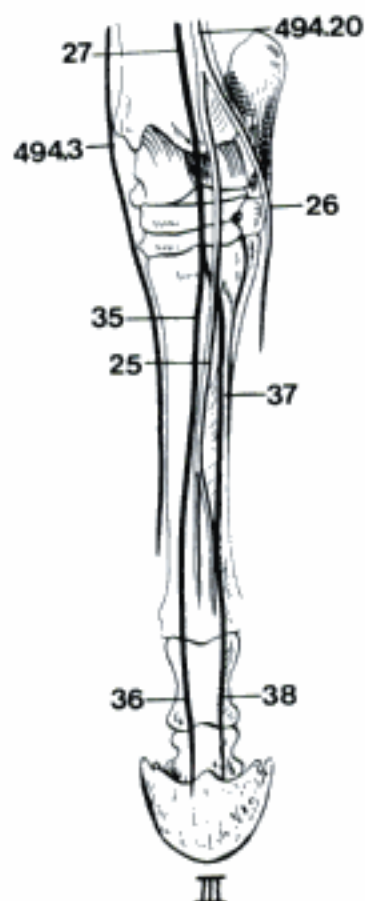
A Nn. peronei superficialis and profundus – left pes, dorsal aspect (ca)



B Nn. peronei superficialis and profundus – left pes, dorsal aspect (su)



C Nn. peronei superficialis and profundus – left pes, dorsal aspect (bo)



D Nn. peronei superficialis and profundus – left pes, dorsal aspect (eq)

TERMINI COMMUNES

- 1 *N. tibialis*. Tibial nerve, runs parallel to *N. peroneus communis*, then dips between the two heads of *M. gastrocnemius* and runs between the deep digital flexor muscles and *Tendo calcaneus communis*. A B C D, 495 C D
- 2 *Rami musculares*. Muscular branches, to the caudal muscles of the crus. 495 D
- 3 *N. cutaneus surae caudalis*. A B C D
- 4 *Rami cutanei* [*Ramus cutaneus tarsalis medialis, eq.*]. Cutaneous branches [medial tarsal cutaneous branch, eq]. D

CARNIVORA, SUS

- 5 *N. plantaris medialis*. Medial plantar nerve. A B
- 6 *N. digitalis plantaris II abaxialis*. A B
- 7 *N. digitalis plantaris communis II*. A B
- 8 *N. digitalis plantaris proprius II axialis*. A B
- 9 *N. digitalis plantaris proprius III abaxialis*. A B
- 10 *N. digitalis plantaris communis III*. A B
- 11 *Ramus communicans cum n. digitali plantari communi IV (su)*. Branch communicating with the plantar common digital nerve IV. B
- 12 *N. digitalis plantaris proprius III axialis*. A B
- 13 *N. digitalis plantaris proprius IV axialis*. A B
- 14 *N. digitalis plantaris communis IV (Car)*. A
- 15 *N. digitalis plantaris proprius IV abaxialis (Car)*. A
- 16 *N. digitalis plantaris proprius V axialis (Car)*. A

RUMINANTIA

- 17 *N. plantaris medialis*. Runs in the groove between *M. interosseus medius* and the digital flexor tendons. C
- 18 *N. digitalis plantaris communis II*. C
- 19 *N. digitalis plantaris proprius II*. C
- 20 *N. digitalis plantaris proprius III abaxialis*. C

21 *Ramus communicans cum n. digitali dorsali proprio III abaxiali*. Branch communicating with the abaxial proper dorsal digital nerve III. C

22 *N. digitalis plantaris communis III*. C

23 *N. digitalis plantaris proprius III axialis*. C

24 *N. digitalis plantaris proprius IV axialis*. C

EQUUS

25 *N. plantaris medialis* [*N. digitalis plantaris communis II*]. Runs in the groove between *interosseus medius* and the digital flexor tendons. D

26 *Ramus communicans*. Branch communicating with *N. plantaris lateralis*, crosses flexors superficially. D

27 *N. digitalis plantaris [proprius] medialis*. Medial plantar [proper] digital nerve. D

28 *Ramus dorsalis*. Dorsal branch. D

CARNIVORA

29 *N. plantaris lateralis*. Lateral plantar nerve, gives branches to the skin. A

30 *Ramus profundus*. Deep branch, trunk of *Nn. metatarsi plantares*, supplies the *Mm. interossei*. A

31 *Nn. metatarsi plantares*. Plantar metatarsal nerves (II, III, IV). A

32 *N. digitalis plantaris V abaxialis*. Abaxial plantar digital nerve V. A

SUS

33 *N. plantaris lateralis*. B

34 *Ramus profundus*. Deep branch, supplies the *Mm. interossei*.

35 *N. digitalis plantaris communis IV*. B

36 *N. digitalis plantaris proprius IV abaxialis*. B

37 *N. digitalis plantaris proprius V axialis*. B

38 *N. digitalis plantaris V abaxialis*. B

Hidden page

RUMINANTIA

- 1 *N. plantaris lateralis*. Gives branches to the skin. A
- 2 *Ramus profundus*. Deep branch, to *M. interosseus medius*. A
- 3 *N. digitalis plantaris communis IV*. Continuation of *N. plantaris lateralis*. A
- 4 *N. digitalis plantaris proprius IV abaxialis*. A
- 5 *Ramus communicans cum n. digitali dorsali proprio IV abaxiali*. A
- 6 *N. digitalis plantaris proprius V*. A

EQUUS

- 7 *N. plantaris lateralis*. [*N. digitalis plantaris communis III*]. Runs in the groove between *M. interosseus medius* and the digital flexor tendons. B
- 8 *Ramus profundus*. Deep branch, supplies the *Mm. interossei*. B
- 9 *Nn. metatarsi plantares*. Plantar metatarsal nerves (II, III), course between *M. interosseus medius* and the corresponding splint bone. B
- 10 *N. digitalis plantaris [proprius] lateralis*. B
- 11 *Ramus dorsalis*. Dorsal branch. B

TERMINI COMMUNES

- 12 **Ramus musculi coccygei**. Branch for the coccygeus. Originates in ca from *Nn. sacrales caudales*, in su and eq combined with *Nn. rectales caudales*, in bo usually combined with *Ramus m. levatoris ani* and *N. pudendus* or *N. rectalis caudalis*. C
- 13 **Ramus musculi levatoris ani**. Branch for *m. levator ani*, has the same relationships as *Ramus musculi coccygei* (see 12). C
- 14 **N. pudendus**. Pudendal nerve, arises from S1–S2 (S3) (ca), S2–S3 (fe, su), S2–S4 (Ru), S3–S4 (eq), carries motor, sensor, and parasympathetic fibers. C
- 15 *Rami cutanei*. Proximal and distal cutaneous branches in su and Ru, innervate approximately the same area as *N. cutaneus femoralis caudalis* of other species, the distal also supplies the *N. perinealis superficialis* in su and Ru. C
- 16 *Ramus communicans cum n. cutaneo femoris caudali*. C

- 17 *N. perinealis profundus*. Deep perineal nerve, arises by common trunk with *N. perinealis superficialis* in eq, independently as a series of branches in ca. Innervates perineal muscles. C
- 18 *N. perinealis superficialis*. Arises together with *N. perinealis profundus* in eq, is supplied by the distal cutaneous branch of *N. pudendus* in su and Ru. C
- 19 *Nn. scrotales dorsales*. Dorsal scrotal nerves. C
- 20 *Nn. labiales*. Labial nerves.
- 21 *Ramus preputialis [prae-] et scrotalis*. Preputial and scrotal branch. Terminal branch of *N. pudendus* in bo and eq, represented by a series of branches of *N. dorsalis penis* in other species. C
- 22 *Ramus mammarius*. Mammary branch, for the *Mammae inguinales*.
- 23 *N. dorsalis penis*. Runs on the dorsal surface of the penis to *Glans penis* and *Lamina interna preputii*. C
- 24 *N. dorsalis clitoridis*. Dorsal nerve of the clitoris.
- 25 **Nn. rectales caudales**. Caudal rectal nerves, one or two from S3–S5. In ca the single nerve arises from *N. pudendus*. D E
- 26 *Ramus communicans cum n. pudendo*. E
- 27 *Rami musculares*. Muscular branches, supply *Mm. sphincter ani externus*, *retractor penis (clitoridis)*, *bulbospongiosus*, in eq a part of *M. semimembranosus*. D E
- 28 *Rami cutanei*. Cutaneous branches, supply the skin around the anus. D E
- 29 **Nn. caudales [coccygei]**. Caudal [coccygeal] nerves, 5–8 depending on species. D
- 30 *Rami dorsales*. Dorsal branches. Form *Plexus caudalis dorsalis*. D
- 31 *Plexus caudalis [coccygeus] dorsalis*. Gives off branches for the dorsal muscles of the tail and the corresponding skin. D F
- 32 *Rami ventrales*. Form *Plexus caudalis ventralis*. D
- 33 *Plexus caudalis [coccygeus] ventralis*. Gives off branches to the ventral muscles of the tail and corresponding skin. D F

Hidden page

- 1 **SYSTEMA NERVOSUM AUTONOMICUM.** Autonomic nervous system.
- 2 **Plexus aorticus thoracicus.** Thoracic aortic plexus, network surrounding Aorta ascendens, Arcus aortae, and Aorta thoracica, with branches of Truncus sympathicus and parasympathetic fibers from N. vagus. A
- 3 **Plexus cardiacus.** Cardiac plexus, network of sympathetic fibers from Ganglia cervicothoracicum, cervicale medium, and thoracica and parasympathetic fibers from N. vagus.
- 4 **Ganglia cardiaca.** Cardiac ganglia. A
- 5 **Plexus esophageus [oesophageus].** Esophageal plexus, with sympathetic and parasympathetic fibers (N. vagus), lies on the thoracic part of the esophagus. A
- 6 **Rami pulmonales.** Pulmonary branches. A
- 7 **Plexus pulmonalis.** Pulmonary plexus, contains sympathetic and parasympathetic fibers. A
- 8 **Plexus aorticus abdominalis.** Abdominal aortic plexus, on Aorta abdominalis.
- 9 **Plexus celiacus [coeliacus].** Celiac plexus, network on A. celiaca. B C
- 10 **Ganglia celiaca [coeliaca].** Celiac ganglia, paired, on both sides of A. celiaca, connected by communicating branches. B C
- 11 **Plexus mesentericus cranialis.** Cranial mesenteric plexus. B C
- 12 **Ganglion mesentericum craniale.** Cranial mesenteric ganglion, impaired, located at the origin of A. mesenterica cranialis. B C
- 13 **Plexus intermesentericus.** Intermesenteric plexus, connecting Plexus mesentericus cranialis and caudalis. B C
- 14 **Plexus mesentericus caudalis.** Caudal mesenteric plexus, network surrounding A. mesenterica caudalis. B C
- 15 **Ganglion mesentericum caudale.** Caudal mesenteric ganglion, unpaired, located at the origin of A. mesenterica caudalis. B C
- 16 **Ganglia aorticorenalia.** Aorticorenal ganglia, paired, located at the level of A. renalis. B C
- 17 **Ganglia phrenica.** Phrenic ganglia (su, Ru), in a network that surrounds A. phrenica caudalis. B
- 18 **Plexus hepaticus.** Hepatic plexus, from Plexus celiacus, accompanies A. hepatica to the liver. D
- 19 **Plexus lienalis.** Splenic plexus, from Plexus celiacus, accompanies A. lienalis. D
- 20 **Plexus gastrici.** Gastric plexuses. Fibers from Plexus celiacus accompanying the branches of gastric arteries. D
- 21 **Plexus ruminalis dexter.** Right ruminal plexus, from Plexus celiacus, contains also fibers from N. vagus, esp. the dorsal trunk. E
- 22 **Plexus ruminalis sinister.** Left ruminal plexus, from Plexus celiacus, contains also fibers from N. vagus, esp. the dorsal trunk, arising on the right side, passing to the left in Sulcus cranialis ruminis. E
- 23 **Plexus reticularis.** Reticular plexus. E
- 24 **Plexus pancreaticus.** Pancreatic plexus, from Plexus celiacus, accompanying pancreatic arteries. D
- 25 **Plexus adrenalis [suprarenalis].** Adrenal [suprarenal] plexus, formed by Nn. splanchnici and Plexus celiacus, contains preganglionic fibers for the medulla.
- 26 **Plexus renalis.** Renal plexus, surrounds A. renalis with fibers from Plexus mesentericus cranialis and Nn. splanchnici. B C
- 27 **Ganglia renalia.** Renal ganglia, may be observed in the Plexus renalis.
- 28 **Plexus uretericus.** Ureteric plexus, accompanies the ureters with fibers from Plexus renalis and aorticus abdominalis.

Hidden page

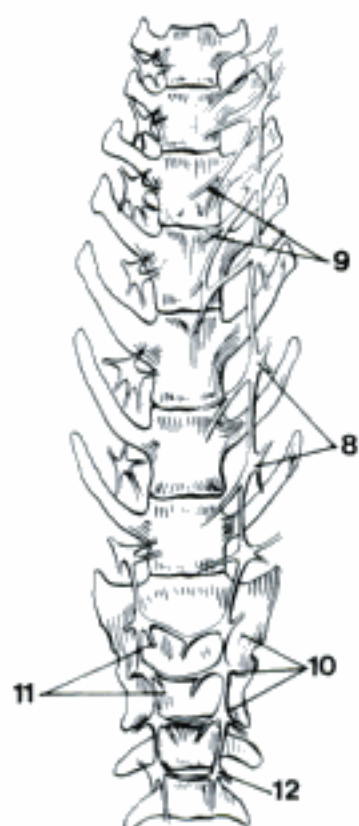
- 1 *Plexus testicularis*. Testicular plexus, receives fibers from Plexus abdominalis aorticus, Plexus mesentericus caudalis, and Nn. splanchnici lumbales, innervates testis and epididymis. A
- 2 *Plexus ovaricus*. Ovarian plexus, receives fibers from Plexus aorticus abdominalis, Plexus mesentericus caudalis, and Nn. splanchnici lumbales, accompanies A. ovarica and can be divided into ovarian, tubal, and cranial uterine plexuses. B
- 3 *Plexus colicus*. Colic plexus, occurs in eq. It connects the Plexus mesentericus cranialis and caudalis by passing through the dorsal part of the Mesenterium. Its connection with Rami celiaci trunci vagalis dorsalis provides a pathway for parasympathetic fibers to Colon descendens. It follows the A. colica sinistra. C
- 4 *Plexus rectalis cranialis*. Cranial rectal plexus, follows A. rectalis cranialis. C
- 5 *Plexus entericus*. Enteric plexus, general term for the autonomic nervous network supplying the intestinal wall. D
- 6 *Plexus subserosus*. Subserosal plexus, network deep to the serosa of the intestine. D
- 7 *Plexus myentericus*. Myenteric or Auerbach's plexus, between the two muscular layers of the intestinal wall; provided with microganglia. D
- 8 *Plexus submucosus*. Submucosal or Meissner's plexus, located in the submucosa; provided with microganglia. D
- 9 *Plexus iliaci*. Iliac plexuses, continuation of Plexus aorticus abdominalis, following the right and left external and internal iliac arteries. C
- 10 *Plexus femoralis*. Femoral plexus, continuation of Plexus iliacus on A. femoralis. C
- 11 *N. hypogastricus*. Hypogastric nerve (right and left), arises from Plexus mesentericus caudalis, runs to Plexus pelvinus. E F
- 12 *Plexus pelvinus*. Pelvic plexus, contains sympathetic fibers from N. hypogastricus and sacral parasympathetic fibers, is located at the lateral wall of pelvis, extraperitoneally, contains pelvic ganglia. E F
- 13 *Plexus rectales medii*. Middle rectal plexuses, continuations of Plexus pelvinus into the retroperitoneal portion of the rectum along A. rectalis media. E
- 14 *Plexus rectales caudales*. Caudal rectal plexuses, continuations of Plexus pelvinus to the caudal portion of the rectum along A. rectalis caudalis. E
- 15 *Plexus prostaticus*. Prostatic plexus, located chiefly on the dorsal surface of the prostate body, extends along the pelvic part of urethra. E
- 16 *Plexus deferentialis*. Deferential plexus, from Plexus pelvinus, accompanying the Ductus deferens. E
- 17 *Plexus uterovaginalis*. Uterovaginal plexus, basically located in the parametrium, sending branches to vagina and uterus. F
- 18 *Nn. vaginales*. Vaginal nerves. F
- 19 *Plexus vesicales*. Vesical plexuses. The cranial one accompanies Aa. vesicales craniales in Lig. versicae laterale to Vertex vesicae, the caudal one extends to Corpus and Cervix vesicae. E
- 20 *Nn. corporis cavernosi penis*. Nerves of Corpus cavernosum penis, from Plexus prostaticus. E
- 21 *Nn. corporis cavernosi clitoridis*. Nerves of Corpus cavernosum clitoridis, from Plexus uterovaginalis. F

Hidden page

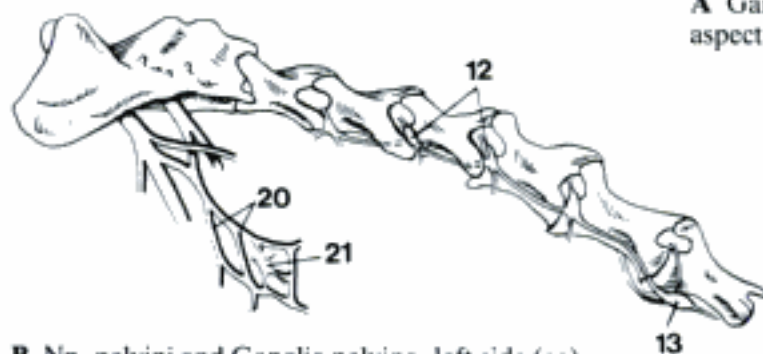
- 1 **Pars sympathica.** Sympathetic part of Systema nervosum autonomicum. Its origin in Medulla spinalis is between (T1) T2 and L2–4, its extent into the lumbar part depending on species.
- 2 *Truncus sympathicus.* Sympathetic trunk, ganglionic chain ventrolateral to the vertebral column from the first thoracic to the 4th–7th caudal vertebra, only the cervical part runs with N. vagus in the Vagina carotica. B
- 3 *Ganglia trunci sympathici.* Sympathetic trunk ganglia. In these ganglia, composed of multipolar nerve cells, are synapses of preganglionic with postganglionic neurons. A B
- 4 *Ganglia intermedia.* Intermediate ganglia, most commonly found in the Rami communicantes of the lumbar region and in the Rami interganglionares. A
- 5 *Rami interganglionares.* Interganglionic branches, connect the Ganglia trunci sympathici of the homolateral chain, in some cases also the paired ganglia. B
- 6 *Rami communicantes.* Communicating branches, connections between Truncus sympathicus and Nn. spinales, contain preganglionic fibers from Medulla spinalis or postganglionic fibers to the periphery. A B
- 7 *Ganglion cervicale craniale.* Cranial cervical ganglion, most cranial condensation of nerve cells in which preganglionic sympathetic neurons synapse with postganglionic, located close to A. carotis interna, between it and A. occipitalis. C
- 8 *N. jugularis.* Jugular nerve. Branch communicating with Nn. glossopharyngeus and vagus. C
- 9 *N. caroticus internus.* Internal carotid nerve, forms Plexus caroticus internus. C
- 10 *Plexus caroticus internus.* Internal carotid plexus, in the wall of A. carotis interna, gives off N. petrosus profundus and branches to the ear and the eye. C
- 11 *Nn. carotici externi.* External carotid nerves, descending branches to Plexus caroticus externus. C
- 12 *Plexus caroticus externus.* External carotid plexus, network surrounding the A. carotis externa. C
- 13 *Plexus caroticus communis.* Common carotid plexus, surrounds A. carotis communis. C
- 14 *Rami laryngopharyngei.* Laryngopharyngeal branches.
- 15 *Ganglion cervicale medium.* Middle cervical ganglion, inconstant in eq, located in the thoracic inlet. D
- 16 *N. cardiacus cervicalis.* Cervical cardiac nerve. D
- 17 *Ganglion cervicothoracicum [stellatum].* Cervicothoracic [stellate] ganglion, results from the fusion of the Ganglion cervicale caudale with one or more Ganglia thoracica, lateral to M. longus colli in the first intercostal space. D
- 18 *Ansa subclavia.* Loop around A. subclavia. D
- 19 *Plexus subclavius.* Subclavian plexus, network in the wall of A. subclavia. D
- 20 *N. vertebralis.* Vertebral nerve, connection of nerve fibers from Ganglion cervicothoracicum to C8–C2, accompanies A. vertebralis into the vertebral canal. Sometimes a vertebral ganglion is present. D
- 21 *Plexus vertebralis.* Vertebral plexus, surrounds A. vertebralis. D
- 22 *Nn. cardiaci cervicales.* Cervical cardiac nerves, named according to the ganglion of origin, in this case they arise from Ganglion cervicale caudale. D

Hidden page

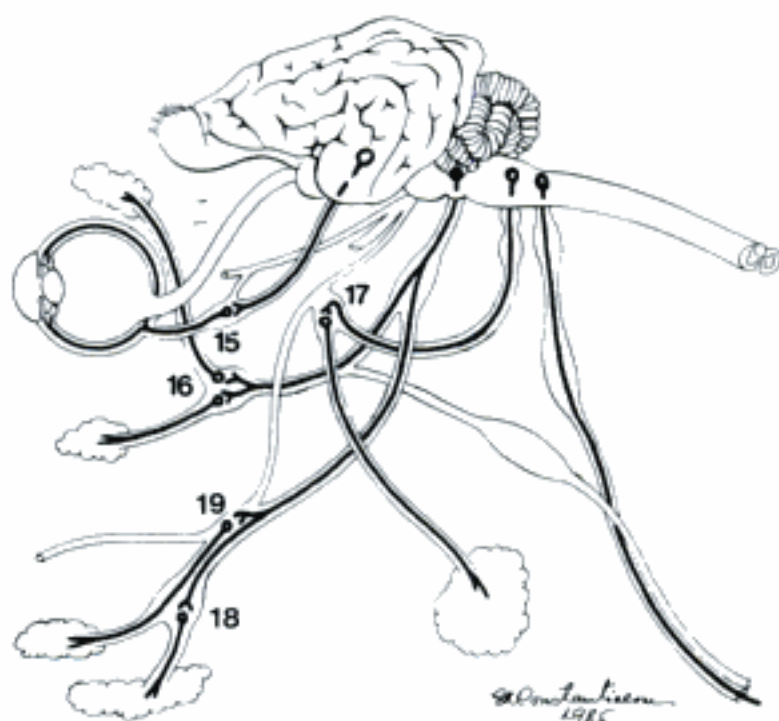
Hidden page



A Ganglia lumbalia, sacralia, and caudalia, ventral aspect (ca)

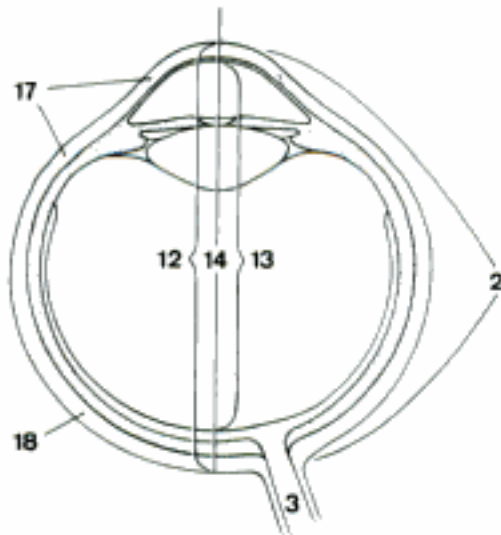


B Nn. pelvini and Ganglia pelvina, left side (ca)



C Parasympathetic ganglia of the head, left side (ca)

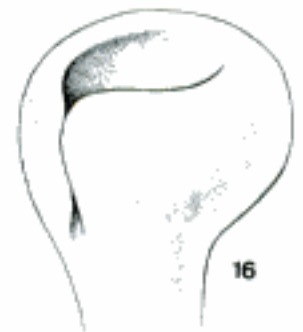- 1 **ORGANUM VISUS.** The organ of vision.
- 2 **OCULUS.** Eye. A
- 3 *N. opticus.* Optic nerve, actually a tract of the central nervous system enveloped by extensions of the meninges. Extends from the Chiasma opticum to the Bulbus oculi, radiates in the retina. A E
- 4 *Vagina externa n. optici.* External sheath of the optic nerve, extension of the dura mater. E
- 5 *Vagina interna n. optici.* Internal sheath of the optic nerve, extension of pia mater and arachnoidea, deep to the Vagina ext. n. optici. E
- 6 *Spatia intervaginalia.* Intervaginal spaces, the subarachnoid space and the capillary space between the vagina externa and interna surrounding the optic nerve. E
- 7 **Bulbus oculi.** Eyeball, comprising cornea and sclera and the structures and spaces enclosed. D
- 8 *Polus anterior.* Anterior pole, the highest point of the cornea. D
- 9 *Polus posterior.* Posterior pole, the highest point on the posterior hemisphere of the eyeball, opposite the anterior pole. D
- 10 *Equator [Aequator].* The largest circumference of the eyeball between anterior and posterior poles. D
- 11 *Meridiani.* Meridians, lines encircling the eyeball and passing through anterior and posterior poles. D
- 12 *Axis bulbi externus.* External axis of eyeball, line connecting anterior and posterior poles. A
- 13 *Axis bulbi internus.* Internal axis of eyeball, the segment of the external axis of the eyeball from the posterior surface of the cornea to the anterior surface of the retina. A
- 14 *Axis opticus.* Optic axis, line through the optical centers of cornea, lens and Corpus vitreum, usually coincident with the external axis of the eyeball connecting the two poles. A
- 15 *Vesicula ophthalmica (ont).* Ophthalmic vesicle, early primordium of the eye in the form of bilateral hollow outgrowths from diencephalon. B
- 16 *Caliculus ophthalmicus (ont).* Ophthalmic cup, later double-walled primordium of the eye developed by invagination of the ophthalmic vesicle. C
- 17 **Tunica fibrosa bulbi.** Fibrous coat of eyeball, the outer wall consisting of cornea and sclera. A
- 18 **Sclera.** The bluish white, protective layer covering the eyeball except for the anterior portion which is covered by the cornea. It consists of dense fibrous connective tissue. A E G
- 19 *Sulcus sclerae.* Scleral groove, the shallow groove at the junction of sclera and cornea. D
- 20 *Anulus sclerae.* Scleral ring, the circular ridge on the inner surface of the sclera near the Limbus corneae to which the ciliary muscle is attached. G
- 21 *Sinus venosus sclerae.* Venous sinus of the sclera, following the Limbus corneae and in communication with the spaces of the iridocorneal angle through which aqueous humor leaves the anterior chamber. G
- 22 *Plexus venosus sclerae.* Venous plexus of the sclera, formed by the often double or multiple Sinus venosus sclerae. G
- 23 *Lamina episcleralis.* Episcleral lamina, a thin layer of loose connective tissue on the external surface of the sclera between the latter and the Vagina bulbi. F
- 24 *Substantia propria sclerae.* Proper substance of the sclera, consisting mainly of interwoven collagenous and some elastic fibers. G
- 25 *Lamina fusca sclerae.* Dark lamina of the sclera, the innermost layer of the sclera consisting of less dense connective tissue and pigmented cells. E
- 26 *Area cribrosa sclerae.* Cribriform area of the sclera, the fine holes in the wall of the sclera through which the fiber bundles of the optic nerve leave the interior of the eyeball. F



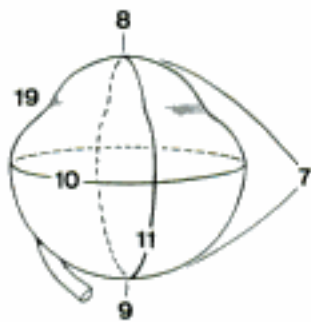
A Eyeball, meridional section, schematic (ca)



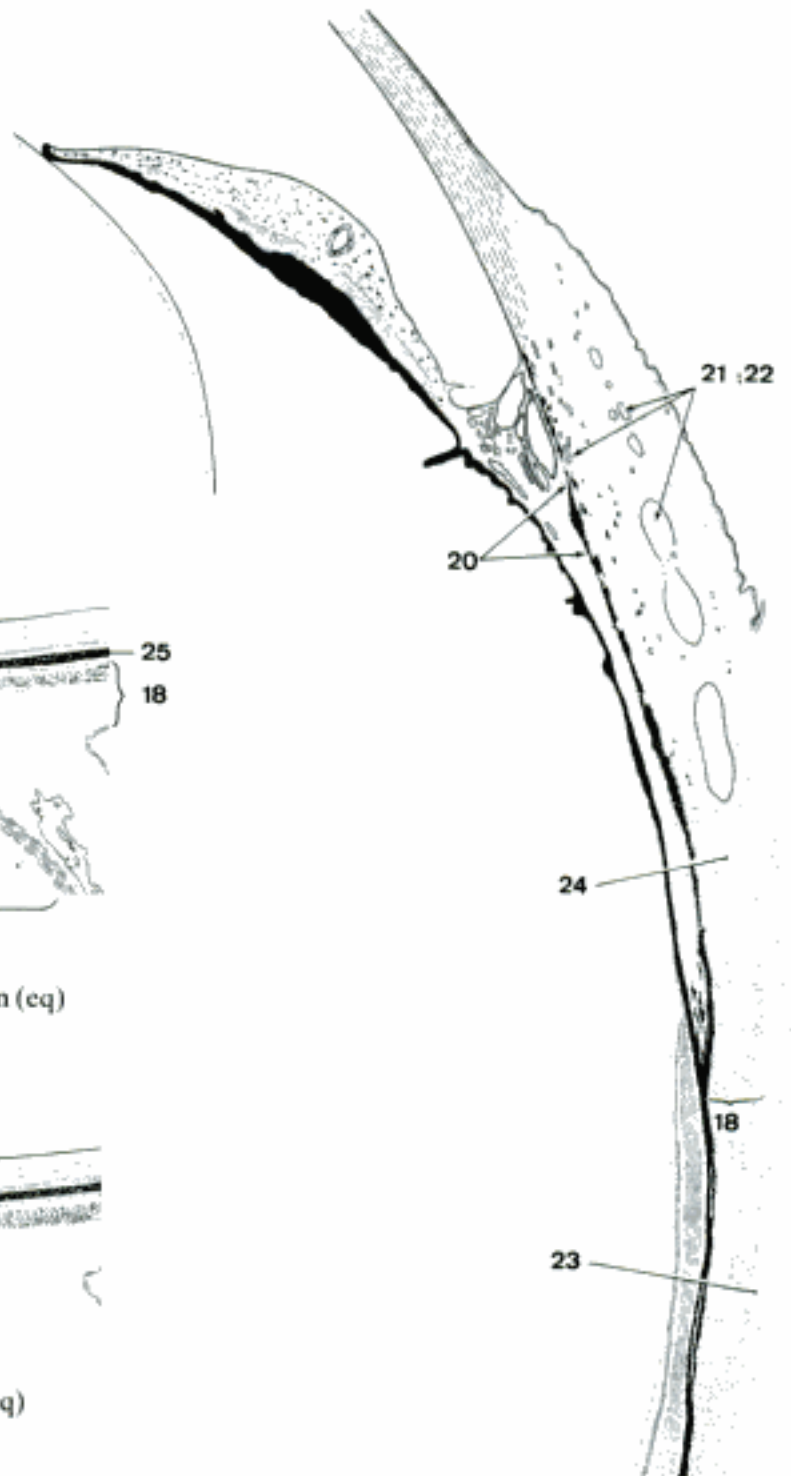B Head of an 18 day-old embryo, transverse section (ca)



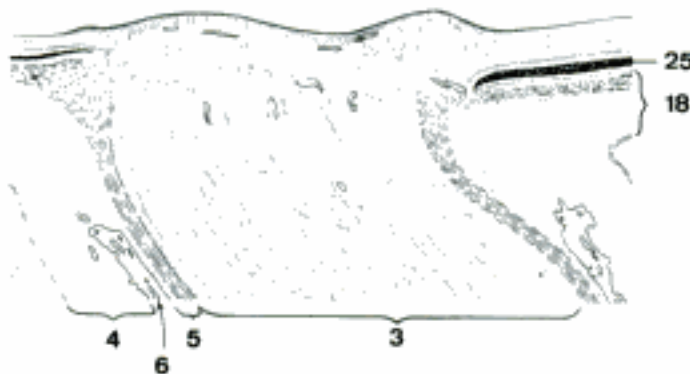C Caliculus ophthalmicus



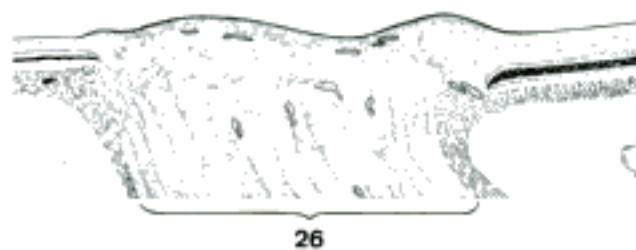
D Right eyeball, medial aspect (eq) (Sack and Habel)



G Sclera, iris, ciliary body, meridional section (fe)

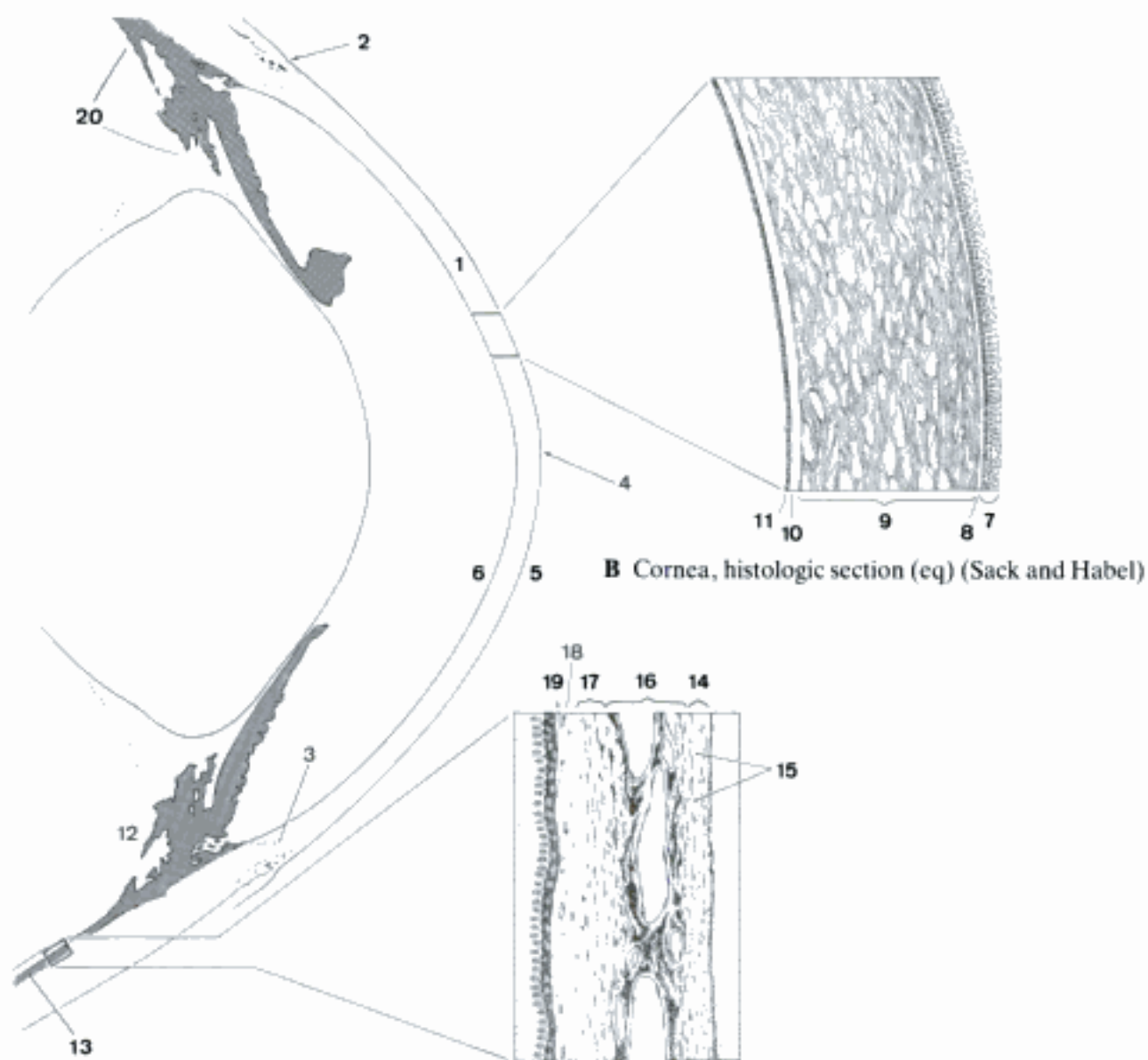


E Optic nerve and vaginae, histologic section (eq)



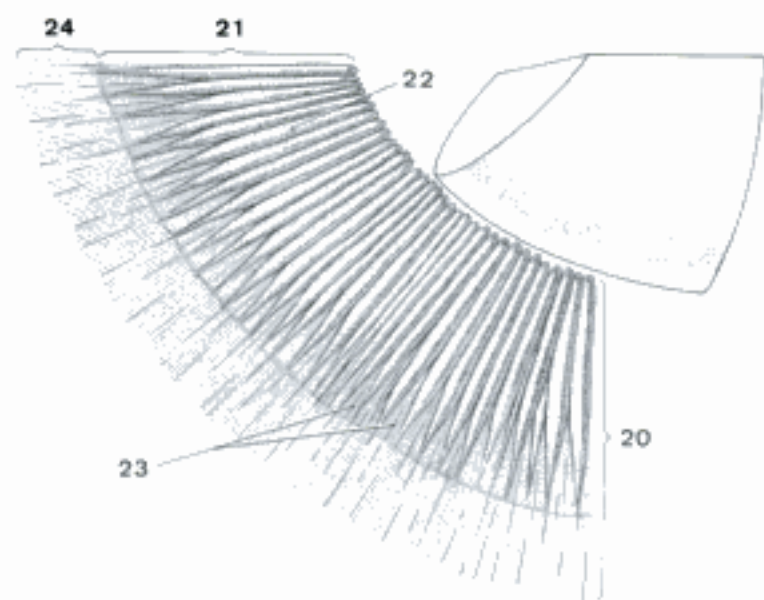
F Area cribrosa sclerae, histologic section (eq)

- 1 **Cornea.** Avascular translucent anterior wall of the eyeball, more strongly curved than the sclera. A
- 2 *Anulus conjunctivae.* Conjunctival ring, the junction of the anterior epithelium of the cornea with the epithelium of the conjunctiva. A
- 3 *Limbus corneae.* Corneal limbus, the edge of the cornea where it is continuous with the sclera. A
- 4 *Vertex corneae.* The highest part of the cornea. A
- 5 *Facies anterior.* Anterior surface of the cornea. A
- 6 *Facies posterior.* Posterior surface of the cornea. A
- 7 *Epithelium anterius corneae.* Anterior corneal epithelium, about 5–12 layers of cells which do not cornify and remain soft and nucleated. B
- 8 *Lamina limitans anterior.* Anterior limiting membrane; thin, nearly homogeneous, not very distinct; between anterior epithelium and Substantia propria. B
- 9 *Substantia propria corneae.* Proper substance of cornea, connective tissue lamellae of interweaving fibrils; the cementing substance contains flat cells connected by cytoplasmic processes. B
- 10 *Lamina limitans posterior.* Posterior limiting membrane; fairly thick, homogeneous; between Substantia propria and posterior epithelium. B
- 11 *Epithelium posterius corneae.* Posterior corneal epithelium, single layer of flat cells on the posterior surface of the cornea in contact with the aqueous humor. B
- 12 **Tunica vasculosa bulbi.** Vascular tunic of the eyeball, consisting of Choroidea, Corpus ciliare and iris. A
- 13 **Choroidea [Chorioidea].** Choroid, part of the Tunica vasculosa bulbi between sclera and Pars optica retinae. A C
- 14 *Lamina suprachoroidea [-chorioidea].* Suprachoroid layer, outermost layer of the choroid, composed of elastic fibers and pigmented connective tissue cells that form loosely connected lamellae. C
- 15 *Spatium perichoroideale [chorioideale].* Perichoroidal space, interlamellar spaces in the Lamina suprachoroidea, contain lymph, blood vessels, and nerves. C
- 16 *Lamina vasculosa.* Vascular layer, thickest layer of the choroid containing the branches of Aa. ciliares posteriores longae et breves and of Vv. vorticosae. C
- 17 *Tapetum lucidum.* In Ru and eq fibrous, in Car cellular, avascular layer deep to the Lamina vasculosa that gives the luster to the eyes of some animals. C
- 18 *Lamina choroideocapillaris [chorioideo-].* Choriocapillary layer on the inner surface of Lamina vasculosa or Tapetum lucidum. C
- 19 *Lamina basalis.* Basal layer, transparent innermost layer of the choroid lying next to the Stratum pigmentosum. C
- 20 **Corpus ciliare.** Ciliary body, thick annular part of the Tunica vasculosa between choroid and iris. A D
- 21 *Corona ciliaris.* Ciliary crown, raised portion of the ciliary body adjacent to the iris, bearing the ciliary processes. D
- 22 *Processus ciliares.* Ciliary processes, radially arranged fibroelastic ridges on the inner surface of the Corona ciliaris; they secrete the aqueous humor. D
- 23 *Plicae ciliares.* Ciliary folds, microscopic folds on and between the ciliary processes. D
- 24 *Orbiculus ciliaris.* Ciliary ring, peripheral flat portion of the ciliary body continuous with the choroid. D
- 25 *M. ciliaris.* Ciliary muscle, ring of smooth muscle fibers in the ciliary body; it functions in the accommodation of the lens. E
- 26 *Fibrae meridionales.* Meridian fibers, forming the bulk of the ciliary muscle. E
- 27 *Fibrae circulares.* Circular fibers, parallel to the free margin of the iris and posterior to the Fibrae meridionales. E
- 28 *Lamina basalis.* Basal layer, the innermost layer of the ciliary body, lying next to the Stratum pigmentosum. E

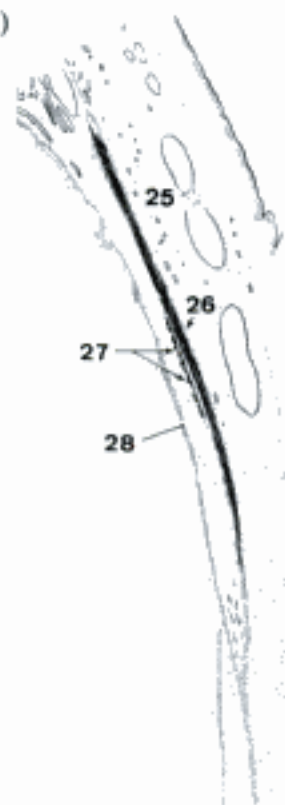


A Anterior part of the eyeball, meridional section (eq) (Sack and Habel)

C Chorioidea, histologic section (eq)

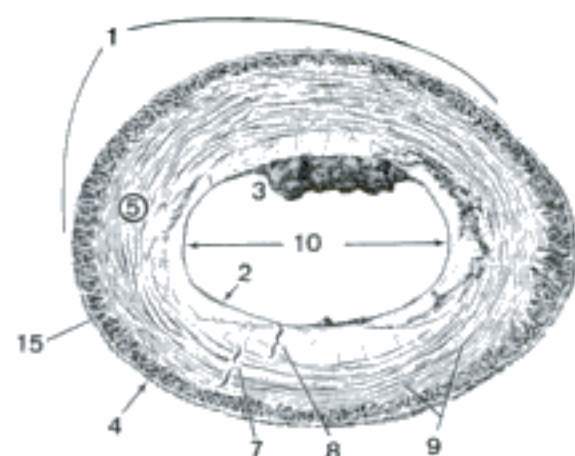


D Internal surface of ciliary body (eq) (Sack and Habel)

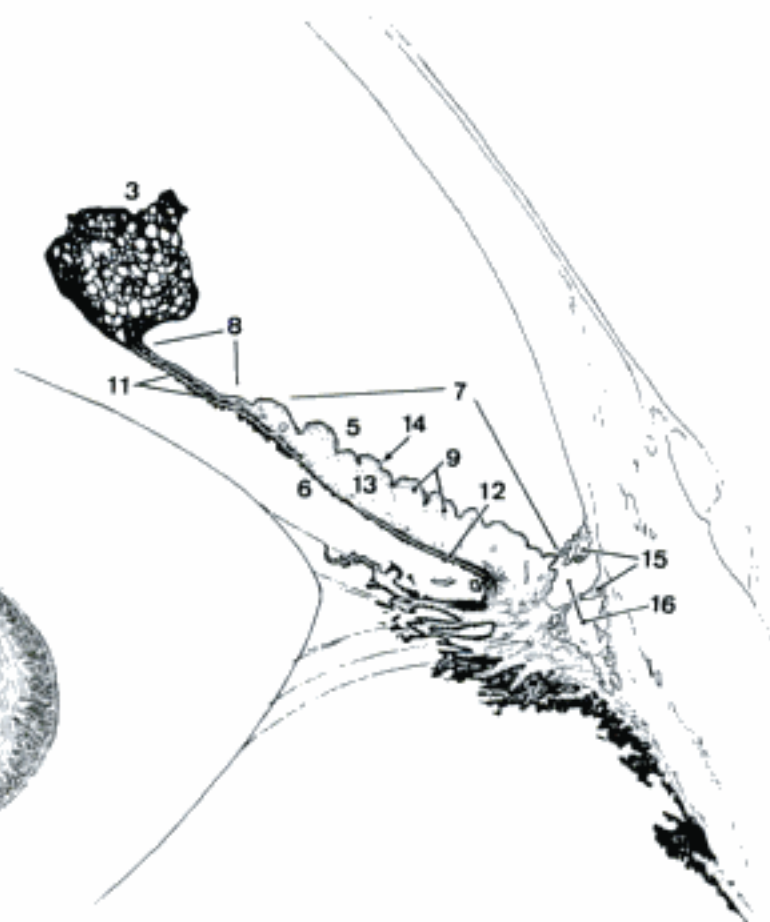


E Ciliary body, histologic section (fe)

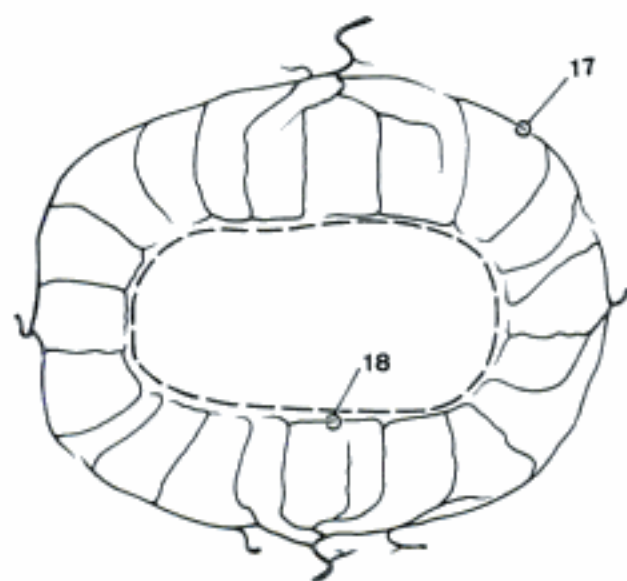
- 1 **Iris.** Contractile diaphragm with a central opening (pupil) anterior to the lens; it is the most anterior part of the Tunica vasculosa bulbi and regulates the amount of light admitted into the fundus of the eye. A
- 2 *Margo pupillaris.* Pupillary margin, central margin of the iris surrounding the pupil. A
- 3 *Granula iridica.* Iridic granules, vascular extensions of the stroma of the iris covered on the posterior surface with pigmented epithelium of the Pars iridica retinae. A B
- 4 *Margo ciliaris.* Ciliary margin, the periphery of the iris continuous with the ciliary body and attached to the inside of the Limbus corneae by the Lig. pectinatum anguli iridocornealis. A
- 5 *Facies anterior.* Anterior surface, facing the cornea. A B
- 6 *Facies posterior.* Posterior surface, facing the lens. B
- 7 *Anulus iridis major.* Major iridic ring, the wider peripheral portion of the iris that has a relatively uneven and folded anterior surface. A B
- 8 *Anulus iridis minor.* Minor iridic ring, the narrow central portion of the iris that has a relatively smooth anterior surface. A B
- 9 *Plicae iridis.* Folds of the iris, present on the anterior surface; they may be permanent or temporary; some are radially arranged while others run parallel to the pupillary margin. A B
- 10 *Pupilla.* Pupil opening, surrounded by the iris. A
- 11 *M. sphincter pupillae.* Band of smooth muscle fibers in the Anulus iridis minor that constricts the pupil. B
- 12 *M. dilator pupillae.* Nearly radially oriented smooth muscle fibers near the posterior surface of the iris that open the pupil. B
- 13 *Stroma iridis.* Stroma of the iris, composed mainly of branching interconnected pigment cells and predominantly radially arranged collagenous fibers; contains the vessels of the iris. B
- 14 *Epithelium pigmentosum.* Pigmented epithelium, simple squamous epithelium covering the iridic stroma anteriorly and continuous in the iridocorneal angle with the posterior epithelium of the cornea, provides the specific color of the eyes. B
- 15 *Lig. pectinatum anguli iridocornealis.* Pectinate ligament of the iridocorneal angle, collagenous trabeculae covered with iridic epithelium; between the trabeculae are the Spatia anguli iridocornealis. A B
- 16 *Spatia anguli iridocornealis.* Spaces of the iridocorneal angle, epithelium lined spaces between the trabeculae that form the Lig. pectinatum through which the aqueous humor reaches the Plexus venosus sclerae. B
- 17 *Circulus arteriosus iridis major.* Major arterial ring of the iris near Margo ciliaris, formed by anastomosing branches of principally the Aa. ciliares posteriores longae; the ring gives rise to radial branches that pass toward the pupil in the stroma of the iris. C
- 18 *Circulus arteriosus iridis minor.* Minor arterial ring of the iris, near the pupillary margin, often incomplete; formed by anastomoses of the radial branches of the Circulus arteriosus iridis major. C
- 19 *Membrana pupillaris (ont).* Pupillary membrane, a layer of mesenchyme temporarily covering the anterior surface of iris and pupillary portion of the fetal lens, permitting blood vessels to nourish the latter for a period of its development. D



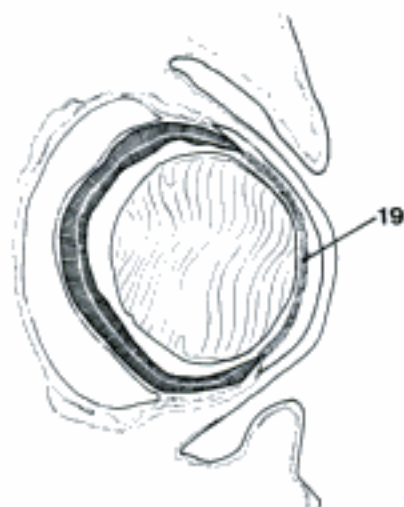
A Anterior surface of iris (eq)



B Iris, meridional section (eq)

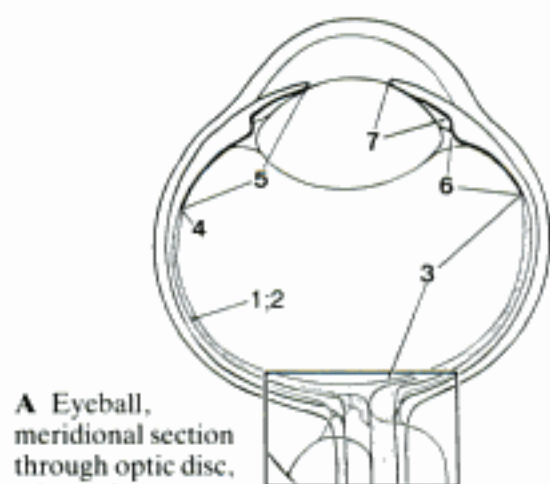


C Arteries of the iris (eq)

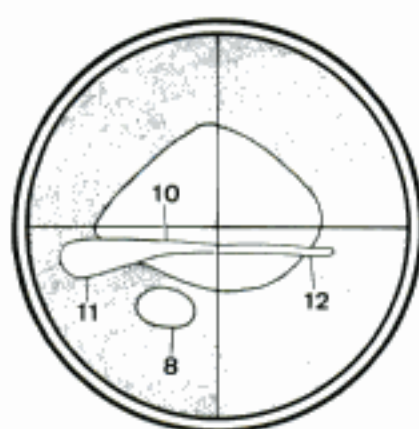


D Eyeball, meridional section (21.5 mm crown-rump length embryo, ca)

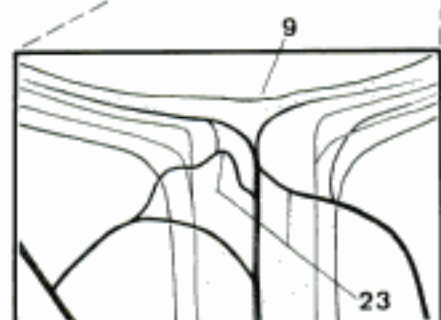
Hidden page



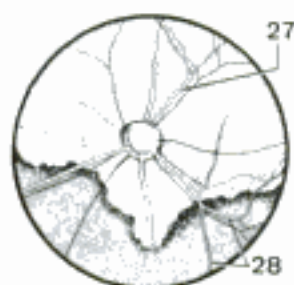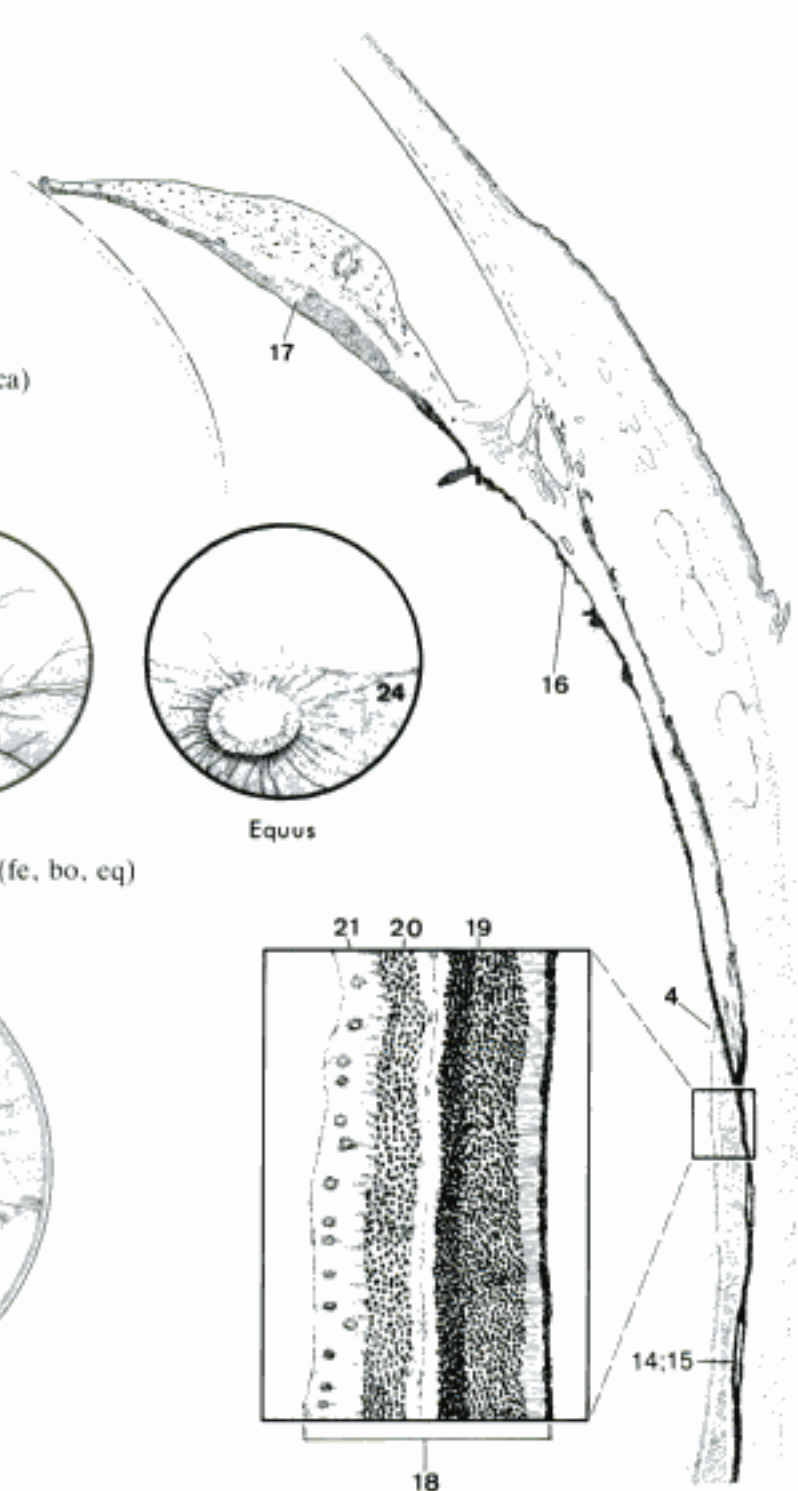
A Eyeball, meridional section through optic disc, schematic



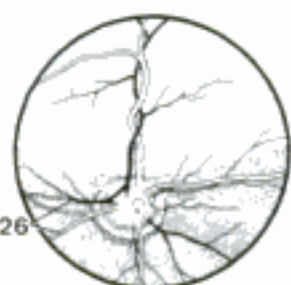C Fundus of the eyeball, schematic (eq) (Seiferle, Hebel)



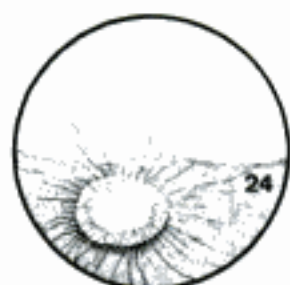B Discus n. optici, arteries of the retina (ca)



Felis

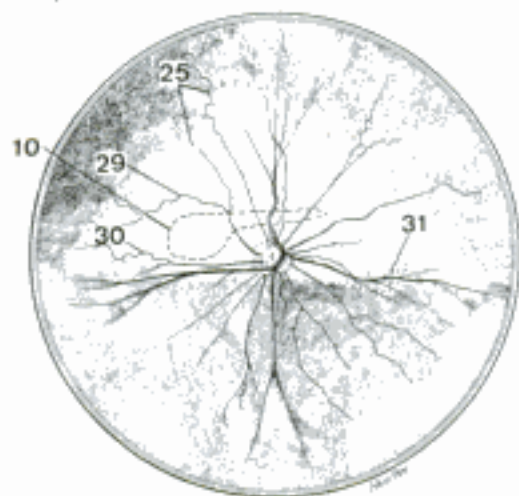


Bos



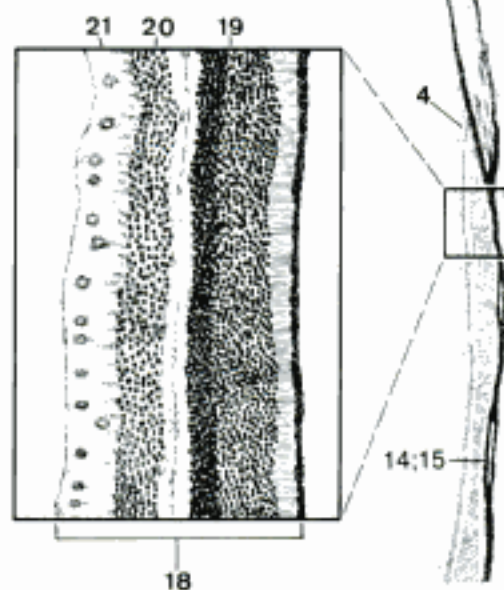
Equus

D Discus n. optici, vessels of the retina (fe, bo, eq) (Habel)



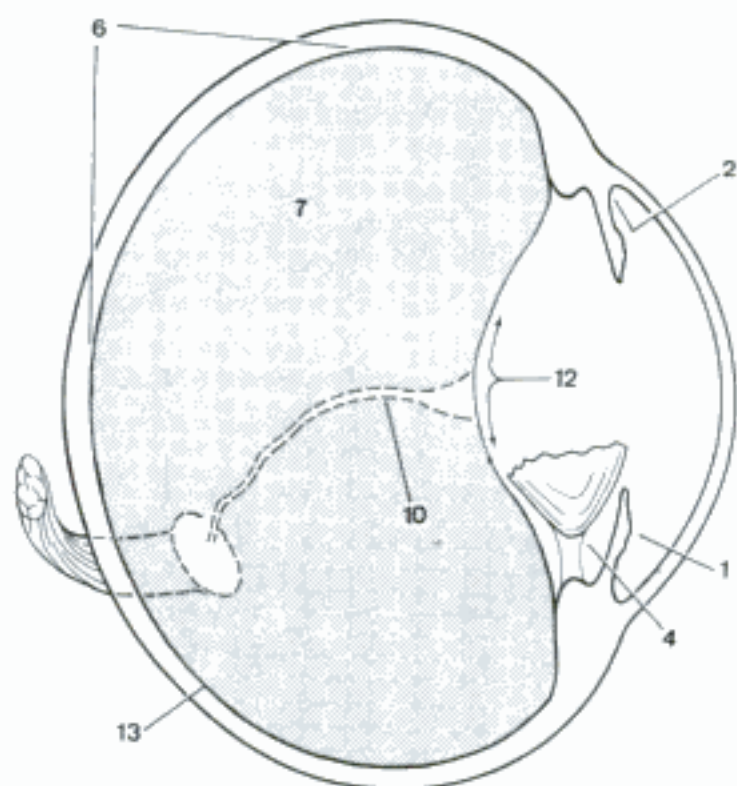
Canis

E Fundus of the eyeball (ca) (Evans and Christensen)

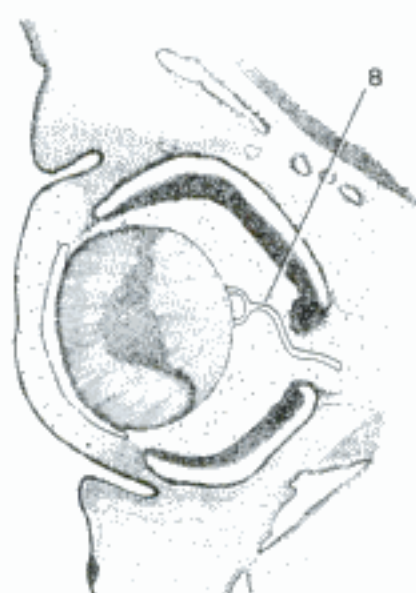


F Retina, histologic section (fe)

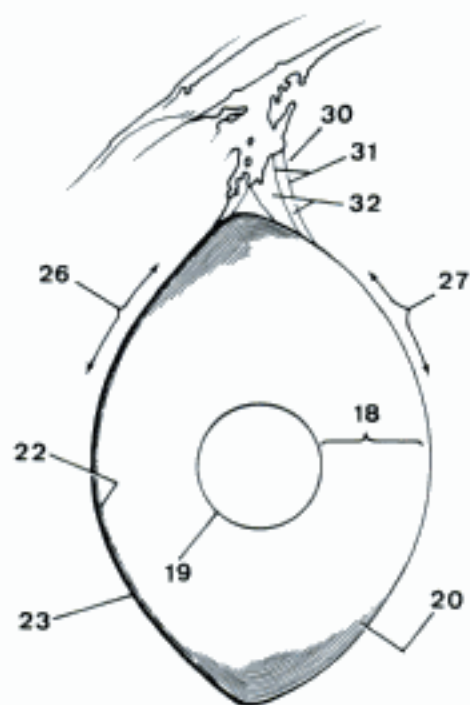
- 1 **Camera anterior bulbi.** Anterior chamber of the eyeball, space between iris and cornea, contains aqueous humor. A
- 2 *Angulus iridocornealis.* Iridocorneal angle, between iris and cornea, contains the Lig. pectinatum. A
- 3 *Humor aquosus.* Aqueous humor, fluid in the anterior and posterior chambers of the eyeball.
- 4 **Camera posterior bulbi.** Posterior chamber of the eyeball, space between iris and lens, contains aqueous humor. A
- 5 *Humor aquosus.* Aqueous humor.
- 6 **Camera vitrea bulbi.** Vitreous chamber of the eyeball, the space posterior to lens and ciliary body. A
- 7 *Corpus vitreum.* Vitreous body, gelatinous mass filling the vitreous chamber of the eyeball. A
- 8 *A. hyaloidea (ont).* Hyaloid artery, passing from the Discus n. optici to the posterior pole of the lens, supplies the developing lens.
- 9 (*Processus hyloideus*). Remnant of the A. hyaloidea in the middle of the Discus n. optici. About 2 mm long in eq, present also in Ru. D
- 10 *Canalis hyaloideus.* Hyaloid canal, condensation fibrils of the vitreous body, from the Discus n. optici to the posterior pole of the lens, contains the fetal A. hyaloidea. A
- 11 (*Conus papillaris*). Projection of minute blood vessels covered by pigmented epithelium from the Discus n. optici. In 15 to 20 percent of cap (and golden hamsters). F
- 12 *Fossa hyaloidea.* Hyaloid fossa, depression on the anterior surface of the vitreous body occupied by the lens. A
- 13 *Membrana vitrea.* Vitreous membrane, condensation of vitreous fibrils at the periphery of the vitreous body. A
- 14 *Stroma vitreum.* Stroma of the vitreous body, framework of transparent fibrils whose meshes contain the vitreous humor.
- 15 *Humor vitreus.* Vitreous humor, liquid filling the meshes of the vitreous body.
- 16 **Lens.** Transparent, biconvex structure focuses the light on the retina. E
- 17 *Substantia lentis.* Substance of the lens.
- 18 *Cortex lentis.* Cortex of the lens, outer, softer zone of the lens. C
- 19 *Nucleus lentis.* Lens nucleus, the harder center of the lens. C
- 20 *Fibrae lentis.* Lens fibers, transparent, constituting the substance of the lens. They are hexagonal in cross section; those close to the periphery are nucleated and have a semiliquid content. C
- 21 *Radii lentis.* Lens stars, Y-shaped figures on the lens where the ends of individual lens fibers meet. E
- 22 *Epithelium lentis.* Lens epithelium, a single layer of cuboidal cells on the anterior surface of the lens. C
- 23 *Capsula lentis.* Lens capsule, a highly elastic covering of the lens, thicker on the anterior surface and at the equator than on the posterior surface. C
- 24 *Polus anterior lentis.* Anterior pole of the lens, the highest point on the anterior surface. E
- 25 *Polus posterior lentis.* Posterior pole of the lens, the highest point on the posterior surface. E
- 26 *Facies anterior lentis.* Anterior surface of the lens, in Un less convex than the posterior surface. C
- 27 *Facies posterior lentis.* Posterior surface of the lens, in Un more strongly curved than the anterior surface. C
- 28 *Axis lentis.* Axis of the lens, passing through both poles of the lens. E
- 29 *Equator [Aequator] lentis.* Equator of the lens, border of the lens. E
- 30 **Zonula ciliaris.** Suspensory apparatus of the lens, consisting of many fibers that extend from the ciliary processes to the lens capsule anterior and posterior to the equator. C
- 31 *Fibrae zonulares.* Zonular fibers, fine homogeneous fibers extending from the ciliary processes to the capsule of the lens. C
- 32 *Spatia zonularia.* Zonular spaces, between the Fibrae zonulares. C



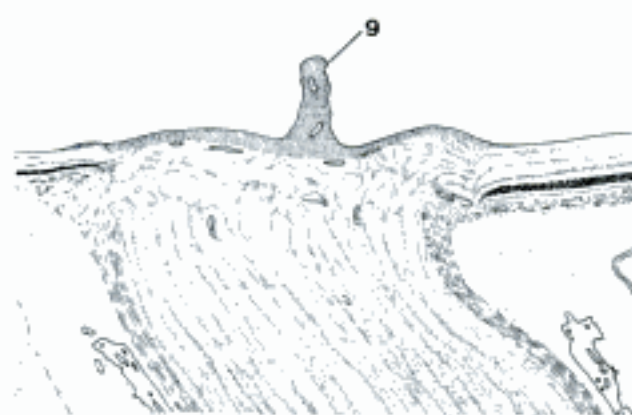
A Eyeball, meridional section (ov)



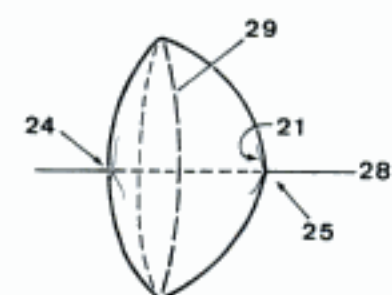
B Eyeball, meridional section (33 day old embryo, su) (Zietzschmann and Krölling)



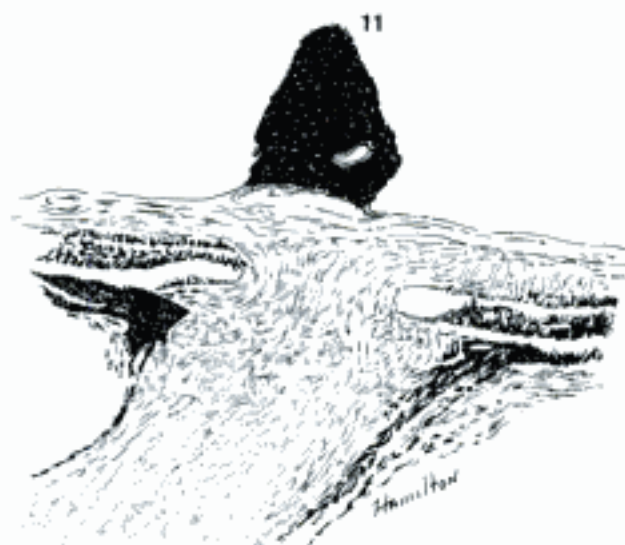
C Lens, meridional section (cap)



D Discus n. optici, section (eq)



E Lens (bo)

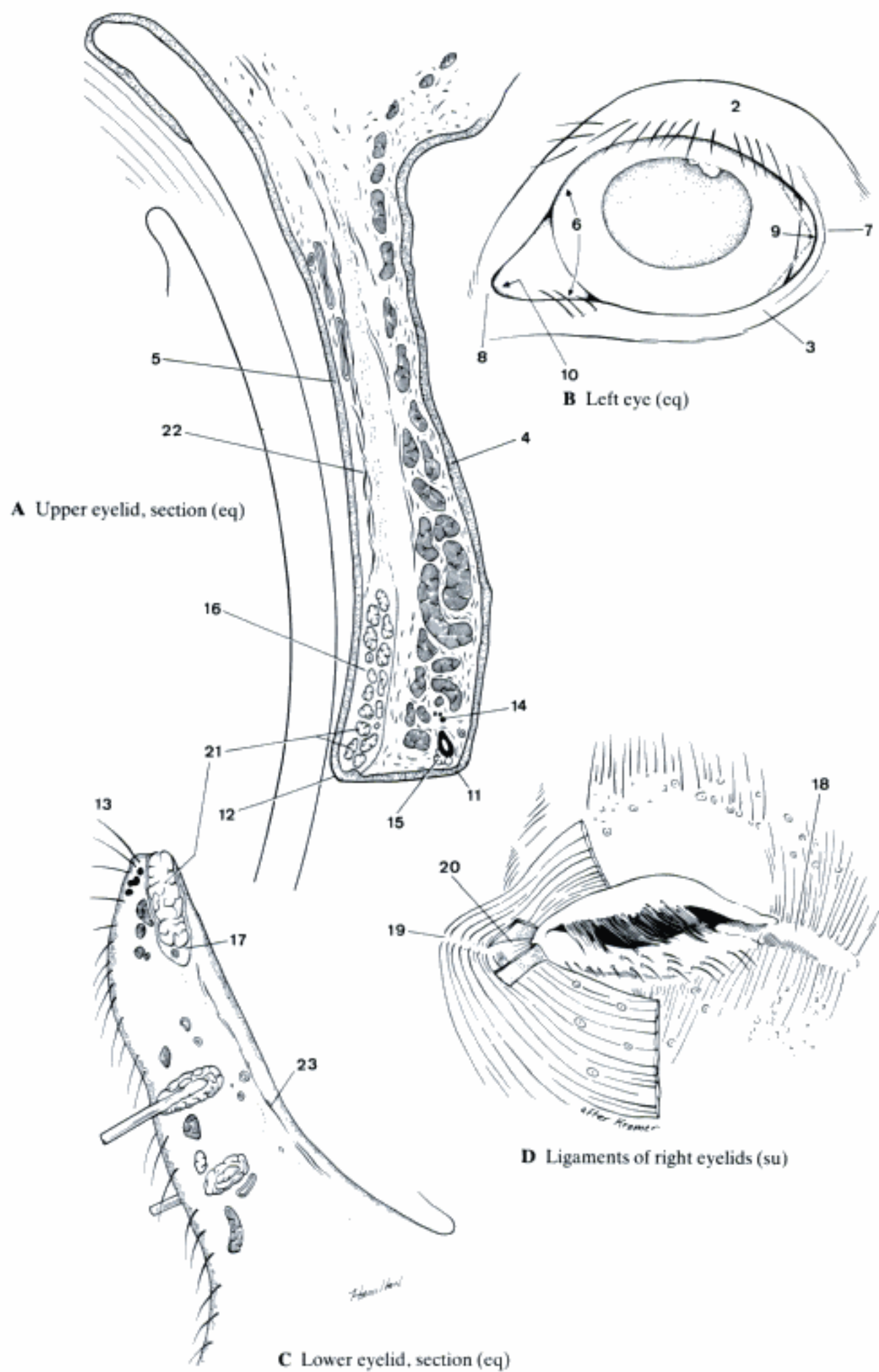


F Discus n. optici, section (golden hamster) (Baesich)

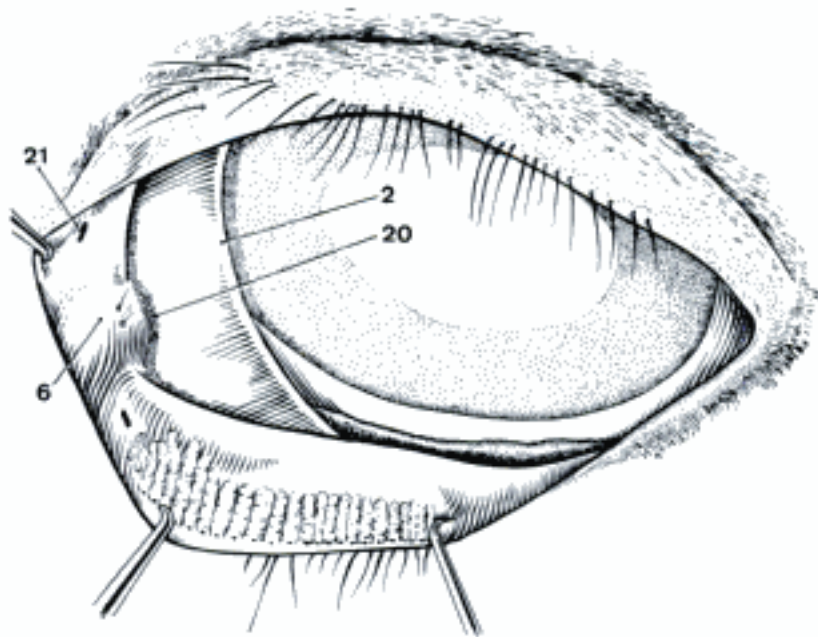
Hidden page

Hidden page

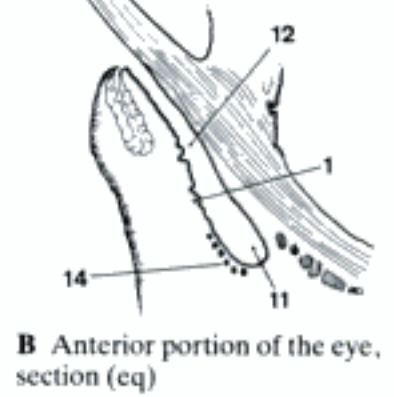
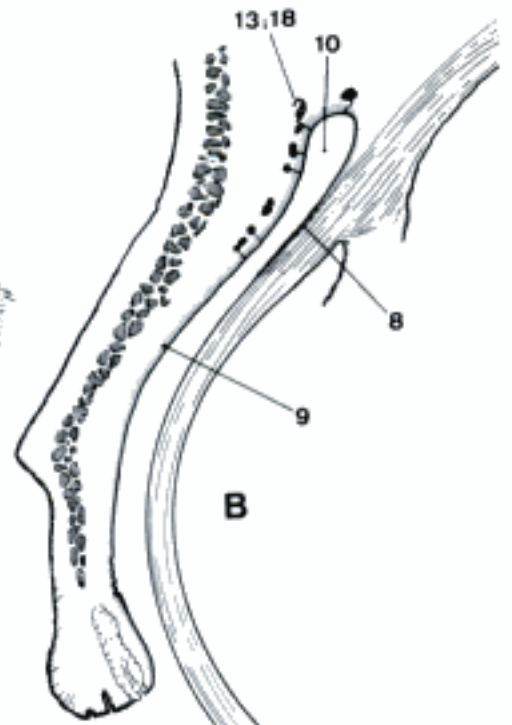
Hidden page



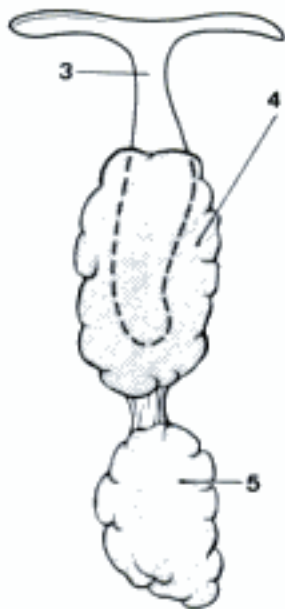
- 1 **Tunica conjunctiva.** Conjunctiva, the mucous membrane on the posterior surface of the eyelids, reflects itself onto the anterior surface of the eyeball to the edge of the cornea. B
- 2 *Plica semilunaris conjunctivae [Palpebra III].* Third eyelid, fold of conjunctiva supported by a thin plate of cartilage in the medial angle of the eye. It slides over the eyeball when the latter is retracted. On its bulbar surface are accumulations of lymphoid nodules. A
- 3 *Cartilago.* Supporting cartilage of the third eyelid, roughly T-shaped with the bar of the T in the free edge of the third eyelid and the stem between the medial wall of the orbit and the eyeball. C
- 4 *Glandula superficialis.* Accessory lacrimal gland surrounding the stem of the T-shaped cartilage of the third eyelid. Its secretion enters the conjunctival sac on the bulbar surface of the third eyelid. C
- 5 *Glandula profunda.* Deep accessory lacrimal gland in su and bo. C
- 6 *Caruncula lacrimalis.* Lacrimal caruncle, elevation in the medial angle of the eye, bears fine hairs and contains sebaceous and sudoriferous glands. A
- 7 *Glandula carunculae lacrimalis.* Gland deep to the lacrimal caruncle in ca.
- 8 *Tunica conjunctiva bulbi.* Bulbar conjunctiva, on the anterior surface of the eyeball except the cornea. It is loosely attached to the sclera and covered with stratified squamous epithelium. B
- 9 *Tunica conjunctiva palpebrarum.* Palpebral conjunctiva, on the posterior surface of the eyelids. It is covered with a stratified columnar to cuboidal epithelium containing goblet cells near the fornix. B
- 10 *Fornix conjunctivae superior.* Upper fornix, formed by the reflection of the palpebral conjunctiva onto the bulbar conjunctiva. B
- 11 *Fornix conjunctivae inferior.* Lower fornix, formed by the reflection of the palpebral conjunctiva onto the bulbar conjunctiva. B
- 12 *Saccus conjunctivae.* Conjunctival sac, space between bulbar and palpebral conjunctivae. B
- 13 *Glandulae conjunctivales.* Conjunctival glands, small accessory lacrimal glands in the vicinity of the fornix. B
- 14 *Lymphonoduli [Noduli lymphatici] conjunctivales.* Lymph nodules in the conjunctiva. B
- 15 **Apparatus lacrimalis.** Lacrimal apparatus.
- 16 *Glandula lacrimalis.* Lacrimal gland, located dorsolateral to the eyeball. E
- 17 *Ductuli excretorii.* Excretory ductules, connecting the lacrimal gland with the lateral part of Fornix conjunctivae superior. E
- 18 (*Gll. lacrimales accessoriae*). Accessory lacrimal glands, especially in the vicinity of the fornices. B
- 19 *Rivus lacrimalis.* The narrow space, filled with lacrimal fluid, between the free borders of the closed eyelids and the eyeball.
- 20 *Lacus lacrimalis.* Lacrimal lake, the semicircular recess surrounding the lacrimal caruncle. A
- 21 *Punctum lacrimale.* Lacrimal punctum, minute, slitlike opening through which the lacrimal fluid leaves the eye, on the Limbus palpebralis posterior close to the medial angle of the eye. A
- 22 *Canaliculus lacrimalis.* Lacrimal canaliculus, short duct connecting the Punctum lacrimale with the lacrimal sac. E
- 23 *Saccus lacrimalis.* Lacrimal sac, enlargement of the proximal end of the nasolacrimal duct occupying the Fossa sacci lacrimalis. E
- 24 *Fornix sacci lacrimalis.* Dorsal recess of the lacrimal sac in ov.
- 25 *Ductus nasolacrimalis.* Nasolacrimal duct, connects the lacrimal sac with the nasal cavity. It opens in the wall of the nostril but may have accessory openings farther caudally. E
- 26 *Plica lacrimalis.* Lacrimal fold, at the opening of the nasolacrimal duct in some species. D



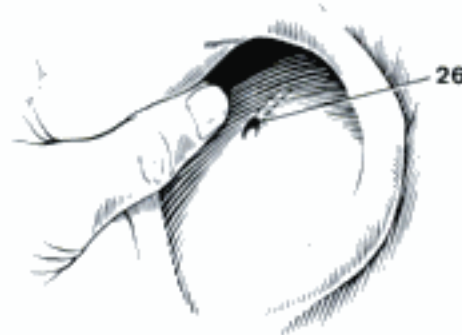
A Left eye (eq)



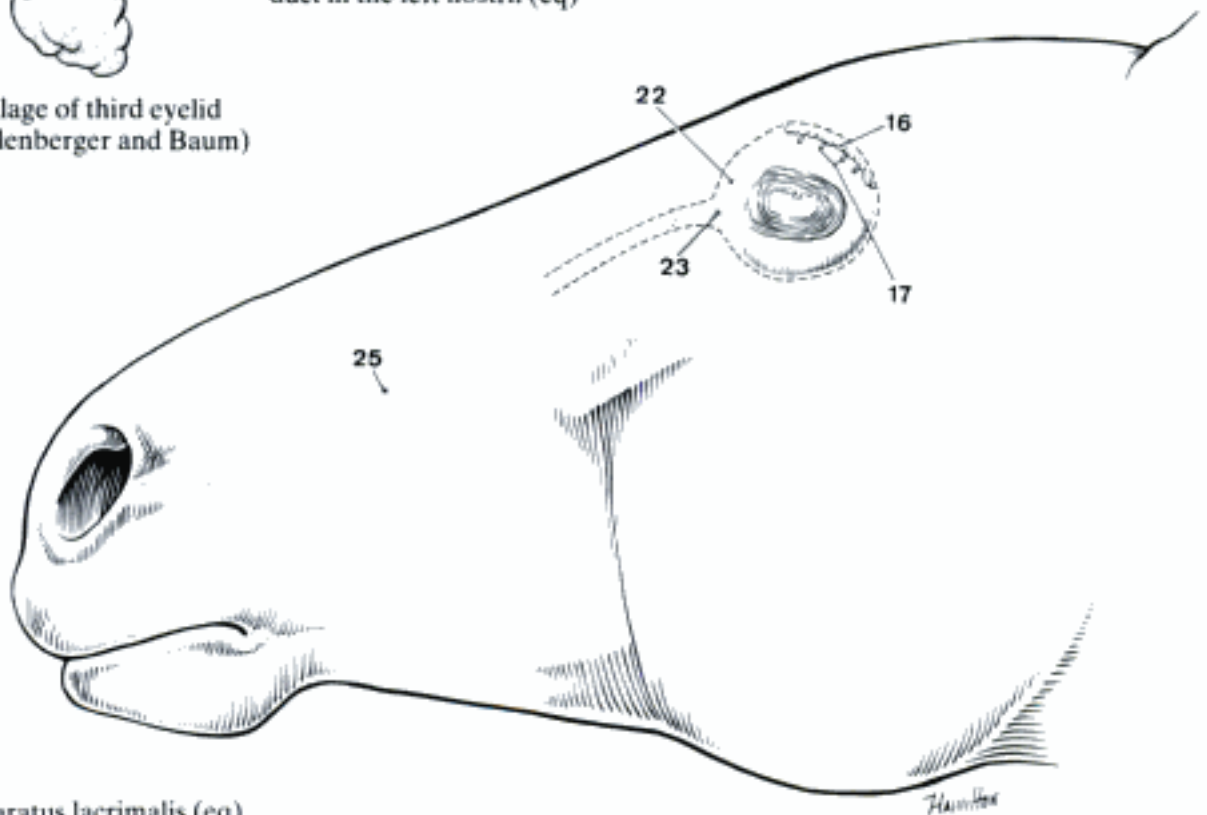
B Anterior portion of the eye, section (eq)



C Cartilage of third eyelid (su) (Ellenberger and Baum)

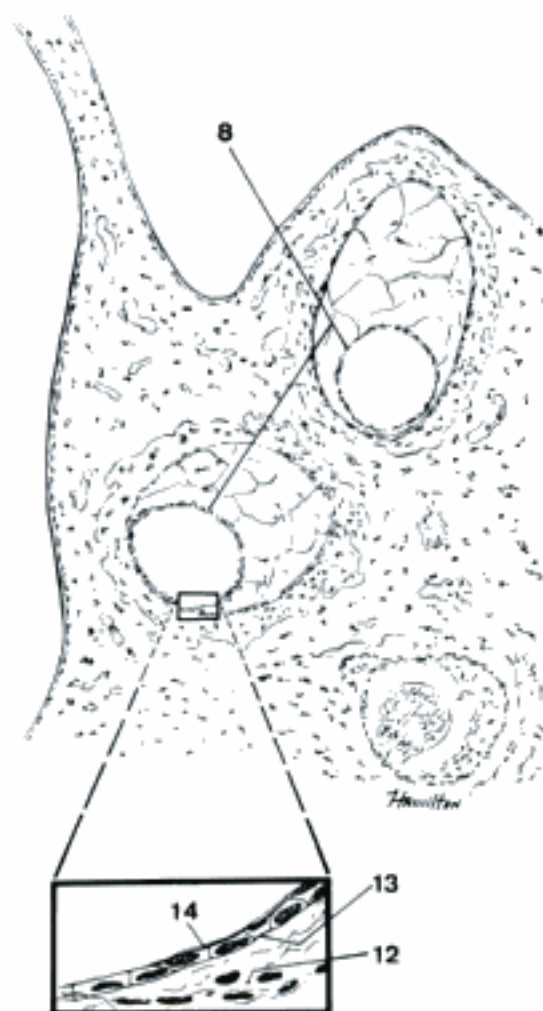
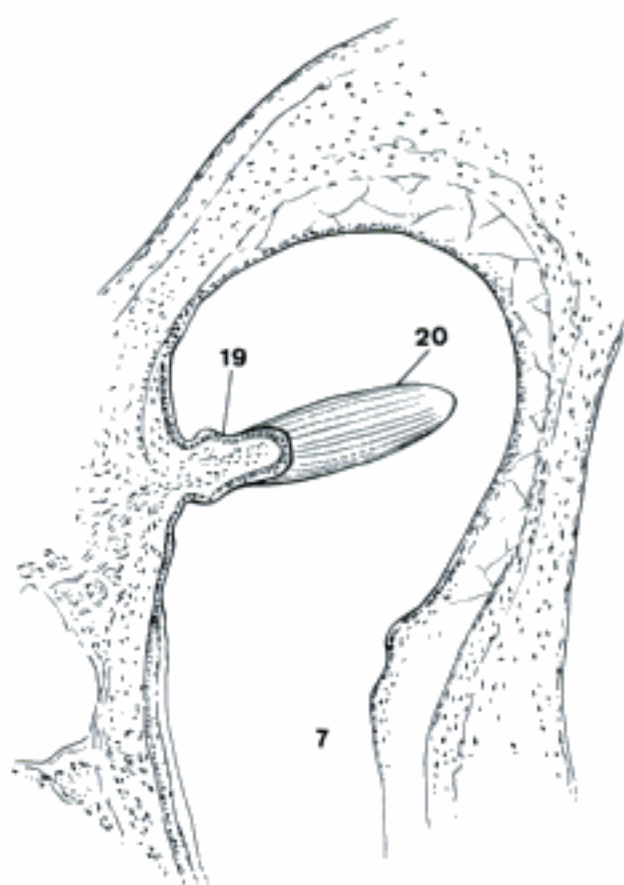
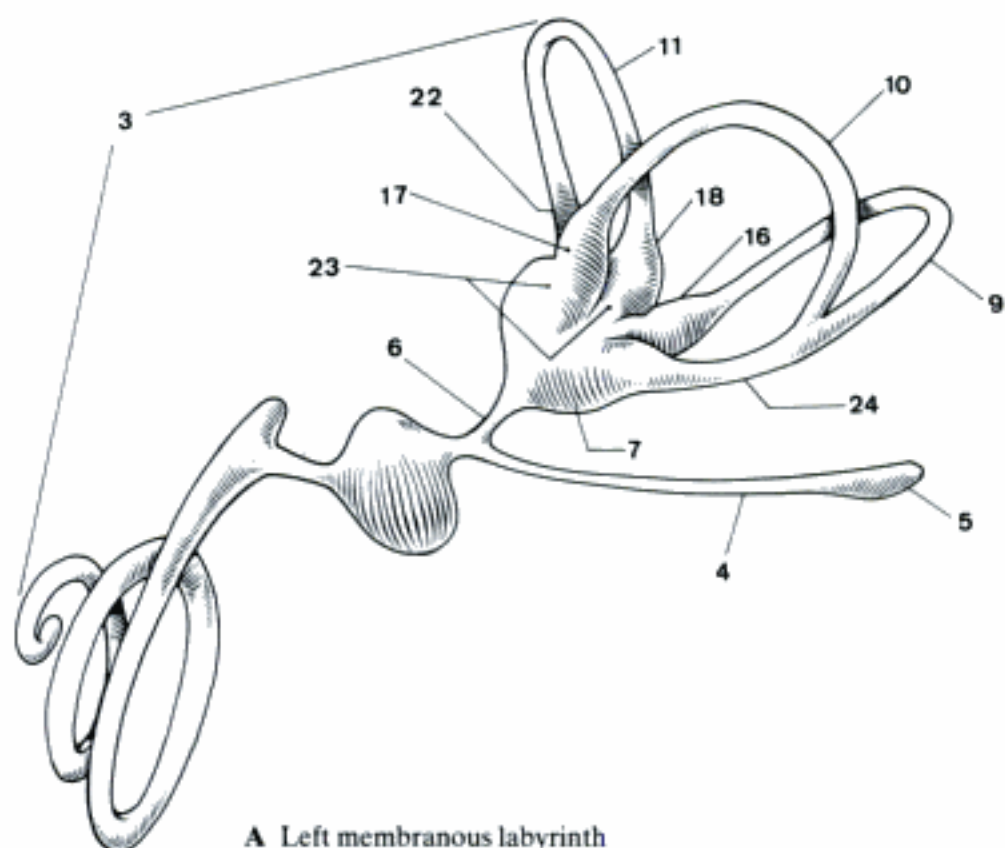


D Opening of nasolacrimal duct in the left nostril (eq)

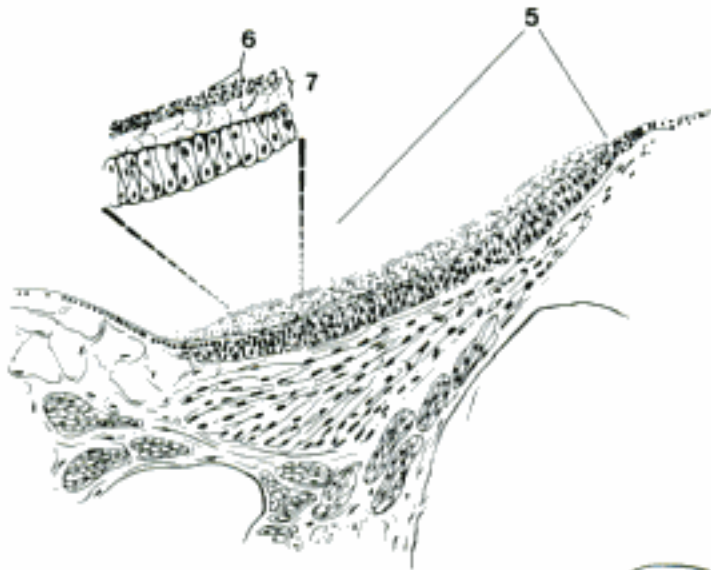


E Apparatus lacrimalis (eq)

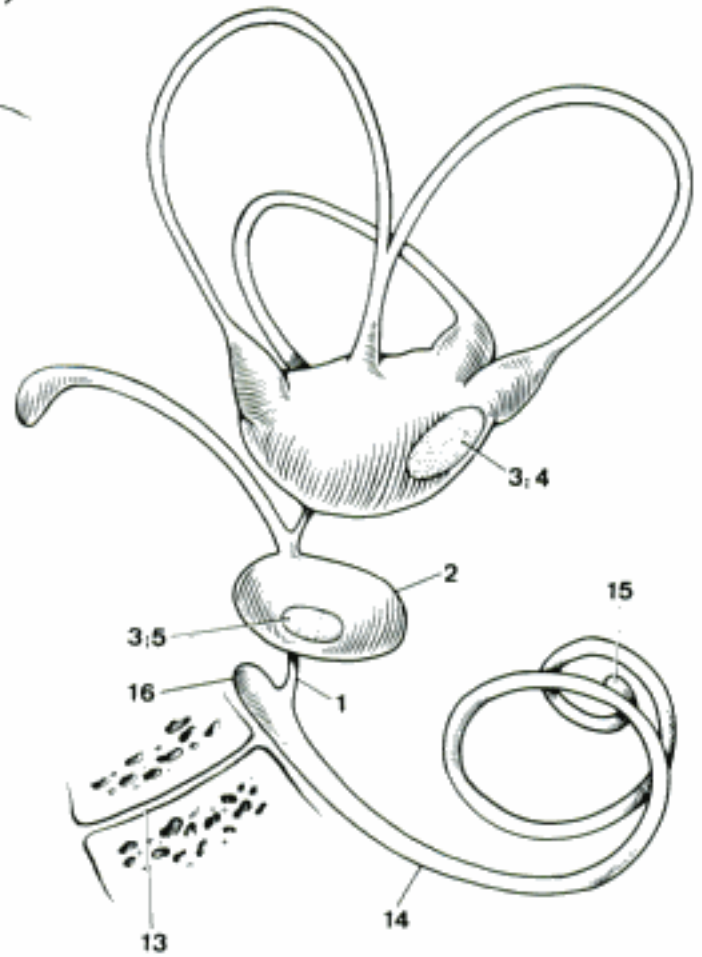
- 1 **ORGANUM VESTIBULOCOCHLEARE [AURIS].** Vestibulocochlear organ (ear). Sense organ receptive to sounds, gravity and changes in the position of the head.
- 2 **AURIS INTERNA.** Internal ear, located in the petrosal bone, converts the mechanical stimuli of sound and positional changes into nerve impulses.
- 3 **Labyrinthus membranaceus.** Membranous labyrinth, closed system of membranous ducts and cavities, contains endolymph, located in the osseous labyrinth. A
- 4 *Ductus endolymphaticus.* Endolymphatic duct, in the Aqueductus vestibuli from the Sacculus to the Dura mater. A
- 5 *Saccus endolymphaticus.* Endolymphatic sac, the slightly enlarged end of the Ductus endolymphaticus. A
- 6 *Ductus utriculosaccularis.* Utriculosaccular duct, short connection between the saccular end of the Ductus endolymphaticus and the Utriculus. A
- 7 *Utriculus.* Enlargement of the membranous labyrinth that gives rise to the three semicircular ducts. It occupies the Recessus ellipticus of the Vestibulum. A
- 8 *Ductus semicirculares.* Semicircular ducts, membranous, originating and ending at the Utriculus. They are oriented at nearly right angles to each other.
- 9 *Ductus semicircularis anterior.* Anterior semicircular duct, the plane of its circle relative to the base of the skull faces rostromedially. A
- 10 *Ductus semicircularis posterior.* Posterior semicircular duct, the plane of its circle relative to the base of the skull faces rostrolaterally and slightly dorsally. A
- 11 *Ductus semicircularis lateralis.* Lateral semicircular duct, the plane of its circle relative to the base of the skull faces dorsally and slightly caudally. A
- 12 *Membrana propria ductus semicircularis.* Propria mucosae of the semicircular duct, external layer of the wall. C
- 13 *Membrane basalis ductus semicircularis.* Basal membrane of the semicircular duct, thin layer between propria mucosae and epithelium. C
- 14 *Epithelium ductus semicircularis.* Epithelium of the semicircular duct, simple squamous cells lining the interior of the duct. Along the concave surface of the duct is a strip of columnar cells that extends into the ampulla. C
- 15 *Ampullae membranaceae.* Membranous ampullae, spindle-shaped enlargements of the semicircular ducts near their junction with the Utriculus, one for each duct.
- 16 *Ampulla membranacea anterior.* Enlargement of the anterior semicircular duct. A
- 17 *Ampulla membranacea posterior.* Enlargement of the posterior semicircular duct. A
- 18 *Ampulla membranacea lateralis.* Enlargement of the lateral semicircular duct. A
- 19 *Crista ampullaris.* Semilunar crest projecting into the membranous ampulla, consists of connective tissue and nerve fibers, covered with neuroepithelium from which tufts of sensory hair project into the overlying cupula. B
- 20 *Cupula.* Tall, gelatinous layer on the Crista ampullaris, bellshaped in cross section, consists of fibrillar columns alternating with endolymphatic spaces for the sensory hairs of the neuroepithelium. B
- 21 *Crura membranacea.* Ends of the semicircular ducts where they join the Utriculus.
- 22 *Crus membranaceum simplex.* Single non-ampullated end of the lateral semicircular duct. A
- 23 *Crura membranacea ampullaria.* Junctions between the ampullated ends of the semicircular ducts and the Utriculus. A
- 24 *Crus membranaceum commune.* Common junction of the non-ampullated ends of the anterior and posterior semicircular ducts with the Utriculus. A



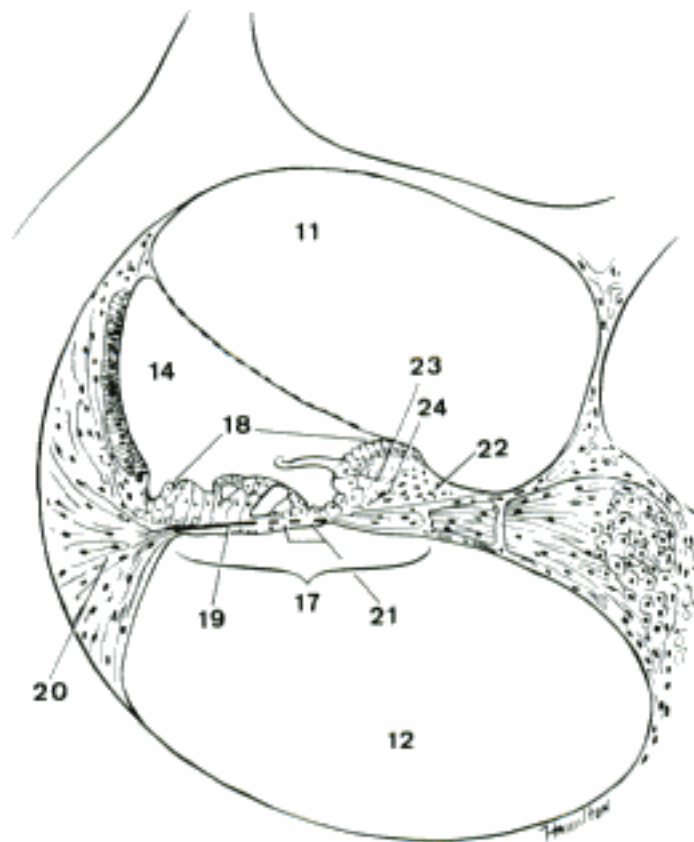
- 1 *Ductus reuniens*. Short duct connecting the Sacculus with the Ductus cochlearis. B
- 2 *Sacculus*. Enlargement of the membranous labyrinth occupying the Recessus sphericus of the Vestibulum. B
- 3 *Maculae*. Oval areas of neuroepithelium in the wall of the membranous labyrinth monitoring the position of the head. B
- 4 *Macula utriculi*. Macula in the medial wall of the Utriculus. B
- 5 *Macula sacculi*. Macula in the medial wall of the Sacculus. A B
- 6 *Statoconia*. Minute calcium carbonate rods in the surface of the Membrana statoconiorum. A
- 7 *Membrana statoconiorum*. Gelatinous layer covering the neuroepithelial cells of the macula. It contains the statoconia and the sensory hairs of the neuroepithelial cells. A
- 8 *Endolympha*. Endolymph, fluid in the membranous labyrinth.
- 9 *Perilympha*. Perilymph, fluid in the spaces between the membranous and osseous labyrinths.
- 10 *Spatium perilymphaticum*. Perilymphatic space, between membranous and osseous labyrinths, subdivided by fine trabeculae, except in the scalae. A
- 11 *Scala vetibuli*. Perilymphatic space on the cupular surface of the Ductus cochlearis. C
- 12 *Scala tympani*. Perilymphatic space on the basilar surface of the Ductus cochlearis. C
- 13 *Ductus perilymphaticus*. Perilymphatic duct, connecting the perilymphatic space in the vicinity of the base of the cochlea to the subarachnoid space. B
- 14 **Ductus cochlearis**. Cochlear duct, the spiral part of the membranous labyrinth, triangular in cross section, that occupies the cochlea. B C
- 15 *Cecum [Caecum] cupulare*. Blind end in the cupula of the cochlea. B
- 16 *Cecum [Caecum] vestibulare*. Blind beginning in the Vestibulum near the Sacculus. B
- 17 *Paries tympanicus ductus cochlearis [Membrana spiralis]*. Wall of the cochlear duct facing the Scala tympani. C
- 18 *Organum spirale*. Spiral organ, complex neuroepithelium in the Paries tympanicus ductus cochlearis, transforming sound waves to nerve impulses. C
- 19 *Lamina basilaris*. Basilar lamina, connective tissue components of the Paries tympanicus ductus cochlearis, extending from the Lamina spiralis ossea to the Lig. spirale cochleae. C
- 20 *Lig. spirale cochleae*. Spiral ligament of the cochlea, condensation of periosteum, triangular in cross section, extending from the periphery of the cochlea inward to the Lamina basilaris. C
- 21 *Foramina nervosa*. Foramina in the Lamina basilaris for nerve fibers going to the Organum spirale. C
- 22 *Limbus laminae spiralis osseae*. Dense connective tissue on the vestibular surface of the Lamina spiralis ossea, extending peripherally and ending in two lips between which is the Sulcus spiralis internus. C
- 23 *Labium limbi vestibulare*. Lip of the Limbus laminae spiralis osseae on the vestibular side of the Sulcus spiralis internus, continued peripherally by the Membrana tectoria. C
- 24 *Labium limbi tympanicum*. Lip of the Limbus laminae spiralis osseae on the tympanic side of the Sulcus spiralis internus, continued by the Lamina basilaris. C



A Sacculus, section (guinea pig)



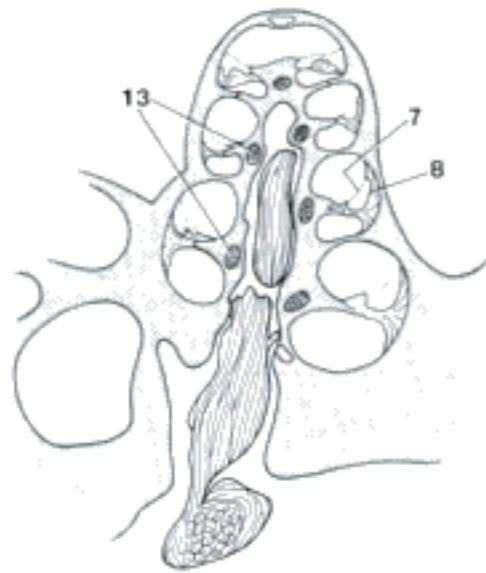
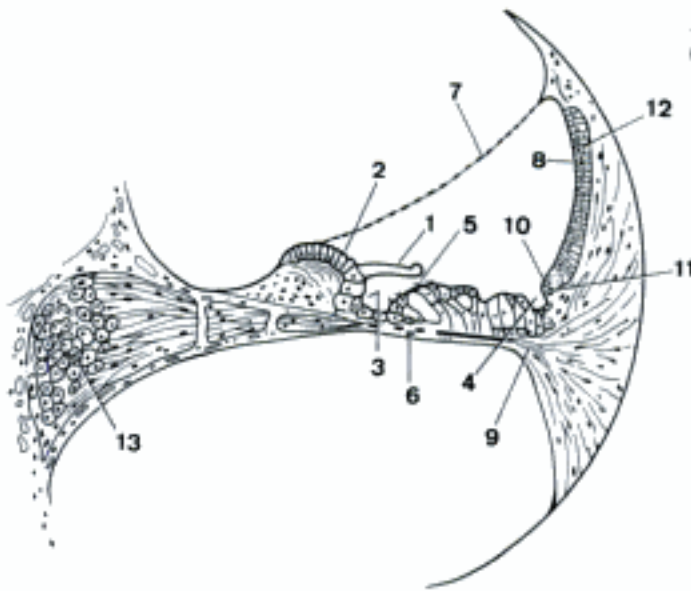
B Left membranous labyrinth, medial aspect



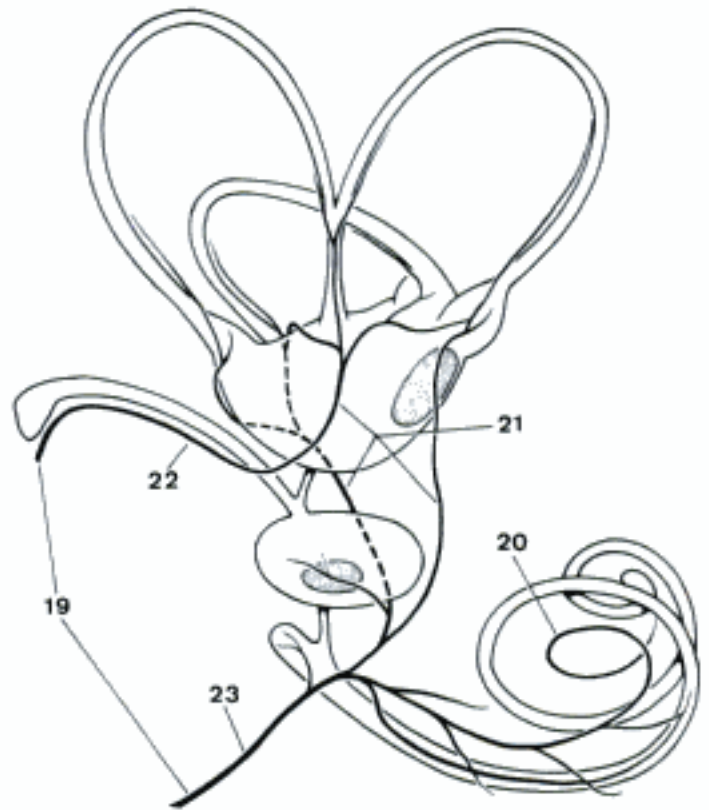
C Canalis spiralis cochleae, transverse section (guinea pig)

- 1 *Membrana tectoria*. Tectorial membrane, continuation of the Labium limbi vestibulare overlying the Organum spirale and the Sulcus spiralis internus. A
- 2 *Dentes acustici*. Tooth-like ridges on the vestibular surface of the Labium limbi vestibulare, caused by slightly projecting rows of cells. A
- 3 *Sulcus spiralis internus*. Internal spiral sulcus, the groove between the two lips of the Limbus laminae spiralis osseae, covered by the Membrana tectoria. A
- 4 *Sulcus spiralis externus*. External spiral sulcus, the groove on the peripheral end of the Organum spirale, at the junction of tympanic and external walls of the cochlear duct. A
- 5 *Membrana reticularis*. Reticular membrane, covering the sensory cells of the Organum spirale, formed by the processes of the deeper lying phalangeal cells. Through its meshes project the sensory hairs of the sensory cells. A
- 6 *Vas spirale*. Small vein under the Organum spirale on the tympanic side of the Lamina basilaris. A
- 7 *Paries vestibularis ductus cochlearis [Membrana vestibularis]*. Vestibular wall of the cochlear duct, thin membrane between Scala vestibuli and Ductus cochlearis. A B
- 8 *Paries externus ductus cochlearis*. External wall of the cochlear duct, lying against the Lig. spirale. A B
- 9 *Crista basilaris*. Basilar crest of the Lig. spirale where it is continuous with the Lamina basilaris. A
- 10 *Prominentia spiralis*. Spiral prominence in the external wall of the cochlear duct above the Sulcus spiralis externus. A
- 11 *Vas prominens*. Small blood vessel in the Prominentia spiralis. A
- 12 *Stria vascularis*. Thick layer of pigmented epithelium invaded by capillaries; it is thought to secrete endolymph. A
- 13 *Ganglion spirale cochleae*. Spiral ganglion, cord-like accumulation of bipolar nerve cells in the modiolus of the cochlea. The dendrites come from the sensory cells in the Organum spirale, the axons form the N. cochlearis. A B
- 14 **Vasa auris internae**. Vessels of the internal ear.
- 15 *A. labyrinthi*. Labyrinthine artery, branch of A. basilaris or A. cerebelli caudalis, passes through the internal acoustic meatus into the petrosal bone to supply the internal ear. D
- 16 *Rami vestibulares*. Vestibular branches, for the supply of Utriculus, Ductus semicirculares, and Sacculus. D
- 17 *Ramus cochlearis*. Cochlear branch, passes into the center of the cochlea and supplies the cochlear duct and adjacent structures. D
- 18 *Glomeruli arteriosi [Glomerula arteriosa] cochleae*. Glomus-type arteriovenous anastomoses between branches of Ramus cochlearis and Vas spirale. In bo and ov, they range from .05–2 mm in diameter, have also been seen in the Vestibulum. D
- 19 *Vv. labyrinthi*. Labyrinthine veins, draining the internal ear, through Canaliculus cochleae (mainly) and Aqueductus vestibuli. There is no satellite vein to the A. labyrinthi in domestic mammals. C
- 20 *V. spiralis modioli*. Spiral vein in the center of the cochlea. C
- 21 *Vv. vestibulares*. Vestibular veins, draining Utriculus, Ductus semicirculares, and Sacculus. C
- 22 *V. aqueductus [aquae-] vestibuli*. Vein in the Aqueductus vestibuli, draining Utriculus and Ductus semicirculares. C
- 23 *V. canaliculi cochleae*. Vein in the canaliculus cochleae, principal drainage of the internal ear. C

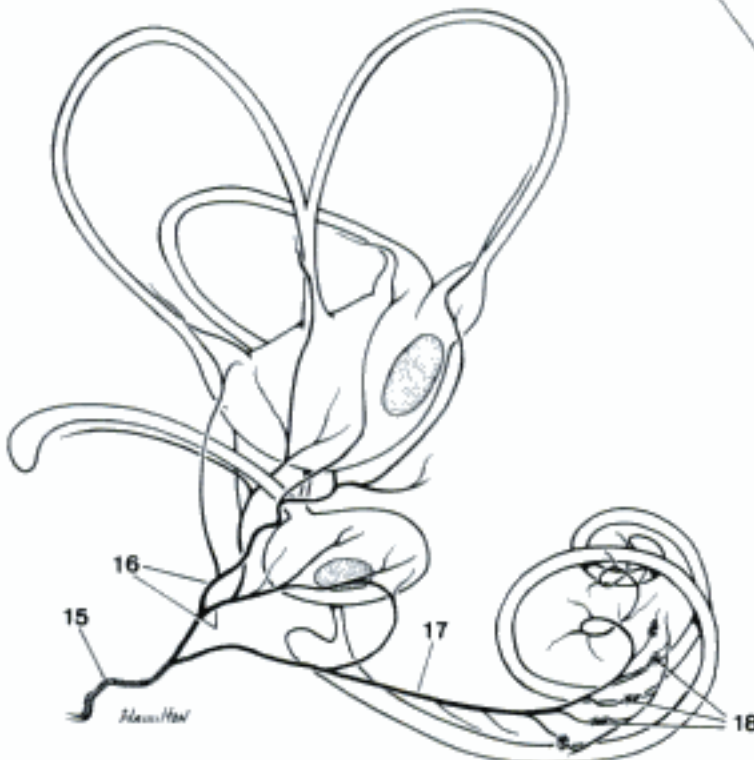
A Ductus cochlearis, transverse section (guinea pig)



B Cochlea, longitudinal section (guinea pig)

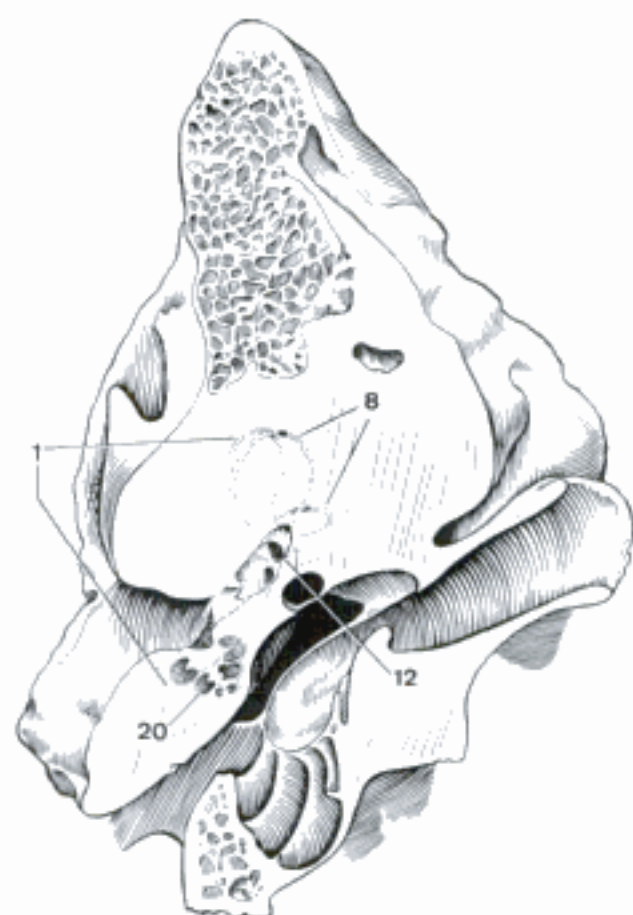


C Veins of the left membranous labyrinth, medial aspect (ca) (Shambaugh)

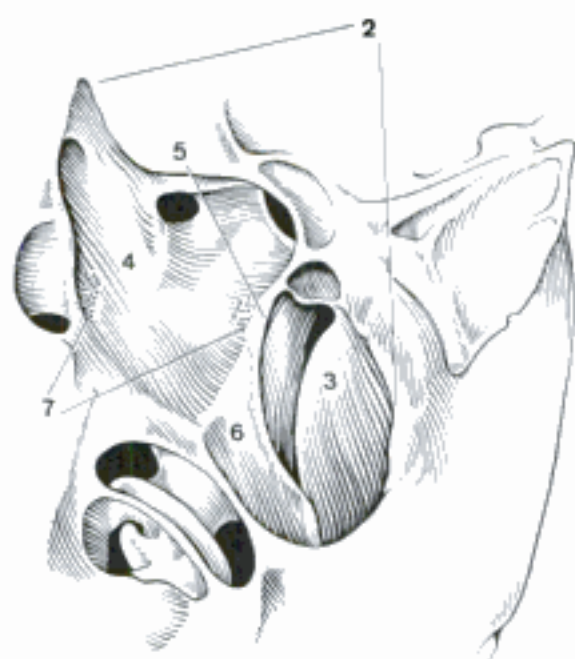


D Arteries of the left membranous labyrinth, medial aspect (ov) (Lewin)

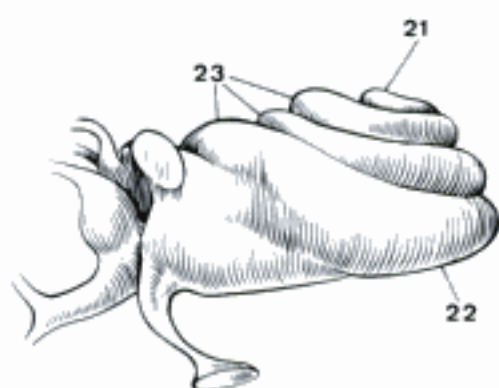
- 1 **Labyrinthus osseus.** Osseous labyrinth, excavation in the petrosal bone, houses the membranous labyrinth. A
- 2 **Vestibulum.** Vestibule, contains Utriculus and Sacculus. B
- 3 *Recessus sphericus [sphaericus].* Spherical recess, in the anterior part of the Vestibulum containing the Sacculus. B
- 4 *Recessus ellipticus.* Elliptical recess, in the posterior part of the Vestibulum containing the Utriculus. B
- 5 *Crista vestibuli.* Vestibular crest, in the medial wall of the Vestibulum between Recessus sphericus and ellipticus. B
- 6 *Recessus cochlearis.* Cochlear recess, recess in the rostroventral wall of the Recessus sphericus for the Cecum vestibulare of the cochlear duct. B
- 7 *Maculae cribrosae.* Cribriform areas in the medial wall of the Vestibulum for the passage of the fibers of the N. vestibularis. B
- 8 **Canales semicirculares ossei.** Osseous semicircular canals, 0.2–0.5 mm in diameter, containing the Ductus semicirculares. A
- 9 *Canalis semicircularis anterior.* Anterior semicircular canal, for the Ductus semicircularis anterior. D
- 10 *Canalis semicircularis posterior.* Posterior semicircular canal, for the Ductus semicircularis posterior. D
- 11 *Canalis semicircularis lateralis.* Lateral semicircular canal, for the Ductus semicircularis lateralis. D
- 12 *Ampullae osseae.* Osseous ampullae, fusiform excavations at one end of the three semicircular canals for the Ampullae membranaceae.
- 13 *Ampulla osseae anterior.* Anterior osseous ampulla. D
- 14 *Ampulla ossea posterior.* Posterior osseous ampulla. D
- 15 *Ampulla ossea lateralis.* Lateral osseous ampulla. D
- 16 *Crura ossea.* The junctions of the osseous semicircular canals with the Vestibulum.
- 17 *Crus osseum commune.* The combined non-ampullated ends of the osseous anterior and posterior semicircular canals. D
- 18 *Crus osseum simplex.* The simple non-ampullated end of the lateral semicircular canal. D
- 19 *Crura ossea ampullaria.* The ampullated ends of the semicircular canals at the Vestibulum. D
- 20 **Cochlea.** Pyramidal excavation of the petrosal bone, similar in shape to a snail's shell. A
- 21 *Cupula cochleae.* Apex of the cochlea. C
- 22 *Basis cochleae.* Base of the cochlea. C
- 23 *Canalis spiralis cochleae.* Spiral canal of the cochlea, winding around the modiolum in 1½ to 4 turns. C D E
- 24 *Modiolus.* Cone-shaped osseous center of the cochlea. E
- 25 *Basis modioli.* Base of the modiolum, the center of the base of the cochlea. E
- 26 *Lamina modioli.* The spiral shelf passing around the modiolum between adjacent turns of the spiral canal of the cochlea. E
- 27 *Canalis spiralis modioli.* Spiral canal of the modiolum, space for the Ganglion spirale cochleae in the base of the Lamina spiralis ossea. E
- 28 *Canales longitudinales modioli.* Longitudinal canals of the modiolum, containing the fibers of the N. cochlearis. E
- 29 *Lamina spiralis ossea.* Osseous spiral lamina, shelf projecting from the modiolum into the Canalis spiralis cochleae. E
- 30 *Hamulus laminae spiralis.* Hook-like end of the Lamina spiralis ossea in the Cupula cochleae. E
- 31 *Helicotrema.* Opening by which Scala vestibuli and Scala tympani communicate in the Cupula cochleae. E
- 32 *Lamina spiralis secundaria.* Projects from the outer wall of Canalis spiralis cochleae, opposite to Lamina spiralis ossea, attachment of Lamina basilaris, present only in the basal turn.



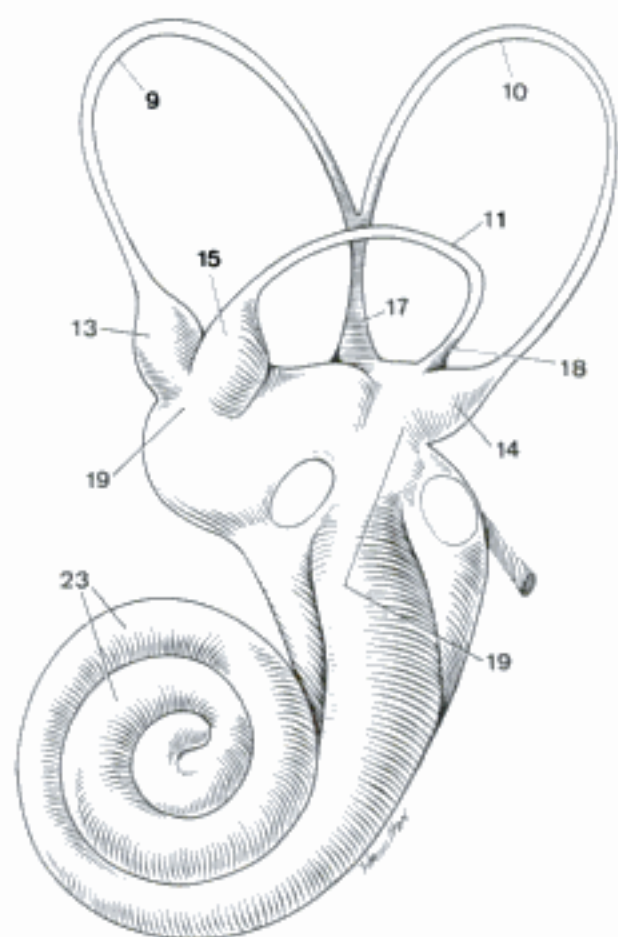
A Left petrosal bone, transverse section, rostral aspect (eq)



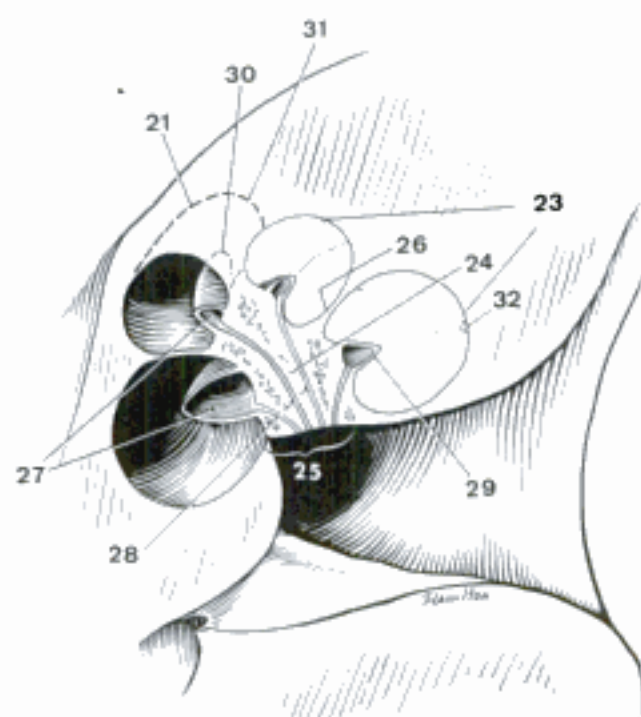
B Left osseous labyrinth, opened, ventral aspect (eq)



C Cast of right cochlea, ventral aspect (bo)

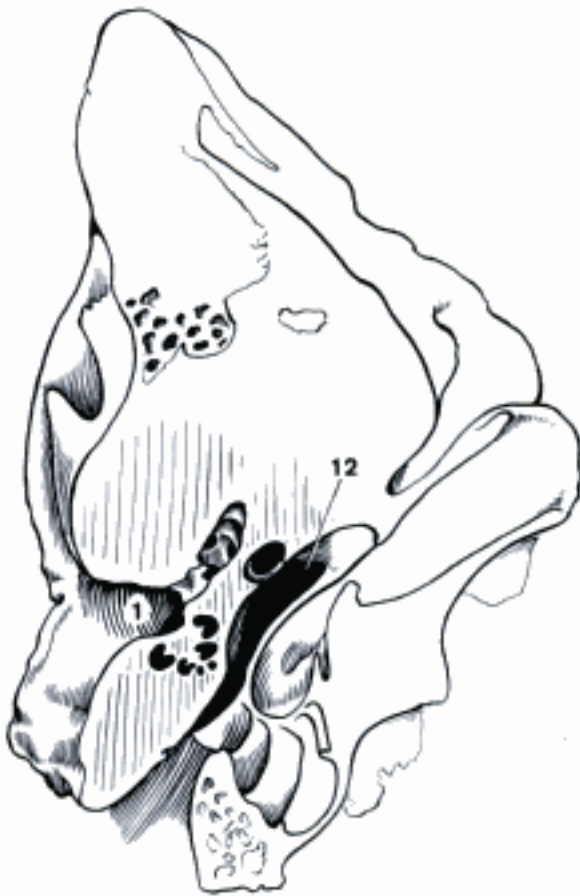


D Cast of left osseous labyrinth, lateral aspect (bo)

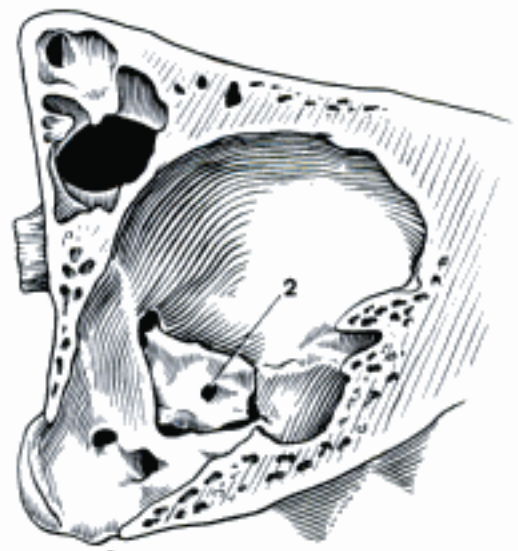


E Left cochlea, section, dorsal aspect (eq)

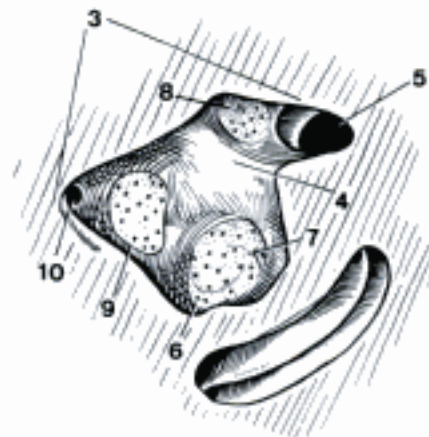
- 1 **Meatus acusticus internus.** Internal acoustic meatus, passage in the medial surface of the petrosal bone for N. facialis and N. vestibulocochlearis. A
- 2 *Porus acusticus internus.* The orifice of the internal acoustic meatus. B
- 3 *Fundus meatus acustici interni.* Fundus (floor) of the internal acoustic meatus. C
- 4 *Crista transversa.* Transverse crest, dividing the fundus into upper and lower parts.
- 5 *Area n. facialis [intermediofacialis].* Part of the fundus that receives the N. facialis. C
- 6 *Area cochleae.* Small cribriform area, spiral in appearance, transmits the fibers of N. cochlearis. C
- 7 *Tractus spiralis foraminosus.* Inward spiraling tract of minute foramina in the center of the Area cochleae. C
- 8 *Area vestibularis superior.* Small cribriform area that transmits the fibers of the N. utriculoampullaris. C
- 9 *Area vestibularis inferior.* Small cribriform area that transmits the fibers of the N. saccularis. C
- 10 *Foramen singulare.* Orifice for the N. ampullaris posterior. C
- 11 **AURIS MEDIA.** Middle ear, consists of tympanic cavity, tympanic membrane, auditory ossicles, and auditory tube.
- 12 **Cavum tympani.** Tympanic cavity, oblique space between Pars petrosa and tympanica of the temporal bone. In it the auditory ossicles transmit the vibrations of the tympanic membrane to the perilymphatic space in the internal ear. A
- 13 *Paries tegmentalis.* Dorsal wall of the tympanic cavity. D E
- 14 *Recessus epitympanicus.* Epitympanic recess, dorsal part of the tympanic cavity, containing the auditory ossicles. E
- 15 *Pars cupularis.* A rounded recess in the upper part of the Recessus epitympanicus. E
- 16 *Paries jugularis.* Caudovernal wall of the tympanic cavity. D
- 17 *Paries labyrinthicus.* Medial wall of the tympanic cavity, formed by the petrosal bone. E
- 18 *Fenestra vestibuli.* Vestibular window, closed by the base of the stapes by means of which the vibrations act on the perilymph in the internal ear. E
- 19 *Promontorium.* Promontory, the convexity on the medial wall of the tympanic cavity caused by the basal turn of the cochlea. E
- 20 *Sinus tympani.* Depression posterior to the Promontorium and Fenestra cochleae of man.
- 21 *Fenestra cochleae.* Cochlear window, round foramen in the medial wall of the tympanic cavity, communication to the Scala tympani, closed by the Membrana tympani secundaria. E
- 22 *Membrana tympani secundaria.* Secondary tympanic membrane, closing the Fenestra cochleae.
- 23 *Paries mastoideus.* Caudodorsal wall of the tympanic cavity. D
- 24 *Annexae mastoideae.* This term was introduced in the NA for the clinically important airspaces in the human mastoid. Similar spaces are present in su and bo.
- 25 *Cellulae tympanicae.* The subdivisions of the ventral part of the tympanic cavity, not present in Car. D
- 26 *Apertura tympanica canaliculi chordae tympani.* Tympanic opening of the canal for the Chorda tympani. D
- 27 *Paries caroticus.* Rostral wall of the tympanic cavity. D E
- 28 *Paries membranaceus.* Lateral wall of the tympanic cavity, formed mainly by the tympanic membrane. D



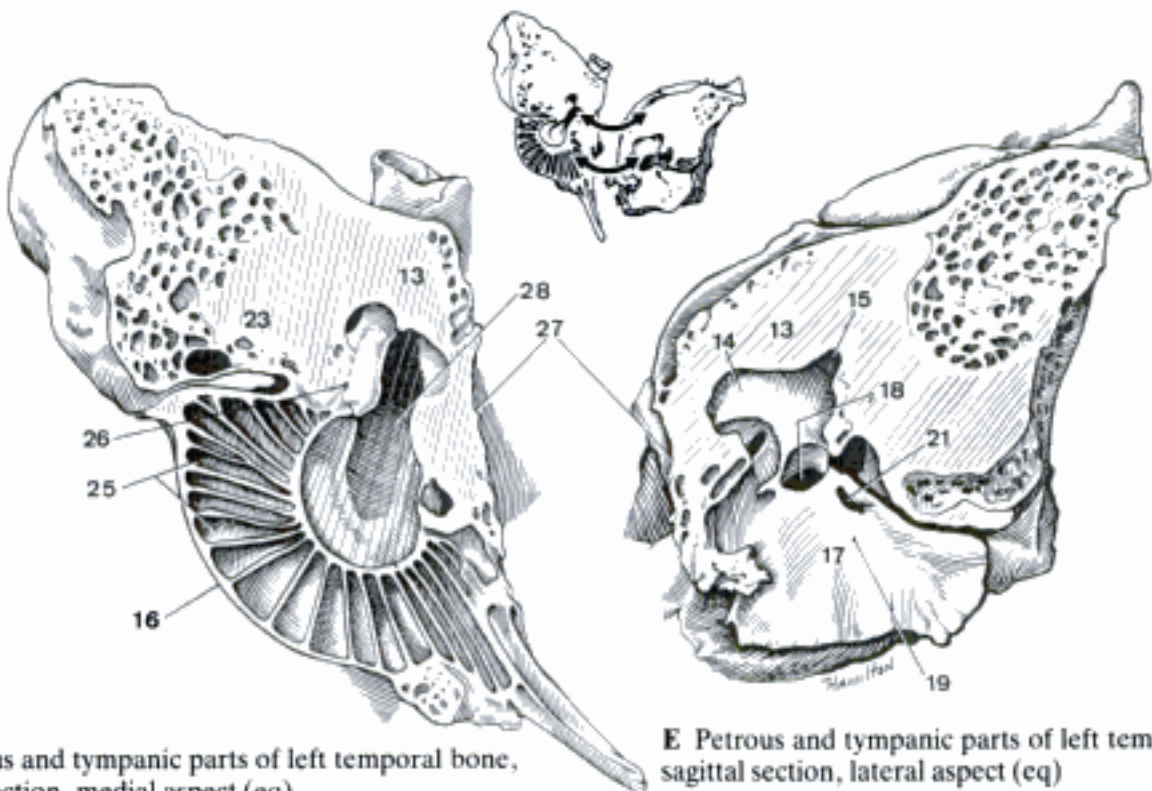
A Petrous and tympanic parts of left temporal bone, transverse section, rostral aspect (eq)



B Cranial cavity, medial aspect (bo)



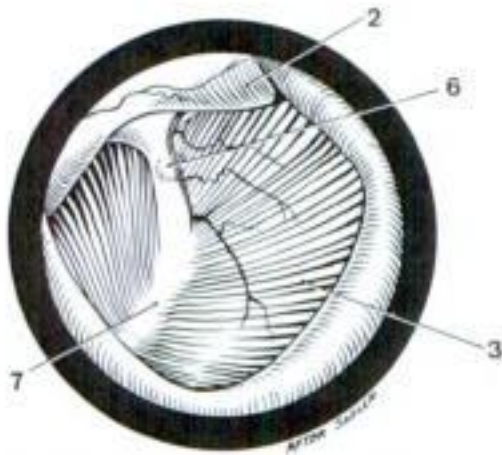
C Fundus of left internal acoustic meatus (eq)



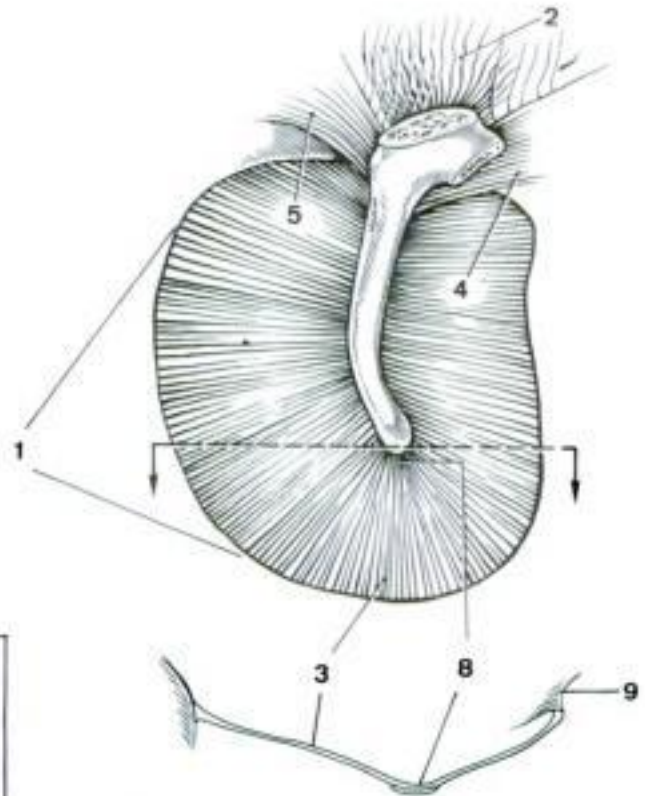
D Petrous and tympanic parts of left temporal bone, sagittal section, medial aspect (eq)

E Petrous and tympanic parts of left temporal bone, sagittal section, lateral aspect (eq)

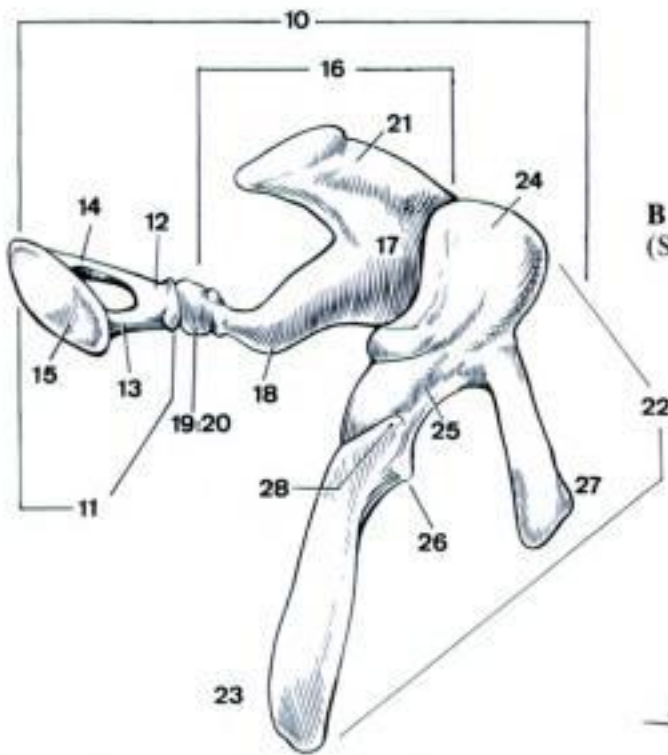
- 1 **Membrana tympani.** Tympanic membrane, obliquely placed at the medial end of the external acoustic meatus. B
- 2 *Pars flaccida.* Flaccid part, dorsal to the Pars tensa, closes the notch in the dorsal wall of the external acoustic meatus. A B
- 3 *Pars tensa.* Tense part, the large functional part attached to the Anulus tympanicus. A B
- 4 *Plica mallearis rostralis.* Rostral fold attaching the proximal part of the Manubrium mallei to the Anulus tympanicus. B
- 5 *Plica mallearis caudalis.* Caudal fold attaching the proximal part of the Manubrium mallei to the Anulus tympanicus. B
- 6 *Prominentia mallearis.* Elevation of the tympanic membrane caused by the Processus lateralis mallei. A
- 7 *Stria mallearis.* Light strip on the tympanic membrane caused by the Manubrium mallei. A
- 8 *Umbo membranae tympani.* The apex of the tympanic membrane, projecting into the tympanic cavity caused by the distal end of the Manubrium mallei. B
- 9 *Anulus fibrocartilagineus.* The fibrocartilaginous ring by means of which the tympanic membrane is attached to the osseous Anulus tympanicus. B D
- 10 **Ossicula auditus.** Auditory ossicles, three articulating bones, that transmit the vibrations of the tympanic membrane across the tympanic cavity to the perilymph in the Scala vestibuli. C
- 11 *Stapes.* Most internal auditory ossicle, articulates with the incus and closes the Fenestra vestibuli. C
- 12 *Caput stapedis.* Head of stapes, articulates with the incus through the interposed Os lenticulare. C
- 13 *Crus rostrale.* Limb of stapes, connecting head and base rostrally. C
- 14 *Crus caudale.* Limb of stapes, connecting head and base caudally. C
- 15 *Basis stapedis.* Base of stapes, closes the Fenestra vestibuli. C
- 16 *Incus.* Middle auditory ossicle, articulates with stapes and malleus. C
- 17 *Corpus incudis.* Body of incus, articulates with the malleus. C
- 18 *Crus longum.* Long process, articulates with the stapes. C
- 19 *Processus lenticularis.* Lenticular process, the end of the Crus longum which articulates with the stapes in man and occasionally ca. C
- 20 *Os lenticulare.* Minute accessory ossicle in the articulation between incus and stapes. C
- 21 *Crus breve.* Short process, attached to the wall of the Recessus epitympanicus. C
- 22 *Malleus.* Most external auditory ossicle, articulates with the incus, its manubrium is embedded in the tympanic membrane. C
- 23 *Manubrium mallei.* Handle-like process of the malleus which is embedded in the tympanic membrane. C
- 24 *Caput mallei.* Head of malleus, articulates with the incus. C
- 25 *Collum mallei.* Indistinct constriction between head and manubrium of the malleus. C
- 26 *Processus lateralis.* Short lateral process at the proximal end of the manubrium. C
- 27 *Processus rostralis.* Long rostral process, connected to the vicinity of the Anulus tympanicus. C
- 28 *Processus muscularis.* Muscular process, attachment of the M. tensor tympani. C



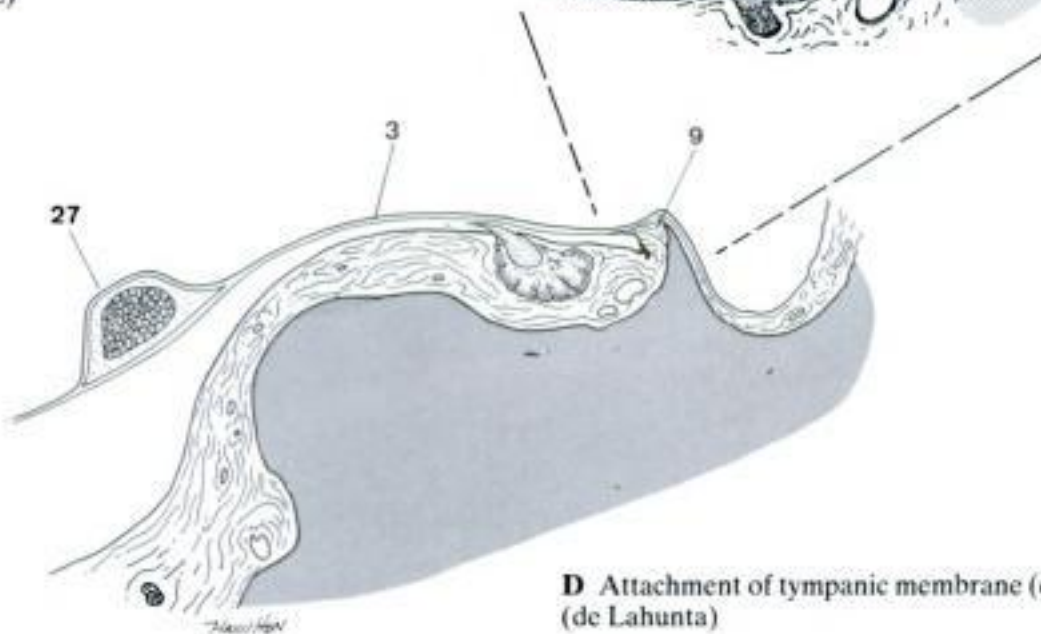
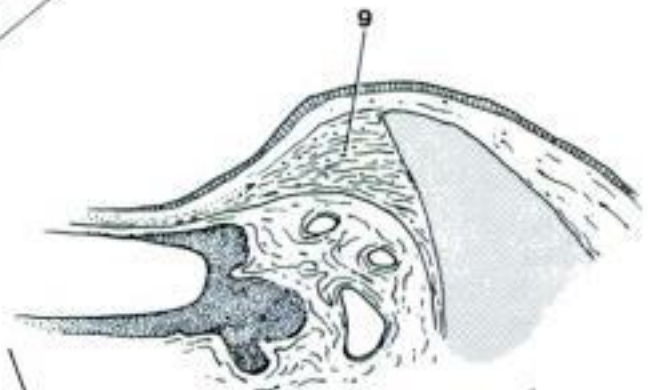
A Left tympanic membrane as seen through the otoscope (ca) (de Lahunta Habel)



B Left tympanic membrane, internal surface (ca) (Spreull)

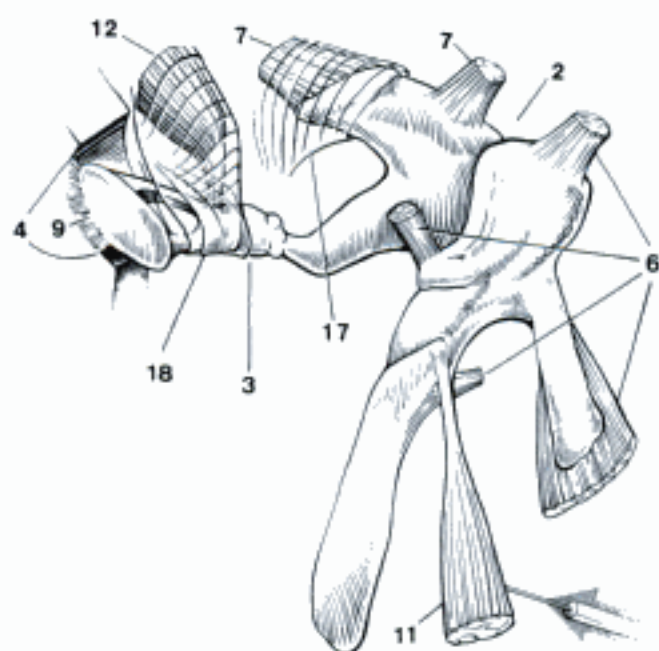


C Left auditory ossicles, rostromedial aspect (eq) (Holz)

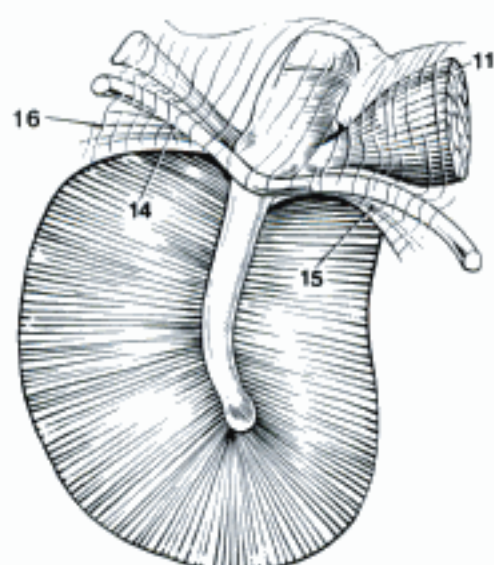


D Attachment of tympanic membrane (ca) (de Lahunta)

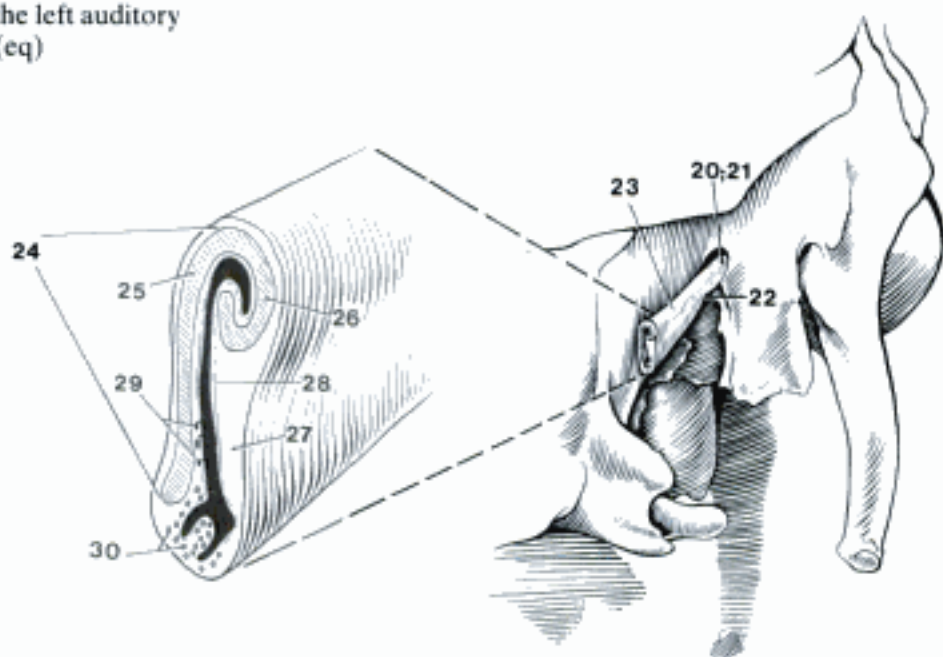
- 1 *Articulationes ossiculorum auditus*. Articulations of the auditory ossicles.
- 2 *Articulatio incudomallearis*. Articulation between the body of incus and the head of malleus. A
- 3 *Articulatio incudostapedia*. Articulation between the Crus longum of the incus, the Os lenticulare, and the head of stapes. A
- 4 *Syndesmosis tympanostapedia*. Attachment of the base of stapes to the margin of Fenestra vestibuli by the Lig. anulare stapedis. A
- 5 *Ligg. ossiculorum auditus*. Ligaments that attach the auditory ossicles to the walls of the tympanic cavity.
- 6 *Ligg. mallei*. Ligaments associated with the malleus. A
- 7 *Ligg. incudis*. Ligaments associated with the incus. A
- 8 *Membrana stapedis*. Stapedial membrane, closing the space between crura and base of stapes. D
- 9 *Lig. anulare stapedis*. Anular ligament of stapes, attaching the base of stapes to the margin of the Fenestra vestibuli. A D
- 10 *Mm. ossiculorum auditus*. Muscles associated with the auditory ossicles.
- 11 *M. tensor tympani*. Arises from the wall of the tympanic cavity, ends on the Processus muscularis of the malleus. A B
- 12 *M. stapedius*. Arises from the wall of the tympanic cavity, ends on the head of stapes, dampening the vibrations of the ossicles. A
- 13 **Tunica mucosa cavi tympani**. Mucous membrane lining the tympanic cavity, reflected over the auditory ossicles.
- 14 *Plica mallearis caudalis*. Caudal malleolar fold, from the Manubrium mallei to the caudal part of the Anulus tympanicus, contains the Chorda tympani. B
- 15 *Plica mallearis rostralis*. Rostral malleolar fold, from the Manubrium mallei to the rostral part of the Anulus tympanicus, contains the Chorda tympani. B
- 16 *Plica mallearis tympani*. Fold covering the Chorda tympani crossing the dorsal part of the tympanic membrane. B
- 17 *Plica incudis*. Fold reflected over the Crus breve of the incus. A
- 18 *Plica stapedis*. Fold reflected over the stapes and the M. stapedius. A
- 19 **Tuba auditiva**. Auditory tube, connecting the tympanic cavity with the nasopharynx. E
- 20 *Ostium tympanicum tubae auditivae*. Tympanic opening of the auditory tube. C
- 21 *Pars ossea tubae auditivae*. Osseous part of the auditory tube, the short caudal part, supported by the temporal and (in part) basisphenoid bones. C
- 22 *Isthmus tubae auditivae*. The constriction of the auditory tube at the junction of its osseous and cartilaginous parts. C
- 23 *Pars cartilaginea tubae auditivae*. Cartilaginous part of the auditory tube, the longer rostral part supported by cartilage. C
- 24 *Cartilago tubae auditivae*. Cartilage of the auditory tube, shaped like an inverted trough. C
- 25 Lamina [cartilaginis] medialis. Wider medial lamina of the cartilage. C
- 26 Lamina [cartilaginis] lateralis. Shorter lateral lamina of the cartilage. C
- 27 *Lamina membranacea*. The portion of the wall that is not supported by cartilage. C
- 28 *Tunica mucosa*. Mucous membrane, covered with pseudostratified ciliated epithelium containing goblet cells. C
- 29 *Glandulae tubariae*. Mucous or mixed glands in the wall of the auditory tube, esp. numerous in ov. C
- 30 *Lymphonoduli [Noduli lymphatici] tubarii*. Lymph nodules in the wall of the auditory tube, well developed in Ru and su, forming the tubal tonsil. C
- 31 *Ostium pharyngeum tubae auditivae*. Pharyngeal opening of the auditory tube, in the lateral wall of the nasopharynx. E
- 32 *Diverticulum tubae auditivae*. Gut-tural pouch of eq, caudoventral enlargement of the auditory tube with a capacity of about 300 ml. E



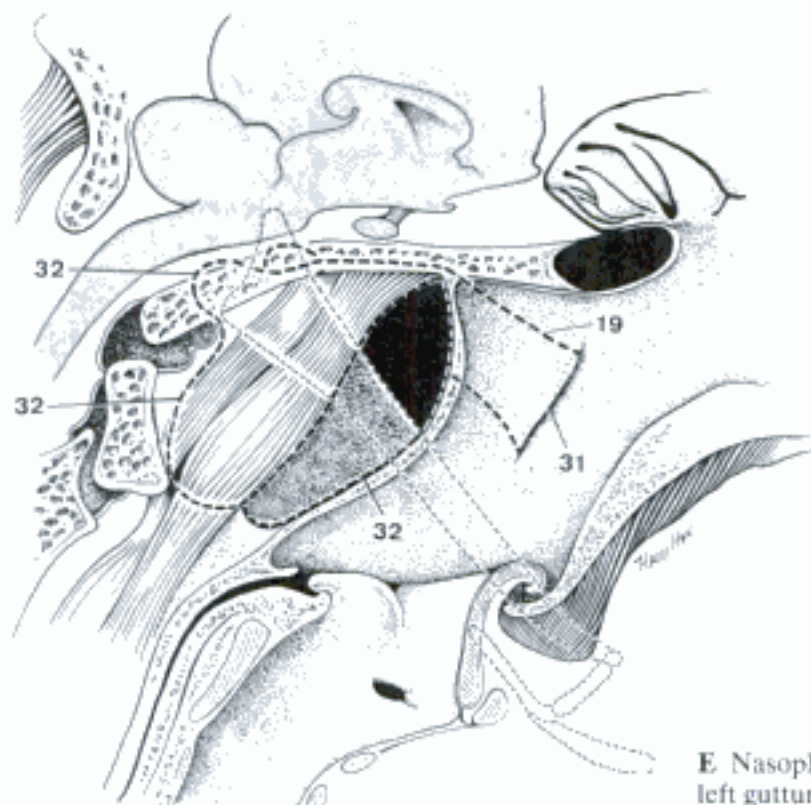
A Muscles and ligaments of the left auditory ossicles, rostromedial aspect (eq)



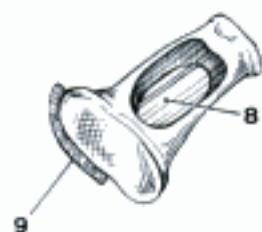B Left tympanic membrane, internal surface (ca) (Spreull)



C Left auditory tube, schematic (su)



E Nasopharynx (median section) and left guttural pouch (eq)

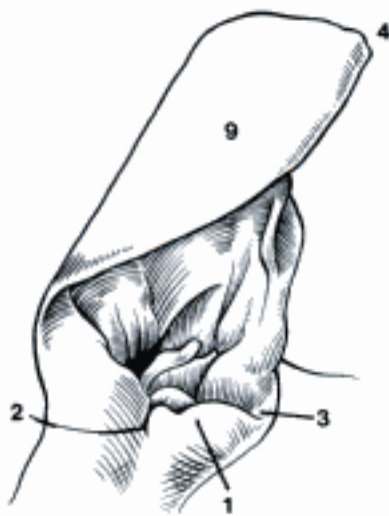


D Left stapes, rostromedial aspect (eq)

Hidden page

Hidden page

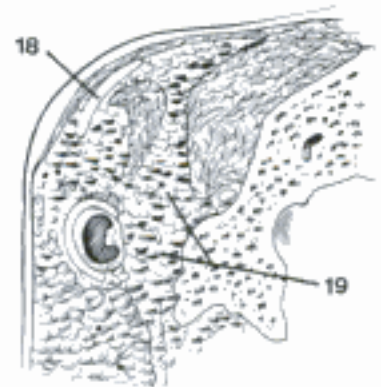
- 1 *Tragus*. An elongated prominence on the rostromedial border of the entrance to the Cavum conchae. A E
- 2 *Incisura pretragica [prae-]*. Pretragic notch, rostromedial to the tragus, separating it from the Crus heliis laterale. A B
- 3 *Incisura intertragica*. Intertragic notch, caudolateral to the tragus, separating it from the antitragus. A B E
- 4 *Apex auriculae*. Tip of the auricle. A
- 5 *Incisura terminalis*. Notch separating the Lamina tragi from the remainder of the auricular cartilage. E
- 6 *Incisura antitragohelicina*. Antitragohelicine notch, between the antitragus and the helix. E
- 7 *Processus styloideus*. Styloid process, the drawn-out proximal end of the auricular cartilage overlapping the anular cartilage caudolaterally, prominent in eq.
- 8 *Eminentia conchae*. The caudolateral bulge on the rolled-up part of the auricular cartilage indicating a change in direction of the lumen. E
- 9 *Dorsum auriculae*. The convex surface of the auricle. A
- 10 *Mm. auriculares*. Intrinsic auricular muscles, very small and of little importance.
- 11 *M. heliis*. On the Margo tragicus.
- 12 *M. heliis minor*. Between Crus heliis mediale and laterale, attached to Lamina tragi. 541 D
- 13 *M. tragicus*. Between Crus heliis laterale and Lamina tragi. 541 D
- 14 *M. antitragicus*. Caudal to Incisura intertragica. 541 E
- 15 *M. caudoantitragicus*. On the caudal surface of antitragus.
- 16 *M. transversus auriculae*. On the outer surface of concha. 541 F
- 17 *M. obliquus auriculae*. On the outer surface of concha. 541 F
- 18 *Cartilago scutiformis*. Scutiform cartilage, rostromedial to the base of the auricle, lying on M. temporalis and fat. It gives attachment to several muscles that move the auricle. C
- 19 *Corpus adiposum auriculare*. Auricular fat pad, surrounding the external acoustic meatus. C
- 20 **ORGANUM OLFACTUS**. Olfactory organ. D
- 21 *Regio olfactoria tunicae mucosae nasi*. Olfactory region. The olfactory mucosa on the caudal portions of the Conchae ethmoidales and the Septum nasi. D
- 22 *Glandulae olfactoriae*. Olfactory glands, serous glands deep to the olfactory epithelium. G
- 23 **ORGANUM VOMERONASALE**. Vomeronasal organ. The olfactory capability is thought to be related to sexual behavior and the recognition of kin. H
- 24 *Ductus vomeronasalis*. Vomeronasal duct, caudally blind-ending tube of olfactory mucosa and associated olfactory glands. H
- 25 *Cartilago vomeronasalis*. Vomeronasal cartilage, trough-shaped supporting the Ductus vomeronasalis. H
- 26 **ORGANUM GUSTUS**. Organ of taste, composed of all the taste buds.
- 27 *Caliculus gustatorius*. Taste bud, spindle-shaped aggregation of sustentacular and gustatory cells of the same height as the surrounding epithelium. The gustatory cells bear microvilli with which they project through the Porus gustatorius. F
- 28 *Porus gustatorius*. Taste pore, opening in the epithelium at the tip of the taste bud through which ingested substances reach the exposed ends of the gustatory cells. F



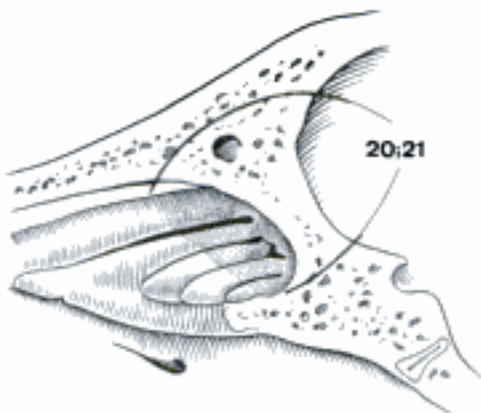
A Left auricle, shaved, rostralateral aspect (ca)



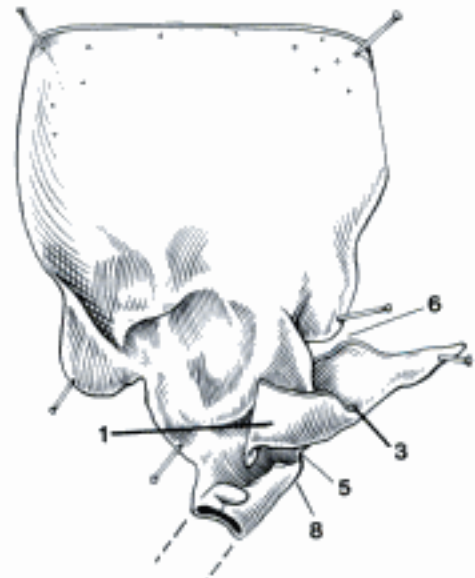
B Right Cartilagineus meatus acustici and anularis, rostralateral aspect (eq)



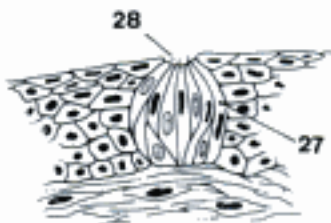
C Cartilago scutiformis and Corpus adiposum auriculare, transverse section (eq)



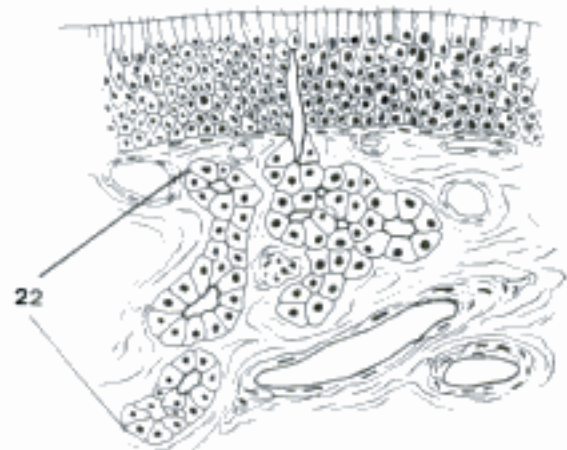
D Right nasal conchae (ov)



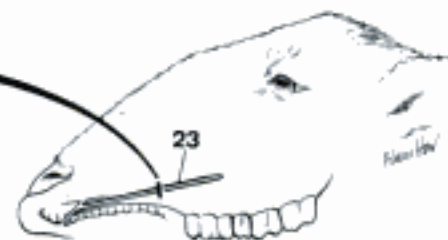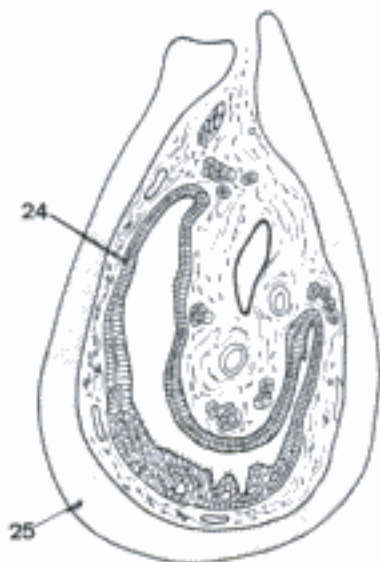
E Left auricular cartilage, rostral aspect (ca)



F Taste bud, histologic section

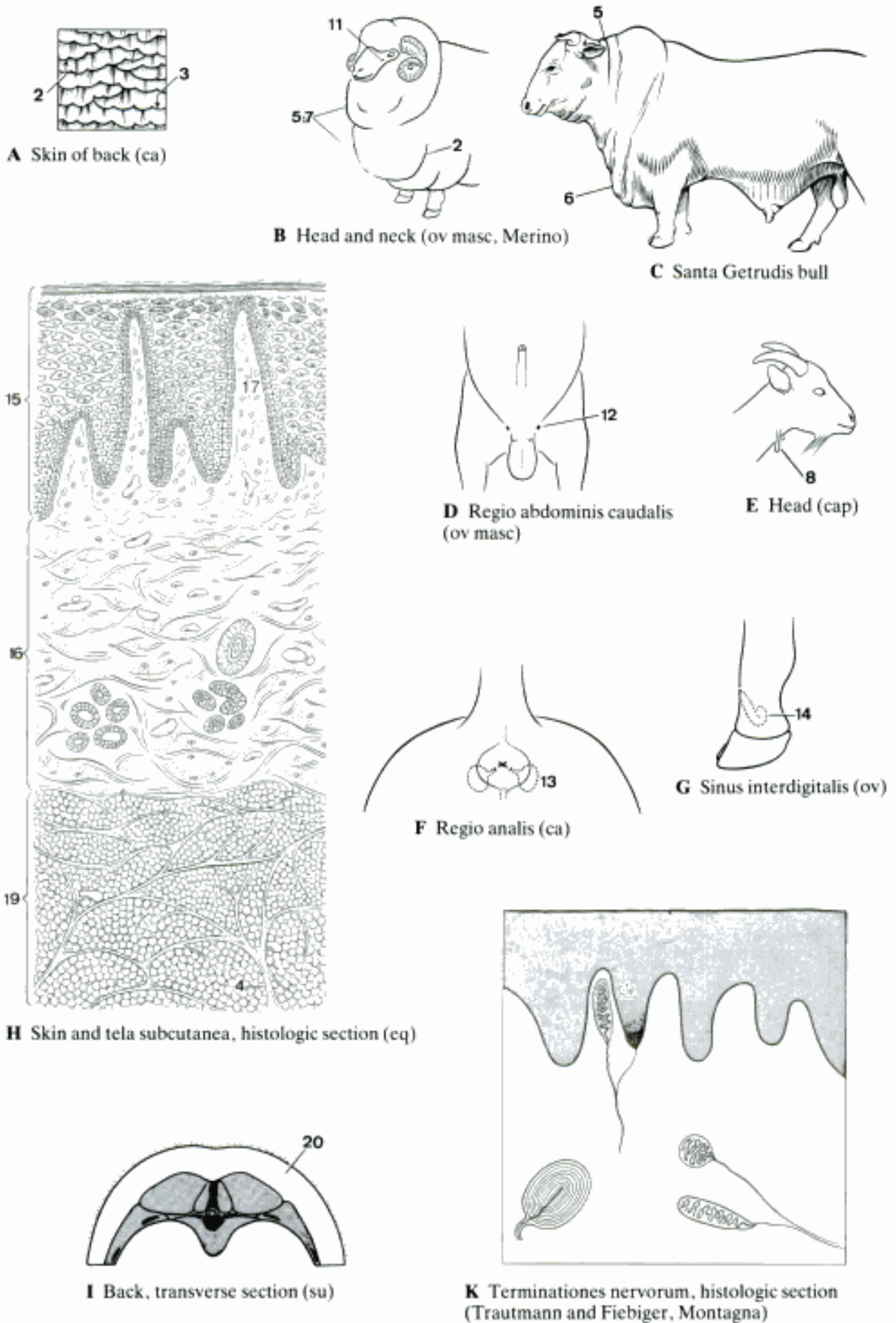


G Olfactory mucosa, histologic section



H Left Organum vomeronasale, lateral aspect and transverse section (ov) (Kratzing)

- 1 **CUTIS**. Skin, consisting of epidermis, dermis and tela subcutanea.
- 2 *Sulci cutis*. Grooves of the skin of various depths and locations. A B
- 3 *Cristae cutis*. Crests of the skin, formed by the epidermis and separated by small Sulci cutis. A
- 4 *Retinacula cutis*. Strands of connective tissue attaching the skin to underlying fascia or periosteum. H
- 5 *Plicae cutis*. Permanent folds of the skin in various regions. B C
- 6 *Palear (bo)*. Dewlap. C
- 7 *Plicae transversae colli (ov)*. Large permanent folds on the neck of Merino sheep. B
- 8 *Appendices colli (su, cap, ov)*. Wattles. Cutaneous appendages on the ventral surface of the neck containing a bar of cartilage; most commonly in cap. E
- 9 *Toruli tactiles (Car)*. Tactile elevations.
- 10 *Sinus cutanei*. General term for various cutaneous pouches.
- 11 *Sinus infraorbitalis (ov)*. Cutaneous pouch rostral to the eye, containing a fatty yellow secretion. B
- 12 *Sinus inguinalis (ov)*. Cutaneous pouch in the inguinal region, containing a fatty yellow secretion. D
- 13 *Sinus paranasalis (Car)*. Cutaneous sac, opening into the anus and containing a fatty gray secretion with an unpleasant odor. F
- 14 *Sinus interdigitalis (ov)*. Tubular invagination of the skin between the digits, containing a colorless waxy secretion. G
- 15 **Epidermis**. The stratified, squamous epithelium on the surface of the skin. H
- 16 **Dermis [Corium]**. The connective tissue layer of the skin deep to the epidermis, well supplied with vessels and nerves and containing the cutaneous glands. H
- 17 *Papillae*. Dermal projections of various length and thickness, also branched, that are received into corresponding depressions of the epidermis. H
- 18 *Terminationes nervorum*. Collective term for the sensory nerve endings. K
- 19 **Tela subcutanea**. Subcutaneous tissue consisting of collagenous and elastic fibers and fat. It merges with the overlying dermis and is loosely attached to the fascia deep to it. H
- 20 *Panniculus adiposus*. Thick deposit of fat in the tela subcutanea, such as the back fat in su. I
- 21 *Terminationes nervorum*. Collective term for the sensory nerve endings.



A Skin of back (ca)

B Head and neck (ov masc, Merino)

C Santa Getrudis bull

D Regio abdominis caudalis (ov masc)

E Head (cap)

F Regio analis (ca)

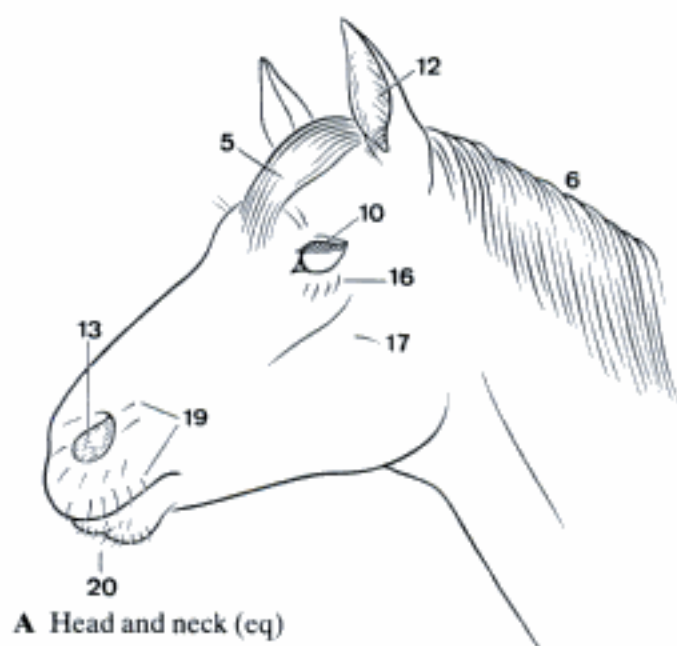
G Sinus interdigitalis (ov)

H Skin and tela subcutanea, histologic section (cq)

I Back, transverse section (su)

K Terminaciones nervorum, histologic section (Trautmann and Fiebiger, Montagna)

- 1 **Pili.** Hairs. Term for all types of hair.
- 2 *Capilli.* The hairs of the mammal's coat, except in ov (*Pili lanei*) and su (mostly *Setae*).
- 3 *Setae.* Bristles, the stiff hairs of su.
- 4 *Pili lanei.* Wool hairs, comprising the fleece of ov, and forming the undercoat in other species.
- 5 *Cirrus capitis.* Forelock, the most cranial hairs of the mane that fall onto the forehead of eq. A
- 6 *Juba.* Mane. A
- 7 *Cirrus caudae.* The long hairs of the tail. C
- 8 *Cirrus metacarpeus.* The tuft of long hairs on the fetlock in eq. B
- 9 *Cirrus metatarsus.* The tuft of long hairs on the fetlock in eq.
- 10 *Cilia.* Eye lashes. A
- 11 *Barba (cap).* Beard, the tuft of long hairs on the ventral surface of the lower jaw. D
- 12 *Tragi.* The hairs at the entrance to the external acoustic meatus. A
- 13 *Vibrissae.* The hairs in the nostrils. A
- 14 *Pili tactiles.* Tactile hairs. General term for the long stiff hairs, found mainly on the head, that are surrounded at the root by a blood sinus and numerous sensory nerve endings.
- 15 *Pili tact. supraorbitales.* Supraorbital tactile hairs, dorsal to the eye. D E
- 16 *Pili tact. infraorbitales.* Infraorbital tactile hairs, immediately ventral to the eye. A
- 17 *Pili tact. zygomatici.* Zygomatic tactile hairs, ventral or caudoventral to the eye. A E
- 18 *Pili tact. buccales.* Buccal tactile hairs, on the cheek. E
- 19 *Pili tact. labiales superiores.* Tactile hairs of the upper lip and around the nostrils. A
- 20 *Pili tact. labiales inferiores.* Tactile hairs of the lower lip. A
- 21 *Pili tact. mentales.* Mental tactile hairs, on the ventral surface of the lower jaw. E
- 22 *Pili tact. carpales (fe).* Carpal tactile hairs, on the caudomedial surface of the forearm, a short distance proximal to the carpal pad. F
- 23 *Apex pili.* Tip of the hair.
- 24 *Scapus pili.* Hair shaft, especially that portion that extends from the skin. G
- 25 *Radix pili.* Hair root, the embedded part of the hair. G
- 26 *Bulbus pili.* Bulb of the hair, the proximal enlarged part of the hair root. G
- 27 *Folliculus pili.* Hair follicle, invagination of the epidermis and connective tissue enclosing the embedded part of the hair. G
- 28 *Papilla pili.* Hair papilla, peg of connective tissue extending into the expanded proximal end of the hair. G
- 29 *Mm. arrectores pilorum.* Thin bundles of smooth muscle extending from the side of the hair follicle to the papillary layer of the dermis. They raise the hair. G
- 30 *Flumina pilorum.* Hair streams, fields of hairs pointing in one direction. H
- 31 *Vortex pilorum convergens.* Converging whorl of hair. H
- 32 *Vortex pilorum divergens.* Diverging whorl of hair. H
- 33 *Linea pilorum convergens.* Line or crest formed between two fields of converging hairs. H
- 34 *Linea pilorum divergens.* Line or trough formed between two fields of diverging hairs. H
- 35 *Cruces pilorum.* Cross-shaped hair pattern formed at the intersection of two lines of converging hair. H



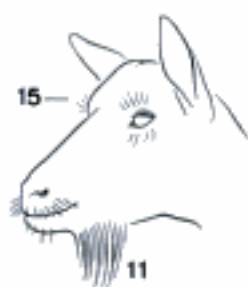A Head and neck (eq)



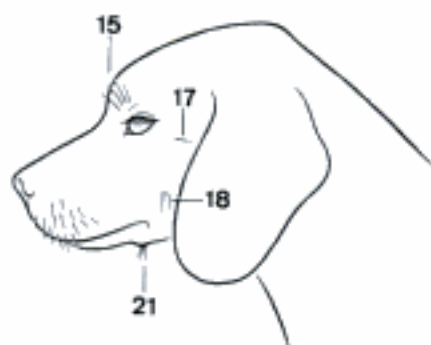
B Digit (eq)



C Tail (bo)



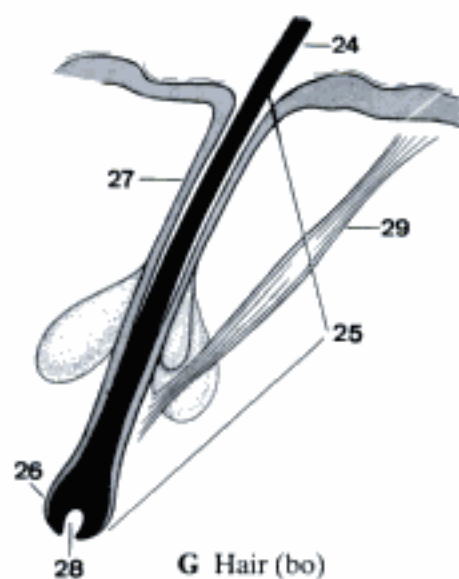
D Head (cap)



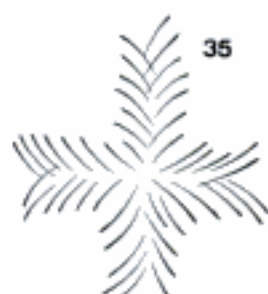

E Head (ca)



F Right manus, palmar aspect (fe)

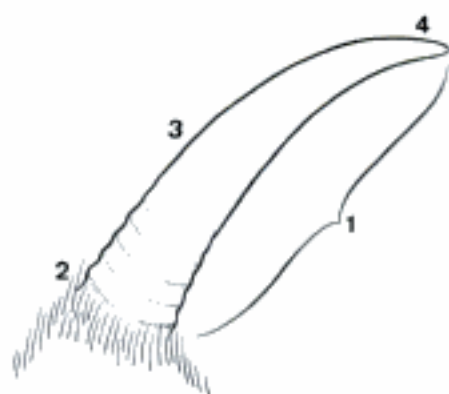


G Hair (bo)

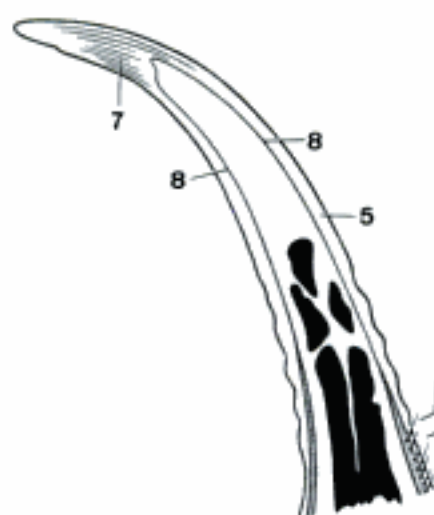


H Flumina pilorum

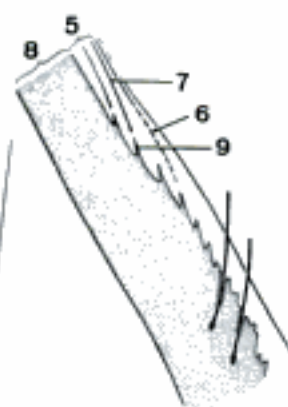
- 1 **CORNU.** The horn of Ru. A
- 2 *Basis cornus.* Base of the horn, the wide proximal part. A
- 3 *Corpus cornus.* Body of the horn, the elongated part between base and apex. A
- 4 *Apex cornus.* The pointed tip of the horn. A
- 5 *Epidermis cornus.* The epithelium of the horn, including the living cells and the cornified external part of the horn. It is homologous to the epidermis of the skin and covers the dermis of the horn. B C
- 6 *Epiceras.* The zone of soft horn at the base of the horn. It is intermediate in character between the epidermis of the skin and that of the horn and corresponds to the Epidermis limbi (Perioplum) of the hoof. C
- 7 *Tubuli epidermales.* Horn tubules growing off the papillae of the dermis. They are parallel to the direction of growth of the horn and are connected by intertubular horn. B C
- 8 *Dermis [Corium] cornus.* Dermis of the horn. The very vascular fibrous layer between the osseous cornual process and the epidermis of the horn. It corresponds to the dermis of the skin. B C
- 9 *Papillae dermales [coriales].* Projections of the dermis of the horn which fit into conical depressions of the epidermis of the horn. The tubuli epidermales originate from the deep layers of the epidermis that cover the papillae. C
- 10 **TORI.** Pads, consist of a thick epidermis, dermis and a subcutaneous cushion, Pulvinus, which may, however, be absent.
- 11 *Torus carpeus.* Carpal pad. In Car on the palmar surface of the carpus. In eq it is known as the chestnut and is on the caudomedial surface of the forearm proximal to the carpus. D E
- 12 *Torus tarseus.* Tarsal pad. Present only in eq as the chestnut on the caudomedial surface of the tarsus. F
- 13 *Torus metacarpeus.* Metacarpal pad. In Car on the palmar surface of the Regio metacarpophalangea. D
- 14 *Calcar metacarpeum.* Ergot, a rudiment of the metacarpal pad on the palmar surface of the Regio metacarpophalangea in eq. E
- 15 *Torus metatarseus.* Metatarsal pad. In Car on the plantar surface of the Regio metatarsophalangea, similar to metacarpal pad.
- 16 *Calcar metatarseum.* Ergot, a rudiment of the metatarsal pad on the plantar surface of the Regio metatarsophalangea in eq. F
- 17 *Torus digitalis.* Digital pad, on the palmar (plantar) surface of each digit in Car. D
- 18 *Torus ungulae.* Digital pad on the Facies solearis of the hoof palmar to the sole. G



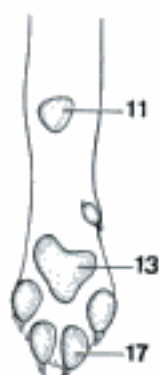
A Left horn, lateral aspect (cap)



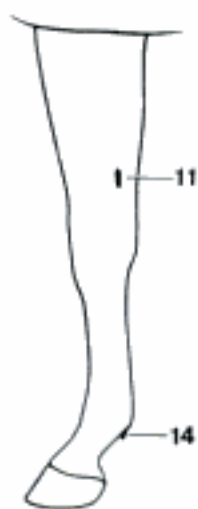
B Horn, longitudinal section (cap)



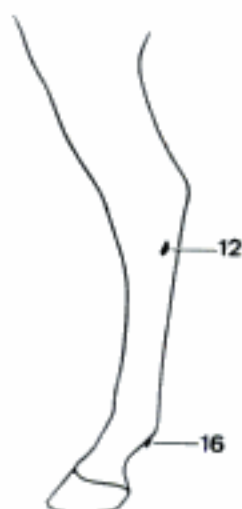C Epicerias, schematic section (cap)



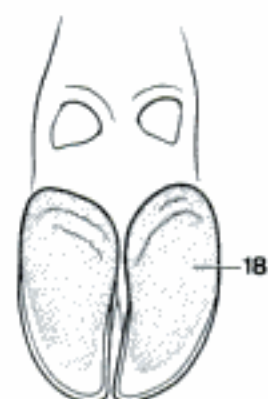
D Left manus, palmar aspect (ca)



E Right thoracic member, medial aspect (eq)



F Right pelvic member, medial aspect (eq)

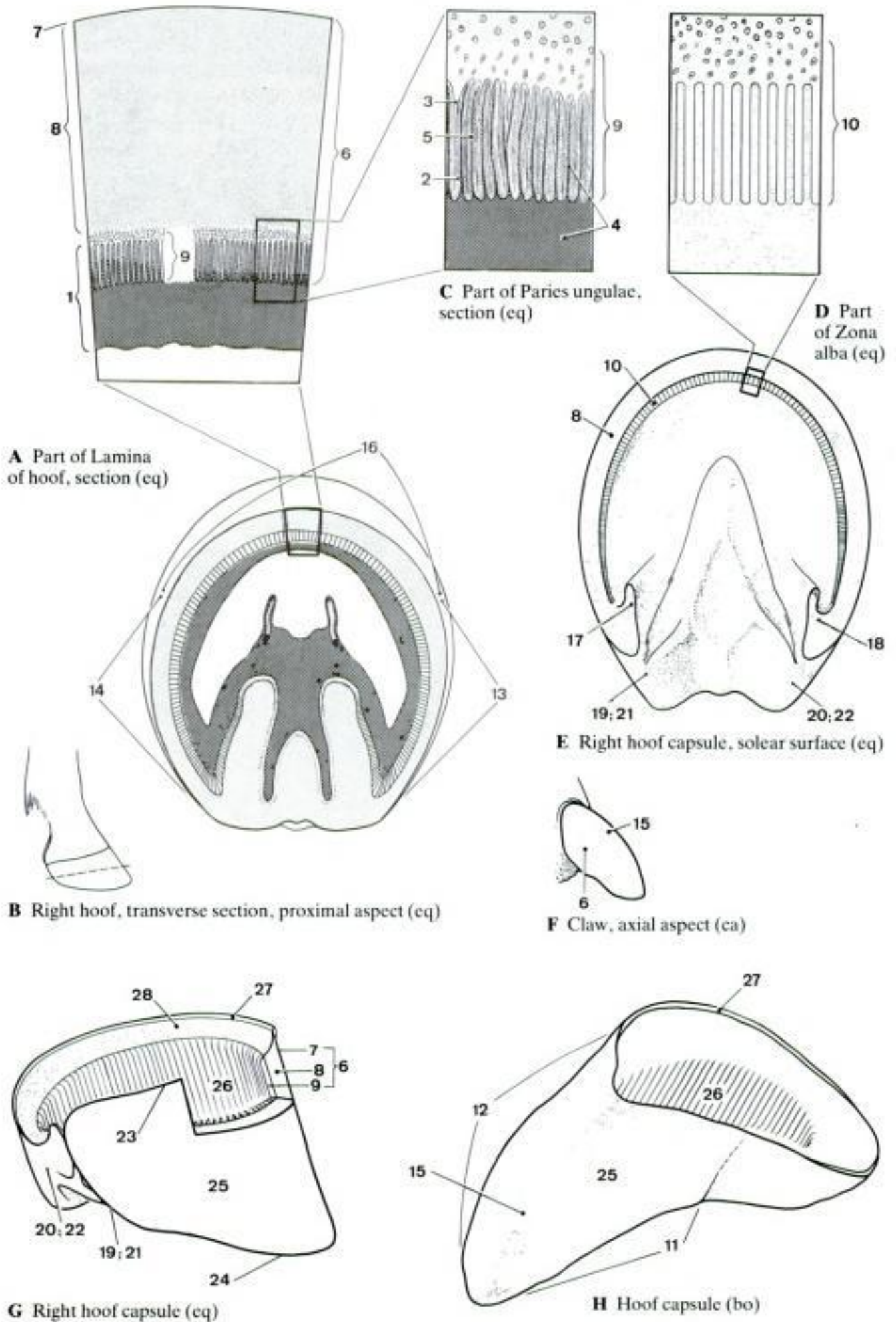


G Digits of manus, palmar aspect (bo)

- 1 **UNGUICULA.** Claw of Car, including the cornified epidermis, the dermis and the tela subcutanea. A
- 2 **UNGULA.** Hoof, including the cornified epidermis, the dermis and the tela subcutanea; in su, Ru and eq. C
- 3 **Limbus [Vallum, Car].** The narrow band of modified skin forming the proximal part of the claw or hoof, and including the tela subcutanea, dermis and epidermis. The latter is intermediate in character between the epidermis of the skin and that of the claw or hoof. In Car, this band and the skin proximal to it form a fold, Vallum, that partly covers the claw. A B D
- 4 *Epidermis limbi [Perioplum, Un].* The soft horn produced by the Limbus growing distally with the claw or hoof. The Epidermis limbi of the hoof is known as the periople and forms the Stratum externum of the horny wall of the hoof. C D
- 5 *Tubuli epidermales (Un).* Horn tubules growing off the papillae of the Dermis limbi. They are parallel to the direction of the growth of the hoof and are connected by intertubular horn. D
- 6 *Dermis [Corium] limbi.* Limbic (perioplic) dermis [corium], underlying and nourishing the Epidermis limbi. It is continuous with the dermis of the skin proximally and with the Dermis coronae of the claw or hoof distally. B D
- 7 *Papillae dermales [coriales].* Projections of the limbic (perioplic) dermis [corium] which fit into conical depressions of the Epidermis limbi. D
- 8 *Tela subcutanea limbi [Pulvinus limbi, Un].* The subcutaneous tissue of the limbus which may be slightly raised to form a bandlike cushion, Pulvinus limbi. D
- 9 **Corona.** The bandlike proximal segment of the claw or hoof deep and distal to the limbus. It includes the tela subcutanea, dermis and epidermis. The latter grows distally over the distal phalanx and forms the middle, or thickest, layer of the horny wall. D
- 10 *Epidermis coronae.* The epidermis produced by the coronary segment of the claw or hoof. It consists proximally of a thin layer of proliferating cells followed by a mass of cornified cells which form the Stratum medium of the horny wall (Lamina). D
- 11 *Tubuli epidermales (Un).* Horn tubules, about 160 μm in diameter, growing distally off the papillae of the coronary corium and making the epidermis much thicker and stronger. The tubules are embedded in intertubular horn; their spiral nature makes the wall of the hoof elastic to proximodistal compression. D
- 12 *Dermis [Corium] coronae.* Coronary dermis [corium], a band of dermis at the proximal border of the claw or hoof nourishing the Epidermis coronae. It is continuous proximally with the Dermis limbi and distally with the Dermis parietis. D
- 13 *Papillae dermales [coriales].* Projections of the coronary dermis [corium] which fit into conical depressions of the Epidermis coronae. D
- 14 *Tela subcutanea coronae [Pulvinus coronae, Un].* Subcutaneous tissue of the coronary segment (Corona). It bulges outward in eq to form a bandlike cushion, Pulvinus coronae.

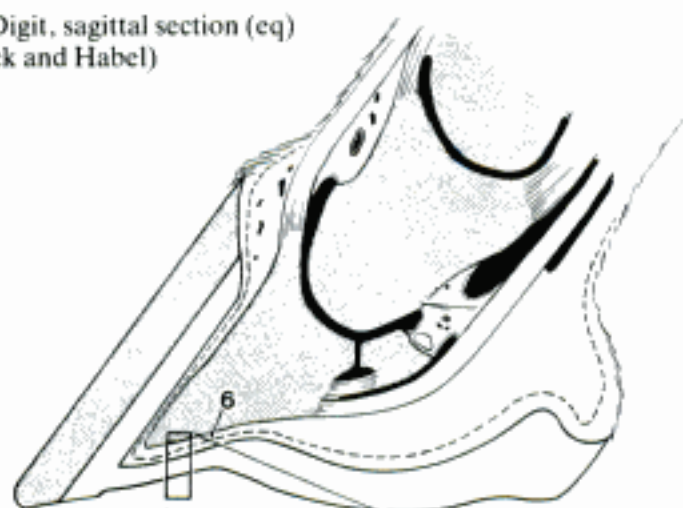
Hidden page

Hidden page

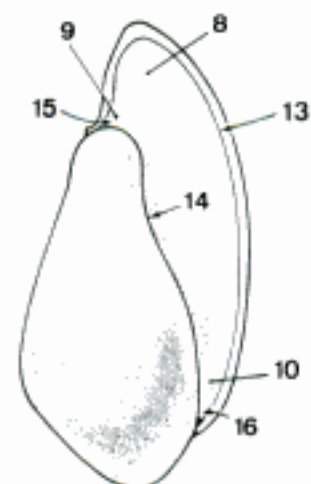
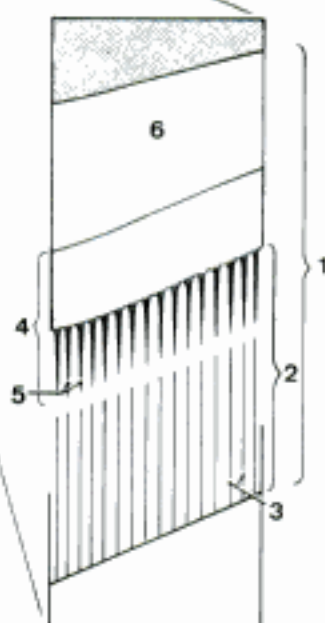


Hidden page

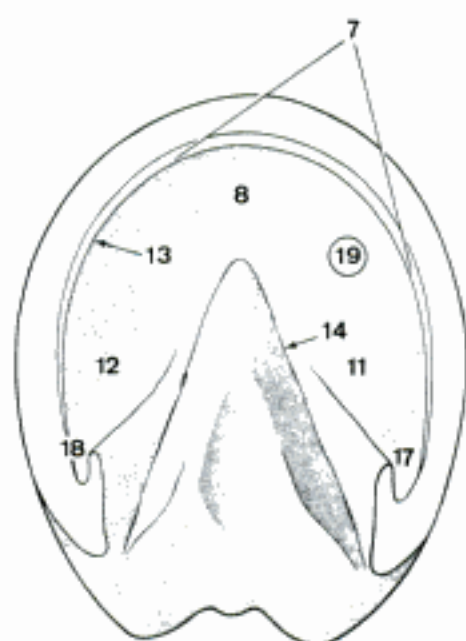
A Digit, sagittal section (eq)
(Sack and Habel)



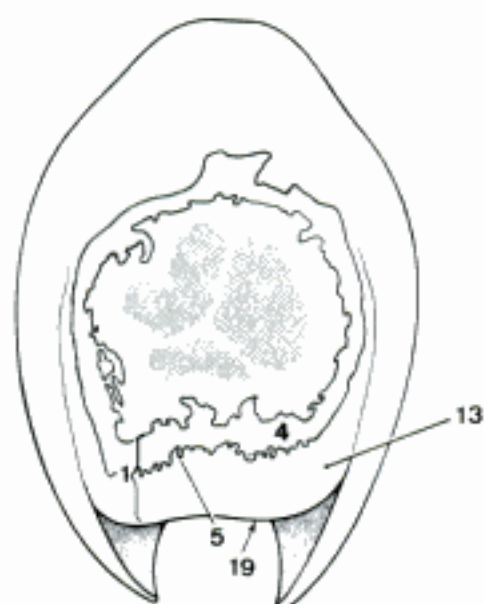
B Sole segment, histologic section (eq)
(Sack and Habel)



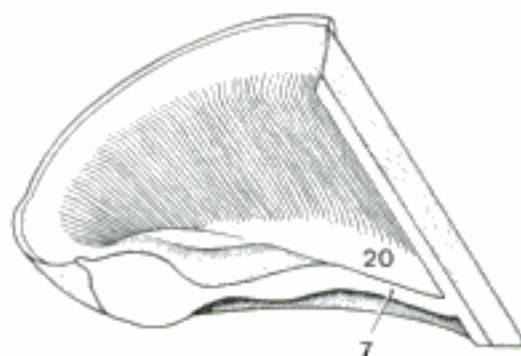
C Hoof capsule, solear surface (su)



D Left hoof capsule, solear surface (eq)



E Claw, transverse section (ca)

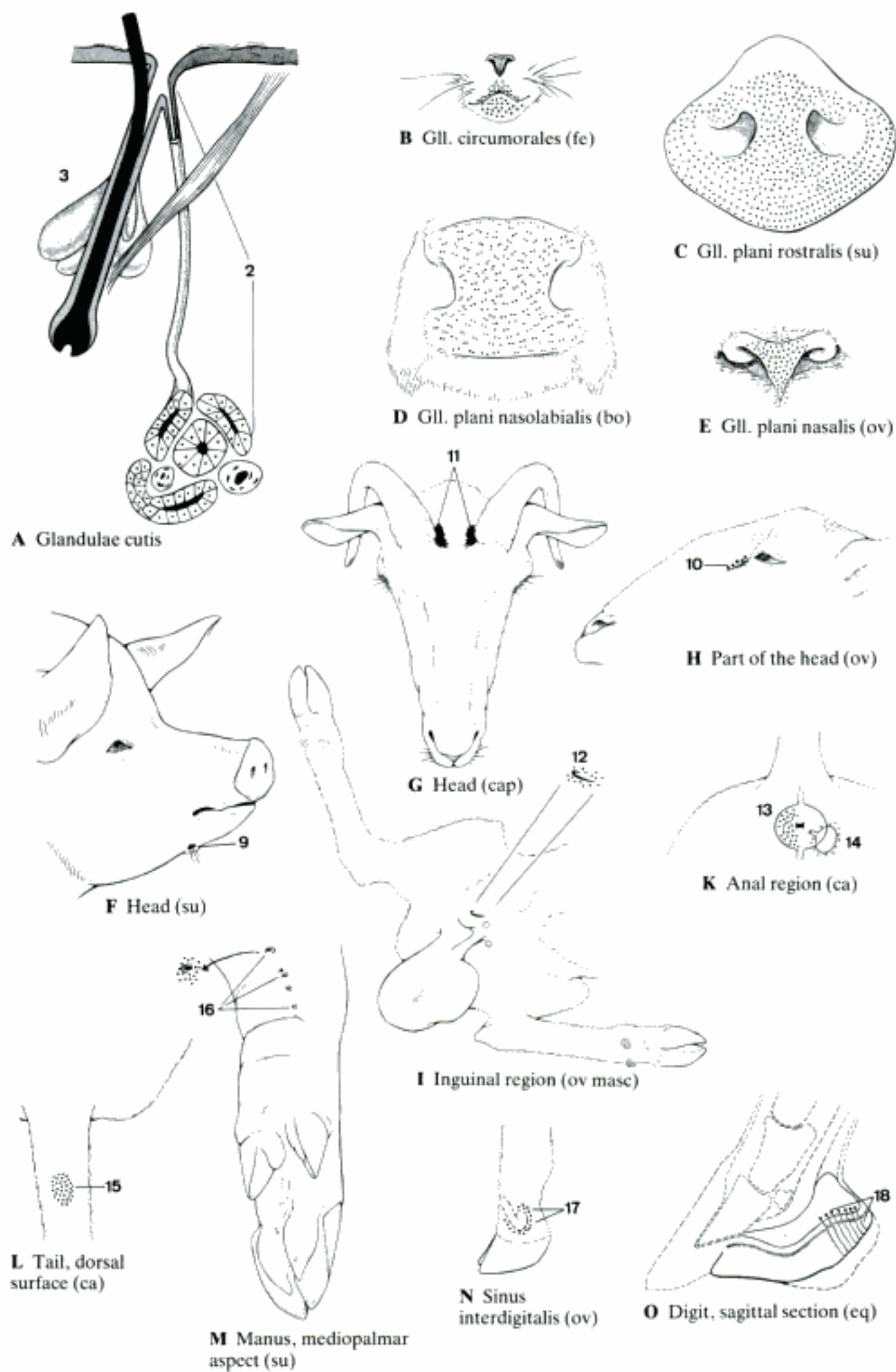


F Hoof capsule, sagittal section (eq)

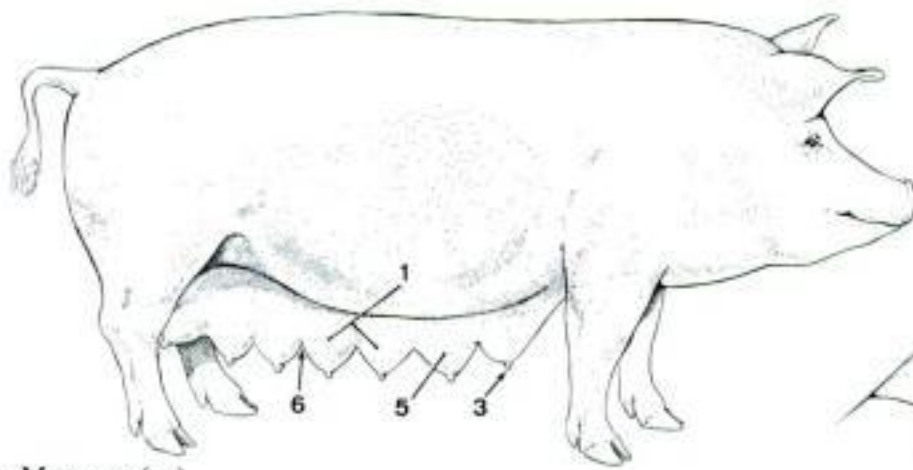
- 1 **Torus digitalis.** Digital pad, including tela subcutanea, dermis, and epidermis. A
- 2 **Torus ungulae.** Pad of the hoof, occupies the space between the borders of the wall and projects into the sole. B
- 3 *Epidermis tori.* Epidermis of the digital pad, consisting of a thin layer of proliferating cells covered by a mass of cornified cells. F
- 4 *Tubuli epidermales (Un).* Horn tubules, growing distally off the papillae of the dermis, embedded in intertubular horn. F
- 5 *Dermis [Corium] tori.* Dermis [corium] of the digital pad or pad of the hoof. F
- 6 *Papillae dermales [coriales].* Distally directed projections of the dermis [corium]. F
- 7 *Tela subcutanea tori [Pulvinus digitalis].* Thick layer of connective tissue deep to the dermis of the digital pad, known as the digital cushion. C F
- 8 *Pars torica pulvini digitalis.* The palmar (plantar) part of the Pulvinus digitalis in eq. E
- 9 *Torus corneus.* Horny pad of the hoof. C G
- 10 *Pars lateralis (eq).* Lateral rounded prominence above the palmar (plantar) border of the wall (heel), known as the bulb of the heel. D
- 11 *Pars medialis (eq).* See 10. D
- 12 *Apex tori.* Apex of the digital pad which in su and Ru projects dorsally into the sole. B G
- 13 *Basis tori.* Palmar (plantar) part of the digital pad, in su and Ru. G
- 14 *Facies externa.* External surface. G
- 15 *Facies interna.* Internal surface. H
- 16 **Cuneus ungulae.** Apex tori of the hoof in eq, known as the frog. E
- 17 *Epidermis cunei.* Epidermis of the frog, consisting of a thin layer of proliferating cells followed by a mass of cornified cells. F
- 18 *Tubuli epidermales.* Horn tubules, growing distally off the papillae of the Dermis cunei, embedded in intertubular horn. F
- 19 *Dermis [Corium] cunei.* Dermis [corium] of the frog. F
- 20 *Papillae dermales [coriales].* Distally directed projections of the dermis [corium]. F
- 21 *Tela subcutanea cunei [Pars cunealis pulvini digitalis].* Thick layer of connective tissue of the frog, the cuneal part of the digital cushion. E F
- 22 *Cuneus corneus.* Cornified part of the Epidermis cunei, the horny frog. I
- 23 *Apex cunei.* Apex of the wedge-shaped frog directed dorsally into the sole. I
- 24 *Basis cunei.* The wide part of the wedge-shaped frog between the Partes inflexae parietis (bars). I
- 25 *Crus cunei laterale.* Lateral crus of the frog. I
- 26 *Crus cunei mediale.* Medial crus of the frog. I
- 27 *Facies externa.* External surface. I
- 28 *Facies interna.* Internal surface. K
- 29 *Sulcus paracunealis lateralis.* Groove on the side of the frog, bounded laterally by the sole and the bar. I
- 30 *Sulcus paracunealis medialis.* See 29. I
- 31 *Sulcus cunealis centralis.* Central groove on the external surface of the frog. I
- 32 *Spina cunei.* Spine of the frog ("frog-stay"), central ridge on the internal surface of the horny frog. K
- 33 *Capsula ungulae.* Horny hoof, consisting of the cornified cells of limbus, corona, wall, sole and digital pad. K

Hidden page

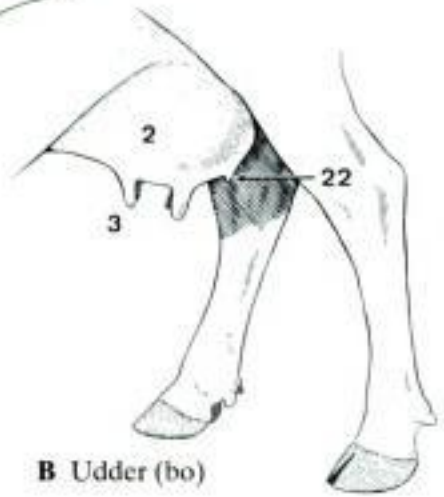
Hidden page



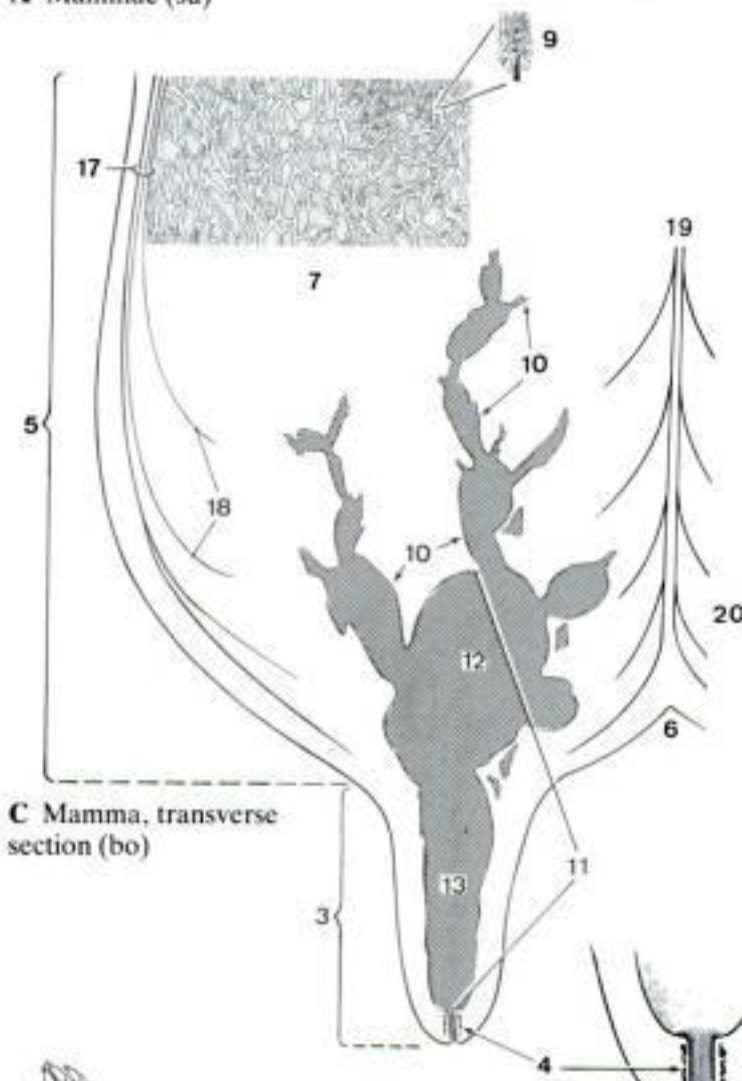
- 1 **MAMMA.** One mammary complex consisting of one Corpus and one Papilla mammae (teat, nipple) and homologous to one human breast. The usual number of mammae is: dog 10, cat 8, pig 14, cow 4, sheep, goat, and horse 2. A
- 2 *Uter.* Udder, the collective term for all the mammae in Ru and eq. B
- 3 *Papilla mammae.* The projection on the ventral surface of each mamma through which the milk is withdrawn; known as the nipple in Car and su, and as the teat in Ru and eq. A B C
- 4 *M. sphincter papillae.* Smooth muscle fibers surrounding Ductus papillaris, known as the teat sphincter in Ru. C D
- 5 *Corpus mammae.* The conical body of a mamma, consisting of skin, glandular tissue and connective tissue. It is attached at its base to the ventral surface of the trunk and is continued apically by the Papilla mammae. A C
- 6 *Sulcus intermammaris.* Intermammary groove, either longitudinal or transverse, separating adjacent mammae. A C
- 7 *Glandula mammaria.* Single gland and associated duct system of a mamma. The usual number of glands per mamma is: fe 5–7, ca 8–14, su 2, Ru 1, eq 2. C E
- 8 *Lobi glandulae mammariae.* The macroscopic subdivision of the Glandula mammaria separated by connective tissue. E
- 9 *Lobuli glandulae mammariae.* Mammary lobule, a cluster $1 \times 1.5 \times 0.5$ mm in size, of 150–200 (cow) alveoli secreting into a central ductule and separated from adjacent lobules by a thin layer of connective tissue. C
- 10 *Ductus lactiferi.* Lactiferous ducts, of various diameters, often ampullate, convey the milk to the Sinus lactifer in the ventral part of the Corpus mammae. C
- 11 *Sinus lactifer.* Lactiferous sinus, dilated distal part of the duct system formed by the confluence of the larger Ductus lactiferi, extending into the Papilla mammae. C
- 12 *Pars glandularis.* Glandular part, in the ventral end of the Corpus mammae. C
- 13 *Pars papillaris.* Papillary part, in the papilla and usually set off from the glandular part by a constriction. C
- 14 *Ductus papillaris.* Papillary duct, in the tip of the Papilla mammae, connecting the Pars papillaris sinus lactiferi with the outside. D E
- 15 *Ostium papillare.* Papillary opening of the Ductus papillaris on the tip of the Papilla mammae. D E
- 16 *Apparatus suspensorius mammaris.* Suspensory apparatus, the medial and lateral sheets of collagenous and elastic tissue that originate from the body wall and suspend the mammae; especially well developed in the heavy pendulous udder of the dairy cow. F
- 17 *Laminae laterales.* Connective tissue sheets on the lateral surface of the mamma. C F
- 18 *Lamellae suspensoriae.* Suspensory lamellae, thin sheets of connective tissue originating from the Laminae laterales and entering the mamma at different levels, thus supporting the weight. C F
- 19 *Laminae mediales [Ligamentum suspensorium uberis].* The elastic connective tissue sheets on the medial surface of the mamma. The laminae of each side are apposed in the median plane and form the Lig. suspensorium uberis between the right and left halves of the udder. C F
- 20 *Lamellae suspensoriae.* Suspensory lamellae, thin sheets of connective tissue originating from the Laminae mediales, entering the mamma at different levels, thus supporting the weight. C F
- 21 *Mamma masculina.* Rudimentary mamma of the male. Since functional glandular tissue does not usually develop, a Corpus mammae is not formed and only the papilla is present. G
- 22 (*Mamma accessoria*). Supernumerary mamma, occasionally functional, either cranial or caudal to the normally existing. B



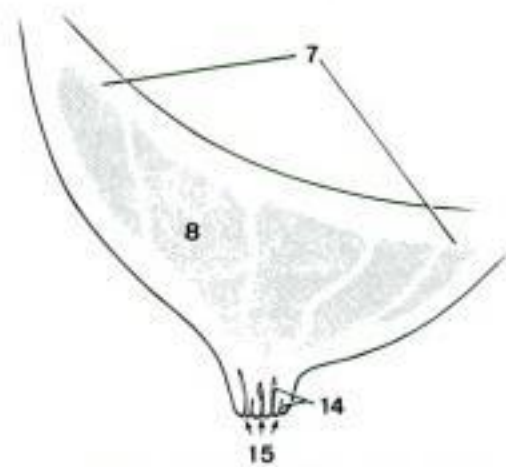
A Mammae (su)



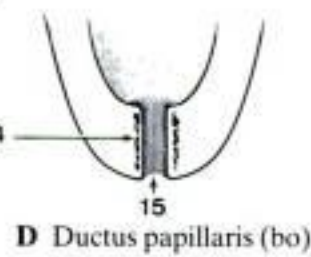
B Udder (bo)



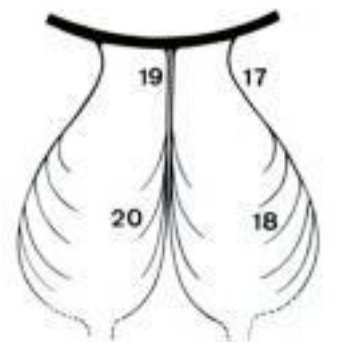C Mamma, transverse section (bo)



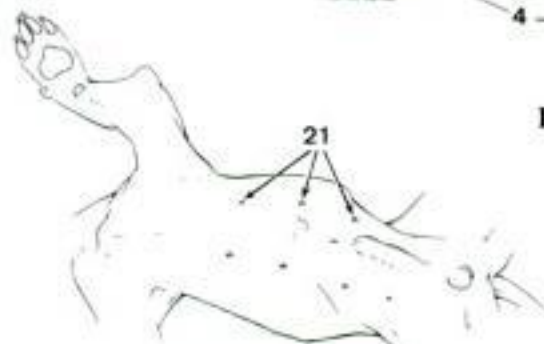E Mamma, transverse section (ca)



D Ductus papillaris (bo)



F Apparatus suspensorius mammarius, schematic (bo)



G Mammae masculinae (ca)

CAPUT. Head**Cranium***Vertex.* Crown of the head*Sinciput.* Rostral part of the cranium*Frons.* Forehead*Occiput.* Caudal part of the cranium*Tempora.* Temples*Cornu.* Horn*Auris.* Ear*Auricula.* Auricle**Facies.** Face*Oculus.* Eye*Palpebra superior.* Upper eyelid*Palpebra inferior.* Lower eyelid*Rima palpebrarum.* Palpebral fissure*Bulbus oculi.* Eyeball*Sulcus infrapalpebralis.* Infrapalpebral groove*Nasus.* Nose*Dorsum nasi.* Bridge of the nose*Apex nasi.* Apex of the nose*Ala nasi.* Wing of the nose*Naris.* Nostril*Planum nasale.* Nasal plane*Planum nasolabiale.* Nasolabial plane*Rostrum**Planum rostrale.* Rostral plane*Os.* Mouth*Labium superius.* Upper lip*Labium inferius.* Lower lip*Rima oris.* Opening of mouth*Cavum oris.* Oral cavity*Lingua.* Tongue*Fauces.* Entrance to pharynx*Bucca [Mala].* Cheek*Mentum.* Chin*Sulcus mentolabialis.* Mentolabial groove**COLLUM.** Neck*Cervix.* Neck*Nucha.* Back of the neck*Juba.* Mane*Paelear.* Dewlap*Larynx**Prominentia laryngea.* Laryngeal prominence*Pharynx**Trachea**Esophagus [Oesophagus]***TRUNCUS.** Trunk**Dorsum.** Back*Columna vertebralis.* Vertebral column*Lumbus.* Loin**Thorax***Cavum thoracis.* Thoracic cavity*Pectus.* Breast*Mamma thoracica.* Thoracic mamma*Papilla mammae.* Nipple (Car, su), teat (Ru, eq)**Abdomen***Cavum abdominis.* Abdominal cavity*Umbilicus.* Navel*Latus.* Flank*Plica lateris.* Fold of the flank*Inguen.* Groin*Mamma abdominalis.* Abdominal mamma*Papilla mammae.* Nipple (Car, su), teat (Ru, eq)*Mamma inguinalis.* Inguinal mamma*Papilla mammae.* Nipple (Car, su), teat (Ru, eq)*Sulcus intermammarius.* Intermammary groove*Uber.* Udder. All the mammae collectively in Ru and eq*Preputium [Praeputium].* Prepuce*Scrotum***Pelvis***Cavum pelvis.* Pelvic cavity*Coxa.* Hip*Nates [Clunes].* Part of the pelvis dorsal to the level of the Tuber ischiadicum on both sides, known as the croup or rump*Perineum*

Anus

Crena ani. Anal cleft

Pudendum femininum [Vulva]. Female pudendum

CAUDA. Tail

Radix caudae. Root of the tail

Cirrus caudae. Long hairs of the tail

MEMBRA. Limbs

Membrum thoracicum. Thoracic limb

Axilla

Plica axillaris. Axillary fold

Brachium. Arm

Facies cranialis. Cranial surface

Facies caudalis. Caudal surface

Facies lateralis. Lateral surface

Facies medialis. Medial surface

Sulcus bicipitalis lateralis. Lateral bicipital groove

Sulcus bicipitalis medialis. Medial bicipital groove

Cubitus. Elbow.

Antebrachium. Forearm

Facies cranialis. Cranial surface

Facies caudalis. Caudal surface

Facies lateralis. Lateral surface

Facies medialis. Medial surface

Manus

Dorsum manus. Dorsum of manus

Palma manus. Palm of manus

Carpus

Facies dorsalis. Dorsal surface

Facies palmaris. Palmar surface

Facies lateralis. Lateral surface

Facies medialis. Medial surface

Torus carpeus. Carpal pad (Car), chestnut (eq)

Metacarpus

Facies dorsalis. Dorsal surface

Facies palmaris. Palmar surface

Facies lateralis. Lateral surface

Facies medialis. Medial surface

Torus metacarpeus. Metacarpal pad (Car)

Calcar metacarpeum. Spur, ergot (eq)

Digitus manus. Digits of manus

Digitus I [Pollex]. First digit [thumb]

Digitus II–V. Second–fifth digits

Facies dorsalis. Dorsal surface

Facies palmaris. Palmar surface

Facies solearis. Solear surface

Facies lateralis. Lateral surface (eq)

Facies medialis. Medial surface (eq)

Facies axialis. Axial surface (Car, su, Ru).

Facies abaxialis. Abaxial surface (Car, su, Ru)

Paradigitus. Digit that does not reach the plane of support of other digits (Car, su, bo)

Paraungula. Horny structure without phalanx (ov, cap)

Ungula. Hoof (su, Ru, eq)

Unguicula. Claw (Car)

Membrum pelvinum. Pelvic limb

Femur. Thigh

Facies cranialis. Cranial surface

Facies caudalis. Caudal surface

Facies lateralis. Lateral surface

Facies medialis. Medial surface

Genu. Stifle

Poples. Hollow of stifle

Patella

Crus. Leg

Facies cranialis. Cranial surface

Facies caudalis. Caudal surface

Facies lateralis. Lateral surface

Facies medialis. Medial surface.

Sura. Calf

Malleolus lateralis. Lateral malleolus

Malleolus medialis. Medial malleolus

Pes

Dorsum pedis. Dorsum of pes

<i>Planta pedis</i> . Sole of pes	<i>Digiti II–V</i> . Second–fifth digits
<i>Tarsus</i>	<i>Facies dorsalis</i> . Dorsal surface
<i>Facies dorsalis</i> . Dorsal surface	<i>Facies plantaris</i> . Plantar surface
<i>Facies plantaris</i> . Plantar surface	<i>Facies solearis</i> . Solear surface
<i>Facies lateralis</i> . Lateral surface	<i>Facies lateralis</i> . Lateral surface (eq)
<i>Facies medialis</i> . Medial surface	<i>Facies medialis</i> . Medial surface (eq)
<i>Calx</i> . Heel	<i>Facies axialis</i> . Axial surface (Car, su, Ru)
<i>Torus tarseus</i> . Chestnut (eq).	<i>Facies abaxialis</i> . Abaxial surface (Car, su, Ru)
<i>Metatarsus</i>	<i>Paradigitus</i> . Digit that does not reach the plane of support of other digits ((ca), su, bo)
<i>Facies dorsalis</i> . Dorsal surface	<i>(Paraunguicula)</i> . Horny structure without phalanx (ca)
<i>Facies plantaris</i> . Plantar surface	<i>Paraungula</i> . Horny structure without phalanx (ov, cap)
<i>Facies lateralis</i> . Lateral surface	<i>Ungula</i> . Hoof (su, Ru, eq)
<i>Facies medialis</i> . Medial surface	<i>Unguicula</i> . Claw (Car)
<i>Torus metatarsus</i> . Metatarsal pad (Car)	
<i>Calcar metatarsium</i> . Spur, ergot (eq)	
<i>Digiti pedis</i> . Digits of pes	
<i>Digitus I [Hallux]</i> . First digit	

REGIONES CORPORIS. Regions of the body

OSTEOLOGIA. Osteology

Systema skeletale. Skeletal system

Pars ossea. Osseous part

Periosteum

Endosteum

Substantia corticalis. Cortical substance

Substantia compacta. Compact substance

Substantia spongiosa. Spongy substance

Pars cartilaginea. Cartilaginous part

Perichondrium

Skeleton axiale. Axial skeleton

Skeleton appendiculare. Appendicular skeleton

Os longum. Long bone

Os breve. Short bone

Os planum. Flat bone

Os irregulare. Irregular bone

Os pneumaticum. Pneumatic bone

Diaphysis

Metaphysis. End of the diaphysis where calcified cartilage is replaced by bone

Cartilago epiphysialis. Epiphysial cartilage, the radiolucent plate of cartilage between epiphysis and diaphysis during growth

Linea epiphysialis. Epiphysial line, the radio-opaque line of fusion of the epiphysis to the diaphysis in a mature bone

Epiphysis

Centrum ossificationis primarium. Primary center of ossification in the diaphysis

Centrum ossificationis secundarium. Secondary center of ossification in an epiphysis

Synostosis. Osseous connection between bones

Apophysis

Facies articularis. Articular surface

Cavum medullare. Medullary cavity

Medulla ossium flava. Yellow bone marrow

Medulla ossium rubra. Red bone marrow

Foramen nutricium. Nutrient foramen

Canalis nutricius. Nutrient canal

ARTHROLOGIA. Arthrology

ARTICULATIONES. Articulations, general term for all joints – fibrous, cartilaginous, and synovial

Articulationes fibrosae. Fibrous articulations

Syndesmosis

Sutura. Suture

Sutura serrata

Sutura squamosa

Sutura foliata

Sutura plana

Schindylesis

Gomphosis [Articulatio dentoalveolaris]. Implantation of the tooth in the alveolus

Periodontium

Articulationes cartilagineae. Cartilaginous articulations

Synchondrosis

Symphysis

Articulationes synoviales. Synovial articulations

Articulatio simplex. Simple articulation

Articulatio composita. Composite articulation

Articulatio plana. Plane articulation

Articulatio spheroida [sphaeroidea, cotylica]. Spheroidal (socket) articulation

Articulatio ellipsoidea. Ellipsoidal articulation

Ginglymus. Hinge articulation

Articulatio condylaris. Condylar articulation

Articulatio trochoidea. Trochoid articulation

Articulatio sellaris. Saddle articulation

Cartilago articularis. Articular cartilage

Cavum articulare. Articular cavity

Discus articularis. Articular disk

Meniscus articularis. Articular meniscus

Labrum articulare. Articular lip

Capsula articularis. Articular capsule

- Stratum fibrosum. Fibrous layer
 Stratum synoviale. Synovial layer
 Plica synovialis. Synovial fold
 Villi synoviales. Synovial villi
 Synovia
Ligamenta. Ligaments
 Ligg. extracapsularia. Extracapsular ligaments
 Ligg. capsularia. Capsular ligaments
 Ligg. intracapsularia. Intracapsular ligaments
- MYOLOGIA.** Myology
Musculus. Muscle
 Caput. Head
 Venter. Belly
 Cauda. Tail
Musculus fusiformis. Fusiform muscle
Musculus quadratus. Quadrangle muscle
Musculus triangularis. Triangular muscle
Musculus planus. Flat muscle
Musculus unipennatus. Unipennate muscle
Musculus bipennatus. Bipennate muscle
Musculus multipennatus. Multipennate muscle
Musculus flexor. Flexor muscle
Musculus extensor. Extensor muscle
Musculus abductor. Abductor muscle
Musculus adductor. Adductor muscle
Musculus rotator. Rotator muscle
Musculus pronator. Pronator muscle
Musculus supinator. Supinator muscle
Musculus dilator. Dilator muscle
Musculus tensor. Tensor muscle
Musculus depressor. Depressor muscle
Musculus levator. Levator muscle
Musculus retractor. Retractor muscle
Musculus protractor. Protractor muscle
Musculus sphincter. Sphincter muscle
Musculus orbicularis. Orbicular muscle
Musculus articularis. Articular muscle
Musculus skeleti. Skeletal muscle
- Origo*. Origin
Terminatio. Termination
Musculus cutaneus. Cutaneous muscle
Tendo. Tendon
Peritendineum. Peritendon
Aponeurosis
Perimysium
Fascia
Intersectio tendinea. Tendinous intersection
Arcus tendineus. Tendinous arch
Vagina fibrosa tendinis. Fibrous tendon sheath
Vagina synovialis tendinis. Synovial tendon sheath
Mesotendineum. Mesotendon
Trochlea muscularis. Muscular trochlea
Bursa synovialis. Synovial bursa
- BURSAE ET VAGINAE SYNOVIALES.** Synovial bursae and sheaths
Bursa synovialis subcutanea. Subcutaneous synovial bursa
Bursa synovialis submuscularis. Submuscular synovial bursa
Bursa synovialis subfascialis. Subfascial synovial bursa
Bursa synovialis subtendinea. Subtendinous synovial bursa
Bursa synovialis subligamentosa
Vagina synovialis tendinis. Synovial tendon sheath
- SPLANCHNOLOGIA.** Splanchnology
Tunica mucosa
Lamina propria mucosae
Lamina muscularis mucosae
Tela submucosa
Tunica muscularis
Tunica fibrosa
Tunica albuginea
Tunica adventitia
Tela subserosa

Hidden page

Corpuscula nervosa terminalia. Terminal nervous corpuscles

Terminationes nervorum liberae. Free nerve endings

SYSTEMA NERVOSUM AUTONOMICUM. Autonomic nervous system

Plexus autonomici. Autonomic plexuses

Ganglia plexuum autonomicurum. Ganglia of autonomic plexuses

Ganglia autonómica. Autonomic ganglia

ORGANA SENSUUM. Sense organs

INTEGUMENTUM COMMUNE. Common integument

TERMINI SITUM ET DIRECTIONEM PARTIUM CORPORIS INDICANTES. Terms describing location and orientation of parts of the body

Medianus. Located in the median plane

Sagittalis. Parallel to the median plane

Transversalis. Perpendicular to the long axis of the body or part

Medialis. Closer to the median plane

Intermedius. Intermediate

Lateralis. More distant to the median plane

Cranialis. Closer to the cranium, used on neck, trunk and the limbs proximal to carpus and tarsus

Medius. Middle

Caudalis. Closer to the tail, used on head, neck, trunk and the limbs proximal to carpus and tarsus

Anterior. In quadrupeds, the use is restricted to some structures of the head

Rostralis. Closer to the tip of the nose, resp. the orifice of the mouth, used on the head

Posterior. In quadrupeds, the use is restricted to some structures of the head

Dorsalis. Closer to the dorsum. This term refers to back or dorsum of the tail, trunk, neck and to the corresponding surface of the head.

Ventralis. Closer to the ground in the standing position of a quadruped.

Superior. In quadrupeds, the use is restricted to some structures of the head

Inferior. In quadrupeds, the use is restricted to some structures of the head

Internus. Internal

Externus. External

Dexter. Right

Sinister. Left

Longitudinalis. Longitudinal

Transversus. Transverse

Superficialis. Superficial

Profundus. Deep

TERMINI AD MEMBRA SPECTANTES. Terms related to the limbs.

Proximalis. Toward the trunk

Distalis. Toward the periphery

Medialis. Closer to the median plane

Lateralis. More distant to the median plane

Axialis. Closer to the functional axis of the limb, used on the digit of Car, su, Ru

Abaxialis. More distant to the functional axis of the limb, used on the digits of Car, su, Ru

Dorsalis. Dorsal, refers to the dorsum of manus and pes.

Palmaris. Palmar, refers to the palm of manus.

Plantaris. Plantar, refers to the planta of pes.

Hidden page

<i>Convolutus</i> . Convoluted	<i>Folliculus</i> . Follicle
<i>Corniculatus</i> . In relation to a small horn	<i>Frons, frontis</i> . Forehead
<i>Corpusculum</i> . Corpusele	<i>Frontalis</i> . Frontal
<i>Costa</i> . Rib	<i>Fuscus</i> . Dark
<i>Cotyla</i> . Bowl	<i>Fusiformis</i> . Spindle-shaped
<i>Coxa</i> . Hip	<i>Gallus</i> . Chicken, fowl
<i>Crassus</i> . Thick	<i>Gelatinosus</i> . Gelatinous
<i>Cribriformis</i> . Sieve-like	<i>Genesis</i> . Origin
<i>Cribrosus</i> . Perforated	<i>Genitalis</i> . Genital
<i>Cricoideus</i>	<i>Germen, germinis</i> . Germ
<i>Cruciatus</i> . Crossed	<i>Germinativus</i> . Germinative
<i>Deciduus</i> . Deciduous	<i>Globus</i> . Globe
<i>Declive, declivis</i> . Declivity	<i>Gluteus [Glutaeus]</i> . Gluteal
<i>Deferens</i> . Deferent	<i>Gracilis</i> . Slender
<i>Delta</i>	<i>Granulatio</i> . Granulation
<i>Densus</i> . Dense	<i>Griseus</i> . Gray
<i>Denticulatus</i> . Denticulate	<i>Hamatus</i> . Hamate, with a hook
<i>Depressor</i>	<i>Hyalinus</i> . Hyaline
<i>Descendens</i> . Descending	<i>Hybrida</i> . Hybrid
<i>Digastricus</i> . Digastric, two-bellied	<i>Hyoideus</i> . Hyoid
<i>Digitalis</i> . Digital	<i>Hypogastrium</i>
<i>Dilatator</i>	<i>Hypoglossus</i> . Hypoglossal
<i>Diplois</i> . Lying between two layers	<i>Iliia, ilium</i> . Flank
<i>Ductulus</i> . Ductule	<i>Iliacus</i> . Iliac
<i>Durus</i> . Hard	<i>Impar</i> . Unpaired
<i>Efferens</i> . Efferent	<i>Imus</i> . Lowest, lowermost
<i>Ejaculatorius</i> . Ejaculatory	<i>Incisivus</i> . Suitable for cutting
<i>Elasticus</i> . Elastic	<i>Intestitium</i> . Intestice
<i>Ellipsoideus</i> . Ellipsoidal	<i>Intestinum</i> . Intestine
<i>Embryo</i>	<i>Intima</i> . Innermost
<i>Emissarius</i> . Emissary	<i>Introitus</i> . Entrance
<i>Endothelium</i>	<i>Ischiadicus</i> . Sciatic
<i>Entericus</i> . Enteric	<i>Ischium</i> . Seat, buttock
<i>Epigastrium</i>	<i>Jugulum</i> . Fossa between sternocephalicus, brachiocephalicus and pectoralis descendens
<i>Equinus</i> . Equine	<i>Lac, lactis</i> . Milk
<i>Erector</i>	<i>Lacer</i> . Lacerated, torn
<i>Extensor</i>	<i>Lacrima</i> . Tear
<i>Fetus</i>	<i>Lanugo</i> . Wool, down
<i>Fibra</i> . Fibre	<i>Laryngeus</i> . Laryngeal
<i>Fibrilla</i>	<i>Latissimus</i> . Broadest
<i>Fibrocartilago</i> . Fibrocartilage	<i>Levator</i>
<i>Fibularis</i> . Fibular	<i>Liber</i> . Free
<i>Flavus</i> . Yellow	<i>Limitans</i> . Limiting
<i>Flexor</i>	

Hidden page

<i>Pubes</i> . External genitalia	<i>Status</i> . State
<i>Pudendus</i> . Pudendal	<i>Stella</i> . Star
<i>Pulposus</i> .	<i>Stellatus</i> . Stellate, starshaped
<i>Pupillaris</i> . Pupillary	<i>Stoma, stomatis</i> . Mouth
<i>Quadratus</i> . Quadratic, square	<i>Striatus</i> . Striate, striped
<i>Quadriceps, quadricipitis</i> . Four-headed	<i>Stylopodium</i>
<i>Radialis</i> . Radial	<i>Stylus</i> . Style
<i>Rectus</i> . Straight	<i>Succus</i> . Juice
<i>Recurrentis, recurrens</i> . Recurrent	<i>Sudor, sudoris</i> . Sweat
<i>Reflexus</i> . Reflected	<i>Supinus</i> . Turned upwards
<i>Renalis</i> . Renal	<i>Suspensus</i> . Suspended
<i>Respiration, respirationis</i> . Respiration	<i>Sympathicus</i> . Sympathetic
<i>Retroflexus</i> . Retroflex	<i>Tactus</i> . Sense of touch
<i>Rhis, rhinos</i> . Nose	<i>Tactilis</i> . Tactile
<i>Rhomboideus</i> . Rhomboid	<i>Taenia (vide Tenia)</i>
<i>Rotundus</i> . Round	<i>Tectorius</i> . Tectorial, covering
<i>Ruber</i> . Red	<i>Tempus, temporis</i> . Temple
<i>Rudimentum</i> . Rudiment	<i>Tenia [Taenia]</i>
<i>Sacer</i> . Sacred	<i>Tensor</i>
<i>Saliva</i> . Spit	<i>Tenuis</i> . Thin
<i>Sanguis, sanguinis</i> . Blood	<i>Teres, teretis</i> . Round
<i>Scalenus</i> . Stairs-like	<i>Terminalis</i> . Terminal
<i>Sebaceus</i> . Sebaceous	<i>Theca</i>
<i>Sebum</i>	<i>Thorax, thoracis</i> . Chest
<i>Secretum</i> . Secretion	<i>Tibialis</i> . Tibial
<i>Semen, seminis</i>	<i>Tubulus</i> . Tubule
<i>Sensorium</i> . Consciousness	<i>Tubus</i> . Tube
<i>Sensus</i> . Sense	<i>Tympanum</i> . Drum
<i>Septulum</i> . Small septum	<i>Ulnaris</i> . Ulnar
<i>Serratus</i> . Serrate	<i>Uncinatus</i> . Uncinate, hookshaped
<i>Serum</i>	<i>Uncus</i> . Hook
<i>Sesamoideus</i> . Sesamoid	<i>Urina</i> . Urine
<i>Sigmoideus</i> . Sigmoid, S-curved	<i>Vagus</i> . Running about
<i>Simplex, simplicis</i> . Simple	<i>Vascularis</i> . Vascular
<i>Singularis</i> . Singular	<i>Vastus</i> . Vast
<i>Solitarius</i> . Solitary	<i>Vellus, vellris</i> . Wool, fleece, fur
<i>Sperma, spermatis</i> . Sperm	<i>Verus</i> . True
<i>Sphenoidalis</i> . Sphenoid, wedge-shaped	<i>Vesicalis</i> . Vesical
<i>Spheroideus [Sphaeroideus]</i> . Spherical	<i>Vestibularis</i> . Vestibular
<i>Sphincter</i>	<i>Vestigium</i> . Vestige
<i>Splanchnicus</i> . Splanchnic	<i>Villus</i>
<i>Spongiosus</i> . Spongy	<i>Viscus, visceris</i> . Singular of viscera, used only in plural
<i>Spurius</i> . False	<i>Visus</i> . Sense of sight
<i>Squamosus</i> . Squamous	

<i>Vita</i> . Life	<i>Xiphoideus</i> . Xiphoid, sword-shaped
<i>Vitellus</i> . Yolk	<i>Zeugopodium</i>
<i>Vitreus</i> . Vitreous	<i>Zygomaticus</i> . Zygomatic, pertaining to zygomatic arch
<i>Vocalis</i> . Vocal	
<i>Vorticosus</i> . Vorticose, vortex-like	

References

- Acheson, G. H.*: The topographical anatomy of the smooth muscle of the cat's nictating membrane. *Anat. Rec.* 71: 297 (1938)
- Arey, L. B.*: Developmental Anatomy. 7th ed. Saunders, Philadelphia 1965
- Backhouse, K. M., Butler, H.*: The gubernaculum testis of the pig. *J. Anat.* 94: 107 (1960)
- Bacsich, P., et al.*: On the presence of a reptilian-type conus papillaris in the eye of the Golden Hamster. *J. Anat.* 99: 195 (1965)
- Blom, E., Christensen, N. O.*: Cysts and cyst-like formations in the genitals of the bull. *Roy. Vet. and Agr. College Copenhagen, Yearbook 1958*: 101
- Blom, E., Christensen, N. O.*: The Etiology of Spermio-stasis in the Bull. *Nord. Vet.-Med.* 12: 453 (1960)
- deLahunta, A., Habel, R. E.*: Applied Veterinary Anatomy. Saunders, Philadelphia 1986
- De Schaepdrijver, L., Simoens, P., Princemaille, J.*: De glans penis en glans clitoridis by het paard: enkele morfologische aspecten met klinisch belang. *Vlaams Dierg. Tijdschr.* 57: 72 (1988)
- Dyce, K. M., Sack, W. O., Wensing, C. J. G.*: Textbook of Veterinary Anatomy. Saunders, Philadelphia 1987
- Eichhorn, E. B., Boyden, E. A.*: The cholecho-duodenal junction in the dog - a restudy of Oddi's sphincter. *Am. J. Anat.* 97: 431 (1955)
- Ellenberger, W., Baum, H.*: Handbuch der vergleichenden Anatomie der Haustiere. 18th ed. Springer, Berlin 1943
- Evans, H. E., Christensen, G. C.*: Miller's Anatomy of the dog. 2nd ed. Saunders, Philadelphia 1979
- Feneis, H.*: Pocket Atlas of Human Anatomy based on the International Nomenclature. Thieme, Stuttgart 1976
- Garrett, P. D.*: Urethral recess in male goats, sheep, cattle, and swine. *J. Am. Vet. Med. Ass.* 191: 689 (1987)
- Geiger, G.*: Die anatomischen Grundlagen des „Hymenalringes“ beim Rinde. *Tierärztl. Umschau* 9: 398 (1954)
- Gerisch, D., Neurand, K.*: Topographie und Histologie der Drüsen der Regio analis des Hundes. *Anat. Hist. Emb.* 2: 280 (1973)
- Getty, R.*: Sisson and Grossman's The Anatomy of the Domestic Animals. 5th ed. Saunders, Philadelphia 1975
- Habel, R. E.*: Guide to the dissection of domestic ruminants. 4th ed. Published by the author. Ithaca, N. Y., 1989
- Habermehl, K. H.*: Über besondere Randpapillen an der Zunge neugeborener Säugetiere. *Z. Anat. Entw.* 116: 355 (1952)
- Hart, B. L., Kitchell, R. L.*: External morphology of the erect glans penis of the dog. *Anat. Rec.* 152: 193 (1965)
- Hebel, R.*: Distribution of retinal ganglion cells in five mammalian species. *Anat. Embryol.* 150: 45 (1976)
- Hertwig, O.*: Entwicklungslehre des Menschen und der Wirbeltiere. Fischer, Jena 1900
- Hofmann, R.*: Zur Topographie und Morphologie des Wiederkäuermagens in Hinblick auf seine Funktion. *Suppl. 10, Zbl. Vet. Med.* 1969
- Holz, K.*: Vergleichende anatomische und topographische Studien über das Mittelohr der Säugetiere. *Vet. Diss. Berlin* 1931
- Horowitz, A., Kramer, B., Sack, W. O.*: Atlas of musculoskeletal anatomy of the pig. *Veterinary Textbooks, Ithaca, N. Y.*, 1982
- Krage, P.*: Präputium der Haussäugetiere. *Diss. Vet. Med. Zürich* 1907
- Kratzing, J.*: The structure of the vomeronasal organ in the sheep. *J. Anat.* 108: 247 (1971)
- Lewin, N. A.*: Die Venenstruktur und der venöse Abfluß im Innenohr des Rindes und des Schafes. *Wien. tierärztl. Mschr.* 50: 888 (1963)
- McCotter, R. E.*: The connection of the vomeronasal nerves with the accessory olfactory bulb in the opossum and other mammals. *Anat. Rec.* 6: 299 (1912)
- McCotter, R. E.*: The Nervus terminalis in the adult dog and cat. *J. Comp. Neurol.* 23: 145 (1913)
- Miller, M. E., Evans, H. E., Christensen, G. L.*: Anatomy of the dog. 2nd ed. Saunders, Philadelphia 1979
- Montagna, W.*: Advances in biology of skin. Vol I. Pergamon Press, New York 1960
- Nickel, R., Schummer, A., Seiferle, E.*: Lehrbuch der Anatomie der Haustiere. Vol. I. Parey, Berlin 1954
- Nickel, R., Schummer, A., Seiferle, E., Sack, W. O.*: The viscera of the Domestic Mammals. 2nd ed. Parey, Berlin 1979
- Nomina Anatomica Veterinaria.* 3rd ed. Publ. by Int. Committee on Vet. Gross Anat. Nomenclature. Ithaca, N. Y., 1983
- Popesko, P.*: Atlas of Topographical Anatomy of the Domestic Animals. Saunders, Philadelphia 1971
- Sack, W. O., Habel, R. E.*: Rooney's guide to the dissection of the horse. *Veterinary Textbooks, Ithaca, N. Y.*, 1977
- Schaller, O.*: Der N. intercostobrachialis des Rindes. *Wien. tierärztl. Mschr., Schreiber-Festschrift*: 292 (1960)
- Schmaltz, R.*: Die Geschlechtsorgane. In W. Ellenberger, Handbuch der vergleichenden mikroskopischen Anatomie der Haustiere. Vol. II. Parey, Berlin 1911
- Schreiber, J.*: Der Bandapparat des Tarsus vom Schwein. *Wien. tierärztl. Mschr.* 48: 602 (1961)
- Seiferle, E.*: In Nickel, Schummer, Seiferle, Lehrbuch der Anatomie der Haustiere. Vol. IV. Parey, Berlin 1975

- Shambaugh, G. E.*: Bloodstream in the labyrinth of the ear of dog and man. *Am. J. Anat.* 32: 189 (1923)
- Simoens, P., De Vos, N. R., Lauwers, H.*: Illustrated anatomical nomenclature of the heart and the arteries of head and neck in the domestic mammals. *Medelingen Fac. Diergeneeskunde, Rijks-univ. Gent* 21: 1 (1978)
- Simoens, P., De Vos, N. R., Lauwers, H., Nicaise, M.*: Illustrated anatomical nomenclature of the arteries of the thoracic limb in the domestic mammals. *Medelingen Fac. Diergeneeskunde, Rijks-univ. Gent* 22: 1 (1980)
- Simoens, P., De Vos, N. R., Lauwers, H.*: Illustrated anatomical nomenclature of the arteries of the abdomen, the pelvis, and the pelvic limb in domestic mammals. *Medelingen Fac. Diergeneeskunde Rijksuniv. Gent.* 25: II/1 (1980)
- Spreull, J. S. A.*: Treatment of otitis media in the dog. *J. Small Anim. Pract.* 5: 107 (1964)
- Trautmann, A., Fiebiger, J.*: *Fundamentals of the Histology of Domestic Animals.* Comstock, Ithaca, N. Y., 1957
- Vollmerhaus, B.*: Zur vergleichenden Nomenklatur des lymphoepithelialen Rachenringes der Haus-säugetiere. *Zbl. Vet. Med.* 6: 82 (1959)
- Zietzschmann, O., Krölling, O.*: *Lehrbuch der Entwicklungsgeschichte der Haustiere.* Parey, Berlin 1955

Index

- Abaxialis [568](#)
 Abdomen [562](#)
 Abducens [569](#)
 Abductor [569](#)
 Aberrans [569](#)
 Abomasum [158](#)
 Accessorius [569](#)
 Acetabulum [62](#)
 Acinus [569](#)
 Acromion [48](#)
 Acropodium [569](#)
 Acutus [569](#)
 Adductor [569](#)
 Adenohypophysis [232](#)
 Adeps, adipis [569](#)
 Adhesio interthalamica [436](#)
 Aditus ad recessum caudalem [226](#)
 Aditus laryngis [186](#)
 Aditus orbitae [14](#)
 Adventicius [569](#)
 [Adventitius] [569](#)
 [Aequator lentis] [518](#)
 [Aequator] [510](#)
 Afferens [569](#)
 Affixus [569](#)
 Ala [18, 20](#)
 [Ala atlantis] [42](#)
 Ala lobuli centralis [428](#)
 Ala nasi [562](#)
 Ala ossis ilii [62](#)
 Ala sacralis [44](#)
 Ala vomeris [30](#)
 Alae nasi [174](#)
 Albicans [569](#)
 Albugineus [569](#)
 Albus [569](#)
 Alimentarius [569](#)
 Allantois [220](#)
 Allocortex [452](#)
 Alveoli dentales [34, 38](#)
 Alveoli pulmonis [190](#)
 Alveolus [369](#)
 Alveus hippocampi [450](#)
 Ambiguus [569](#)
 Amnion [220](#)
 Ampulla coli [166](#)
 Ampulla ductus deferentis [202, 204](#)
 Ampulla duodeni [162](#)
 Ampulla hepatopancreatica [172](#)
 Ampulla membranacea anterior [526](#)
 Ampulla membranacea lateralis [526](#)
 Ampulla membranacea posterior [526](#)
 Ampulla ossea anterior [532](#)
 Ampulla ossea lateralis [532](#)
 Ampulla ossea posterior [532](#)
 Ampulla recti [166](#)
 Ampulla tubae uterinae [214](#)
 Ampullae membranaceae [526](#)
 Ampullae osseae [532](#)
 Amygdala [569](#)
 Anastomosis arteriovenosa [567](#)
 Anatomia, anatomica [569](#)
 Ancon, anconis [569](#)
 Angiologia [567](#)
 Angulus arcuum costalium [46](#)
 Angulus caudalis [48](#)
 Angulus costae [46](#)
 Angulus cranialis [48](#)
 Angulus frontalis [26](#)
 Angulus iridocornealis [518](#)
 Angulus mandibulae [38](#)
 Angulus mastoideus [26](#)
 Angulus occipitalis [26](#)
 Angulus oculi lateralis [522](#)
 Angulus oculi medialis [522](#)
 Angulus oris [140](#)
 Angulus soleae abaxialis [554](#)
 Angulus soleae axiali [554](#)
 Angulus soleae lateralis [554](#)
 Angulus soleae medialis [554](#)
 Angulus sphenoidalis [26](#)
 Angulus stylohyoideus [38](#)
 Angulus ventralis [48](#)
 Annexae mastoideae [534](#)
 Ansa axillaris [482](#)
 Ansa cardiaca [160](#)
 Ansa cervicalis [480](#)
 Ansa distalis coli [166](#)
 Ansa lenticularis [442](#)
 Ansa peduncularis [442](#)
 Ansa proximalis coli [166](#)
 Ansa sigmoidea [162](#)
 Ansa spiralis coli [166](#)
 Ansa subclavia [506](#)
 Ansa [480](#)
 Antebrachium [563](#)
 Anterior [568](#)
 Antitragus [540](#)
 Antrum pyloricum [154](#)
 Anuli fibrosi [236](#)
 Anulus conjunctivae [512](#)
 Anulus femoralis [130](#)
 Anulus fibrocartilagineus [536](#)
 Anulus fibrosus [80](#)
 Anulus inguinalis profundus [114](#)
 Anulus inguinalis supf. [114](#)
 Anulus iridis major [514](#)
 Anulus iridis minor [514](#)
 Anulus pancreatis [172](#)
 Anulus preputialis [prae-] [206](#)
 Anulus sclerae [510](#)
 Anulus tympanicus [24](#)
 Anulus umbilicalis [114](#)
 Anulus vaginalis [202](#)
 Anus [168, 563](#)
 Aorta [242](#)
 Aorta abdominalis [304](#)
 Aorta ascendens [242](#)
 Aorta descendens [302](#)
 Aorta thoracica [302](#)
 Apertura conchomaxillaris [180](#)
 Apertura externa aq. vest. [22](#)
 Apertura externa canal. coch. [22](#)
 Apertura frontomaxillaris [180](#)
 Apertura maxillopalatina [180](#)
 (Apertura mediana ventriculi quarti) [430](#)
 Apertura nasi ossea [14](#)
 Apertura nasomaxillaris [180](#)
 Apertura pelvis caudalis [64](#)
 Apertura pelvis cranialis [64](#)
 Apertura sinus lacrimalis [32](#)
 Apertura sinus sphenoidalis [20, 180](#)
 Apertura thoracis caudalis [46](#)
 Apertura thoracis cranialis [46](#)
 Apertura tympanica canalic. chord. tymp. [534](#)
 Aperturæ laterales ventriculi quarti [430](#)
 Aperturæ sinuum frontium [28, 180](#)
 Aperturæ ventriculi quarti [430](#)
 Apex [42, 60, 184](#)
 Apex auriculæ [542](#)
 Apex cartilaginis arytеноideae [arytaenoideae] [184](#)
 Apex cecii [caecii] [184](#)
 Apex cordis [234](#)
 Apex cornu [548](#)
 Apex cornu dorsalis [414](#)
 Apex cunei [556](#)
 Apex cuspidis [144](#)
 Apex linguae [146](#)
 Apex nasi [174, 562](#)
 Apex ossis sacri [44](#)
 Apex partis petrosae [22](#)
 Apex patellae [68](#)
 Apex pili [546](#)
 Apex pulmonis [188](#)
 Apex radices dentis [144](#)
 Apex tori [556](#)
 Apex vesicae [198](#)
 Apicalis [569](#)
 Aponeurosis [566](#)
 Aponeurosis linguae [148](#)
 Aponeurosis palatina [152](#)
 Apophysis [565](#)
 Apparatus digestorius [140](#)
 Apparatus hyoideus [38](#)
 Apparatus lacrimalis [524](#)
 Apparatus respiratorius [174](#)
 Apparatus suspensorius mammarius [560](#)

- Apparatus urogenitalis 194
 Appendices colli [544](#)
 Appendices epiploicae 166
 Appendices vesiculosae 212
 Appendix 569
 (Appendix fibrosa hepatis) 170
 (Appendix testis) [200](#)
 [Aquaeductus mesencephali] 432
 [Aquaeductus vestibuli] [22](#)
 [Aq. cerebri] 432
 Aqueductus mesencephali 432
 Aqueductus vestibuli [22](#)
 Aquosus 569
 Arachne 569
 Arachnoidea encephali 462
 Arachnoidea spinalis 462
 Arbor bronchialis [188](#)
 Arbor vitae [428](#)
 Archicortex 452
 Archipallium [446](#)
 Arcuatus 569
 Arcus alveolaris [34](#), [38](#)
 Arcus aortae 244
 Arcus arteriosus 567
 Arcus cartilaginis cricoideae [182](#)
 Arcus costalis 4, [46](#)
 Arcus dentalis inferior [146](#)
 Arcus dentalis superior [146](#)
 Arcus dorsalis 42
 Arcus dorsalis profundus 394
 Arcus dorsalis supf. 284, 392
 Arcus hemalis [haemalis] 44
 Arcus hyoideus 348, 350, 352
 Arcus hyoideus profundus 350
 Arcus inguinalis 112
 Arcus ischiadicus 64
 Arcus laryngeus caudalis 344
 Arcus lumbocostalis 112
 Arcus palatoglossus [150](#)
 Arcus palatopharyngeus [150](#)
 Arcus palmaris profundus 288,
 292, 296, 300, 368, 370
 Arcus palmaris profundus dist.
 370
 Arcus palmaris superficialis 288,
 292, 296, 368, 370
 (Arcus palmaris superficialis) 300
 Arcus plantaris profundus 322,
 326, 330, 334, 394–400
 Arcus plantaris profundus dist.
 398, 400
 Arcus plantaris supf. 394
 Arcus superciliaris [26](#)
 Arcus tendineus 566
 Arcus tendineus fasciae pelvis [222](#)
 (Arcus tendineus m. levatoris ani)
[222](#)
 Arcus terminalis 292, 296, 300,
 326, 330, 336, 370, 400
 Arcus venosus 567
 Arcus ventralis 42
 Arcus vertebrae 40
 Arcus zygomaticus 10
 Area centralis rotunda 516
 Area centralis striaformis 516
 Area cochleae 534
 Area cribrosa 194
 Area cribrosa sclerae 510
 Area hypothalamica dorsalis [440](#)
 Area hypothalamica dorsocaudalis
[440](#)
 Area hypothalamica lateralis 414
 Area intercondylaris caud. [68](#)
 Area intercondylaris centralis [68](#)
 Area intercondylaris cran. [68](#)
 Area lateralis m. recti femoris [62](#)
 Area medialis m. recti femoris [62](#)
 Area n. facialis [intermediofacia-
 lis] 534
 Area nuda [168](#)
 Area postrema 430
 Area subcallosa 448
 Area vestibularis inferior 534
 Area vestibularis superior 534
 Areae 174
 Areae gastricae [160](#)
 Arrector 569
 Arteria, Arteriae [242](#), 567
 A. abdominalis caudalis 320
 A. abdominalis cranialis [304](#)
 Aa. adrenales mediae 310
 A. adrenalis media 310
 A. alveolaris inferior [248](#), [254](#),
[260](#), [266](#)
 Aa. angulares oris [246](#)
 A. angularis oculi [246](#), [254](#), [262](#),
 264
 A. angularis oris [254](#), [258](#), 264
 A. antebrachialis supf. cran. 284,
 286, 290, 294
 A. arcuata 324
 Aa. arcuatae [196](#)
 Aa. auriculares rostrales [252](#)
 A. auricularis caudalis [248](#), [252](#),
[258](#), [266](#)
 A. auricularis profunda [248](#), [252](#),
[258](#), [266](#)
 A. auricularis rostralis [248](#), [260](#),
[266](#)
 A. axillaris 284
 A. basilaris 272, 276, 280, 282
 A. bicipitalis 284, 286, 290, 294,
 298
 A. brachialis 284, 286, 290, 294,
 298
 A. brachialis superficialis 284, 286
 A. broncho-esophagea [-oesopha-
 gea] 302
 A. buccalis [250](#), [254](#), [260](#), [268](#)
 A. bulbi penis 312–318
 A. bulbi vestibuli 312–318
 A. caroticobasilaris [270](#)
 A. carotis communis 244
 A. carotis externa [246](#)
 A. carotis interna [270](#)
 Aa. caudales femoris 326
 A. caudalis femoris 332, 334
 A. caudalis femoris dist. 322
 A. caudalis femoris media 322
 A. caudalis femoris prox. 322
 A. caudalis [coccygea] dorsolat.
[304](#), [318](#)
 A. caudalis [coccygea] lat. 312
 A. caudalis [coccygea] mediana
[304](#), [318](#)
 A. caudalis [coccygea] ventrolat.
[304](#), [318](#)
 A. cecalis [caecalis] 310
 A. cecalis [caecalis] lat. 310
 A. cecalis [caecalis] med. 310
 A. celiaca [coeliaca] 306
 A. centralis retinae [248](#), 256, [262](#),
[268](#)
 Aa. cerebelli caudales [282](#)
 A. cerebelli caudalis 272, 276, 280
 A. cerebelli rostr. 272
 Aa. cerebri 272
 A. cerebri caudalis 272
 A. cerebri media 272
 A. cerebri rostralis 272
 A. cervicalis profunda [274–278](#),
[282](#)
 A. cervicalis superficialis [274](#),
 280, [282](#)
 A. cervicalis superficialis dextra
 276
 A. cervicalis superficialis sinistra
 276
 A. choroidea [chorioidea] rostr.
 272
 Aa. ciliares anteriores [248](#), [250](#),
[254](#), [262](#), [268](#)
 Aa. ciliares posteriores breves
[248](#), [250](#), 256, [262](#), [268](#)
 Aa. ciliares posteriores longae
[248](#), [250](#), [256](#), [262](#), [268](#)
 A. circumflexa femoris lat. 322,
 326, 330, 334
 A. circumflexa femoris med. 320
 A. circumflexa humeri caud. 284,
 290, 294, 298
 A. circumflexa humeri cran. 284,
 290, 294, 298
 A. circumflexa ilium profunda
[304](#), 320
 A. circumflexa ilium supf. 322
 A. circumflexa scapulae 284, 290,
 294, 298
 A. clitoridis 312, 314, 316
 A. clitoridis media [318](#)
 A. colica dextra 310
 A. colica media 310
 A. colica sinistra 310
 Aa. colicae dextrae 310
 A. collateralis media 284, 290,
 294, 298
 A. collateralis radialis 284, 290,
 294, 298
 A. collateralis ulnaris 284, 286,
 290, 294, 298
 A. comitans n. ischiadici 312
 A. communicans caudalis 272
 A. communicans rostralis 272
 A. condylaris [246](#), 264, [270](#)
 Aa. conjunctivales anteriores 256,
[262](#)
 Aa. conjunctivales posteriores
[248](#), [250](#), 256, [262](#), [268](#)

- A. cornualis* 260
A. coronalis 292, 296, 300, 326, 330, 336
A. coronaria dextra 242
A. coronaria sinistra 242
A. costoabdominalis dors. 302
A. cremasterica 320
A. cystica 306, 308
Aa. digit. dors. communes I–IV 284
Aa. digit. dors. communes II et III 294
Aa. digit. dors. communes II–IV 286
Aa. digit. dors. communes II–IV, I–IV 322
A. digit. dors. communis I 286
A. digit. dors. communis III 290
A. digit. dors. communis III, II–IV 332
A. digit. dors. II abaxialis 322
A. digit. dors. V. abaxialis 284, 286, 322
Aa. digit. dors. propriae 284, 286, 290, 294, 322, 328, 332
A. digit. lateralis 300, 336
A. digit. medialis 300, 336
Aa. digit. palm. communes I–IV, II–IV 288
Aa. digit. palm. communes II–IV 292
A. digit. palm. communis II 296, 300
A. digit. palm. communis III 296, 300
A. digit. palm. communis IV 298
A. digit. palm. propria II axialis 296
A. digit. palm. propria III abaxialis 296
[A. digit. palm. propria III lat.] 300
[A. digit. palm. propria III med.] 300
A. digit. palm. propria IV abaxialis 298
A. digit. palm. propria V axialis 298
Aa. digit. palm. propriae 288, 292
Aa. digit. palm. propriae III et IV axiales 296
A. digit. palm. V abaxialis 288
Aa. digit. plantares propriae 322, 326
[A. digit. plantaris propria III lat.] 336
[A. digit. plantaris propria III med.] 336
A. digit. plant. communis II 330
[A. digit. plant. communis II] 334
Aa. digit. plant. communes II–IV 322, 326
A. digit. plant. communis III 330
[A. digit. plant. communis III] 334
[A. digit. plant. communis IV] 332
A. digit. plant. propria II axialis 330
A. digit. plant. propria III abaxialis 332
A. digit. plant. propria IV abaxialis 332
A. digit. plant. propria V axialis 332
Aa. digit. plant. propriae III et IV axiales 330
A. diverticuli 306
A. dorsalis clitoridis 312–318
A. dorsalis nasi 256, 260–264
A. dorsalis nasi caudalis 248
A. dorsalis nasi rostralis 250
A. dorsalis pedis 324, 328, 332, 336
A. dorsalis penis 312–318
A. ductus deferentis 312–318
A. epigastrica caudalis 320
A. epigastrica caudalis supf. 320
A. epigastrica cranialis 274, 278–282
A. epigastrica cranialis supf. 274, 280
Aa. episclerales 248, 250, 262, 268
A. ethmoidalis externa 250, 254, 262, 268
A. ethmoidalis interna 272
A. facialis 246, 252, 258, 264
A. femoralis 322, 326, 330, 334
A. gastrica dextra 306, 308
A. gastrica sinistra 306, 308
Aa. gastricae breves 306, 308
A. gastroduodenalis 306, 308
A. gastroepiploica dextra 306, 308
A. gastroepiploica sinistra 306, 308
A. genus descendens 322, 326, 332, 334
A. genus distalis lat. 324, 328, 332, 334
A. genus distalis med. 324, 328, 332, 334
A. genus media 324, 328, 332, 334
A. genus proximalis lat. 324, 328, 332, 334
A. genus proximalis med. 324, 326, 334
A. glutea [glutaea] caud. 312–318
A. glutea [glutaea] cran. 312–318
Aa. helicinae 208
A. hepatica 306, 308
A. hyaloidea 518
Aa. ilei 310
A. ileocolica 310
A. iliaca externa 320
A. iliaca interna 312
A. iliocofemoralis 318
A. iliolumbalis 312–318
A. infraorbitalis 250, 256, 264, 268
A. intercarotica caudalis 270
A. intercarotica rostralis 270
Aa. intercostales dorsales 270
Aa. intercostales dorsales I et II (III) 278
Aa. intercostales dorsales II et III 274
Aa. intercostales dorsales II–V 284
Aa. intercostales dorsales III–V 276
A. intercostalis dorsalis I 274, 282
A. intercostalis dorsalis I dextra 276
A. intercostalis dorsalis I sinistra 276
A. intercostalis dorsalis II 276
A. intercostalis suprema 274–278, 282
A. interdigitalis 288, 292, 296, 322, 326, 330
Aa. interlobares renis 196
Aa. interlobulares 170, 196
A. interossea caudalis 284, 288, 290, 294, 298
A. interossea communis 286, 290, 294, 298
A. interossea cranialis 284, 286, 290, 294, 298
A. interossea cruris 328, 332
Aa. jejunales 310
Aa. labiales inferiores 258
A. labialis inferior 246, 254, 260, 264
A. labialis superior 246, 254, 260, 264
A. labyrinthi 272, 276, 280, 282, 530
A. lacrimalis 250, 256, 262, 268
A. laryngea cranialis 244, 246
Aa. laterales nasi 256
A. lateralis nasi 250, 264
A. lateralis nasi caudalis 262
A. lateralis nasi rostralis 262
A. lienalis 306, 308
A. lig. teretis uteri 320
A. lingualis 246, 252, 258, 264
A. lobi caudati 306, 308
Aa. lumbales 304
Aa. lumbales V et VI 318
A. lumbalis VI 316
A. lumbalis VI (VII) 304
A. malaris 250, 256, 262, 268
A. malleolaris caudalis lat. 336
A. malleolaris cranialis lat. 328, 332
A. malleolaris cranialis med. 328, 332
[A. mammaria caudalis] 320
[A. mammaria cranialis] 320
A. masseterica 248, 254, 260
A. maxillaris 248, 254, 260, 266
A. mediana 288, 292, 296, 300
A. meningea caudalis 246, 264, 270
A. meningea media 248, 254, 266
A. meningea rostralis 250, 254, 268, 272
A. mentalis 260, 266
A. mesenterica caudalis 310
A. mesenterica cranialis 310

- Aa. metacarpeae dorsales I–IV [288](#)
 Aa. metacarpeae dors. II et III [300](#)
 Aa. metacarpeae dors. II et IV [292](#)
 A. metacarpea dorsalis III [292](#), [296](#)
 Aa. metacarpeae palm. I–IV [288](#)
 Aa. metacarpeae palm. II et III [300](#)
 Aa. metacarpeae palm. II–IV [292](#), [296](#)
 Aa. metatarseae dors. II et IV [324](#), [326](#)
 Aa. metatarseae dors. II–IV [324](#)
 A. metatarsea dorsalis III [328](#), [332](#), [336](#)
 Aa. metatarseae plant. II et III [334](#)
 Aa. metatarseae plant. II–IV [322](#), [326](#), [330](#)
 A. musculophrenica [274](#), [278](#), [280](#), [282](#)
 Aa. nasales caudales laterales et septales [250](#), [256](#), [262](#), [268](#)
 Aa. nasales septales caudales [250](#)
 A. nutricia fibulae [328](#)
 A. nutricia humeri [284](#), [290](#), [294](#), [298](#)
 A. nutricia tibiae [328](#), [332](#), [336](#)
 A. nutricia tibiae et fibulae [324](#)
 A. obturatoria [312](#), [314](#), [318](#)
 A. occipitalis [246](#), [264](#), [270](#)
 A. ophthalmica externa [250](#), [254](#), [262](#), [268](#)
 A. ophthalmica interna [270](#), [272](#)
 A. ovarica [310](#)
 A. palatina ascendens [244](#), [246](#), [252](#), [264](#)
 A. palatina descendens [250](#), [256](#), [262](#), [268](#)
 A. palatina major [250](#), [256](#), [262](#), [268](#)
 A. palatina minor [250](#), [256](#), [262](#), [268](#)
 A. palpebrae tertiae [250](#), [256](#), [264](#), [268](#)
 A. palpebralis inf. lat. [248](#), [256](#), [260](#), [268](#)
 A. palpebralis inf. med. [250](#), [254](#), [264](#), [268](#)
 A. palpebralis sup. lat. [248](#), [256](#), [260](#), [268](#)
 A. palpebralis sup. med. [250](#), [254](#), [264](#), [268](#)
 A. pancreaticoduodenalis caud. [310](#)
 A. pancreaticoduodenalis cran. [306](#), [308](#)
 A. parotidea [248](#)
 A. penis 312–318
 A. penis cranialis [320](#)
 A. penis media [318](#)
 A. pericardiacophrenica [274](#), [278](#)–[282](#)
 A. perinealis dorsalis [312](#), [314](#), [316](#)
 A. perinealis ventralis [312](#)–[318](#)
 A. pharyngea ascendens [244](#), [246](#), [252](#)
 A. phrenica caudalis [304](#), [306](#)
 (A. phrenica caudalis) [306](#)
 Aa. phrenicae caudales [308](#)
 A. phrenica cranialis [302](#)
 A. plantaris lateralis [322](#), [326](#), [330](#), [334](#)
 A. plantaris medialis [322](#), [326](#), [330](#), [334](#)
 A. poplitea [324](#), [328](#), [332](#), [334](#)
 A. profunda antebrachii [284](#), [286](#), [290](#), [296](#), [300](#)
 A. profunda brachii [284](#), [286](#), [290](#), [294](#), [298](#)
 A. profunda clitoridis [312](#)–[318](#)
 A. profunda femoris [320](#)
 A. profunda linguae [246](#), [252](#), [258](#), [264](#)
 A. profunda penis 312–318
 A. prostatica 312–318
 A. pudenda externa [320](#)
 A. pudenda interna 312–318
 A. pulmonalis dextra [242](#)
 A. pulmonalis sinistra [242](#)
 Aa. radiales superficiales [284](#), [286](#)
 A. radialis [288](#), [292](#), [296](#), [300](#)
 A. radialis proximalis [300](#)
 A. rectalis caudalis 312–318
 A. rectalis cranialis [310](#)
 A. rectalis media 312–318
 A. recurrens interossea [284](#), [286](#), [290](#), [294](#), [298](#)
 A. recurrens tibialis caud. [324](#)
 A. recurrens tibialis cran. [324](#), [328](#), [332](#)
 A. recurrens ulnaris [284](#), [286](#)
 A. renalis [310](#)
 Aa. renis [196](#)
 A. reticularis [308](#)
 A. reticularis accessoria [308](#)
 A. ruminalis dextra [308](#)
 A. ruminalis sinistra [308](#)
 A. sacralis lateralis [304](#)
 (A. sacralis lateralis) [304](#)
 A. sacralis mediana [304](#)
 (A. sacralis mediana) [304](#)
 A. saphena [322](#), [326](#), [330](#), [334](#)
 A. scapularis dorsalis [274](#)–[278](#), [282](#)
 Aa. sigmoideae [310](#)
 A. sphenopalatina [250](#), [256](#), [262](#), [268](#)
 A. spinalis dorsalis [276](#), [280](#), [282](#)
 A. spinalis ventralis [272](#)
 A. stylomastoidea [248](#), [258](#), [266](#), [270](#)
 A. stylomastoidea profunda [270](#)
 A. subclavia [272](#)
 A. sublingualis [246](#), [252](#), [258](#), [264](#)
 A. submentalis [246](#), [252](#), [258](#), [264](#)
 A. subscapularis [284](#), [290](#), [294](#), [298](#)
 A. supraorbitalis [250](#), [254](#), [262](#), [268](#)
 [A. suprarenalis media] [310](#)
 [Aa. suprarenales mediae] [310](#)
 A. suprascapularis [274](#), [280](#), [290](#), [294](#), [298](#)
 A. supratrochlearis [254](#)
 Aa. surales [324](#), [328](#), [332](#)
 A. tarsea lateralis [324](#), [328](#), [332](#)
 A. tarsea medialis [324](#), [328](#), [332](#)
 A. tarsea perforans [332](#), [336](#)
 A. tarsea perforans dist. [328](#)
 A. tarsea perforans prox. [328](#)
 A. temporalis profunda [260](#)
 A. temporalis profunda caud. [248](#), [254](#), [260](#), [266](#)
 A. temporalis profunda rostr. [248](#), [254](#), [260](#), [266](#)
 A. temporalis supf. [248](#), [252](#), [260](#), [266](#)
 A. testicularis [310](#)
 A. thoracica externa [284](#), [290](#), [294](#), [298](#)
 A. thoracica interna [274](#), [278](#)–[282](#)
 A. thoracica lateralis [284](#), [290](#)
 A. thoracodorsalis [284](#), [290](#), [294](#), [298](#)
 A. thyroidea [thyroidea] caud. [244](#)
 (A. thyroidea [thyroidea] caud.) [246](#)
 A. thyroidea [thyroidea] caud. dextra [276](#)
 A. thyroidea [thyroidea] caud. sin. [244](#)
 A. thyroidea [thyroidea] cran. [244](#), [246](#)
 A. tibialis caudalis [324](#), [328](#), [332](#), [336](#)
 A. tibialis cranialis [324](#), [328](#), [332](#), [336](#)
 A. transversa cubiti [284](#), [286](#), [290](#), [294](#), [298](#)
 A. transversa faciei [248](#), [252](#), [260](#), [266](#)
 A. tympanica caudalis [246](#), [266](#)
 A. tympanica rostralis [248](#), [266](#)
 A. ulnaris [284](#), [286](#)
 A. umbilicalis 312–318
 A. urethralis [312](#), [314](#), [316](#)
 A. uterina 312–316, [320](#)
 A. vaginalis 312–318
 A. vertebralis [272](#), [276](#), [280](#), [282](#)
 A. vertebralis thoracica [274](#)
 A. vesicalis caudalis 312–318
 Aa. vesicales craniales [314](#), [316](#), [318](#)
 A. vesicalis cranialis [312](#)
 (A. vesicalis cranialis) [312](#)
 A. vesicalis media [320](#)
 A. vestibularis [316](#)
 Arteriola [567](#)
 Arteriola glomerularis afferens [196](#)
 Arteriola glomerularis efferens [196](#)

- Arteriola lat. retinae dors. 516
 Arteriola lat. retinae ventr. 516
 Arteriola macularis dorsalis 516
 Arteriola macularis ventralis 516
 Arteriola medialis retinae 516
 Arteriola med. retinae dors. 516
 Arteriola med. retinae ventr. 516
 Arteriolae rectae 196
 Arthrologia 565
 Articulatio, Articulationes 565
 Art. antebrachioarpea 84
 Art. atlantoaxialis 80
 Art. atlantooccipitalis 80
 Art. calcaneoquartalis [calcaneo-cuboidea] 94
 Art. capitis costae 82
 Art. carpi 84
 Artt. carpometacarpeae 86
 Artt. cartilagineae 565
 Art. centrodistalis [cuneonavicularis] 565
 Artt. columnae vertebralis, thoracis et cranii 80
 Art. composita 565
 Art. condylaris 565
 Artt. costochondrales 82
 Art. costotransversaria 82
 Artt. costovertebrales 82
 Art. coxae 90
 Art. cricoarytenoidea [-arytaenoidea] 184
 Art. cricothyroidea [-thyroidea] 182
 Art. cubiti 84
 [Art. dentoalveolaris] 565
 Art. ellipsoidea 565
 Art. femoropatellaris 92
 Art. femorotibialis 92
 Artt. fibrosae 565
 Art. genus 92
 Art. humeri 84
 Art. humeroradialis 84
 Art. humeroulnaris 84
 Art. incudomallearis 538
 Art. incudostapedia 538
 Artt. intercarpeae 84
 Art. intermandibularis 78
 Artt. intermetacarpeae 86
 Artt. intermetatarseae 96
 Artt. interphalangeae dist. manus 88
 Artt. interphalangeae pedis 96
 Artt. interphalangeae prox. manus 88
 Artt. intertarseae 94
 Art. intertransversaria lumbosacralis 80
 Artt. intertransversariae lumbales 80
 Artt. intrachondrales 82
 Art. lumbosacralis 80
 Artt. manus 84
 Art. mediocarpea 84
 Artt. membri pelvini 90
 Artt. membri thoracici 84
 Artt. metacarpophalangeae 86
 Artt. metatarsophalangeae 96
 Artt. ossiculorum auditus 538
 Art. ossis carpi accessorii [ossis pisiformis] 86
 Artt. pedis 94
 Art. plana 565
 Artt. processuum articularium 80
 Art. radiocarpea 84
 Art. radioulnaris distalis 84
 Art. radioulnaris proximalis 84
 Art. sacroiliaca 90
 Art. sellaris 565
 Art. simplex 565
 Art. spherioidea [sphaeroidea, cotylica] 565
 Artt. sternocostales 82
 Artt. synoviales 565
 Art. synovialis manubriosternalis 82
 Art. talocalcanea 94
 Art. talocalcaneocentralis [talocalcaneonavicularis] 94
 Art. tarsi 94
 Art. tarsoeruralis 94
 Artt. tarsometatarseae 96
 Art. temporohyoidea 78
 Art. temporomandibularis 78
 Art. thyrohyoidea [thyreo-] 182
 Art. tibiofibularis distalis 94
 Art. tibiofibularis proximalis 92
 Art. trochoidea 565
 Art. ulnocarpea 84
 [Arytaena] 569
 Arytena 569
 Ascendens 569
 Asper 569
 Associus 569
 Atavus 569
 Atlas 42
 Atrium cordis 236
 Atrium dextrum 238
 Atrium ruminis 156
 Atrium sinistrum 240
 Auditus 569
 Auricula 540, 562
 Auricula atrii 236
 Auricula dextra 238
 Auricula sinistra 240
 Auris 562
 [Auris] 526
 Auris externa 540
 Auris interna 526
 Auris media 534
 Autonomicus 569
 Autopodium 569
 Axialis 568
 Axilla 563
 Axis 42
 Axis bulbi externus 510
 Axis bulbi internus 510
 Axis lentis 518
 Axis opticus 510
 Axis pelvis 645
 Azygos 569
 Barba 546
 Basalis 569
 Basihyoideum 38
 Basilaris 569
 Basipodium 569
 Basis 56, 74, 184
 Basis cartilaginis arytenoideae [arytaenoideae] 184
 Basis cecii [caeci] 164
 Basis cerebri 446
 Basis cochleae 532
 Basis cordis 234
 Basis cornus 548
 Basis cranii externa 10
 Basis cranii interna 12
 Basis cunei 556
 Basis modioli 532
 Basis omasi 158
 Basis ossis sacri 44
 Basis patellae 68
 Basis phalangis mediae 58
 Basis phalangis proximalis 58
 Basis pulmonis 188
 Basis pyramidis 194
 Basis stapedis 536
 Basis tori 556
 Bicornis 569
 Bifidus 569
 Bifurcatio tracheae 188
 Brachium 563
 Brachium colliculi caudalis 432
 Brachium colliculi rostralis 432
 [Brachium conjunctivum] 424, 434
 [Brachium pontis] 424
 Branchia 569
 Brevis 569
 Bronchi 188
 Bronchi lobares 188
 Bronchi segmentales 188
 Bronchuli 190
 Bronchuli respiratorii 190
 Bronchulus 569
 Bronchus principalis [dext. et sin.] 188
 Bronchus trachealis 188
 Bucca 140, 562
 Buccina 569
 Bulbus aortae 242
 Bulbus glandis 206
 Bulbus oculi 510, 562
 Bulbus olfactorius 448
 Bulbus olfactorius accessorius 448
 Bulbus penis 208
 Bulbus pili 546
 Bulbus vestibuli 218
 Bulla conchalis dorsalis 178
 Bulla conchalis ventralis 178
 Bulla lacrimalis 30
 Bulla tympanica 24
 Bursa bicipitoradialis 132
 B. calcanea m. flexoris digit. supf. 138
 Bb. et vag. synoviales 566
 Bb. et vag. synoviales capitis et trunci 132

- Bb. et vag. synoviales membri pelvini [136](#)
- Bb. et vag. synoviales membri thoracici [132](#)
- [B. infracardiaca] [192](#)
- B. infrapatellaris distalis [136](#)
- B. infrapatellaris proximalis [136](#)
- B. intertubercularis [132](#)
- B. intratendinea olecrani [132](#)
- B. ischiadica m. obturatorii externi [136](#)
- B. ischiadica m. obturatorii interni [136](#)
- B. ischiadica m. semitendinosi [136](#)
- Bb. m. flexoris digit. supf. [134](#)
- B. m. recti femoris [136](#)
- B. m. tensoris veli palatini [132](#)
- B. omentalis 226
- B. ovarica 230
- (B. pharyngea) [148](#)
- Bb. podotrochleares manus [134](#)
- Bb. podotrochleares pedis [136](#)
- B. subcutanea calcanea [136](#)
- B. subcutanea iliaca [coxalis] [136](#)
- B. subcutanea ischiadica [136](#)
- B. subcutanea malleoli lat. [136](#)
- B. subcutanea malleoli med. [136](#)
- B. subcutanea olecrani [132](#)
- B. subcutanea precarpalis [prae-] [132](#)
- B. subcutanea prepatellaris [prae-] [136](#)
- B. subcutanea prescapularis [prae-] [132](#)
- B. subcutanea trochanterica [136](#)
- B. subcutanea tuberositatis tibiae [136](#)
- B. subdeltoidea 132
- B. subfascialis prepatellaris [prae-] [136](#)
- B. subligamentosa nuchalis caud. [132](#)
- B. subligamentosa nuchalis cran. [132](#)
- B. subligamentosa supraspinalis [132](#)
- B. subtendinea iliaca [136](#)
- B. subtendinea m. abductoris digiti I [pollicis] longi [134](#)
- B. subtendinea m. bicipitis femoris dist. [136](#)
- B. subtendinea m. brachialis [132](#)
- B. subtendinea m. coracobrachialis [132](#)
- B. subtendinea m. extensoris carpi obliqui [134](#)
- B. subtendinea m. extensoris carpi radialis [134](#)
- B. subtendinea m. extensoris carpi ulnaris [m. ulnaris lateralis] [134](#)
- B. subtendinea m. extensoris digit. communis [134](#)
- B. subtendinea m. extensoris digit. lat. manus [134](#)
- B. subtendinea m. extensoris digit. lat. pedis [136](#)
- B. subtendinea m. extensoris digit. longi [136](#)
- B. subtendinea m. flexoris digit. profundi 134
- B. subtendinea m. infraspinati [132](#)
- B. subtendinea m. obturatorii externi 136
- B. subtendinea m. obturatorii interni [136](#)
- B. subtendinea m. peron. [fibularis] brevis [136](#)
- B. subtendinea m. peron. [fibularis] longi [136](#)
- B. subtendinea m. semitendinosi [136](#)
- B. subtendinea m. subscapularis [132](#)
- B. subtendinea m. supraspinati [132](#)
- B. subtendinea m. teretis majoris [132](#)
- B. subtendinea m. teretis minoris [132](#)
- B. subtendinea m. tibialis cran. [136](#)
- B. subtendinea m. tricipitis brachii [132](#)
- Bb. subtendineae mm. interosseorum manus [134](#)
- Bb. subtendineae mm. interosseorum pedis [136](#)
- Bb. subtendineae prepatellares [prae-] [136](#)
- B. synovialis [566](#)
- B. synovialis subcutanea [566](#)
- B. synovialis subfascialis [566](#)
- B. synovialis subligamentosa [566](#)
- B. synovialis submuscularis [566](#)
- B. synovialis subtendinea [566](#)
- B. tendinis calcanei [136](#)
- B. testicularis 202, 230
- B. trochanterica m. bicipitis femoris [132](#)
- B. trochanterica m. glutei [glutaei] prof. [136](#)
- B. trochanterica m. glutei [glutaei] supf. [136](#)
- Bb. trochantericae m. glutei [glutaei] medii [136](#)
- [Caecum] [164](#)
- [Caecum cupulare] [528](#)
- [Caecum vestibulare] [528](#)
- Caecus 569
- Caeruleus 569
- Calcaneus [72](#)
- Calcar metacarpeum [548](#), [563](#)
- Calcar metatarseum [548](#), [564](#)
- Calices renales [196](#)
- Calices renales majores [196](#)
- Calices renales minores [196](#)
- Calculus gustatorius [542](#)
- Calculus ophthalmicus [510](#)
- Calix 569
- Callosus 569
- Calvaria [10](#)
- Calx [564](#)
- Calx, calcis 569
- Camera anterior bulbi [518](#)
- Camera posterior bulbi [518](#)
- Camera vitrea bulbi [518](#)
- Canales alveolares [32](#)
- Canales diploici [10](#)
- Canales longitudinales modioli [532](#)
- Canales palatini minores [36](#)
- Canales semicirculares ossei [532](#)
- Canaliculi caroticotypanici [24](#)
- Canaliculus chordae tympani [22](#)
- Canaliculus cochleae [22](#)
- Canaliculus lacrimalis [524](#)
- Canaliculus mastoideus [22](#)
- Canaliculus tympanicus [22](#)
- Canalis alaris [20](#)
- Canalis alimentarius [152](#)
- Canalis alveolaris [32](#), [38](#)
- Canalis analis [168](#)
- Canalis caroticus [24](#)
- Canalis carpi [86](#), [122](#)
- Canalis centralis [414](#)
- Canalis cervicis uteri [216](#)
- Canalis condylaris [16](#)
- (Canalis craniopharyngeus) [18](#)
- Canalis facialis [22](#)
- Canalis femoralis [130](#)
- Canalis hyaloideus [518](#)
- Canalis infraorbitalis [32](#)
- Canalis inguinalis [114](#)
- Canalis interincisivus [12](#)
- Canalis lacrimalis [30](#)
- Canalis mandibulae [38](#)
- Canalis metacarpi dist. [56](#)
- Canalis metacarpi prox. [56](#)
- Canalis metatarsi dist. [74](#)
- Canalis metatarsi prox. [74](#)
- Canalis musculotubarius [24](#)
- Canalis nasolacrimalis [14](#)
- Canalis nutricius [565](#)
- Canalis n. hypoglossi [16](#)
- Canalis n. petrosi majoris [22](#)
- Canalis n. petrosi minoris [22](#)
- Canalis n. trigemini [22](#)
- Canalis obturatorius [90](#)
- Canalis omasi [158](#)
- Canalis opticus [20](#)
- Canalis palatinus major [12](#), [36](#)
- Canalis petrooccipitalis [12](#)
- Canalis pterygoideus [20](#)
- Canalis pudendalis [224](#)
- Canalis pyloricus [154](#)
- Canalis radialis dentis [144](#)
- Canalis sacralis [44](#)
- Canalis semicircularis anterior [532](#)
- Canalis semicircularis lateralis [532](#)
- Canalis semicircularis posterior [532](#)
- Canalis sinus transversi [10](#)
- Canalis solearis [58](#)
- Canalis spiralis cochleae [532](#)
- Canalis spiralis modioli [532](#)
- Canalis supraorbitalis [26](#)

- Canalis tarsi 72
 Canalis vaginalis [202](#)
 Canalis vertebralis 40
 Capillaris 569
 Capilli 546
 Capillus 569
 Capitalis 569
 Capitatus 569
 Capitulum humeri [50](#)
 Capsula [232](#), 402, 412
 Capsula adiposa 194
 Capsula articularis [78–96](#), 565
 Capsula articularis cricoarytenoidea [-arytaenoidea] [184](#)
 Capsula articularis cricothyroidea [-thyroidea] [182](#)
 Capsula articularis thyrohyoidea [thyreo-] [182](#)
 Capsula externa 460
 Capsula fibrosa 194, 230
 Capsula fibrosa perivascularis 170
 Capsula interna 460
 Capsula lentis 518
 Capsula prostatae [204](#)
 Capsula tonsillaris [150](#)
 Capsula unguis 556
 Capsulae articulares 86, 88, 96
 Caput 56, [74](#), 562, 566
 Caput accessorium 116
 Caput costae [46](#)
 Caput epididymidis 200
 Caput fibulae [20](#)
 Caput humerale 118
 Caput humeri [50](#)
 Caput laterale 116, 128
 Caput longum 116
 Caput mallei 536
 Caput mandibulae [38](#)
 Caput mediale 116, 128
 Caput nuclei caudati 460
 Caput ossis femoris [66](#)
 Caput phalangis mediae [58](#)
 Caput phalangis proximalis [58](#)
 Caput radiale 118
 Caput radii [52](#)
 Caput stapedis 536
 Caput tali 72
 Caput ulnae [54](#)
 Caput ulnare 118
 [Caput vertebrae] 40
 Cardiacus 569
 Cardia 569
 Carina tracheae [188](#)
 Carneus 569
 Carpus 563
 Cartilagineae bronchiales [188](#)
 Cartilagineae laryngis [182](#)
 Cartilagineae nasi externi 174
 Cartilagineae tracheales [188](#)
 Cartilago 524
 Cartilago alaris 174
 Cartilago anularis 540
 Cartilago articularis 565
 Cartilago arytenoidea [arytaenoidea] [184](#)
 Cartilago auriculae 540
 Cartilago cordis 236
 Cartilago costalis 46
 Cartilago cricoidea [182](#)
 Cartilago dorsi linguae [148](#)
 Cartilago epiglottica [184](#)
 Cartilago epiphysialis 565
 Cartilago interarytenoidea [-arytaenoidea] [184](#)
 Cartilago manubrii [46](#)
 Cartilago meatus acustici 540
 Cartilago nasalis accessoria lat. 174
 Cartilago nasalis accessoria med. 174
 Cartilago nasi lateralis dors. 174
 Cartilago nasi lateralis ventr. 174
 Cartilago scapulae 48
 Cartilago scutiformis 542
 Cartilago septi nasi [176](#)
 Cartilago sesamoidea [184](#)
 Cartilago thyroidea [thyroidea] [182](#)
 Cartilago tubae auditivae 538
 Cartilago unguis lateralis 60
 Cartilago unguis medialis 60
 Cartilago vomeronasalis [176](#), 542
 Cartilago xiphoidea 46
Caruncula 220
 Caruncula lacrimalis 524
 Caruncula sublingualis 140
 Carunculae 216
 Cauda 563, 566
 Cauda epididymidis [200](#)
 Cauda equina [480](#)
 Cauda helices 540
 Cauda nuclei caudati 460
 Caudalis 568
 Caverna 569
 Cavernae corporis spongiosi 208
 Cavernae corporum cavernosorum 208
 Cavitas glenoidalis 48
 Cavum abdominis 562
 Cavum articulare 565
 Cavum conchae 540
 Cavum coronale dentis [144](#)
 Cavum cranii 10
 Cavum dentis [pulpae] [144](#)
 Cavum epidurale 462
 Cavum hypophysis [232](#)
 Cavum infraglotticum 186
 Cavum laryngis 186
 Cavum mediastini serosum [192](#)
 Cavum medullare 565
 Cavum nasi [14](#), [176](#)
 Cavum oris 140, 562
 Cavum oris proprium 140
 Cavum pelvis 64, 562
 Cavum pericardii [234](#)
 Cavum peritonei [peritoneae] [226](#)
 Cavum pharyngis [148](#)
 Cavum pleurae [192](#)
 Cavum preputiale [prae-] 206
 Cavum septi telencephali [pellucidi] 448
 Cavum subarachnoideale 462
 Cavum subdurale 462
 Cavum thoracis [46](#), [192](#), 562
 Cavum trigeminale 464
 Cavum tympani [22](#), 534
 Cavum uteri [214](#)
 Cavum vaginale [202](#)
 Cavus 569
 Cecum [164](#)
 Cecum cupulare 528
 Cecum vestibulare 528
 Cecus 569
 Celiacus 569
 Cella 569
 Cellula 569
 Cellulae 178
 Cellulae ethmoidales 28, [180](#)
 Cellulae reticuli [160](#)
 Cellulae tympanicae 534
 Cementum [144](#)
 Centralis 569
 [Centrum medianum] [444](#)
 Centrum ossificationis primarium 565
 Centrum ossificationis secundarium 565
 Centrum semiovale 458
 Centrum tendineum 112
 Centrum tendineum perinei 224
 Cephalicus 569
 Ceratohyoideum [38](#)
 Cerebellum [476](#)
 Cerebrum [446](#)
 Ceruleus 569
 Cervix 562
 Cervix dentis [144](#)
 Cervix uteri [214](#)
 Cervix vesicae 198
 Chiasma opticum 438
 Choanae [14](#), [176](#)
 Chorda tympani 472
 Chordae tendineae 236
 [Chorioidea] 512
Chorion 220
 Chorioidea 512
 Chroma 569
 Chylus 569
 Cilia 522, 546
 Cilium 569
 Cinereus 569
 Cingulum [144](#), [458](#)
 Cingulum membri pelvini [62](#)
 Cingulum membri thoracici 48
 Circulus arteriosus cerebri 272
 Circulus arteriosus iridis major 514
 Circulus arteriosus iridis minor 514
 Circulus articularis vasculosus 567
 Circulus vasculosus n. optici 516
 Circumferentia articularis [52](#)
 Circumflexus 569
 Cirrus capitis 546
 Cirrus caudae 546, 563
 Cirrus metacarpeus 546
 Cirrus metatarsus 546
 Cisterna 567

- Cisterna cerebellomedullaris 462
 Cisterna chiasmatis 462
 Cisterna chyli 402
 Cisterna interpeduncularis 462
 Cisterna valliculae [fossae] lat. cerebri 462
 Cisternae subarachnoideales 462
 Claustrum 460
 Clavicula 48
 Clinoideus 569
 Clitoris [218](#)
 Clivus 12
 [Clunes] 562
 Clunis 569
 Coccyx 569
 Cochlea 532
 Cochlea tibiae [70](#)
 Coeliacus 569
 Collateralis 569
 Colliculus caudalis 432
 Colliculus rostralis 432
 Colliculus seminalis [210](#)
 Collum 562
 Collum coli 166
 Collum costae 46
 Collum fibulae [70](#)
 Collum glandis 206
 Collum humeri [50](#)
 Collum mallei 536
 Collum mandibulae [38](#)
 Collum omasi 158
 Collum ossis femoris [66](#)
 Collum processus cornualis 28
 Collum radii [52](#)
 Collum scapulae 48
 Collum tali 72
 Collum ves. felleae [172](#)
 Colon 166
 Colon ascendens 166
 Colon crassum 166
 Colon descendens 166
 Colon dorsale dextrum 166
 Colon dorsale sinistrum 166
 Colon sigmoideum 166
 [Colon tenue] 166
 Colon transversum 166
 Colon ventrale dextrum 166
 Colon ventrale sinistrum 166
 Columna fornicis [450](#)
 Columna ureterica 198
 Columna vertebralis 40, 562
 Columnae anales [168](#)
 Columnae rectales [168](#)
 Columnae renales 194
 Comes, comitis 569
 Commissura alba 416
 Commissura caudalis 436
 Commissura colliculorum caudalium 436
 Commissura colliculorum rostralium 436
 Commissura fornicis [hippocampi] dors. [450](#)
 Commissura fornicis [hippocampi] ventr. [450](#)
 Commissura grisea 416
 Commissura habenularum 442, [446](#)
 Commissura labiorum dorsalis [218](#)
 Commissura labiorum ventralis [218](#)
 Commissura palpebrarum lateralis 522
 Commissura palpebrarum medialis 522
 Commissura rostralis 452
 Commissura supramamillaris [440](#)
 Commissura supraoptica dors. [440](#)
 Commissura supraoptica ventr. [440](#)
 Commissurae [440](#)
 Commissurae intrahypothalamicae [440](#)
 Commissurae supraopticae [440](#)
 Communicatio 569
 Communis 569
 Compactus 569
 Compressor 569
 Concha auriculae 540
 Concha nasalis dorsalis [30](#), 178
 Concha nasalis media [30](#), 178
 Concha nasalis ventralis 178
 Conchae ethmoidales 178
 Condylus humeri 48
 Condylus lateralis [68](#)
 Condylus medialis 68
 Condylus occipitalis 16
 Confluens sinuum [362](#)
 Congenitus 569
 [Coni epididymidis] [200](#)
 Conjugatio 569
 Conjunctivus 569
 Connexus 569
 Constrictor 569
 Conus arteriosus [238](#)
 Conus medullaris 414
 (Conus papillaris) 518
 Convexus 569
 Convolutus 570
 Cor [234](#)
 [Corium] [544](#)
 [Corium cornus] 548
 [Corium coronae] [550](#)
 [Corium cunei] 556
 [Corium limbi] [550](#)
 [Corium parietis] 552
 [Corium soleae] 554
 [Corium tori] 556
 Cornea 512
 Corniculatus 570
 Cornu 174, 548, 562
 [Cornu ammonis] [450](#), 452, 460
 Cornu ammonis inversum [450](#)
 Cornu caudale [182](#)
 Cornu dorsale 414
 Cornu laterale 414
 [Cornu majus] [38](#)
 [Cornu minus] [38](#)
 Cornu rostrale [182](#), 460
 Cornu temporale 460
 Cornu uteri [dextrum et sinistrum] [214](#)
 Cornu ventrale 414
 Corona [550](#)
 Corona ciliaris 512
 Corona clinica [144](#)
 Corona dentis [144](#)
 Corona glandis 206
 Corona processus cornualis 28
 Corona radiata 458
 Corpora caudalia [coccygea] [304](#), [318](#)
 Corpora paraaortica 244
 Corpus [18](#), [20](#), [74](#)
 [Corpus] [38](#)
 Corpus abomasi [160](#)
 Corpus adiposum auriculare 542
 Corpus adiposum buccae 140
 Corpus adiposum extraperiorbitale 520
 Corpus adiposum fossae ischio-rect. 224
 Corpus adiposum infrapatellare 92
 Corpus adiposum intraperiorbitale 520
 Corpus adiposum orbitae 520
 Corpus albicans 212
 Corpus amygdaloideum 452
 Corpus callosum 456
 Corpus cavernosum clitoridis [218](#)
 Corpus cavernosum penis 208
 Corpus ceci [caeci] [164](#)
 Corpus cerebelli [426](#)
 Corpus ciliare 512
 Corpus clitoridis [218](#)
 Corpus cornus 548
 Corpus costae [46](#)
 Corpus dentis [144](#)
 Corpus epididymidis [200](#)
 Corpus fibulae [70](#)
 Corpus fornicis [450](#)
 Corpus geniculatum laterale 442
 Corpus geniculatum mediale 442
 Corpus [glandulae pinealis] 442
 Corpus humeri 48
 Corpus incudis 536
 Corpus juxtarestiforme 418
 Corpus linguae [146](#)
 Corpus luteum 212
 Corpus mamillare 438
 Corpus mammae 560
 Corpus mandibulae [38](#)
 Corpus maxillae 32
 Corpus medullare [428](#)
 Corpus nuclei caudati 460
 Corpus omasi 158
 Corpus ossis femoris [66](#)
 Corpus ossis ilii [62](#)
 Corpus ossis incisivi [34](#)
 Corpus ossis ischii 64
 Corpus ossis pubis 64
 Corpus pancreatis [172](#)
 Corpus penis 206
 [Corpus perineale] 224
 Corpus phalangis mediae [58](#)

- Corpus phalangis prox. [58](#)
 Corpus prostatae [204](#)
 Corpus radii [52](#)
 Corpus restiforme [418](#)
 Corpus soleae [554](#)
 Corpus spongiosum glandis [208](#),
[218](#)
 Corpus spongiosum penis [208](#)
 Corpus sterni [46](#)
 Corpus striatum [460](#)
 Corpus subthalamicum [442](#)
 Corpus tali [72](#)
 Corpus tibiae [68](#)
 Corpus trapezoideum [422](#), [424](#)
 Corpus ulnae [54](#)
 Corpus uteri [214](#)
 Corpus ventriculi [154](#)
 Corpus vertebrae [40](#)
 Corpus vesicae [198](#)
 Corpus vesicae felleae [172](#)
 Corpus vitreum [518](#)
 Corpuscula nervosa terminalia
[568](#)
 Corpuscula renis [194](#)
 Corpusculum [570](#)
 Cortex [232](#), [402](#), [412](#)
 Cortex cerebelli [428](#)
 Cortex cerebri [446](#)
 Cortex frontalis [458](#)
 Cortex lentis [518](#)
 Cortex occipitalis [458](#)
 Cortex ovarii [212](#)
 Cortex parietalis [458](#)
 Cortex renis [194](#)
 Cortex temporalis [458](#)
 Costa [570](#)
 Costae [46](#)
 Costae fluctuantes [46](#)
 Costae spuriae [asternales] [46](#)
 Costae verae [sternales] [46](#)
 Cotyla [569](#)
Cotyledon [220](#)
 Coxa [562](#), [569](#)
 Cranialis [568](#)
 Cranium [10](#), [562](#)
 Crassus [570](#)
 Crena ani [563](#)
 (Crena marginis solearis) [60](#)
 Cribriformis [570](#)
 Cribrosus [570](#)
 Cricoideus [570](#)
 Crista ampullaris [526](#)
 Crista arcuata [154](#)
 Crista basilaris [530](#)
 Crista capitis costae [46](#)
 Crista colli costae [46](#)
 Crista conchalis [32](#)
 Crista enameli [144](#)
 Crista ethmoidalis [30](#), [34](#)
 Crista facialis [32](#), [36](#)
 Crista frontalis [28](#)
 Crista galli [28](#)
 Crista humeri [48](#)
 Crista iliaca [62](#)
 Crista infratemporalis [18](#)
 Crista intertrochanterica [66](#)
 Crista marginalis [144](#)
 Crista mediana [182](#)
 Crista nasalis [34](#)
 Crista nuchae [16](#)
 Crista occipitalis externa [16](#)
 Crista occipitalis interna [16](#)
 Crista orbitalis ventralis [28](#)
 Crista orbitosphenoidalis [20](#)
 Crista orbitotemporalis [28](#)
 (Crista palatina) [36](#)
 Crista partis petrosae [22](#)
 Crista pterygoidea [20](#)
 Crista renalis [194](#)
 Crista sacralis intermedia [44](#)
 Crista sacralis lateralis [44](#)
 Crista sacralis mediana [44](#)
 Crista sagittalis externa [16](#), [18](#), [26](#)
 Crista sagittalis interna [18](#)
 (Crista sagittalis interna) [26](#)
 Crista sphenoidalis [20](#)
 Crista sphenoccipitalis [12](#)
 Crista sterni [46](#)
 Crista supracondylaris lat. [50](#)
 Crista supramastoidea [24](#)
 Crista supraventricularis [238](#)
 Crista symphysialis [64](#)
 Crista tentorica [24](#)
 Crista terminalis [238](#)
 Crista transversa [52](#), [534](#)
 Crista tuberculi majoris [50](#)
 Crista tuberculi minoris [50](#)
 Crista unguicularis [60](#)
 Crista urethralis [210](#), [220](#)
 Crista ventralis [40](#)
 Crista vestibuli [532](#)
 Crista vomeris [30](#)
 Cristae cutis [544](#)
 Cristae reticuli [160](#)
 Cruces pilorum [546](#)
 Cruciatus [570](#)
 Crura membranacea [526](#)
 Crura membranacea ampullaria
[526](#)
 Crura ossea [532](#)
 Crura ossea ampullaria [532](#)
 Crus [563](#)
 Crus breve [536](#)
 Crus caudale [428](#), [536](#)
 Crus caudale capsulae internae
[460](#)
 Crus cerebri [432](#), [434](#)
 Crus clitoridis [218](#)
 Crus cunei laterale [556](#)
 Crus cunei mediale [556](#)
 Crus dextrum [112](#)
 Crus [dextrum et sinistrum] [236](#)
 Crus fornicis [450](#)
 Crus helcis laterale [540](#)
 Crus helcis mediale [540](#)
 Crus laterale [114](#)
 Crus longum [536](#)
 Crus mediale [114](#)
 Crus membranaceum commune
[526](#)
 Crus membranaceum simplex [526](#)
 Crus osseum commune [532](#)
 Crus osseum simplex [532](#)
 Crus penis [206](#)
 Crus rostrale [428](#), [536](#)
 Crus rostrale capsulae internae
[450](#)
 Crus sinistrum [112](#)
 Crus soleae abaxiale [554](#)
 Crus soleae axiale [554](#)
 Crus soleae laterale [554](#)
 Crus soleae mediale [554](#)
 Cryptae tonsillares [150](#)
 Cubitus [563](#)
 Culmen [428](#)
 [Culmen] [190](#)
 Cuneus corneus [556](#)
 Cuneus unguulae [556](#)
 Cupula [526](#)
 Cupula cochleae [532](#)
 Cupula diaphragmatis [112](#)
 Cupula pleurae [192](#)
 Curvatura ceci [caeci] major [164](#)
 Curvatura ceci [caeci] minor [164](#)
 Curvatura dorsalis [156](#)
 Curvatura major [158](#)
 Curvatura minor [158](#)
 Curvatura omasi [158](#)
 Curvatura ventralis [156](#)
 Curvatura ventriculi major [154](#)
 Curvatura ventriculi minor [154](#)
 Cuspis angularis [238](#)
 Cuspis [coronae] dentis [144](#)
 Cuspis parietalis [238](#)
 Cuspis septalis [238](#)
 Cutis [544](#)
 Cutis scroti [210](#)

 Deciduus [570](#)
 Declive [428](#)
 Declive, declivis [570](#)
 Decussatio dorsalis [434](#)
 Decussatio lemniscorum medi-
 alium [422](#)
 Decussatio nervorum trochlea-
 rium [434](#), [464](#)
 Decussatio pedunculorum cere-
 bellarium rostr. [434](#)
 Decussatio pyramidum [418](#), [422](#)
 Decussatio ventralis [434](#)
 Decussationes tegmenti [434](#)
 Deferens [570](#)
 Delta [570](#)
 Dens [42](#)
 Dens lupinus [146](#)
 Dens sectorius [146](#)
 Densus [570](#)
 Dentes [144](#)
 Dentes acustici [530](#)
 Dentes canini [146](#)
 Dentes decidui [146](#)
 Dentes incisivi [146](#)
 Dentes molares [146](#)
 Dentes permanentes [146](#)
 Dentes premolares [prae-] [146](#)
 Denticulatus [570](#)
 Dentinum [144](#)
 Depressor [570](#)

- Dermis [544](#)
 Dermis cornus [548](#)
 Dermis coronae [550](#)
 Dermis cunei [556](#)
 Dermis limbi [550](#)
 Dermis parietis [552](#)
 Dermis soleae [554](#)
 Dermis tori [556](#)
 Descendens [570](#)
Descensus testis [204](#)
 Dexter [568](#)
 Diameter conjugata [64](#)
 Diamater transversa [64](#)
 Diameter verticalis [64](#)
 Diaphragma [112](#)
 Diaphragma pelvis [222](#)
 Diaphragma sellae [462](#)
 Diaphysis [565](#)
 Diastema [146](#)
 Diencephalon [436](#)
 Digastricus [570](#)
 Digitalis [570](#)
 Digiti II – V [563](#), [564](#)
 Digiti manus [563](#)
 Digiti pedis [564](#)
 Digitus [563](#), [564](#)
 Dilator [570](#)
 Diploë [10](#)
 Diplois [570](#)
 Discus articularis [78](#), [565](#)
 Discus intervertebralis [80](#)
 Discus n. optici [516](#)
 Distalis [568](#)
 Diverticulum nasi [176](#)
 Diverticulum pharyngeum [148](#)
 Diverticulum preputiale [prae-] [206](#)
 Diverticulum suburethrale [218](#)
 Diverticulum tubae auditivae [538](#)
 Diverticulum ventriculi [154](#)
 Dorsalis [568](#)
 Dorsum [562](#)
 Dorsum auriculae [542](#)
 Dorsum linguae [146](#)
 Dorsum manus [563](#)
 Dorsum nasi [174](#), [562](#)
 Dorsum pedis [563](#)
 Dorsum penis [206](#)
 Dorsum sellae [18](#)
 (Ductuli aberrantes) [200](#)
 Ductuli alveolares [190](#)
 Ductuli biliferi [170](#)
 Ductuli efferentes testis [200](#)
 Ductuli excretorii [524](#)
 Ductuli interlobulares [170](#)
 Ductuli prostatici [204](#)
 Ductuli transversi [212](#)
 Ductulus [570](#)
Ductus arteriosus [242](#)
 Ductus choledochus [172](#)
 Ductus cochlearis [528](#)
 Ductus cysticus [172](#)
 Ductus deferens [202](#)
 (Ductus deferens vestigialis) [216](#)
 Ductus ejaculatorius [202](#)
 Ductus endolymphaticus [526](#)
 Ductus epididymidis [200](#)
 Ductus epoöphori longitudinalis [212](#)
 Ductus excretorius [204](#)
 Ductus gl. bulbourethralis [204](#)
 Ductus gl. zygomaticae major [142](#)
 Ductus gl. zygomaticae minores [142](#)
 Ductus hepaticus communis [170](#)
 Ductus hepaticus dexter [170](#)
 Ductus hepaticus sinister [170](#)
 Ductus hepatocystici [172](#)
 Ductus incisivus [176](#)
 Ductus lactifer [560](#)
 Ductus lymphaticus dexter [402](#)
 Ductus mandibularis [142](#)
Ductus mesonephricus [220](#)
 Ductus nasolacrimalis [524](#)
 Ductus pancreaticus [172](#)
 Ductus pancreaticus accessorius [172](#)
 Ductus papillares [194](#)
 Ductus papillaris [560](#)
Ductus paramesonephricus [220](#)
 (Ductus paraurethrales) [220](#)
 Ductus parotideus [142](#)
 Ductus perilymphaticus [528](#)
 Ductus reuniens [528](#)
 Ductus semicirculares [526](#)
 Ductus semicircularis anterior [526](#)
 Ductus semicirculares lateralis [526](#)
 Ductus semicirculares posterior [526](#)
 Ductus sublinguales minores [142](#)
 Ductus sublingualis major [142](#)
 Ductus thoracicus [402](#)
Ductus thyroglossus [thyreo-] [146](#)
 Ductus utriculosaccularis [526](#)
Ductus venosus [374](#)
 Ductus vomeronasalis [276](#), [542](#)
 Duodenum [162](#)
 Dura mater encephali [462](#)
 Dura mater spinalis [462](#)
 Durus [570](#)
 Ectoturbinalia [28](#)
 Efferens [570](#)
 Ejaculatorius [570](#)
 Elasticus [570](#)
 Ellipsoideus [570](#)
 Embryo [570](#)
 Eminentia conchae [542](#)
 Eminentia cruciformis [10](#)
 Eminentia iliopubica [64](#)
 Eminentia intercondylaris [68](#)
 Eminentia medialis [430](#)
 Eminentia nuclei vestibularis med. [430](#)
 Emissarius [570](#)
 Enamelum [144](#)
 Encephalon [416](#)
 Endocardium [236](#)
 Endolympha [528](#)
 [Endometrium] [216](#)
 Endosteum [565](#)
 Endothelium [570](#)
 Endoturbinalia [28](#)
 Entericus [570](#)
 Ependyma [567](#)
 [Epicardium] [234](#)
 Epiceras [548](#)
 Epicondylus lateralis [52](#), [66](#)
 Epicondylus medialis [52](#), [66](#)
 Epidermis [544](#)
 Epidermis cornus [548](#)
 Epidermis coronae [550](#)
 Epidermis cunei [556](#)
 Epidermis limbi [550](#)
 Epidermis parietis [552](#)
 Epidermis soleae [554](#)
 Epidermis tori [556](#)
 Epididymis [200](#)
 Epigastrium [570](#)
 Epiglottis [184](#)
 Epiphyoideum [38](#)
 Epiphysis [565](#)
 [Epiploön] [226](#)
 Epithalamus [442](#)
 Epithelium anterius corneae [512](#)
 Epithelium ductus semicircularis [526](#)
 Epithelium lentis [518](#)
 Epithelium pigmentosum [514](#)
 Epithelium posterius corneae [512](#)
 Epithelium superficiale [212](#)
 Epoöphoron [212](#)
 Equator [510](#)
 Equator lentis [518](#)
 Equinus [570](#)
 Erector [570](#)
 Esophagus [152](#), [562](#)
 Ethmoturbinalia [28](#)
 Excavatio disci [516](#)
 Excavatio pubovesicalis [230](#)
 Excavatio rectogenitalis [230](#)
 Excavatio vesicogenitalis [230](#)
 Extensor [570](#)
 Externus [568](#)
 Extremitas capitata [200](#)
 Extremitas caudalis [40](#), [156](#), [194](#)
 Extremitas caudata [200](#)
 Extremitas cranialis [40](#), [156](#), [194](#)
 Extremitas dorsalis [412](#)
 Extremitas tubaria [212](#)
 Extremitas uterina [212](#)
 Extremitas ventralis [412](#)
 Facies [12](#), [562](#)
 Facies abaxialis [563](#), [564](#)
 Facies anterior [512](#), [514](#)
 Facies anterior lentis [518](#)
 Facies anterior palpebrarum [522](#)
 Facies articulares calcaneae [72](#)
 Facies articulares malleoli [70](#)
 Facies articulares talaris [72](#)
 Facies articularis [24](#), [56–60](#), [68](#), [184](#), [565](#)
 Facies articularis arytenoidea [arytaenoidea] [182](#)
 Facies articularis capitis costae [46](#)
 Facies articularis capitis fibulae [70](#)

- Facies articularis carpea [52](#)
 Facies articularis cricoidea [182](#)
 Facies articularis cuboidea [72](#)
 Facies articularis dorsalis [42](#)
 Facies articularis fibularis [68](#)
 Facies articularis hyoidea [182](#)
 Facies articularis malleolaris [72](#)
 Facies articularis navicularis [72](#)
 Facies articularis prox. [68](#)
 Facies articularis sesamoidea [58](#)
 Facies articularis sesamoidea lat. [66](#)
 Facies articularis sesamoidea med. [66](#)
 Facies articularis tarsea [74](#)
 Facies articularis thyroidea [thyroidea] [182](#)
 Facies articularis tuberculi costae [46](#)
 Facies articularis ventr. [42](#)
 Facies aspera [66](#)
 Facies atrialis [234](#)
 Facies auricularis [44](#), [62](#), [234](#)
 Facies axialis [60](#), [563](#), [564](#)
 Facies basilaris [446](#)
 Facies buccalis [38](#)
 Facies caudalis [50](#), [52](#), [68](#), [70](#), [563](#)
 Facies cerebialis [18](#), [24](#)
 Facies contactus [144](#)
 Facies convexa [446](#)
 Facies costalis [188](#)
 Facies costalis [medialis] [48](#)
 Facies cranialis [50](#), [52](#), [68](#), [563](#)
 Facies diaphragmatica [158](#), [168](#), [190](#)
 Facies distalis [144](#)
 Facies dorsalis [44](#), [56](#), [74](#), [172](#), [184](#), [194](#), [198](#), [204](#), [214](#), [232](#), [564](#)
 [Facies dorsolateralis] [446](#)
 Facies externa [26](#), [30](#), [552](#)–[556](#)
 Facies facialis [30](#), [32](#)
 Facies flexoria [58](#)
 Facies gastrica [412](#)
 Facies glutea [glutaea] [62](#)
 Facies iliaca [62](#)
 Facies interlobares [190](#)
 Facies interna [26](#)–[30](#), [552](#)–[556](#)
 Facies intestinalis [412](#)
 Facies labialis [34](#), [38](#)
 Facies laryngea [184](#)
 Facies lateralis [36](#), [48](#), [50](#), [54](#), [70](#), [74](#), [184](#), [200](#), [212](#), [563](#), [564](#)
 Facies lingualis [38](#), [144](#), [184](#)
 Facies lunata [62](#)
 Facies maxillaris [18](#), [36](#)
 Facies medialis [48](#), [50](#), [54](#), [68](#), [70](#), [74](#), [184](#), [188](#), [200](#), [212](#), [446](#), [563](#), [564](#)
 Facies medialis partis petrosae [22](#)
 Facies mesialis [144](#)
 Facies m. infraspinati [50](#)
 Facies m. interossei [60](#)
 Facies nasalis [30](#), [32](#), [36](#)
 Facies occipitalis [22](#)
 Facies oclusalis [144](#)
 Facies orbitalis [18](#), [28](#), [30](#), [32](#), [36](#)
 Facies palatina [34](#), [36](#)
 Facies palmaris [56](#), [563](#)
 Facies parietalis [58](#), [154](#)–[158](#)
 Facies parietalis [diaphragmatica] [412](#)
 Facies pelvina [44](#)
 Facies plantaris [74](#), [564](#)
 Facies poplitea [66](#)
 Facies posterior [512](#), [514](#)
 Facies posterior lentis [518](#)
 Facies posterior palpebrarum [522](#)
 Facies pterygopalatina [32](#)
 Facies renalis [412](#)
 Facies rostralis partis petrosae [22](#)
 Facies sacropelvina [62](#)
 Facies serrata [48](#)
 Facies solearis [58](#), [563](#), [564](#)
 Facies symphysialis [64](#)
 Facies temporalis [18](#), [24](#), [26](#)
 Facies urethralis [206](#)
 Facies ventralis [172](#), [194](#), [198](#), [204](#), [214](#), [232](#)
 Facies ventralis linguae [146](#)
 Facies ventralis partis petrosae [22](#)
 Facies vestibularis [facialis] [144](#)
 Facies visceralis [154](#)–[158](#), [168](#), [412](#)
 Falx cerebelli [462](#)
 Falx cerebri [462](#)
 Fascia [566](#)
 Fascia antebrachii [120](#)
 Fascia axillaris [120](#)
 Fascia brachii [120](#)
 Fascia buccopharyngea [104](#)
 Fascia caudae [coccygis] [114](#)
 Fascia cervicalis [106](#)
 Fascia clitoridis [218](#)
 Fascia cremasterica [202](#)
 Fascia cruris [130](#)
 [Fascia dentata] [450](#), [452](#)
 Fascia diaphragm. pelvis externa [222](#)
 Fascia diaphragm. pelvis interna [222](#)
 Fascia digiti [122](#), [130](#)
 Fascia dorsalis manus [122](#)
 Fascia dorsalis pedis [130](#)
 Fascia endothoracica [110](#), [192](#)
 Fascia glutea [glutaea] [130](#)
 Fascia iliaca [130](#)
 Fascia lata [130](#)
 Fascia masseterica [104](#)
 Fascia nuchae [110](#)
 Fascia obturatoria [222](#)
 Fascia palmaris [122](#)
 Fascia parotidea [104](#)
 Fascia pectoralis [110](#)
 Fascia pelvis [222](#)
 Fascia pelvis parietalis [222](#)
 Fascia pelvis visceralis [222](#)
 Fascia penis profunda [208](#)
 Fascia penis superficialis [208](#)
 Fascia perinei supf. [224](#)
 Fascia pharyngobasilaris [150](#)
 Fascia plantaris [130](#)
 Fascia prostatae [222](#)
 Fascia renalis [194](#)
 Fascia spermatica externa [202](#)
 Fascia spermatica interna [202](#)
 Fascia temporalis [104](#)
 Fascia thoracolumbalis [110](#)
 Fascia transversalis [114](#)
 Fasciae musculares [520](#)
 Fasciae orbitales [520](#)
 Fasciculi proprii [416](#)
 Fasciculi tegmenti [434](#)
 Fasciculus atrioventricularis [236](#)
 Fasciculus cuneatus [416](#), [418](#), [422](#)
 Fasciculus gracilis [416](#), [418](#), [422](#)
 Fasciculus longitudinalis dors. [426](#), [432](#), [440](#)
 Fasciculus longitudinalis inf. [458](#)
 Fasciculus longitudinalis medialis [416](#), [422](#), [426](#)
 Fasciculus longitudinalis sup. [458](#)
 Fasciculus mamillohypothalamicus [442](#)
 Fasciculus medialis telencephali [440](#)
 Fasciculus paraopticus [438](#)
 Fasciculus retroflexus [436](#), [446](#)
 Fasciculus uncinatus [458](#)
 Fauces [150](#), [562](#)
 Femur [563](#)
 [Femur] [66](#)
 Fenestra cochleae [534](#)
 Fenestra vestibuli [534](#)
 Fetus [570](#)
 Fibra [570](#)
 Fibrae arcuatae cerebri [458](#)
 Fibrae arcuatae profundae [422](#)
 Fibrae arcuatae superficiales [418](#), [422](#)
 Fibrae circulares [512](#)
 Fibrae commissurospinales [432](#)
 Fibrae corticonucleares [422](#), [426](#), [434](#)
 Fibrae corticoreticulares [422](#), [426](#), [434](#)
 Fibrae corticospinales [422](#), [426](#), [434](#)
 Fibrae hypothalamoretinales [440](#)
 Fibrae intercrurales [114](#)
 Fibrae interstitiospinales [432](#)
 Fibrae lentis [518](#)
 Fibrae longitudinales prof. [148](#)
 Fibrae longitudinales supf. [148](#)
 Fibrae meridionales [512](#)
 Fibrae obliquae externae [160](#)
 Fibrae obliquae internae [160](#)
 Fibrae periventriculares [440](#)
 Fibrae perpendiculares [148](#)
 Fibrae pontis transversae [426](#)
 Fibrae ruminoreticuloabomasicae [160](#)
 Fibrae tectospinales laterales [416](#), [422](#)
 Fibrae transversae [148](#)
 Fibrae vestibulocommissurales [432](#)
 Fibrae vestibulotectales [432](#)

- Fibrae vestibulothalamicae 432
 Fibrae zonulares 518
 Fibrilla 570
 Fibrocartilagineae parapatellares 92
 Fibrocartilago 570
 Fibula 70
 Fibularis 570
 Fila radicularia 480
 Filamentum 570
 Filum durae matris spinalis 462
 Filum terminale 414
 Fimbria hippocampi 450
 Fimbria ovarica 212
 Fimbriae tubae 212
 Fissura interincisiva 12
 Fissura interlobaris caud. 190
 Fissura interlobaris cran. [pulm. dext.] 190
 Fissura lig. teretis 168
 Fissura longitudinalis cerebri 446
 Fissura mediana [ventralis] 414, 418
 Fissura nasolacrimalis 14
 Fissura nasomaxillaris 14
 Fissura orbitalis 14
 Fissura palatina 12
 Fissura petrooccipitalis 12
 Fissura petrosquamosa 22
 Fissura petrotympanica 22
 Fissura prima 426
 Fissura pseudosylvia 454
 Fissura sphenopetrosa 12
 Fissura sphenotympanica 12
 Fissura sylvia [lateralis cerebri] 454
 Fissura thyroidea [thyreoidea] 182
 Fissura transversa cerebri 446
 Fissura tympanomastoidea 22
 Fissura tympanooccipitalis 22
 Fissura tympanosquamosa 22
 Fissura uvulonodularis 426
 Fissurae cerebelli 426
 Flavus 570
 Flexor 570
 Flexura centralis 166
 Flexura coli dextra 166
 Flexura coli sinistra 166
 Flexura diaphragmatica [dorsalis] 166
 Flexura duodeni caudalis 162
 Flexura duodeni cranialis 162
 Flexura duodenojejunalis 162
 Flexura pelvina 166
 Flexura sigmoidea penis 206
 Flexura sternalis [diaphragmatica ventr.] 166
 Flocculus 428
 Flumina pilorum 546
 Folia cerebelli 426
 Folium vermis 428
 Folliculi 230
 Folliculi linguales 146
 Folliculi ovarici primarii 212
 Folliculi ovarici vesiculosi 212
 Folliculi tonsillares 148
 Folliculus 570
 Folliculus pili 546
 Fonticuli cranii 12
 Fonticulus frontoparietalis 12
 Fonticulus mastoideus 12
 Fonticulus sphenoidalis 12
 For. alare 42
 For. alare caudale 20
 For. alare parvum 20
 For. alare rostrale 20
 Forr. alveolaria 32
 For. apicis dentis 144
 For. axiale 60
 [For. epiploicum] 226
 For. ethmoidale 14, 28, 30
 Forr. ethmoidalia 14, 28
 For. infraorbitale 32
 For. interventriculare 436, 460
 For. intervertebrale 40
 Forr. intervertebralia 44
 For. ischiadicum majus 90
 For. ischiadicum minus 90
 For. jugulare 12
 For. lacerum 12
 For. lacrimale 30
 Forr. lacrimalia 30
 For. magnum 16
 For. mandibulae 38
 For. mastoideum 10
 For. maxillare 32
 For. mentale 38
 For. mentale mediale 38
 Forr. mentalia 38
 Forr. mentalia lateralia 38
 Forr. nervosa 528
 For. nutricium 565
 For. obturatum 62
 For. omentale 226
 For. orbitorotundum 14
 For. ovale 18
 For. ovale 238
 Forr. palatina minora 36
 For. palatinum caudale 12
 For. palatinum majus 12, 36
 Forr. papillaria 194
 For. processus palmaris 58
 For. processus plantaris 74
 For. retroarticulare 24
 For. rotundum 18
 Forr. sacralia dorsalia 44
 Forr. sacralia ventralia 44
 For. singulare 534
 For. sinus sagittalis dors. 16
 For. soleare abaxiale 60
 For. soleare axiale 60
 For. soleare laterale 58
 For. soleare mediale 58
 For. sphenopalatinum 14, 36
 For. spinosum 18
 For. stylo-mastoideum 22
 For. supracondylare 52
 For. supraorbitale 26
 For. supratrochleare 52
 For. thyroideum [thyreoideum] 182
 For. transversarium 40
 For. venae cavae 112
 Forr. venarum minimarum 236
 For. vertebrale 40
 For. vertebrale laterale 40
 Formatio reticularis 414, 422, 424, 432
 Fornix 440, 450
 Fornix conjunctivae inferior 524
 Fornix conjunctivae superior 524
 Fornix pharyngis 148
 Fornix sacci lacrimalis 524
 Fornix vaginae 216
 Fossa acetabuli 62
 Fossa atlantis 42
 Fossa axillaris 8
 Fossa canina 32
 Fossa carotica 18
 Fossa cerebellaris 22
 Fossa clitoridis 218
 Fossa condylaris dorsalis 16
 Fossa condylaris ventralis 16
 Fossa coronoidea 50
 Fossa cranii caudalis 12
 Fossa cranii media 12
 Fossa cranii rostralis 12
 Fossa ductus venosi 168
 Fossa extensoria 66
 Fossa frontalis 10
 Fossa glandis 206
 Fossa glandulae lacrimalis 28
 Fossa hayloidea 518
 Fossa hypophysialis 18
 Fossa infraspinata 48
 Fossa infratemporalis 10
 Fossa inguinalis lateralis 230
 Fossa intercondylaris 66
 Fossa interpeduncularis 432
 Fossa ischio-rectalis 224
 Fossa jugularis 4
 Fossa lacrimalis externa 30
 [Fossa lateralis cerebri] 448
 Fossa linguae 146
 Fossa mandibularis 24
 Fossa masseterica 38
 Fossa m. obliqui ventralis 30
 Fossa m. poplitei 66
 Fossa navicularis urethrae 210
 Fossa olecrani 50
 Fossa ovalis 238
 Fossa ovarii 212
 Fossa paralumbalis 6
 Fossa pararectalis 230
 Fossa piriformis 18
 Fossa pterygoidea 20, 38
 Fossa pterygopalatina 12
 Fossa radialis 52
 Fossa retromandibularis 4
 Fossa rhomboidea 430
 Fossa sacci lacrimalis 14, 30
 Fossa scaphoidea 20
 Fossa subarcuata 22
 Fossa subscapularis 48
 Fossa supracondylaris 52
 Fossa supraorbitalis 2
 Fossa supraspinata 48
 Fossa supratornillaris 150

- Fossa temporalis [10](#)
 Fossa tonsillaris 150
 Fossa trochanterica [66](#)
 [Fossa vertebrae] 40
 Fossa vesicae felleae [168](#)
 Fossae ethmoidales [12](#)
 Fossula petrosa [22](#)
 Fossulae tonsillares 150
 Fovea articularis [58](#)
 Fovea articularis caudalis 42
 Fovea articularis cranialis 42
 Fovea capitis [66](#)
 Fovea capitis radii 52
 Fovea caudalis 430
 Fovea centralis 516
 Fovea costalis caudalis [vertebrae cervicalis VII] 40
 Fovea costalis caud. 42
 Fovea costalis cran. 42
 Fovea costalis proc. transversi 42
 Fovea dentis 42
 Fovea pterygoidea [38](#)
 Fovea rostralis 430
 Fovea trochlearis 28
 Foveolae [174](#)
 Foveolae gastricae [160](#)
 Foveolae granulares [10](#)
 Frenulum clitoridis [218](#)
 Frenulum labii inferioris 140
 Frenulum labii superioris 140
 Frenulum linguae 146
 Frenulum papillae ilealis [164](#)
 Frenulum preputii [prae-] [164](#)
 Frenulum veli medullaris rostr. 430
 Frons 10, 562
 Frons, frontis 570
 Frontalis 570
 Fundus abomasi 158
 Fundus meatus acustici interni 530
 Fundus reticuli 158
 Fundus sulci reticuli 158
 Fundus uteri [214](#)
 Fundus ventriculi [154](#)
 Fundus ves. felleae [172](#)
 Funiculi medullae spinalis 414
 Funiculus dorsalis 414, 416
 Funiculus lateralis 414, 416
 Funiculus nuchae [80](#)
 Funiculus spermaticus 202
Funiculus umbilicalis 220
 Funiculus ventralis 414, 416
 Fuscus 570
 Fusiformis 570

 Gallus 570
 Ganglia aorticorenalia 502
 Ganglia autonómica 568
 Ganglia cardiaca 502
 Ganglia caudalia 508
 Ganglia celiaca [coeliaca] 502
 Ganglia intermedia 506
 Ganglia lumbalia 508
 Ganglia pelvina 508
 Ganglia phrenica 502
 Ganglia plexuum autonomicorum 568
 Ganglia renalia 502
 Ganglia sacralia 508
 Ganglia thoracica 508
 Ganglia trunci sympathici 506
 Ganglion 567
 Ganglion cervicale craniale 506
 Ganglion cervicale medium 506
 Ganglion cervicothoracium [strelatum] 506
 Ganglion ciliare [464](#), 508
 Ganglion distale 474, [476](#)
 Ganglion geniculi 472
 Ganglion impar 508
 Ganglion lateropharyngeum 474
 Ganglion mandibulare 472, 508
 Ganglion mesentericum caudale 502
 Ganglion mesentericum craniale 502
 Ganglion oticum 472, 508
 Ganglion proximale 474, [476](#)
 Ganglion pterygopalatinum 468, 508
 Ganglion spinale 480
 Ganglion spirale 474
 Ganglion spirale cochleae 530
 Ganglion splanchnicum 508
 Ganglion sublinguale 472, 508
 Ganglion terminale [464](#)
 Ganglion trigeminale [464](#)
 Ganglion vestibulare 474
 [Gaster] [154](#)
 Gelatinosus 570
 Genesis 570
 Geniculum canalis facialis [22](#)
 Geniculum n. facialis 472
 Genitalis 570
 Genu 563
 Genu capsulae internae 460
 Genu corporis callosi 456
 Genu costae [46](#)
 Genu n. facialis 420, 424
 Germen, germinis 570
 Germinativus 570
 Gingiva 140
 Ginglymus 565
 Glandula, Glandulae [174](#), 567
 (Gll. adrenales [suprarenales] accessoriae 232
 Gl. adrenalis [suprarenalis] 232
 Gll. ampullae 202
 Gll. anales [168](#)
 Gll. bronchiales [188](#)
 Gll. buccales 142
 Gll. buccales dorsales 142
 Gll. buccales intermediae 142
 Gll. buccales ventrales 142
 Gl. bulbourethralis 204
 Gll. cardiaca [160](#)
 Gll. carpeae 558
 Gl. carunculae lacrimalis 524
 Gll. caudae 558
 Gll. ceruminosae 558
 Gll. cervicales 216
 Gll. ciliares 522
 Gll. circumanales [168](#), 558
 Gll. circumanales 558
 Gll. conjunctivales 524
 Gl. cornualis 558
 Gll. cutis 558
 Gll. duodenales [162](#)
 Gll. endocrinae [230](#)
 Gll. esophageae [oesophageae] 152
 Gll. gastricae [propriae] [160](#)
 Gll. genitales accessoriae 204
 Gll. gustatoriae 142
 Gll. intestinales [162](#), [164](#)
 Gll. labiales 142
 (Gll. lacrimales accessoriae) 524
 Gl. lacrimalis 524
 Gll. laryngeae 186
 Gll. linguales 142
 Gl. lingualis apicalis 142
 Gl. mammaria 560
 Gl. mandibularis 142
 Gl. mentalis 558
 Gll. molares 142
 Gl. mucosa 567
 Gll. nasales 178
 Gl. nalis lateralis 178
 Gll. olfactoriae 178, 542
 Gll. oris 142
 Gll. palatinae 142
 Gl. paracaruncularis 142
 Gl. parathyroidea [-thyroidea] externa [III] 232
 Gl. parathyroidea [-thyroidea] interna [IV] 232
 (Gll. paraurethrales) 220
 Gl. parotis 142
 Gl. parotis accessoria 142
 Gll. pelvis renalis [196](#)
 Gll. pharyngeae 150
 Gl. pinealis 232, [442](#), [438](#)
 [Gl. pituitaria] 232, [438](#)
 Gll. plani nasalis 558
 Gll. plani nasolabialis 558
 Gll. plani rostralis 558
 Gll. preputiales [prae-] 208
 Gl. profunda 524
 Gll. pyloricae [160](#)
 Gll. salivariae majores 142
 Gll. salivariae minores 142
 Gll. sebaceae 522, 558
 Gl. seromucosa 567
 Gl. serosa 567
 Gll. sinus infraorbitalis 558
 Gll. sinus inguinalis 558
 Gll. sinus interdigitalis 558
 Gll. sinus paranasalis [168](#), 558
 Gl. sublingualis monostomatia 142
 Gl. sublingualis polystomatia 142
 Gll. sudoriferae 558
 Gl. superficialis 524
 [Gl. suprarenalis] 232
 Gll. tarsales 522
 Gl. thyroidea [thyroidea] [230](#)
 (Gll. thyroidea [thyreo-]accessoriae) [230](#)
 Gll. tori 558

- Gll. tracheales [188](#)
 Gll. tubariae [538](#)
 Gll. uretericae [196](#)
 Gll. urethrales [210](#), [220](#)
 Gll. uterinae [216](#)
 Gl. vesiciae felleae [174](#)
 Gl. vesicularis [204](#)
 Gll. vestibularis minores [218](#)
 Gl. vestibularis major [218](#)
 Gl. zygomatica [142](#)
 Glans clitoridis [218](#)
 Glans penis [206](#)
 Globus [570](#)
 [Globus pallidus] [460](#)
 [Glomerula] [194](#)
 [Glomerula arteriosa cochleae] [530](#)
 Glomeruli [194](#)
 Glomeruli arteriosi cochleae [530](#)
 Glomus caroticum [270](#)
 Glomus choroideum [chorioideum] [462](#)
 Glottis [186](#)
 [Glutaeus] [570](#)
 Gluteus [570](#)
 Gomphosis [565](#)
 Gracilis [570](#)
 Granula iridica [514](#)
 Granulatio [570](#)
 Granulationes arachnoideales [462](#)
 Griseus [570](#)
Gubernaculum testis [204](#)
 Gyri centrifugales [166](#)
 Gyri centripetales [166](#)
 Gyri cerebri [446](#)
 Gyri insulae [456](#)
 Gyrus cinguli [456](#)
 Gyrus compositus caudalis [456](#)
 Gyrus compositus rostralis [456](#)
 Gyrus dentatus [450](#), [452](#)
 Gyrus diagonalis [448](#)
 Gyrus ectomarginalis [ectosagittalis] caud. [456](#)
 Gyrus ectomarginalis [ectosagittalis] medius [456](#)
 Gyrus ectomarginalis [ectosagittalis] rostr. [456](#)
 Gyrus ectosylvius caudalis [456](#)
 Gyrus ectosylvius medius [456](#)
 Gyrus ectosylvius rostralis [456](#)
 Gyrus geniculi [450](#)
 Gyrus intersylvius [456](#)
 Gyrus marginalis [sagittalis] [456](#)
 Gyrus obliquus caudalis [456](#)
 Gyrus obliquus rostralis [456](#)
 Gyrus occipitalis [456](#)
 Gyrus olfactorius lateralis [448](#)
 Gyrus parahippocampalis [448](#)
 Gyrus paraterminalis [448](#)
 Gyrus posterocruciatas [postcentralis] [456](#)
 Gyrus precruciatas [precentralis, prae-] [456](#)
 Gyrus proreus [456](#)
 Gyrus supracallosus [450](#)
 Gyrus sylvius caudalis [456](#)
 Gyrus sylvius rostralis [456](#)
 Habenula [442](#)
 [Hallux] [564](#)
 Hamatus [570](#)
 Hamulus laminae spiralis [532](#)
 Hamulus pterygoideus [20](#)
 Haustra ceci [caeci] [164](#)
 Haustra coli [166](#)
 Helicotrema [532](#)
 Helix [540](#)
 [Hemisphaerium] [446](#)
 [Hemisphaerium] cerebelli [428](#)
 Hemisphaerium [446](#)
 Hemisphaerium cerebelli [428](#)
 Hepar [168](#)
 Hiatus aorticus [112](#)
 Hiatus esophageus [oesophageus] [112](#)
 Hiatus maxillaris [32](#)
 Hilus [232](#), [402](#)
 Hilus lienis [412](#)
 Hilus nuclei olivaris [420](#)
 Hilus ovarii [212](#)
 Hilus pulmonis [190](#)
 Hilus renalis [194](#)
 Hippocampus [450](#)
 Humerus [50](#)
 Humor aquosus [518](#)
 Humor vitreus [518](#)
 Hyalinus [570](#)
 Hybrida [570](#)
 Hymen [216](#)
 Hyoideus [570](#)
 Hypogastrium [570](#)
 Hypoglossus [570](#)
 Hypophysis [232](#), [438](#)
 Hypothalamus [438](#)
 Ileum [164](#)
 Iliacus [570](#)
 Ilium, ilia [570](#)
 Impar [570](#)
 Impressio adrenalis [170](#)
 Impressio aortica [188](#)
 Impressio cardiaca [188](#)
 Impressio cecalis [caecalis] [170](#)
 Impressio colica [170](#)
 Impressio duodenalis [170](#)
 Impressio esophagea [oesophagea] [168](#), [188](#)
 Impressio gastrica [168](#)
 Impressio medullaris [16](#)
 Impressio n. trigemini [22](#)
 Impressio omasica [170](#)
 Impressio pontina [16](#)
 Impressio renalis [170](#)
 Impressio reticularis [168](#)
 Impressio vermialis [16](#)
 Impressiones digitatae [10](#)
 Impressiones rugales [12](#)
 Imus [570](#)
 Incisura acetabuli [62](#)
 Incisura alaris [42](#)
 Incisura angularis [154](#)
 Incisura antitragohelicina [542](#)
 Incisura apicis cordis [234](#)
 Incisura cardiaca [154](#)
 Incisura cardiaca pulmonis dextri [190](#)
 Incisura cardiaca pulmonis sinistri [190](#)
 Incisura carotica [18](#)
 Incisura ethmoidalis [28](#)
 Incisura fibularis [70](#)
 Incisura glenoidalis [48](#)
 Incisura infratrochlearis [30](#)
 Incisura interarytenoidea [-arytaen-] [186](#)
 Incisura intertragica [542](#)
 Incisura intertrochlearis [56](#), [74](#)
 Incisura ischiadica major [62](#)
 Incisura ischiadica minor [64](#)
 Incisura jugularis [16](#), [22](#)
 Incisura lig. teretis [170](#)
 Incisura mandibulae [38](#)
 Incisura nasoincisiva [14](#)
 Incisura ovalis [18](#)
 Incisura pancreatis [172](#)
 Incisura poplitea [68](#)
 Incisura pretragica [prae-] [542](#)
 Incisura processus palmaris [58](#)
 Incisura processus plantaris [74](#)
 Incisura pterygoidea [20](#)
 Incisura radialis [54](#)
 Incisura scapulae [48](#)
 Incisura sphenoidalis [28](#)
 Incisura sphenopalatina [36](#)
 Incisura spinosa [18](#)
 Incisura supraorbitalis [26](#)
 Incisura tentorii [462](#)
 Incisura terminalis [542](#)
 Incisura thyroidea [thyreo-] caud. [182](#)
 Incisura thyroidea [thyreo-] rostr. [182](#)
 Incisura trochanterica [66](#)
 Incisura trochlearis [54](#)
 Incisura tympanica [24](#)
 Incisura ulnaris [52](#)
 Incisura vasorum facialis [38](#)
 Incisura vertebralis caud. [40](#)
 Incisura vertebralis cran. [40](#)
 Incisurae cartilaginis meatus acustici [540](#)
 Incisurae costales [46](#)
 Incisurae interlobares [170](#)
 Incisus [570](#)
 Inclinatio pelvis [64](#)
 Incus [536](#)
 [Indusium griseum] [450](#)
 Inferior [568](#)
 Infundibulum [232](#)
 Infundibulum dentis [144](#)
 Infundibulum tubae uterinae [212](#)
 Inguen [562](#)
 Insula [456](#)
 Insula ruminis [156](#)
 Insulae pancreaticae [232](#)
 Integumentum commune [568](#)
 Intermedius [568](#)
 Internus [568](#)
 Intersectio clavicularis [104](#)
 Intersectio tendinea [566](#)

- Intersectiones tendineae [112](#)
 Interstitium [570](#)
 Intestinum crassum [164](#)
 Intestinum tenue [162](#)
 Intima [570](#)
 Introitus [570](#)
 Intumescencia cervicalis [414](#)
 Intumescencia lumbalis [414](#)
 Iris [514](#)
 Ischiadicus [570](#)
 Ischium [570](#)
 [Isocortex] [458](#)
 Isthmus faucium [150](#)
 Isthmus fibrosus [230](#)
 Isthmus glandularis [230](#)
 Isthmus prostatae [204](#)
 Isthmus tubae auditivae [538](#)
 Isthmus tubae uterinae [214](#)
 Isthmus urethrae [210](#)
- Jejunum [162](#)
 Juba [546](#), [562](#)
 Juga alveolaria [32](#), [34](#), [38](#)
 Jugulum [570](#)
 Jugum sphenoidale [20](#)
- Labia oris [140](#)
 Labium dextrum [158](#)
 Labium externum [62](#)
 Labium inferius [140](#), [562](#)
 Labium internum [62](#)
 Labium laterale [66](#)
 Labium limbi tympanicum [528](#)
 Labium limbi vestibulare [528](#)
 Labium mediale [66](#)
 Labium pudendi [vulvae] [218](#)
 Labium sinistrum [158](#)
 Labium superius [140](#), [562](#)
 Labrum acetabulare [90](#)
 Labrum articulare [565](#)
 Labrum glenoidale [84](#)
 Labyrinthus ethmoidalis [28](#)
 Labyrinthus membranaceus [526](#)
 Labyrinthus osseus [532](#)
 Lac, lactis [570](#)
 Lacer [570](#)
 Lacertus fibrosus [116](#)
 Lacrima [570](#)
 Lacuna musculorum [130](#)
 Lacuna vasorum [130](#)
 Lacunae laterales [362](#)
 Lacunae urethrales [210](#), [220](#)
 Lacus lacrimalis [524](#)
 Lamella diagonalis [452](#)
 Lamellae dermales [coriales] [552](#)
 Lamellae epidermales [552](#)
 Lamellae intrasinuales [180](#)
 Lamellae suspensoriae [560](#)
 Lamina [174](#)
 [Lamina] [552](#)
 Lamina affixa [460](#)
 Lamina alaris [567](#)
 Lamina arcus vertebrae [40](#)
 Lamina basalis [30](#), [512](#)
 Lamina basalis [567](#)
 Lamina basilaris [528](#)
 Lamina cartilaginea cricoideae [182](#)
 Lamina [cartilaginea] lateralis [538](#)
 Lamina [cartilaginea] medialis [538](#)
 Lamina choroidocapillaris [chorioideo-] [512](#)
 Lamina cribrosa [28](#)
 Lamina [dextra et sinistra] [182](#)
 Lamina episcleralis [510](#)
 Lamina epithelialis [567](#)
 Lamina externa [10](#), [112](#), [206](#)
 Lamina femoralis [114](#)
 Lamina fibrocartilaginea intercoxalis [90](#)
 Lamina fusca sclerae [510](#)
 Lamina horizontalis [36](#)
 Lamina interna [10](#), [112](#), [206](#)
 Lamina limitans anterior [512](#)
 Lamina limitans posterior [512](#)
 Lamina medullaris lateralis [460](#)
 Lamina medullaris medialis [460](#)
 Lamina medullaris thalami ext. [444](#)
 Lamina medullaris thalami int. [444](#)
 Lamina membranacea [538](#)
 Lamina modioli [532](#)
 Lamina muscularis mucosae [152](#), [160–164](#), [188](#), [566](#)
 Lamina nuchae [80](#)
 Lamina orbitalis [30](#)
 Lamina parietalis [202](#), [234](#)
 Lamina perpendicularis [28](#), [36](#)
 Lamina pretrachealis [prae-] [106](#)
 Lamina prevertebralis [prae-] [106](#)
 Lamina profunda [104](#)
 Lamina propria mucosae [566](#)
 Lamina septi telencephali [pellucidi] [448](#)
 Lamina sphenothmoidalis [36](#)
 Lamina spiralis ossea [532](#)
 Lamina spiralis secundaria [532](#)
 Lamina superficialis [104](#), [106](#)
 Lamina suprachoroidea [-chorioidea] [512](#)
 Lamina tecti [432](#)
 Lamina tectoria [30](#)
 Lamina terminalis grisea [438](#)
 Lamina tragi [540](#)
 Lamina vasculosa [512](#)
 Lamina ventralis [vertebrae cervic. VI] [40](#)
 Lamina visceralis [202](#), [234](#)
 Laminae albae [428](#)
 Laminae laterales [560](#)
 Laminae mediales [560](#)
 Laminae omasi [162](#)
 Lanugo [570](#)
 Laryngeus [570](#)
 Larynx [182](#), [562](#)
 Lateralis [568](#)
 Latissimus [570](#)
 Latus [562](#)
 Lemniscus lateralis [426](#), [434](#)
 Lemniscus medialis [422](#), [426](#), [434](#)
 Lemniscus trigeminalis [426](#), [434](#)
 Lens [518](#)
 Levator [570](#)
 Liber [570](#)
 Lien [412](#)
 (Lien accessorius) [412](#)
 Ligamentum, Ligamenta [566](#)
 Lig. accessorio-carpoulnare [pisotriquetrum] [86](#)
 Lig. accessorio-metacarpeum [pisometacarpeum] [86](#)
 Lig. accessorio-quartale [pisohamatum] [86](#)
 Lig. accessorio-ulnare [pisoulnare] [86](#)
 Lig. accessorium [118](#), [128](#)
 Lig. accessorium ossis femoris [90](#)
 Ligg. alaria [80](#)
 [Lig. anulare digiti] [122](#), [130](#)
 [Lig. anulare palmaris] [122](#)
 [Lig. anulare plantare] [130](#)
 Lig. anulare radii [84](#)
 Lig. anulare stapedis [538](#)
 Ligg. anularia [trachealia] [188](#)
 Lig. apicale penis [208](#)
 Lig. apicis dentis [80](#)
 Lig. arcuatum ischiadicum [90](#)
 Lig. arteriosum [242](#)
 Lig. ary-corniculatum [184](#)
 Lig. arytenoideum [arytaenoideum] transversum [184](#)
 Lig. atlanto-axiale dorsale [80](#)
 Lig. atlanto-axiale ventrale [80](#)
 Lig. calcaneo-centrale [calcaneo-naviculare] dorsale [96](#)
 Lig. calcaneo-centrale [calcaneo-naviculare] plantare [96](#)
 Lig. calcaneo-quartale [calcaneo-cuboideum] dorsale [96](#)
 Lig. calcaneo-quartale [calcaneo-cuboideum] interosseo [96](#)
 Lig. calcaneo-quartale [calcaneo-cuboideum] plantare [96](#)
 Lig. capitis costae intraarticulare [82](#)
 Lig. capitis costae radiatum [82](#)
 Lig. capitis fibulae caudale [92](#)
 Lig. capitis fibulae craniale [92](#)
 Lig. capitis ossis femoris [90](#)
 Ligg. capsularia [566](#)
 Lig. carpi radiatum [84](#)
 Ligg. carpometacarpea dorsalia [86](#)
 Ligg. carpometacarpea palmaria [86](#)
 Lig. caudae epididymidis [202](#)
 Lig. caudale [78](#)
 Lig. centrodistale [cuneonaviculare] interosseo [96](#)
 Ligg. centrodistalia [cuneonavicularia] dorsalia [96](#)
 Ligg. centrodistalia [cuneonavicularia] plantaria [96](#)
 Lig. centroquartale [cuboideo-naviculare] dorsale [96](#)
 Lig. centroquartale [cuboideo-naviculare] interosseo [96](#)

- Lig. centroquartale [cuboideo-naviculare] plantare 96
- Ligg. chondrocompedalia 88
- Ligg. chondrocoronalia 88
- Ligg. chondrosesamoidea 88
- Ligg. chondroungularia collat. 88
- Ligg. chondroungularia cruciata 88
- Lig. collaterale carpi lat. 84
- Lig. collaterale carpi med. 84
- Lig. collaterale cubiti lat. 84
- Lig. collaterale cubiti med. 84
- Lig. collaterale laterale 92
- Lig. collaterale mediale 92
- Lig. collaterale tarsi lat. 94
- Lig. collaterale tarsi lat. breve 94
- Lig. collaterale tarsi lat. longum 94
- Lig. collaterale tarsi med. 94
- Lig. collaterale tarsi med. breve 94
- Lig. collaterale tarsi med. longum 94
- Ligg. collateralia 86, 88
- Lig. coracohumerale 84
- Lig. coronarium hepatis 228
- Lig. costotransversarium 82
- Ligg. costoxiphoidea 82
- Lig. cricoarytenoideum [-arytaeno-] 184
- Lig. cricothyroideum [-thyroideum] 182
- Lig. cricotracheale 182
- Ligg. cruciata genus 92
- Lig. cruciatum caudale 92
- Lig. cruciatum craniale 92
- Lig. denticulatum 462
- Ligg. dorsalia 88
- Lig. dorsoscapulare 110
- Ligg. extracapsularia 566
- Lig. falciforme hepatis 228
- Lig. femoropatellare laterale 92
- Lig. femoropatellare mediale 92
- Ligg. flava 80
- Lig. fundiforme penis 114, 208
- Lig. gastrolienale 226
- Lig. gastrophrenicum 226
- Ligg. glenohumeralia 84
- Lig. hepatoduodenale 228
- Lig. hepatogastricum 228
- Lig. hepatorenale 228
- Lig. hyoepiglotticum 184
- Lig. iliofemorale 90
- Lig. iliolumbale 80
- Ligg. incudis 538
- [Lig. inguinale] 112
- Lig. intercapitale 82
- Ligg. intercarpea dorsalia 84
- Ligg. intercarpea interossea 84
- Ligg. intercarpea palmaria 84
- Lig. intercornuale 214
- Lig. intercornuale dors. 214
- Lig. intercornuale ventr. 214
- Lig. interdigitale proximale 86
- Ligg. interdigitalia distalia 88
- Ligg. interdistalia [intercuneiformia] dorsalia 96
- Ligg. interdistalia [intercuneiformia] interossea 96
- Ligg. interdistalia [intercuneiformia] plantaria 96
- Lig. interosseum antebrachii 84
- Lig. intersesamoideum interdig. 86
- Ligg. interspinalia 80
- Ligg. intertransversaria 80
- Ligg. intracapsularia 566
- Lig. ischiofemorale 90
- Lig. laterale 78, 80
- Lig. latum uteri 230
- [Lig. lienorenale] 226
- Lig. longitudinale dentis 80
- Lig. longitudinale dorsale 80
- Lig. longitudinale ventrale 80
- Lig. lumbocostale 82
- Ligg. mallei 538
- Lig. meniscofemorale 92
- Ligg. metacarpea dorsalia 86
- Ligg. metacarpea interossea 86
- Ligg. metacarpea palmaria 86
- Lig. metacarpeum transversum prof. 86
- Lig. metacarpeum transversum supf. 122
- Lig. metacarpointersesamoideum 86
- Ligg. metatarsea dorsalia 96
- Ligg. metatarsea interossea 96
- Ligg. metatarsea plantaria 96
- Lig. metatarscum transversum prof. 96
- Lig. metatarscum transversum supf. 130
- Lig. metatarsointersesamoideum 96
- Lig. nuchae 80
- Lig. olecrani 84
- Lig. orbitale 14
- Ligg. ossiculorum auditus 538
- Lig. ovarii proprium 212
- Ligg. palmaria 86
- Lig. palpebrale laterale 522
- Lig. palpebrale mediale 522
- Lig. patellae 92
- Lig. patellae intermedium 92
- Lig. patellae laterale 92
- Lig. patellae mediale 92
- Lig. pectinatum anguli iridocornealis 514
- Ligg. phalangosesamoidea interdig. 86
- Lig. phrenicolenale 226
- Lig. phrenicopericardiacum 234
- Lig. plantare longum 96
- Ligg. plantaria 96
- Lig. popoliteum obliquum 92
- Lig. pubicum craniale 90
- Lig. pubofemorale 90
- Lig. pubovesicale 222
- Lig. pulmonale 192
- Lig. quartodistale [cuneocuboideum] dorsale 96
- Lig. quartodistale [cuneocuboideum] interossea 96
- Lig. quartodistale [cuneocuboideum] plantare 96
- Lig. radiocarpeum dorsale 84
- Lig. radiocarpeum palmare 84
- Lig. radioulnare 84
- Ligg. sacroiliaca dorsalia 90
- Ligg. sacroiliaca interossea 90
- Ligg. sacroiliaca ventralia 90
- Lig. sacrotuberale 90
- Lig. sacrotuberale latum 90
- Lig. scroti 202
- Ligg. sesamoidea brevia 86
- Ligg. sesamoidea collateralia 86
- Ligg. sesamoidea cruciata 86
- Ligg. sesamoidea obliqua 86
- Lig. sesamoideum dist. abaxiale 88
- Lig. sesamoideum dist. axiale 88
- Lig. sesamoideum dist. impar 88
- Lig. sesamoideum rectum 86
- Lig. spirale cochleae 528
- Lig. sterni 82
- Lig. sternocostale intraarticulare 82
- Ligg. sternocostalia radiata 82
- Lig. sternopericardiaca 234
- Lig. sternopericardiacum 234
- Lig. supraspinale 80
- Lig. suspensorium clitoridis 114
- Lig. suspensorium ovarii 230
- Lig. suspensorium penis 114, 208
- [Lig. suspensorium uberis] 560
- Lig. talocalcaneum interossea 96
- Lig. talocalcaneum laterale 94
- Lig. talocalcaneum plantare 94
- Lig. talocentrale [talonaviculare] interossea 96
- Lig. talocentrodistometatarsium [talonaviculocuneometatarsium] 96
- Lig. talofibulare plantare 94
- Ligg. tarsi dorsalia 96
- Ligg. tarsi interossea 96
- Ligg. tarsi plantaria 96
- Ligg. tarsometatarsea dorsalia 96
- Ligg. tarsometatarsea plantaria 96
- Ligg. tarsometatarsea [cuneometatarsea] interossea 96
- Lig. teres hepatis 168, 374
- Lig. teres uteri 216
- Lig. teres vesicae 198, 312–318
- Lig. testis proprium 202
- Lig. thyroepiglotticum [thyreo-] 184
- Lig. tibiofibulare caudale 94
- Lig. tibiofibulare craniale 94
- Lig. tibiotalarare plantare 94
- Lig. transversum acetabuli 90
- Lig. transversum atlantis 80
- Lig. transversum genus 92
- Lig. transversum perinei 224
- Lig. triangulare dextrum 228
- Lig. triangulare sinistrum 228
- Lig. ulnocarpeum palmare 84
- Lig. vesicae laterale 198, 230
- Lig. vesicae medianum 198, 230

- Lig. vestibulare 186
 Lig. vocale 186
 Limbi palpebrales anteriores 522
 Limbi palpebrales posteriores 522
 Limbus [550](#)
 Limbus corneae 512
 Limbus fossae ovalis [238](#)
 Limbus laminae spiralis osseae 528
 Limen insulae 448, 456
 Limen nasi [176](#)
 Limen pharyngoesophageum [-oesophageum] [150](#)
 Limitans 570
 Linea alba 114
 Linea anocutanea [168](#)
 Linea anorectalis [168](#)
 Linea arcuata [62](#), 112
 Linea epiphysialis 565
 Linea glutea [glutaea] access. [62](#)
 Linea glutea [glutaea] caud. [62](#)
 Linea glutea [glutaea] ventr. [62](#)
 Linea intercondylaris [66](#)
 Linea intertrochanterica [66](#)
 Linea mediana dorsalis 2
 Linea mediana ventralis 2
 Linea m. poplitei [68](#)
 Linea m. tricipitis [50](#)
 Linea mylohyoidea [38](#)
 Linea nuchae 16
 Linea obliqua [182](#)
 Linea pilorum convergens 546
 Linea pilorum divergens 546
 Linea semilunaris [58](#)
 Linea temporalis 15, 16, [26](#)
 Linea terminalis 64
 Lineae gluteae [glutaeae] [62](#)
 Lineae transversae 44
 Lingua [146](#), 562
 [Lingula] 190
 Lingula cerebelli [428](#)
 Liquor cerebrospinalis 462
 Lobi glandulae mammariae 560
 Lobi renales 194
 Lobuli [230](#)
 Lobuli corticales 194
 Lobuli epididymidis [200](#)
 Lobuli glandulae mammariae 560
 Lobuli hepatis 170
 Lobuli pulmonis 190
 Lobuli testis [200](#)
 Lobuli thymi 412
 Lobulus 402, 567
 Lobulus ansiformis [428](#)
 Lobulus centralis [428](#)
 Lobulus paramedianus [428](#)
 Lobulus quadrangularis [428](#)
 Lobulus simplex [428](#)
 Lobus 567
 Lobus accessorius [pulm. dext.] 190
 Lobus caudalis 190, [426](#)
 Lobus caudatus 170
 Lobus cervicalis [dexter et sinister] 412
 Lobus cranialis [pulm. dext.] 190
 Lobus [dexter et sinister] [204](#), [230](#)
 Lobus flocculonodularis [426](#)
 Lobus hepatis dexter 170
 Lobus hepatis dexter lat. 170
 Lobus hepatis dexter med. 170
 Lobus hepatis sinister 170
 Lobus hepatis sinister lat. 170
 Lobus hepatis sinister med. 170
 Lobus intermedius 412
 Lobus medius [pulm. dext.] 190
 Lobus nervosus [232](#)
 Lobus pancreatis dexter [172](#)
 Lobus pancreatis sinister [172](#)
 Lobus piriformis 448
 Lobus pyramidalis [230](#)
 Lobus quadratus 170
 Lobus rostralis [426](#)
 Lobus thoracicus [dext. et sin.] 412
 Locus ceruleus [caeruleus] 430
 Longissimus 570
 Longitudinalis 568
 Longus 571
 Lucidus 571
 Lumbricus 571
 Lumbus 562
 Lunatus 571
 Lunula 571
 Lunulae valvularum semilunarium 240
 Luteus 571
 Lympha 567, 571
 Lymphaticus 571
 Lymphocentrum 402
 Lymphocentrum axillare 404
 Lymphocentrum bronchiale 406
 Lymphocentrum celiacum [coeliacum] [408](#)
 Lymphocentrum cervicale profundum 404
 Lymphocentrum cervicale supf. 404
 Lymphocentrum iliofemorale 410
 Lymphocentrum iliosacrale 410
 [Lymphocentrum inguinale profundum] 410
 [Lymphocentrum inguinale supf.] 410
 Lymphocentrum inguinofemorale 410
 Lymphocentrum ischiadicum 410
 Lymphocentrum lumbale 406
 Lymphocentrum mandibulare 404
 Lymphocentrum mediastinale 406
 Lymphocentrum mesentericum caudale [408](#)
 Lymphocentrum mesentericum craniale [408](#)
 Lymphocentrum parotideum 404
 Lymphocentrum popliteum 410
 Lymphocentrum retropharyngeum 404
 Lymphocentrum thoracicum dorsale 406
 Lymphocentrum thoracicum ventrale 406
 Lymphonodus, Lymphonodi 402, 567
 Lnn. abomasiales dorsales [408](#)
 Lnn. abomasiales ventrales [408](#)
 Lnn. anorectales 410
 Lnn. axillares 404
 Lnn. axillares primae costae 404
 Lnn. axillaris proprii 404
 Ln. axillaris accessorius 404
 Lnn. cecales [caecales] [408](#)
 Lnn. celiaci [coeliaci] [408](#)
 Lnn. cervicales profundi caudales 404
 Lnn. cervicales profundi craniales 404
 Lnn. cervicales profundi medii 404
 Lnn. cervicales supf. 404
 Lnn. cervicales supf. accessorii 404
 Lnn. cervicales supf. dorsales 404
 Lnn. cervicales supf. medii 404
 Lnn. cervicales supf. ventrales 404
 Lnn. colici 408
 Ln. costocervicalis 404
 Ln. coxalis 410
 Ln. coxalis accessorius 410
 Lnn. cubitales 404
 Ln. epigastricus 410
 Ln. femoralis 410
 Lnn. fossae paralumbalis 410
 Lnn. gastrici [408](#)
 Ln. gluteus [glutaeus] 410
 Ln. hemalis [haemalis] 402, 567
 Lnn. hepatici accessorii [408](#)
 Lnn. hepatici [portales] [408](#)
 Ln. hyoideus caudalis 404
 Ln. hyoideus rostralis 404
 Lnn. hypogastrici 410
 Lnn. ileocolici [408](#)
 Lnn. iliaci laterales 410
 Lnn. iliaci mediales 410
 Lnn. iliofemorales 410
 Ln. infraspinaus 404
 [Lnn. inguinales profundi] 410
 Lnn. inguinales supf. 410
 Lnn. intercostales 406
 Lnn. ischiadici 410
 Lnn. jejunaes [408](#)
 Lnn. lienales 408
 Lnn. lumbales aortici 406

- Lnn. lumbales proprii 406
 Lnn. mammarii 410
 Lnn. mandibulares 404
 Lnn. mandibulares accessorij 404
 Lnn. mediastinales caudales 406
 Lnn. mediastinales craniales 406
 Lnn. mediastinales medij 406
 Lnn. mesenterici caudales 408
 Lnn. mesenterici craniales 408
 Ln. nuchalis 406
 Ln. obturatorius 410
 Lnn. omasiales 406
 Lnn. omentales 406
 Ln. ovaricus 406
 Lnn. pancreaticoduodenales 406
 Lnn. parotidei profundi 404
 Lnn. parotidei supf. 404
 Lnn. pectorales 404
 Lnn. phrenici 406
 Ln. phrenicoabdominalis 406
 Lnn. poplitei 410
 Lnn. poplitei profundi 410
 Lnn. poplitei supf. 410
 Ln. pterygoideus 404
 Lnn. pulmonales 406
 Lnn. renales 406
 Lnn. reticulares 408
 Lnn. reticuloabomasiales 408
 Lnn. retropharyngei laterales 404
 Lnn. retropharyngei mediales 404
 Lnn. ruminales craniales 408
 Lnn. ruminales dextri 408
 Lnn. ruminales sinistri 408
 Lnn. ruminoabomasiales 408
 Lnn. sacrales 410
 Lnn. scrotales 410
 Lnn. sternales 406
 Lnn. sternales caudales 406
 Lnn. sternales craniales 406
 Lnn. subiliaci 410
 Ln. subrhomboideus 404
 Lnn. subscapulares 404
 Ln. testicularis 406
 Lnn. thoracici aortici 406
 Lnn. tracheobronchales craniales 406
 Lnn. tracheobronchales [bifurcationis] dextri 406
 Lnn. tracheobronchales [bifurcationis] medij 406
 Lnn. tracheobronchales [bifurcationis] sinistri 406
 Ln. tuberalis 410
 Ln. uterinus 410
 Lnn. vesicales 408
 Lyssa [148](#)

 Macula 516
 Macula sacculi 528
 Macula utriculi 528
 Maculae 528
 Maculae cribrosae 532
 Magnus 571
 Major 571
 [Mala] 562
 Malleolus lateralis 70, 563
 Malleolus medialis 70, 563
 Malleus 536
 Mamilla 571
 Mamma 560
 Mamma abdominalis 562
 (Mamma accessoria) 560
 Mamma inguinalis 562
 Mamma masculina 560
 Mamma thoracica 562
 Mandibula [38](#)
 Manica flexoria [118](#), 128
 Manubrium mallei 536
 Manubrium sterni [46](#)
 Manus 563
 Margines laterales [184](#)
 Margo acetabuli [62](#)
 Margo acutus 190
 Margo alveolaris [34](#), [38](#)
 Margo antitragicus 540
 Margo basalis 190
 Margo caudalis 48, [54](#), 70, [172](#), 412
 Margo centralis 554
 Margo cilicaris 514
 Margo colli dorsalis [4](#)
 Margo coronalis 60, 552
 Margo cranialis 48, 70, [172](#), 412
 Margo dexter 170, [172](#)
 Margo distalis 60
 Margo dorsalis 48, 60, 170, 552
 Margo dorsalis [dorsomedialis] 446
 Margo dorsalis [obtusus] 190
 Margo epididymalis [200](#)
 Margo ethmoidalis 28
 Margo frontalis [26](#)
 Margo gingivalis 140
 Margo incisalis [144](#)
 Margo infraorbitalis [14](#), 36
 Margo interalveolaris [34](#), [38](#)
 Margo interosseus [54](#), 70
 [Margo interosseus] 70
 Margo interparietalis [26](#)
 Margo lateralis 52, [54](#), 70, [194](#), 232
 Margo liber 36, [200](#), [212](#), [214](#)
 Margo limitans peritonei [peritoaci] [212](#)
 Margo linguae 146
 Margo mastoideus [16](#)
 Margo medialis 52, [54](#), 70, [194](#), [262](#)
 Margo mesometricus [214](#)
 Margo mesovaricus [212](#)
 Margo nasalis 28
 Margo occipitalis [26](#)
 Margo orbitalis [14](#)
 Margo palmaris lateralis 552
 Margo palmaris medialis 552
 Margo parietalis [16](#), 28, 554
 Margo plantaris lateralis 552
 Margo plantaris medialis 552
 Margo plicatus [160](#)
 Margo proximalis 60
 Margo pupillaris 514
 Margo sagittalis [26](#)
 Margo sinister 170, [172](#)
 Margo solearis 60, 552
 Margo sphenoidalis 24
 Margo squamosus [26](#)
 Margo supraorbitalis [14](#), [26](#)
 Margo tragicus 540
 Margo tricipitalis [2](#)
 Margo uteri [dexter et sinister] [214](#)
 Margo ventralis [38](#), 170
 Margo ventralis partis petrosae [22](#)
 Margo ventricularis dexter [234](#)
 Margo ventricularis sinister [234](#)
 Massa lateralis 42
 Masticatus 571
 Mastoideus 571
 Mater, matris 571
 Matrix, matricis 571
 Maxilla [32](#)
 Meatus acusticus externus 24, 540
 Meatus acusticus ext. cartilagineus 540
 Meatus acusticus internus [22](#), 534
 Meatus ethmoidales 28, 178
 Meatus nasi communis [14](#), 178
 Meatus nasi dorsalis [14](#), 178
 Meatus nasi medius [14](#), 178
 Meatus nasi ventralis [14](#), 178
 Meatus nasopharyngeus [14](#)
 Meatus temporalis [10](#)
 Medialis 568
 Medianus 568
 Mediastinum [192](#)
 Mediastinum caudale [192](#)
 Mediastinum craniale [192](#)
 Mediastinum dorsale [192](#)
 Mediastinum medium [192](#)
 Mediastinum testis [200](#)
 Mediastinum ventrale [192](#)
 Medius 568
 Medulla 232, 402, 412
 Medulla oblongata 416
 Medulla ossium flava 565
 Medulla ossium rubra 565
 Medulla ovarii [212](#)
 Medulla renis [194](#)
 Medulla spinalis 414
 Membra 563
 Membrana atlantoaxialis dors. [80](#)
 Membrana atlantooccipitalis dors. [80](#)
 Membrana atlantooccipitalis ventr. [80](#)
 Membrana basalis ductus semicircularis 526
 Membrana fibroelastica laryngis 186
 Membrana intercostalis externa 82
 Membrana intercostalis interna 82
 Membrana interossea anterbrachii 84
 Membrana interossea cruris 92
 Membrana obturatoria 90
 Membrana perinei 224
 Membrana propria ductus semicircularis 526

- Membrana pupillaris* 514
 Membrana reticularis 530
 [Membrana spiralis] 528
 Membrana stapedis 538
 Membrana statoconiorum 528
 Membrana sterni 82
 Membrana synovialis dorsalis 78
 Membrana synovialis ventralis 78
 Membrana tectoria 80, 530
 Membrana thyrohyoidea [thyreo-]
 182
 Membrana tympani 536
 Membrana tympani secundaria
 534
 [Membrana vestibularis] 530
 Membrana vitrea 518
Membranae fetales 220
 Membrum pelvinum 563
 Membrum thoracicum 563
 Meninges 462
 Meninx, meningis 571
 Meniscus articularis 565
 Meniscus lateralis 92
 Meniscus medialis 92
 Mentum 562
 Meridiani 510
 Mesencephalon 432
 Mesenterium 228
Mesenterium dorsale primitivum
 226
Mesenterium ventrale primitivum
 228
 Mesepididymis 202, 230
 Mesocolon 228
 Mesocolon ascendens 228
 Mesocolon descendens 228
 Mesocolon sigmoideum 228
 Mesocolon transversum 228
 Mesoductus deferens 202, 230
 Mesoduodenum 228
 Mesofuniculus 202
Mesogastrium dorsale 226
Mesogastrium ventrale 228
 Mesoileum 228
 Mesojejenum 228
 Mesometrium 230
Mesonephros 220
Mesorchium 202, 230
 Mesorchium distale 202
 Mesorchium proximale 202
 Mesorectum 228
 Mesosalpinx 233
 Mesotendineum 566
 Mesothelium 570
 Mesovarium 230
 Mesovarium distale 230
 Mesovarium proximale 230
 Metacarpus 563
 Metaphysis 565
 Metapodium 571
 Metatarsus 564
 Metathalamus 442
 Metencephalon 424
 Minor 571
 Mitra 571
 Modiolus 532
 Mola 571
 Molecularis 571
 Mollis 571
 Mons, montis 571
 Motor 571
 Mucosus 571
 Mucus 571
 Multifidus 571
 Musculus 566
 Mm. abdominis 112
 M. abductor 566
 M. abductor cruris caud. 126
 M. abductor digiti I [hallucis] 128
 M. abductor digiti I [pollicis]
 brevis 120
 M. abductor digiti I [pollicis]
 longus 120
 M. abductor digiti II 120, 128
 M. abductor digiti V 120, 128
 M. adductor 126, 566
 M. adductor brevis 126
 M. adductor digiti I [hallucis] 128
 M. adductor digiti I [pollicis] 120
 M. adductor digiti II 120, 128
 M. adductor digiti V 120, 128
 M. adductor longus 126
 M. adductor magnus 126
 M. anconeus [anconaeus] 116
 M. antitragicus 543
 Mm. arrectores pilorum 546
 M. articularis 566
 M. articularis coxae 124
 M. articularis genus 126
 M. articularis humeri 116
 M. arytenoideus [arytaenoideus]
 transversus 186
 Mm. auriculares 543
 Mm. auriculares caudales 100
 Mm. auriculares dorsales 100
 Mm. auriculares rostrales 100
 Mm. auriculares ventrales 100
 M. biceps brachii 116
 M. biceps femoris 126
 M. bipennatus 566
 M. biventer cervicis 108
 M. brachialis 116
 M. brachiocephalicus 104
 M. brachioradialis 118
 M. bronchoesophageus [-oesopha-
 geus] 152
 M. buccinator 102
 Mm. bulbi 520
 M. bulboglandularis 224
 M. bulbospongiosus 224
 M. caninus 102
 Mm. capitis 98
 Mm. caudae [coccygis] 114
 M. caudoantitragicus 542
 M. ceratohyoideus 106
 M. cervicoauricularis medius 100
 M. cervicoauricularis prof. 100
 M. cervicoauricularis supf. 100
 M. cervicoscutularis 100
 M. ciliaris 512
 M. cleidobrachialis 104
 [M. chleidobrachialis] 116
 M. cleidocephalicus 104
 M. coccygeus 114, 222
 Mm. colli 104
 M. complexus 108
 [M. constrictor pharyngis medius]
 152
 M. constrictor vestibuli 224
 M. constrictor vulvae 224
 Mm. constrictores pharyngis
 caud. 152
 Mm. constrictores pharyngis
 rostr. 152
 M. coracobrachialis 116
 M. cremaster 112, 202
 M. cricoarytenoideus [-arytaeno-
 ideus] dors. 186
 M. cricoarytenoideus [-arytaeno-
 ideus] lat. 186
 M. cricopharyngeus 152
 M. cricothyroideus [-thyroideus]
 186
 Mm. cutanei 98
 M. cutaneus 566
 M. cutaneus colli 98
 M. cutaneus faciei 98
 M. cutaneus omobrachialis 98
 M. cutaneus trunci 98
 M. deltoideus 116
 M. depressor 566
 M. depressor anguli oris 102
 M. depressor labii inferioris 102
 M. depressor labii superioris 102
 M. digastricus 102
 M. dilatator 566
 M. dilatator naris apicalis 100
 M. dilator pupillae 514
 Mm. dorsi 106
 M. erector spinae 108
 M. esophageus [oesophageus]
 longitudinalis dors. 152
 M. esophageus [oesophageus]
 longitudinalis lat. 152
 M. esophageus [oesophageus]
 longitudinalis ventr. 152
 M. extensor 566
 [M. extensor carpi obliquus] 120
 M. extensor carpi radialis 118
 M. extensor carpi radialis brevis
 118
 M. extensor carpi radialis longus
 118
 M. extensor carpi ulnaris 118
 M. extensor digiti I [hallucis] lon-
 gus 126
 M. extensor digiti I [pollicis] 120
 M. extensor digiti II 120
 M. extensor digitorum [digitalis]
 brevis 128
 M. extensor digitorum [digitalis]
 communis 118
 M. extensor digitorum [digitalis]
 lat. 118, 126
 M. extensor digitorum [digitalis]
 longus 126
 M. flexor 566
 [M. flexor accessorius] 128

- M. flexor carpi radialis [118](#)
 M. flexor carpi ulnaris [118](#)
 M. flexor digiti I [hallucis] brevis [128](#)
 M. flexor digiti I [pollicis] brevis [120](#)
 M. flexor digiti II [120](#)
 M. flexor digiti V [120](#)
 M. flexor digitorum brevis [120](#)
 M. flexor digitorum [digitalis] brevis [128](#)
 M. flexor digitorum [digitalis] lat. [128](#)
 M. flexor digitorum [digitalis] med. [128](#)
 M. flexor digitorum [digitalis] prof. [118](#)
 M. flexor digitorum [digitalis] supf. [118](#), [128](#)
 Mm. flexores digitorum [digitalis] prof. [128](#)
 M. frontalis [100](#)
 M. frontoscutularis [100](#)
 M. fusiformis [566](#)
 M. gastrocnemius [128](#)
 Mm. gemelli [124](#)
 M. genioglossus [148](#)
 M. geniohyoideus [106](#)
 M. gluteobiceps [glutaeo-] [124](#)
 M. gluteofemoralis [glutaeo-] [124](#)
 M. gluteus [glutaeus] accessorius [124](#)
 M. gluteus [glutaeus] medius [124](#)
 M. gluteus [glutaeus] prof. [124](#)
 M. gluteus [glutaeus] supf. [124](#)
 M. gracilis [126](#)
 M. helicis [542](#)
 M. helicis minor [542](#)
 M. hyoepiglotticus [186](#)
 M. hyoglossus [148](#)
 Mm. hyoidei [106](#)
 M. hyoideus transversus [106](#)
 M. hyopharyngeus [152](#)
 M. iliacus [122](#)
 M. iliocaudalis[-coccygeus] [222](#)
 M. iliocostalis [108](#)
 M. iliocostalis cervicis [108](#)
 M. iliocostalis lumborum [108](#)
 M. iliocostalis thoracis [108](#)
 M. iliopsoas [122](#)
 M. incisivus inferior [102](#)
 M. incisivus superior [102](#)
 M. infraspinalis [116](#)
 Mm. intercostales externi [110](#)
 Mm. intercostales interni [110](#)
 Mm. interflexorii [118](#), [128](#)
 Mm. interossei [120](#), [128](#)
 M. interscutularis [100](#)
 Mm. interspinales [108](#)
 Mm. intertransversarii [110](#)
 Mm. intertransversarii dors. caudae [coccygis] [114](#)
 Mm. intertransversarii dors. cervicis [110](#)
 Mm. intertransversarii lumborum [110](#)
 Mm. intertransversarii thoracis [110](#)
 Mm. intertransversarii ventr. caudae [coccygis] [114](#)
 Mm. intertransversarii ventr. cervicis [110](#)
 M. ischioavernosus [224](#)
 M. ischiourethralis [224](#)
 Mm. laryngis [186](#)
 M. lateralis nasi [100](#)
 M. latissimus dorsi [106](#)
 M. levator [566](#)
 M. levator anguli oculi med. [100](#)
 M. levator ani [222](#)
 M. levator labii superioris [102](#)
 M. levator nasolabialis [102](#)
 M. levator palpebrae superioris [520](#)
 M. levator veli palatini [152](#)
 Mm. levatores costarum [110](#)
 Mm. linguae [148](#)
 M. lingualis proprius [148](#)
 M. longissimus [108](#)
 M. longissimus atlantis [108](#)
 M. longissimus capitis [108](#)
 M. longissimus cervicis [108](#)
 M. longissimus lumborum [108](#)
 M. longissimus thoracis [108](#)
 M. longitudinalis perinei cutaneus [224](#)
 M. longus capitis [98](#)
 M. longus colli [104](#)
 Mm. lumbricales [120](#), [128](#)
 M. malaris [100](#)
 M. masseter [102](#)
 Mm. membri pelvini [122](#)
 Mm. membri thoracici [116](#)
 M. mentalis [102](#)
 Mm. multifidi [108](#)
 M. multipennatus [566](#)
 M. mylohyoideus [106](#)
 M. obliquus auriculae [542](#)
 M. obliquus capitis caud. [98](#)
 M. obliquus capitis cran. [98](#)
 M. obliquus dorsalis [520](#)
 M. obliquus externus abdominis [112](#)
 M. obliquus internus abdominis [112](#)
 M. obliquus ventralis [520](#)
 M. obturatorius externus [126](#)
 M. obturatorius internus [124](#)
 M. occipitalis [100](#)
 M. occipitohyoideus [106](#)
 M. omohyoideus [106](#)
 M. omotransversarius [106](#)
 M. orbicularis [566](#)
 M. orbicularis oculi [100](#)
 M. orbicularis oris [102](#)
 M. orbitalis [520](#)
 Mm. ossiculorum auditus [538](#)
 Mm. palati et faucium [152](#)
 M. palatinus [152](#)
 M. palatopharyngeus [152](#)
 Mm. papillares [236](#)
 Mm. papillares parvi [240](#)
 M. papillaris magnus [240](#)
 M. papillaris subarteriosus [240](#)
 M. papillaris subatrialis [240](#)
 M. papillaris subauricularis [240](#)
 M. parietoauricularis [100](#)
 M. parietoscutularis [100](#)
 M. parotidoauricularis [parotideo-] [100](#)
 Mm. pectinati [238](#), [240](#)
 M. pectineus [126](#)
 Mm. pectorales superficiales [110](#) [M. pectoralis ascendens] [110](#)
 M. pectoralis descendens [110](#)
 M. pectoralis profundus [110](#)
 M. pectoralis transversus [110](#)
 Mm. perinei [222](#)
 M. peroneus [peronaeus, fibularis] brevis [126](#)
 M. peroneus [peronaeus, fibularis] longus [126](#)
 M. peroneus [peronaeus, fibularis] tertius [126](#)
 M. piriformis [124](#)
 M. planus [566](#)
 M. pleuroesophageus[-oesophageus] [152](#)
 M. popliteus [128](#)
 M. preputialis [prae-]caudalis [98](#), [208](#)
 M. preputialis [prae-]cranialis [98](#), [208](#)
 M. pronator [566](#)
 M. pronator quadratus [118](#)
 M. pronator teres [118](#)
 M. protractor [566](#)
 M. psoas major [122](#)
 M. psoas minor [122](#)
 M. pterygoideus lateralis [102](#)
 M. pterygoideus medialis [102](#)
 M. pterygopharyngeus [152](#)
 M. pubocaudalis[-coccygeus] [222](#)
 M. pubovesicalis [198](#)
 M. quadratus [566](#)
 M. quadratus femoris [124](#)
 M. quadratus lumborum [112](#)
 M. quadratus plantae [128](#)
 M. quadriceps femoris [124](#)
 M. rectococcygeus [168](#)
 M. rectourethralis [168](#), [198](#)
 M. rectus abdominis [112](#)
 M. rectus capitis dors. major [98](#)
 M. rectus capitis dors. minor [98](#)
 M. rectus capitis lat. [98](#)
 M. rectus capitis ventralis [98](#)
 M. rectus dorsalis [520](#)
 M. rectus femoris [124](#)
 M. rectus lateralis [520](#)
 M. rectus medialis [520](#)
 M. rectus thoracis [110](#)
 M. rectus ventralis [520](#)
 M. retractor [566](#)
 M. retractor anguli oculi lat. [100](#)
 M. retractor bulbi [520](#)
 M. retractor clitoridis [224](#)
 M. retractor costae [110](#)
 M. retractor penis [224](#)

- M. rhomboideus capitis* [106](#)
M. rhomboideus cervicis [106](#)
M. rhomboideus thoracis [106](#)
M. rotator [566](#)
Mm. rotatores [108](#)
M. sacrocaudalis[-coccygeus] dors. lat. [114](#)
M. sacrocaudalis[-coccygeus] dors. med. [114](#)
M. sacrocaudalis[-coccygeus] vent. lat. [114](#)
M. sacrocaudalis[-coccygeus] vent. med. [114](#)
M. sartorius [124](#)
M. scalenus dorsalis [104](#)
M. scalenus medius [104](#)
M. scalenus ventralis [104](#)
Mm. scutuloauriculares profundi [100](#)
Mm. scutuloauriculares supf. [100](#)
M. semimembranosus [126](#)
M. semispinalis [108](#)
M. semispinalis capitis [108](#)
M. semispinalis cervicis [108](#)
M. semispinalis thoracis [108](#)
M. semitendinosus [126](#)
M. serratus dorsalis caud. [106](#)
M. serratus dorsalis cran. [106](#)
M. serratus ventr. cervicis [106](#)
M. serratus ventr. thoracis [110](#)
M. skeleti [566](#)
M. soleus [128](#)
M. sphincter [566](#)
M. sphincter ampullae hepato-pancreaticae [172](#)
[M. sphincter ampullae] [172](#)
M. sphincter ani externus [168](#), [222](#)
M. sphincter ani internus [168](#)
M. sphincter cardiacae [160](#)
M. sphincter ceci [caeci] [164](#)
M. sphincter colli profundus [98](#)
M. sphincter colli supf. [98](#)
M. sphincter ductus choledochi [172](#)
M. sphincter ductus pancreatici [172](#)
M. sphincter ductus pancreatici accessorii [172](#)
M. sphincter ilei [164](#)
M. sphincter labiorum cutaneus [224](#)
M. sphincter papillae [560](#)
M. sphincter pupillae [514](#)
M. sphincter pylori [160](#)
M. sphincter reticulo-omasicus [160](#)
M. spinalis [108](#)
M. spinalis cervicis [108](#)
M. spinalis thoracis [108](#)
M. splenius capitis [98](#)
M. splenius cervicis [104](#)
M. stapedius [538](#)
M. sternocephalicus [104](#)
M. sternohyoideus [106](#)
M. sternohyoideus[-thyreoideus] [106](#)
M. styloauricularis [100](#)
M. styloglossus [148](#)
M. stylohyoideus [106](#)
M. stylopharyngeus caud. [152](#)
M. stylopharyngeus rostr. [152](#)
M. subclavius [110](#)
Mm. subcostales [110](#)
M. subscapularis [116](#)
M. supinator [120](#), [566](#)
M. supramammarius caudalis [98](#)
M. supramammarius cranialis [98](#)
M. supraspinatus [116](#)
M. tarsalis inferior [522](#)
M. tarsalis superior [522](#)
M. temporalis [102](#)
M. tensor [566](#)
M. tensor fasciae antebrachii [116](#)
M. tensor fasciae latae [124](#)
M. tensor tympani [538](#)
M. tensor veli palatini [152](#)
M. tensor ventriculi laryngis [186](#)
M. teres major [116](#)
M. teres minor [116](#)
Mm. thoracis [110](#)
M. thyroarytenoideus [thyreoarytaenoideus] [186](#)
M. thyroarytenoideus [thyreoarytaenoideus] accessorius [186](#)
M. thyrohyoideus [thyreo-] [106](#)
M. thyropharyngeus [thyreo-] [152](#)
M. tibialis caudalis [128](#)
M. tibialis cranialis [126](#)
M. trachealis [188](#)
M. tragicus [542](#)
M. transversospinalis [108](#)
M. transversus abdominis [112](#)
M. transversus auricularae [542](#)
M. transversus perinei supf. [224](#)
M. transversus thoracis [110](#)
M. trapezius [106](#)
M. triangularis [566](#)
M. triceps brachii [116](#)
M. triceps surae [128](#)
[M. ulnaris lateralis] [118](#)
M. unipennatus [566](#)
M. urethralis [224](#)
M. vastus intermedius [124](#)
M. vastus lateralis [124](#)
M. vastus medialis [124](#)
M. ventricularis [186](#)
M. vocalis [186](#)
M. zygomaticoauricularis [100](#)
M. zygomaticoscutularis [100](#)
M. zygomaticus [102](#)
Myelencephalon [416](#)
Myocardium [236](#)
Myologia [566](#)
[Myometrium] [216](#)

Nares [176](#)
Naris [562](#)
Nasus [562](#)
Nasus externus [174](#)
Nates [562](#)
Navicula [571](#)
Neocortex [458](#)

Neopallium [446](#), [454](#)
Nephros [571](#)
Nervus [567](#)
N. abducens [472](#)
N. accessorius [478](#)
N. alveolaris inferior [470](#)
N. ampullaris anterior [474](#)
N. ampullaris lateralis [474](#)
N. ampullaris posterior [474](#)
N. articularis [567](#)
Nn. auriculares rostrales [470](#)
N. auricularis caudalis [472](#)
N. auricularis magnus [480](#)
N. auriculopalpebralis [472](#)
N. auriculotemporalis [468](#)
N. axillaris [482](#)
N. buccalis [468](#)
N. canalis pterygoidei [468](#)
Nn. cardiaci cervicales [506](#)
Nn. cardiaci thoracici [508](#)
N. cardiacus cervicalis [506](#)
Nn. carotici externi [506](#)
Nn. caroticotympanici [474](#)
N. caroticus internus [506](#)
Nn. caudales [coccygei] [500](#)
Nn. cervicales [480](#)
Nn. ciliares breves [464](#)
Nn. ciliares longi [466](#)
Nn. clunium caudales [494](#)
Nn. clunium craniales [492](#)
Nn. clunium medii [492](#)
N. cochlearis [474](#)
Nn. corporis cavernosi clitoridis [504](#)
Nn. corporis cavernosi penis [504](#)
N. costoabdominalis [490](#)
Nn. craniales [464](#)
N. cutaneus [567](#)
N. cutaneus antebrachii caud. [488](#)
N. cutaneus antebrachii cran. [482](#)
N. cutaneus antebrachii lat. [484](#)
N. cutaneus antebrachii med. [482](#)
N. cutaneus brachii lat. caud. [484](#)
N. cutaneus brachii lat. cran. [482](#)
N. cutaneus femoris caudalis [494](#)
N. cutaneus femoris lateralis [492](#)
N. cutaneus surae caud. [498](#)
N. cutaneus surae lat. [494](#)
N. depressor [476](#)
Nn. digit. dorsales proprii [484](#)
N. digit. dors. I abaxialis [484](#)
N. digit. dors. II abaxialis [496](#)
N. digit. dors. III lat. [496](#)
N. digit. dors. III med. [496](#)
N. digit. dors. V abax. [488](#), [496](#)
Nn. digit. dorsales communes [484](#)
N. digit. dors. communis II [496](#)
N. digit. dors. communis III [496](#)
N. digit. dors. communis IV [488](#), [490](#), [496](#)
N. digit. dors. proprius II axialis [496](#)
N. digit. dors. proprius III abax. [496](#)
N. digit. dors. proprius III axialis [496](#)

- N. digit. dors. proprius IV abax. 488, 490, [496](#)
 N. digit. dors. proprius IV axialis [496](#)
 N. digit. dors. proprius V 490
 N. digit. dors. proprius V axialis 488, [496](#)
 N. digit. palm. I abax. 484
 N. digit. palm. II abax. [486](#)
 N. digit. palm. III axialis [486](#)
 N. digit. palm. IV axialis [486](#)
 N. digit. palm. V abax. 488
 N. digit. palm. communis I 484
 N. digit. palm. communis II 484, [486](#)
 [N. digit. palm. communis II] [486](#)
 N. digit. palm. communis III 484, [486](#)
 [N. digit. palm. communis III] [486](#), 490
 N. digit. palm. communis IV 488, 490
 N. digit. palm. proprius I axialis 484
 N. digit. palm. proprius II [486](#)
 N. digit. palm. proprius II abax. 484
 N. digit. palm. proprius II axialis 484, [486](#)
 N. digit. palm. proprius III abax. 484, [486](#)
 N. digit. palm. proprius III axialis 484, [486](#)
 N. digit. palm. proprius IV abax. 488, 490
 N. digit. palm. proprius IV axialis 484, [486](#)
 N. digit. palm. proprius V 490
 N. digit. palm. proprius V axialis 488
 N. digit. palm. [proprius] lat. [486](#), 490
 N. digit. palm. [proprius] med. [486](#)
 N. digit. plant. II abax. [498](#)
 N. digit. plant. V abax. [498](#)
 N. digit. plant. communis II [498](#)
 [N. digit. plant. communis II] [498](#)
 N. digit. plant. communis III [498](#), [500](#)
 [N. digit. plant. communis III] [500](#)
 N. digit. plant. communis IV [498](#), [500](#)
 N. digit. plant. proprius II 498
 N. digit. plant. proprius II axialis [498](#)
 N. digit. plant. proprius III abax. [498](#)
 N. digit. plant. proprius III axialis [498](#)
 N. digit. plant. proprius IV abax. [498](#), [500](#)
 N. digit. plant. proprius IV axialis [498](#)
 N. digit. plant. proprius V 500
 N. digit. plant. proprius V axialis [498](#)
 N. digit. plant. [proprius] lat. [500](#)
 N. digit. plant. [proprius] med. [498](#)
 N. dorsalis clitoridis [500](#)
 N. dorsalis penis [500](#)
 N. dorsalis scapulae [482](#)
 N. ethmoidalis 466
 N. facialis [472](#)
 N. femoralis 494
 N. frontalis [464](#)
 N. genitofemoralis [492](#)
 N. glossopharyngeus 474
 N. gluteus [glutaeus] caudalis 494
 N. gluteus [glutaeus] cranialis 494
 N. hypogastricus [504](#)
 N. hypoglossus [478](#)
 N. iliohypogastricus [492](#)
 N. iliohypogastricus caudalis 492
 N. iliohypogastricus cranialis [492](#)
 N. ilioinguinalis 492
 N. infraorbitalis 468
 N. infratrochlearis 466
 [Nn. intercostales] 490
 N. intercostobrachialis 490
 [N. intermediofacialis] [472](#)
 N. intermedius 472
 N. interosseus antebrachii 484
 N. ischiadicus 494
 N. jugularis 506
 Nn. labiales [500](#)
 N. lacrimalis [464](#)
 N. laryngeus caudalis [476](#)
 N. laryngeus cranialis [476](#)
 N. laryngeus recurrens [476](#)
 N. lingualis 470
 Nn. lumbales 492
 Nn. lumbales, sacrales, et caudales [coccygei] [492](#)
 N. mandibularis 468
 N. massetericus 468
 N. masticatorius 468
 N. maxillaris 466
 N. meatus acustici externi 468
 N. medianus 484
 Nn. mentales 470
 N. mentalis 470
 Nn. metacarpei palmares 488, 490
 Nn. metatarsi plantares [498](#), [500](#)
 N. metatarsus dors. II [496](#)
 N. metatarsus dors. III [496](#)
 N. metatarsus dors. IV [496](#)
 N. musculocutaneus [482](#)
 N. mylohyoideus 470
 N. nasalis caudalis [466](#)
 N. nasociliaris 466
 N. nasopalatinus [466](#)
 N. obturatorius 494
 N. occipitalis major [480](#)
 N. oculomotorius [464](#)
 Nn. olfactorii [464](#)
 N. ophthalmicus [464](#)
 N. opticus [464](#), [510](#)
 N. palatinus accessorius [466](#)
 N. palatinus major [466](#)
 N. palatinus minor [466](#)
 N. palmaris lateralis [486](#), 490
 N. palmaris medialis [486](#)
 Nn. pectorales caudales [482](#)
 Nn. pectorales craniales [482](#)
 Nn. pelvini 508
 N. perinealis profundus [500](#)
 N. perinealis superficialis [500](#)
 N. peroneus [peronaeus, fibularis] communis 494
 N. peroneus [peronaeus, fibularis] prof. [496](#)
 N. peroneus [peronaeus, fibularis] supf. 494
 N. petrosus major 468, [472](#)
 N. petrosus minor [472](#), 474
 N. petrosus profundus 468
 N. phrenicus 480
 N. plantaris lateralis [498](#), [500](#)
 N. plantaris medialis [498](#)
 N. pterygoideus lateralis 468
 N. pterygoideus medialis 468
 N. pterygopalatinus 466
 N. pudendus [500](#)
 N. radialis 484
 Nn. rectales caudales [500](#)
 N. sacralis 474
 Nn. sacrales [492](#)
 N. saphenus 494
 Nn. scrotales dorsales [500](#)
 N. sinuum frontium [464](#)
 Nn. spinales [480](#)
 Nn. splanchnici lumbales [500](#)
 Nn. splanchnici sacrales [500](#)
 (N. splanchnicus imus) [500](#)
 N. splanchnicus major [500](#)
 N. splanchnicus minor [500](#)
 N. stapedius [472](#)
 N. subclavius 482
 N. sublingualis 470
 N. suboccipitalis 480
 Nn. subscapulares [482](#)
 Nn. supraclaviculares [480](#)
 Nn. supraclaviculares dorsales [480](#)
 Nn. supraclaviculares intermedii [480](#)
 Nn. supraclaviculares ventrales [480](#)
 N. supraorbitalis 464
 N. suprascapularis 482
 N. supratrochlearis 464
 Nn. temporales profundi 468
 N. tensoris tympani 468
 N. tensoris veli palatini 468
 N. terminalis 464
 Nn. thoracici 490
 N. thoracicus lateralis [482](#)
 N. thoracicus longus [482](#)
 N. thoracodorsalis [482](#)
 N. tibialis [498](#)
 N. transversus colli [480](#)
 N. trigeminus [464](#)
 N. trochlearis [464](#)
 N. tympanicus 474
 N. ulnaris 488
 N. utricularis 474
 N. utriculoampullaris 474
 Nn. vaginales 504

- N. vagus [476](#)
 N. vascularis [567](#)
 N. vertebralis [506](#)
 N. vestibularis [474](#)
 N. vestibulocochlearis [474](#)
 N. vomeronasalis [464](#)
 N. zygomaticus [466](#)
 Neurohypophysis [232](#)
 Neuron [571](#)
 Niger [571](#)
 [Noduli lymphatici] [150](#)
 [Noduli lymphatici aggregati] [162](#), [164](#)
 [Noduli lymphatici bronchiales] [188](#)
 [Noduli lymphatici conjunctivales] [524](#)
 [Noduli lymphatici gastrici] [160](#)
 [Noduli lymphatici laryngei] [186](#)
 [Noduli lymphatici lienales] [412](#)
 [Noduli lymphatici preputiales] [\[prac-\]](#) [208](#)
 [Noduli lymphatici solitarii] [162](#), [164](#)
 [Noduli lymphatici tubarii] [538](#)
 [Noduli lymphatici vaginales] [216](#)
 (Noduli thymici accessorii) [412](#)
 Noduli valvularum semilunarium [240](#)
 Nodus [428](#)
 [Nodus lymphaticus] [402](#), [567](#)
 Nodus atrioventricularis [236](#)
 [Nodus lymphaticus], [Nodi lymphatici] [402](#), [567](#)
 Nodus sinuatrialis [236](#)
 Nomen, nominis [571](#)
 Norma [571](#)
 Nucha [562](#)
 Nuclei habenulares [446](#)
 Nuclei interpositi cerebelli [430](#)
 Nuclei intralaminares thalami [444](#)
 Nuclei laterales thalami [444](#)
 Nuclei lemnisci lateralis [434](#)
 Nuclei n. vestibulocochlearis [424](#)
 Nuclei nervorum cranialium [567](#)
 Nuclei originis [567](#)
 Nuclei parasympathici n. oculomotorii [434](#)
 Nuclei paraventriculares thalami [444](#)
 Nuclei pontis [426](#)
 Nuclei rostrales thalami [444](#)
 Nuclei septi [452](#)
 Nuclei tegmenti [434](#)
 Nuclei terminationis [567](#)
 Nuclei tuberis laterales [440](#)
 Nuclei ventrales corporis trapezoides [420](#), [424](#)
 Nuclei vestibulares [420](#)
 Nucleolus [570](#)
 Nucleus accumbens [460](#)
 Nucl. ambiguus [418](#)
 Nucl. arcuatus [422](#)
 Nucl. basalis [452](#)
 Nucl. caudatus [460](#)
 Nucl. centralis [452](#)
 Nucl. centralis lateralis [444](#)
 Nucl. centralis medialis [444](#)
 Nucl. centralis thalami [444](#)
 Nucl. ceruleus [caeruleus] [424](#)
 Nucl. cervicalis lateralis [414](#)
 Nucl. cochlearis dorsalis [420](#), [424](#)
 Nucl. cochlearis ventralis [420](#), [424](#)
 Nucl. colliculi caudalis [436](#)
 Nucl. corticalis [452](#)
 Nucl. cuneatus lateralis [420](#)
 Nucl. cuneatus medialis [420](#)
 [Nucl. dentatus] [430](#)
 Nucl. dorsalis corporis trapezoides [420](#), [424](#)
 Nucl. dorsomedialis thalami [444](#)
 [Nucl. emboliformis] [430](#)
 Nucl. endopeduncularis [442](#)
 Nucl. fastigii [430](#)
 Nucl. funiculi lateralis [420](#)
 Nucl. geniculatus lat. [446](#)
 Nucl. geniculatus med. [446](#)
 [Nucl. globosus] [430](#)
 Nucl. gracilis [420](#)
 Nucl. habenularis lat. [444](#)
 Nucl. habenularis med. [444](#)
 Nucl. hypothalamicus dorsomed. [440](#)
 Nucl. hypothalamicus lat. [440](#)
 Nucl. hypothalamicus perifornicallis [440](#)
 Nucl. hypothalamicus rostralis [438](#)
 Nucl. hypothalamicus ventromed. [440](#)
 Nucl. infundibularis [440](#)
 Nucl. intercatalus [418](#)
 [Nucl. intercalatus] [440](#)
 Nucl. interpeduncularis [434](#)
 Nucl. interpositus lat. cerebelli [430](#)
 Nucl. interpositus med. cerebelli [430](#)
 Nucl. interstitialis [434](#)
 Nucl. lateralis [452](#)
 Nucl. lateralis caudalis [444](#)
 Nucl. lateralis cerebelli [430](#)
 Nucl. lateralis dorsalis [444](#)
 Nucl. lemnisci lateralis [426](#)
 Nucl. lentiformis [460](#)
 Nucl. lentis [518](#)
 Nucl. mamillaris cinereus [440](#)
 Nucl. mamillaris lateralis [440](#)
 Nucl. mamillaris medialis [440](#)
 Nucl. medialis [452](#)
 Nucl. motorius n. abducentis [420](#), [424](#)
 Nucl. motorius n. accessorii [414](#), [418](#)
 Nucl. motorius n. facialis [420](#), [424](#)
 Nucl. motorius n. hypoglossi [418](#)
 Nucl. motorius n. oculomotorii [434](#)
 Nucl. motorius n. trigemini [420](#), [424](#)
 Nucl. motorius n. trochlearis [434](#)
 [Nucl. motorius nn. vagi et glosso-pharyngei] [418](#)
 Nucl. olivaris [420](#)
 Nucl. olivaris accessorius dors. [420](#)
 Nucl. olivaris accessorius med. [420](#)
 Nucl. paracentralis [444](#)
 Nucl. parafascicularis [444](#)
 Nucl. parasympathicus n. facialis [420](#)
 Nucl. parasympathicus n. glosso-pharyngei [418](#)
 Nucl. parasympathicus n. intermedii [420](#)
 Nucl. parasympathicus n. vagi [418](#)
 Nucl. paraventricularis [438](#)
 Nucl. paraventricularis parvocellularis [438](#)
 Nucl. paraventricularis caud. [440](#)
 Nucl. paraventricularis rostralis [438](#)
 Nucl. precommissuralis [prae-] [434](#)
 Nucl. premamillaris [prae-] [440](#)
 Nucl. preopticus [prae-] lateralis [438](#)
 Nucl. preopticus [prae-] medialis [438](#)
 Nucl. preopticus [prae-] medianus [438](#)
 Nucl. preopticus [prae-] periventricularis [438](#)
 Nucl. prepositus [prae-] n. hypoglossi [418](#)
 Nucl. prestitialis [prae-] [434](#)
 Nucl. pretecalis [prae-] [436](#)
 Nucl. pulposus [80](#)
 Nucl. pulvinaris [444](#)
 Nucl. reticulatus thalami [444](#)
 Nucl. rostralis dorsalis [444](#)
 Nucl. rostralis medialis [444](#)
 Nucl. rostralis ventralis [444](#)
 Nucl. ruber [434](#)
 Nucl. sensibilis pontinus n. trigemini [424](#)
 Nucl. subthalamicus [442](#)
 Nucl. suprachiasmaticus [438](#)
 Nucl. supraopticus [438](#)
 Nucl. thoracicus [414](#)
 Nucl. tractus mesencephalici n. trigemini [424](#), [432](#)
 Nucl. tr. olfactorii lat. [452](#)
 Nucl. tr. solitarii [418](#)
 Nucl. tr. spinalis n. trigemini [414](#), [420](#), [424](#)
 Nucl. tuberomamillaris [440](#)
 Nucl. ventralis caudalis [444](#)
 Nucl. ventralis lateralis [444](#)
 Nucl. ventralis rostralis [444](#)
 Nucl. vestibularis caudalis [descendens] [420](#), [424](#)
 Nucl. vestibularis lateralis [420](#), [424](#)
 Nucl. vestibularis medialis [420](#), [424](#)

- Nucl. vestibularis rostralis 420, 424
 Nutricius 571

 Obex 430
 Obliquus 571
 Obturator 571
 Obtusus 571
 Occipitalis 571
 Occiput 10, 562
 Occultus 571
 Oculus 510, 562
 [Oesophagus] 152, 562
 Olecranon 54
 Olfactus 571
 Oliva 418
 Omasum 158
 Omentum majus 226
 Omentum minus 228
 Omphalos 571
 Opercula insulae 456
 Ophthalmicus 571
 Ora serrata 516
 Orbicularis 571
 Orbiculus ciliaris 512
 Orbita 14
 Organa genitalia feminina 212
 Organa genitalia masculina 200
 Organa oculi accessoria 520
 Organa sensuum 568
 Organa urinaria 194
 Organum gustus 542
 Organum olfactus 542
 Organum orobasale 140
 Organum spirale 528
 Organum subcommissurale 436
 Organum subfornicale 436
 Organum vasculosum hypothalami 438
 Organum vasculosum laminae terminalis griseae 438
 Organum vasculosum subfornicale 450
 Organum vestibulocochleare 526
 Organum visus 510
 Organum vomeronasale 176, 542
 Orificium 571
 Origo 566
 Os, oris 562, 571
 Os, ossis 571
 Os arcus hemalis [haemalis] 44
 Os basisphenoidale 18
 Os breve 565
 [Os capitatum] 56
 Os carpale I 56
 Os carpale II 56
 Os carpale II et III 56
 Os carpale III 56
 Os carpale IV 56
 Os carpi accessorium 56
 (Os carpi centrale) 56
 Os carpi intermedioradiale 56
 Os carpi intermedium 56
 Os carpi radiale 56
 Os carpi ulnare 56
 Os centroquartale 72
 [Os compedale] 58
 Os conchae nasalis ventr. 34
 [Os coronale] 58
 Os costale 46
 Os coxae 62
 [Os cuboideum] 72
 [Os cuneiforme intermedio-laterale] 72
 [Os cuneiforme intermedium] 72
 [Os cuneiforme laterale] 72
 [Os cuneiforme mediale] 72
 [Os cuneiforme mediointermedium] 72
 Os ethmoidale 28
 Os femoris 66
 Os frontale 26
 [Os hamatum] 56
 [Os hyoideum] 38
 Os ilium 62
 Os incisivum 34
 Os interparietale 18
 Os irregulare 565
 Os ischii 64
 Os lacrimale 30
 Os lenticulare 536
 Os longum 565
 [Os lunatum] 56
 Os metacarpale III et IV 56
 Os metatarsale III et IV 74
 Os nasale 30
 [Os naviculare] 72
 [Os naviculocuboideum] 72
 Os occipitale 16
 Os palatinum 36
 Os parietale 26
 Os penis 208
 [Os pisiforme] 56
 Os planum 565
 Os pneumaticum 565
 Os presphenoidale [prae-] 20
 Os pterygoideum 20
 Os pubis 64
 Os rostrale 34
 Os sacrum 44
 [Os scaphoideum] 56
 [Os scapholunatum] 56
 Os sesamoideum distale 60
 Os sesamoideum metatarsale 74
 Os sesamoideum m. abductoris digiti I [pollicis] longi 56
 Os sesamoideum m. poplitei 68
 Os tarsale I 72
 Os tarsale I et II 72
 Os tarsale II 72
 Os tarsale II et III 72
 Os tarsale III 72
 Os tarsale IV 72
 Os tarsi centrale 72
 Os temporale 22
 [Os trapezium] 56
 [Os trapezoideocapitatum] 56
 [Os trapezoideum] 56
 [Os triquetrum] 56
 [Os unguiculare] 58
 [Os unguulare] 58
 Os zygomaticum 36
 Ossa carpi 56
 Ossa cordis 236
 Ossa cranii 16
 Ossa digitorum manus 58
 Ossa digitorum pedis 74
 Ossa faciei 30
 Ossa membri pelvini 62
 Ossa membri thoracici 48
 Ossa metacarpalia I–V 56
 Ossa metatarsalia I–V 74
 Ossa sesamoidea dorsalia 60
 Ossa sesamoidea m. gastrocnemii 68
 (Ossa sesamoidea palmaria) 56
 Ossa sesamoidea proximalia 60
 (Ossa suturarum) 10
 Ossa tarsi 72
 Ossicula auditus 536
 Ossiculum 571
 Osteologia 565
 Ostia venarum pulmonalium 240
 Ostium abdominale tubae uterinae 212
 Ostium aortae 240
 Ostium atrioventriculare dextrum 238
 Ostium atrioventriculare sinistrum 240
 Ostium atrioventriculare [dext. et sin.] 236
 Ostium cardiacum 154
 Ostium cecocolicum [caeco-] 164
 Ostium ejaculatorium 210
 Ostium ileale 164
 Ostium intrapharyngeum 150
 Ostium intraruminale 156
 Ostium nasolacrimale 176
 Ostium omasoabomasicum 158
 Ostium papillare 560
 Ostium pharyngeum tubae auditivae 148, 538
 Ostium preputiale [prae-] 206
 Ostium pyloricum 154
 Ostium reticulo-omasicum 158
 Ostium ruminoreticulare 156
 Ostium trunci pulmonalis 240
 Ostium tympanicum tubae auditivae 538
 Ostium ureteris 198
 Ostium urethrae externum 210, 220
 Ostium urethrae internum 198
 Ostium uteri externum 216
 Ostium uteri internum 216
 Ostium uterinum tubae 214
 Ostium vaginae 216
 Ostium venae cavae caud. 238
 Ostium venae cavae cran. 238
 Oticus 571
 Ovarium 212
 Ovum 571

 [Palaeocortex] 452
 [Palaeopallium] 446
 Palatum 140
 Palatum durum 140

- Palatum molle [140](#), [150](#)
 Palatum osseum [12](#)
 Palmar [544](#), [562](#)
 Paleocortex [452](#)
 Palcopallium [446](#)
 Pallidum [460](#)
 Pallidus [571](#)
 Pallium [446](#)
 Palma manus [563](#)
 Palmaris [568](#)
 Palpebra inferior [522](#), [562](#)
 Palpebra superior [522](#), [562](#)
 [Palpebra III] [524](#)
 Palpebrae [520](#)
 Pampiniformis [571](#)
 Pancreas [172](#)
 (Pancreas accessorium) [172](#)
 Panniculus adiposus [544](#)
 Papilla dentis [144](#)
 Papilla duodeni major [162](#)
 Papilla duodeni minor [162](#)
 Papilla gingivalis [interdentalis] [140](#)
 Papilla ilealis [164](#)
 Papilla incisiva [140](#)
 Papilla mammae [560](#), [562](#)
 Papilla parotidea [140](#)
 Papilla pili [546](#)
 Papilla zygomatica [140](#)
 Papillae [544](#)
 Papillae buccales [140](#)
 Papillae conicae [146](#)
 Papillae dermales [coriales] [548](#), [550](#), [554](#), [556](#)
 Papillae filiformes [146](#)
 Papillae foliatae [146](#)
 Papillae fungiformes [146](#)
 Papillae labiales [140](#)
 Papillae lentiformes [146](#)
 Papillae linguales [146](#)
 Papillae marginales [146](#)
 Papillae omasi [162](#)
 Papillae renales [194](#)
 Papillae reticuli [160](#)
 Papillae ruminis [160](#)
 Papillae tonsillares [146](#)
 Papillae unguiculiformes [162](#)
 Papillae vallatae [146](#)
 (Paradidymis) [200](#)
 Paradigitus [563](#), [564](#)
 Paraflocculus [428](#)
 Paraflocculus dorsalis [428](#)
 Paraflocculus ventralis [428](#)
 Paraganglion [571](#)
 Parametrium [216](#)
 Parasympathicus [571](#)
 (Paraunguicula) [564](#)
 Paraungula [563](#), [564](#)
 Parenchyma [204](#), [230](#), [567](#)
 Parenchyma testis [200](#)
 Paries [552](#)
 Paries caroticus [534](#)
 Paries corneus [552](#)
 Paries dorsalis [14](#), [216](#)
 Paries externus ductus cochlearis [530](#)
 Paries jugularis [534](#)
 Paries labyrinthicus [534](#)
 Paries lateralis [14](#)
 Paries mastoideus [534](#)
 Paries medialis [14](#)
 Paries membranaceus [188](#), [534](#)
 Paries profundus [226](#)
 Paries superficialis [226](#)
 Paries tegmentalalis [534](#)
 Paries tympanicus ductus cochlearis [528](#)
 Paries ventralis [14](#), [216](#)
 Paries ventriculi [160](#)
 Paries vestibularis ductus cochlearis [530](#)
 Paroöphoron [212](#)
 Parotis, parotidis [571](#)
 Pars abaxialis [552](#)
 Pars abdominalis [152](#), [196](#)
 Pars accessoria [438](#)
 Pars acromialis [116](#)
 Pars analis [224](#)
 Pars anularis vag. fibrosae [122](#), [130](#)
 Pars ascendens [162](#)
 Pars axialis [552](#)
 Pars basalis rhinencephali [448](#)
 Pars basilaris [16](#)
 Pars buccalis [102](#)
 Pars calcaneofibularis [94](#)
 Pars calcaneometatarsae [94](#)
 Pars cardiaca [154](#)
 Pars cartilaginea [565](#)
 Pars cartilaginea tubae auditivae [538](#)
 Pars caudalis [50](#), [66](#), [124](#), [178](#), [190](#), [414](#), [420](#), [428](#), [440](#), [448](#), [452](#)
 [Pars caudalis] [162](#)
 Pars caudalis tuberculi [438](#)
 Pars cava [232](#)
 Pars ceca [caeca] retinae [516](#)
 Pars centralis [460](#)
 Pars cervicalis [106](#), [152](#), [188](#)
 Pars ciliaris retinae [516](#)
 Pars claviculalis [116](#)
 [Pars claviculalis m. deltoidei] [104](#)
 Pars clitoridea [224](#)
 Pars commissurospinalis [416](#), [422](#), [426](#)
 Pars compacta [232](#), [434](#)
 Pars convoluta [194](#)
 Pars costalis [112](#)
 Pars cranialis [50](#), [66](#), [124](#), [162](#), [190](#)
 Pars cruciformis vag. fibrosae [122](#), [130](#)
 [Pars cunealis pulvini digitalis] [556](#)
 Pars cupularis [534](#)
 Pars cutanea [222](#)
 Pars descendens [162](#)
 Pars disseminata prostatae [204](#)
 Pars distalis [232](#)
 Pars dorsalis [178](#), [446](#), [552](#)
 Pars dorsalis pontis [424](#)
 Pars endotympanica [24](#)
 Pars esophagea, [oesophagea] [150](#)
 Pars fetalis [220](#)
 Pars flaccida [536](#)
 Pars frontopontina [434](#)
 Pars glandularis [160](#), [560](#)
 Pars incisiva [38](#)
 Pars inferior [474](#)
 Pars inflexa lateralis [552](#)
 Pars inflexa medialis [552](#)
 Pars intercartilaginea [186](#)
 Pars intermedia [230](#)
 Pars intermedia bulborum [218](#)
 Pars intermembranacea [186](#)
 Pars interpolaris [420](#)
 Pars interstitiospinalis [416](#), [422](#), [426](#)
 Pars intrapelvina [126](#)
 Pars iridica retinae [516](#)
 Pars labialis [102](#)
 Pars laryngea pharyngis [150](#)
 Pars lateralis [16](#), [42](#), [444](#), [456](#), [552](#), [556](#)
 Pars libera penis [206](#)
 Pars limbica rhinencephali [450](#)
 Pars longa glandis [206](#)
 Pars lumbalis [112](#), [414](#)
 Pars magnocellularis [434](#)
 Pars major [62](#)
 Pars mandibularis [104](#)
 Pars marginalis [102](#)
 Pars mastoidea [104](#)
 Pars medialis [444](#), [456](#), [552](#), [556](#)
 Pars mediastinalis [188](#)
 Pars membranacea [176](#), [236](#)
 Pars minor [62](#)
 Pars mobilis septi nasi [174](#)
 Pars molaris [38](#), [102](#)
 Pars muscularis [236](#)
 Pars nasalis [28](#)
 Pars nasalis pharyngis [148](#)
 Pars nonglandularis [160](#)
 Pars occipitalis [104](#)
 Pars occipitomandibularis [102](#)
 Pars optica retinae [516](#)
 Pars oralis pharyngis [150](#)
 Pars orbitalis [28](#), [100](#)
 Pars ossea [176](#), [565](#)
 Pars ossea tubae auditivae [538](#)
 Pars palpebralis [100](#)
 Pars papillaris [560](#)
 Pars parainfundibularis tuberculi [438](#)
 Pars parasymphatica [508](#)
 Pars parietopontina [434](#)
 Pars parvocellularis [434](#)
 Pars pelvina [196](#), [210](#)
 Pars penina [210](#), [224](#)
 Pars petrosa [22](#)
 (Pars pharyngea) [232](#)
 Pars postchiasmatica [438](#)
 Pars precommissuralis [prae-] [450](#)
 Pars preprostatica [prae-] [210](#)
 Pars profunda [102](#), [142](#), [222](#)
 Pars prostatica [210](#)
 Pars pylorica [154](#), [158](#)
 Pars radiata [194](#)
 Pars rectalis [224](#)

- Pars reticulata [434](#)
 Pars reticulospinalis [416](#), [422](#), [426](#)
 Pars retrocommissuralis [450](#)
 Pars retrolenticularis capsulae int. [460](#)
 Pars rostralis [178](#), [420](#), [428](#), [448](#), [452](#)
 Pars rostralis tuberculi [438](#)
 Pars sacralis [414](#)
 Pars scapularis [116](#)
 Pars septalis rhinencephali [448](#)
 Pars squamosa [24](#)
 Pars sternalis [112](#)
 Pars sublentiformis capsulae int. [460](#)
 Pars superficialis [102](#), [142](#), [222](#)
 Pars superior [474](#)
 Pars suprachiasmatica [438](#)
 Pars supracommissuralis [450](#)
 Pars supramamillaris [440](#)
 Pars sympathica [506](#)
 Pars talofibularis [94](#)
 Pars tectospinalis [416](#), [422](#), [426](#)
 Pars tensa [536](#)
 Pars thoracica [106](#), [152](#), [188](#), [414](#)
 Pars tibiofibularis [94](#)
 Pars tibiocentralis [tibionavicularis] [94](#)
 Pars tibiotalaris [94](#)
 Pars torica pulvini digitalis [556](#)
 Pars transversa [162](#), [374](#)
 Pars tuberculi [232](#)
 Pars tympanica [24](#)
 Pars umbilicalis [374](#)
 Pars uterina [214](#)
Pars uterina [220](#)
 Pars ventralis [178](#), [446](#)
 Pars ventralis pontis [426](#)
 Pars vertebralis [188](#)
 Pars vestibulospinalis [416](#), [422](#)
 Partes corporis [562](#)
 Partes genitales feminae ext. [218](#)
 Partes genitales masculinae ext. [206](#)
 Parvus [571](#)
 Patella [68](#), [563](#)
 Pecten ossis pubis [64](#)
 Pectus [562](#)
 Pedalis [571](#)
 Pediculus arcus vertebrae [40](#)
 Pedunculus cerebellaris caudalis [418](#), [422](#)
 Pedunculus cerebellaris medius [424](#)
 Pedunculus cerebellaris rostralis [424](#), [434](#)
 Pedunculus cerebri [432](#)
 Pedunculus flocculi [428](#)
 Pedunculus [glandulae pinealis] [442](#)
 Pedunculus mamillaris [442](#)
 Pedunculus olfactorius [448](#)
 Pedunculus ventralis thalami [442](#)
 Pellis [571](#)
 Pellucidus [571](#)
 Pelvis [64](#), [562](#)
 Pelvis renalis [196](#)
 Penis [206](#)
 Perforatus [571](#)
 Periarchicortex [452](#)
 Pericardium [234](#)
 Pericardium fibrosum [234](#)
 Pericardium serosum [234](#)
 Perichondrium [565](#), [571](#)
 Pericranium [10](#)
 Perilympha [528](#)
 [Perimetrium] [216](#)
 Perimysium [566](#)
 Perineum [222](#), [562](#)
 Periodontium [144](#), [565](#)
 [Perioplum] [550](#)
 Periorbita [520](#)
 Periosteum [565](#), [571](#)
 Peripaleocortex [-palaco-] [452](#)
 Peripheralis [571](#)
 Periphria [571](#)
 Peritendineum [566](#)
 [Peritonacum] [226](#)
 Peritoneum [226](#)
 Peritoneum [Peritonacum] parietale [226](#)
 Peritoneum [Peritonacum] viscerale [226](#)
 Permanens, permanentis [571](#)
 [Peroneus] [571](#)
 Peroneus [571](#)
 Perpendicularis [571](#)
 Pes [563](#)
 Pes hippocampi [450](#), [452](#), [460](#)
 Petiolus epiglottidis [184](#)
 Petra [571](#)
 Petrosus [571](#)
 Phalanx distalis [58](#)
 Phalanx media [58](#)
 Phalanx proximalis [58](#)
 Phallus [571](#)
 Pharynx [148](#), [562](#)
 Philtrum [140](#)
 Pia mater encephali [462](#)
 Pia mater spinalis [462](#)
 Pigmentum [571](#)
 Pila accessoria dextra [156](#)
 Pila accessoria sinistra [156](#)
 Pila caudalis [156](#)
 Pila coronaria dorsalis [156](#)
 Pila coronaria ventralis [156](#)
 Pila cranialis [156](#)
 Pila longitudinalis dextra [156](#)
 Pila longitudinalis sinistra [156](#)
 Pila omasi [158](#)
 Pili [546](#)
 Pili lancei [546](#)
 Pili tactiles [546](#)
 Pili tact. buccales [546](#)
 Pili tact. carpales [546](#)
 Pili tact. infraorbitales [546](#)
 Pili tact. labiales inferiores [546](#)
 Pili tact. labiales superiores [546](#)
 Pili tact. mentales [546](#)
 Pili tact. supraorbitales [546](#)
 Pili tact. zygomatici [546](#)
 Pilus [571](#)
 Pinea [571](#)
 Pinna [571](#)
 Piriformis [571](#)
 Pisiformis [571](#)
 Pituita [571](#)
 Pius [571](#)
Placenta [220](#)
Placenta diffusa [220](#)
Placenta multiplex [220](#)
Placenta zonaria [220](#)
Placentomus [220](#)
 Plana dorsalia [2](#)
 Plana sagittalia [paramediana] [2](#)
 Plana transversalia [2](#)
 Planta pedis [564](#)
 Plantaris [568](#)
 Planum cutaneum [58](#)
 Planum medianum [2](#)
 Planum nasale [174](#), [562](#)
 Planum nasolabiale [174](#), [562](#)
 Planum nuchale [26](#)
 Planum parietale [26](#)
 Planum rostrale [174](#), [562](#)
 Planum temporale [26](#)
 Planus [571](#)
 Platysma [98](#)
 Pleura [192](#)
 Pleura costalis [192](#)
 Pleura diaphragmatica [192](#)
 Pleura mediastinalis [192](#)
 Pleura parietalis [192](#)
 Pleura pericardiaca [192](#)
 Pleura pulmonalis [192](#)
 Plexus adrenalis [suprarenalis] [502](#)
 Plexus aorticus abdominalis [502](#)
 Plexus aorticus thoracicus [502](#)
 Plexus autonomici [568](#)
 Plexus brachialis [482](#)
 Plexus cardiacus [502](#)
 Plexus caroticus communis [506](#)
 Plexus caroticus externus [506](#)
 Plexus caroticus internus [506](#)
 Plexus caudalis [coccygeus] dors. [500](#)
 Plexus caudalis [coccygeus] ventr. [500](#)
 Plexus cavernosi nasales [178](#)
 Plexus celiacus [coeliacus] [502](#)
 Plexus cervicalis [480](#)
 Plexus chorioideus [chorioideus] ventriculi lateralis [462](#)
 Plexus chorioideus [chorioideus] ventriculi quarti [462](#)
 Plexus chorioideus [chorioideus] ventriculi tertii [462](#)
 Plexus colicus [504](#)
 Plexus deferentialis [504](#)
 Plexus dentalis inferior [470](#)
 Plexus dentalis superior [468](#)
 Plexus entericus [504](#)
 Plexus esophageus [oesophageus] [476](#), [502](#)
 Plexus femoralis [504](#)
 Plexus gastrici [502](#)

- Plexus hepaticus 502
 Plexus iliaci [504](#)
 Plexus intermesentericus 502
 Plexus lienalis 502
 Plexus lumbalis 492
 Plexus lumbosacralis 492
 Plexus lymphaticus 402, 567
 Plexus mesentericus caudalis 502
 Plexus mesentericus cranialis 502
 Plexus myentericus [504](#)
 Plexus nervorum spinalium 567
 Plexus ophthalmicus 354–358
 Plexus ovaricus [504](#)
 Plexus palatinus 344, 356–360
 Plexus pampiniformis 372
 Plexus pancreaticus 502
 Plexus parotideus 472
 Plexus plevinus [504](#)
 Plexus periaerialis 567
 Plexus pharyngeus 348–352, [360](#),
 474, 476
 Plexus prostaticus [504](#)
 Plexus pterygoideus 356, 358, [360](#)
 Plexus pulmonalis 476, 502
 Plexus rectales caudales [504](#)
 Plexus rectales medii [504](#)
 Plexus rectalis cranialis [504](#)
 Plexus renalis 502
 Plexus reticularis 502
 Plexus ruminalis dexter 502
 Plexus ruminalis sinister 502
 Plexus sacralis 494
 Plexus subclavius 506
 Plexus submucosus [504](#)
 Plexus subserosus [504](#)
 Plexus testicularis [504](#)
 Plexus tympanicus 474
 Plexus uretericus 502
 Plexus uterovaginalis [504](#)
 Plexus venae profundae faciei 352
 Plexus vasculosus 567
 Plexus venosus 567
 Plexus venosus sclerae 510
 Plexus vertebralis 506
 Plexus vertebralis ext. dors. 338
 Plexus vertebralis ext. ventr. 338
 Plexus vertebralis int. ventr. 338
 Plexus vesicales [504](#)
 Plica alaris [176](#)
 Plica antitragica 540
 Plica aryepiglottica 186
 Plica axillaris 563
 Plica basalis [176](#)
 Plica cecocolica [caeco-] [230](#)
 [Plica ductus deferentis] [202](#)
 Plica duodenocolica 228
 Plica enameli [144](#)
 Plica fimbriata [146](#)
 Plica gastropancreatica [226](#)
 Plica genitalis [230](#)
 Plica glossoepiglottica lat. [150](#)
 Plica glossoepiglottica mediana
 [150](#)
 Plica hepatopancreatica [226](#)
 Plica ileocecalis [-caecalis] [230](#)
 Plica incudis 538
 Plica lacrimalis 524
 Plica lateris 562
 Plica mallearis caudalis 536, 538
 Plica mallearis rostralis 536, 538
 Plica mallearis tympani 538
 Plica obliqua [176](#)
 Plica preputialis [prae-] 206
 Plica pterygomandibularis 140
 Plica recta [176](#)
 Plica ruminoreticularis [156](#)
 Plica semilunaris [150](#)
 Plica semilunaris conjunctivae 524
 Plica stapedis 538
 Plica sublingualis 140
 Plica synovialis 566
 Plica ureterica 198
 [Plica vasculosa] [202](#)
 Plica venae cavae [192](#)
 Plica vestibularis 186
 Plica vocalis 186
 Plica v. cavae sinistrae 338
 Plicae ciliares 512
 Plicae circulares 162, 216
 Plicae cutis [544](#)
 Plicae gastricae [160](#)
 Plicae iridis 514
 Plicae longitudinales 216
 Plicae parallelae [176](#)
 Plicae scaphae 540
 Plicae semilunares ceci [caeci] [164](#)
 Plicae semilunares coli 166
 Plicae spirales abomasi 162
 Plicae transversae colli [544](#)
 Plicae transversales recti [168](#)
 Plicae tubariae [214](#)
 Plicae tunicae mucosae ves.
 felleae [172](#)
 Plicae villosae [160](#)
 Pneumaticus 571
 [Pollex] 563
 Polus anterior 510
 Polus anterior lentis 518
 Polus caudalis [occipitalis] [446](#)
 Polus posterior 510
 Polus posterior lentis 518
 Polus rostralis [frontalis] [446](#)
 Pons 424
 Poples 563
 Porta hepatis 168
 Portio prevaginalis [prae-]
 [cervicis] [214](#)
 Portio vaginalis [cervicis] [214](#)
 Porus acusticus externus [24](#), 540
 Porus acusticus internus [22](#), 530
 Porus gustatorius 542
 Posterior 568
 [Praeputium] 206, 562
 [Praeputium clitoridis] [218](#)
 Preputium 206, 562
 Preputium clitoridis [218](#)
 Primus 571
 Princeps, principis 571
 Prisma, prismatis 571
 Processus accessorius 40
 Proc. alveolaris [38](#)
 Proc. anconeus [anconaeus] [54](#)
 Proc. angularis 38
 Proc. antitragicus lateralis 540
 Proc. antitragicus medialis 540
 Proc. articularis caud. 40, 44
 Proc. articularis cran. 40, 44
 Proc. cartilagineus [68](#)
 Proc. caudalis [176](#)
 Proc. caudatus 170
 Procc. ciliares 512
 Proc. clinoides caudalis [18](#)
 Proc. clinoides rostralis 20
 Proc. condylaris [38](#)
 Proc. coracoideus 48, 72
 Proc. corniculatus [184](#)
 Proc. cornualis 28
 Proc. coronoideus [38](#)
 Proc. coronoideus lateralis [54](#)
 Proc. coronoideus medialis [54](#)
 Proc. costalis 40
 Proc. cuneiformis [184](#)
 Proc. dorsalis glandis 206
 Proc. extensorius [58](#), 60
 Proc. frontalis [30](#), [34](#), [36](#)
 Proc. hamatus 48
 Proc. hemalis [haemalis] 44
 (Proc. hyaloideus) 518
 Proc. interparietalis 16
 Proc. intrajugularis 16
 Proc. jugularis 16
 Proc. lacrimalis caudalis [30](#)
 Proc. lacrimalis rostralis [30](#)
 Proc. lateralis 536
 Proc. lenticularis 536
 Proc. lingualis [38](#)
 Proc. mamillaris 40
 Proc. mastoideus [22](#)
 Proc. medialis [184](#)
 Proc. muscularis 24, [184](#), [536](#)
 Proc. nasalis 34, [36](#)
 Proc. occipitalis [24](#)
 Proc. orbitalis 36
 Proc. palatinus [34](#)
 Proc. palmaris lateralis [58](#)
 Proc. palmaris medialis [58](#)
 Proc. papillaris 170
 Proc. paracondylaris 16
 Proc. plantaris lateralis [74](#)
 Proc. plantaris medialis [74](#)
 Proc. pterygoideus 20
 Proc. pyramidalis [36](#)
 Proc. retroarticularis [24](#)
 Proc. retrotympanicus [24](#)
 Proc. rostralis 536
 Proc. septalis 28, [30](#)
 Proc. sphenoidal 36
 Proc. spinosus 40
 Proc. styloideus [22](#), [52](#), [54](#)
 Proc. styloideus lateralis [52](#)
 Proc. styloideus medialis [52](#)
 Proc. suprahamatus 48
 Proc. temporalis [36](#)
 Proc. tentoricus 16, [18](#), [26](#)
 Proc. transversus 40, 42
 Proc. uncinatus 30, [172](#)
 Proc. unguicularis 60
 Proc. urethrae [210](#)

- Proc. vaginalis peritonei
 [peritoneae] [216](#)
Proc. vaginalis peritonei
 [peritoneae] [204](#), [230](#)
 Proc. vocalis [184](#)
 Proc. xiphoideus [46](#)
 Proc. zygomaticus [24](#), [28](#), [34](#)
 Profundus [568](#)
 Projectio, projectionis [571](#)
 [Prolatio aliformis] [428](#)
 Prominens, prominentis [571](#)
 Prominentia laryngea [182](#), [562](#)
 Prominentia mallearis [536](#)
 Prominentia spiralis [530](#)
 Promontorium [44](#), [534](#)
 Pronator [571](#)
 Prosencephalon [436](#)
 Prostata [204](#)
 Protuberantia intercornualis [10](#)
 Protuberantia occipitalis ext. [16](#)
 Protuberantia occipitalis int. [16](#)
 Proventriculus [156](#)
 Proximalis [568](#)
 [Psalterium dorsale] [450](#)
 [Psalterium ventrale] [450](#)
 Pterygoma, pterygomatis [571](#)
 Pubes [571](#)
 Pudendum femininum [218](#), [563](#)
 Pudendus [572](#)
 Pulmo [dexter et sinister] [18](#)
 Pulpa coronalis [144](#)
 Pulpa dentis [144](#)
 Pulpa lienis alba [412](#)
 Pulpa lienis rubra [412](#)
 Pulpa radicularis [144](#)
 Pulposus [572](#)
 Pulvinar [442](#)
 Pulvini cervicales [216](#)
 [Pulvinus coronae] [550](#)
 [Pulvinus dentalis] [140](#)
 [Pulvinus digitalis] [556](#)
 [Pulvinus limbi] [550](#)
 Punctum lacrimale [524](#)
 Pupilla [514](#)
 Pupillaris [572](#)
 Putamen [460](#)
 Pylorus [154](#)
 Pyramides renales [194](#)
 Pyramis [medullae oblongatae]
 [418](#)
 Pyramis [vermis] [428](#)
- Quadratus [572](#)
 Quadriceps, quadricipitis [572](#)
- Radialis [572](#)
 Radiatio acustica [458](#)
 Radiatio corporis callosi [458](#)
 Radiatio optica [458](#)
 Radices craniales [478](#)
 Radices plexus [482](#), [492](#)
 Radices spinales [478](#)
 Radii lentis [518](#)
 Radius [52](#)
 Radix [232](#)
 Radix caudae [563](#)
 Radix caudalis [480](#)
 Radix clinica [144](#)
 Radix cochlearis [474](#)
 Radix cranialis [480](#)
 Radix dentis [144](#)
 Radix dorsalis [480](#)
 Radix lateralis [438](#), [484](#)
 Radix linguae [146](#)
 Radix medialis [438](#), [484](#)
 Radix mesenterii [228](#)
 Radix motoria [464](#)
 Radix nasi [174](#)
 Radix oculomotoria [464](#)
 Radix penis [206](#)
 Radix pili [546](#)
 Radix pulmonis [190](#)
 Radix sensoria [464](#)
 Radix ventralis [480](#)
 Radix vestibularis [474](#)
 Rami abomasiales parietales [476](#)
 Rr. abomasiales viscerales [478](#)
 Rr. ad pontem [272](#), [276](#), [280](#), [282](#)
 Rr. ad sulcum ventriculi [476](#), [478](#)
 Rr. adrenales [304](#)
 Rr. adrenales caudales [310](#)
 Rr. adrenales craniales [304](#), [308](#),
 [322](#)
 Rr. alveolares inferiores caud. [470](#)
 Rr. alveolares inferiores medii
 [470](#)
 Rr. alveolares superiores caud.
 [468](#)
 Rr. alveolares superiores medii
 [468](#)
 Rr. alveolares superiores rostr.
 [468](#)
 Rr. a. [v.] centralis retinae [516](#)
 Rr. atriales ruminis [476](#), [478](#)
 Rr. auriculares rostrales [472](#)
 Rr. bronchales [476](#)
 Rr. buccales [472](#)
 Rr. buccolabiales [472](#)
 Rr. calcanei [322](#), [326](#), [330](#), [336](#)
 Rr. capsulares [196](#)
 Rr. cardiaci [476](#)
 Rr. carpei dorsales [298](#)
 Rr. caudales [304](#), [480](#)
 Rr. caudales [coccygei], [304](#), [318](#),
 [378](#), [386](#)
 Rr. celiaci [coeliaci] [478](#)
 Rr. centrales [272](#)
 Rr. choroidei [chorioidei] caud.
 [272](#)
 Rr. colici [310](#), [376](#)
 Rr. communicantes [480](#), [506](#)
 Rr. communicantes cum n. auriculotemporalis [472](#)
 Rr. communicantes cum n. buccali [472](#)
 Rr. communicantes cum n. faciali
 [470](#)
 Rr. communicantes cum n. hypoglossi [470](#)
 Rr. communicantes cum n. linguales [472](#)
 Rr. communicantes cum n. nasali
 caudali [468](#)
 Rr. communicantes cum n. palatino
 majore [468](#)
 Rr. communicantes cum n. palatino
 minore [468](#)
 Rr. cornuales [466](#)
 Rr. corticales [272](#)
 Rr. craniales [304](#), [480](#)
 Rr. cutanei [494–500](#)
 Rr. cutanei laterales [302](#)
 Rr. dentales [248](#), [250](#), [254](#), [256](#),
 [260](#), [262](#), [266](#), [268](#), [350](#)
 Rr. dentales inferiores [470](#)
 Rr. dentales superiores [468](#)
 Rr. dorsales [274](#), [340](#), [480](#), [490](#),
 [492](#), [500](#)
 Rr. dorsales linguae [246](#), [252](#), [258](#),
 [264](#)
 Rr. dorsales phalangium prox.
 [296](#), [330](#), [368](#)
 Rr. ductus deferentis [310](#)
 Rr. duodenales [476](#)
 Rr. epididymales [310](#)
 Rr. esophagei [oesophagei] [302](#),
 [306](#), [308](#), [476](#)
 Rr. gastrici parietales [476](#)
 Rr. gastrici viscerales [478](#)
 Rr. gingivales inferiores [470](#)
 Rr. gingivales superiores [468](#)
 Rr. glandulares [252](#), [472](#)
 Rr. glandulares zygomatici [250](#),
 [350](#)
 Rr. hepatici [476](#)
 Rr. interarcuales [338](#)
 Rr. intercostales ventrales [274](#),
 [278–282](#)
 Rr. interganglionares [506](#)
 Rr. isthmi faucium [470](#)
 Rr. labiales dorsales [314](#)
 Rr. labiales inferiores [470](#)
 Rr. labiales superiores [468](#)
 Rr. laryngopharyngei [506](#)
 Rr. lienales [arteriae lienalis] [412](#)
 Rr. linguales [470](#), [474](#), [478](#)
 Rr. malleolares [324](#)
 Rr. malleolares laterales [328](#), [332](#)
 Rr. malleolares mediales [326–332](#)
 Rr. mammarii [274](#), [278](#), [290](#), [302](#)
 Rr. mammarii laterales [284](#), [490](#)
 Rr. mammarii mediales [490](#)
 Rr. mediastinales [274](#), [278–282](#),
 [302](#)
 Rr. mentales [248](#), [254](#)
 Rr. musculares [248](#), [250](#), [256](#), [262](#),
 [268](#), [482](#), [484](#), [488](#), [494–500](#)
 Rr. nasales caudales ventr. [466](#)
 Rr. nasales externi [466](#), [468](#)
 Rr. nasales interni [468](#)
 Rr. omasiales [476](#), [478](#)
 Rr. orbitales [468](#)
 Rr. palatini [244](#), [246](#), [252](#)
 Rr. palmares phalangium prox.
 [296](#), [368](#)
 Rr. palpebrales [466](#), [472](#)
 Rr. pancreatici [306–310](#), [374](#)

- Rr. parotidei [252](#), [258](#), [266](#), [356](#), [360](#), [468](#)
 Rr. perforantes [374](#), [378–382](#)
 Rr. perforantes prox. II et IV [396](#)
 Rr. perforantes prox. II–IV [326](#)
 Rr. pericardiaci [302](#), [480](#)
 Rr. perihyoidei [246](#), [252](#), [258](#), [264](#)
 Rr. pharyngei [244](#), [246](#), [252](#), [476](#)
 Rr. phrenici [302](#), [304](#), [308](#), [344](#)
 Rr. plantares phalangium prox. [330](#)
 Rr. preputiales [prae-] [320](#)
 Rr. pterygoidei [250](#), [254](#), [266](#)
 Rr. pulmonales [502](#)
 Rr. renales [478](#)
 Rr. reticulares caudales [478](#)
 Rr. reticulares craniales [476](#)
 Rr. retis [248](#)
 Rr. rostrales ad rete mirabile epidurale rostr. [262](#)
 Rr. ruminales dorsales [478](#)
 Rr. sacrales [304](#), [318](#), [378](#), [386](#)
 Rr. sacrales I et II [316](#)
 Rr. scrotales dorsales [314](#)
 Rr. septales [242](#)
 Rr. sinistri laterales [306](#)
 Rr. sinistri mediales [306](#)
 Rr. sinus frontalis [466](#)
 Rr. spinales [272](#), [276](#), [280](#), [282](#), [338](#)
 Rr. sternales [274](#), [278–282](#)
 Rr. sternocleidomastoidei [244](#)
 Rr. striati [272](#)
 [Rr. suprarenales] [304](#)
 [Rr. suprarenales caudales] [310](#)
 [Rr. suprarenales craniales] [304](#), [308](#), [372](#)
 Rr. thymici [274](#), [278–282](#)
 Rr. tonsillares [244](#), [474](#)
 Rr. tracheales [476](#)
 Rr. ventrales [480](#), [490](#), [492](#), [500](#)
 Rr. vestibulares [530](#)
 Ramus acetabularis [320](#)
 R. acromialis [274](#), [276](#), [280](#), [346](#)
 R. ad curvaturam majorem abomasi [478](#)
 R. ad rete mirabile epidurale rostr. [254](#), [270](#)
 R. ad sulcum cranialem [478](#)
 R. adrenalis caudalis [372](#)
 R. alveolaris inferior rostr. [470](#)
 R. anastom. cum a. carotide interna [248](#), [250](#)
 R. anastom. cum a. infraorbitali [246](#), [258](#), [264](#)
 R. anastom. cum a. meningea media [250](#)
 R. anastom. cum a. metacarpea dorsali II [300](#)
 R. anastom. cum a. metacarpea dorsali III [300](#)
 R. anastom. cum a. occipitali [272](#), [276](#), [280](#), [282](#)
 R. anastom. cum a. ophthalmica interna [248](#), [250](#), [256](#), [262](#), [268](#)
 R. anastom. cum a. saphena [336](#)
 R. anastom. cum a. tibiali caudali [328](#), [332](#)
 R. anastom. cum plexu ophthalmico [356](#)
 R. anastom. cum v. jugulari interna [340](#)
 R. anastom. cum v. occipitali [342](#)
 R. anastom. cum v. ophthalmica externa dorsali [348](#), [350](#), [354](#)
 R. anastom. cum v. ophthalmica externa ventrali [348](#), [350](#)
 R. anastom. cum v. saphena medialis [magna] [388](#), [390](#), [394](#)
 R. anastom. cum v. temporalis superficiali [348](#), [350](#)
 R. angularis oculi [258](#)
 R. articularis genus [322](#), [392](#)
 R. articularis temporomandibularis [248](#), [252](#), [260](#), [266](#)
 R. ascendens [242](#), [274](#), [276](#), [280](#), [282](#), [318](#), [322](#), [326](#), [330](#), [346](#)
 R. auricularis [346](#), [476](#)
 R. auricularis intermedius [248](#), [252](#), [258](#), [266](#)
 R. auricularis intermedius lat. [258](#)
 R. auricularis intermedius med. [258](#)
 R. auricularis internus [472](#)
 R. auricularis lateralis [248](#), [252](#), [258](#), [266](#)
 R. auricularis medialis [248](#), [252](#), [260](#), [266](#)
 R. bronchialis [302](#)
 R. carpeus dorsalis [284–296](#), [300](#), [346](#), [368](#), [370](#)
 R. carpeus palmaris [284–296](#), [300](#)
 R. caudalis [320](#), [322](#), [326](#), [330](#), [334](#), [388–400](#), [494](#)
 R. caudalis ad rete mirabile epidurale rostr. [262](#)
 R. caudalis ossis pubis [64](#)
 R. circumflexus [244](#)
 R. circumflexus fibulae [328](#)
 R. cochlearis [530](#)
 R. colicus [310](#), [376](#)
 R. collateralis [302](#), [310](#), [376](#)
 R. colli [472](#)
 R. communicans [476](#), [484](#), [486](#), [498](#), [567](#)
 R. communicans cum chorda tympani [470](#)
 R. communicans cum ganglio ciliari [466](#)
 R. communicans cum n. cutaneo femoris caudali [500](#)
 R. communicans cum n. digitali dors. proprio III abaxiali [498](#)
 R. communicans cum n. digitali dors. proprio IV abaxiali [500](#)
 R. communicans cum n. digitali plantari communi IV [498](#)
 R. communicans cum n. digitali plantari proprio III axiali [496](#)
 R. communicans cum n. digitali plantari proprio IV axiali [496](#)
 R. communicans cum n. glosso-pharyngeo [476](#)
 R. communicans cum n. lacrimali [466](#)
 R. communicans cum n. laryngeo caudali [476](#)
 R. communicans cum n. metatarseo dorsali III [496](#)
 R. communicans cum n. nasociliari [464](#)
 R. communicans cum n. pudendo [500](#)
 R. cornualis [466](#)
 R. costoabdominalis ventr. [278](#), [280](#)
 R. cranialis [320](#), [322](#), [334](#), [388–392](#), [396](#), [400](#), [494](#)
 R. cranialis ossis pubis [64](#)
 R. cricothyroideus [-thyroideus] [244](#), [246](#)
 R. cutaneus lateralis [302](#), [304](#), [490](#), [492](#)
 R. cutaneus lateralis [pectoralis et abdominalis] [490](#)
 R. cutaneus medialis [302](#), [304](#), [490](#), [492](#)
 [R. cutaneus tarsalis med.] [498](#)
 R. cutaneus ventralis [492](#)
 R. cutaneus ventralis [pectoralis et abdominalis] [490](#)
 R. deltoideus [274](#), [280](#), [282](#)
 R. descendens [242](#), [272](#), [276–282](#), [322](#), [326](#), [330](#), [334](#), [342](#)
 R. dexter [308](#), [374](#)
 R. dexter lateralis [306](#)
 R. dexter medialis [306](#)
 R. digastricus [472](#)
 R. dorsalis [274](#), [284](#), [286](#), [302](#), [304](#), [318](#), [338–342](#), [366](#), [372](#), [464](#), [478](#), [480](#), [486–490](#), [496–500](#)
 R. dorsalis phalangis dist. [292](#), [296–300](#), [322](#), [330](#), [363](#)
 R. dorsalis phalangis mediae [292](#), [296–300](#), [326](#), [330](#), [336](#), [346](#)
 R. dorsalis phalangis prox. [292](#), [296–300](#), [326](#), [330](#), [336](#), [346](#)
 R. ductus deferentis [314](#), [316](#), [318](#), [386](#)
 R. epiploicus [308](#), [376](#)
 R. esophageus [oesophageus] [302](#), [308](#), [476](#)
 R. externus [476](#), [478](#)
 R. femoralis [492](#)
 R. frontalis [256](#)
 R. gastrolienalis [306](#)
 R. genitales [492](#)
 R. glandularis [246](#), [248](#), [258](#), [264](#)
 R. ilei antimesenterialis [310](#)
 R. ilei mesenterialis [310](#)
 R. infraorbitalis [348](#)
 R. intermedius [242](#), [338](#)
 R. internus [476](#), [478](#)
 R. interosseus [286–290](#), [294](#), [324](#), [366](#)
 R. interventricularis paraconalis [242](#)
 R. interventricularis subinuosus [242](#)

- R. labialis dorsalis 312, [316](#), [318](#)
 R. labialis dors. et mammarius [316](#)
 R. labialis ventralis 320
 R. lacrimalis [260](#)
 R. laryngeus [244](#), [246](#)
 R. laryngeus caudalis [244](#), [246](#), [344](#), [360](#)
 R. lateralis [286](#), 396, [480](#), 484, 490, [492](#), [496](#)
 R. lateralis nasi rostr. [258](#)
 R. lingualis 348
 R. lobi accessorii [242](#), 338
 R. lobi caudalis [242](#)
 R. lobi cranialis [242](#)
 R. lobi medii [242](#)
 R. mammarius [500](#)
 R. mandibulae [38](#)
 R. marginalis mandibulae [472](#)
 [R. marginis ventricularis sinistri] [242](#)
 R. massetericus [258](#), [260](#), [264](#)
 R. medialis [286](#), 396, [480](#), 484, 490, [492](#)
 R. membranae tympani 468
 R. meningeus [258](#), [260](#), [464](#)–[468](#), [472](#), [480](#)
 R. muscularis 567
 R. muscularis distalis [482](#)
 R. muscularis proximalis [482](#)
 R. muscoli coccygei [500](#)
 R. muscoli levatoris ani [500](#)
 R. muscoli stylopharyngei caud. 474
 R. mylohyoideus [248](#), [254](#), [260](#)
 R. nasalis lateralis [466](#)
 R. nasalis medialis [466](#)
 R. obturatorius 320
 R. occipitalis [246](#), [248](#), [258](#), [264](#), [266](#), [270](#), 344, [360](#)
 R. ossis ischii [64](#)
 R. palmaris [286](#)–[290](#), [294](#), [300](#), 488, 490
 R. palmaris phalangis dist. [296](#), [298](#)
 R. palmaris phalangis mediae [292](#), [296](#), [300](#)
 R. palmaris phalangis prox. [292](#), [300](#)
 R. palmaris superficialis [288](#), [292](#), [296](#)
 R. pancreaticus 306
 R. parietalis 308
 R. parotideus [248](#), [252](#)
 R. perforans [328](#), [332](#)
 R. perforans distalis [288](#), [300](#), [322](#), [336](#)
 R. perforans distalis II [334](#)
 R. perforans distalis III [292](#), [296](#), 326, 330
 R. perforans proximalis [288](#), [292](#)
 R. perforans proximalis II [324](#)
 R. perforans proximalis III [296](#), 330
 R. pharyngeus [244](#), [246](#), [252](#), [264](#), 474
 R. phrenicus [280](#)
 R. plantaris phalangis dist. 330, [332](#)
 R. plantaris phalangis mediae 326, 330, [336](#)
 R. plantaris phalangis prox. 326, [336](#)
 R. preputialis [prae-] et scrotalis [500](#)
 R. prescapularis [prae-] [274](#), [276](#), [280](#), [282](#), [346](#)
 R. profundus [286](#)–[290](#), [294](#), [300](#), 320, 322, 326, 330, 334, 484, 488, 498, 500
 R. pterygoideus [260](#)
 R. pyloricus [476](#)
 R. renalis [502](#)
 R. ruminalis dexter [478](#)
 R. scrotalis dorsalis 312
 R. scrotalis ventralis 320
 R. sinister 306, 308
 R. sinus carotici 474
 R. spinalis [274](#)–[278](#), [282](#), [302](#), [304](#), [318](#)
 R. sternocleidomastoideus [244](#), [248](#), [252](#), [258](#)
 R. stylohyoideus [472](#)
 R. sublingualis [360](#)
 R. submentalis [350](#)
 R. superficialis [286](#)–[290](#), [294](#), [300](#), [322](#)–[326](#), 330–336, 484, 488, 490
 [R. suprarenalis caudalis] [322](#)
 R. suprascapularis [280](#), [346](#), [364](#)
 (R. sympathicus ad ganglion ciliare) [464](#)
 (R. sympathicus ad ganglion mandibulare) [472](#)
 R. tori digitalis [288](#), [292](#), [296](#), [300](#), [322](#), 326, 330, [332](#), [336](#)
 R. tori metacarpei [288](#)
 R. tori metatarsi [322](#)
 R. transversus [322](#), 326, 330
 R. transversus faciei 470
 R. tubarius 310, 474
 R. ulnaris [292](#)
 R. uretericus 310–318
 R. urethralis [312](#)–[318](#)
 R. uterinus 310, [314](#), [316](#)
 R. ventralis [464](#), [480](#)
 R. vestibularis [318](#)
 R. visceralis 308
 R. zygomaticofacialis 466
 R. zygomaticofacialis access. [466](#)
 R. zygomaticotemporalis [466](#)
 R. zygomaticus [472](#)
 Raphe [222](#), [418](#), [424](#)
 Raphe palati [140](#)
 Raphe palpebralis lateralis 522
 Raphe penis [208](#)
 Raphe pharyngis [152](#)
 Raphe preputii [206](#)
 Raphe scroti [210](#)
 Recessus caudalis omentalis [226](#)
 Rec. cochlearis [532](#)
 Rec. costodiaphragmaticus [192](#)
 Rec. costomediastinalis [192](#)
 Rec. dorsales [86](#), [88](#)
 Rec. dorsalis omentalis [226](#)
 Rec. duodenalis caudalis [228](#)
 Rec. ellipticus [532](#)
 Rec. epitympanicus 534
 Rec. inframamillaris 438
 [Rec. infundibuli] 436
 Rec. interlaminares [162](#)
 Rec. laryngis medianus [186](#)
 Rec. lat. ventriculi quarti [430](#)
 Rec. lienalis [226](#)
 Rec. lombodiaphragmaticus [192](#)
 Rec. maxillaris [14](#), [180](#)
 Rec. mediastini [192](#)
 Rec. mediastinodiaphragm. sin. [192](#)
 Rec. neurohypophysialis 436
 Rec. opticus 436
 Rec. palmares [86](#), [88](#)
 Rec. pelvis [196](#)
 Rec. pharyngeus 148
 Rec. pinealis 442
 Rec. piriformis [150](#)
 Rec. plantares [96](#)
 Rec. pleurales [192](#)
 Rec. ruminis [156](#)
 Rec. sphericus [sphaericus] [532](#)
 Rec. subextensorius [136](#)
 Rec. sublingualis lateralis [140](#)
 Rec. subpopliteus [136](#)
 Rec. supraomentalis [226](#)
 Rec. suprapinealis [442](#)
 Rec. urethralis [210](#)
 Rec. terminales [196](#)
 Rectum [166](#)
 Rectus [572](#)
 Recurrens, recurrentis [572](#)
 Reflexus [572](#)
 Regg. abdominis [6](#)
 Reg. abdominis caudalis [6](#)
 Reg. abdominis cranialis [6](#)
 Reg. abdominis lateralis [6](#)
 Reg. abdominis media [6](#)
 Reg. acromialis 4
 Reg. analis [6](#)
 Reg. antebrachii [8](#)
 Reg. articulationis coxae [8](#)
 Reg. articulationis humeri [8](#)
 Reg. articulationis temporo-mandib. [2](#)
 Reg. auricularis [2](#)
 Reg. axillaris [8](#)
 Reg. brachii [8](#)
 Reg. brachiocephalica [4](#)
 Reg. buccalis [2](#)
 Reg. calcanea [3](#)
 Regg. capitis [2](#)
 Reg. cardiaca [4](#)
 Reg. carpi [8](#)
 Reg. cartilaginis scapulae [4](#)
 Reg. caudalis [6](#)
 Reg. clunis [6](#)
 Regg. colli [4](#)
 Reg. colli dorsalis [4](#)
 Reg. colli lateralis [4](#)

- Reg. colli ventralis 4
 Reg. compedis 8
 Reg. cornualis 2
 Reg. coronalis 8
 Regg. corporis 564
 Reg. costalis 4
 Regg. cranii 2
 Reg. cruris 8
 Reg. cubiti 8
 Reg. dorsalis nasi 2
 Regg. dorsi 6
 [Reg. dorsocostalis] 6
 Regg. faciei 2
 Reg. femoris 8
 Reg. frontalis 2
 Reg. genus cranialis 8
 Reg. genus lateralis 8
 Reg. genus medialis 8
 Reg. glutea [glutaea] 6
 Reg. hypochondriaca 6
 Reg. hypothalamica caudalis 440
 Reg. hypothalamica intermedia [tuberalis] 440
 Reg. hypothalamica rostralis cum reg. preoptica [prae-] 438
 Reg. infraorbitalis 2
 Reg. infraspinata 4
 Reg. inguinalis 6
 Reg. intermandibularis 2
 Reg. interphalangea proximalis 8
 Reg. interscapularis 6
 Reg. labialis inferior 2
 Reg. labialis superior 2
 Reg. laryngea 4
 Reg. lateralis nasi 2
 Reg. lumbalis 6
 Reg. mammaria abdominalis 6
 Reg. mammaria inguinalis 6
 Reg. mammaria thoracica 4
 Reg. mandibularis 2
 Reg. masseterica 2
 Reg. maxillaris 2
 Regg. membri pelvini 8
 Regg. membri thoracici 8
 Reg. mentalis 2
 Reg. metacarpi 8
 Reg. metacarpophalangea 8
 Reg. metatarsi 8
 Reg. metatarsophalangea 8
 Reg. naris 2
 Reg. nasalis 2
 Reg. occipitalis 2
 Reg. olecrani 8
 Reg. olfactoria 178
 Reg. olfactoria tunicae mucosae nasi 542
 Reg. oralis 2
 Reg. orbitalis 2
 Reg. palpebralis inferior 2
 Reg. palpebralis superior 2
 Reg. parietalis 2
 Reg. parotidea 4
 Reg. patellaris 8
 Regg. pectoris 4
 Regg. pelvis 6
 Reg. perinealis 6
 Reg. phalangis mediae 8
 Reg. phalangis proximalis 8
 Reg. pharyngea 4
 Reg. plicae lateris 6
 Reg. poplitea 8
 Reg. preputialis [prae-] 6
 Reg. prescapularis [prae-] 4
 Reg. presternalis [prae-] 4
 Reg. pubica 6
 Reg. radices caudae 6
 Reg. respiratoria 178
 Reg. retroauricularis 4
 Reg. sacralis 6
 Reg. scapularis 4
 Reg. scrotalis 6
 Reg. sternalis 4
 Reg. sternocephalica 4
 Reg. subhyoidea 2
 Reg. supramammaria 6
 Reg. supraspinata 4
 Reg. tarsi 8
 Reg. temporalis 2
 Reg. tendinis calcanei communis 8
 Reg. trachealis 4
 Reg. tricipitalis 8
 Reg. trochanterica 8
 Reg. tuberi coxae 6
 Reg. tuberi ischiadici 6
 Reg. uberis 6
 Reg. umbilicalis 6
 Reg. urogenitalis 6
 Reg. vertebralis thoracis 6
 Reg. xiphoidea 6
 Reg. zygomatica 2
 Ren 194
 Renalis 572
 Respiratio, respirationis 572
 Rete arteriosum 567
 Rete articulare cubiti 284, 286, 290, 294, 298
 Rete articulare genus 324, 328, 332, 334
 Rete calcaneum 322, 326, 330, 336
 Rete carpi dorsale 288, 292, 296, 300, 368, 370
 Rete chiasmaticum 270
 Rete mirabile 267
 Rete mirabile a. maxillaris 248
 Rete mirabile epidurale caudale 270, 276, 280
 Rete mirabile epidurale rostrale 270
 Rete mirabile ophthalmicum 262
 Rete patellae 324, 328, 332, 334
 Rete testis 200
 Rete venosum 567
 Reticulum 158
 Retina 516
 Retinacula cutis 544
 Retinaculum extensorum 122
 Retinaculum extensorum crurale 130
 Retinaculum extensorum metatarsale 130
 Retinaculum extensorum tarsale 130
 Retinaculum flexorum 122, 130
 Retinaculum mm. peron. [fibularium] 130
 Retinaculum patellae laterale 92
 Retinaculum patellae mediale 92
 Retroflexus 572
 [Rhaphe] 222, 418, 424
 [Rhaphe palati] 140
 [Rhaphe palpebralis lateralis] 522
 [Rhaphe penis] 208
 [Rhaphe pharyngis] 152
 [Rhaphe praeputii] 206
 [Rhaphe scroti] 210
 Rhinencephalon 448
 Rhinos 572
 Rhombencephalon 416
 Rhomboideus 572
 Rima glottidis 186
 Rima oris 140, 562
 Rima palpebrarum 522, 562
 Rima pudendi [vulvae] 218
 Rima vestibuli 186
 Rivus lacrimalis 524
 Rostralis 568
 Rostrum 174, 562
 Rostrum corporis callosi 456
 Rostrum sphenoidale 20
 Rotundus 572
 Ruber 572
 Rudimentum 572
 Rugae palatinae 140
 Rugae vaginales 216
 Rumen 156
 Ruminoreticulum 156
 Sacculi alveolares 190
 Sacculus 528
 Saccus cecus [caecus] caudodorsalis 156
 Saccus cecus [caecus] caudoventralis 156
 Saccus cecus [caecus] ventriculi 156
 Saccus conjunctivae 524
 [Saccus cranialis] 156
 Saccus cutaneus marginalis 540
 Saccus dorsalis 156
 Saccus endolymphaticus 526
 Saccus lacrimalis 524
 Saccus ventralis 156
 Sacrum 572
 Sagittalis 568
 Saliva 572
 Sanguis, sanguinis 567, 572
 Scala tympani 528
 Scala vestibuli 528
 Scalenus 572
 Scapha 540
 Scapula 48
 Scapus pili 546
 Schindylesis 565
 Sclera 510
 Scrotum 210, 562
 Scutum 122, 130
 Sebaceus 572
 Sebum 572

- Secretum 572
 Sectiones cerebelli [428](#)
 Sectiones epithalami [446](#)
 Sectiones hypothalami 438
 Sectiones medullae oblongatae 418
 Sectiones medullae spinalis 414
 Sectiones mesencephali 432
 Sectiones metathalami [446](#)
 Sectiones neopallii 458
 Sectiones pontis 424
 Sectiones rhinencephali 452
 Sectiones subthalami 442
 Sectiones thalamencephali [444](#)
 Sectiones thalami [444](#)
 Segmenta bronchopulmonalia 190
 Segmenta dorsalia lobi caud. 190
 Segmenta dorsalia lobi cran. 190
 Segmenta lateralia lobi caud. 190
 Segmenta lateralia lobi cran. 190
 Segmenta lobi medii 190
 Segmenta medialia lobi caud. 190
 Segmenta medialia lobi cran. 190
 Segmenta ventralia lobi caud. 190
 Segmenta ventralia lobi cran. 190
 Segmentum accessorium 190
 Sella turcica [18](#)
 Semen, seminis 572
 Semicanalisis m. tensoris veli palatini [24](#)
 Semicanalisis tubae auditivae [24](#)
 Sensorium 572
 Sensus 572
 Septa interalveolaria [34](#), [38](#)
 Septa interradicularia [34](#), [38](#)
 Septa sinuum frontalem 28, [180](#)
 Septula testis [200](#)
 Septulum 572
 Septum atrioventriculare 236
 Septum bullae [24](#)
 Septum canalis musculotubarii [24](#)
 Septum conchae dorsalis 178
 Septum conchae ventralis 178
 Septum corporum cavernosorum [218](#)
 Septum femorale 130
 Septum glandis 206
 Septum interatriale 236
 Septum intermedium 462
 Septum interventriculare 236
 Septum linguae [148](#)
 Septum medianum dorsale 414
 Septum nasi [176](#)
 Septum nasi oseum [14](#)
 Septum orbitale 520
 Septum penis 208
 Septum perineale [222](#)
 Septum pharyngis [148](#)
 Septum rectovaginale [222](#)
 Septum scroti 210
 Septum sinuum frontalem 16, 28
 Septum sinuum maxillarium 32, [180](#)
 Septum sinuum palatinorum [34](#), [36](#)
 Septum sinuum sphenoidalium 20, [180](#)
 Septum telencephali [cellulare, verum] 448
 Septum telencephali [pellucidum] 448
 Serratus 572
 Serum 572
 Sesamoideus 572
 Setae 546
 Sigmoideus 572
 Simplex, simplicis 572
 Sinciput 562
 Singularis 572
 Sinister 568
 Sinus anales [168](#)
 Sinus aortae [242](#)
 Sinus basilaris [362](#)
 Sinus caroticus [270](#)
 Sinus cavernosus [362](#)
 Sinus clitoridis [218](#)
 Sinus conchae dorsalis 178
 Sinus conchae mediae 178
 Sinus conchae ventralis 178
 Sinus conchofrontalis [180](#)
 Sinus coronarius 338
 Sinus cutanei [544](#)
 Sinus durae matris [362](#)
 [Sinus epididymalis] [202](#), [230](#)
 Sinus frontalis, frontales 28, [180](#)
 (Sinus frontalis) [30](#)
 Sinus frontalis caudalis 16, [18](#), [24](#), [26](#), [180](#)
 Sinus frontalis lateralis [180](#)
 (Sinus frontalis lateralis) 32
 Sinus frontalis medialis [180](#)
 Sinus frontalis rostralis [180](#)
 Sinus frontalis rostr. intermedius [180](#)
 Sinus frontalis rostr. lat. [180](#)
 (Sinus frontalis rostr. lat.) 32
 Sinus frontalis rostr. med. [180](#)
 Sinus infraorbitalis [544](#)
 Sinus inguinalis 544
 Sinus interbasilaris [362](#)
 Sinus intercavernosi [362](#)
 Sinus interdigitalis [544](#)
 Sinus lacrimalis [30](#), [180](#)
 (Sinus lacrimalis) 32
 Sinus lactifer 560
 Sinus lymphaticus 402
 Sinus maxillaris [30](#), 32, 36, [180](#)
 Sinus maxillaris caudalis 32, [36](#), [180](#)
 Sinus maxillaris rostralis 32, [180](#)
 Sinus ophthalmicus 354
 Sinus palatinus [34](#), [36](#), [180](#)
 Sinus paranasalis [168](#), [544](#)
 Sinus paranasales 178
 Sinus petrosus dors. [362](#)
 Sinus petrosus ventr. [362](#)
 Sinus prostaticus [210](#)
 Sinus rectus [362](#)
 Sinus renalis 194
 Sinus sagittalis dors. [362](#)
 Sinus sagittalis ventr. [362](#)
 (Sinus sagittalis ventr.) [362](#)
 Sinus sigmoideus [362](#)
 Sinus sphenoidalis 16, 20, [24](#), [180](#)
 (Sinus sphenoidalis) [36](#)
 Sinus sphenopalatinus [180](#)
 Sinus tarsi 72
 Sinus temporalis [362](#)
 Sinus tonsillaris [150](#)
 Sinus transversus [362](#)
 Sinus transversus pericardii [234](#)
 Sinus trunci pulmonalis [242](#)
 Sinus tympani 534
 Sinus urethralis 206
Sinus urogenitalis 220
 Sinus venarum cavarum [238](#)
 Sinus venosus 567
 Sinus venosus sclerae 510
 Sinus v. buccalis [360](#)
 Sinus v. profundae faciei 352
 Sinus v. transversae faciei [360](#)
 Skeleton antebrachii [52](#)
 Skeleton appendiculare 48, 565
 Skeleton axiale 10, 565
 Skeleton brachii [50](#)
 Skeleton cruris [68](#)
 Skeleton femoris [66](#)
 Skeleton manus 56
 Skeleton pedis 72
 Skeleton thoracis [46](#)
 Solea 554
 Solea cornea 554
 Solitarius 572
 Solum pelvis osseum 64
 Spatia anguli iridocornealis 514
 Spatia interossea metacarpi 86
 Spatia interossea metatarsi 96
 Spatia intervaginalia 510
 Spatia zonularia 518
 Spatium episclerale 520
 [Spatium inguinale] 114
 Spatium interarcuale 40
 Spatium intercostale [46](#)
 Spatium interdigitale [8](#)
 Spatium interosseum antebrachii [54](#)
 Spatium interosseum antebrachii dist. [54](#)
 Spatium interosseum antebrachii prox. [54](#)
 Spatium lateropharyngeum [152](#)
 Spatium perichoroideale [-choroideale] 512
 Spatium perilymphaticum 528
 Spatium retroperitoneale [-peritoneale] [230](#)
 Spatium retropharyngeum [152](#)
 Sperma, spermatis 572
 Spermaticus 572
 [Sphaeroideus] 572
 Sphenoidalis 572
 Spheroideus 572
 Sphincter 572
 Spina alaris 62
 Spina cunei 556
 Spina helices 540
 Spina iliaca dors. caud. [62](#)
 Spina iliaca dors. cran. [62](#)
 [Spina iliaca ventralis caudalis] [62](#)

- Spina iliaca ventr. cran. [62](#)
 Spina ischiadica [62](#)
 Spina nasalis caudalis [36](#)
 Spina ossis sphenoidalis [18](#)
 Spina scapulae [48](#)
 Splanchnicus [572](#)
 Splanchnologia [566](#)
 Splenium corporis callosi [456](#)
 Spongiosus [578](#)
 Spurius [572](#)
 Squama frontalis [26](#)
 Squama occipitalis [16](#)
 Squamosus [572](#)
 Stapes [536](#)
 Statoconia [528](#)
 Status [572](#)
 Stella [572](#)
 Stellatus [572](#)
 Sternebrae [46](#)
 Sternum [46](#)
 Stoma, stomatis [572](#)
 Strata medullaria colliculi rostr. [436](#)
 Stratum circulare [160](#), [162](#), [164](#)
 Stratum externum [552](#)
 Stratum fibrosum [566](#)
 Stratum ganglionare n. optici [516](#)
 Stratum ganglionare retinae [516](#)
 Stratum granulare [452](#)
 Stratum granulare externum [458](#)
 Stratum granulare internum [458](#)
 Stratum granulosum [428](#)
 Stratum griseum colliculi rostr. [436](#)
 Stratum internum [552](#)
 Stratum longitudinale [160](#), [162](#), [164](#)
 Stratum medium [552](#)
 Stratum moleculare [428](#), [452](#)
 Stratum moleculare [plexiforme] [458](#)
 Stratum multiforme [458](#)
 Stratum nervosum [516](#)
 Stratum neuroepitheliale [516](#)
 Stratum neuronorum piriformium [428](#)
 Stratum periventriculare [438](#)
 Stratum pigmentosum [516](#)
 Stratum pigm. corporis ciliaris [516](#)
 Stratum pigm. iridis [516](#)
 Stratum pigm. retinae [516](#)
 Stratum pyramidale [452](#)
 Stratum pyramidale externum [458](#)
 Stratum pyramidale internum [458](#)
 Stratum spongiosum [210](#), [220](#)
 Stratum synoviale [566](#)
 Stratum zonale [444](#)
 Stratum zonale colliculi rostr. [436](#)
 Stria acustica [424](#)
 Stria habenularis thalami [442](#)
 Stria longitudinalis lat. [450](#)
 Stria longitudinalis med. [450](#)
 Stria malleolaris [536](#)
 Stria terminalis [440](#), [452](#), [460](#)
 Stria vascularis [530](#)
 Striae longitudinales [450](#)
 Striae medullares ventriculi quarti [430](#)
 Striatus [572](#)
 Stroma [567](#)
 Stroma iridis [514](#)
 Stroma ovarii [212](#)
 Stroma vitreum [518](#)
 Stylohyoideum [38](#)
 Stylopodium [572](#)
 Stylus [572](#)
 Subiculum [452](#)
 Substantia alba [416](#), [567](#)
 Subst. compacta [565](#)
 Subst. corticalis [565](#)
 Subst. gelatinosa [414](#), [567](#)
 Subst. grisea [414](#), [567](#)
 Subst. grisea centralis [432](#)
 Subst. intermedia centralis [414](#)
 Subst. intermedia lateralis [414](#)
 Subst. lentis [518](#)
 Subst. muscularis [204](#)
 Subst. nigra [434](#)
 Subst. perforata caudalis [432](#)
 Subst. perforata rostralis [448](#)
 Subst. propria corneae [512](#)
 Subst. propria sclerae [510](#)
 Subst. spongiosa [565](#)
 Subthalamus [442](#)
 Succus [572](#)
 Sudor, sudoris [572](#)
 Sulci [174](#)
 Sulci arteriosi [10](#)
 Sulci cerebelli [426](#)
 Sulci cerebri [446](#)
 Sulci cutis [544](#)
 Sulci gastrici [160](#)
 Sulci venosi [10](#)
 Sulcus abomasi [158](#)
 Sulcus accessorius dexter [156](#)
 Sulcus accessorius sinister [156](#)
 Sulcus alaris [176](#)
 Sulcus ansatus [454](#)
 Sulcus arteriae meningae caudalis [22](#)
 Sulcus basilaris [424](#)
 Sulcus bicipitalis lateralis [563](#)
 Sulcus bicipitalis medialis [563](#)
 Sulcus calcanei [72](#)
 Sulcus calcarinus [454](#)
 Sulcus caroticus [18](#)
 Sulcus carpi [56](#)
 Sulcus caudalis [156](#)
 Sulcus chiasmatis [20](#)
 Sulcus coronalis [454](#), [552](#)
 Sulcus coronarius [234](#)
 Sulcus coronarius dorsalis [156](#)
 Sulcus coronarius ventralis [156](#)
 Sulcus corporis callosi [450](#)
 Sulcus costae [46](#)
 Sulcus cranialis [156](#)
 Sulcus cruciatus [centralis] [454](#)
 Sulcus cunealis centralis [556](#)
 Sulcus dentoammonis [450](#)
 Sulcus diagonalis [454](#)
 Sulcus dorsalis penis [206](#)
 Sulcus ectomarginalis [ectosagittalis] [454](#)
 Sulcus ectosylvius caudalis [454](#)
 Sulcus ectosylvius rostralis [454](#)
 Sulcus endomarginalis [endosagittalis] [454](#)
 Sulcus endorhinalis [448](#)
 Sulcus extensorius [68](#)
 Sulcus fimbriammonis [450](#)
 Sulcus fimbriodentatus [450](#)
 Sulcus genualis [454](#)
 Sulcus gingivalis [140](#)
 Sulcus hamuli pterygoidei [20](#)
 Sulcus hippocampi [450](#)
 Sulcus hypothalamicus [436](#)
 Sulcus infrapalpebralis [562](#)
 Sulcus intermammarius [560](#), [562](#)
 Sulcus intermedius dorsalis [414](#), [418](#)
 Sulcus intertubercularis [50](#)
 Sulcus interventricularis paracanalicularis [234](#)
 Sulcus interventricularis subsinuatus [234](#)
 Sulcus jugularis [4](#)
 Sulcus lacrimalis [14](#), [32](#)
 Sulcus lateralis dorsalis [414](#), [418](#)
 Sulcus lateralis ventralis [414](#), [418](#)
 Sulcus lig. access. ossis femoris [64](#)
 Sulcus limbalis [552](#)
 Sulcus limitans [430](#)
 Sulcus limitans [567](#)
 Sulcus limitans bulbi olfactorii [448](#)
 Sulcus limitans trigoni olfactorii [448](#)
 Sulcus longitudinalis dexter [156](#)
 Sulcus longitudinalis dors. [56](#), [74](#)
 Sulcus longitudinalis palm. [56](#)
 Sulcus longitudinalis plant. [74](#)
 Sulcus longitudinalis sinister [156](#)
 Sulcus malleolaris [70](#)
 Sulcus marginalis [sagittalis] [454](#)
 Sulcus medialis cruris cerebri [432](#)
 Sulcus medianus [430](#)
 Sulcus medianus [dorsalis] [414](#), [418](#)
 Sulcus medianus linguae [146](#)
 Sulcus mentolabialis [562](#)
 Sulcus m. brachialis [50](#)
 Sulcus mylohyoideus [38](#)
 Sulcus n. canalis pterygoidei [20](#)
 Sulcus n. maxillaris [18](#)
 Sulcus n. ophthalmici [18](#)
 Sulcus n. spinalis [40](#)
 Sulcus nn. ophthalmici et maxill. [18](#)
 Sulcus obliquus [454](#)
 Sulcus obturatorius [64](#)
 Sulcus omasi [158](#)
 Sulcus omasoabomasicus [158](#)
 Sulcus palatinus [34](#)
 Sulcus palatinus major [32](#), [36](#)
 Sulcus paracunealis lateralis [556](#)
 Sulcus paracunealis medialis [556](#)
 Sulcus parietalis lateralis [58](#)
 Sulcus parietalis medialis [58](#)
 Sulcus pectoralis lateralis [4](#)
 Sulcus pectoralis medianus [4](#)

- Sulcus postericiatus [postcentralis] [454](#)
 Sulcus presylvius [prae-] [454](#)
 Sulcus proreus [orbitalis] [454](#)
 Sulcus pulmonalis [46](#)
 Sulcus reticuli [158](#)
 Sulcus rhinalis lateralis [448](#)
 Sulcus rhinalis medialis [448](#)
 Sulcus rostralis internus [454](#)
 Sulcus ruminoreticularis [156](#)
 Sulcus sclerae [510](#)
 Sulcus sinus petrosi dorsalis [22](#)
 Sulcus sinus petrosi ventr. [16](#)
 Sulcus sinus sagittalis dors. [10](#), [26](#), [28](#)
 Sulcus sinus transversi [16](#), [18](#)
 Sulcus solearis lateralis [58](#)
 Sulcus solearis medialis [58](#)
 Sulcus spiralis externus [530](#)
 Sulcus spirali internus [530](#)
 Sulcus splenialis [454](#)
 Sulcus supraorbitalis [26](#), [30](#)
 Sulcus suprasplenicus [454](#)
 Sulcus suprasylvius caudalis [454](#)
 Sulcus suprasylvius medius [454](#)
 Sulcus suprasylvius rostralis [454](#)
 Sulcus tali [72](#)
 Sulcus tendinis m. flex. digit. lat. [72](#)
 Sulcus tendinis m. peron. [fibularis] longi [70](#)
 Sulcus tendinum mm. extensoris dig. lat. et peron. [fibularis] brevis [70](#)
 Sulcus terminalis [238](#)
 Sulcus thalamocaudatus [460](#)
 Sulcus tonsillaris [150](#)
 Sulcus tubae auditivae [18](#)
 Sulcus tuberoinfundibularis [438](#)
 Sulcus tuberositatis tibiae [68](#)
 Sulcus tympanicus [24](#)
 Sulcus unguicularis [60](#)
 Sulcus urethralis [206](#)
 Sulcus venae cavae [168](#)
 Sulcus venae cavae caud. [190](#)
 Sulcus venae umbilicalis [168](#)
 Sulcus ventriculi [154](#)
 Sulcus vomeris [septalis] [30](#)
 Superficialis [568](#)
 Superior [568](#)
 Supinus [572](#)
 Sura [563](#)
 Suspensus [572](#)
 Sustentaculum tali [72](#)
 Sutura [565](#)
 Sutura coronalis [76](#)
 Sutura ethmoidomaxillaris [76](#)
 Sutura ethmoidonasalis [76](#)
 Sutura foliata [565](#)
 Sutura frontoethmoidalis [76](#)
 Sutura frontolacrimalis [76](#)
 Sutura frontomaxillaris [76](#)
 Sutura frontonasalis [76](#)
 Sutura frontopalatina [76](#)
 Sutura frontozygomatica [76](#)
 Sutura interfrontalis [76](#)
 Sutura interincisiva [78](#)
 Sutura intermandibularis [78](#)
 Sutura internasalis [78](#)
 Sutura lacrimoconchalis [78](#)
 Sutura lacrimomaxillaris [78](#)
 Sutura lacrimozygomatica [78](#)
 Sutura lambdoidea [76](#)
 Sutura maxilloincisiva [78](#)
 Sutura nasoincisiva [78](#)
 Sutura nasolacrimalis [78](#)
 Sutura nasomaxillaris [78](#)
 Sutura occipitointerparietalis [76](#)
 Sutura occipitomastoidea [76](#)
 Sutura occipitosquamosa [76](#)
 Sutura occipitotympanica [76](#)
 Sutura palatina mediana [78](#)
 Sutura palatina transversa [78](#)
 Sutura palatoethmoidalis [78](#)
 Sutura palatolacrimalis [78](#)
 Sutura palatomaxillaris [78](#)
 Sutura plana [565](#)
 Sutura pterygopalatina [76](#)
 Sutura pterygospheonoidalis [76](#)
 Sutura sagittalis [76](#)
 Sutura serrata [565](#)
 Sutura sphenoeethmoidalis [76](#)
 Sutura sphenofrontalis [76](#)
 Sutura sphenomaxillaris [76](#)
 Sutura sphenopalatina [76](#)
 Sutura sphenoparietalis [76](#)
 Sutura sphenosquamosa [76](#)
 Sutura squamosa [76](#)
 Sutura squamosofrontalis [76](#)
 Sutura squamosomastoidea [76](#)
 Sutura temporozygomatica [76](#)
 Sutura vomeroethmoidalis [76](#)
 Sutura vomeroincisiva [76](#)
 Sutura vomeromaxillaris [76](#)
 Sutura vomeropalatina [76](#)
 Sutura vomerosphenoidalis [76](#)
 Sutura zygomaticomaxillaris [76](#)
 Suturae capitis [76](#)
 Sympathicus [572](#)
 Symphysis [565](#)
 Symphysis intervertebralis [80](#)
 Symphysis ischiadica [90](#)
 Symphysis pelvina [90](#)
 Symphysis pubica [90](#)
 Synchronroses cranii [78](#)
 Synchronroses intersternales [82](#)
 Synchronroses sternales [82](#)
 Synchronrosis [565](#)
 Synchronrosis intermandibularis [78](#)
 Synchronrosis intersphenoidalis [78](#)
 (Synchronrosis intraoccipitalis basilat.) [78](#)
 (Synchronrosis intraoccipitalis squamolat.) [78](#)
 Synchronrosis manubriosternalis [82](#)
 Synchronrosis petrooccipitalis [78](#)
 Synchronrosis sphenoccipitalis [78](#)
 Synchronrosis sphenopetrosa [78](#)
 Synchronrosis xiphosternalis [62](#)
 Syndesmosis [565](#)
 Syndesmosis tympanostapedia [538](#)
 Synostosis [565](#)
 Synovia [566](#)
 Systema lymphaticum [402](#)
 Systema nervosum [567](#)
 Systema nervosum autonomicum [502](#)
 Systema nervosum centrale [414](#), [576](#)
 Systema nervosum periphericum [464](#), [576](#)
 Systema skeletale [565](#)
 Tabula ossis ischii [64](#)
 Tactilis [572](#)
 Tactus [572](#)
 Taenia [572](#)
 [Taenia chorioidea] [460](#)
 [Taenia dorsalis] [164](#)
 [Taenia fornicis] [450](#)
 [Taenia lateralis] [164](#)
 [Taenia libera lateralis] [166](#)
 [Taenia libera medialis] [166](#)
 [Taenia medialis] [164](#)
 [Taenia mesocolica medialis] [166](#)
 [Taenia telae] [567](#)
 [Taenia thalami] [442](#)
 [Taenia ventralis] [164](#)
 [Taenia ventriculi quarti] [430](#)
 [Taeniae caeci] [164](#)
 [Taeniae coli] [166](#)
 Talus [72](#)
 Tepetum lucidum [512](#)
 Tarsus [564](#)
 Tarsus inferior [522](#)
 Tarsus superior [522](#)
 Tectorius [572](#)
 Tectum mesencephali [432](#), [436](#)
 Tegmen tympani [22](#)
 Tegmen ventriculi quarti [430](#)
 Tegmentum mesencephali [432](#)
 [Tegmentum pontis] [424](#)
 Tegmentum rhombencephali [418](#)
 Tela chorioidea [chorioidea] ventriculi quarti [430](#), [462](#)
 Tela chorioidea [chorioidea] ventriculi tertii [436](#), [462](#)
 Tela subcutanea [544](#)
 Tela subcutanea coronae [550](#)
 Tela subcutanea cunei [556](#)
 Tela subcutanea limbi [550](#)
 Tela subcutanea soleae [554](#)
 Tela subcutanea tori [556](#)
 Tela submucosa [150](#), [152](#), [160](#), [162](#), [164](#), [188](#), [198](#), [566](#)
 Tela subserosa [160](#), [162](#), [164](#), [170](#), [566](#)
 Tela subserosa ves. felleae [172](#)
 Telencephalon [446](#)
 Tempora [562](#)
 Tempus, temporis [572](#)
 Tendo [566](#)

- Tendo calcaneus communis [128](#)
 Tendo communis [128](#)
 Tendo cricoesophageus [-oesophageus] [152](#)
 Tendo prepubicus [prae-] [114](#)
 Tendo symphysialis [126](#)
 Tenia [572](#)
 Tenia choroidea [460](#)
 Tenia dorsalis [164](#)
 Tenia fornicis [450](#)
 Tenia lateralis [164](#)
 Tenia libera lateralis [166](#)
 Tenia libera medialis [166](#)
 Tenia medialis [164](#)
 Tenia mesocolica lateralis [166](#)
 Tenia mesocolica medialis [166](#)
 Tenia telae [567](#)
 Tenia thalami [442](#)
 Tenia ventralis [164](#)
 Tenia ventriculi quarti [430](#)
 Teniae cecii [164](#)
 Teniae coli [166](#)
 Tensor [572](#)
 Tentorium cerebelli membranaceum [462](#)
 Tentorium cerebelli osseum [10](#)
 Tenuis [572](#)
 Teres, teretis [572](#)
 Terminalis [572](#)
 Terminatio [566](#)
 Terminations nervorum [544](#)
 Terminations nervorum liberae [568](#)
 Termini ad membra spectantes [568](#)
 Termini generales [569](#)
 Termini ontogenetici [220](#)
 Termini situm et directionem partium corporis indicantes [568](#)
 Testis [200](#)
 Thalamencephalon [442](#)
 Thalamus [442](#)
 Theca [572](#)
 Thorax, thoracis [562](#), [572](#)
 Thymus [232](#), [412](#)
 [Thyrohyoideum] [38](#)
 Thyrohyoideum [38](#)
 Tibia [68](#)
 Tibialis [572](#)
 Tonsilla lingualis [146](#)
 Tonsilla palatina [150](#)
 Tonsilla paraepiglottica [150](#)
 Tonsilla pharyngea [148](#)
 Tonsilla sublingualis [140](#)
 Tonsilla tubaria [148](#)
 Tonsilla veli palatini [150](#)
 Tori [548](#)
 Toruli tactiles [544](#)
 Torus carpeus [548](#), [563](#)
 Torus corneus [556](#)
 Torus digitalis [548](#), [556](#)
 Torus levatorius [148](#)
 Torus linguae [146](#)
 Torus metacarpeus [548](#), [563](#)
 Torus metatarsus [548](#), [564](#)
 Torus palatinus [12](#)
 Torus pyloricus [154](#)
 Torus tarseus [548](#), [564](#)
 Torus tubarius [148](#)
 Torus unguis [548](#), [556](#)
 Trabecula [402](#)
 Trabecula septomarginalis [240](#)
 Trabeculae carnae [236](#)
 Trabeculae corporis spongiosi [208](#)
 Trabeculae corporum cavernosorum [208](#)
 Trabeculae lienis [412](#)
 Trachea [188](#), [562](#)
 Tractus corticopontinus [426](#), [434](#)
 Tractus cruralis transversus [432](#)
 Tractus dorsolateralis [416](#)
 Tractus mamillotegmentalis [442](#)
 Tractus mamillothalamicus [442](#)
 Tractus mesencephalicus n. trigemini [424](#), [434](#)
 Tractus nervosi projectionis [440](#)
 Tractus olfactorius intermedius [456](#)
 Tractus olfactorius lateralis [448](#)
 Tractus olfactorius medialis [448](#)
 Tractus olivocerebellaris [422](#)
 Tractus opticus [438](#)
 Tractus paraventriculohypophysialis [442](#)
 Tractus pyramidalis [422](#), [426](#), [434](#)
 Tractus pyramidalis [corticospinalis] dors. [416](#)
 Tractus pyramidalis [corticospinalis] lat. [416](#)
 Tractus pyramidalis [corticospinalis] ventr. [416](#)
 Tractus reticulospinalis lateralis [416](#), [422](#)
 Tractus rubrospinalis [416](#), [422](#), [426](#)
 Tractus solitarius [418](#)
 Tractus spinalis n. trigemini [420](#), [424](#)
 Tractus spinocerebellaris dorsalis [416](#), [422](#)
 Tractus spinocerebellaris ventralis [416](#), [422](#)
 Tractus spinoolivaris [416](#)
 Tractus spinotectalis [416](#), [422](#)
 Tractus spinothalamicus [416](#), [434](#)
 Tractus spiralis foraminosus [534](#)
 Tractus supraopticohypophysialis [442](#)
 Tractus tectospinalis [426](#), [432](#)
 Tractus tegmenti centralis [422](#), [426](#), [432](#)
 Tractus tuberohypophysialis [442](#)
 Tractus vestibulospinalis [422](#)
 Tragus, Tragi [542](#), [546](#)
 Transversalis [568](#)
 Transversus [568](#)
 Trigona fibrosa [236](#)
 Trigonum femorale [130](#)
 Trigonum inguinale [230](#)
 Trigonum lemnisci [432](#)
 Trigonum n. hypoglossi [430](#)
 Trigonum n. vagi [430](#)
 Trigonum olfactorium [448](#)
 Trigonum phalangis prox. [58](#)
 Trigonum vesicae [198](#)
 Trochanter major [66](#)
 Trochanter minor [66](#)
 Trochanter tertius [66](#)
 Trochlea [520](#)
 Trochlea humeri [50](#)
 Trochlea muscularis [566](#)
 Trochlea ossis femoris [66](#)
 Trochlea radii [52](#)
 Trochlea tali [72](#)
 Trochlea tali distalis [72](#)
 Trochlea tali proximalis [72](#)
 Trunci lumbales [402](#)
 Trunci plexus [482](#), [492](#)
 Truncus [562](#)
 Truncus bicaroticus [244](#)
 Truncus bijugularis [344](#)
 Truncus brachiocephalicus [244](#)
 Truncus celiacus [coeliacus] [402](#)
 Truncus colicus [402](#)
 Truncus corporis callosi [456](#)
 Truncus costocervicalis [276](#), [278](#), [282](#)
 Truncus [fasc. atriovent.] [236](#)
 Truncus gastricus [402](#)
 Truncus hepaticus [402](#)
 Truncus intestinalis [402](#)
 Truncus jejunalis [402](#)
 [Truncus jugularis] [402](#)
 Truncus linguofacialis [258](#), [264](#)
 Truncus lumbosacralis [492](#)
 Truncus pundoepigastricus [320](#)
 Truncus pulmonalis [242](#)
 Truncus sympathicus [506](#)
 Truncus thyrocervicalis [thyreo-] [276](#)
 Truncus trachealis [402](#)
 Truncus vagalis dorsalis [478](#)
 Truncus vagalis ventralis [476](#)
 Truncus vagosympathicus [476](#)
 Truncus visceralis [402](#)
 Tuba auditiva [538](#)
 Tuba uterina [212](#)
 Tuber calcanei [72](#)
 Tuber cinereum [438](#)
 Tuber coxae [62](#)
 Tuber faciale [32](#)
 Tuber frontale [26](#)
 Tuber ischiadicum [64](#)
 Tuber maxillae [32](#)
 Tuber olecrani [54](#)
 Tuber omentale [168](#)
 Tuber parietale [26](#)
 Tuber sacrale [62](#)
 Tuber spinae scapulae [48](#)
 Tuber vermis [428](#)
 [Tuberculum acusticum] [420](#), [424](#)
 Tuberc. articulare [24](#)
 Tuberc. corniculatum [186](#)
 Tuberc. [coronae] dentis [144](#)
 Tuberc. costae [46](#)
 Tuberc. cuneiforme [186](#)
 Tuberc. dorsale [40](#), [42](#)

- Tuberc. flexorium [58](#)
 Tuberc. hippocampi [450](#)
 Tuberc. infraglenoidale [48](#)
 Tuberc. intercondylare lat. [68](#)
 Tuberc. intercondylare med. [68](#)
 Tuberc. intermedium [50](#)
 Tuberc. intervenosum [238](#)
 Tuberc. majus [50](#)
 Tuberc. minus [50](#)
 Tuberc. musculare [16](#)
 Tuberc. m. psoas minoris [62](#)
 Tuberc. m. scaleni ventr. [46](#)
 Tuberc. nuchale [16](#)
 Tuberc. nuclei cuneati [418](#)
 Tuberc. nuclei gracilis [418](#)
 Tuberc. olfactorium [448](#)
 Tuberc. pharyngeum [16](#)
 Tuberc. pubicum dorsale [64](#)
 Tuberc. pubicum ventrale [64](#)
 Tuberc. rostrale thalami [442](#)
 Tuberc. spongiosum [208](#)
 Tuberc. supraglenoidale [48](#)
 Tuberc. tali [72](#)
 Tuberc. trochleae ossis femoris [66](#)
 Tuberc. urethrale [218](#)
 Tuberc. ventrale [40](#), [42](#)
 Tuberositas deltoidea [50](#)
 Tuberos. flexoria [58](#)
 Tuberos. glutea [glutaea] [66](#)
 Tuberos. iliaca [62](#)
 Tuberos. m. bicipitis [66](#)
 Tuberos. m. iliocostalis [46](#)
 Tuberos. m. longissimi [46](#)
 Tuberos. m. sternomandibularis [38](#)
 Tuberos. ossis metacarpalis III [56](#)
 Tuberos. ossis metatarsalis III [74](#)
 Tuberos. radii [52](#)
 Tuberos. sacralis [44](#)
 Tuberos. supracondylaris lat. [66](#)
 Tuberos. supracondylaris med. [66](#)
 Tuberos. teres major [50](#)
 Tuberos. teres minor [50](#)
 Tuberos. tibiae [68](#)
 Tubuli epidermales [548](#), [550](#), [554](#), [556](#)
 Tubuli renales [194](#)
 Tubuli seminiferi contorti [200](#)
 Tubuli seminiferi recti [200](#)
 Tubulus [572](#)
 Tubus [572](#)
 Tunica adventitia [152](#), [168](#), [196](#), [202](#), [204](#), [216](#), [220](#), [566](#)
 Tunica albuginea [200](#), [212](#), [566](#)
 Tunica albuginea corporis spongiosi [208](#)
 Tunica albuginea corporum cavernosorum [208](#)
 Tunica conjunctiva [524](#)
 Tunica conjunctiva bulbi [524](#)
 Tunica conjunctiva palpebrarum [524](#)
 Tunica dartos [210](#)
 Tunica externa [567](#)
 Tunica fibrosa [170](#), [566](#)
 Tunica fibrosa bulbi [510](#)
 Tunica flava abdominis [114](#)
 Tunica interna bulbi [516](#)
 Tunica intima [567](#)
 Tunica media [567](#)
 Tunica mucosa [150](#), [152](#), [160–164](#), [186](#), [188](#), [196](#), [198](#), [202](#), [204](#), [210](#), [214](#), [216](#), [220](#), [538](#), [566](#)
 Tunica mucosa cavi tympani [538](#)
 Tunica mucosa linguae [146](#)
 Tunica mucosa nasi [178](#)
 Tunica mucosa oris [140](#)
 Tunics mucosa ves. felleae [172](#)
 Tunica muscularis [152](#), [160–164](#), [196](#), [198](#), [202](#), [204](#), [210](#), [214](#), [216](#), [220](#), [556](#)
 Tunica muscularis pharyngis [152](#)
 Tunica muscularis ves. felleae [172](#)
 Tunica serosa [160–164](#), [170](#), [198](#), [202](#), [214](#), [216](#), [226](#), [412](#), [567](#)
 Tunica serosa ves. felleae [172](#)
 Tunica vaginalis [202](#)
 Tunica vasculosa bulbi [512](#)
 Tunicae funiculi spermatici et testis [202](#)
 Tympanochoideum [38](#)
 Tympanum [572](#)
 Ueber [560](#), [562](#)
 Ulna [54](#)
 Ulnaris [572](#)
 Umbilicus [562](#)
 Umbo membranae tympani [536](#)
 Uncinatus [572](#)
 Uncus [572](#)
 Unguicula [550](#), [563](#), [564](#)
 Ungula [550](#), [563](#), [564](#)
 Urachus [198](#)
 Ureter [196](#)
 Urethra feminina [220](#)
 Urethra masculina [210](#)
 Urina [572](#)
 Uterus [214](#)
 Uterus bicornis [214](#)
 Uterus masculinus [210](#)
 Utriculus [526](#)
 Uvula [palatina] [150](#)
 Uvula [vermis] [428](#)
 Vagina [216](#)
 Vag. bulbi [520](#)
 Vag. carotica [106](#)
 Vag. distalis tendinum m. extensoris digit. communis [134](#)
 Vag. distalis tendinum m. extensoris digit. longi [138](#)
 Vag. externa n. optici [510](#)
 Vag. fibrosa tendinis [566](#)
 Vagg. fibrosae digitorum manus [122](#)
 Vagg. fibrosae digitorum pedis [130](#)
 Vag. interna n. optici [510](#)
 Vag. m. recti abdominis [112](#)
 Vag. processus styloidei [24](#)
 Vag. synovialis tendinis [566](#)
 Vag. synovialis communis mm. flexorum [134](#)
 Vag. synovialis intertubercularis [132](#)
 Vag. synovialis m. coracobrachialis [132](#)
 Vag. synovialis m. obliqui dorsalis [132](#), [520](#)
 Vagg. synoviales tendinum digitorum manus [122](#), [134](#)
 Vagg. synoviales tendinum digitorum pedis [130](#), [138](#)
 Vag. tendinis m. abductoris digiti I [pollicis] longi [134](#)
 Vag. tendinis m. digastrici [132](#)
 [Vag. tendinis m. extensoris carpi obliqui] [134](#)
 Vag. tendinis m. extensoris carpi radialis [134](#)
 Vag. tendinis m. extensoris carpi ulnaris [m. ulnaris lateralis] [134](#)
 Vag. tendinis m. extensoris digit. lat. manus [134](#)
 Vag. tendinis m. extensoris digit. lat. pedis [138](#)
 Vag. tendinis m. flexoris carpi radialis [134](#)
 Vag. tendinis m. flexoris carpi ulnaris [134](#)
 Vag. tendinis m. flexoris digit. lat. [138](#)
 Vag. tendinis m. flexoris digit. med. [138](#)
 Vag. tendinis m. peron. [fibularis] longi lat. [138](#)
 Vag. tendinis m. peron [fibularis] longi plantaris [138](#)
 Vag. tendinis m. peron [fibularis] tertii [138](#)
 Vag. tendinis m. tibialis caud. [138](#)
 Vag. tendinis m. tibialis cran. [138](#)
 Vag. tendinum m. extensoris digit. communis [134](#)
 Vag. tendinum m. extensoris digit. longi [138](#)
 Vagus [572](#)
 Vallecule cerebelli [426](#)
 Vallecule epiglottica [150](#)
 Vallecule lateralis cerebri [448](#)
 [Vallum] [550](#)
 Valva aortae [240](#)
 Valva atrioventricularis dextra [238](#)
 Valva atrioventricularis sinistra [240](#)
 [Valva bicuspidalis] [240](#)
 Valva cecocolica [caeco-] [164](#)
 [Valva mitralis] [240](#)
 [Valva tricuspidalis] [238](#)
 Valva trunci pulmonalis [240](#)
 Valvula foraminis ovalis [240](#)
 Valvula lymphatica [567](#)
 Valvula semilunaris dextra [240](#)
 Valvula semilunaris intermedia [240](#)
 Valvula semilunaris septalis [240](#)

- Valvula semilunaris sinistra [240](#)
 Valvula sinus coronarii [238](#)
 Valvula venae cavae caud. [238](#)
 Valvula venosa [567](#)
 Vas anastomoticum [567](#)
 Vas capillare [567](#)
 Vas collaterale [567](#)
 Vas lymphaticum [402](#), [567](#)
 Vas prominens [530](#)
 Vas spirale [530](#)
 Vasa auris internae [530](#)
 Vasa lymphatica afferentia [402](#)
 Vasa lymphatica efferentia [402](#)
 Vasa lymphatica profunda [402](#)
 Vasa lymphatica superficialia [402](#)
 Vasa sanguinea retinae [516](#)
 Vasa vasorum [567](#)
 Vascularis [572](#)
 Vastus [572](#)
 Vela abomasica [162](#)
 Vellus, velleries [572](#)
 Velum medullare caudale [430](#)
 Velum medullare rostrale [430](#)
 [Velum palatinum] [140](#), [150](#)
 Velum uteri [214](#)
 Vena, Venae [338](#), [567](#)
 V. abdominalis caudalis [388](#), [390](#)
 V. abdominalis cranialis [272](#)
 Vv. adrenales [272](#)
 V. alveolaris inferior [356](#), [358](#), [360](#)
 V. angularis oculi [348](#), [350](#), [354](#)
 V. angularis oris [348](#), [350](#), [354](#)
 V. aqueductus [aquae-] vestibuli [530](#)
 Vv. arcuatae [196](#)
 Vv. articulares temporomandib. [356](#), [358](#), [360](#)
 V. auricularis caudalis [356](#), [358](#), [360](#)
 V. auricularis intermedia [356](#), [358](#), [360](#)
 V. auricularis lateralis [356](#), [358](#), [360](#)
 V. auricularis medialis [356](#), [358](#), [360](#)
 V. auricularis profunda [356](#), [358](#), [360](#)
 V. auricularis rostralis [356](#), [358](#), [360](#)
 V. axillaris [364](#)
 V. axillobrachialis [364](#)
 V. azygos dextra [340](#)
 V. azygos sinistra [338](#)
 Vv. basivertebrales [338](#)
 V. bicipitalis [366](#)
 V. brachialis [366](#)
 V. brachialis supf. [366](#)
 V. brachiocephalica [344](#)
 Vv. bronchiales [338](#)
 V. broncho-esophagea [-oesophagea] [340](#)
 V. buccalis [356](#), [358](#), [360](#)
 V. bulbi penis [380](#)–[386](#)
 V. bulbi vestibuli [380](#)–[386](#)
 V. canaliculi cochleae [530](#)
 Vv. capsulares [196](#)
 V. caudalis [coccygea] dors. [380](#)
 V. caudalis [coccygea] dorsolat. [378](#), [386](#)
 V. caudalis [coccygea] lat. [380](#)
 V. caudalis [coccygea] mediana [378](#), [386](#)
 V. caudalis [coccygea] ventrolat. [378](#), [386](#)
 Vv. caudales femoris [396](#), [398](#)
 V. caudalis femoris [400](#)
 V. caudalis femoris dist. [392](#)
 V. caudalis femoris media [392](#)
 V. caudalis femoris prox. [392](#)
 V. cava caudalis [372](#)
 V. cava cranialis [340](#)
 Vv. cavernosae [208](#)
 V. cecalis [caecalis] [376](#)
 V. cecalis [caecalis] lat. [376](#)
 V. cecalis [caecalis] med. [376](#)
 Vv. centrales [170](#)
 V. cephalica [346](#)
 V. cephalica accessoria [346](#)
 Vv. cerebelli dorsales [364](#)
 Vv. cerebelli ventrales [364](#)
 Vv. cerebri [364](#)
 Vv. cerebri dorsales [364](#)
 Vv. cerebri internae [364](#)
 V. cerebri magna [364](#)
 Vv. cerebri ventrales [364](#)
 V. circumflexa femoris lat. [392](#), [396](#)–[400](#)
 V. circumflexa femoris med. [388](#), [390](#)
 V. circumflexa humeri caud. [364](#)
 V. circumflexa humeri cran. [364](#)
 V. circumflexa ilium profunda [372](#), [378](#)
 V. circumflexa ilium supf. [388](#)
 V. circumflexa scapulae [364](#)
 V. clitoridis [362](#), [380](#), [384](#), [386](#)
 V. clitoridis media [390](#)
 V. colica dextra [376](#)
 V. colica media [376](#), [378](#)
 V. colica sinistra [378](#)
 Vv. colicae dextrae [376](#)
 V. collateralis media [364](#), [366](#)
 V. collateralis radialis [364](#), [366](#)
 V. collateralis ulnaris [366](#)
 V. comitans [567](#)
 V. comitans a. carotidis externae [344](#)
 V. comitans a. lingualis [344](#)
 Vv. conjunctivales [354](#), [356](#), [358](#)
 Vv. cordis [338](#)
 Vv. cordis dextrae [338](#)
 V. cordis magna [338](#)
 V. cordis media [338](#)
 Vv. cordis minimae [338](#)
 V. cornualis [358](#)
 V. coronalis [346](#), [370](#), [388](#), [390](#), [398](#), [400](#)
 (V. corporis callosi) [364](#)
 V. costoabdominalis dors. [338](#), [340](#)
 V. costocervicalis [340](#)
 V. costocervicalis sinistra [344](#)
 V. cremasterica [390](#)
 V. cricothyroidea [-thyroidea] [344](#), [360](#)
 V. cutanea [567](#)
 Vv. cysticae [374](#)
 Vv. digit. dors. communes I–IV, II–IV [346](#)
 V. digit. dors. communis II [346](#), [392](#), [400](#)
 Vv. digit. dors. communes II–IV [388](#), [392](#)
 V. digit. dors. communis III [346](#)
 Vv. digit. dors. communes III et IV [392](#)
 Vv. digit. dors. communes III et IV, II–IV [390](#)
 V. digit. dors. communis IV [346](#)
 V. digit. dors. II abaxialis [392](#)
 V. digit. dors. V abaxialis [346](#), [392](#)
 Vv. digit. dors. propriae [346](#), [388](#), [390](#), [392](#)
 V. digit. lateralis [370](#), [400](#)
 V. digit. medialis [370](#), [400](#)
 [V. digit. palmaris propria III lat.] [370](#)
 [V. digit. palmaris propria III med.] [370](#)
 Vv. digit. palm. communes I–IV [368](#)
 V. digit. palm. communis II [370](#)
 [V. digit. palm. communis II] [370](#)
 Vv. digit. palm. communes II–IV [368](#)
 V. digit. palm. communis III [370](#)
 [V. digit. palm. communis III] [370](#)
 V. digit. palm. communis IV [370](#)
 Vv. digit. palm. propriae [368](#)
 V. digit. palm. propria II axialis [370](#)
 V. digit. palm. propria III abaxialis [370](#)
 Vv. digit. palm. propriae III et IV axiales [370](#)
 V. digit. palm. propria IV abaxialis [370](#)
 V. digit. palm. propria V axialis [370](#)
 V. digit. palm. V abaxialis [366](#)
 V. digit. plant. communis [398](#)
 [V. digit. plant. communis] [400](#)
 Vv. digit. plant. communes II et IV, II–IV [394](#)
 Vv. digit. plant. communes II–IV [396](#)
 V. digit. plant. communis III [398](#)
 [V. digit. plant. communis III] [400](#)
 Vv. digit. plant. communes IV, II–IV [398](#)
 Vv. digit. plant. propriae [394](#), [396](#), [398](#)
 V. digit. plant. propria II axialis [398](#)

- V. digit. plant. propria III abaxialis* [398](#)
 [V. digit. plant. propria III lat.] [400](#)
 [V. digit. plant. propria III med.] [400](#)
Vv. digit. plant. propriae III et IV axiales [398](#)
V. digit. plant. II abaxialis [394](#)
V. digit. plant. V abaxialis [394](#)
Vv. diploicae [362](#)
V. diploica frontalis [362](#)
V. diploica occipitalis [362](#)
V. diploica parietalis [362](#)
Vv. diverticuli [374](#)
Vv. dorsales linguae [348](#), [350](#), [352](#)
Vv. dorsales nasi [354](#)
V. dorsalis clitoridis [380–386](#)
V. dorsalis nasi [348](#), [350](#), [354](#)
V. dorsalis pedis [394–400](#)
V. dorsalis penis [380–386](#)
V. ductus deferentis [380](#), [384](#)
Vv. emissariae [362](#)
V. emissaria [567](#)
V. emissaria canalis carotici [362](#)
V. emissaria canalis n. hypoglossi [362](#)
V. emissaria fissurae orbitalis [362](#)
V. emissaria foraminis jugularis [362](#)
V. emissaria foraminis laceri [362](#)
V. emissaria foraminis orbitotundi [362](#)
V. emissaria foraminis ovalis [362](#)
V. emissaria foraminis retroarticularis [362](#)
V. emissaria foraminis rotundi [362](#)
V. emissaria mastoidea [362](#)
V. emissaria occipitalis [362](#)
V. epigastrica caudalis [388](#), [390](#)
V. epigastrica caudalis supf. [388](#), [390](#)
V. epigastrica cranialis [344](#)
V. epigastrica cran. supf. [344](#), [364](#)
Vv. esophageae [oesophageae] [338](#)
V. esophagea [oesophagea] caud. [376](#)
V. ethmoidalis externa [354](#), [356](#), [358](#)
V. facialis [348](#), [350](#), [352](#)
V. femoralis [392](#), [396–400](#)
V. frontalis [348](#), [354](#)
V. gastrica dextra [374](#)
V. gastrica sinistra [374](#), [376](#)
V. gastrica sinistra parietalis [374](#)
V. gastrica sinistra visceralis [374](#)
Vv. gastricae breves [374](#)
V. gastroduodenalis [374](#)
V. gastroepiploica dextra [374](#)
V. gastroepiploica sinistra [374](#), [376](#)
Vv. genus [394–400](#)
V. genus descendens [392](#), [396–400](#)
Vv. glandulares [352](#), [358](#)
V. glandularis [348](#), [350](#), [356](#)
V. glutea [glutaea] caud. [380–386](#)
V. glutea [gluteae] cran. [380–386](#)
 (V. hemiazygos dextra) [338](#)
 (V. hemiazygos sinistra) [340](#)
Vv. hepaticae [374](#)
V. hepatica dextra [374](#)
V. hepatica media [374](#)
V. hepatica sinistra [374](#)
Vv. ilei [376](#)
V. ileocolica [376](#)
V. iliaca communis [378](#)
V. iliaca externa [388](#)
V. iliaca interna [380](#)
V. iliocofemoralis [390](#)
V. iliolumbalis [378–384](#)
V. infraorbitalis [350](#), [354](#)
Vv. intercostales dorsales [338](#), [340](#), [342](#)
Vv. intercostales dors. II–VI (sin.), II–IV (dext.) [342](#)
Vv. intercostales dors. III et IV [340](#)
Vv. intercostales dors. III et IV (V) [342](#)
Vv. intercostales ventrales [344](#)
V. intercostalis dorsalis I [340](#), [342](#)
V. intercostalis dorsalis II [340](#), [342](#)
V. intercostalis suprema [340](#), [342](#)
V. interdigitalis [368](#), [370](#), [394–398](#)
Vv. interlobares [196](#)
Vv. interlobulares [170](#), [196](#)
V. interossea caudalis [366](#)
V. interossea communis [366](#)
V. interossea cranialis [366](#)
V. interossea cruris [396](#)
Vv. intervertebrales [340](#), [342](#)
V. intervertebralis [338–342](#), [372](#), [378](#), [386](#)
Vv. jejunaes [376](#)
V. jugularis externa [346](#)
V. jugularis interna [344](#)
Vv. labiales inferiores [352](#)
Vv. labiales superiores [354](#)
V. labialis dorsalis [380](#), [382](#)
V. labialis dorsalis et mammaria [384](#)
V. labialis inferior [348](#), [350](#), [352](#)
V. labialis superior [348–354](#)
V. labialis ventralis [388](#), [390](#)
Vv. labyrinthi [362](#), [530](#)
V. lacrimalis [354](#), [356](#), [358](#)
V. laryngea cranialis [344](#), [348–352](#)
V. laryngea impar [348](#), [350](#)
V. lateralis nasi [348](#), [350](#), [354](#)
V. lienalis [374](#)
V. lingualis [348](#), [350](#), [352](#)
V. lingualis impar [348](#)
V. linguofacialis [348](#)
Vv. lumbales [372](#)
Vv. lumbales I et II (III) [338](#), [340](#)
V. lumbalis V, VI, VII [378](#)
V. malaris [350](#), [354](#), [358](#)
V. malleolaris caudalis lat. [400](#)
 [V. mammaria caudalis] [390](#)
 [V. mammaria cranialis] [390](#)
 [V. marginis ventricularis sinistri] [338](#)
V. masseterica [356](#), [358](#)
V. masseterica ventralis [358](#), [360](#)
V. maxillaris [356](#)
V. mediana [368](#)
V. mediana cubiti [346](#)
Vv. mediastinales [344](#)
V. mentalis [358](#), [360](#)
V. mesenterica caudalis [378](#)
V. mesenterica cranialis [376](#)
V. metacarpea dorsalis [368](#)
V. metacarpea dorsalis III [370](#)
Vv. metacarpeae dors. I–IV [368](#)
Vv. metacarpeae palm. I–IV [368](#)
Vv. metacarpeae palm. II et III [370](#)
Vv. metacarpeae palm. II–IV [368](#), [370](#)
V. metatarsae dors. II [400](#)
V. metatarsae dors. III [396](#), [398](#)
Vv. metatarsae dors. II et IV [396](#)
Vv. metatarsae dors. II–IV, II (III) IV [394](#)
Vv. metatarsae plant. II et III [400](#)
Vv. metatarsae plant. II–IV [394](#), [396](#), [398](#)
V. musculophrenica [344](#)
V. obliqua atrii sinistri [338](#)
V. obturatoria [380–384](#), [390](#)
V. occipitalis [344](#), [360](#)
V. omobrachialis [346](#)
V. ophthalmica externa dors. [354](#), [356](#), [358](#)
V. ophthalmica externa ventr. [352](#), [356](#)
V. ophthalmica interna [354](#), [364](#)
V. ovarica dextra [372](#)
V. ovarica sinistra [372](#), [378](#)
V. palatina, Vv. palatinae [344](#), [356–360](#)
V. palatina ascendens [348](#), [350](#)
V. palatina descendens [348](#), [350](#), [354](#)
V. palatina major [348](#), [350](#), [354](#)
V. palatina minor [348](#), [350](#), [354](#)
V. palpebrae tertiae [358](#)
V. palpebralis inferior [348](#), [350](#)
V. palpebralis inferior lat. [356](#), [358](#)
V. palpebralis inferior med. [348](#), [354](#)
V. palpebralis superior lat. [356](#), [358](#)
V. palpebralis superior med. [348](#), [350](#), [354](#)
Vv. pancreaticae [374](#), [376](#)
V. pancreaticoduodenalis caud. [374](#)
V. pancreaticoduodenalis cran. [374](#)

- V. penis [380–386](#)
 V. penis cranialis [390](#)
 V. penis media [390](#)
 Vv. perforantes [344](#)
 V. pericardiacophrenica [344](#)
 V. perinealis dorsalis [380](#), [382](#), [384](#)
 V. perinealis ventralis [380–386](#)
 V. pharyngea, Vv. pharyngeae [344](#), [358](#), [360](#)
 V. pharyngea ascendens [344](#), [348–352](#), [360](#)
 V. phrenica caudalis [372](#)
 Vv. phrenicae craniales [372](#)
 V. plantaris lateralis [396](#), [398](#), [400](#)
 V. plantaris medialis [392](#), [396–400](#)
 V. poplitea [394–400](#)
 V. portae [374](#)
 V. profunda antebrachii [368](#), [370](#)
 V. profunda brachii [366](#)
 V. profunda clitoridis [380–386](#)
 V. profunda faciei [348](#), [350](#), [352](#)
 V. profunda femoris [388](#), [390](#)
 V. profunda linguae [348](#), [350](#), [352](#)
 V. profunda penis [384](#), [386](#)
 V. prostatica [380–386](#)
 Vv. pterygoideae [356](#), [358](#), [360](#)
 V. pudenda externa [388](#), [390](#)
 V. pudenda interna [380–386](#)
 V. pudendoepigastrica [388](#), [390](#)
 Vv. pulmonales [338](#)
 V. pulm. lobi caud. dextri [338](#)
 V. pulm. lobi caud. sinistri [338](#)
 V. pulm. lobi cran. dextri [338](#)
 V. pulm. lobi cran. sinistri [338](#)
 V. pulm. lobi medii [338](#)
 V. radialis [368](#), [370](#)
 Vv. radiales supf. [366](#)
 V. rectalis caudalis [380–386](#)
 V. rectalis cranialis [378](#)
 V. rectalis media [380](#), [384](#), [386](#)
 V. recurrens interossea [366](#)
 V. recurrens ulnaris [366](#)
 V. renalis [372](#)
 Vv. renis [196](#)
 V. reticularis [376](#)
 V. ruminalis dextra [376](#)
 V. ruminalis sinistra [376](#)
 V. sacralis mediana [378](#)
 (V. sacralis mediana) [378](#)
 V. saphena lateralis [parva] [388](#), [390](#), [392](#), [400](#)
 V. saphena medialis [magna] [392](#), [396–400](#)
 V. scapularis dorsalis [340](#), [342](#)
 V. scrotalis dorsalis [380](#), [382](#)
 V. scrotalis ventralis [388](#), [390](#)
 Vv. sigmoideae [378](#)
 V. sphenopalatina [348](#), [350](#), [354](#)
 Vv. spinales [338](#)
 V. spiralis modioli [530](#)
 V. sternocleidomastoidea [356](#)
 V. stylomastoidea [344](#), [356–360](#)
 V. subclavia [364](#)
 [V. subcutanea abdominis] [344](#), [364](#)
 V. sublingualis [348](#), [350](#), [352](#)
 V. submentalis [348](#), [350](#), [352](#)
 V. subscapularis [364](#)
 V. superficialis ventr. linguae [350](#)
 V. supraorbitalis [354](#), [358](#)
 [Vv. suprarenales] [372](#)
 V. suprascapularis [346](#), [364](#)
 [V. supratrochlearis] [348](#), [354](#)
 V. tarsea lateralis [392](#), [394](#), [396](#)
 V. tarsea medialis [392](#), [394](#), [396](#)
 V. tarsea perforans [398](#), [400](#)
 V. tarsea perforans dist. [396](#)
 V. tarsea perforans prox. [396](#)
 Vv. temporales profundae [356](#)
 V. temporalis profunda [358](#), [360](#)
 V. temporalis supf. [356](#), [358](#), [360](#)
 V. testicularis dextra [372](#)
 V. testicularis sinistra [372](#), [378](#)
 V. thalamostriata [364](#)
 V. thoracica externa [364](#)
 V. thoracica interna [344](#)
 V. thoracica lateralis [364](#)
 V. thoracica supf. [364](#)
 V. thoracodorsalis [364](#)
 Vv. thymicae [344](#)
 V. thyroidea [thyroidea] caud. [344](#)
 V. thyroidea [thyroidea] cran. [344](#), [346](#), [360](#)
 V. thyroidea [thyroidea] media [344](#), [346](#)
 (V. thyroidea [thyroidea] media) [360](#)
 V. tibialis caudalis [394–400](#)
 V. tibialis cranialis [394–400](#)
 V. transversa cubiti [366](#)
 V. transversa faciei [356](#), [358](#), [360](#)
 V. ulnaris [366](#)
 V. umbilicalis [374](#)
 V. urethralis [380](#)
 V. uterina [372](#), [380](#), [384](#), [390](#)
 V. vaginalis [380–386](#)
 V. vaginalis accessoria [384](#)
 V. vertebralis [340](#), [342](#)
 V. vertebralis thoracica [340](#), [342](#)
 V. vesicalis caudalis [380–386](#)
 V. vesicalis cranialis [372](#), [388](#)
 V. vesicalis media [388](#)
 Vv. vestibulares [530](#)
 V. vestibularis [384](#)
 Vv. vorticosae [354](#), [356](#), [358](#)
 Venter [566](#)
 Venter caudalis [102](#)
 Venter rostralis [102](#)
 Ventralis [568](#)
 Ventriculus [154](#)
 Ventriculus cordis [236](#)
 Ventriculus dexter [238](#)
 Ventriculus laryngis [186](#)
 Ventriculus lateralis [460](#)
 Ventriculus quartus [430](#)
 Ventriculus sinister [240](#)
 Ventriculus terminalis [414](#)
 Ventriculus tertius [436](#)
 Venula [567](#)
 Venula lateralis retinae dorsalis [616](#)
 Venula lateralis retinae ventralis [516](#)
 Venula macularis dorsalis [516](#)
 Venula macularis ventralis [516](#)
 Venula medialis retinae dorsalis [516](#)
 Venula medialis retinae ventralis [516](#)
 Venulae rectae [196](#)
 Venulae stellatae [196](#)
 Vermis [428](#)
 Vertebra anticlinalis [42](#)
 Vertebrae caudales [coccygeae] [44](#)
 Vertebrae cervicales [40](#)
 Vertebrae lumbales [42](#)
 [Vertebrae sacrales] [44](#)
 Vertebrae thoracicae [42](#)
 Vertex [10](#), [562](#)
 Vertex corneae [512](#)
 [Vertex vesicae] [198](#)
 Verus [572](#)
 Vesica fellea [172](#)
 Vesica urinaria [198](#)
 Vesicalis [572](#)
 Vesicula ophthalmica [510](#)
 Vestibularis [572](#)
 Vestibulum [532](#)
 Vestibulum bursae omentalis [226](#)
 Vestibulum esophagi [oesophagi] [150](#)
 Vestibulum laryngis [186](#)
 Vestibulum nasi [176](#)
 Vestibulum oris [140](#)
 Vestibulum vaginae [218](#)
 Vestigium [572](#)
 Vibrissae [546](#)
 Villi chorii [220](#)
 Villi intestinales [162](#)
 Villi synoviales [566](#)
 Villus [572](#)
 Vincula tendinum [122](#), [130](#)
 Vinculum lingulae [428](#)
 Viscus, visceris [572](#)
 Visus [572](#)
 Vita [572](#)
 Vitellus [573](#)
 Vitreus [573](#)
 Vocalis [573](#)
 Vomer [30](#)
 Vortex cordis [236](#)
 Vortex pilorum convergens [546](#)
 Vortex pilorum divergens [546](#)
 Vorticosus [573](#)
 [Vulva] [218](#), [563](#)

 Xiphoideus [573](#)

 Zeugopodium [573](#)
 Zona alba [552](#)
 Zona columnaris ani [168](#)
 Zona cutanea [168](#)
 Zona incerta [442](#)
 Zona intermedia [168](#)
 Zona orbicularis [90](#)
 [Zona parenchymatosa] [212](#)
 [Zona vasculosa] [212](#)
 Zonula ciliaris [518](#)
 Zygomaticus [573](#)



The Nomina Anatomica Veterinaria (N.A.V.) published by the World Association of Veterinary Anatomists make up a list of terms without illustrations and definitions. In the present Illustrated Veterinary Anatomical Nomenclature more than 6500 structures named in the N.A.V. are depicted and defined, aiding the user in understanding anatomy and in clarifying its concepts. The book is a reference text for teachers, researchers, veterinarians, and students. Its arrangement adheres strictly to that of the N.A.V. and focuses on the gross anatomical structures of the cat, dog, pig, ox, sheep, goat, and horse.

ISBN 978-3-8304-1069-0



9 783830 410690

www.enke.de

Copyrighted material